

Introduction

Radiography involves the use of x-radiation and thus is potentially dangerous if mishandled. For your own sake, and that of the staff, patient, and public, it is essential that you gain adequate knowledge of radiographic techniques and radiation health and safety, prior to performing clinical procedures.

This course is intended to provide current, vital information on film and tube head placement, to serve as a guide to acquire new skills or refine current skills, and allow you to test yourself as you progress through the pages.

When you complete a continuing education course on the Dental ResourceNet, a form will come up that requests your name, address, etc. If you are a member of the AGD, make sure to fill out the field that asks for your AGD membership number (if you are not an AGD member, leave blank). When you hit submit, a copy of the 'proof of completion' is e-mailed directly to the AGD and P&G. For your records, make sure to print a copy of the 'proof of completion' certificate.

Overview

Radiography involves the use of x-radiation and thus is potentially dangerous if mishandled. For your own sake, and that of the staff, patient, and public, it is essential that you gain adequate knowledge of radiographic techniques and radiation health and safety, prior to performing clinical procedures.

This course is intended to provide current, vital information on film and tube head placement, to serve as a guide to acquire new skills or refine current skills, and allow you to test yourself as you progress through the pages

Learning Objectives

Upon the completion of this course, the dental professional will be able to:

- Understand the basic principles and concepts of intraoral procedures.
 - Demonstrate the paralleling technique of intraoral radiology.
 - Explain the bisecting angle technique of intraoral radiology.
 - Identify proper techniques for bitewing radiography.
 - Describe intraoral occlusal techniques.
-

Course Contents

- Introduction
- Intraoral Procedures
- Paralleling Technique
- Paralleling Technique Methodology
- The Bisecting Angle Technique
- Bisecting Angle Methodology
- Bitewing Radiography
- Intraoral Occlusal Radiography
- Digital Radiology
- Summary
- Glossary
- Course Test
- About the Authors

Introduction

Radiography involves the use of x-radiation and thus is potentially dangerous if mishandled. For your own sake, and that of the staff, patient, and public, it is essential that you gain adequate knowledge of radiographic techniques and radiation health and safety, prior to performing clinical procedures.

This course is intended to provide current, vital information on film and tube head placement, to serve as a guide to acquire new skills or refine current skills, and allow you to test yourself as you progress through the pages.

Intraoral Procedures

Introduction

The intraoral radiograph, when correlated with the case history and clinical examination, is one of the most important diagnostic aids available to the dental practitioner. When examined under proper conditions, diagnostic-quality intraoral radiographs reveal evidence of disease that cannot otherwise be found. They also play a major role in forensic identification.

Two of the fundamental rules of radiography are that 1) the central beam should pass through the area to be examined, and 2) the x-ray film should be placed in position so as to record the image with the least amount of image distortion. Each of three types of intraoral radiologic examinations commonly used in dental practice—periapical, bitewing (interproximal), and occlusal examinations—depend on the operator's

adherence to these two rules even though specific techniques, processes, and indications differ widely among them.

Another aspect that these three examinations have in common pertains to the film packet. The film packet has two sides, a tube side and a tongue side. The tube side may be plain or textured. When placed intraorally, the tube side always faces the radiation source, the tube head. The tongue side may be colored and has a flange to open the packet and remove the film. When placed intraorally, the tongue side always faces the patient's tongue, except in the case of the mandibular occlusal examination.

Because of patient anatomic variations such as narrow arches, missing teeth, or the presence of tori, and limitations of the patient's ability to open sufficiently (caused by age or other factors), or maintain the film placement, a clinical examination must precede the taking of films. After the clinical examination, the operator can determine the number and size of films to expose, the technique modifications necessary, and the type of film retention devices to be employed.

Advancements are continually being made in the development and manufacturing of the actual film packet. These advancements have helped to decrease radiation exposure. Whenever possible the 'fastest' film speed should be used.

Periapical Radiographs

The purpose of the intraoral periapical examination is to obtain a view of the entire tooth and its surrounding structures, as in Figure 1. Two exposure techniques may be employed for periapical radiography: the paralleling technique and the bisecting angle technique. The paralleling technique is the preferred method. This technique provides less image distortion and reduces excess radiation to the patient. The paralleling technique should always be attempted before other techniques. The bisecting technique can be employed for patients unable to accommodate the positioning of the paralleling technique. Candidates may include those with low palatal vaults and children. Disadvantages to the bisecting technique include image distortion and excess radiation due to increased angulations involving the eye and thyroid glands. Regardless of the technique, however, the rules of radiography referred to earlier must be followed.

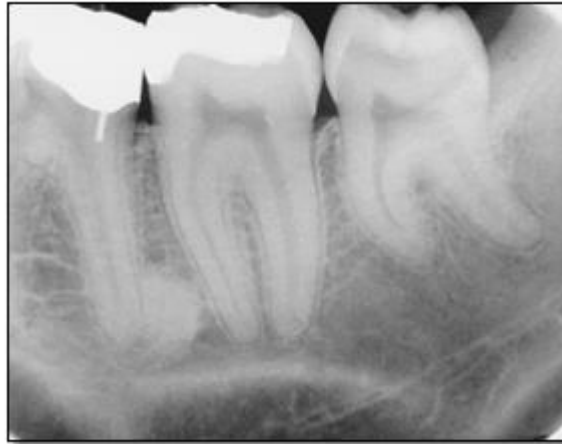

Figure 1

Intraoral Procedures

Bitewing Radiographs

Bitewing examinations were introduced by Raper in 1925. The greatest value of bitewing radiographs is the detection of interproximal caries in the early stages of development, before it is clinically apparent. The arrows in Figure 2 indicate areas of interproximal caries. Bitewing projections also reveal the size of the pulp chamber and the relative extent to which proximal caries have penetrated.

Bitewings also provide a useful adjunct to evaluating periodontal conditions, offer a good view of the septal alveolar crest, and, in addition, permit changes in bone height to be accurately assessed by comparison with adjacent teeth. Bitewings do not show the apices of the teeth and cannot be used to diagnose in this area.

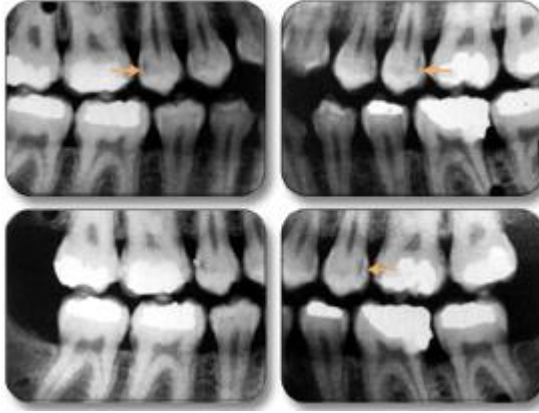


Figure 2

Occlusal Radiographs

Occlusal radiography is a supplementary radiographic examination designed to provide a more extensive view of the maxilla and mandible (Figure 3).

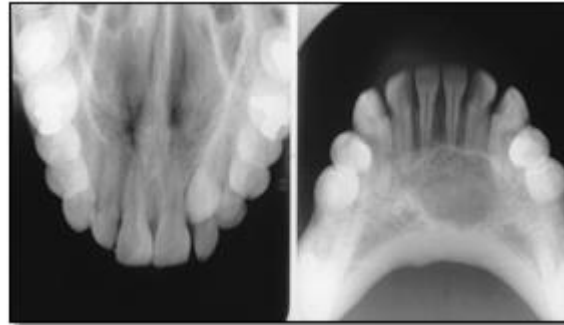


Figure 3

The occlusal radiograph is very useful in determining the buccolingual extension of pathologic conditions, and provides additional information as to the extent and displacement of fractures of the mandible and maxilla. Occlusals also aid in localizing unerupted teeth, retained roots, foreign bodies, and calculi in the submandibular and sublingual salivary glands and ducts. It should be noted that when imaging soft tissues exposure time needs to be appropriately reduced.

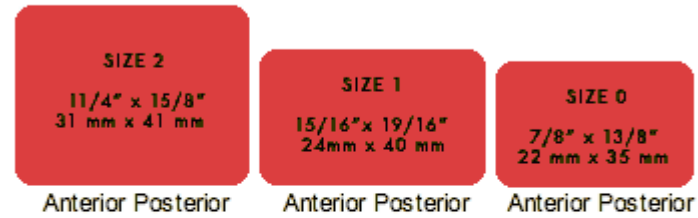Dentulous Adult Survey

The number of films needed for a full mouth series varies greatly. Some practitioners may prefer 10 films, while others may prefer 18, 20 or more exposures.

The selection of film sizes used in a full mouth series also varies. A full survey can consist of narrow anterior film (size #1); standard adult film (size #2); #2 bitewing film or long bitewing film (size #3), (Figure 4) and may include anterior bitewings. It is generally recommended to use 20 films --- four bitewings and 16 periapicals. Eight anterior #1 films will allow for ease of film placement on patients with narrow palates. However, in some cases six anterior periapicals will cover the area needed.

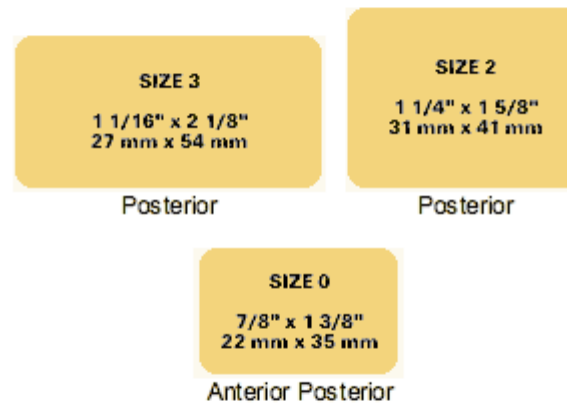
Periapical film

for the examination of the entire tooth and its surrounding structures



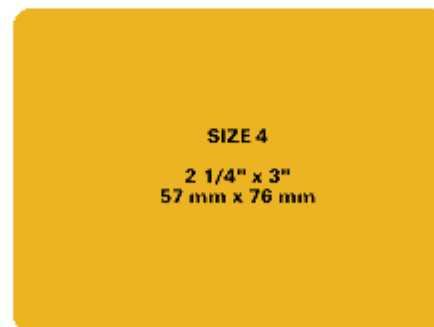
Bite-wing film

for the interproximal examination



Occlusal film

for examination of large areas of the maxilla and the mandible



Warning: mysql_num_rows() expects parameter 1 to be resource, boolean given in **/home/svadan38/public_html/replace_diacritice.php** on line **143**

Fatal error: Call to undefined function replace_diacritice_google_