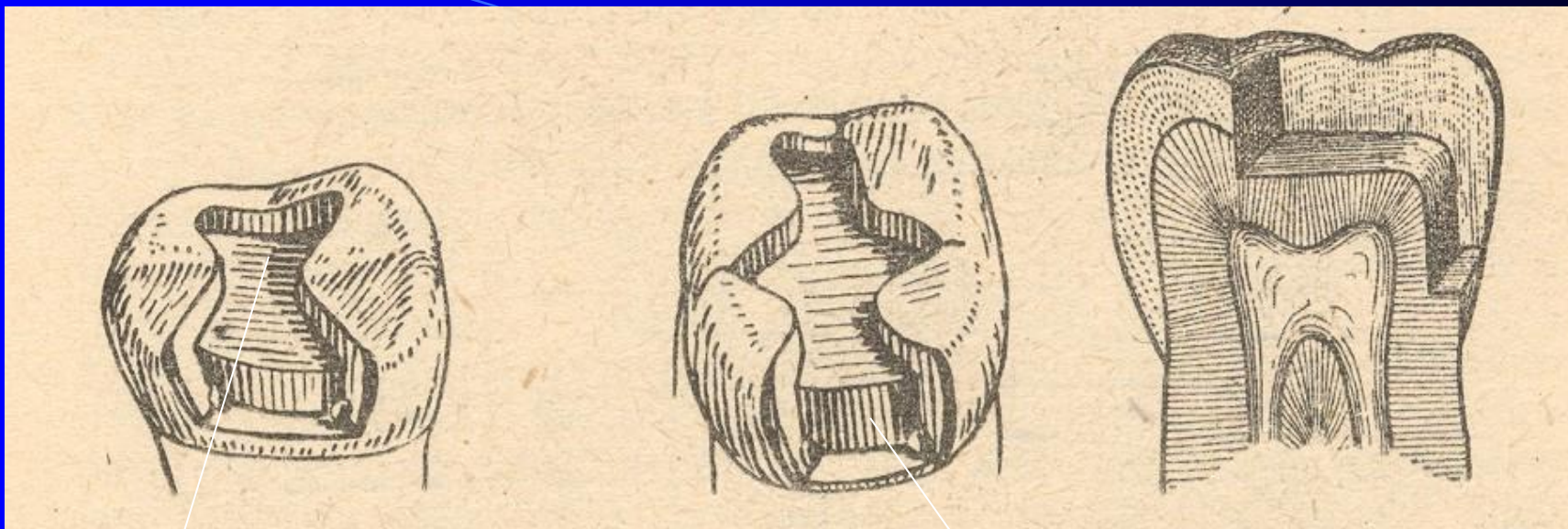


Class II. - modifications

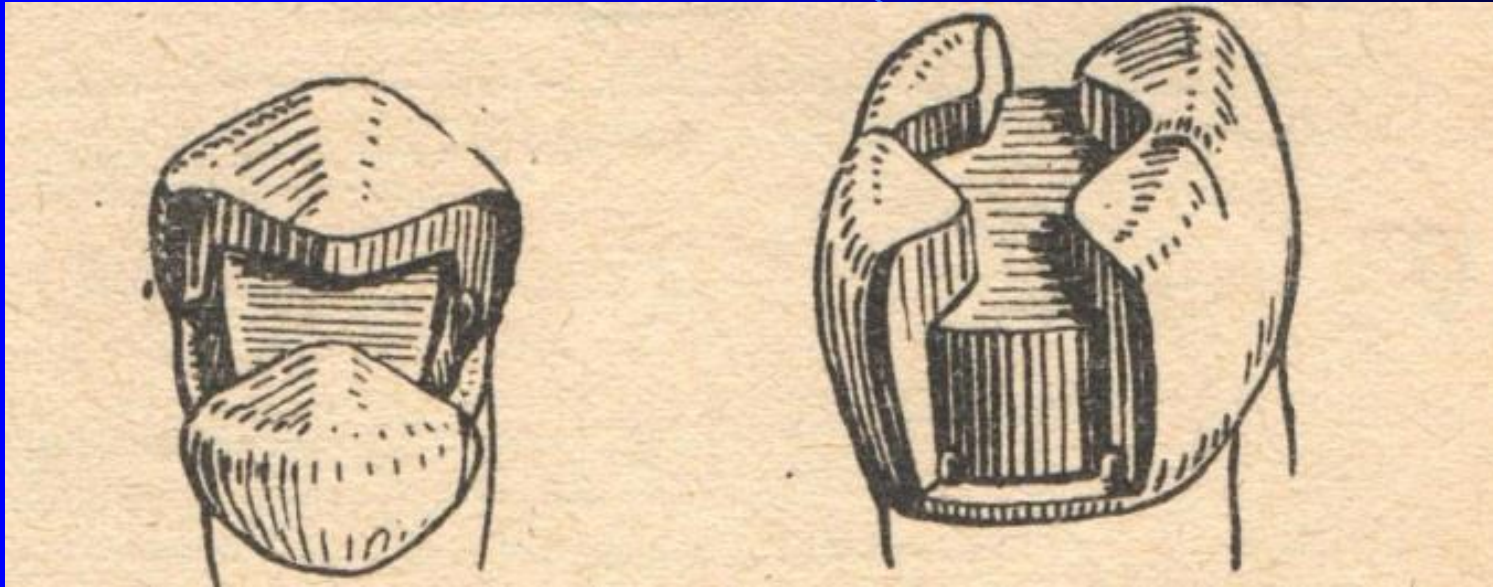
- Compound cavity
- Slot
- Large restoration with cusps replacement



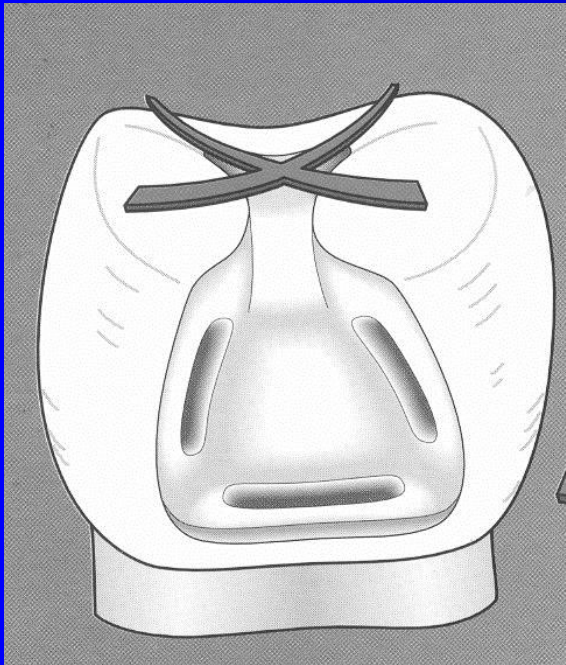
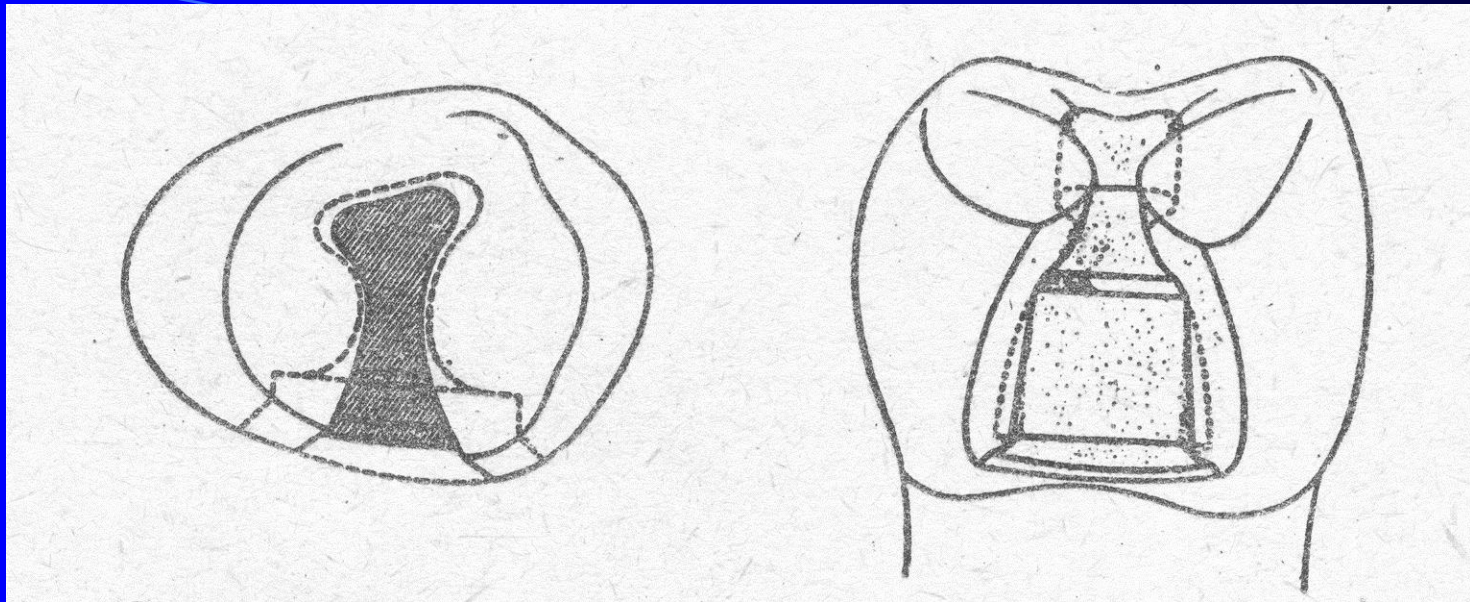
Kavita okluzální

Kavita aproximální

MO, OD



MOD



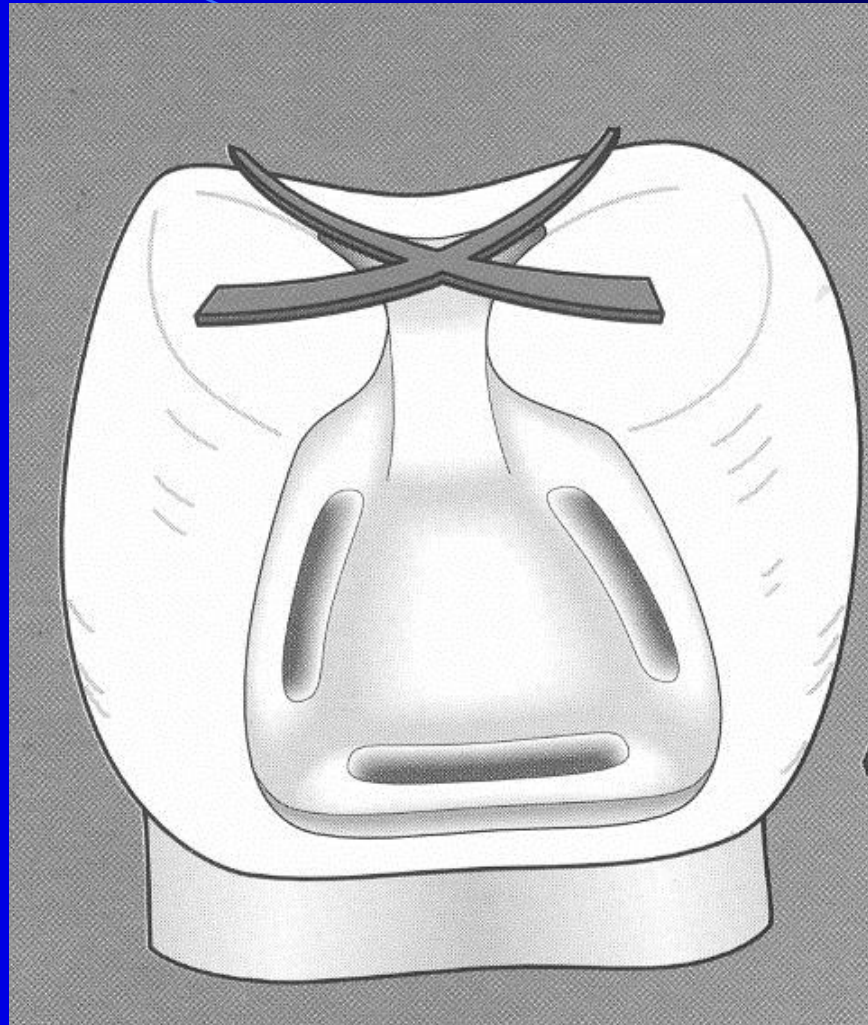
Grooves in proximal box

A groove in gingival wall

Divergency of axial wall to the gingiva

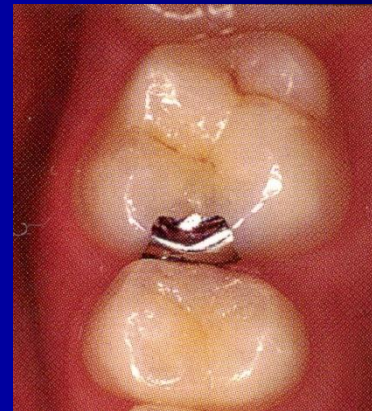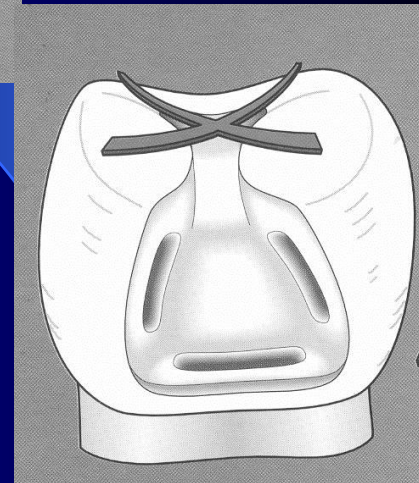
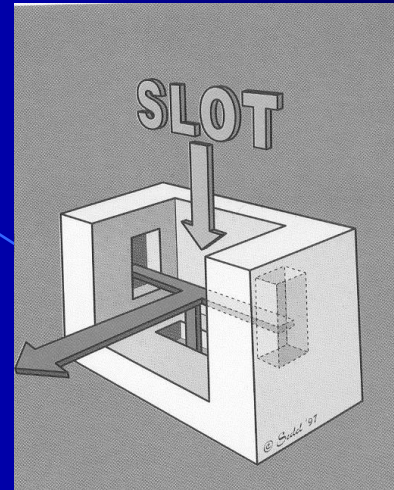


Autoretention



Slot preparation

- Small slot
- Limited on proximal ridge
- No large cavity on occlusal surface
- Grooves
- Divergency of proximal walls to the gingiva



Slot for amalgam

- Access to the caries lesion
 - go through the enamel wall
 - breaking out of the proximal enamel lamella
 - excavation of carious dentin

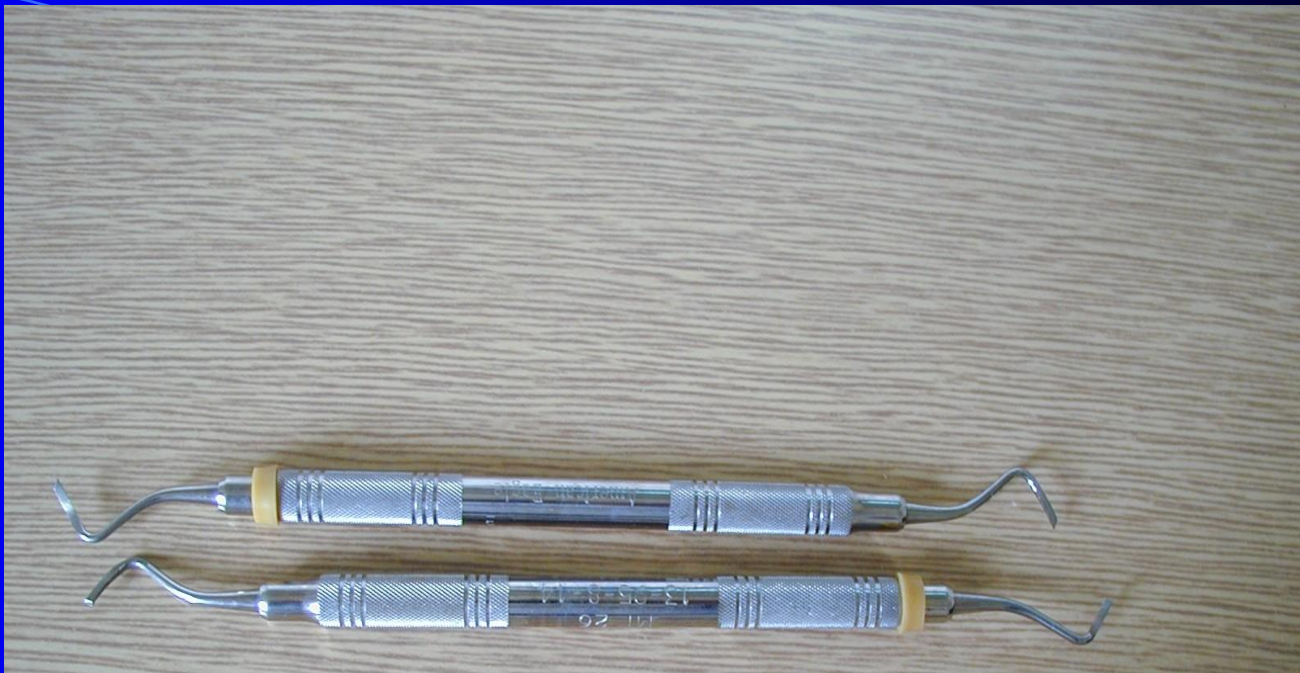
Slot

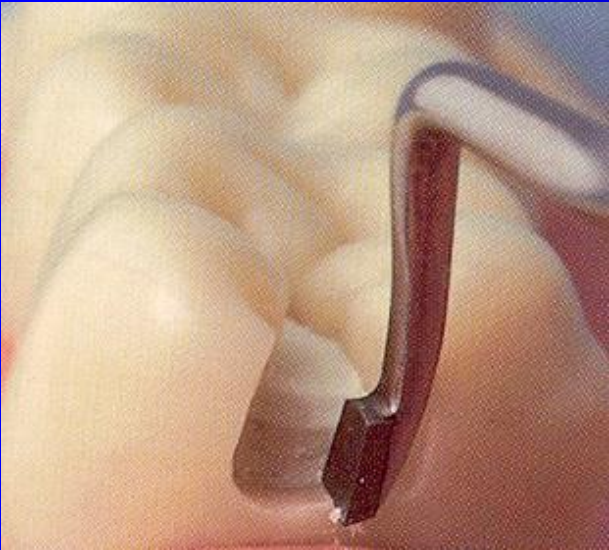
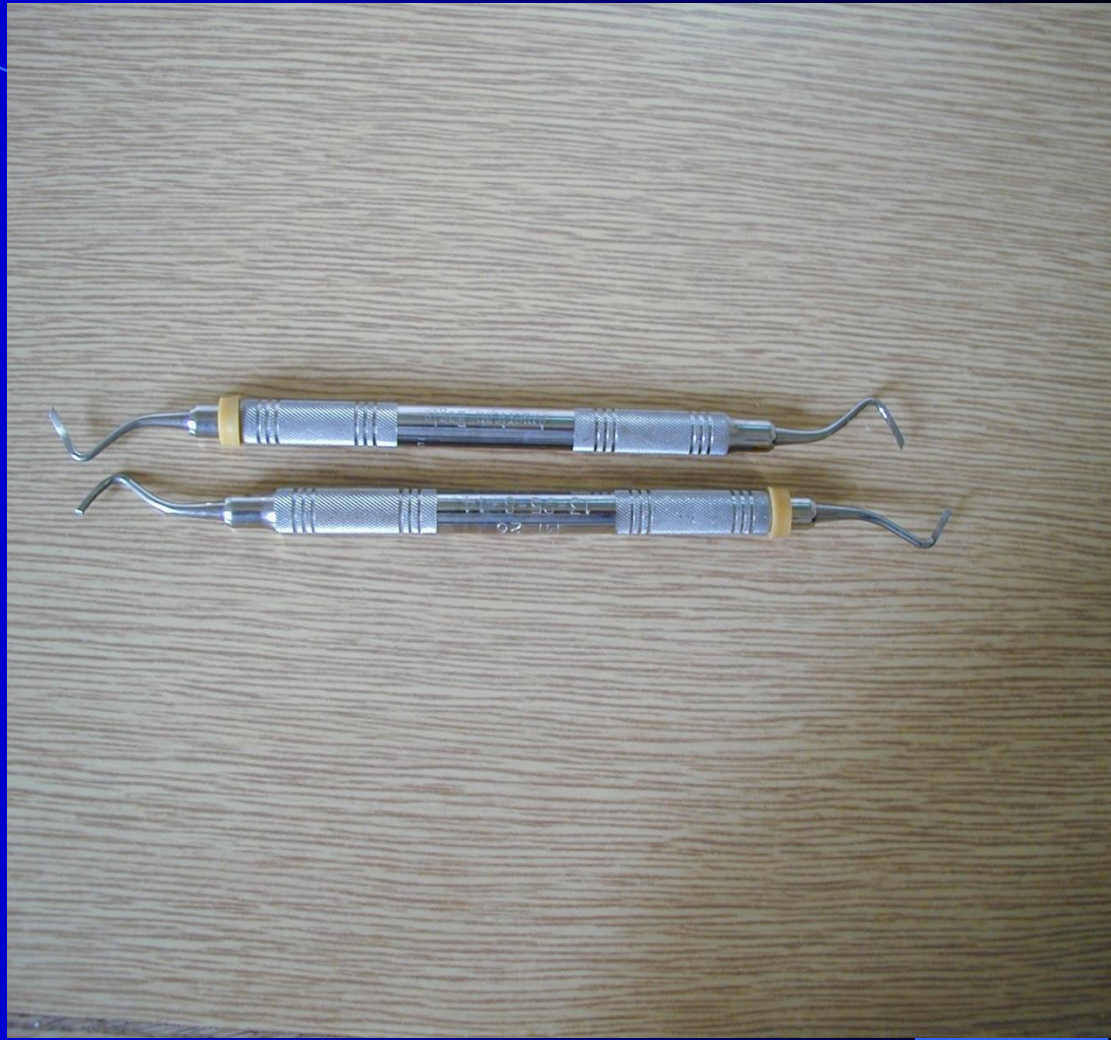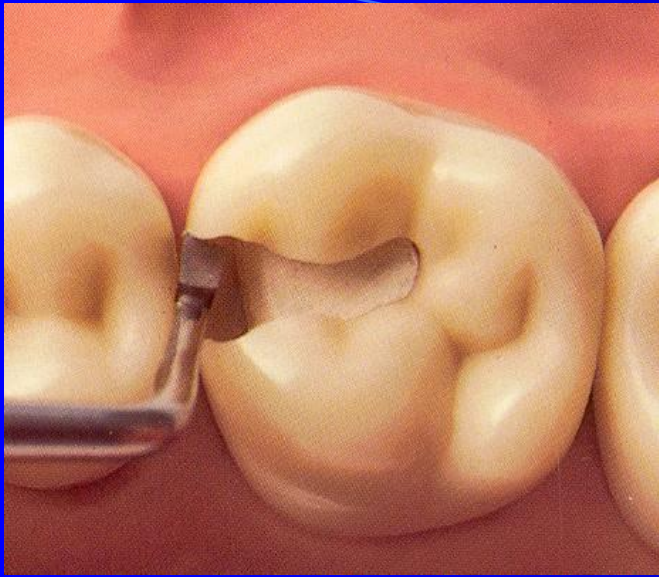
- Autoretention
- Rule of the gingival wall

Slot

- Rule of the gingival wall

90° angle towards the pulpal wall
outer line beveled if in enamel
horizontal groove

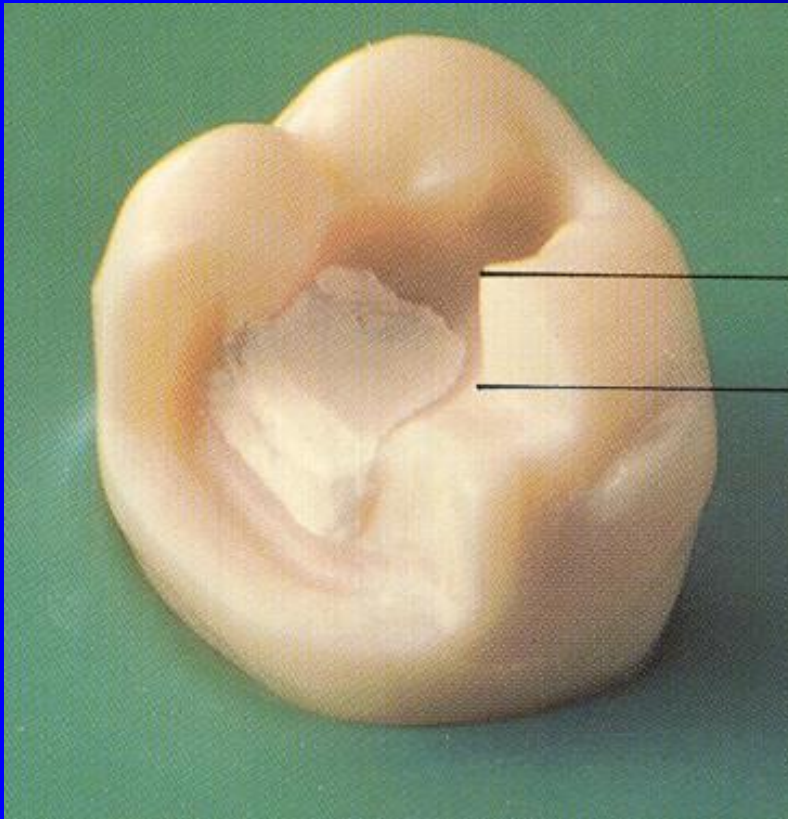




Slot preparation

- Indication: Small cavities, good level of oral hygiene.
- Contraindication: Large cavities, high risk of new caries lesions, bad level of oral hygiene.

Large preparation with replacement of cusps

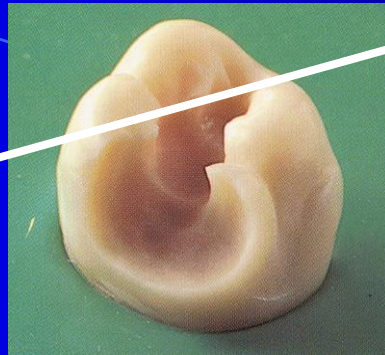
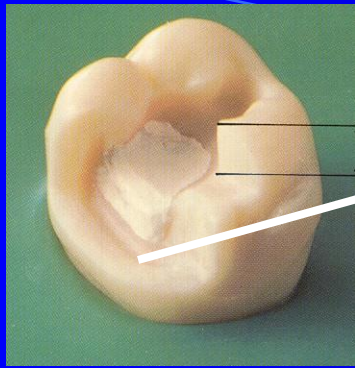


Thickness of amalgam
on the cusp is 3 – 4 mm

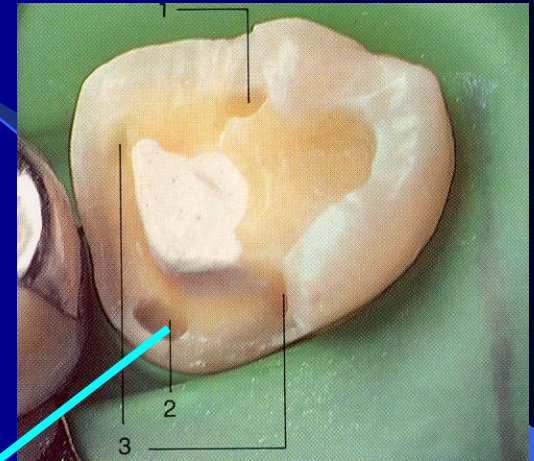
Grooves

Pins

Slots



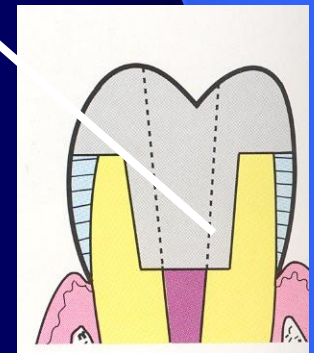
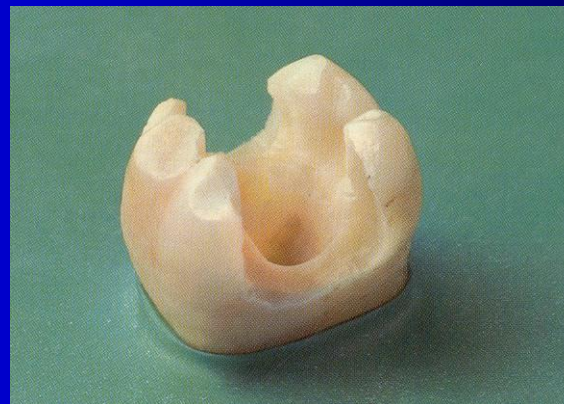
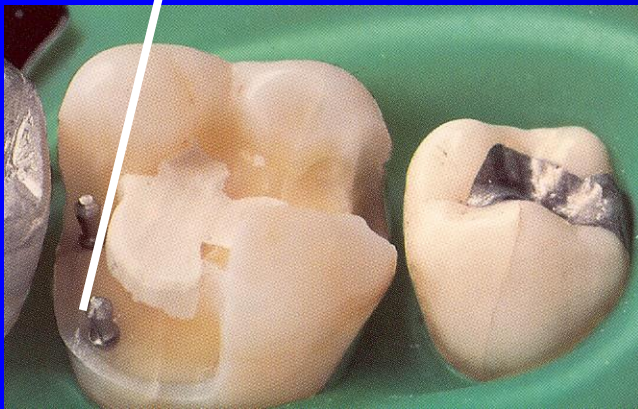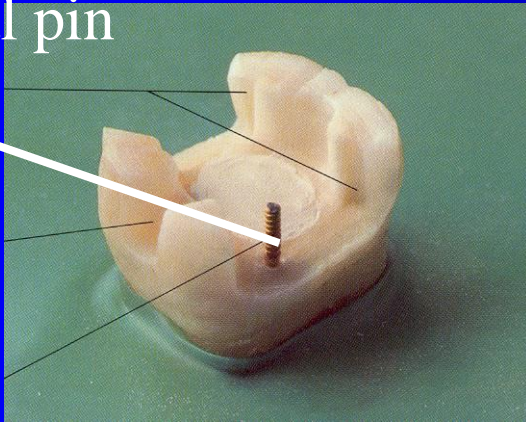
Groove



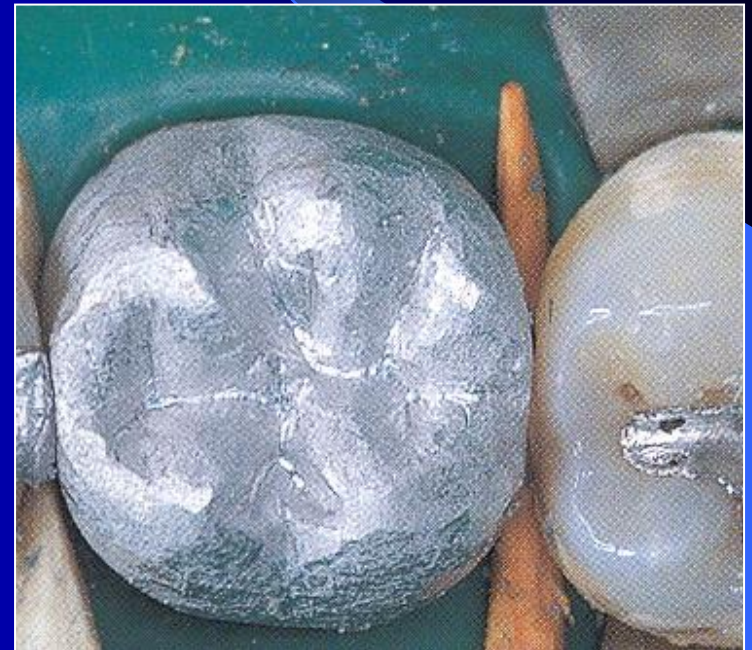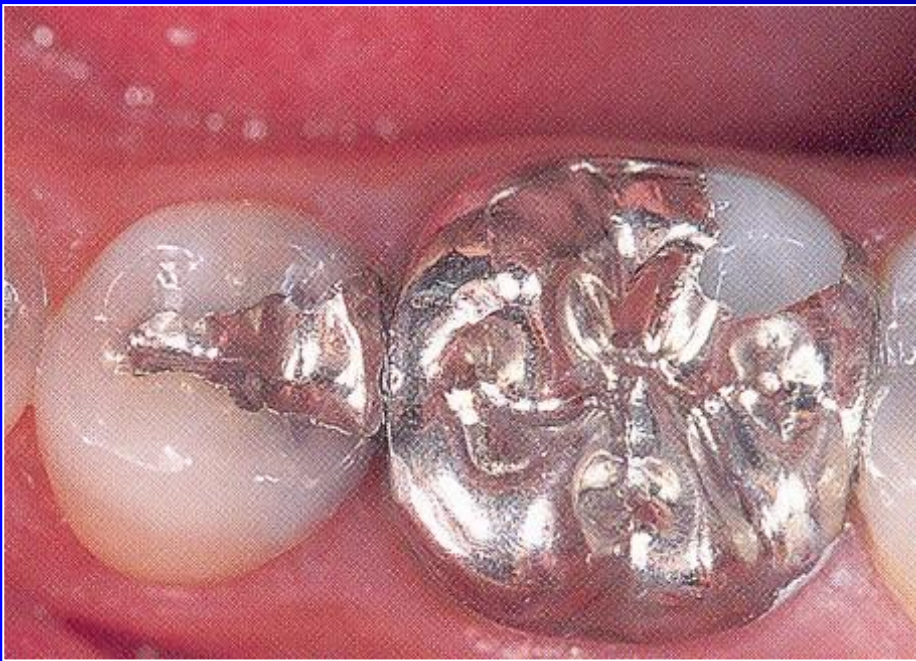Slot

Retention in endodontic cavity

Parapulpal pin



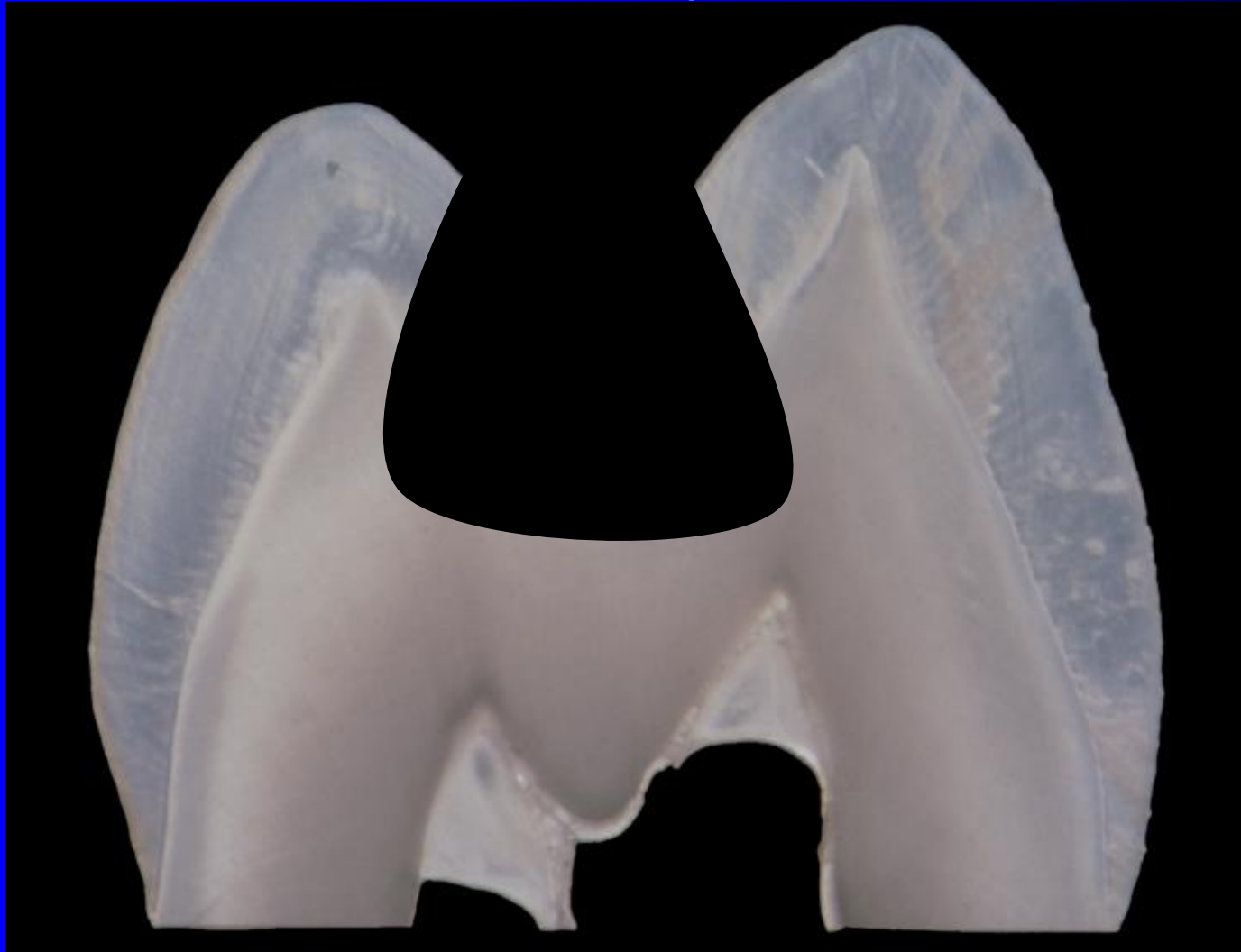Large amalgam restoration - overlays



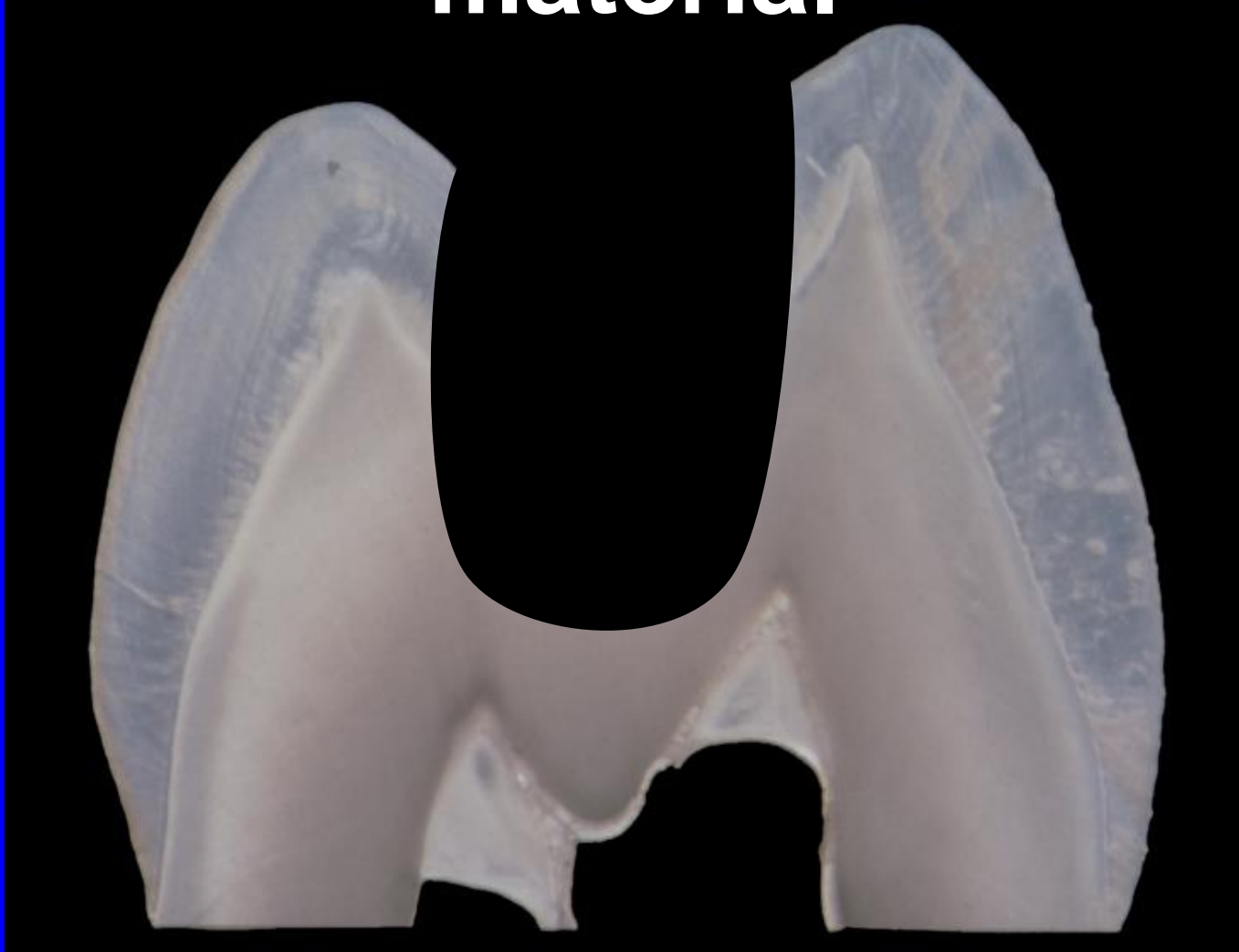Composite materials and class II.

- Indication: Aesthetic reasons, small to moderate cavities, good level of oral hygiene, isolation of operating field.
- Contraindication:
Large cavities, bad level of oral hygiene, poor isolation of operating field.

Preparation for amalgam

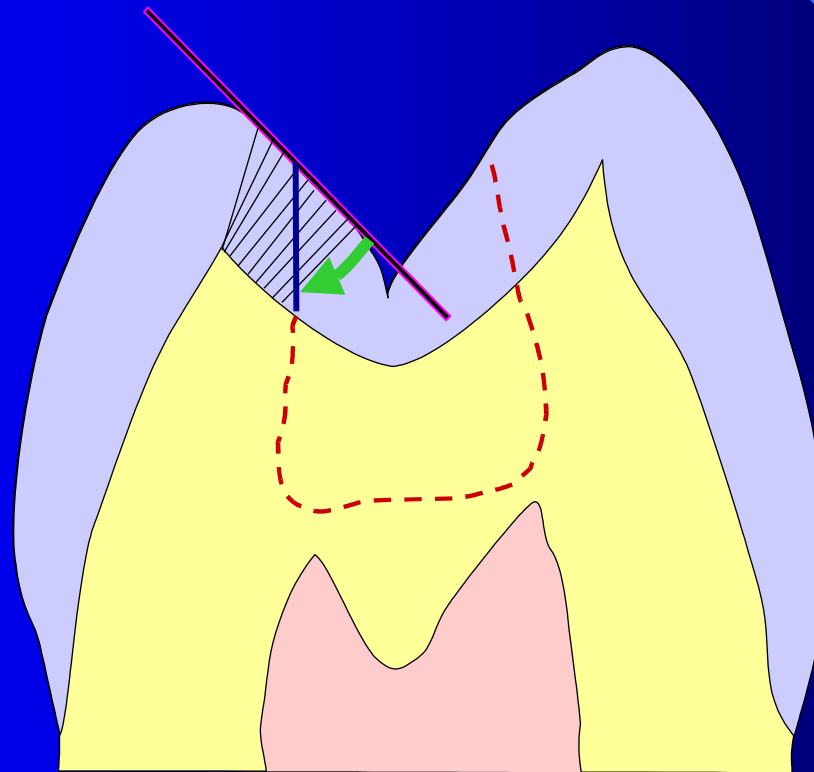


Preparation for composite material



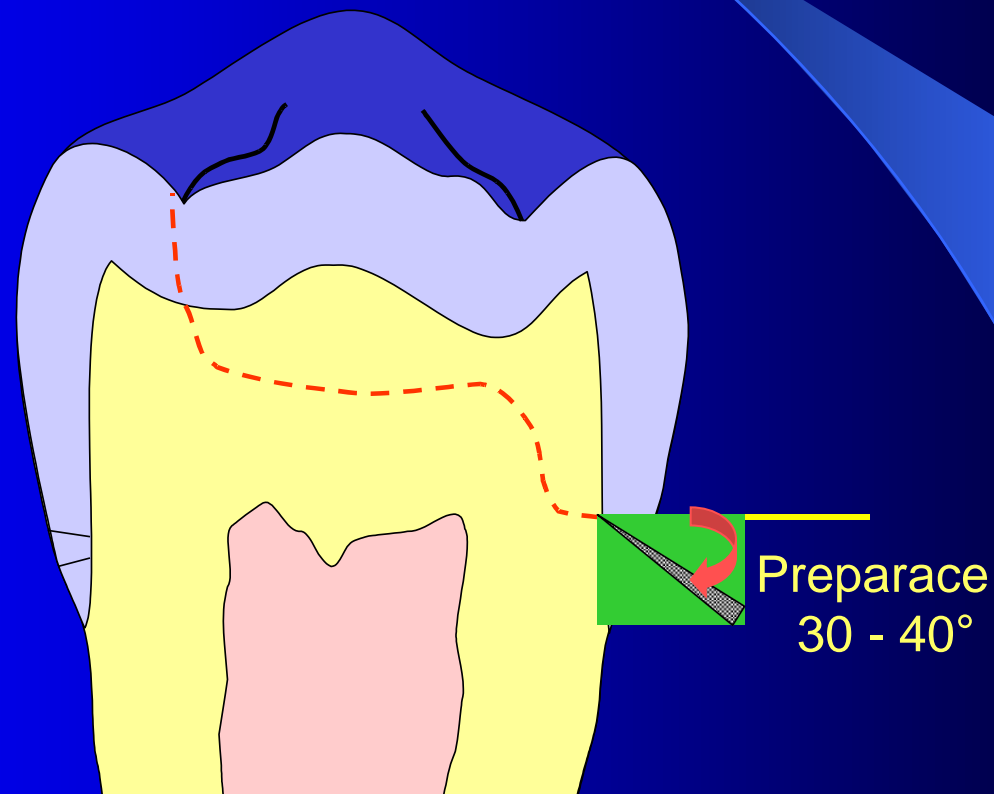
Preparation for adhesive fillings

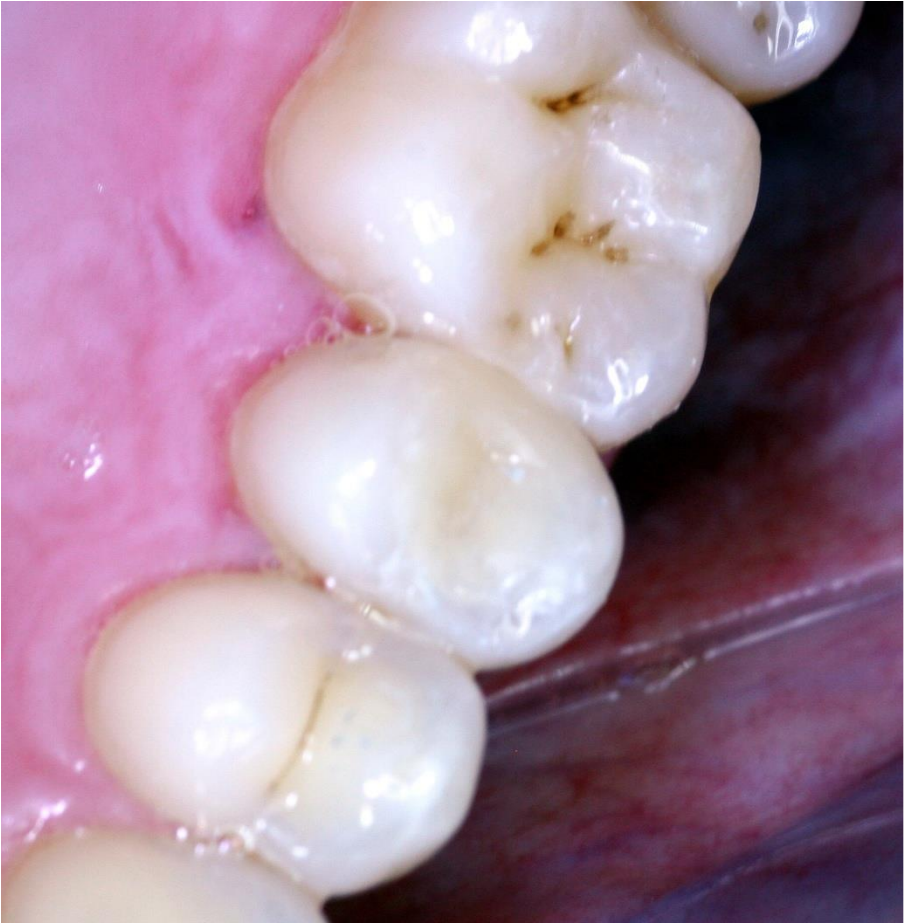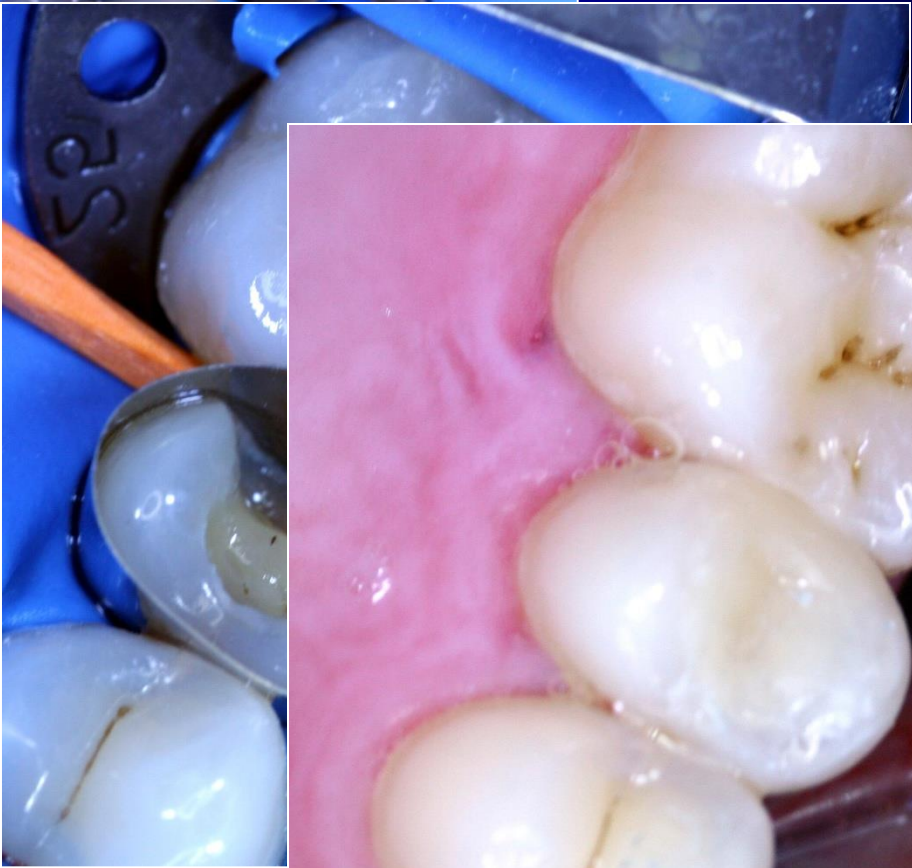
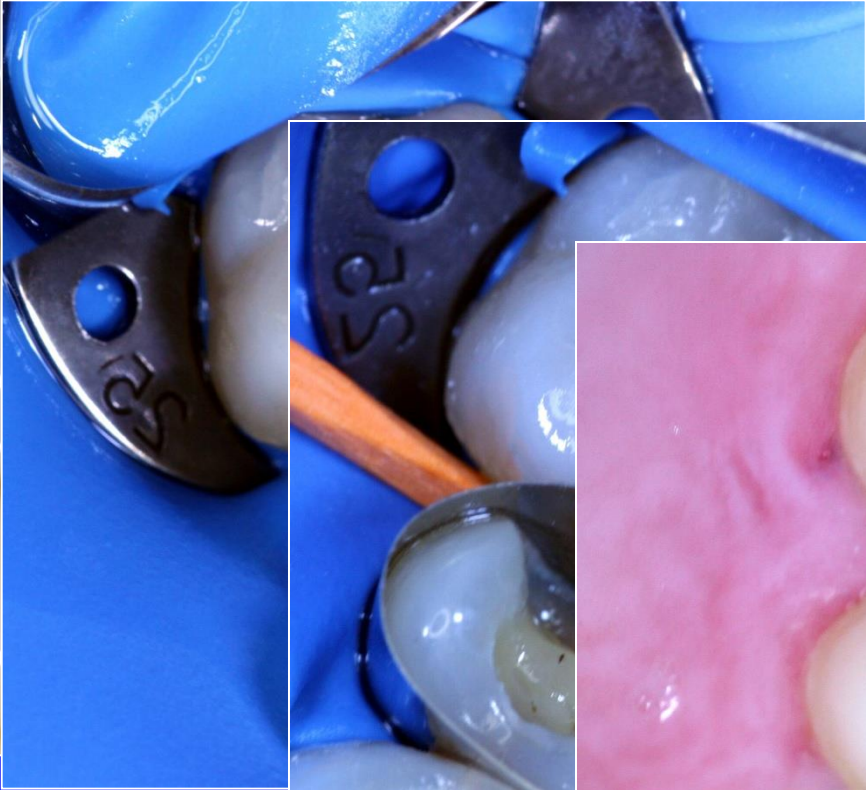
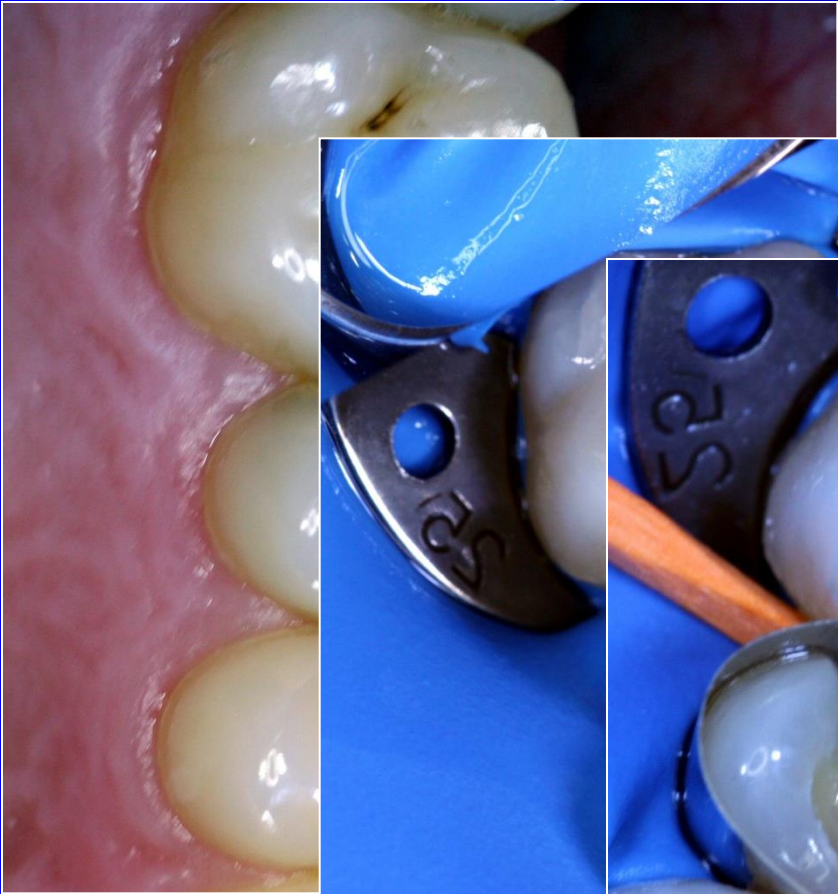
We do not bevel the cavosurface margin in occlusal cavity

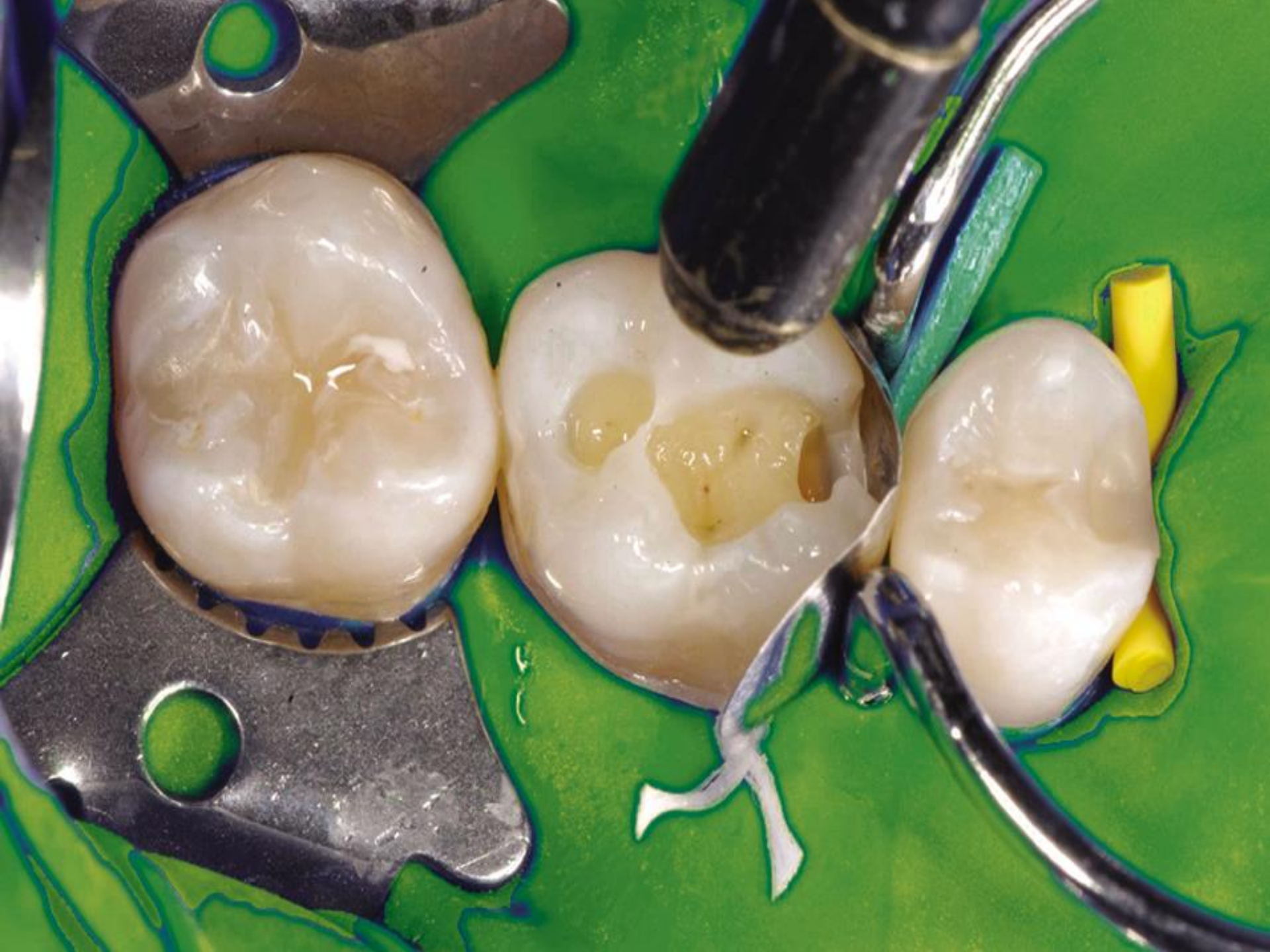

Gingival wall

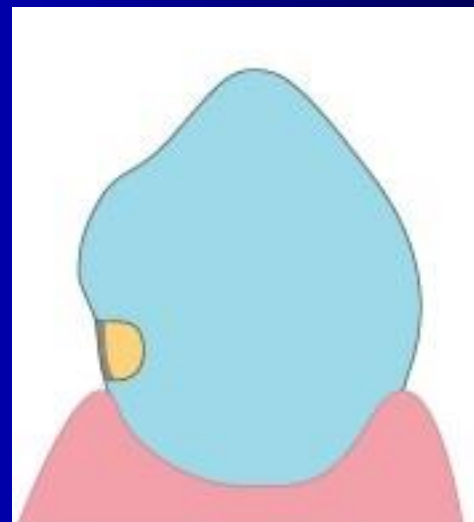
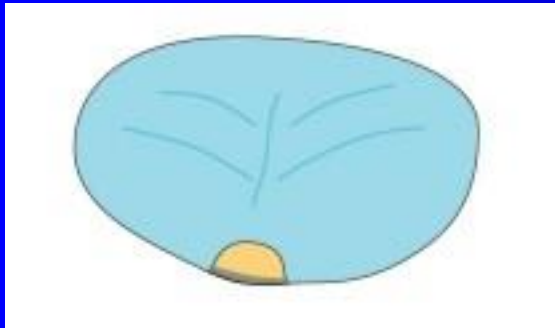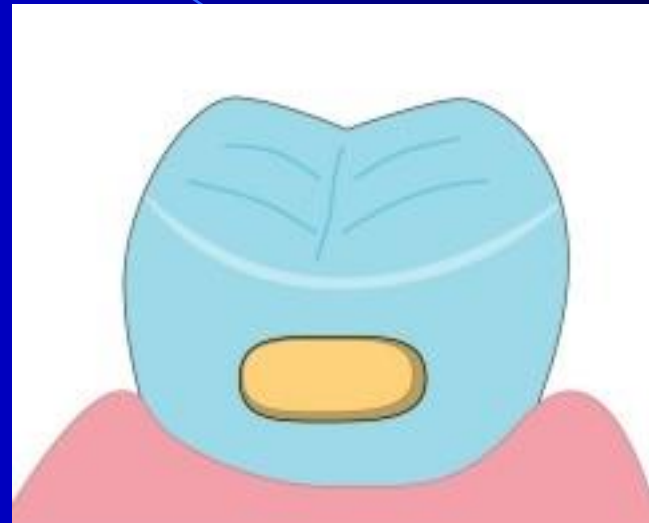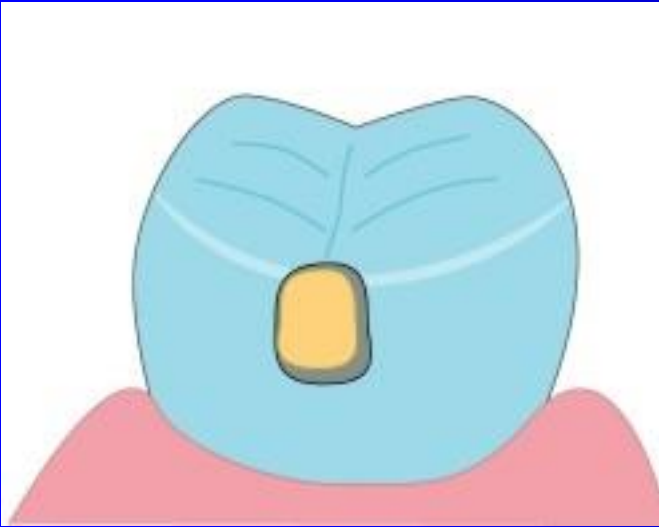
The cavosurface margin is beveled if situated in enamel
The cavosurface margin is not beveled if situated out of enamel

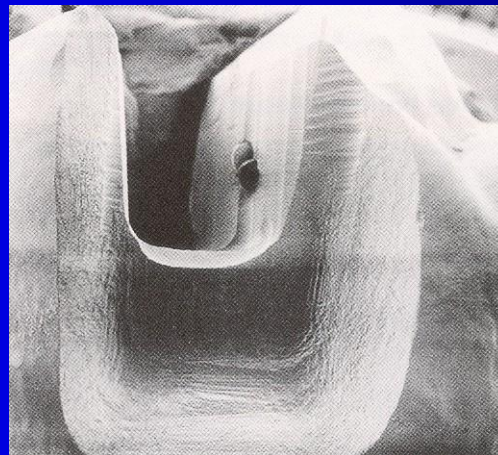
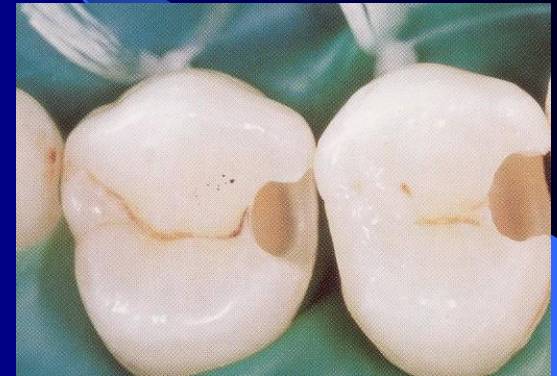
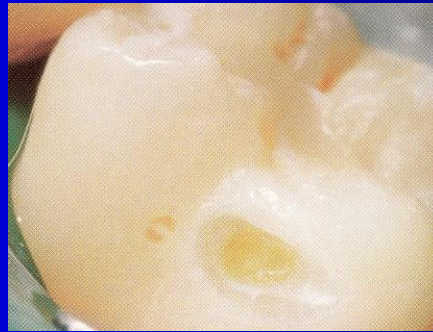
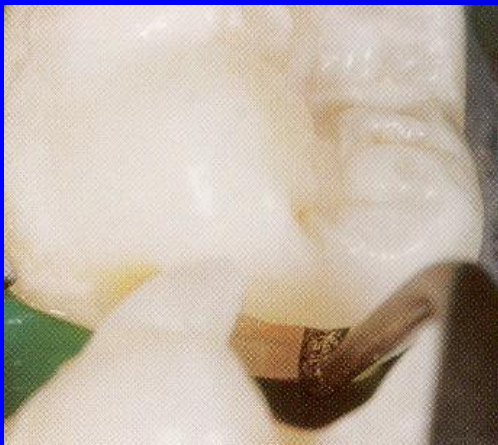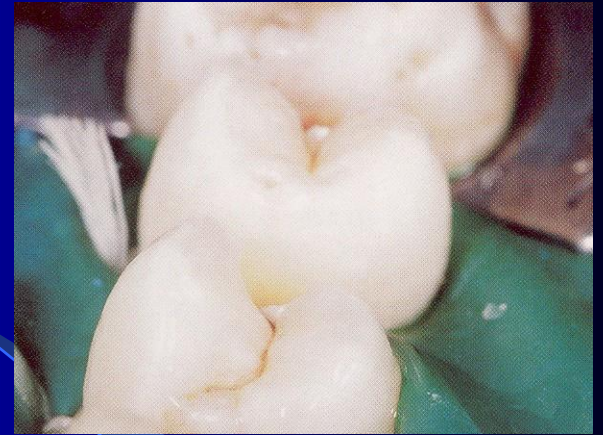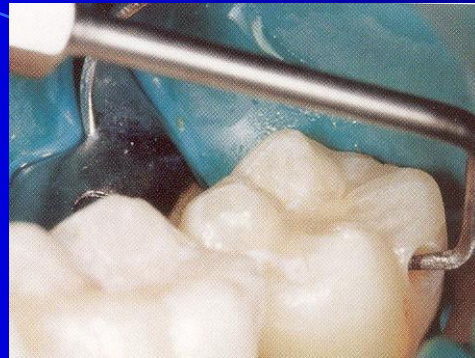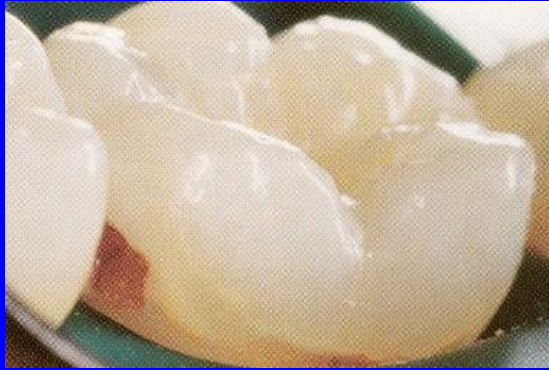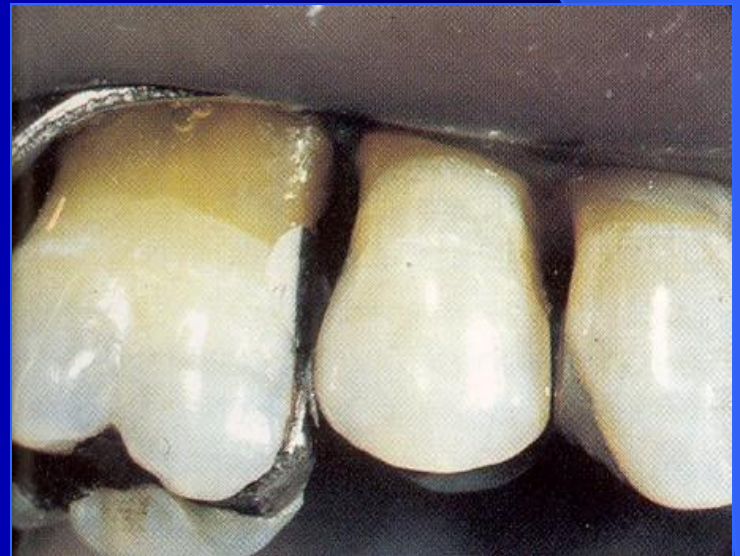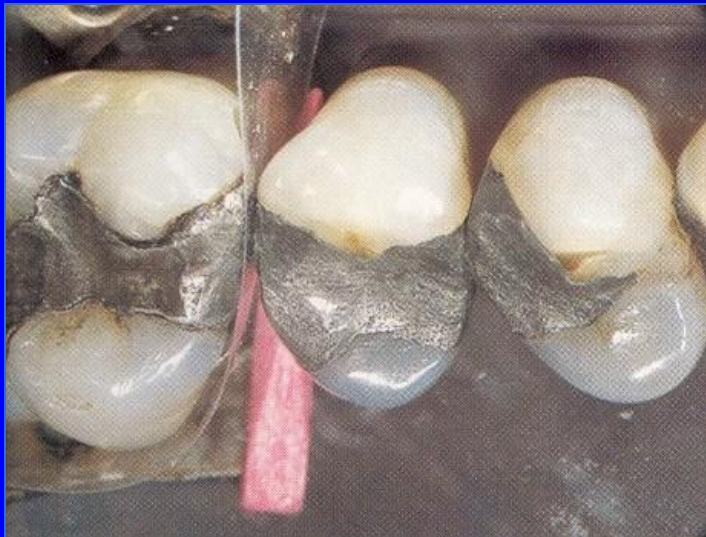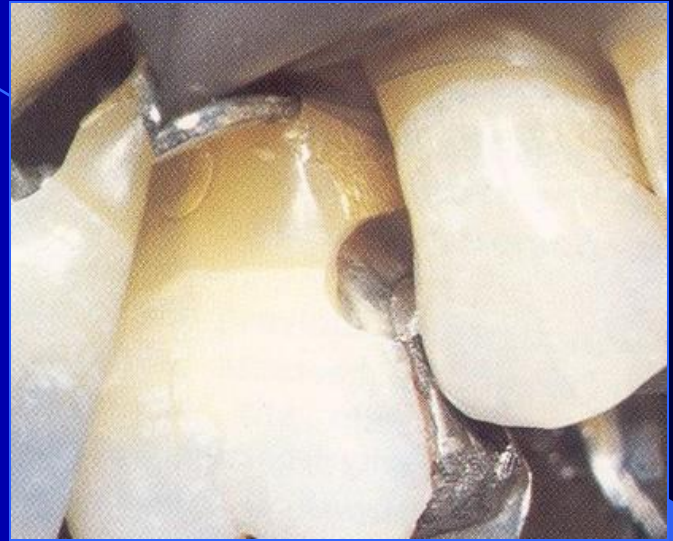




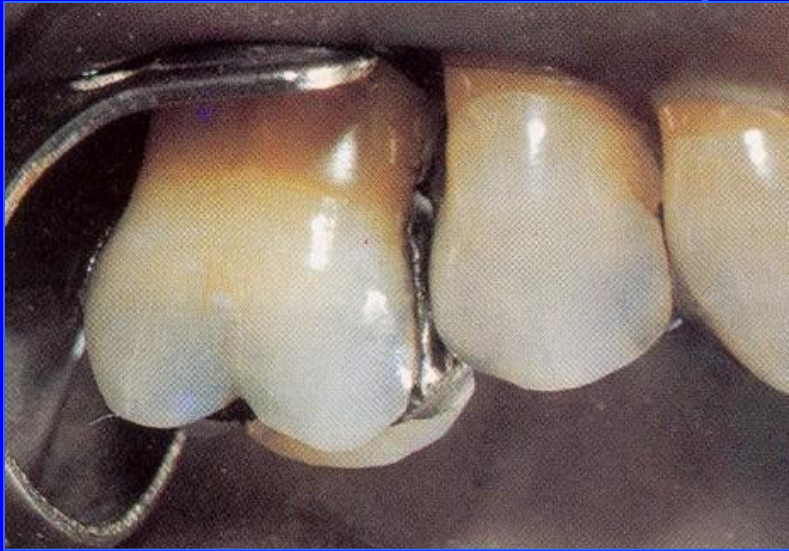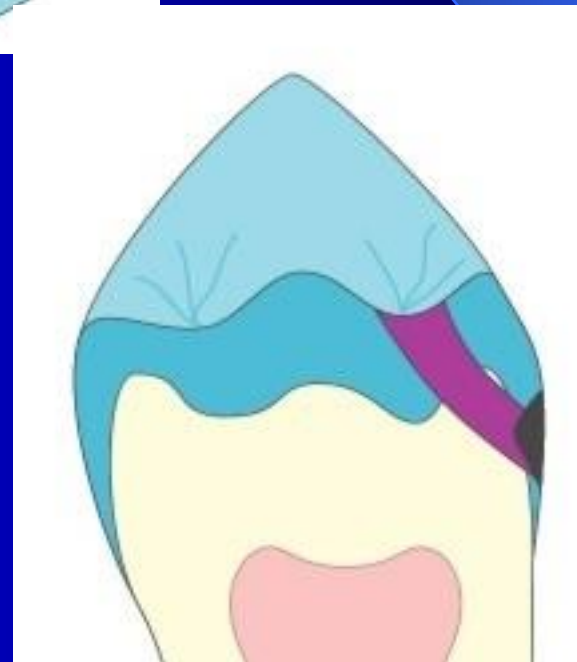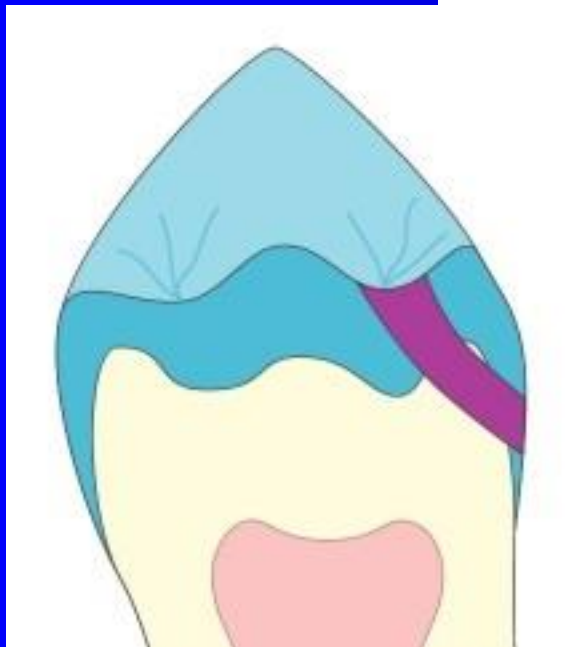
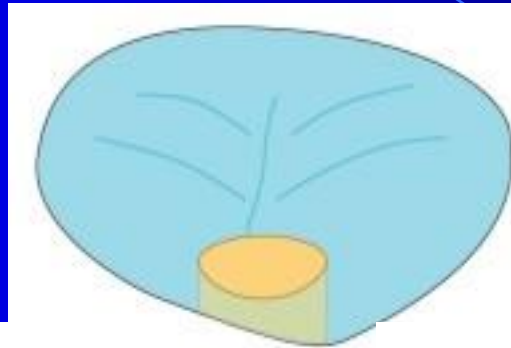
Adhesive slot



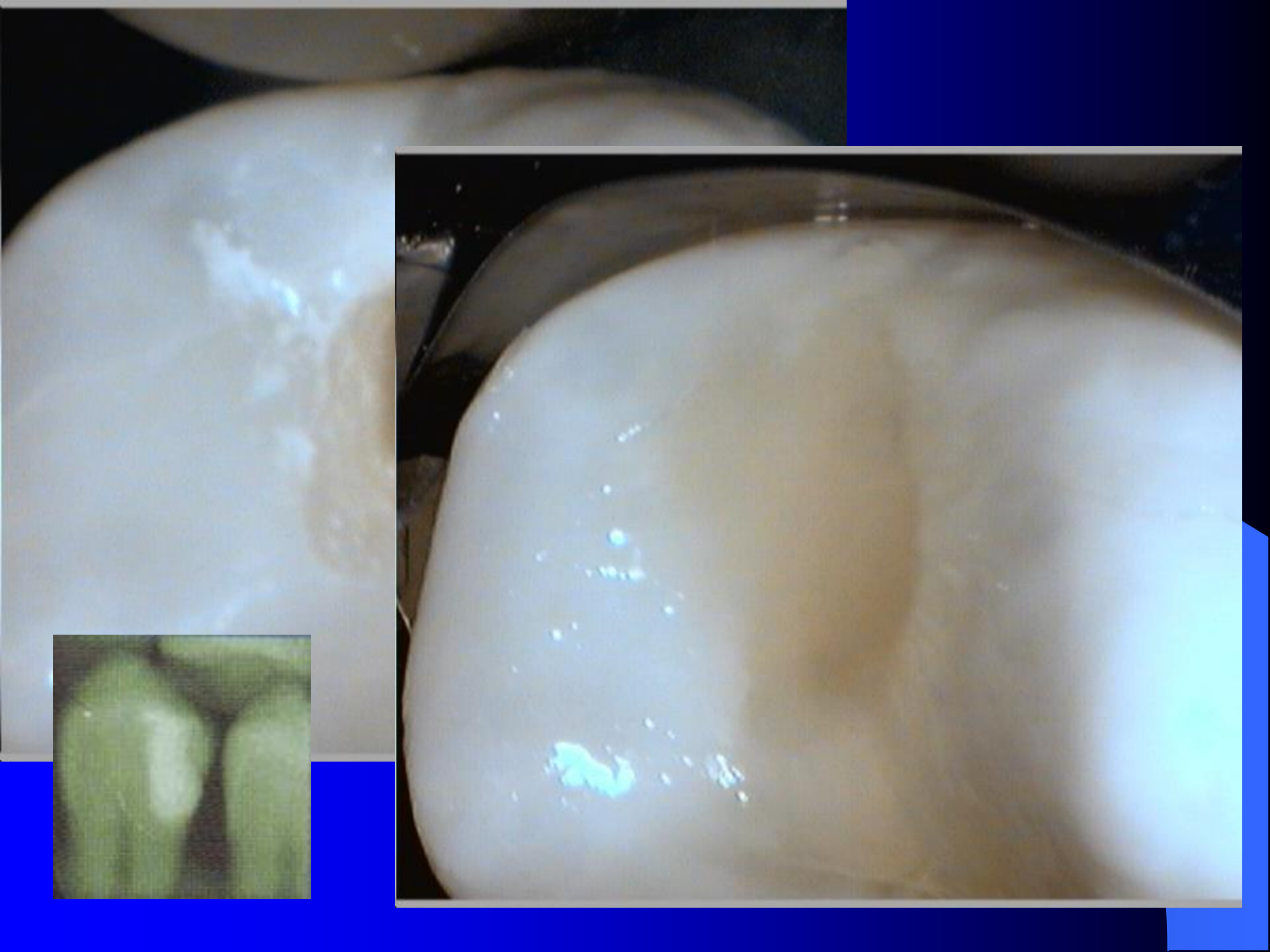


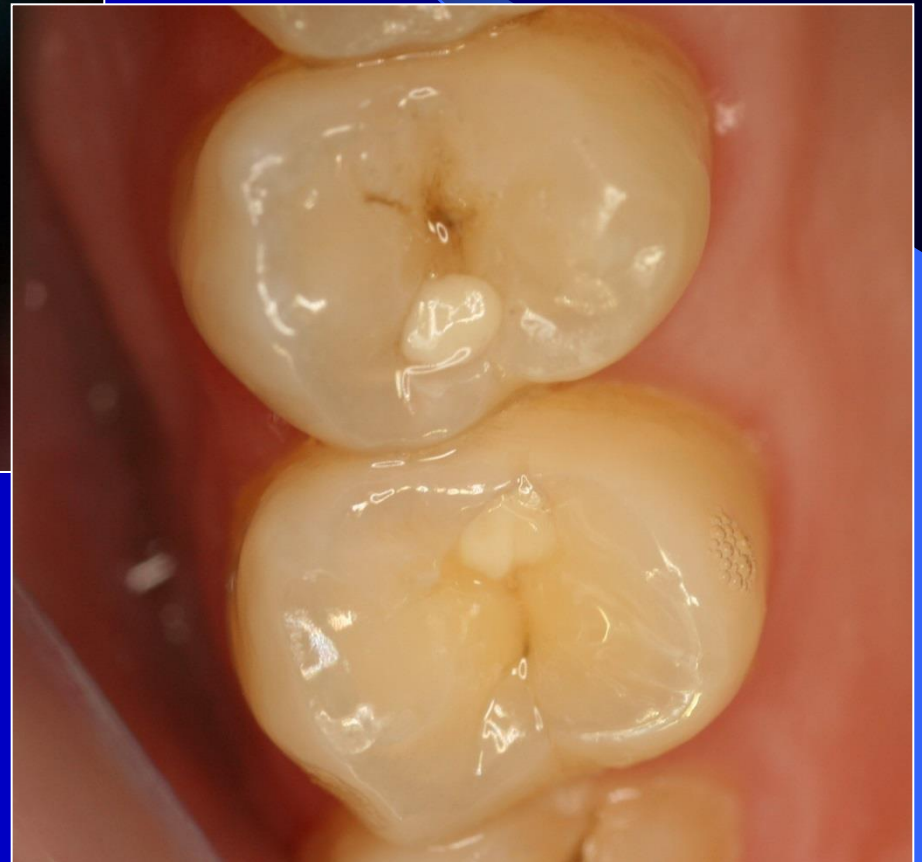
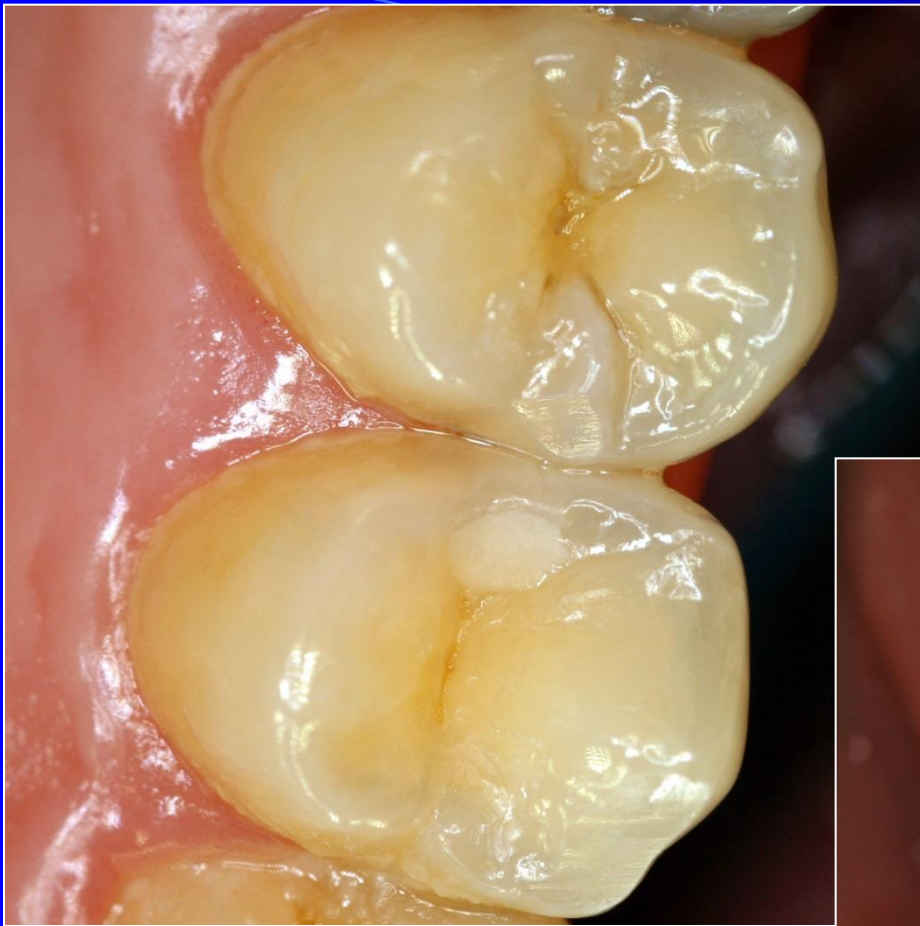
Tunnel preparation









Small cavities

1. Magnification
2. Small instruments
3. Capsulated GIC or composite
5. X-ray post op

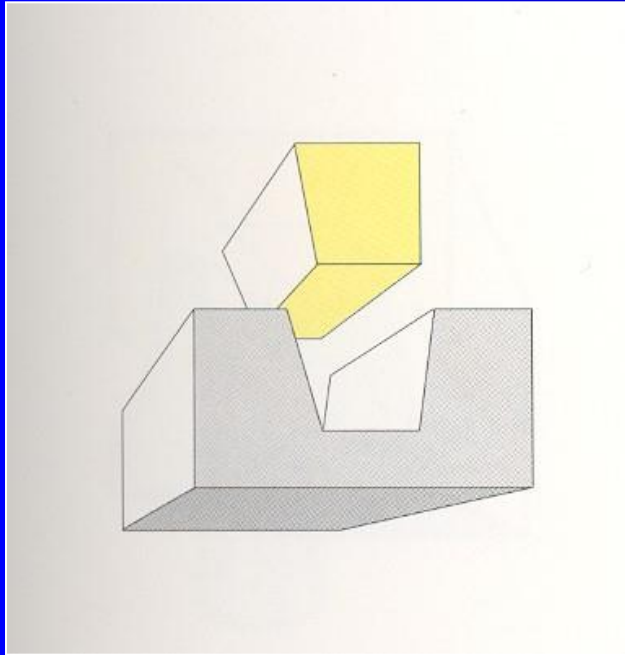
Inlays – class II.

- Rigid fillings – made in dental lab
- Luting into prepared cavity using cements.
- Material:
 - Metal alloy (usu golden)
 - Comosite material
 - Ceramics

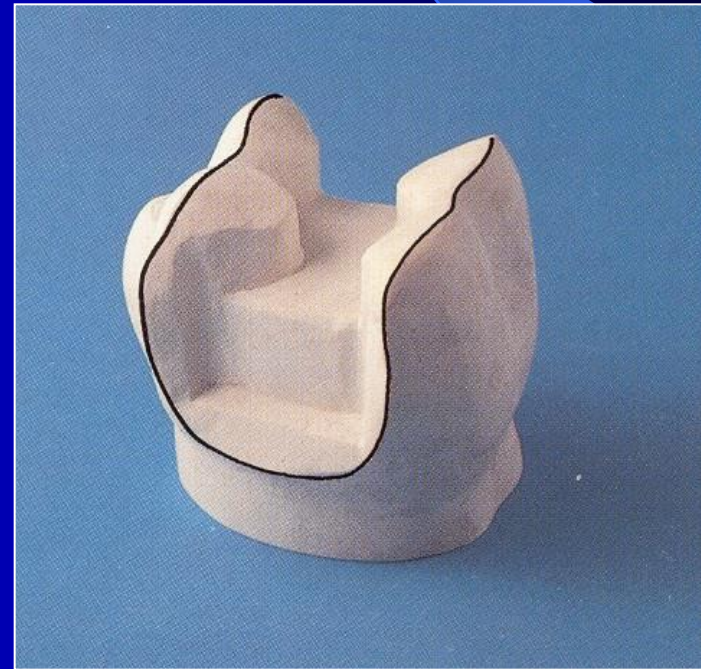
Inlays – class II.

- Indications:
- Large defects
- Low risk of new caries lesions

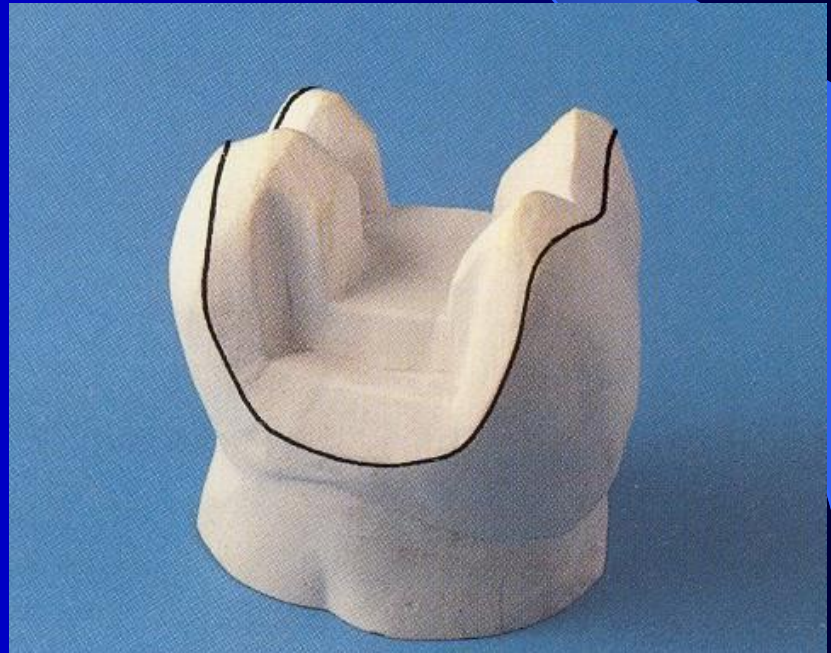
Inlay



Onlay



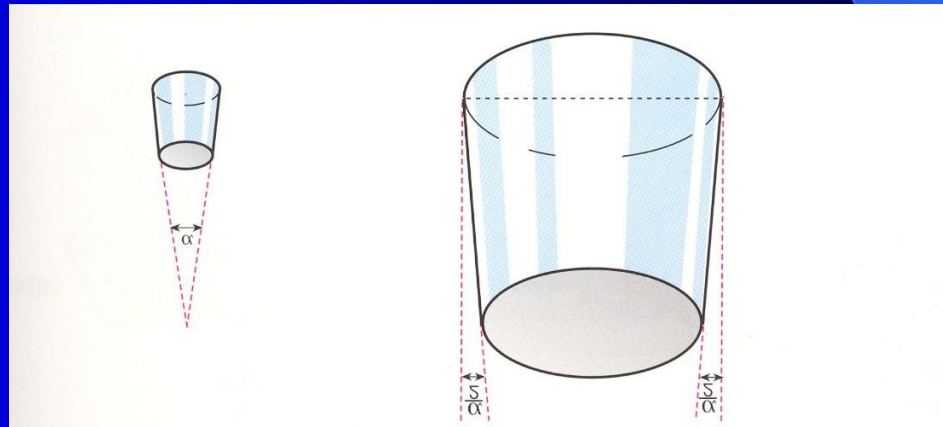
Overlay



Geometry of preparation

- Strict extension for prevention
- No undecuts, no grooves
- The walls are divergent to the occlusal surface !!!

The angle
6 – 15°



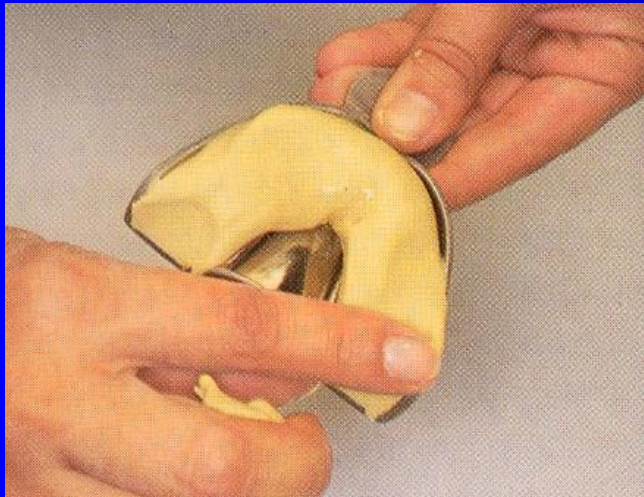
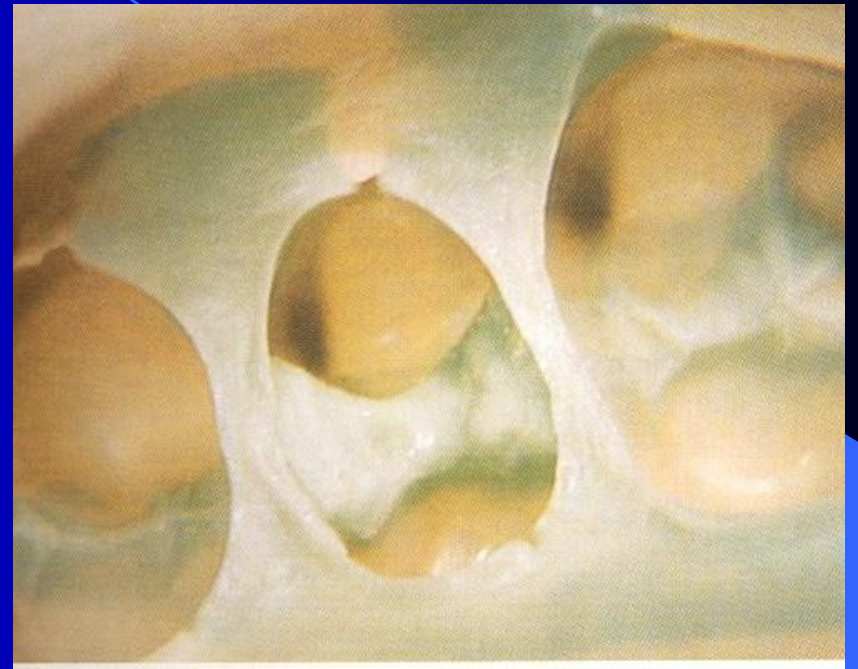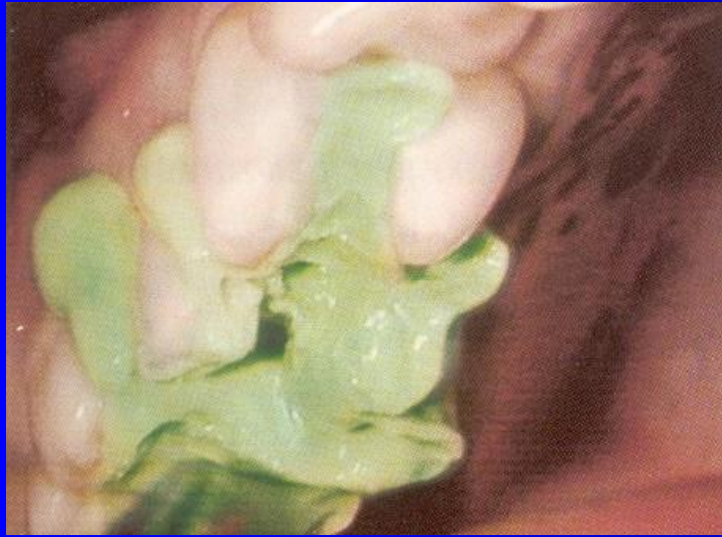Preparation

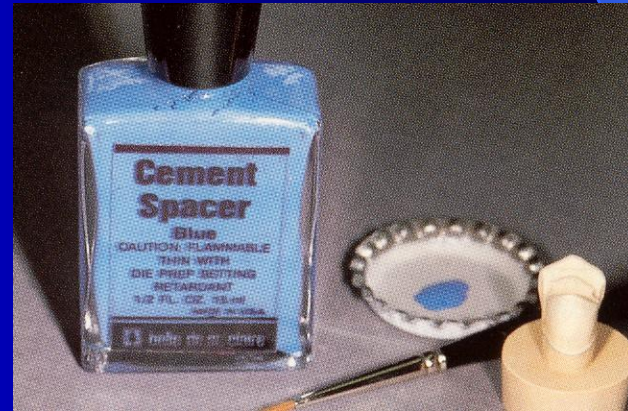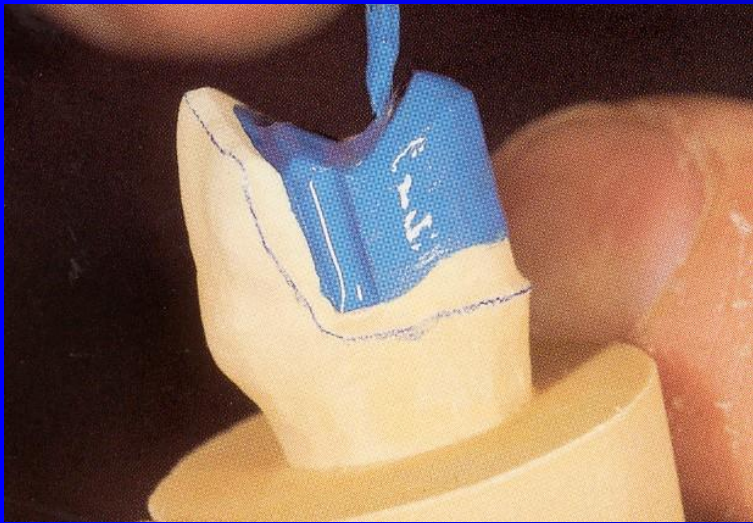
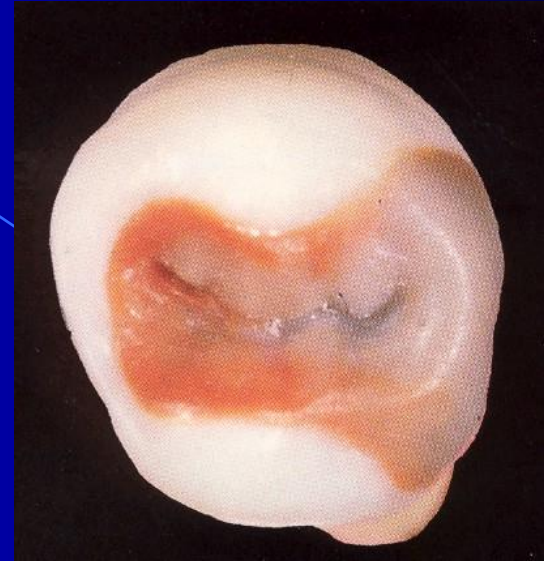
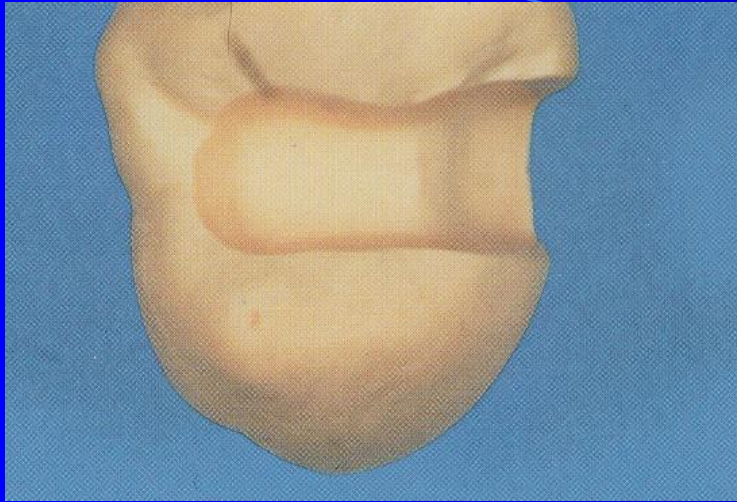
- For inlays made of the metal alloy the cavosurface margin must be beveled.
- The depth of preparation when metal alloy is used must leave the space for inlay 1,5 mm
- For inlays made of composite or ceramics the cavosurface margin is not beveled, the thickness of the material must be appr. 3mm.

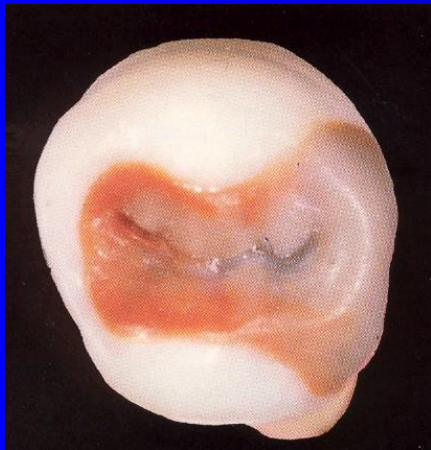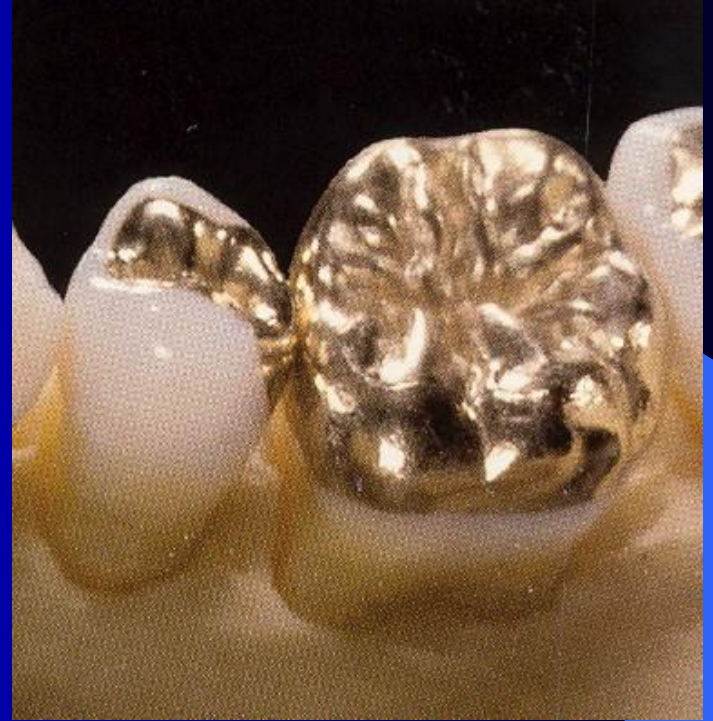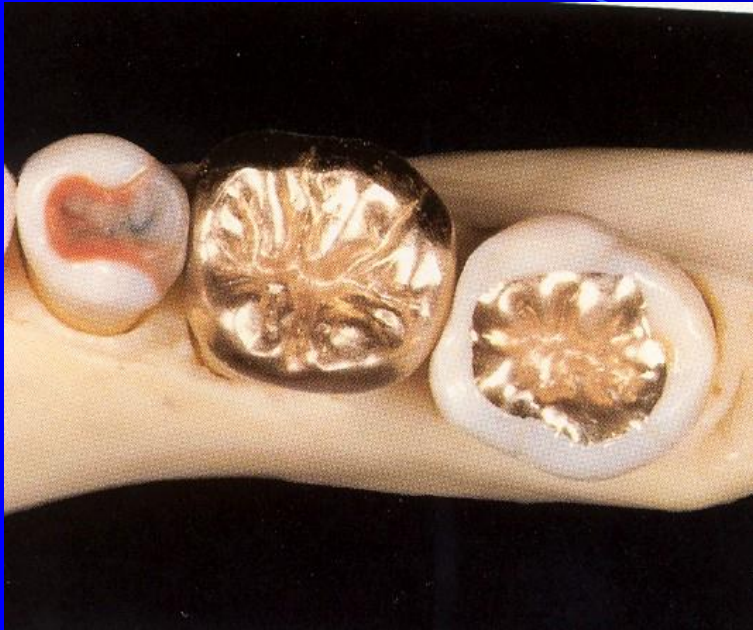All these rules are important for resistance

For inlays the impression must be taken

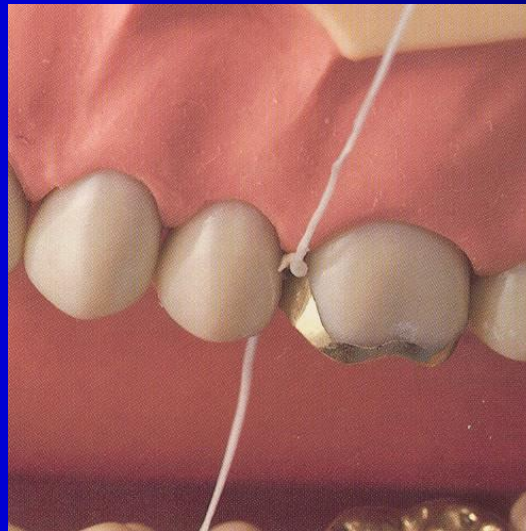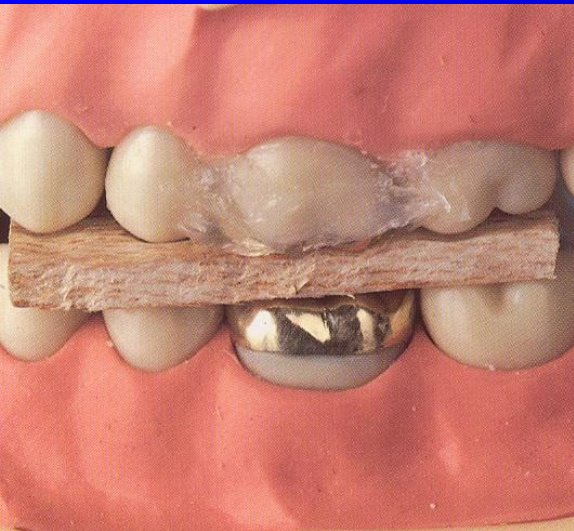
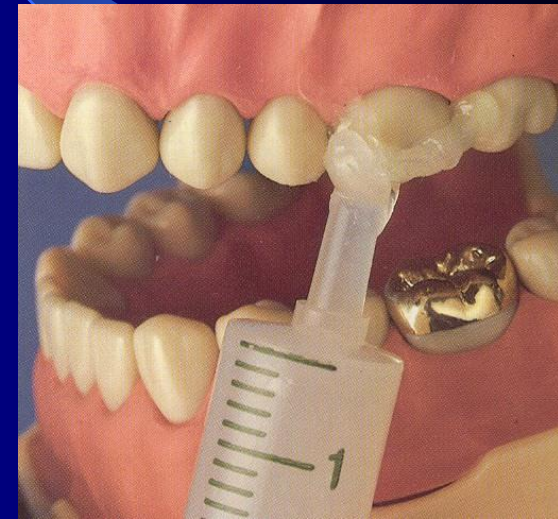
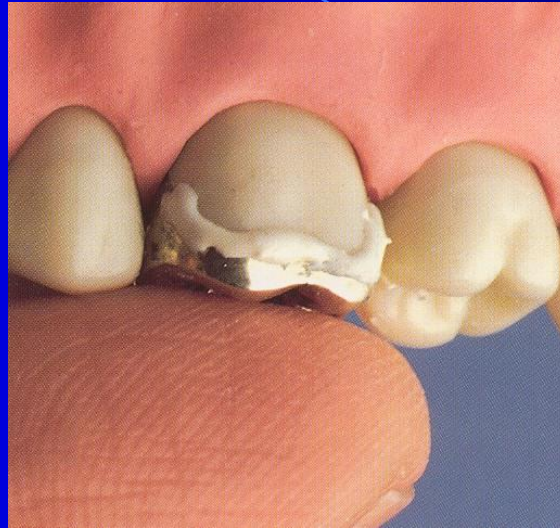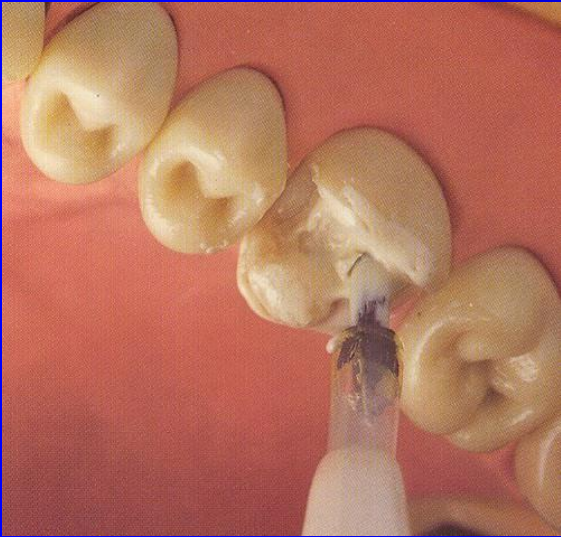
- Elastomeric materials
- Register of intermaxillary relations
- impression of the antagonal dental arch – alginate material.

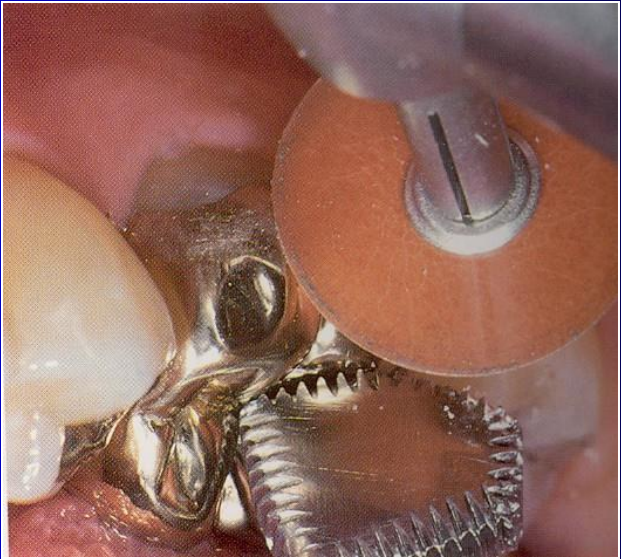
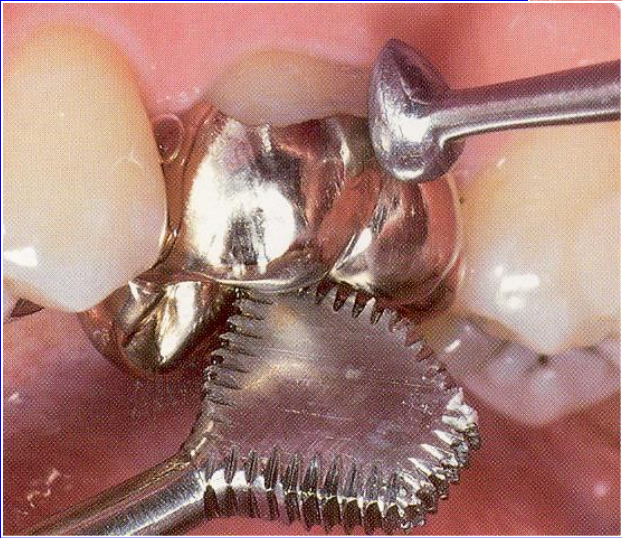
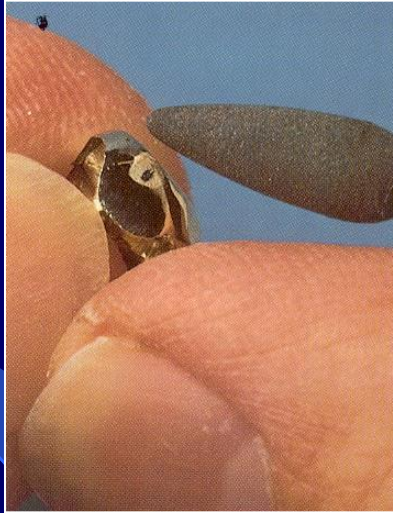
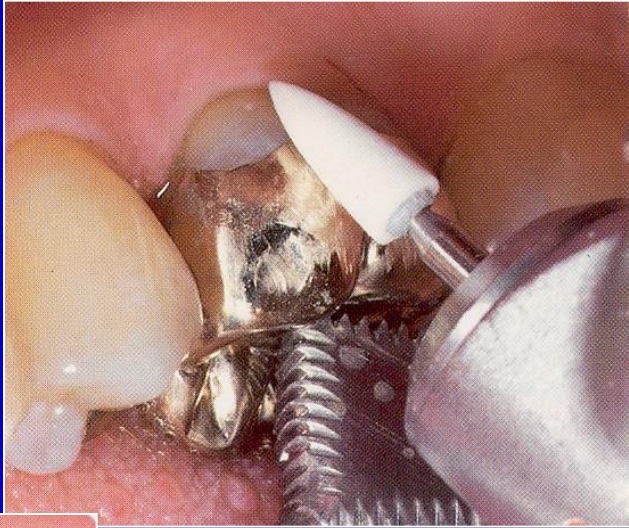
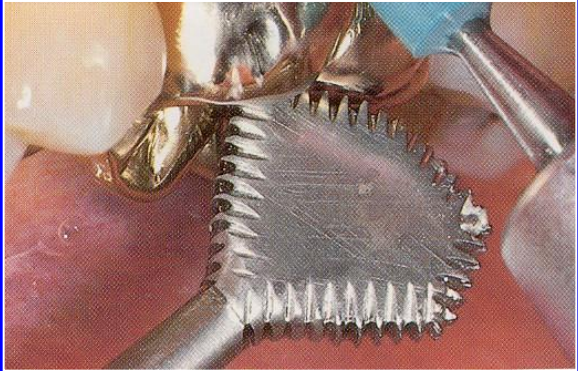






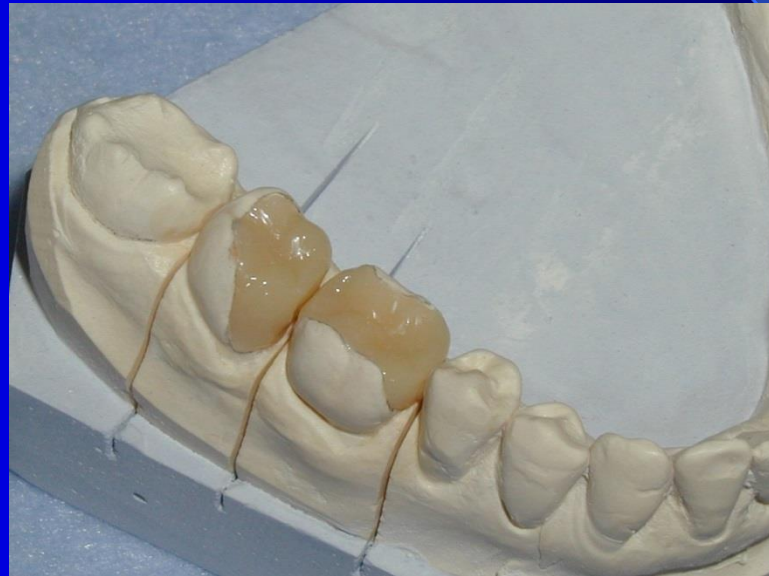Cementation of metal inlays – zinkoxidphosphate cement


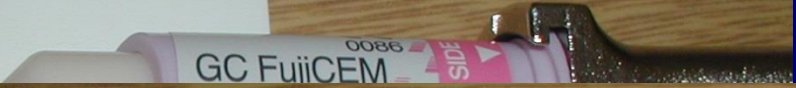




Cementation of composite or ceramic inlays – adhesive cements

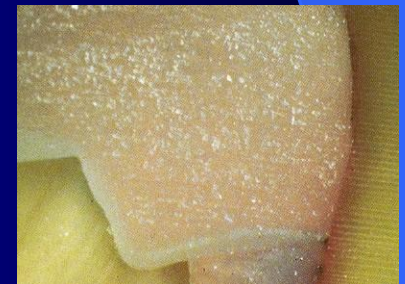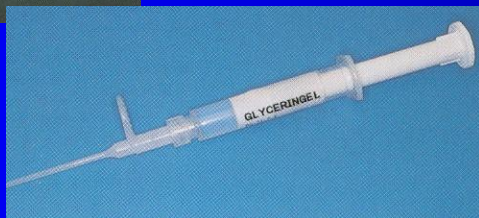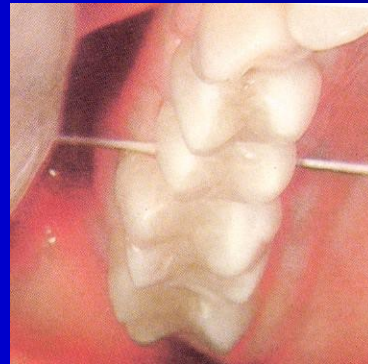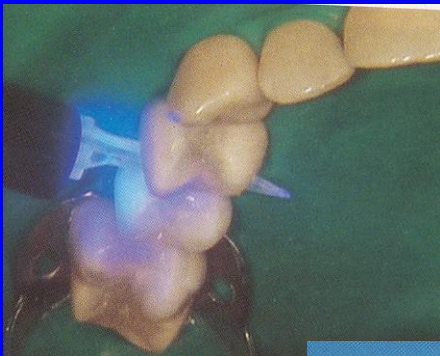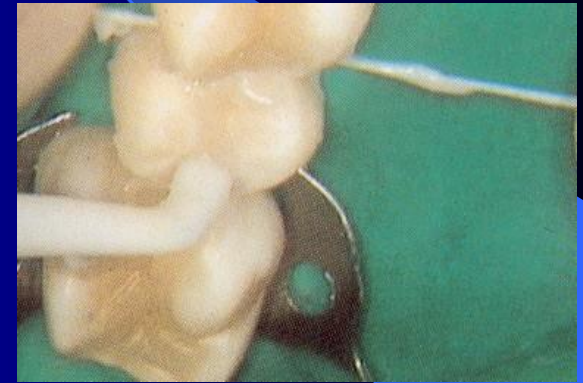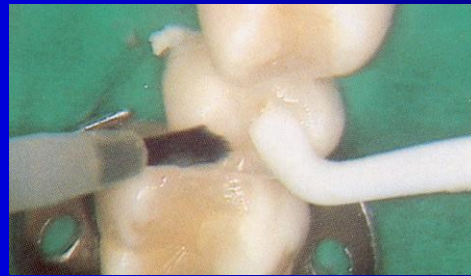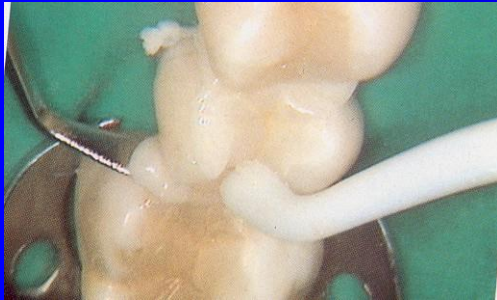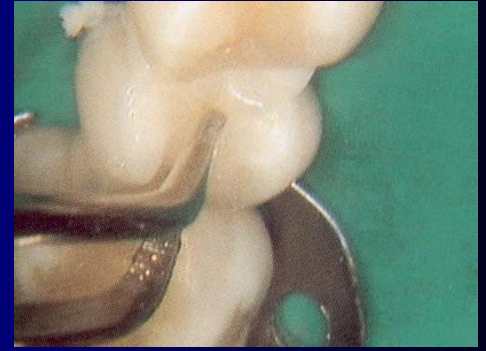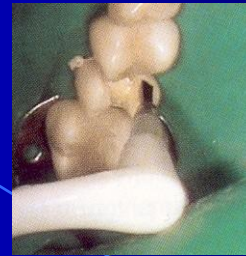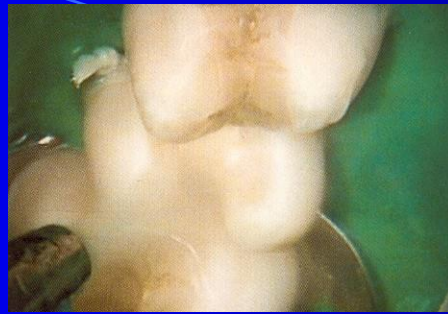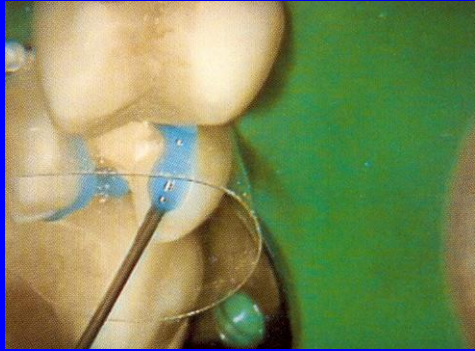
- These cements are based on composite material.

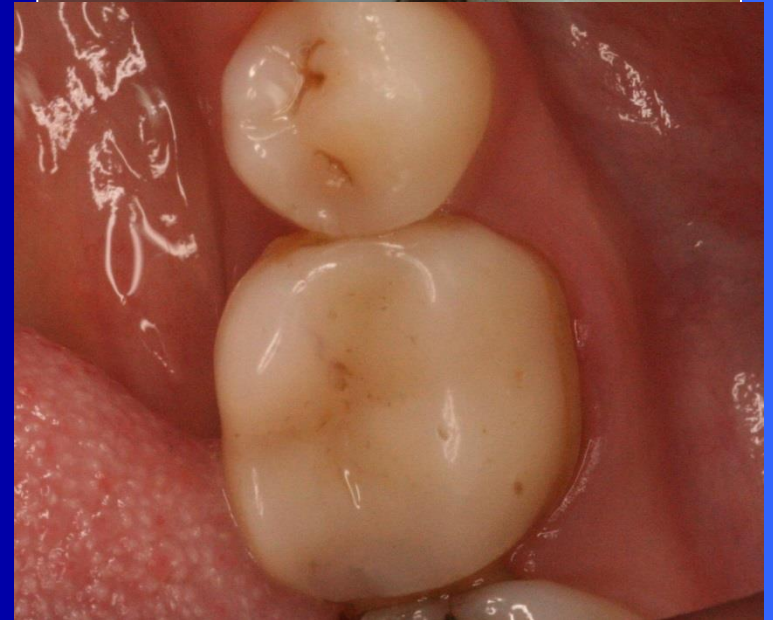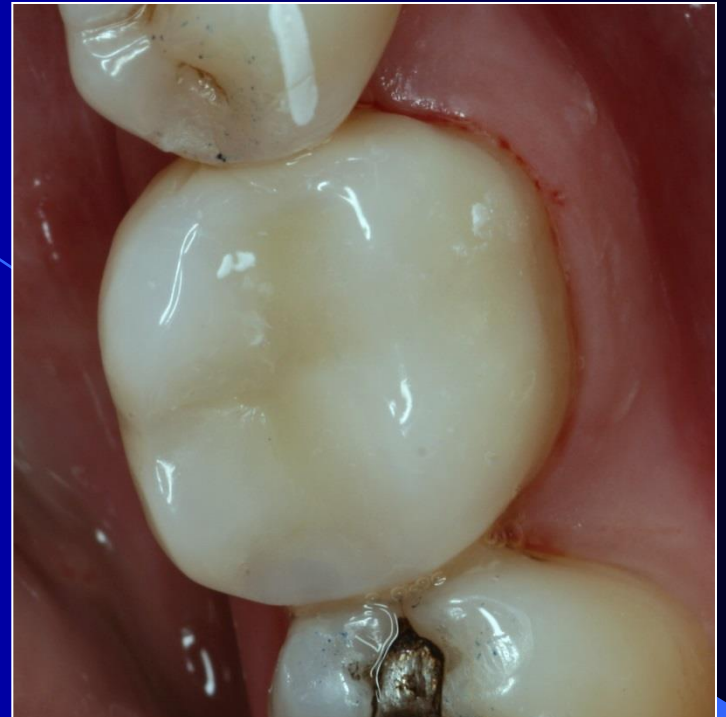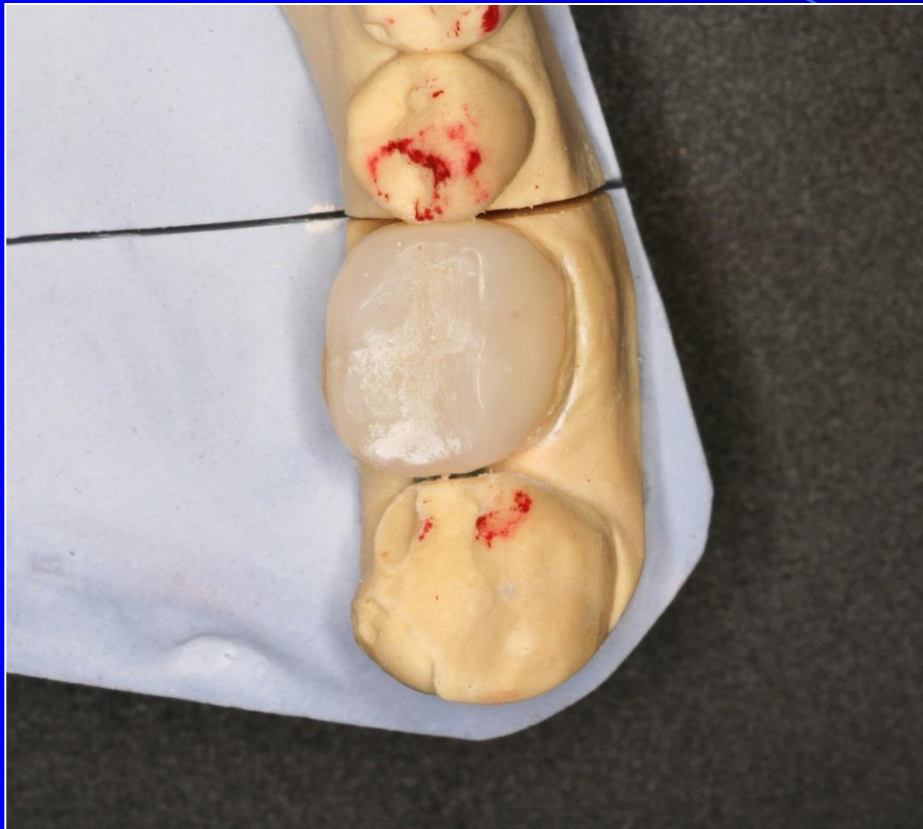




0086
GC FujiCEM
REINFORCED GLASS IONOMER
LUTING CEMENT
13.3g
(7.2mL)
YELLOW
GC
GC CORPORATION
TOKYO, JAPAN
MADE IN JAPAN
EXP. 20...
LOT 00...







lenka.roubalikova@tisc
ali.cz