

# AUTONOMNÍ NERVOVÝ SYSTÉM (ANS)

**složka centrální**

**složka periferní**

**sympatikus (pars sympathica)**

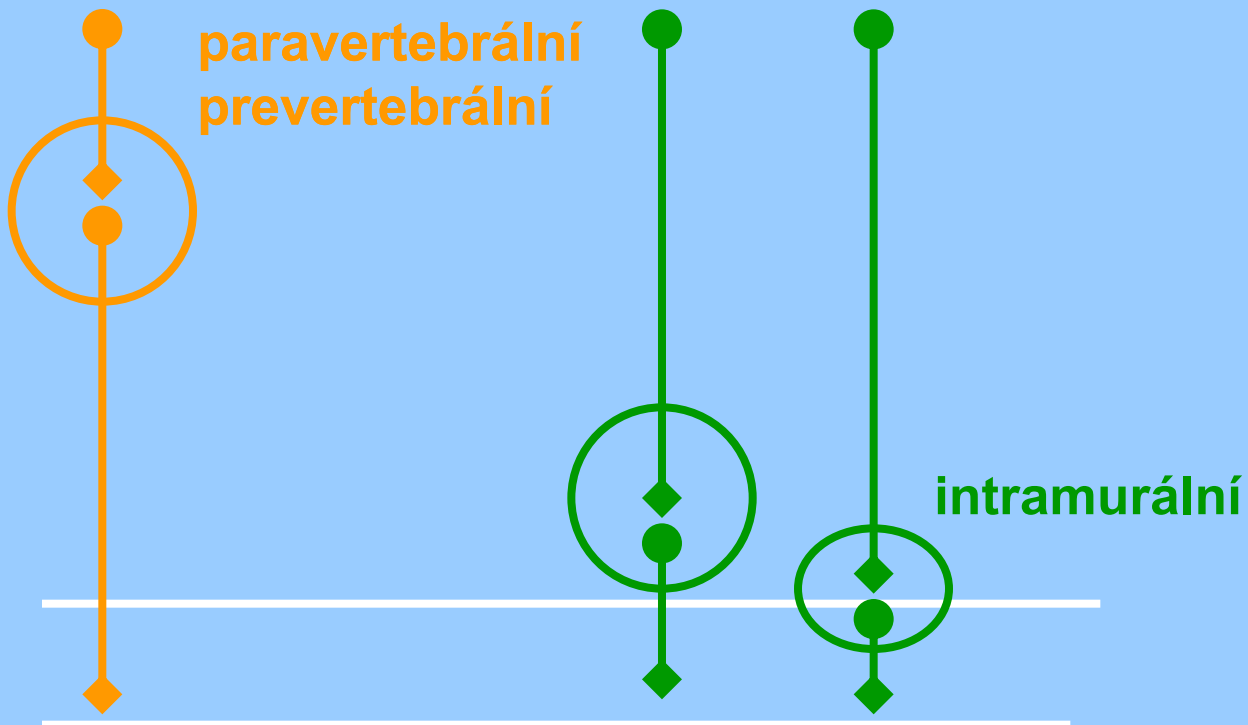
**parasympatikus (pars parasympathica)**

**enterický systém**

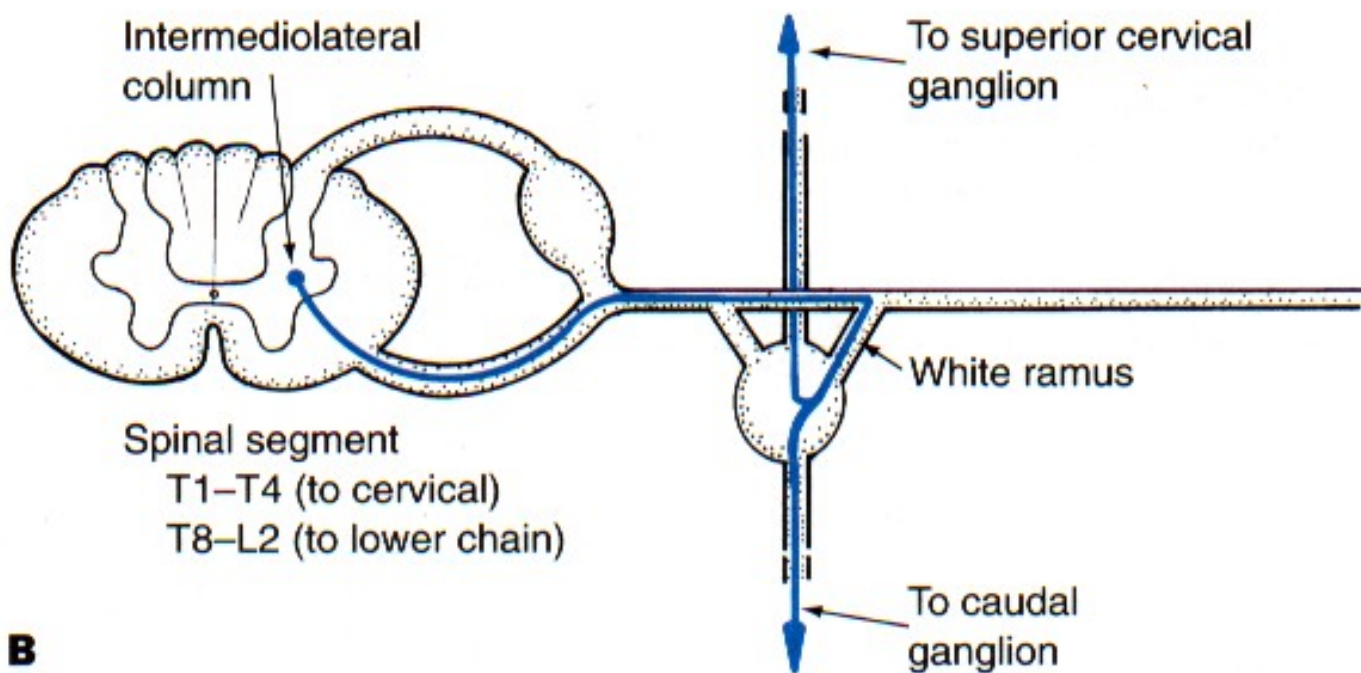
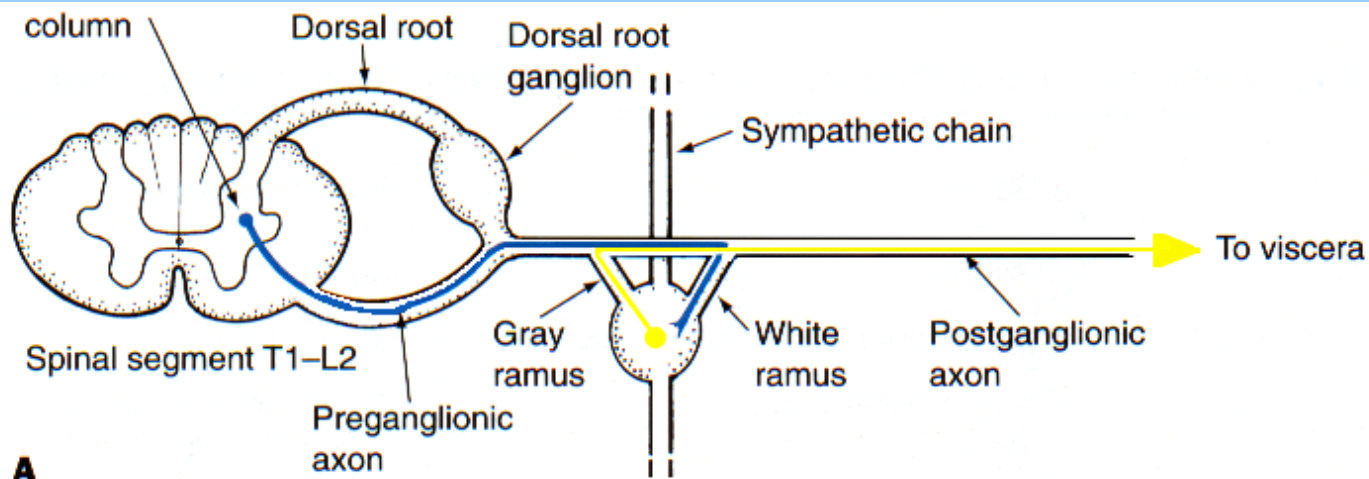
system kranio-sakrální (parasympathicus)

system thorako-lumbální (sympathicus)

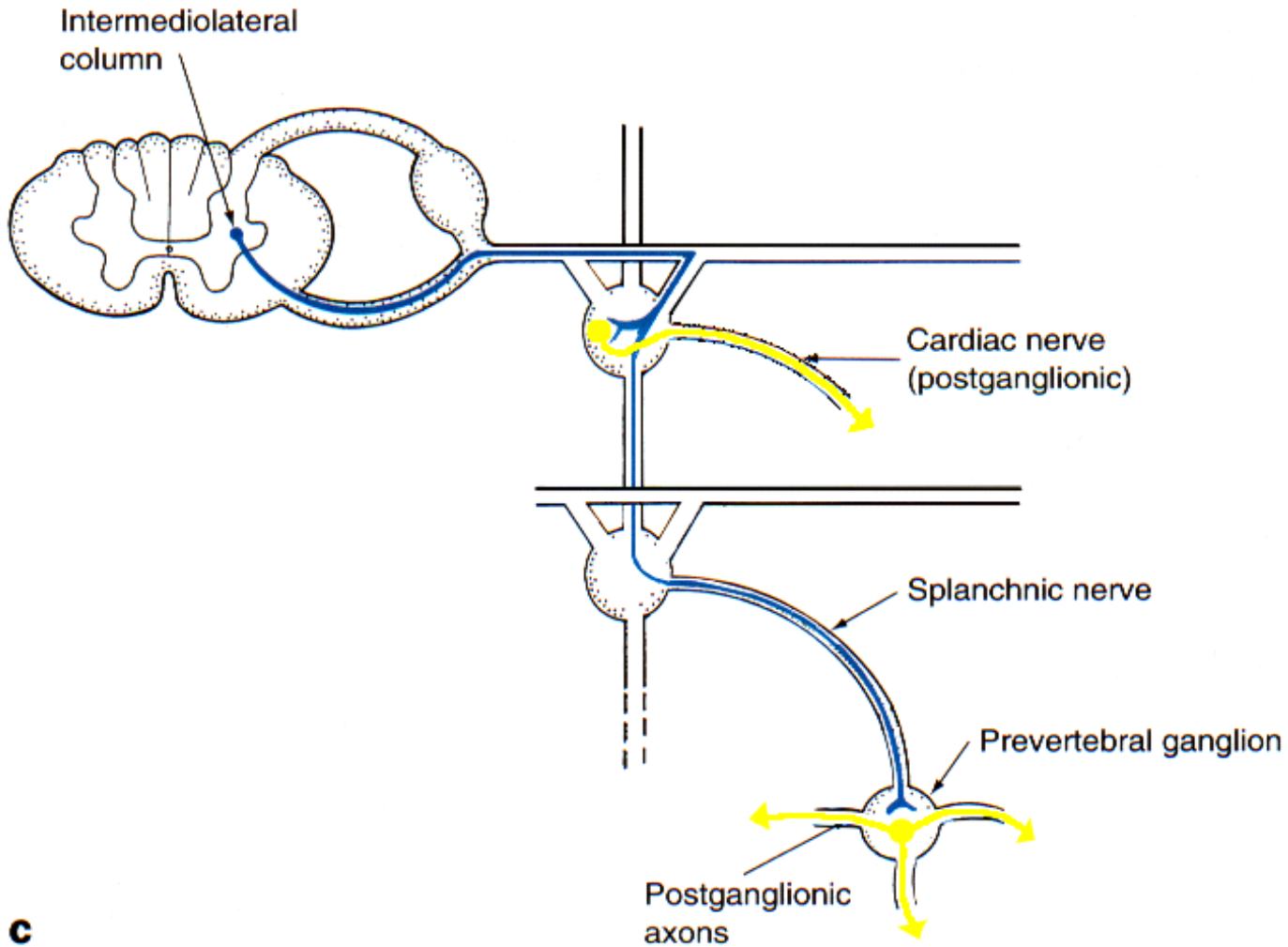
system kranio-sakrální (parasympathicus)



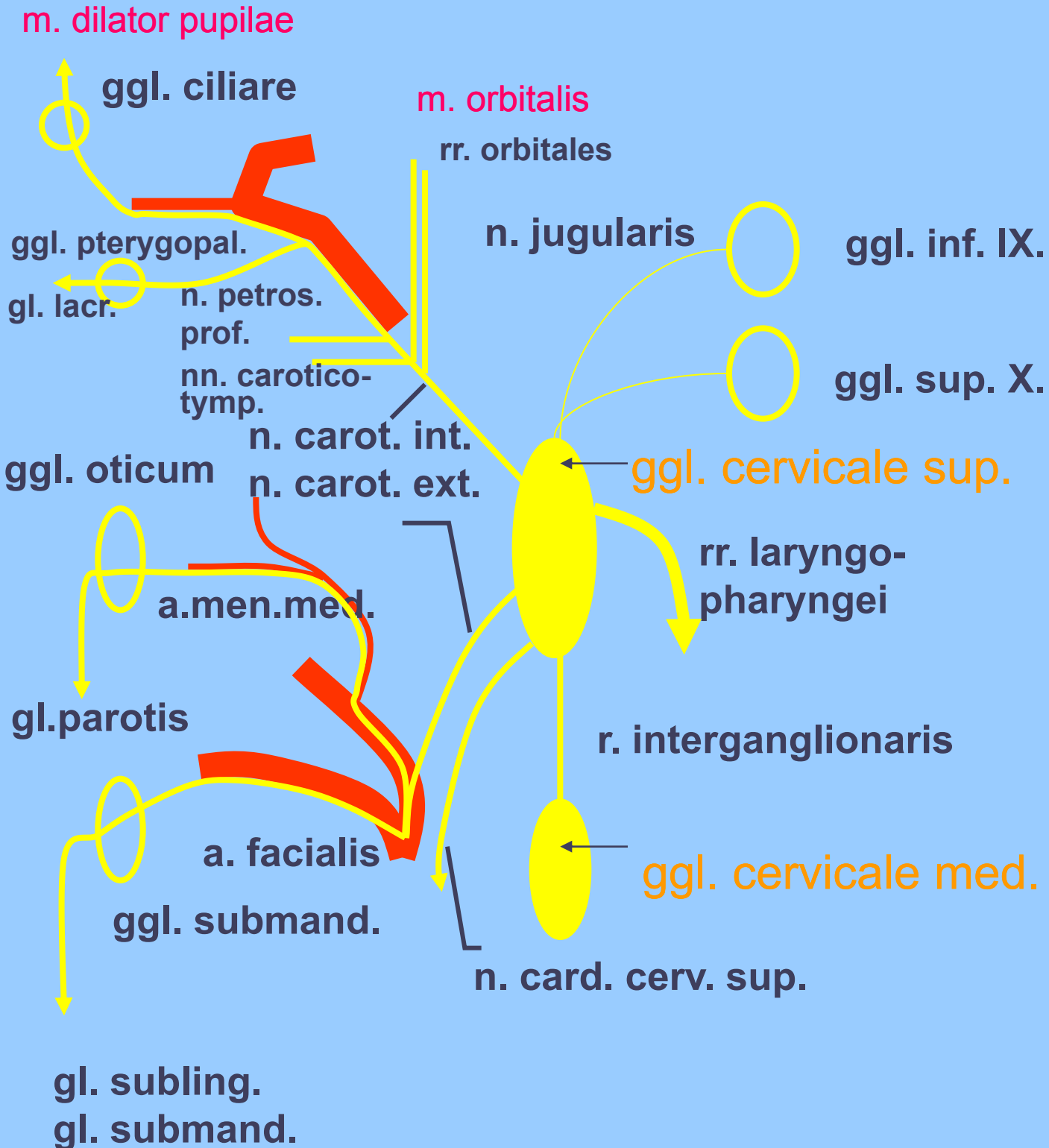
# Způsob přepojení sympatických pregangliových axonů I-II



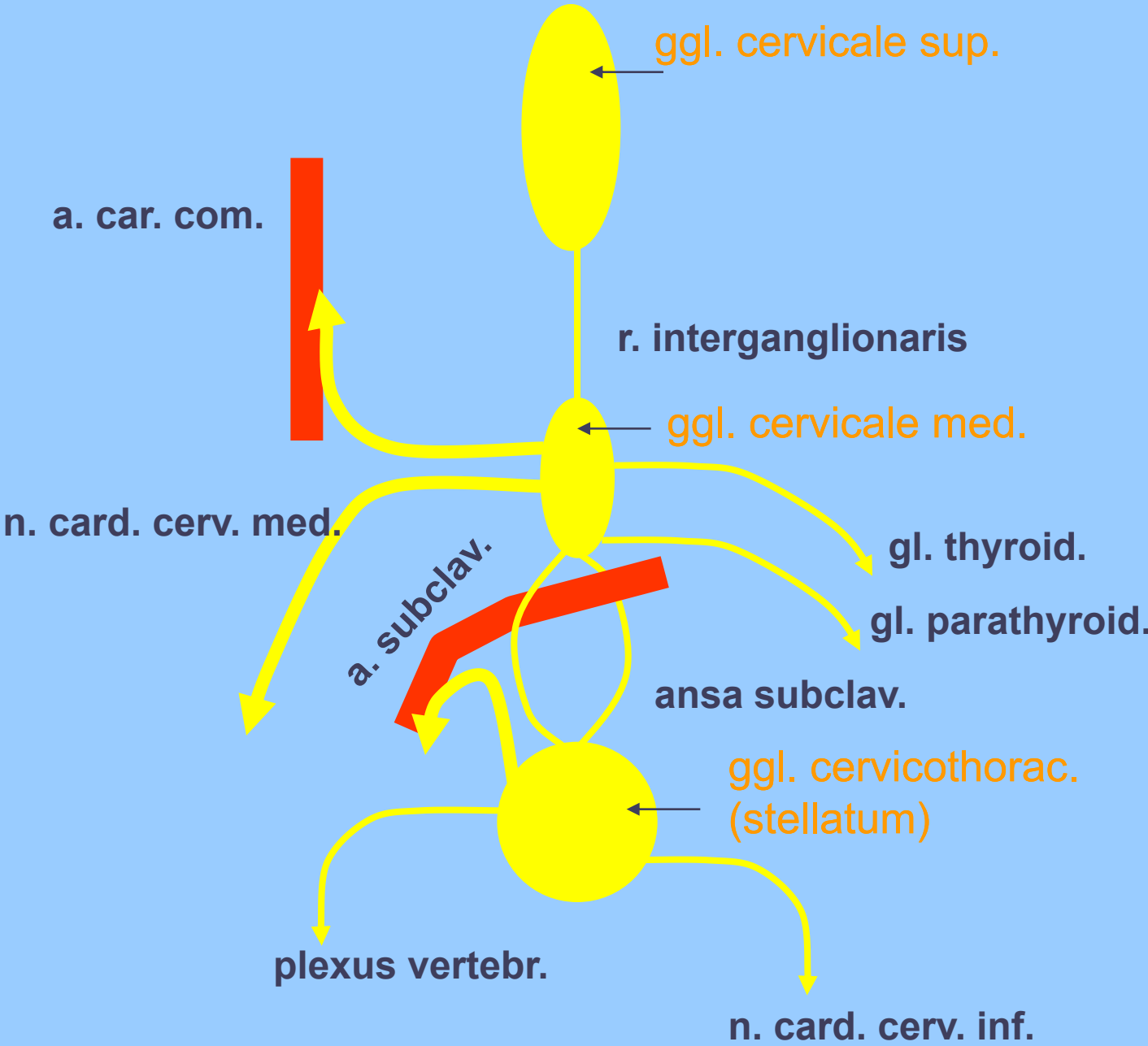
# Způsob přepojení sympatických pregangliových axonů III



# Ggl. cervicale sup.



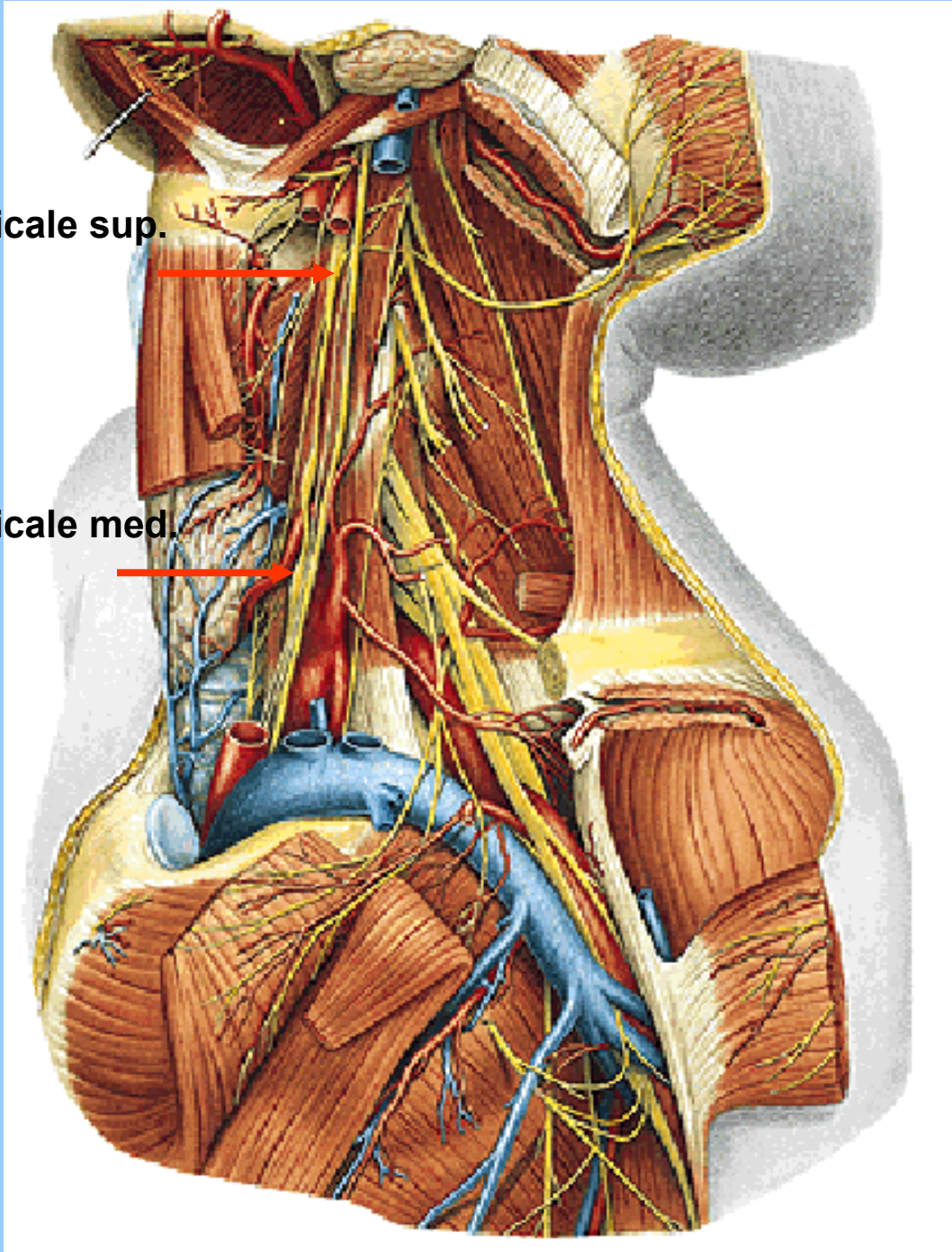
# Ggl. cervicale med. et stellatum



# Ganglion cervicale sup. et med.

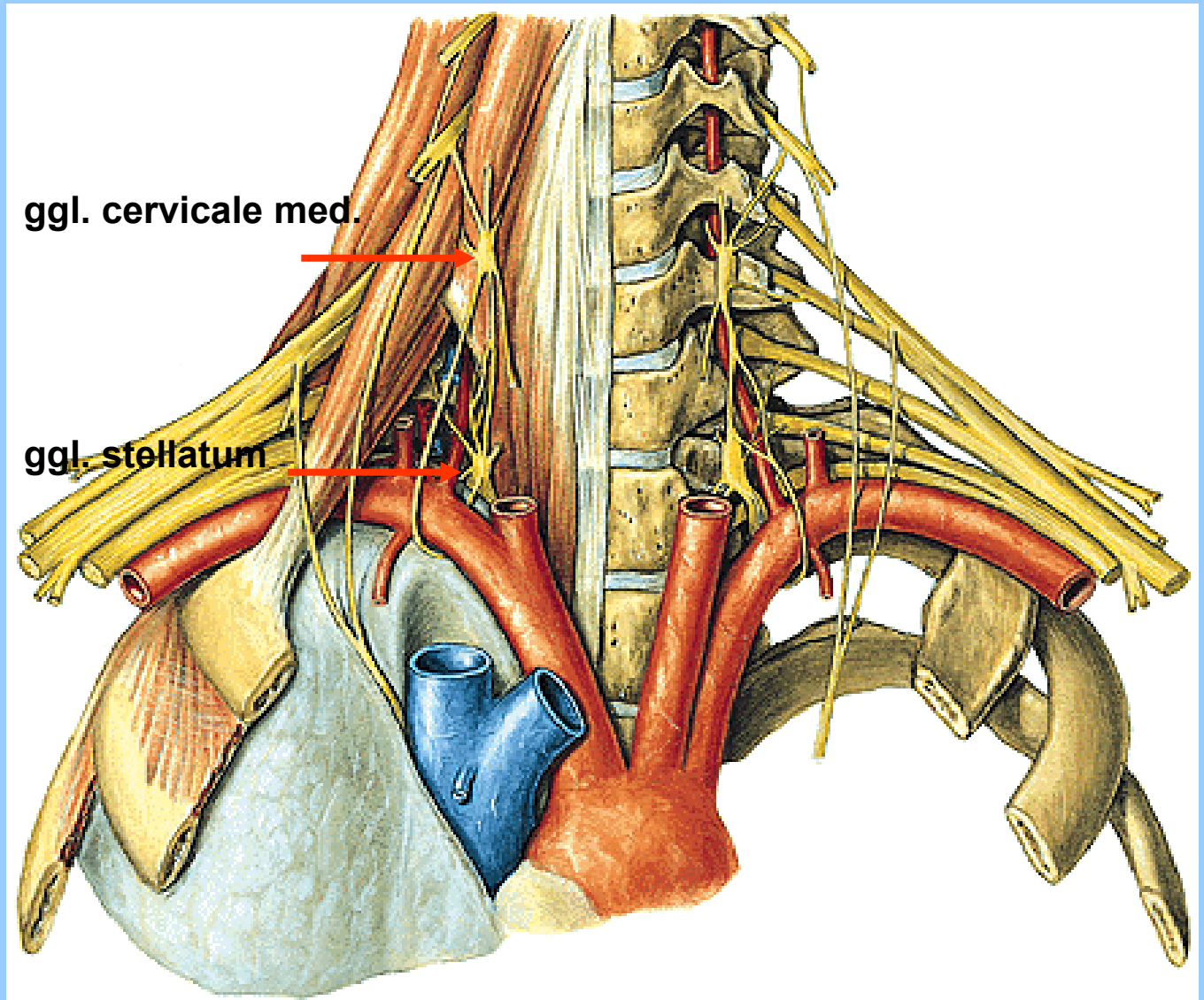
ggl. cervicale sup.

ggl. cervicale med.

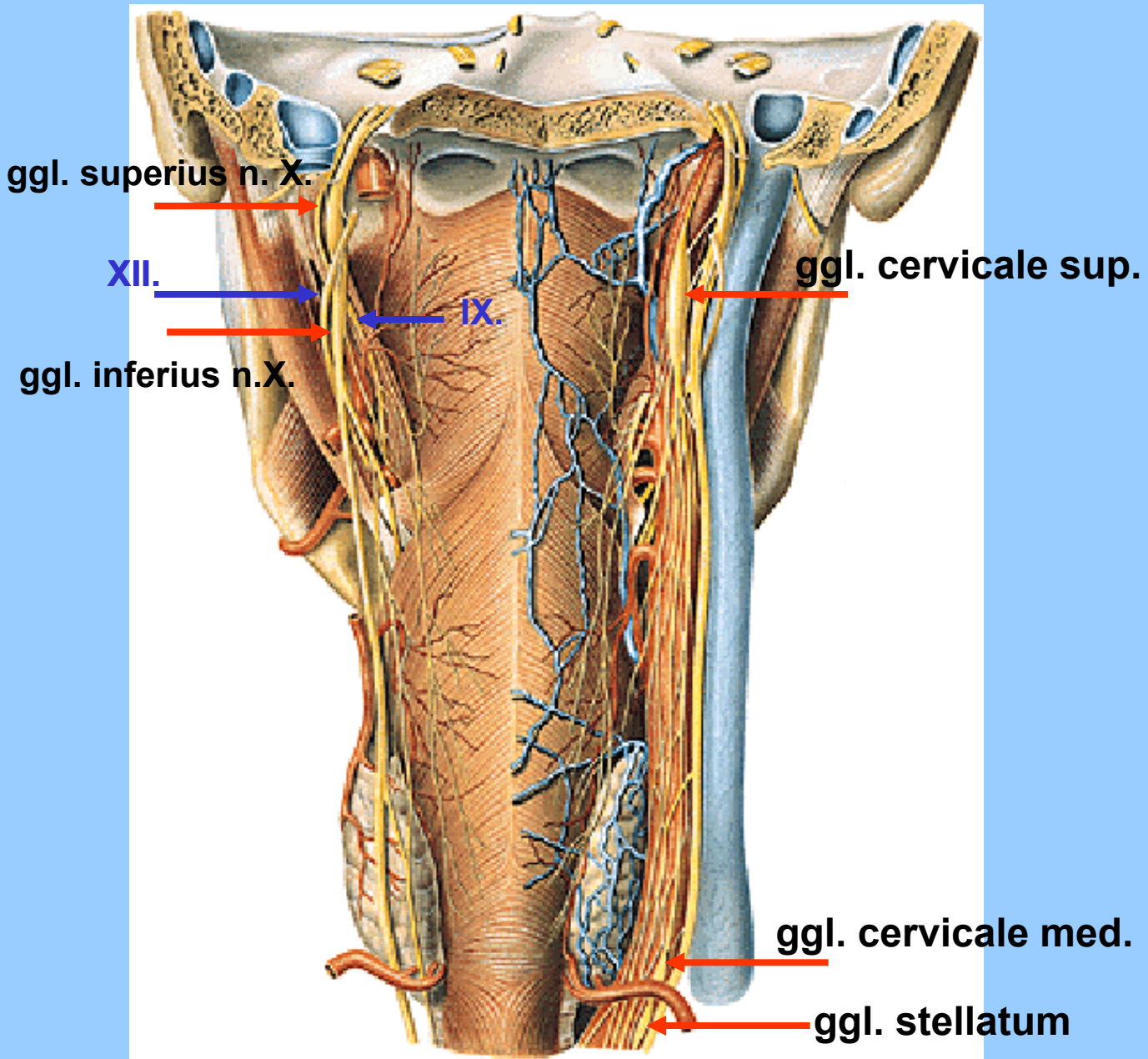




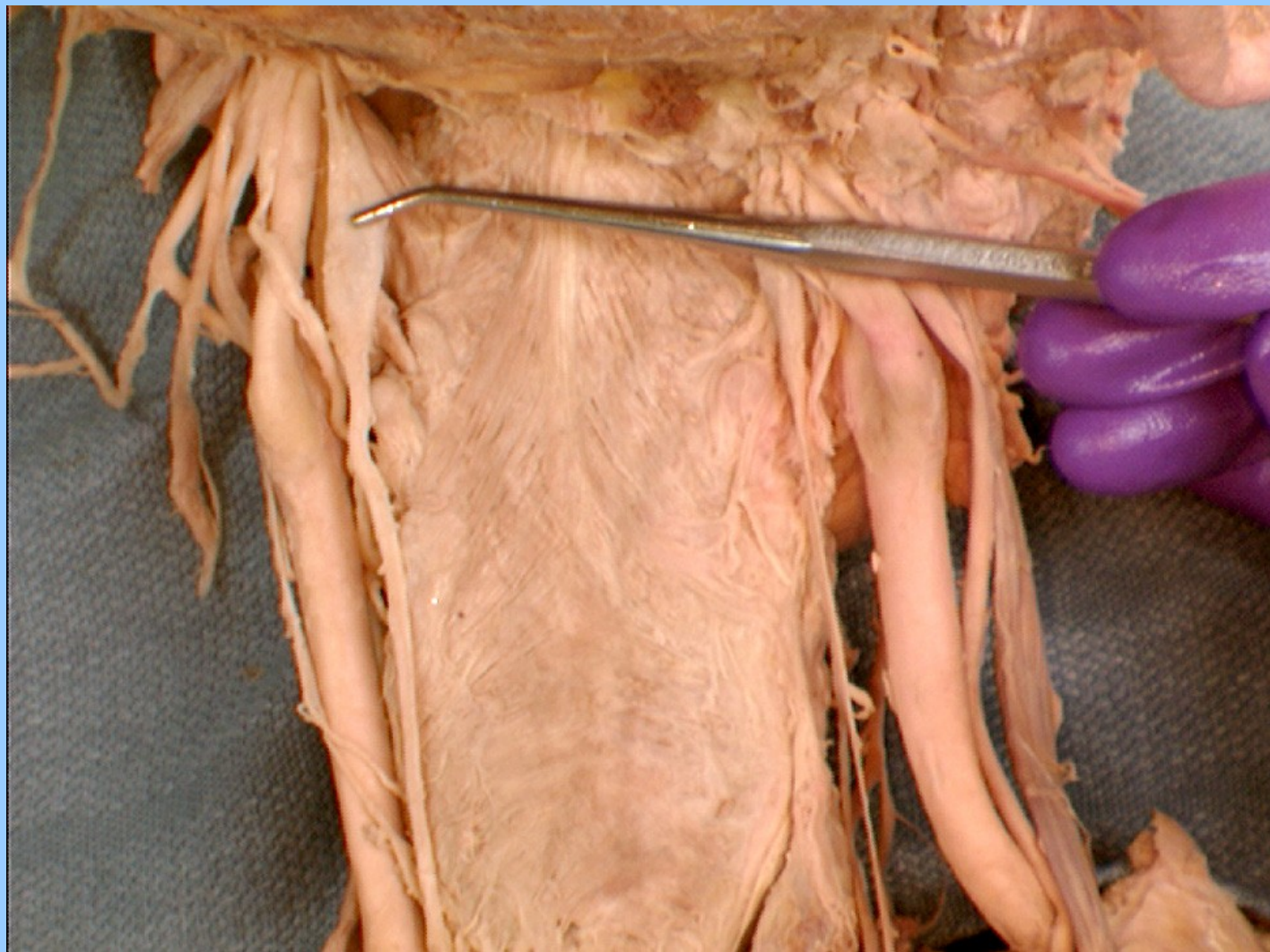
# Ganglion cervicale med. et stellatum



# Ganglion cervicale sup. et med.



## GANGLION CERVICALE SUP.



# INNERVATION OF THE HEART

ggl. cervicale sup.



ggl. cervicale med.



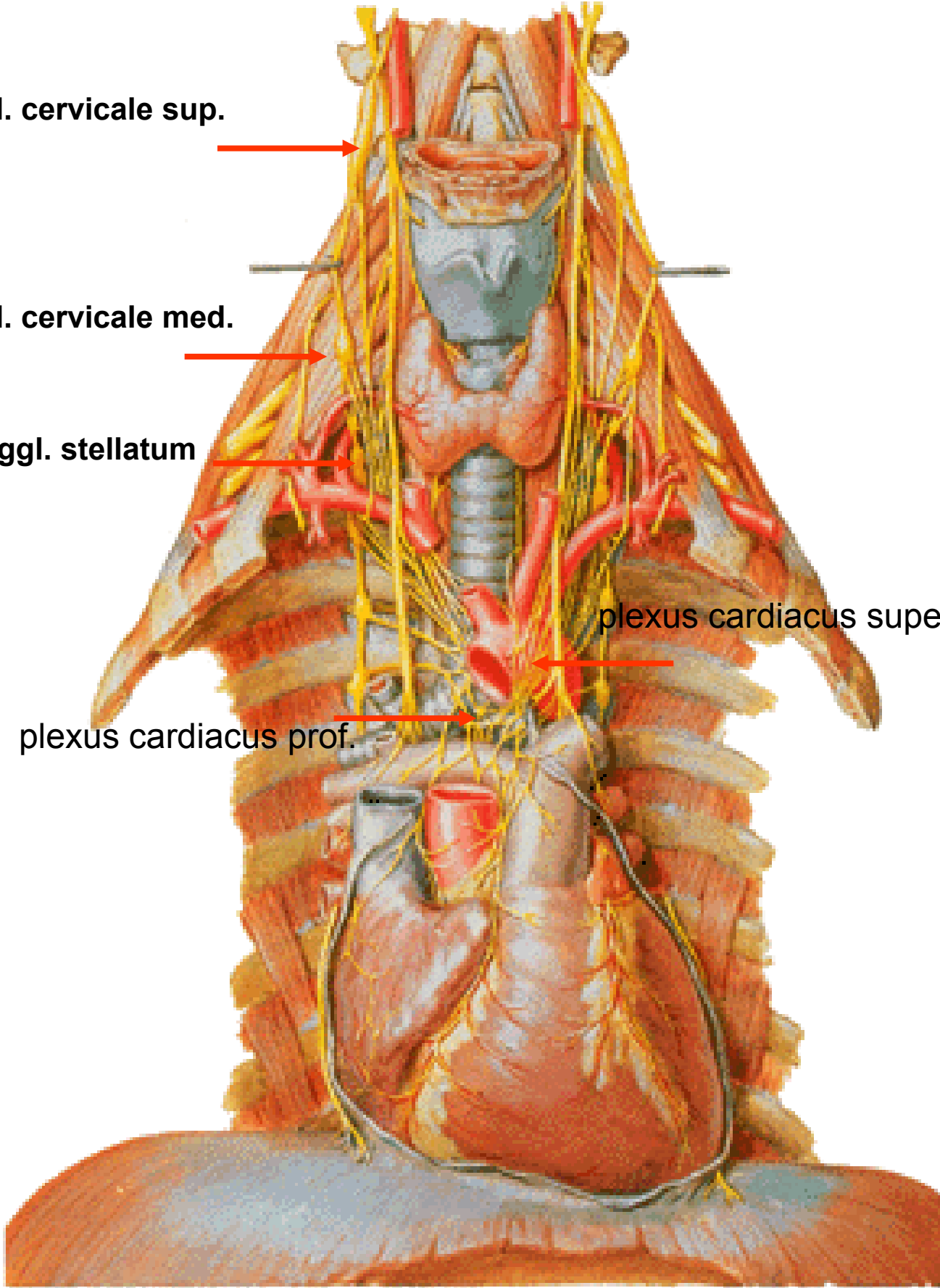
ggl. stellatum

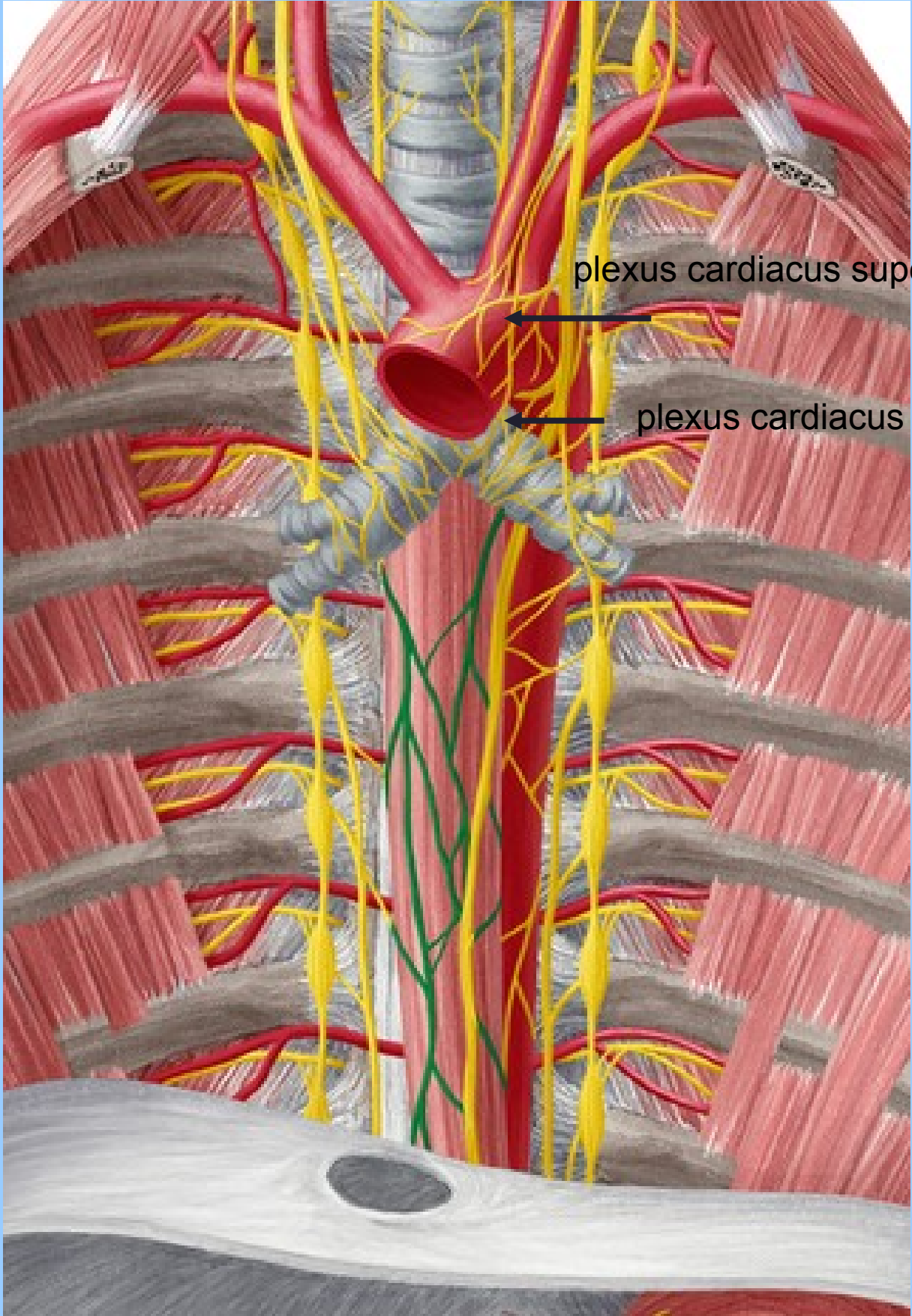


plexus cardiacus superf.



plexus cardiacus prof.





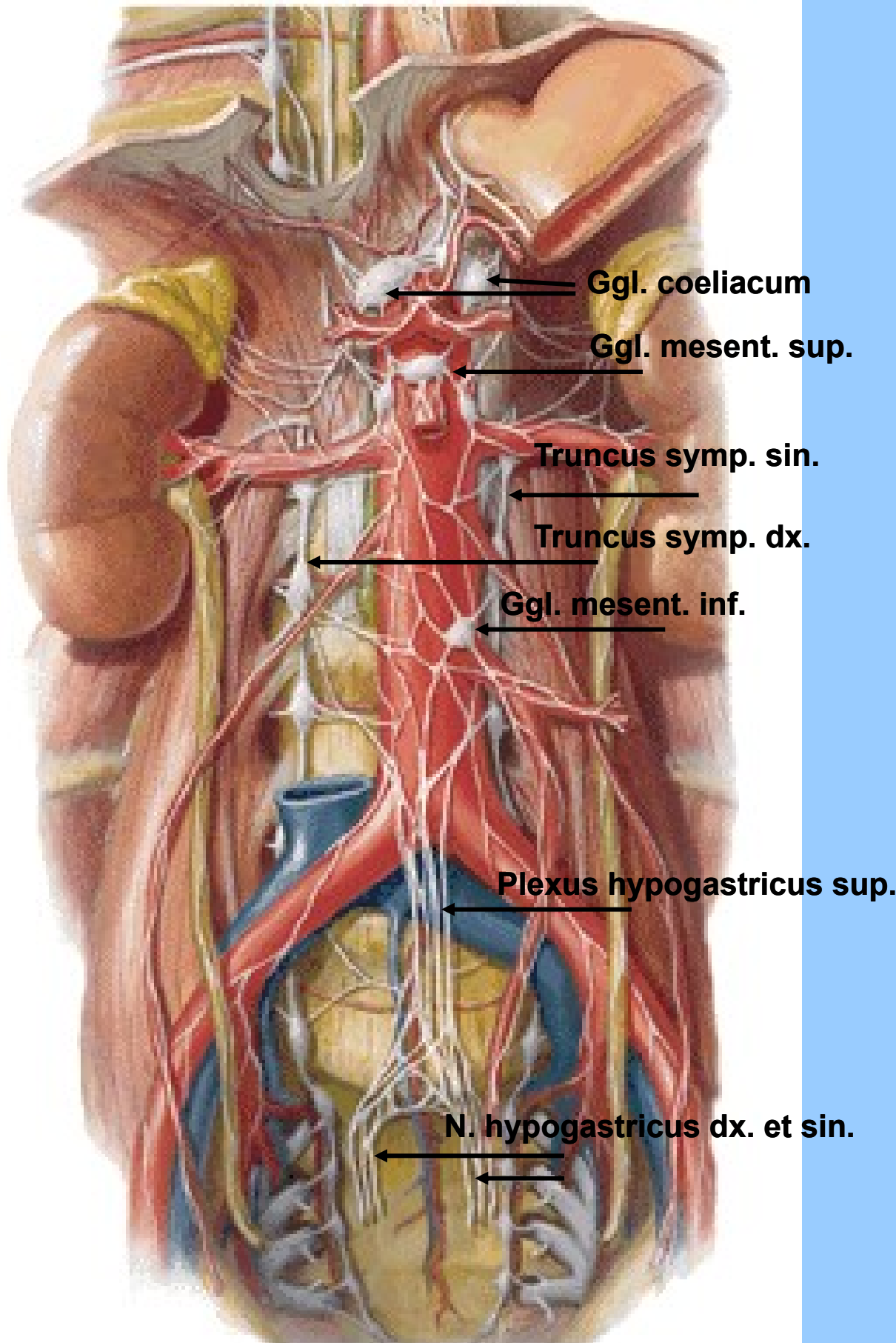
plexus cardiacus superf.

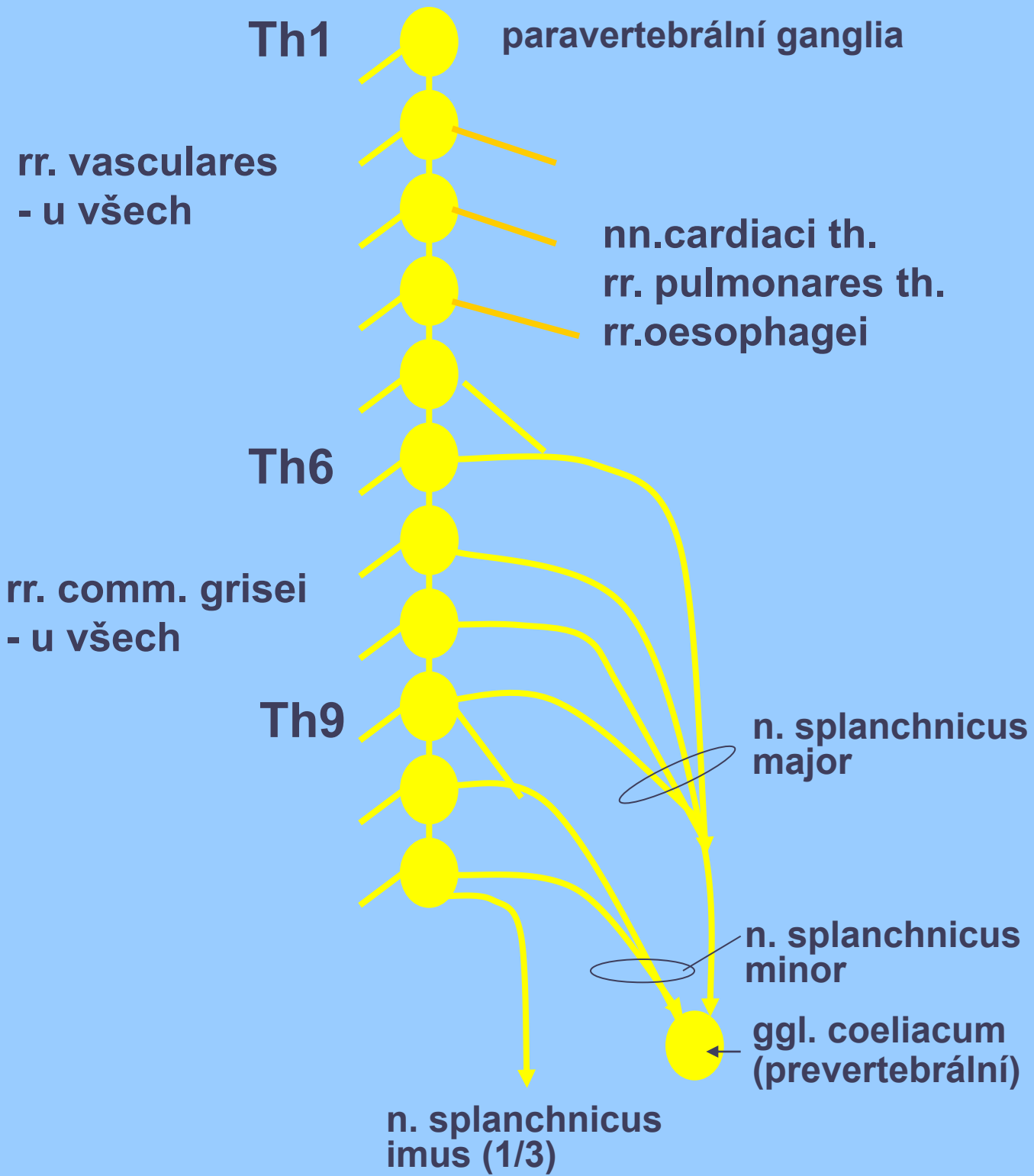


plexus cardiacus prof.









## **Prevertebrální ganglia**

ggl. coeliacum

ggl. mesentericum superius

ggl. mesentericum inferius

ggl. aorticorenale

## **Plexus aorticus lumbalis**

### ***ggl./plexus coeliacus***

plexus gastricus dx., sn.

plexus hepaticus

plexus lienalis

plexus duodenalis

plexus pancreaticus

plexus uretericus

plexus testicularis/ovaricus

### ***ggl. mesentericum superius***

plexus mesentericus superior

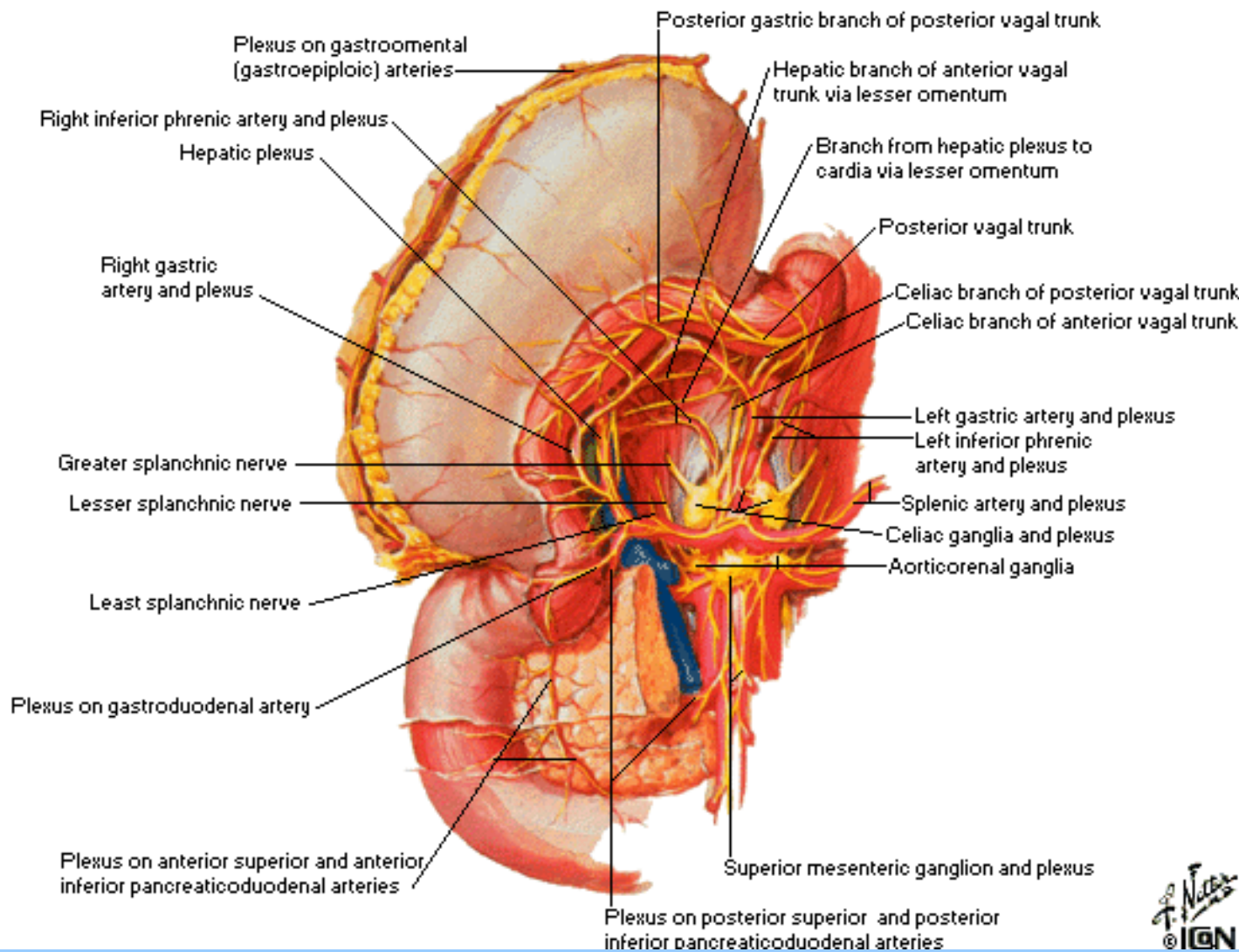
### ***ggl. mesentericum inferius***

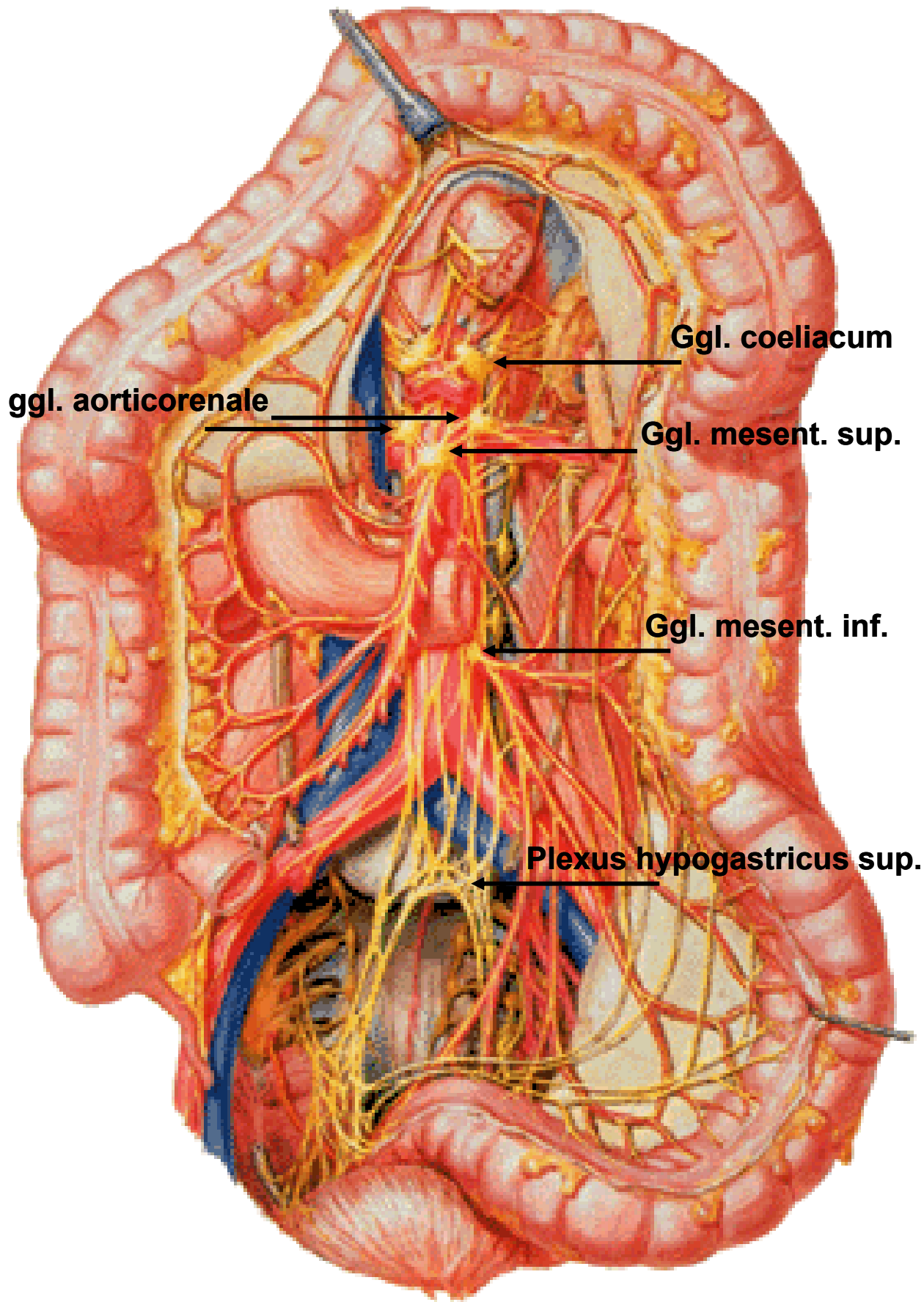
plexus mesentericus inferior

plexus rectalis superior

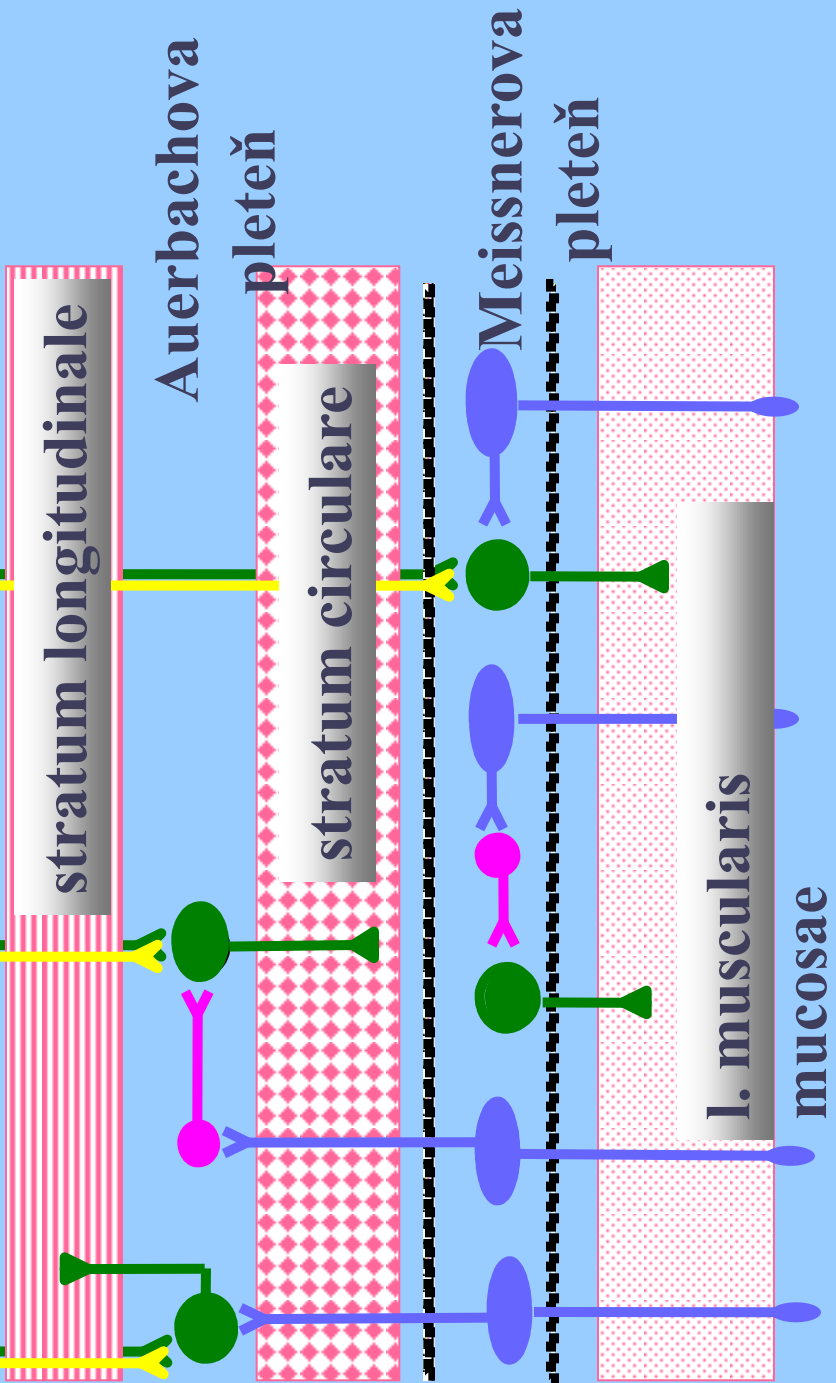
## **Plexus hypogastricus superior et inferior**







ovlivnění  
(modulace)  
symp. a  
parasymptatik  
em



enterický motorický neuron)



enterický interneuron



enterický viscerosenzorický neuron

