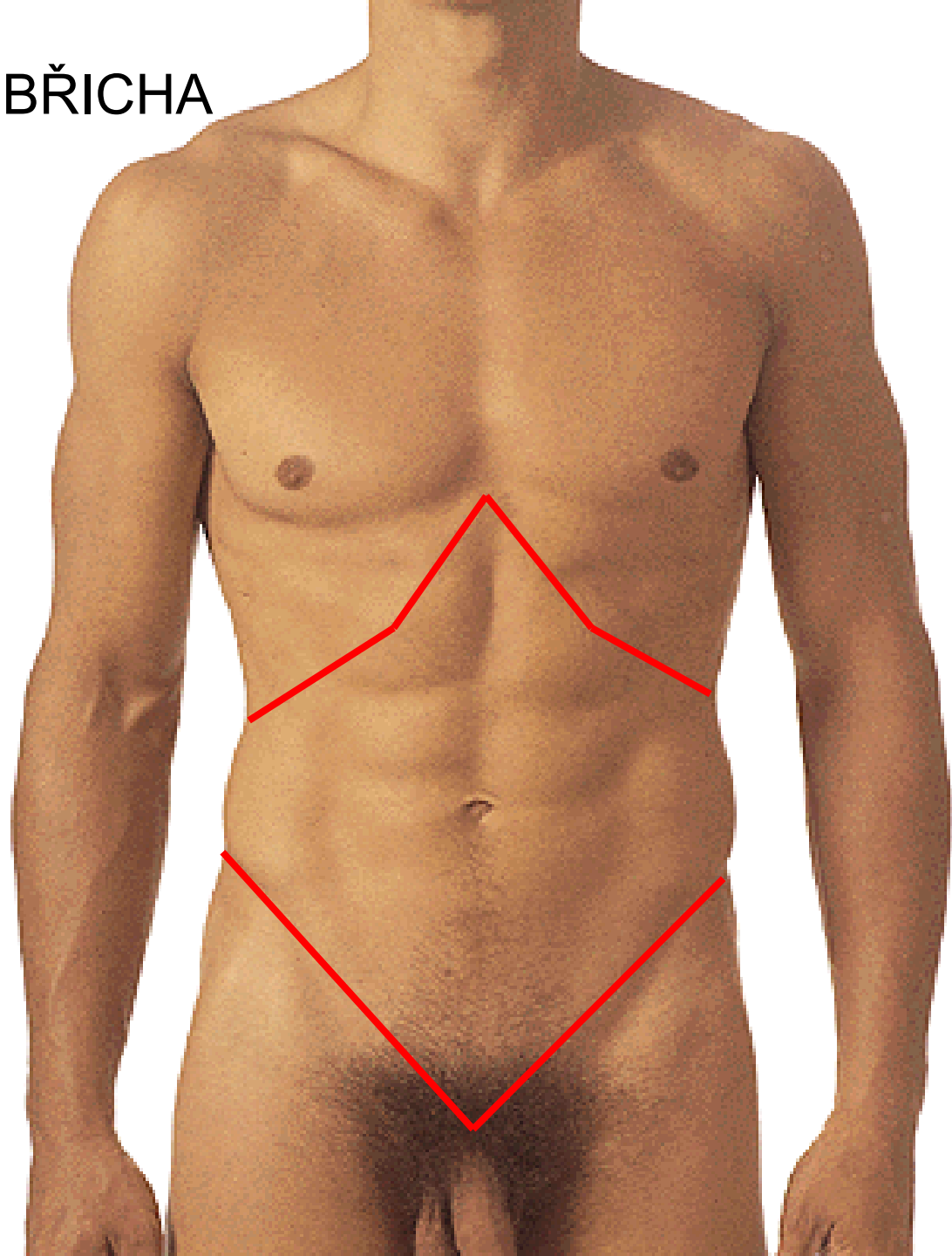
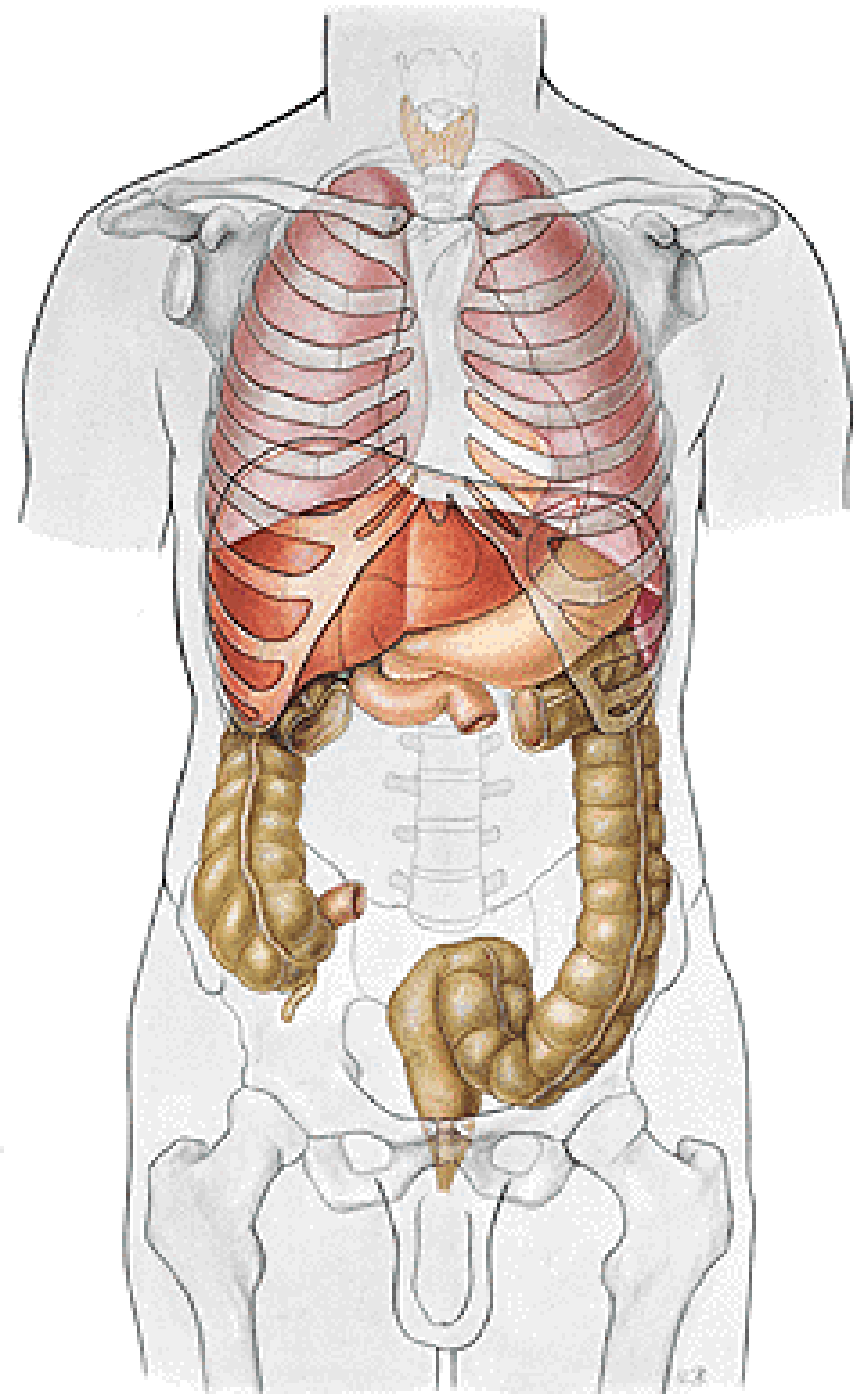


PROJEKCE ORGÁNŮ NA STĚNU BŘIŠNÍ

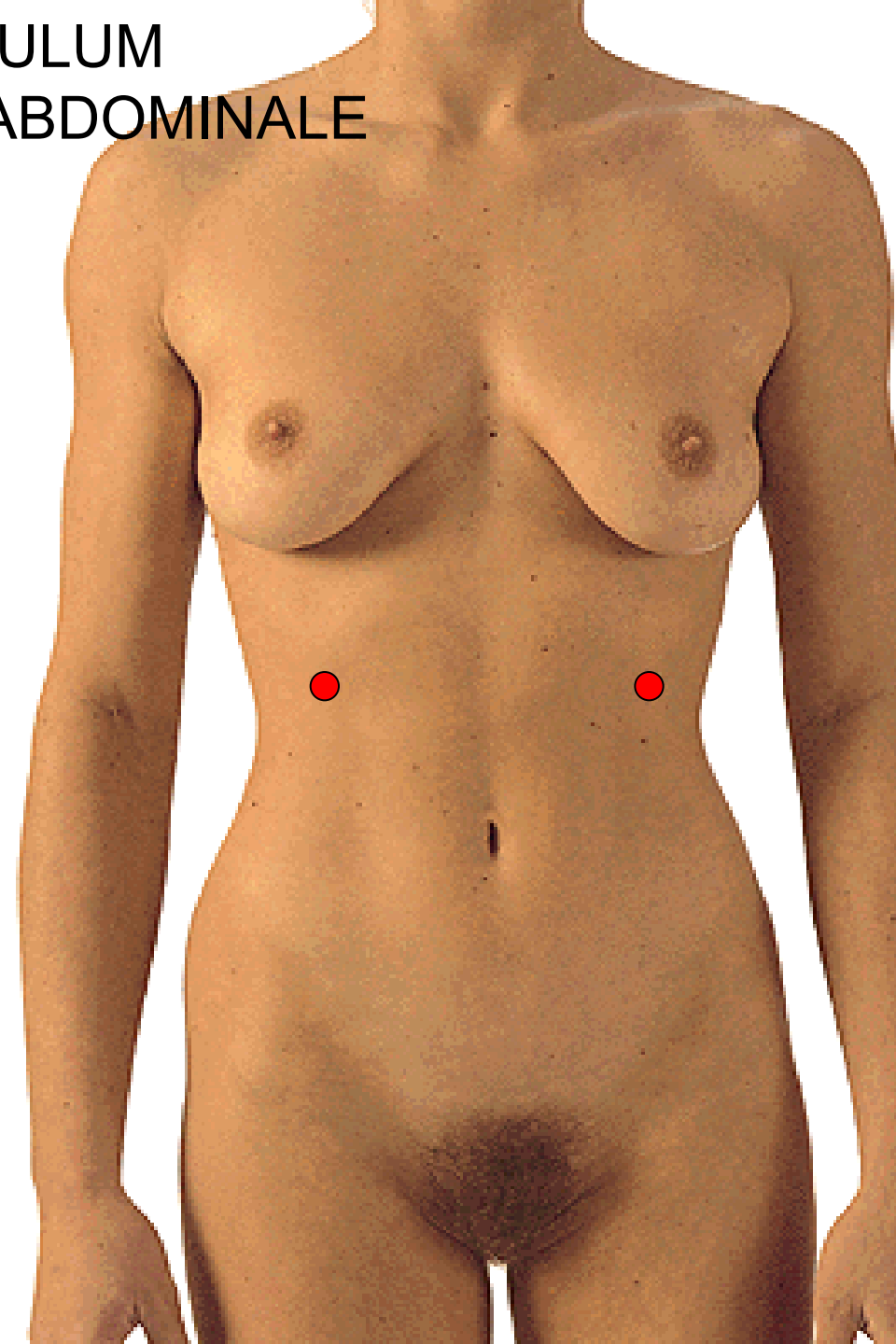
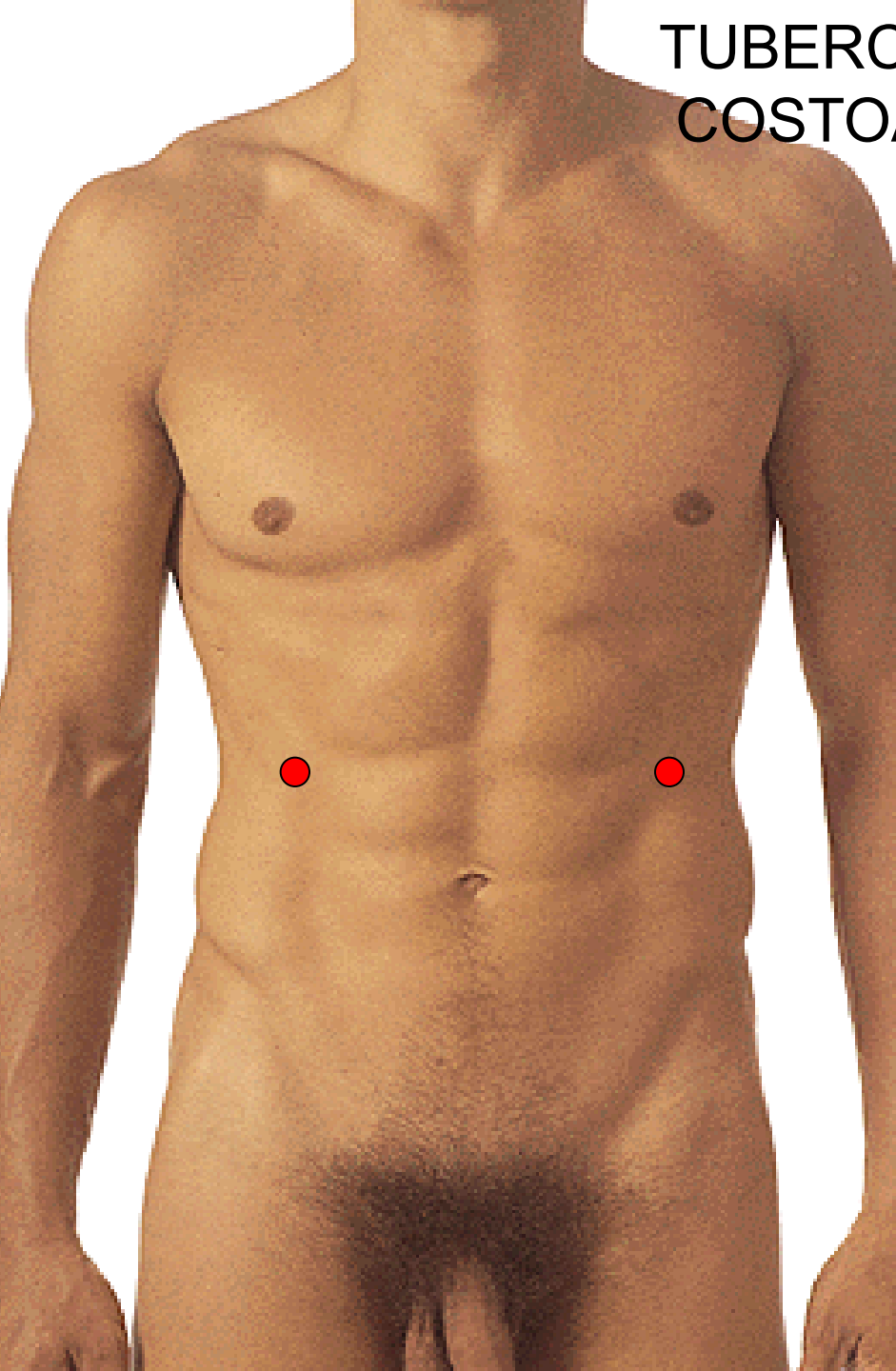
POVRCHOVÉ HRANICE BŘICHA



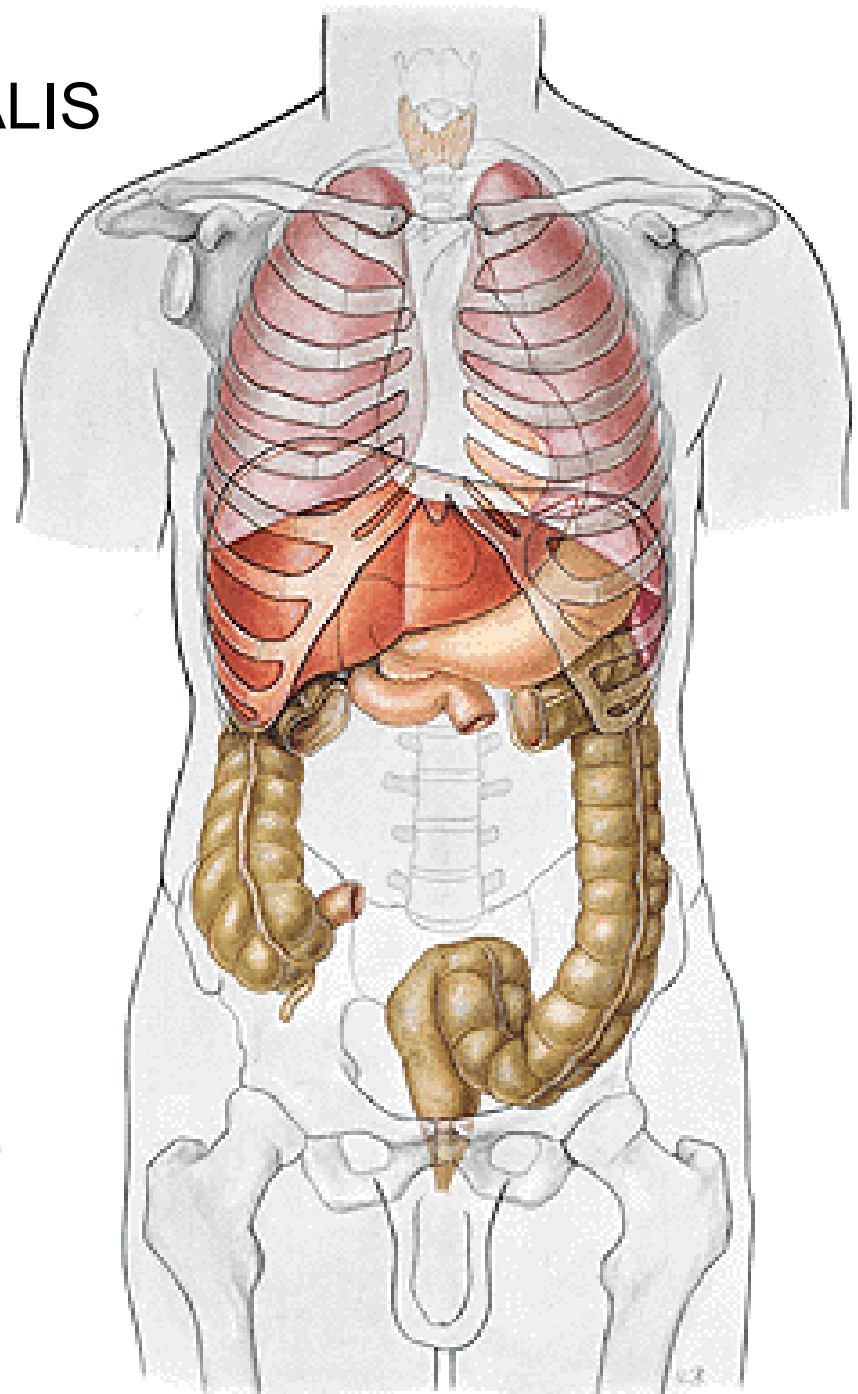
HLUBOKÉ HRANICE
- DIAPHRAGMA
- LINEA TERMINALIS



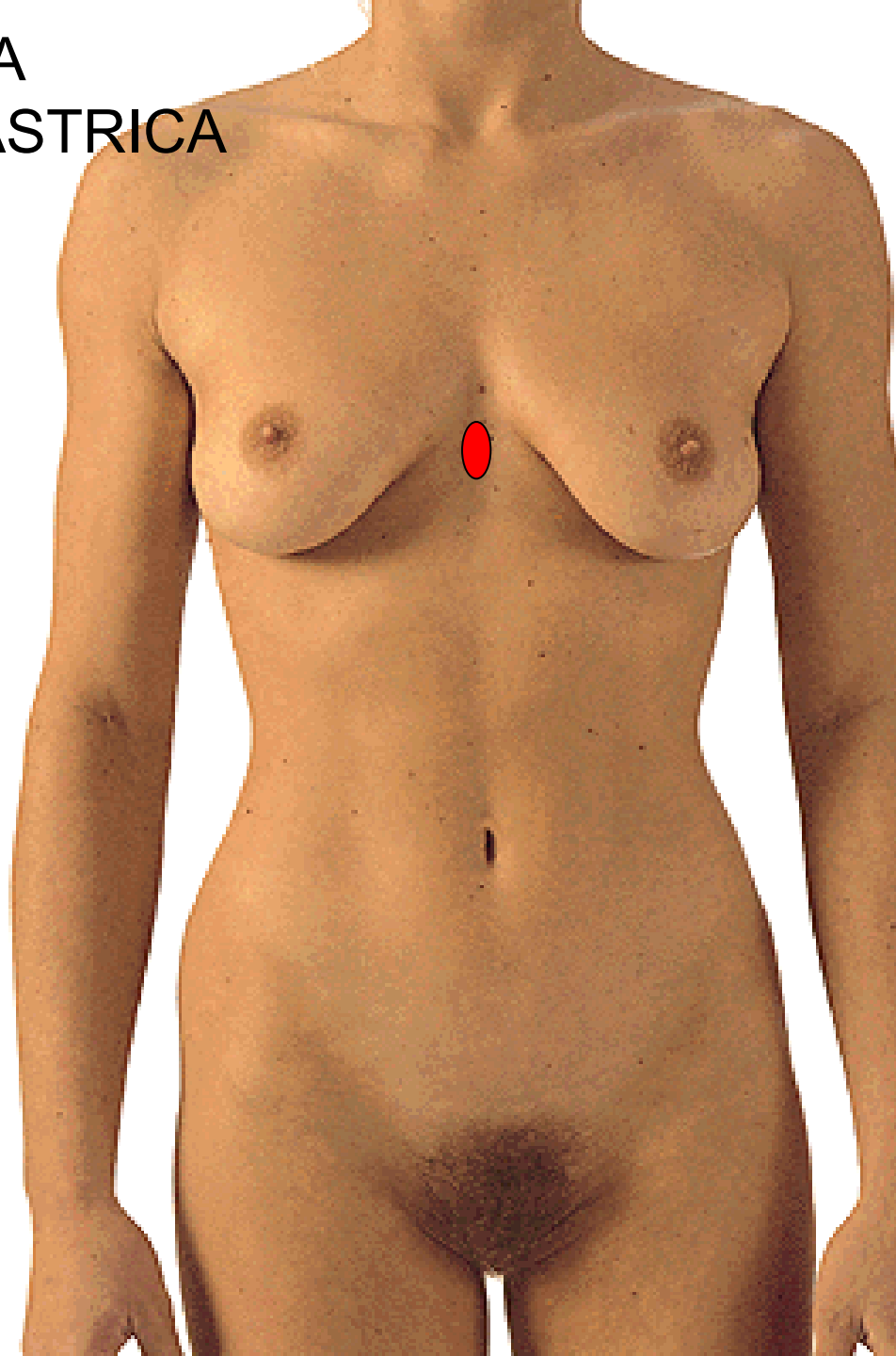
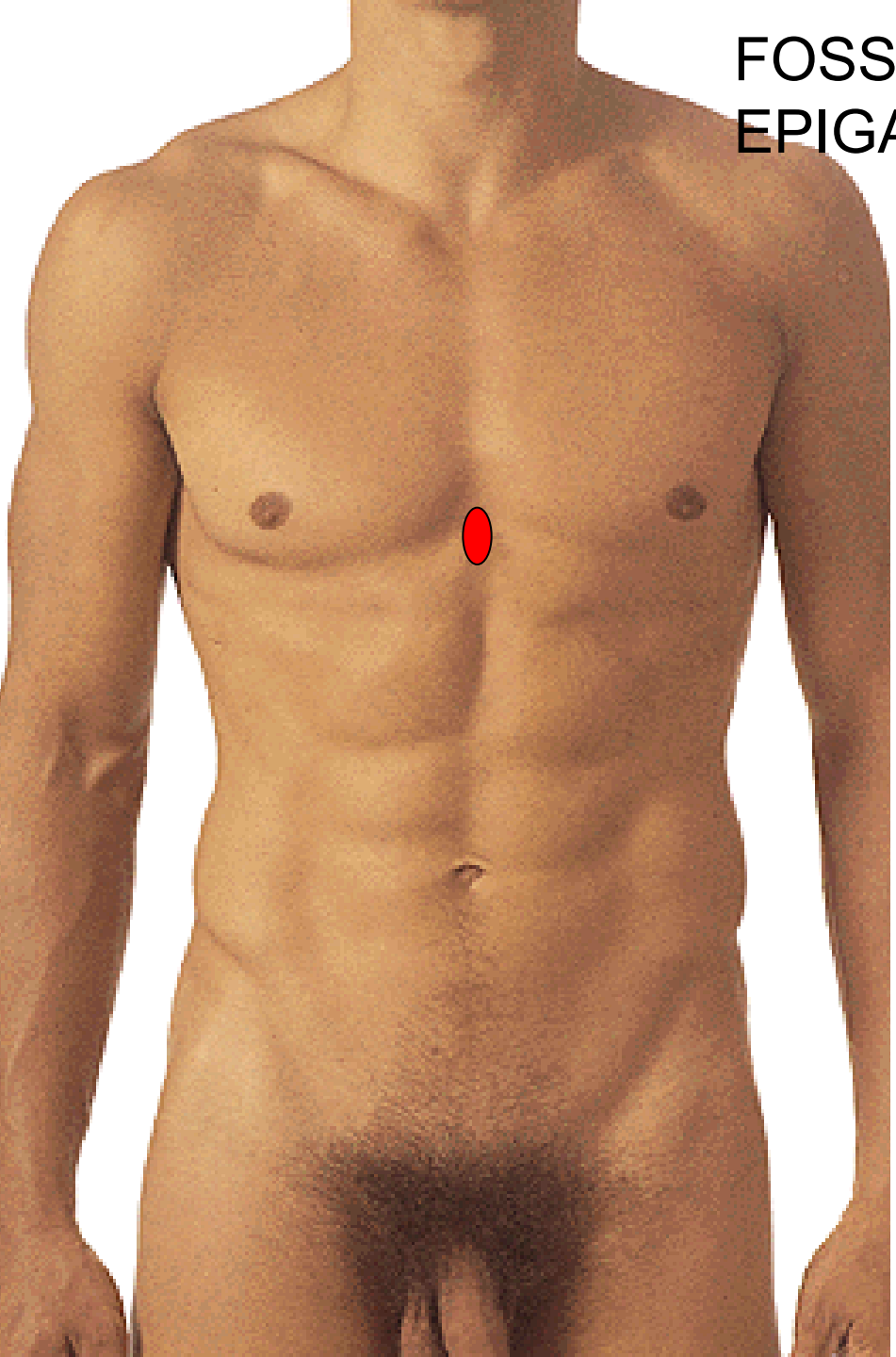TUBERCULUM
COSTOABDOMINALE



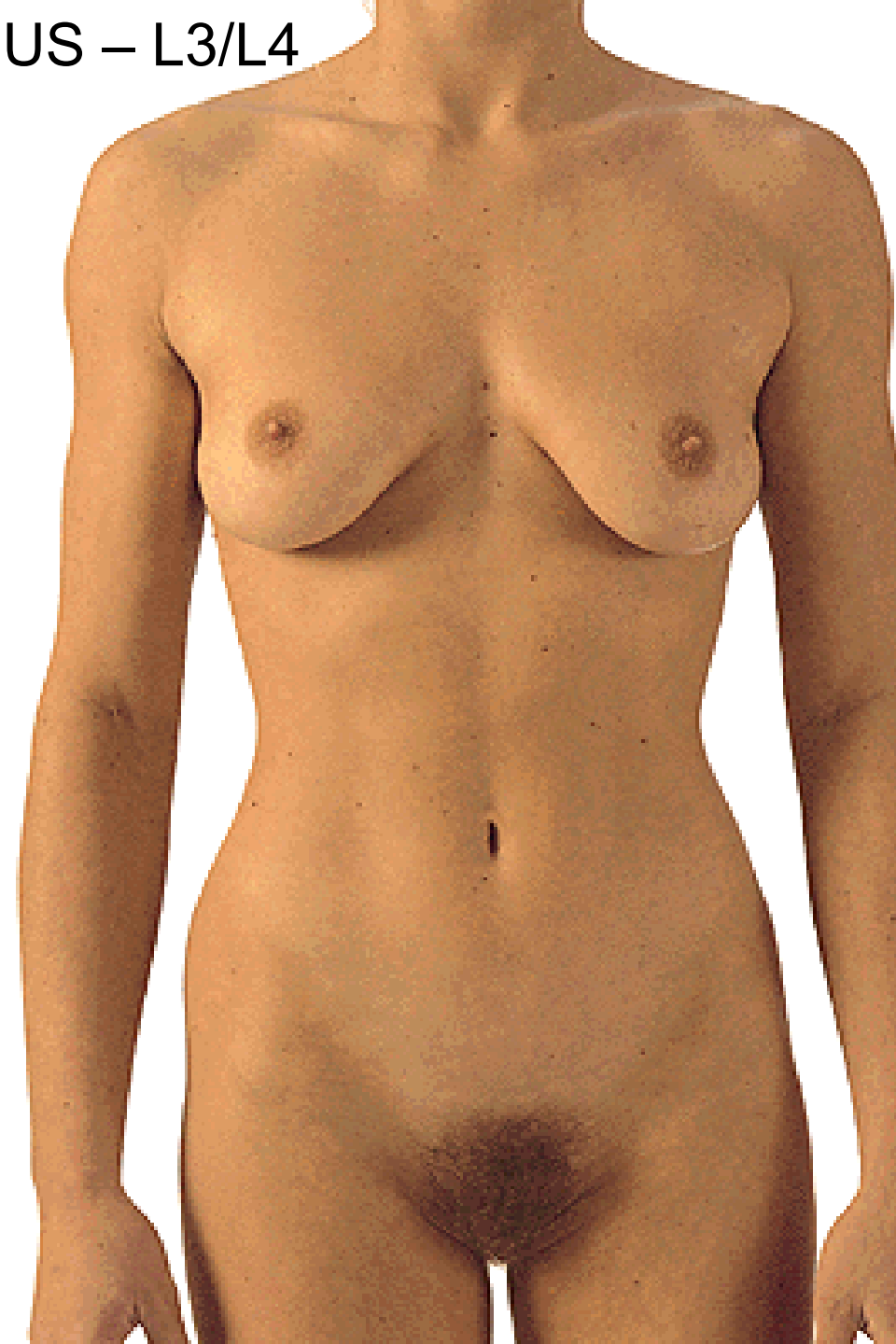ANGULUS INFRASTERNALIS



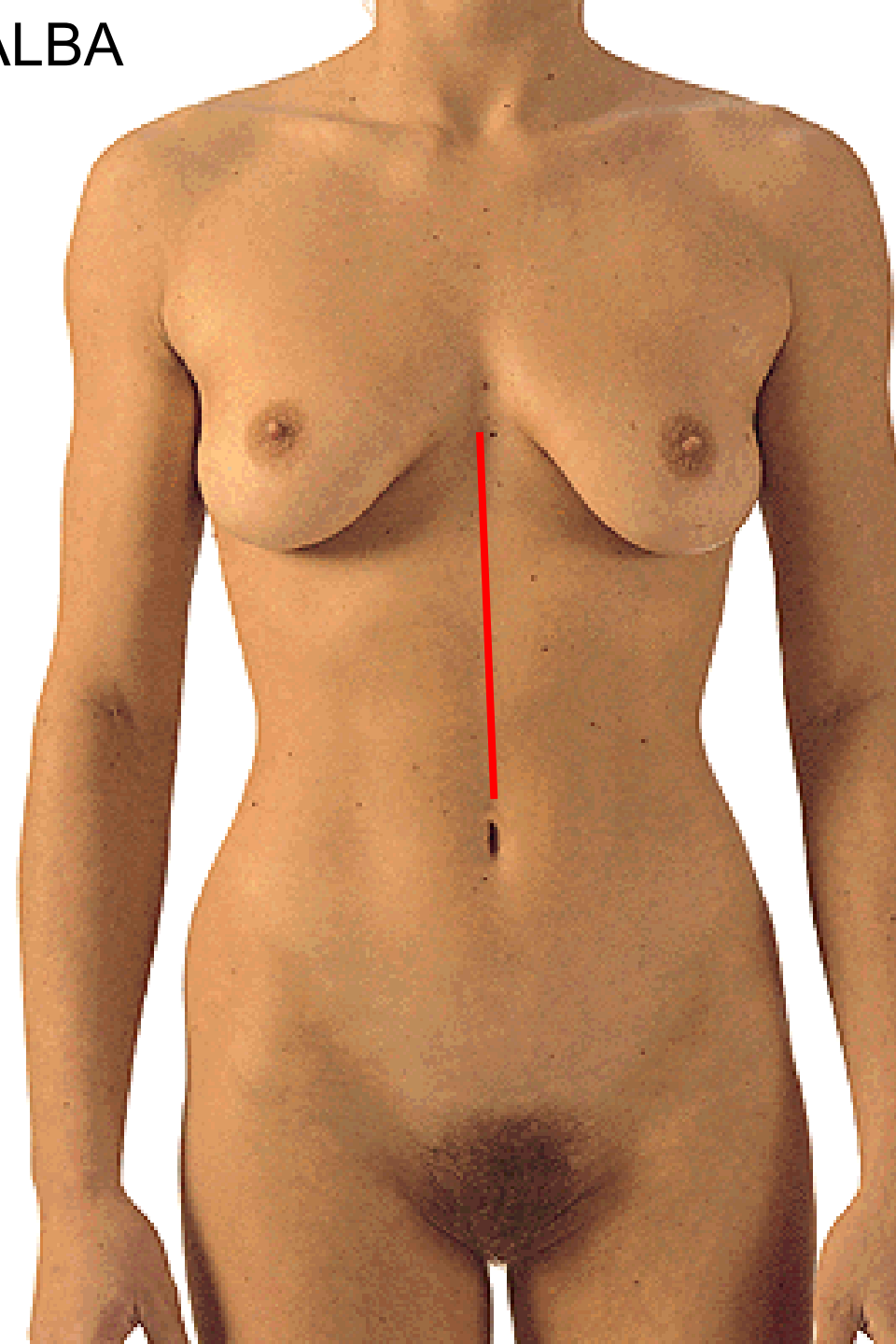
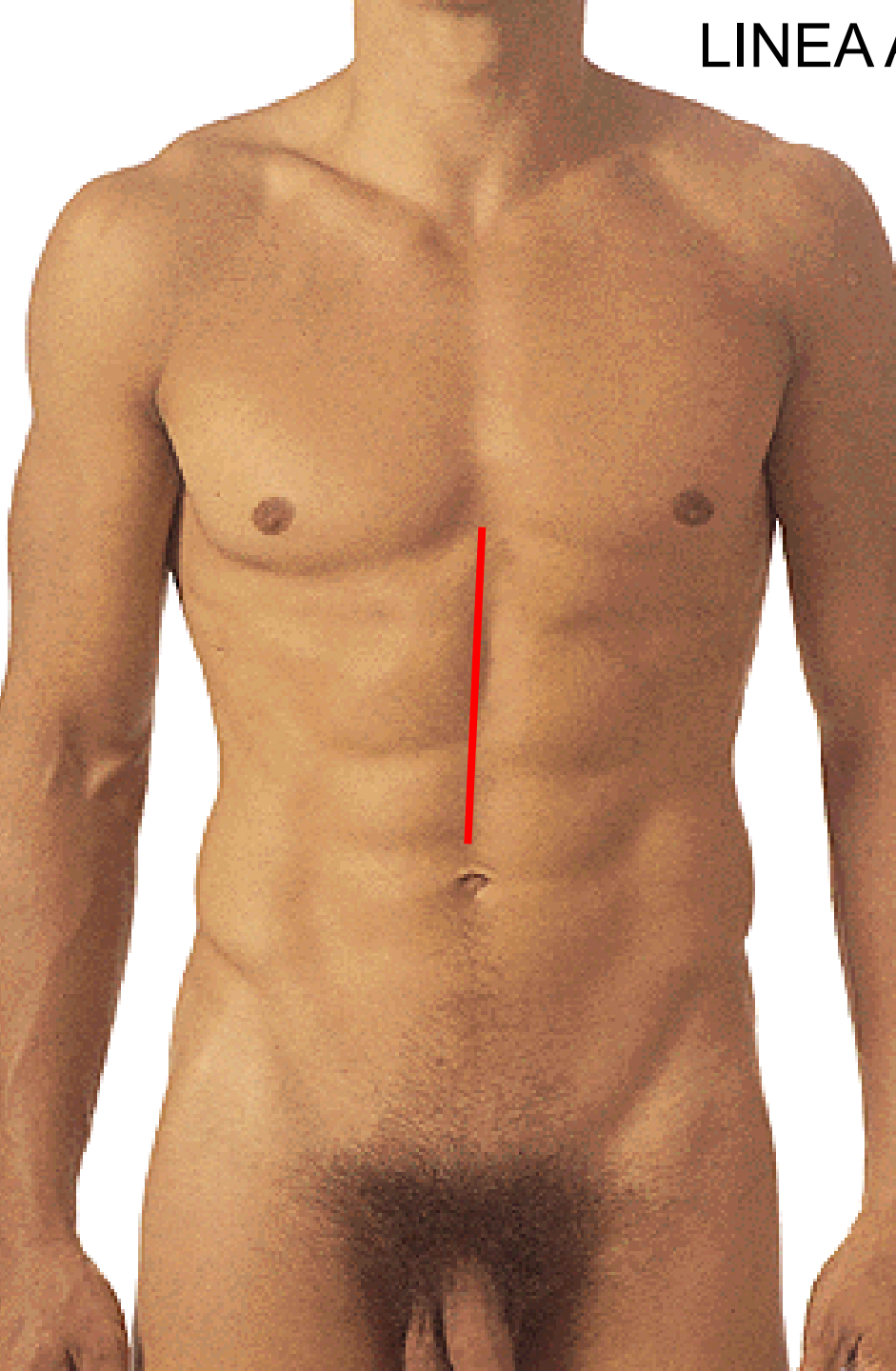
FOSSA
EPIGASTRICA



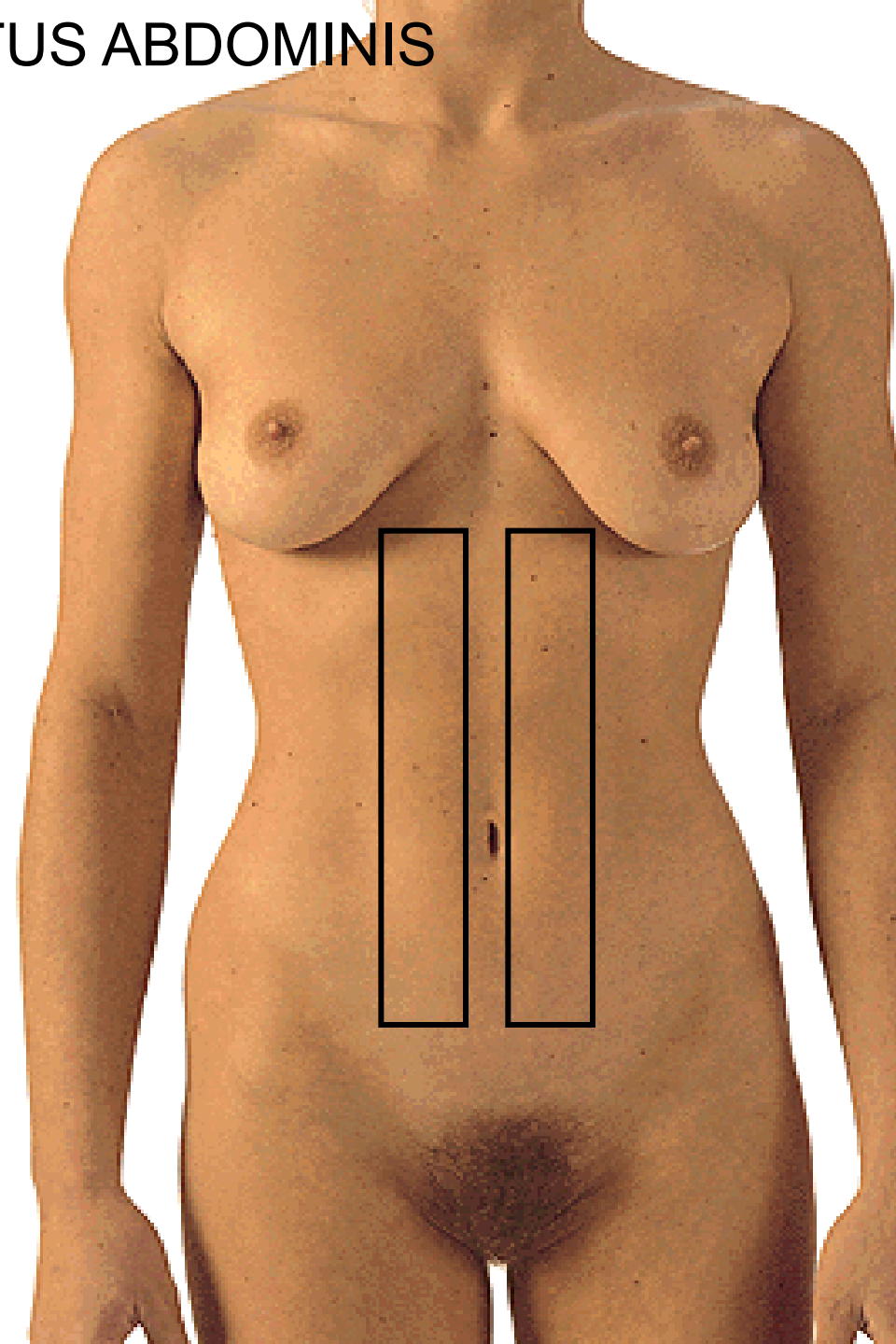
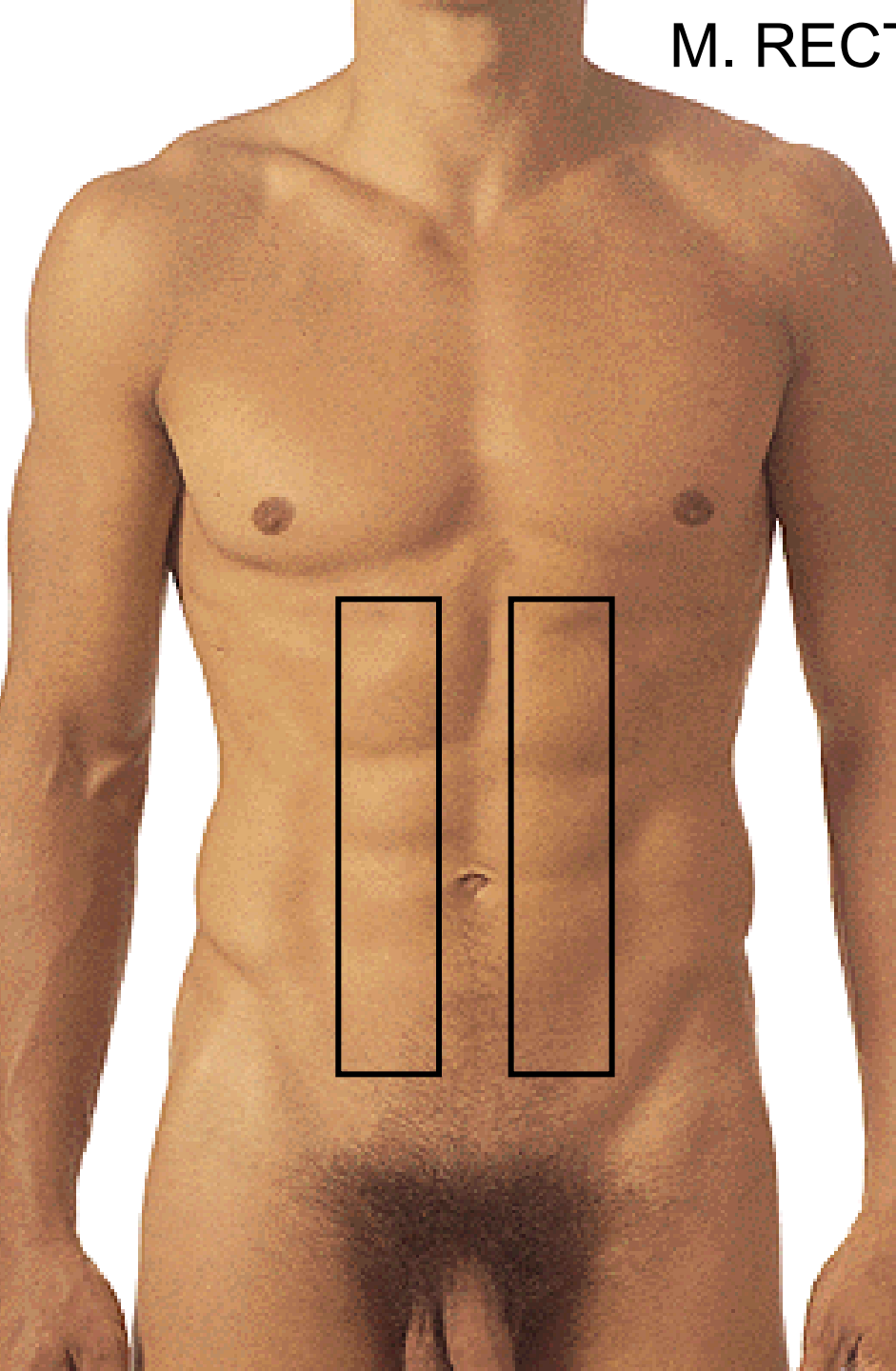
UMBILICUS – L3/L4



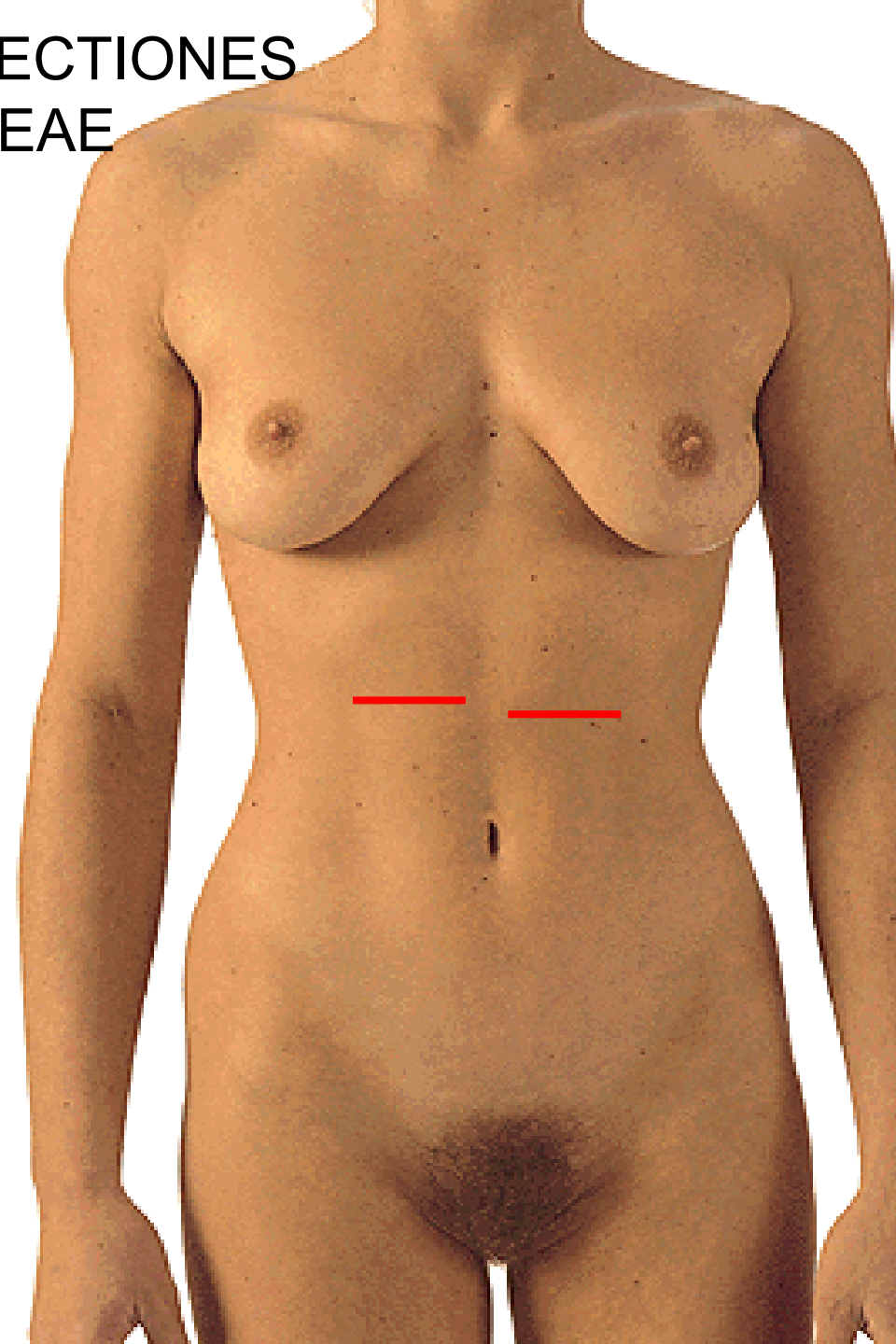
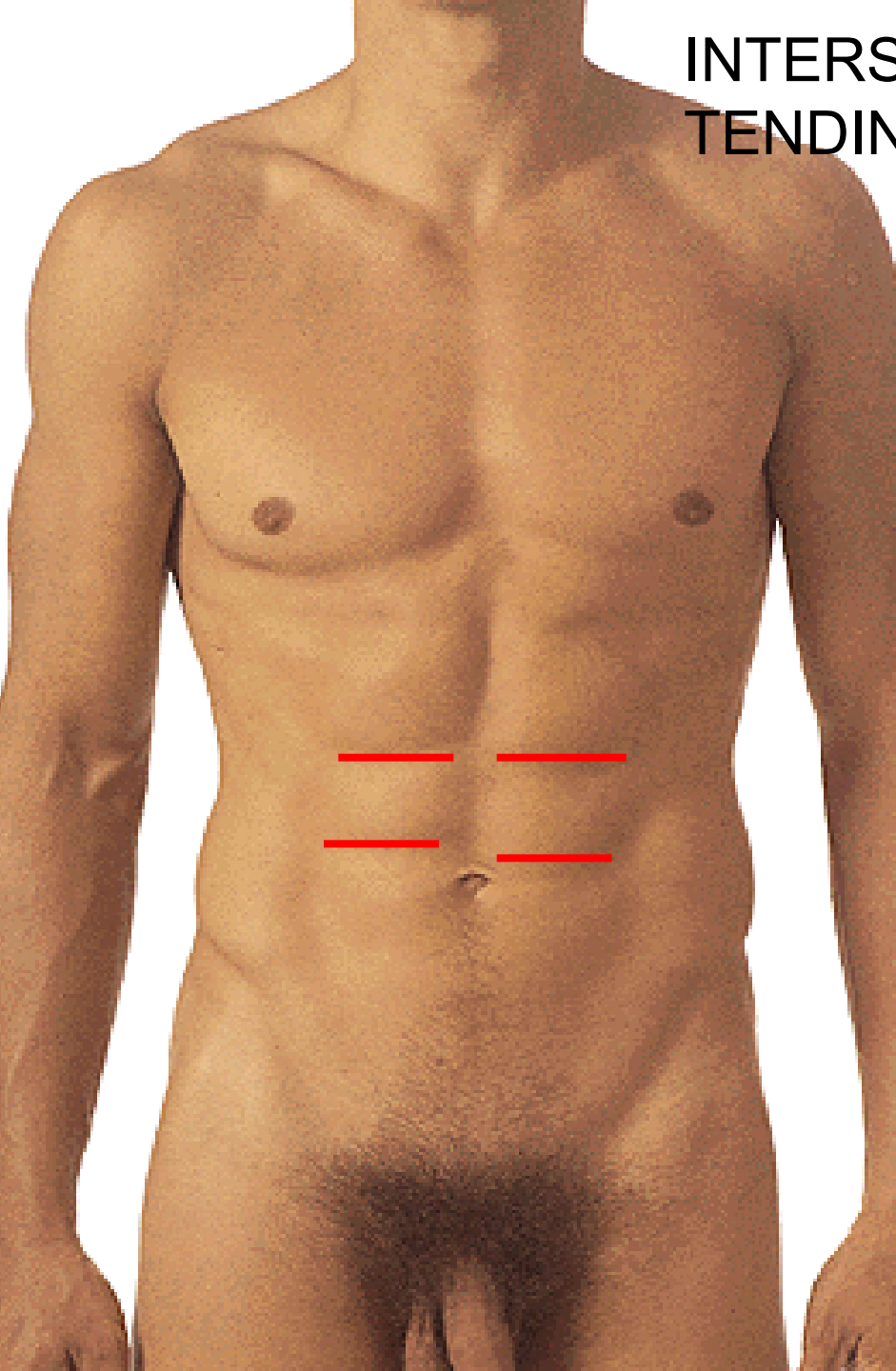
LINEA ALBA



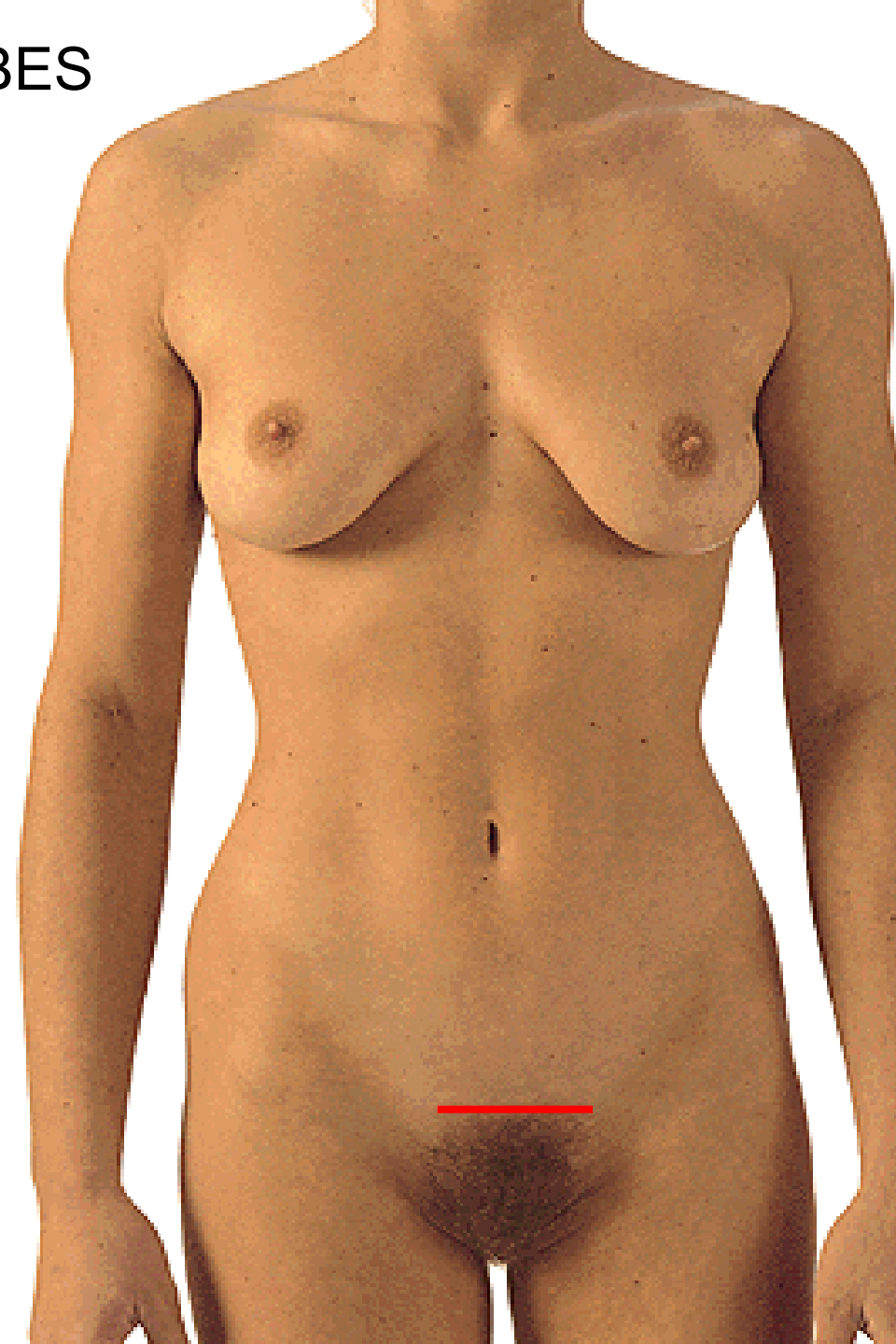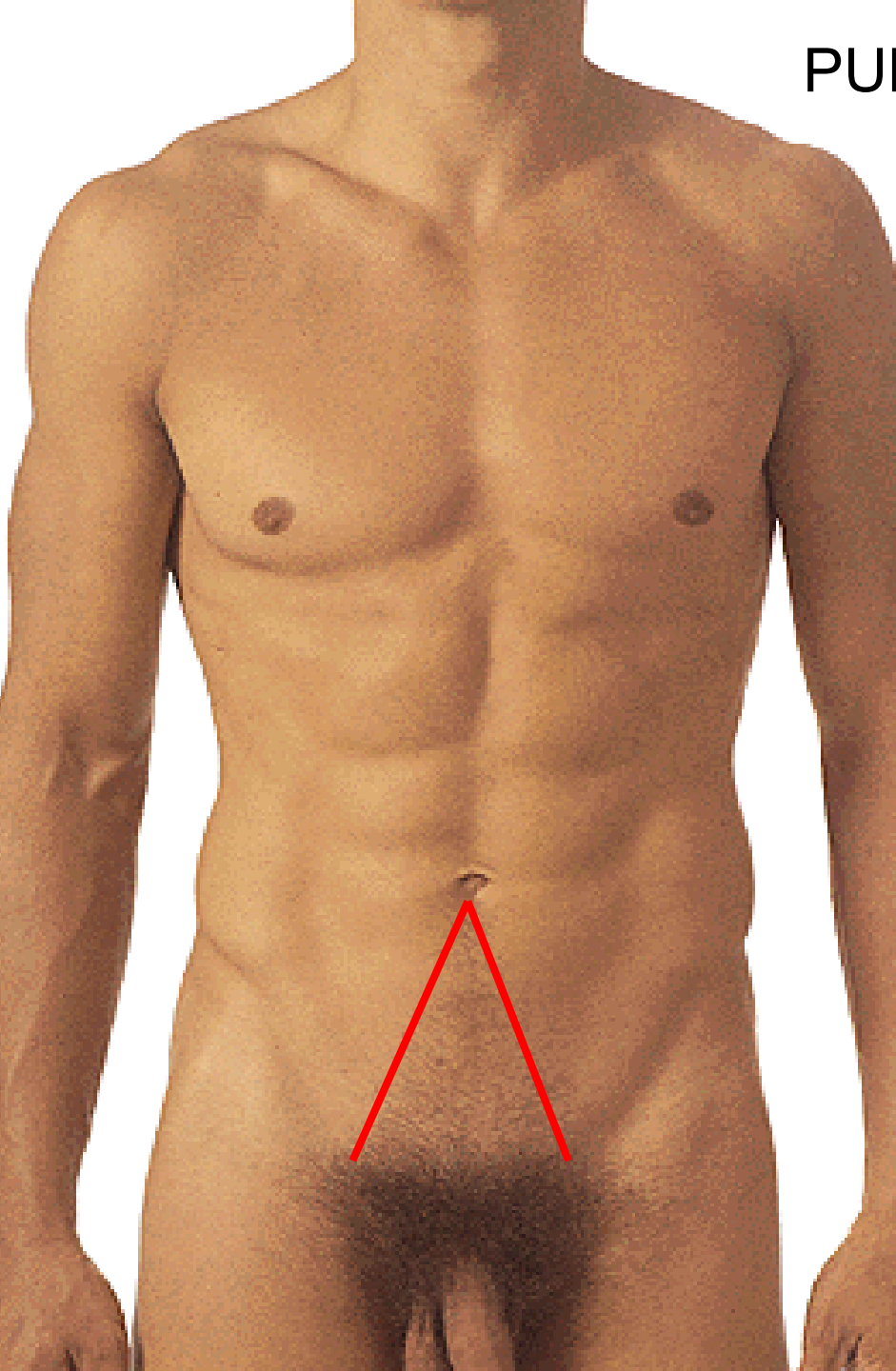
M. RECTUS ABDOMINIS



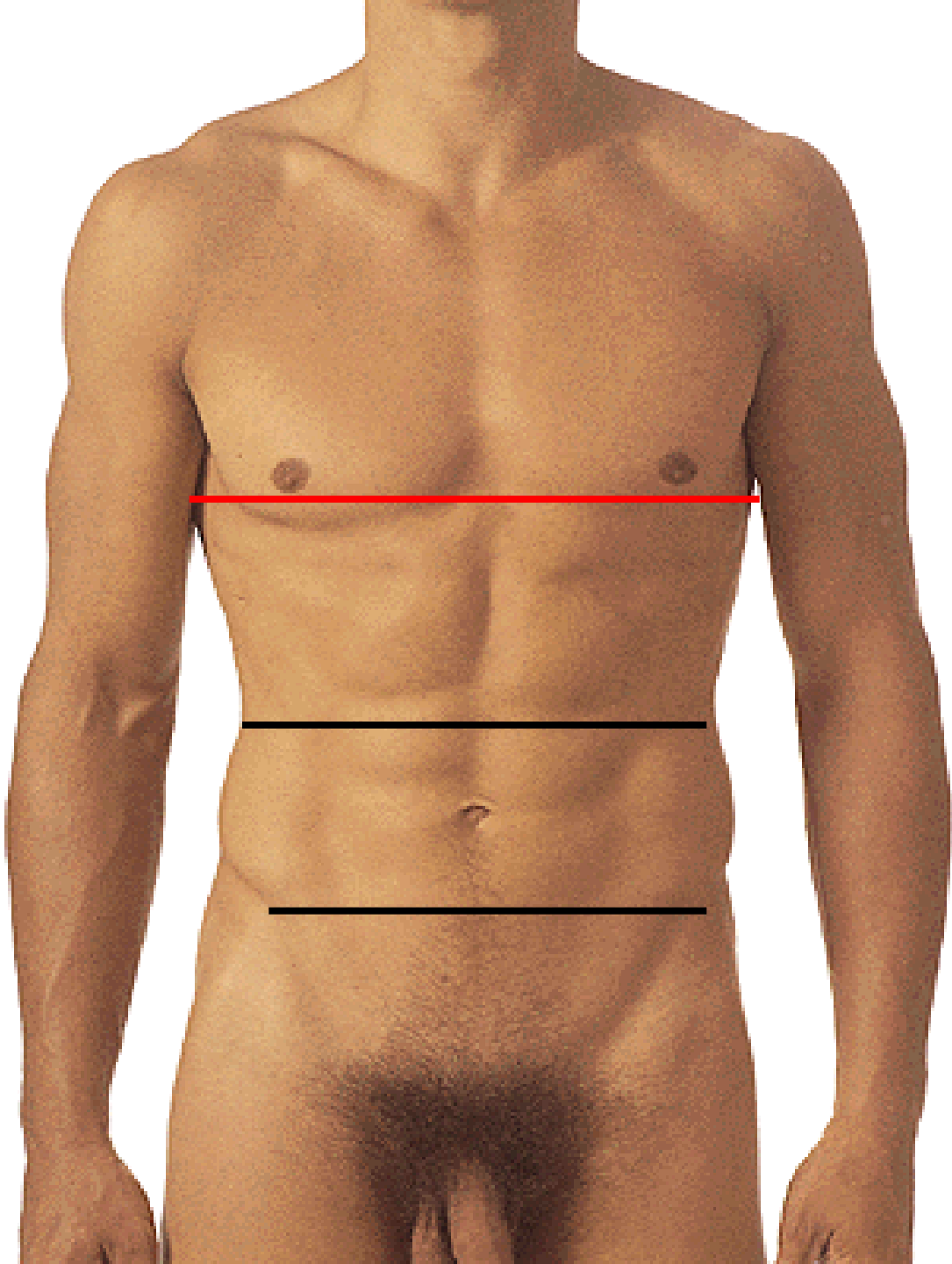
INTERSECTIONS TENDINEAE



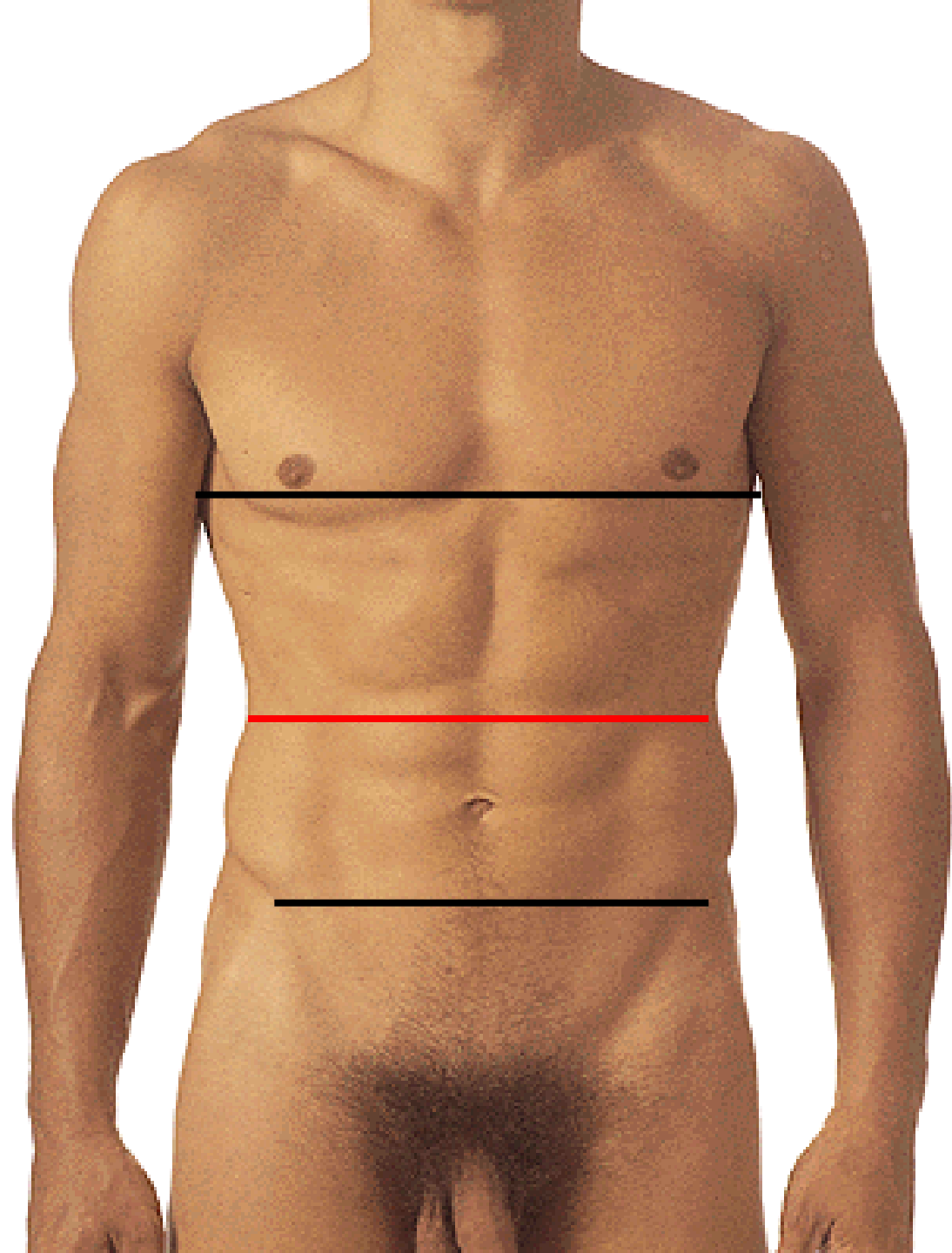
PUBES



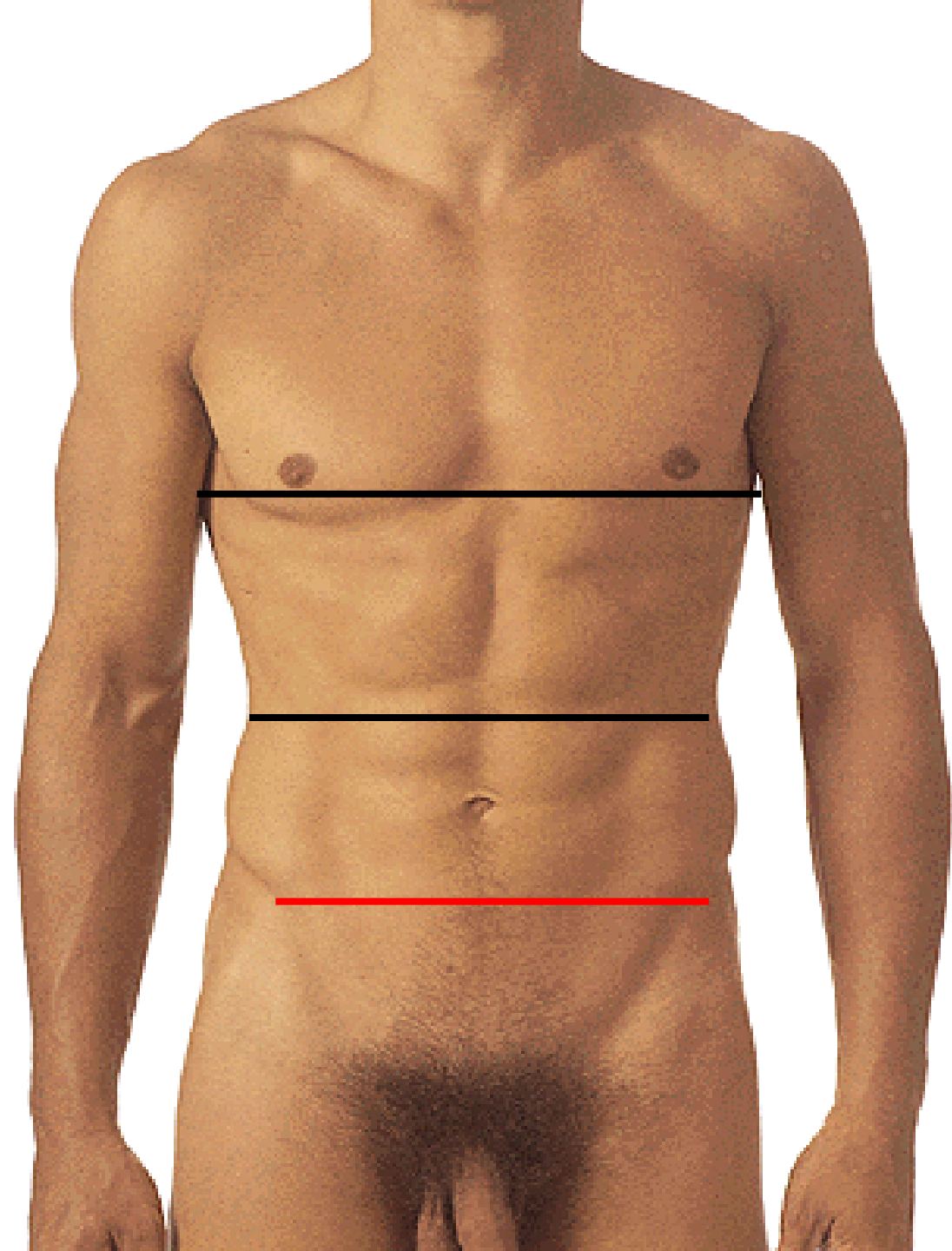
LINEA XIPHISTERNALIS



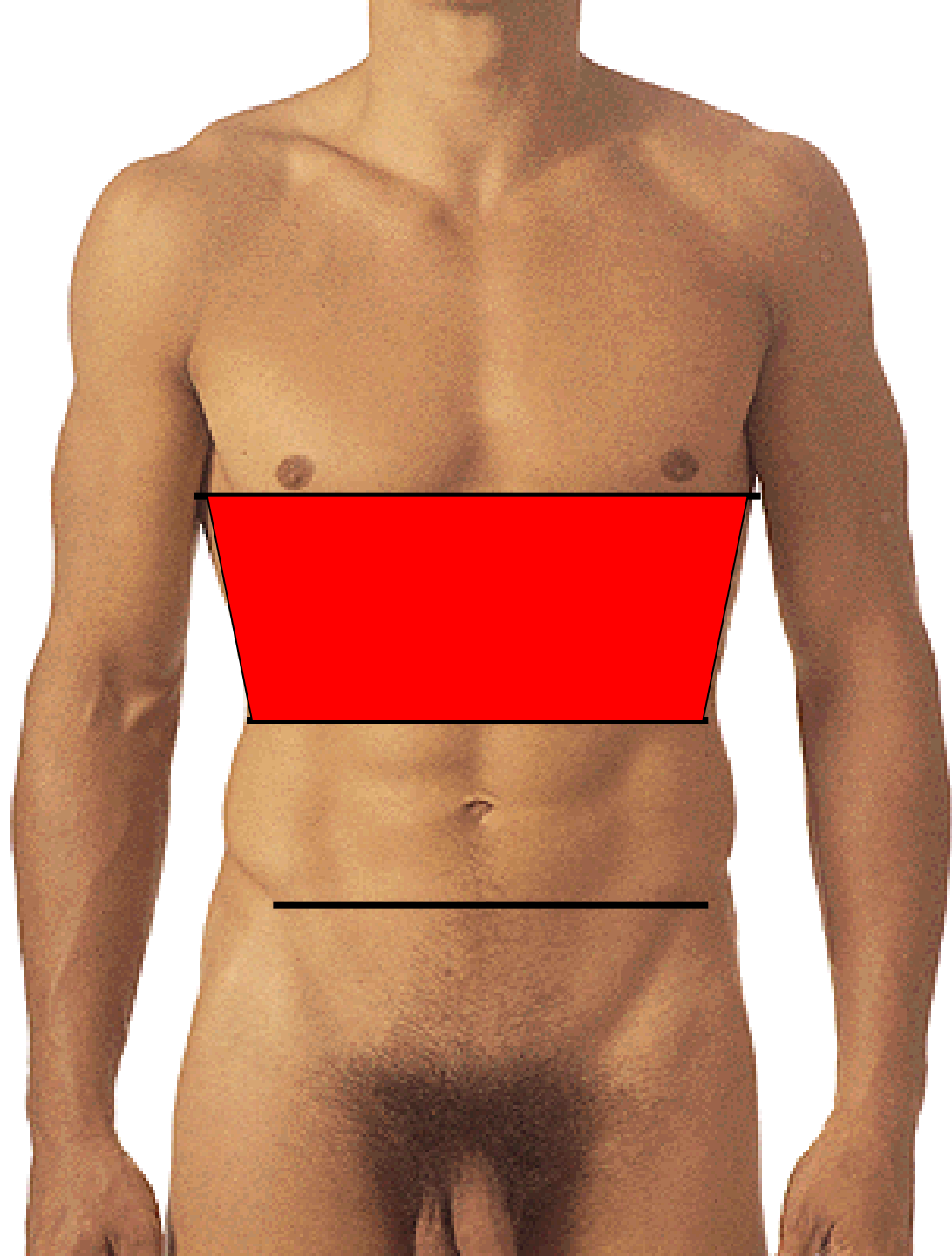
LINEA SUBCOSTALIS



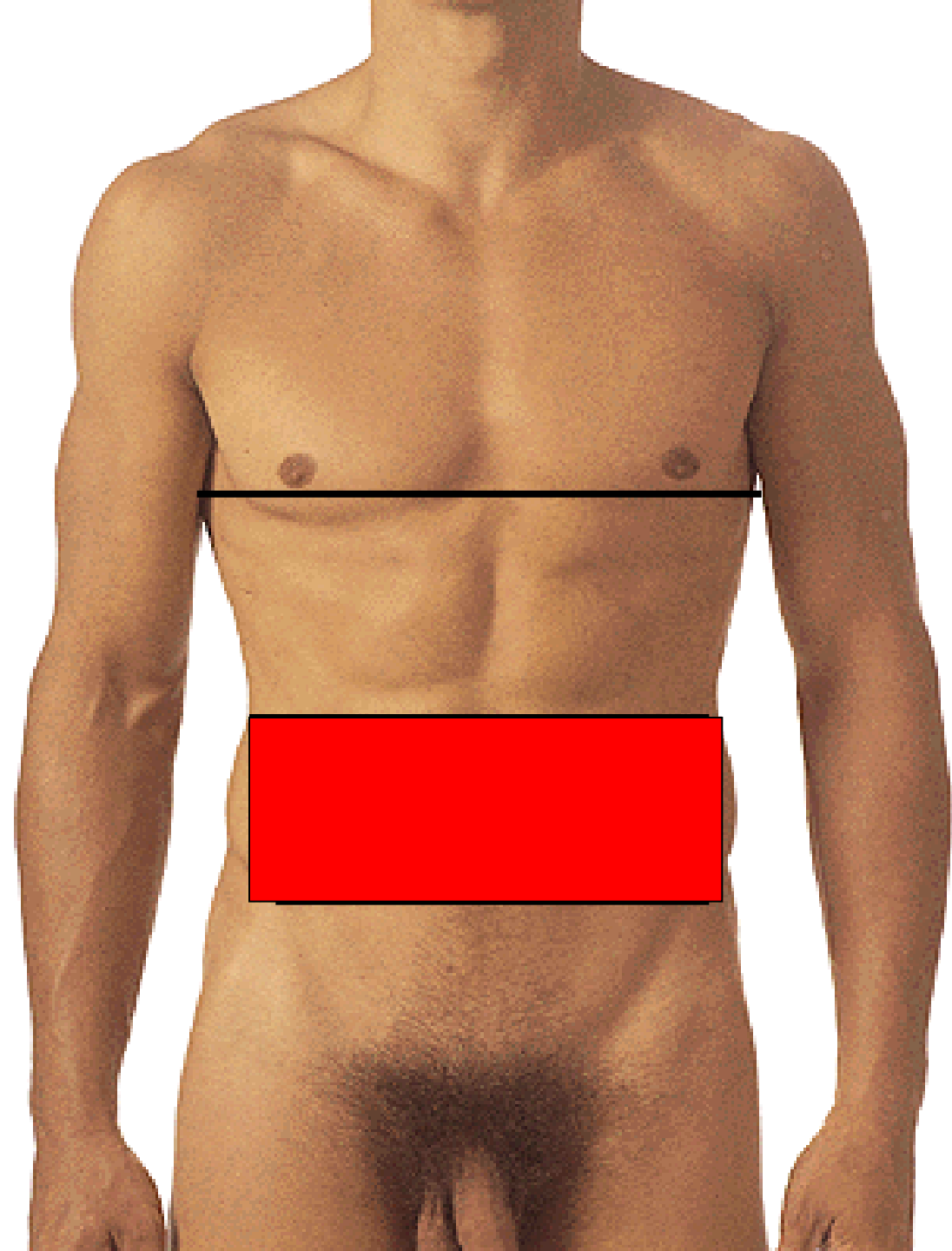
LINEA INTERSPINALIS



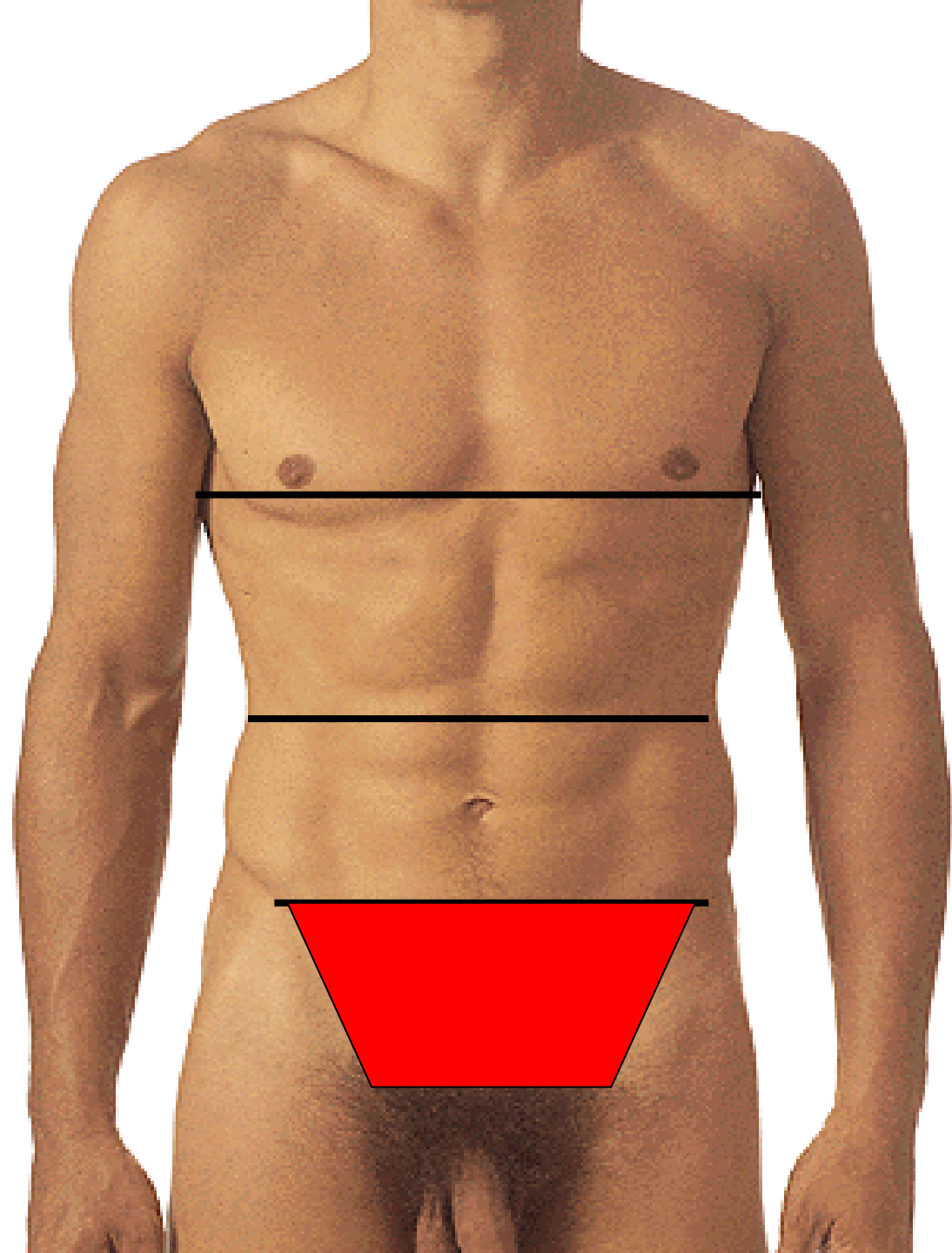
EPIGASTRIUM

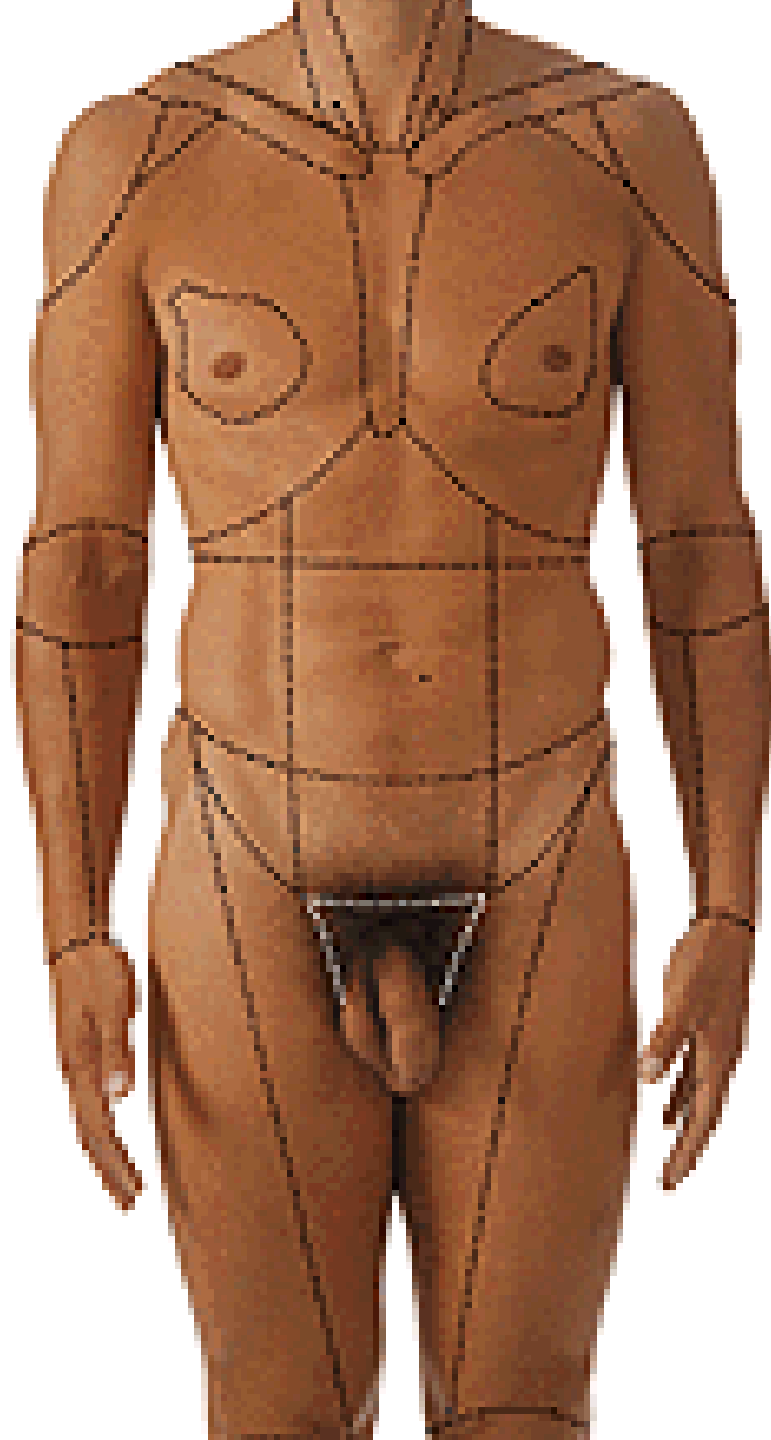


MESOGASTRIUM

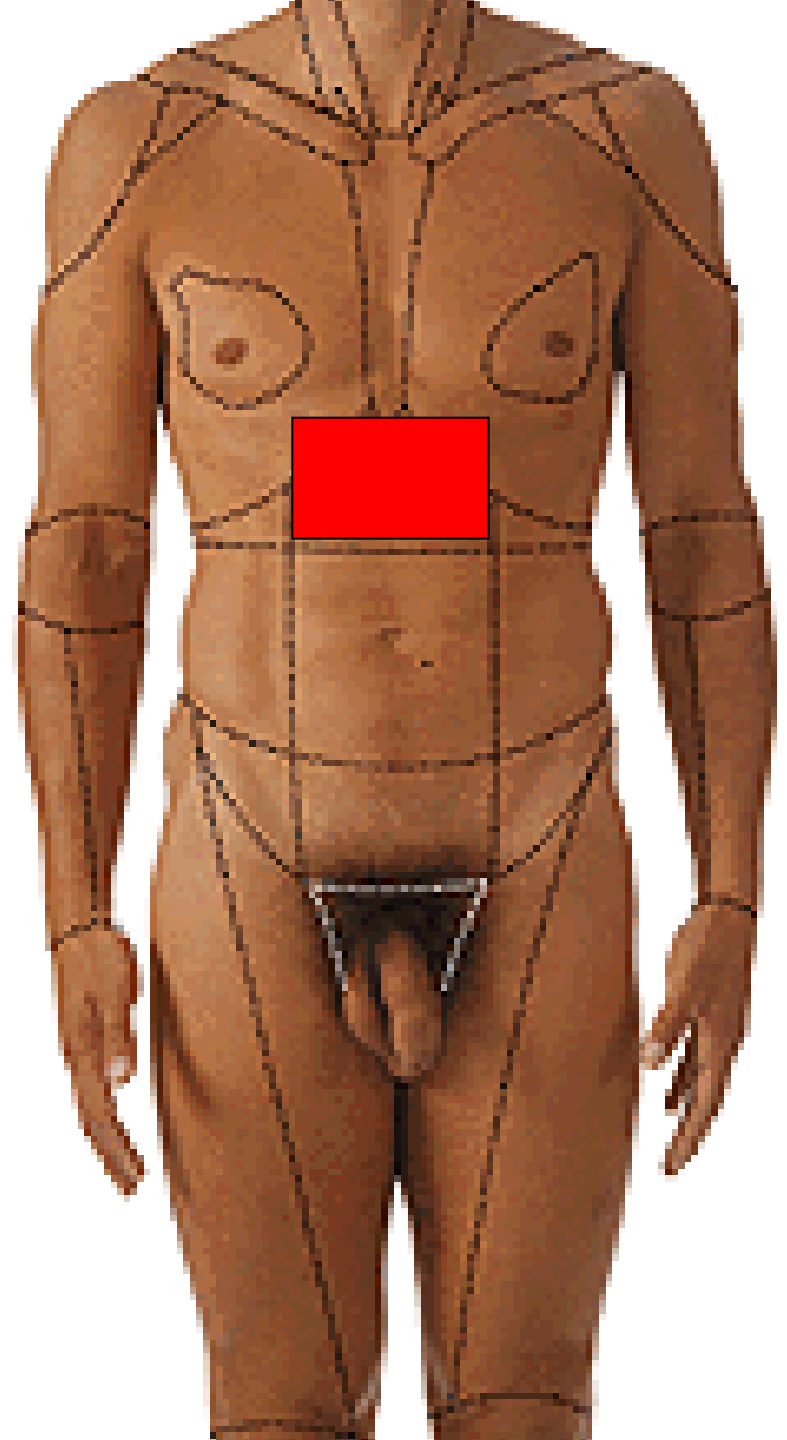


HYPOGASTRIUM

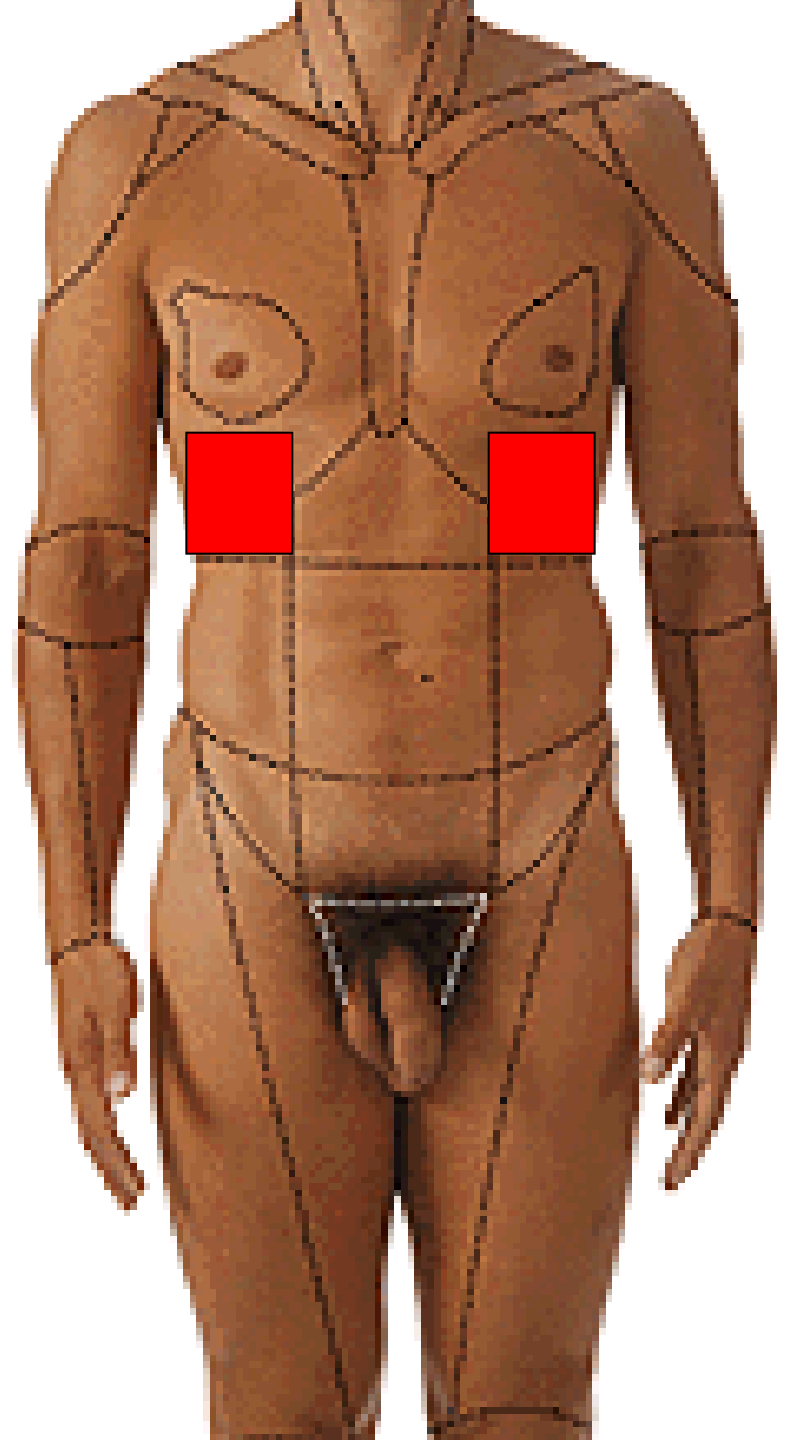




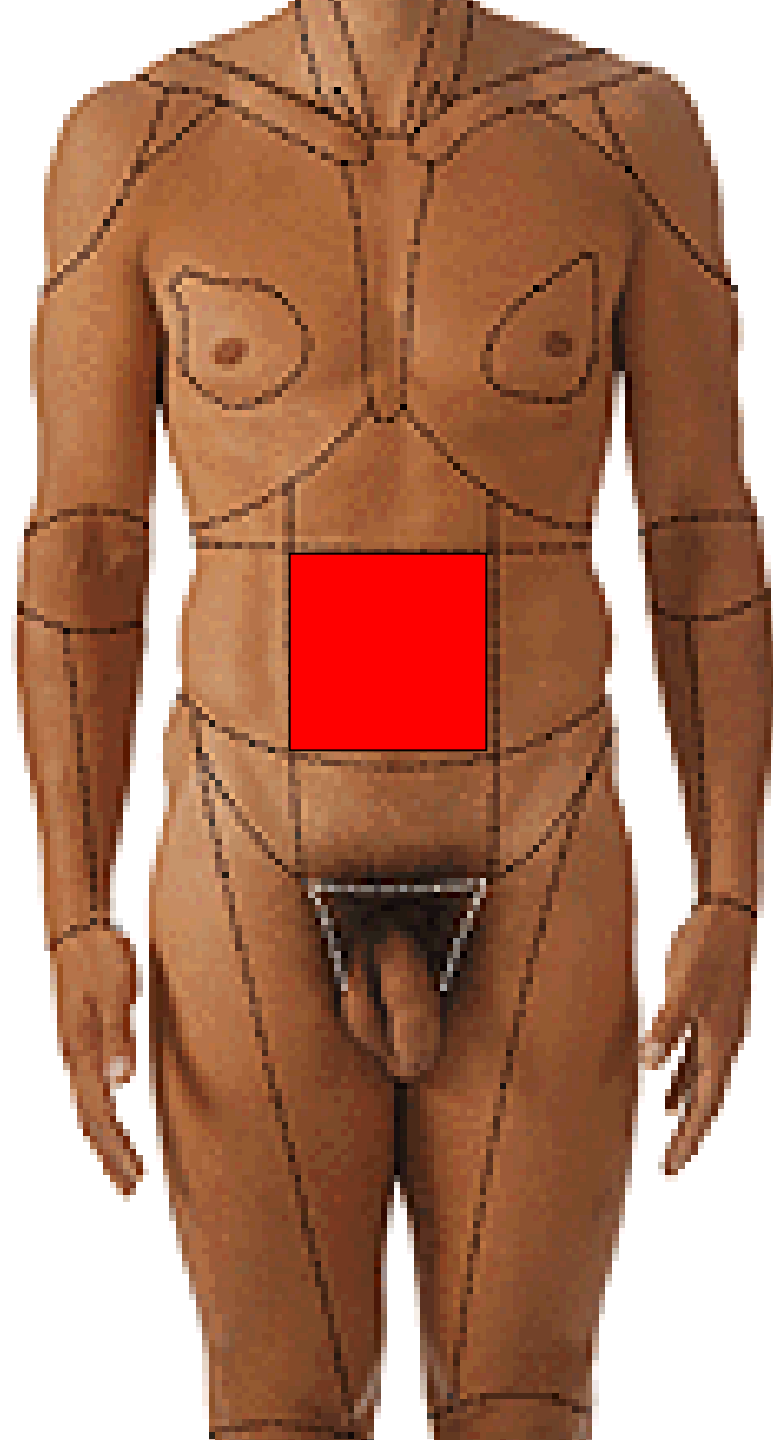
REGIO EPIGASTRICA



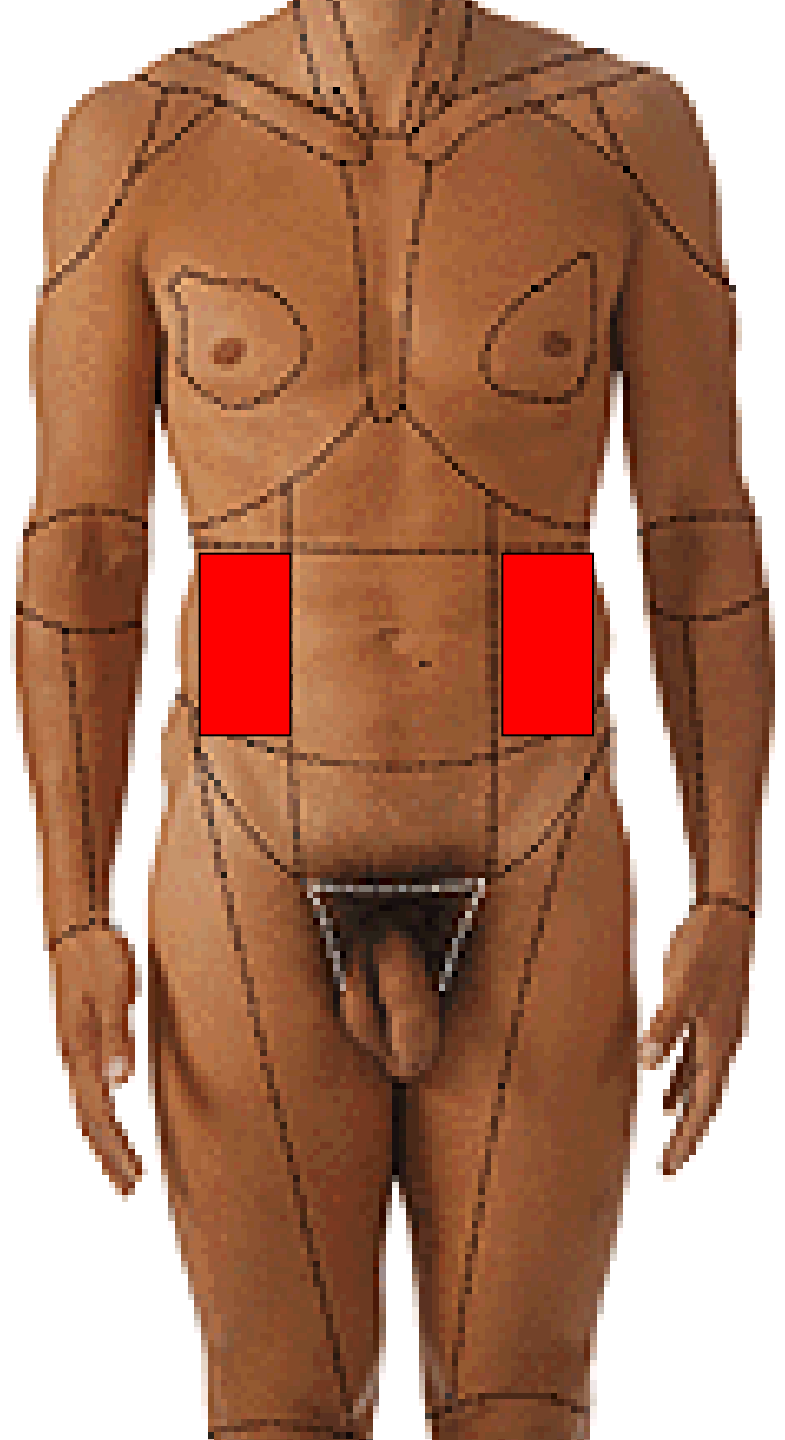
**REGIO HYPOCHONDRIACA
DEXTRA ET SINISTRA**



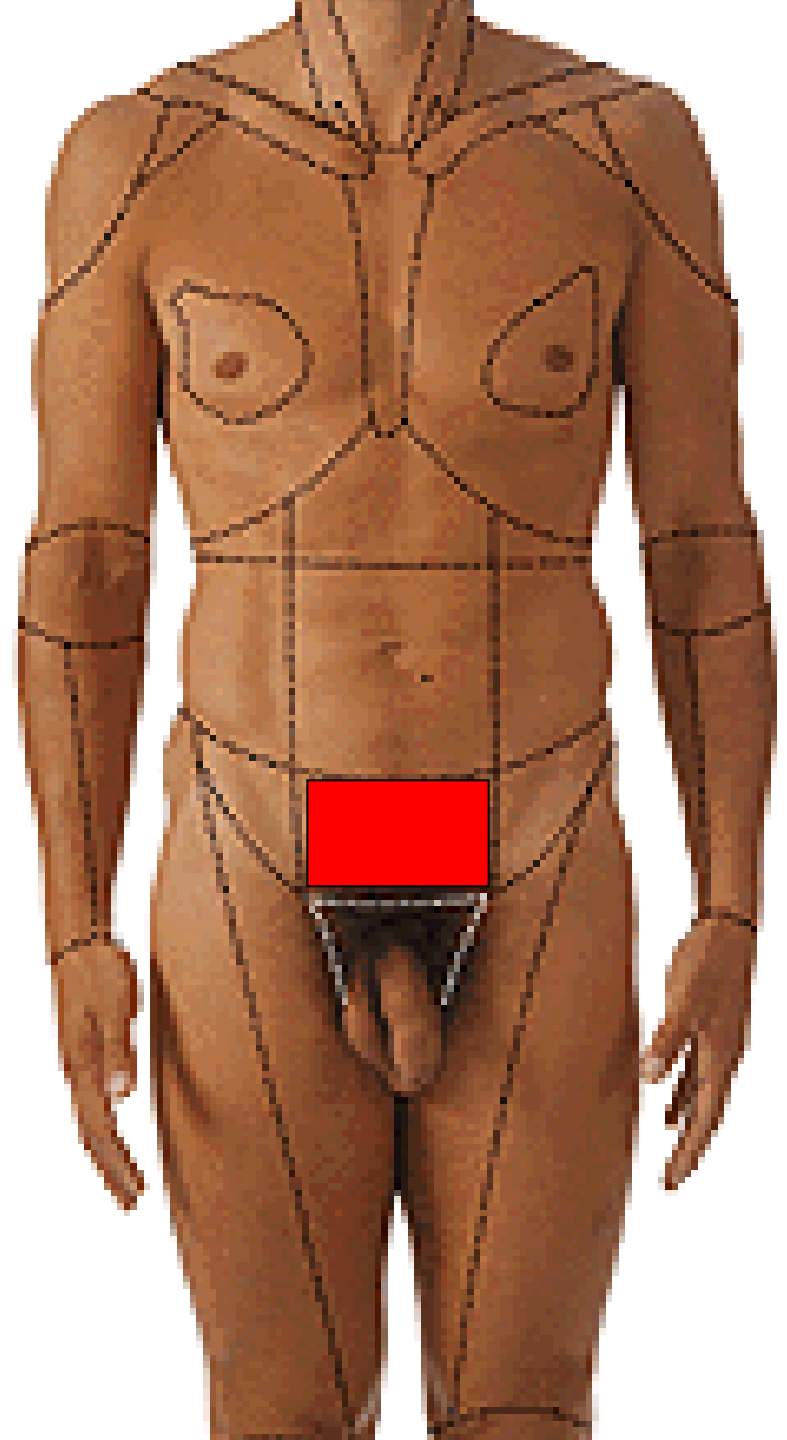
REGIO UMBILICALIS



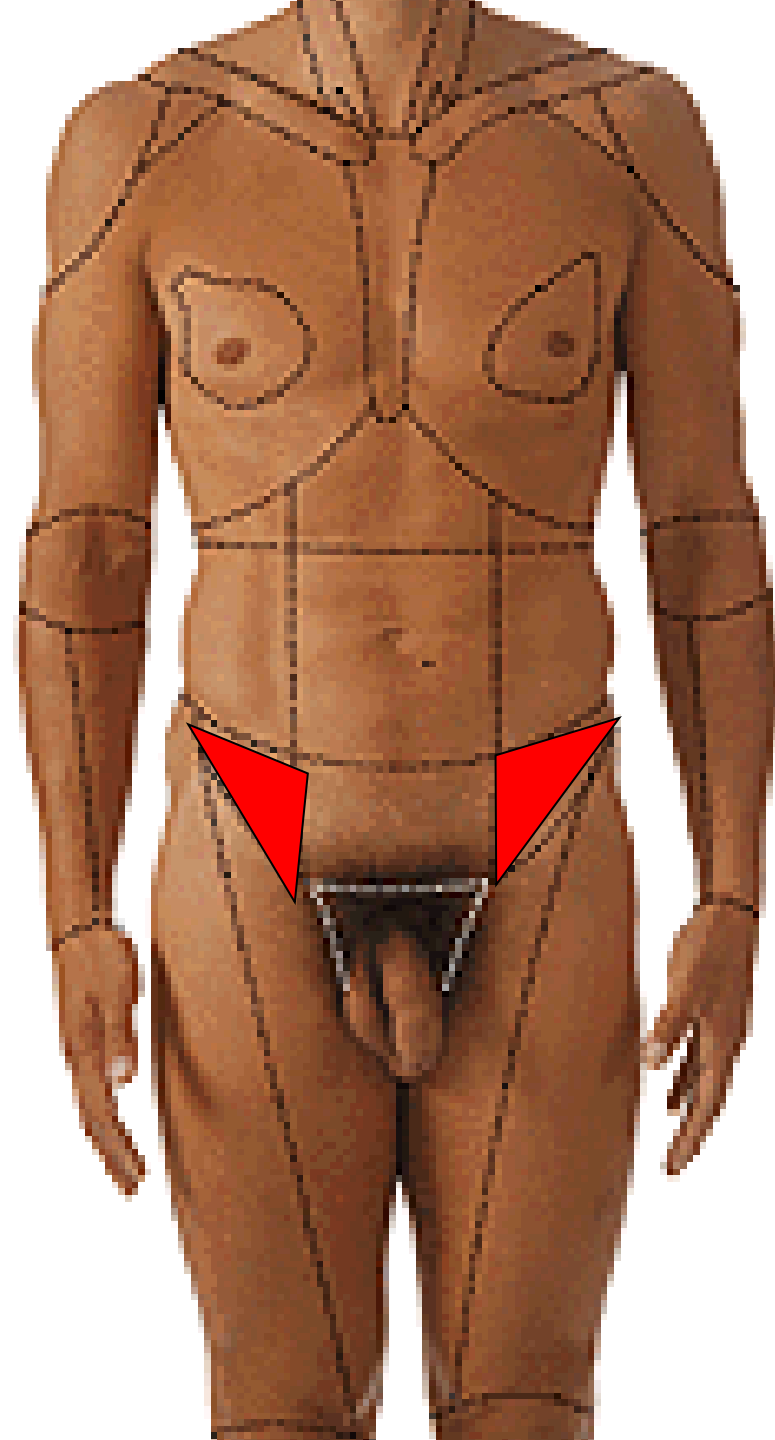
**REGIO LATERALIS
DEXTRA ET SINISTRA**



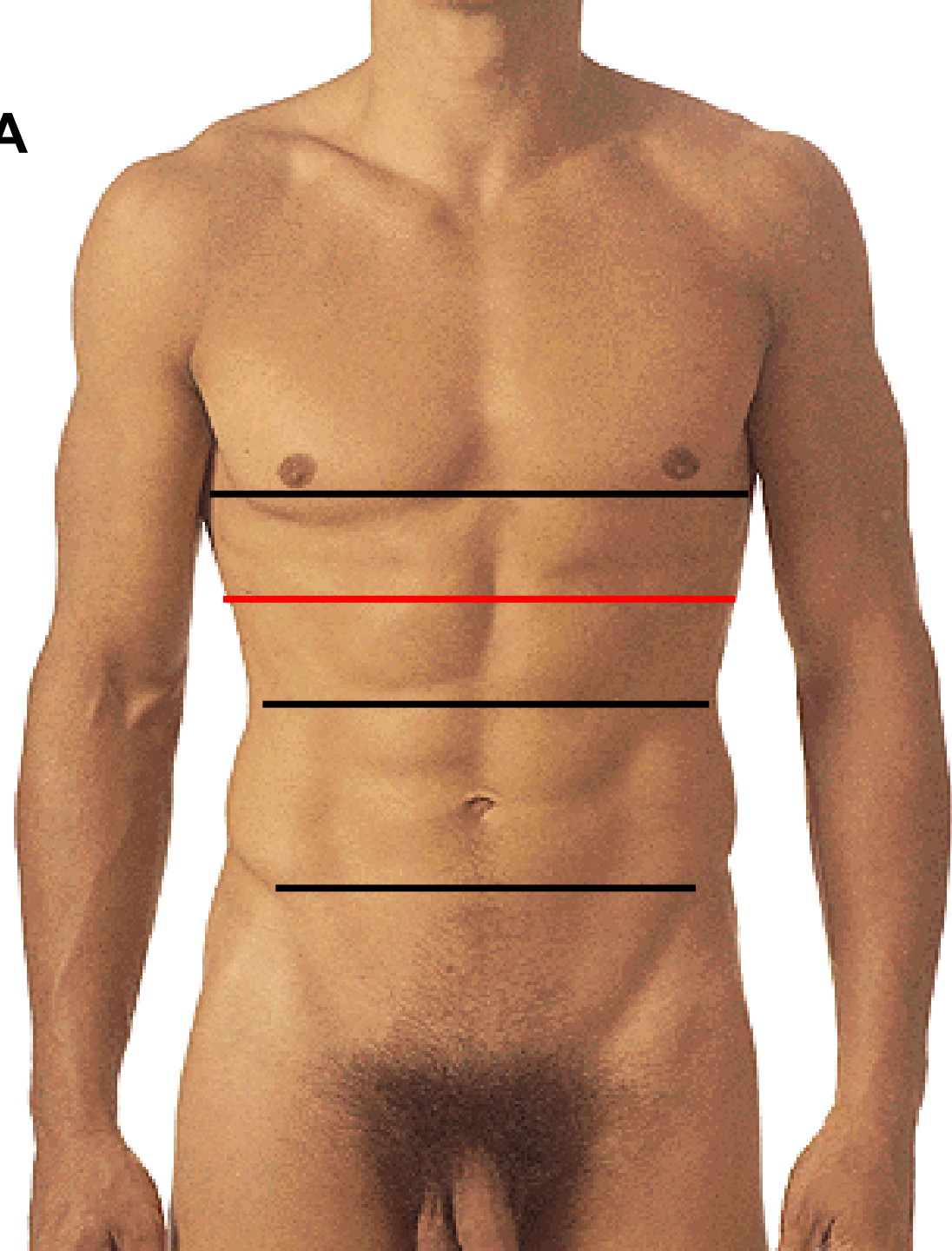
REGIO PUBICA



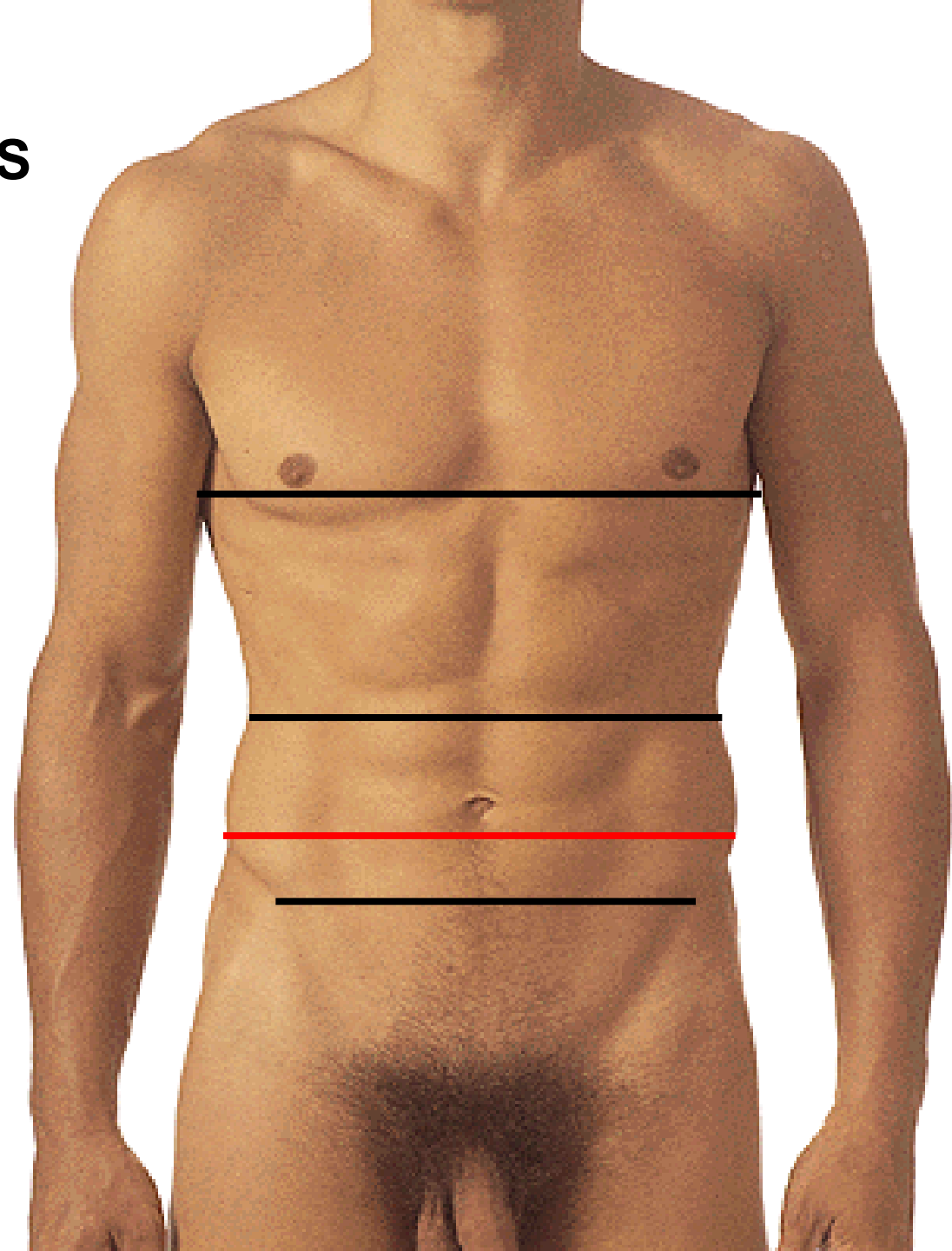
**REGIO INGUINALIS
DEXTRA ET SINISTRA**



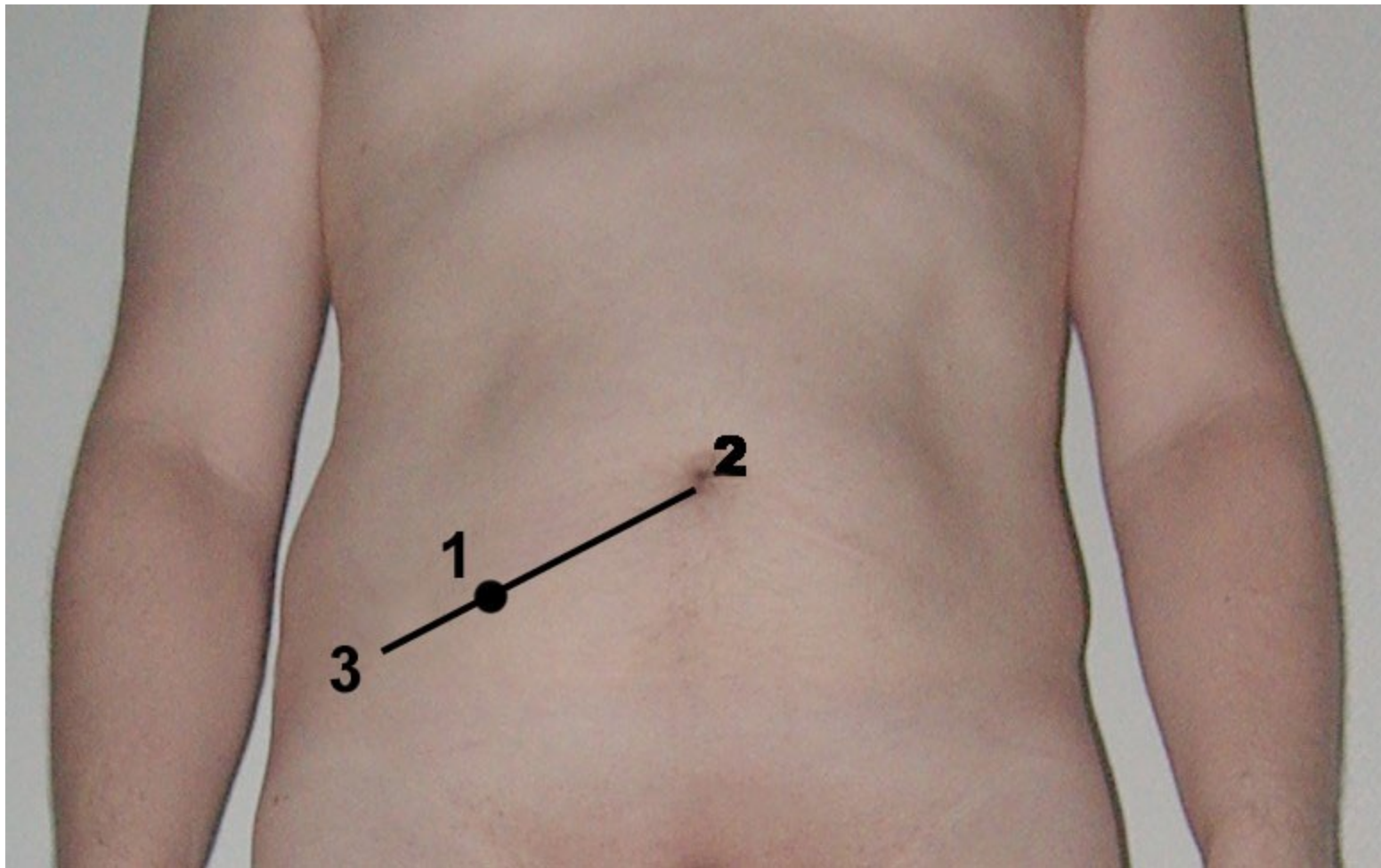
LINEA TRANSPYLORICA



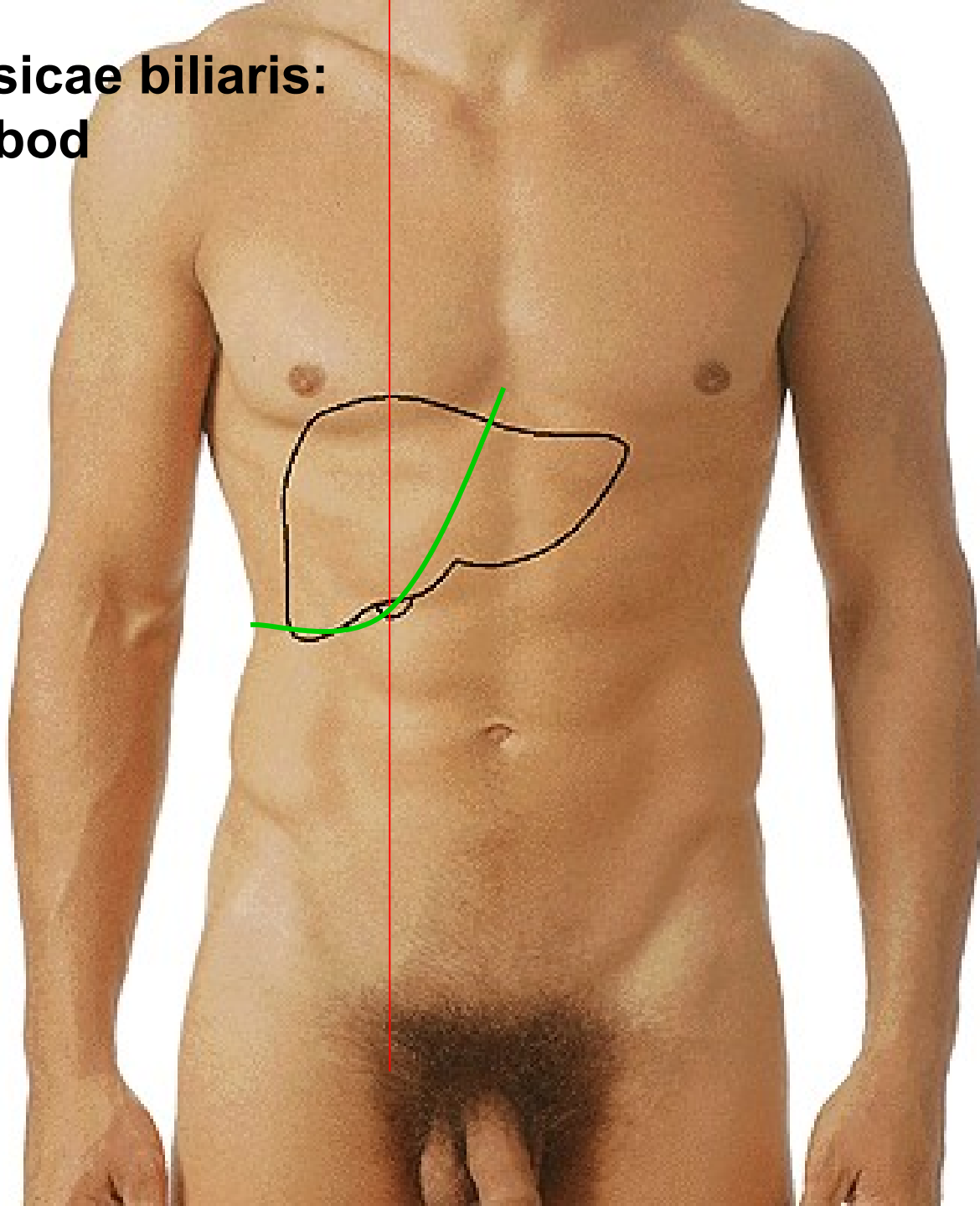
LINEA INTERCRISTALIS



Appendix vermiformis: Mac Burneyův bod (Monroova čára)



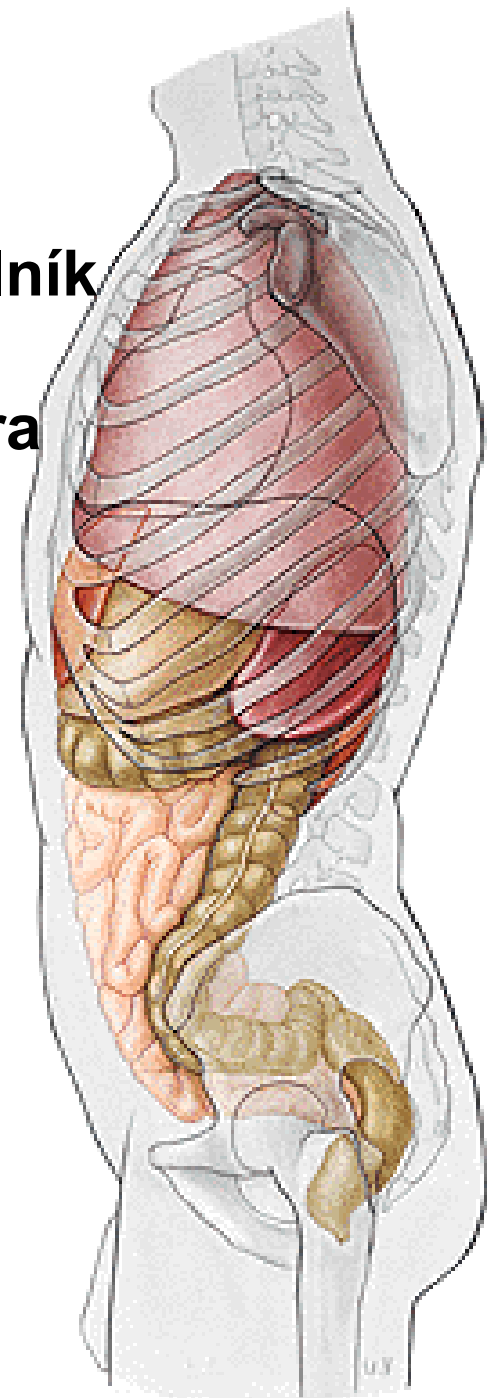
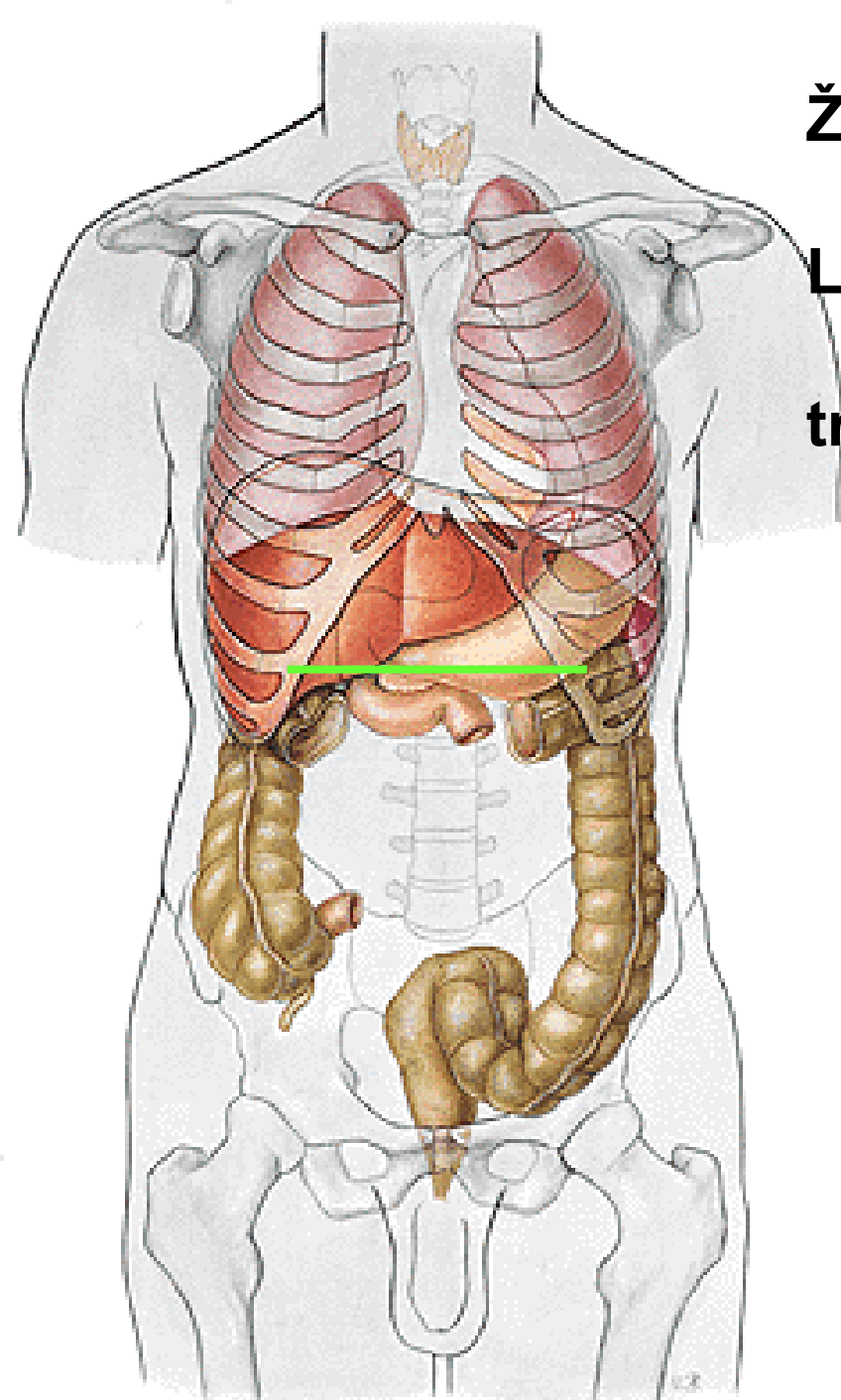
**Fundus vesicae biliaris:
Murphyův bod**



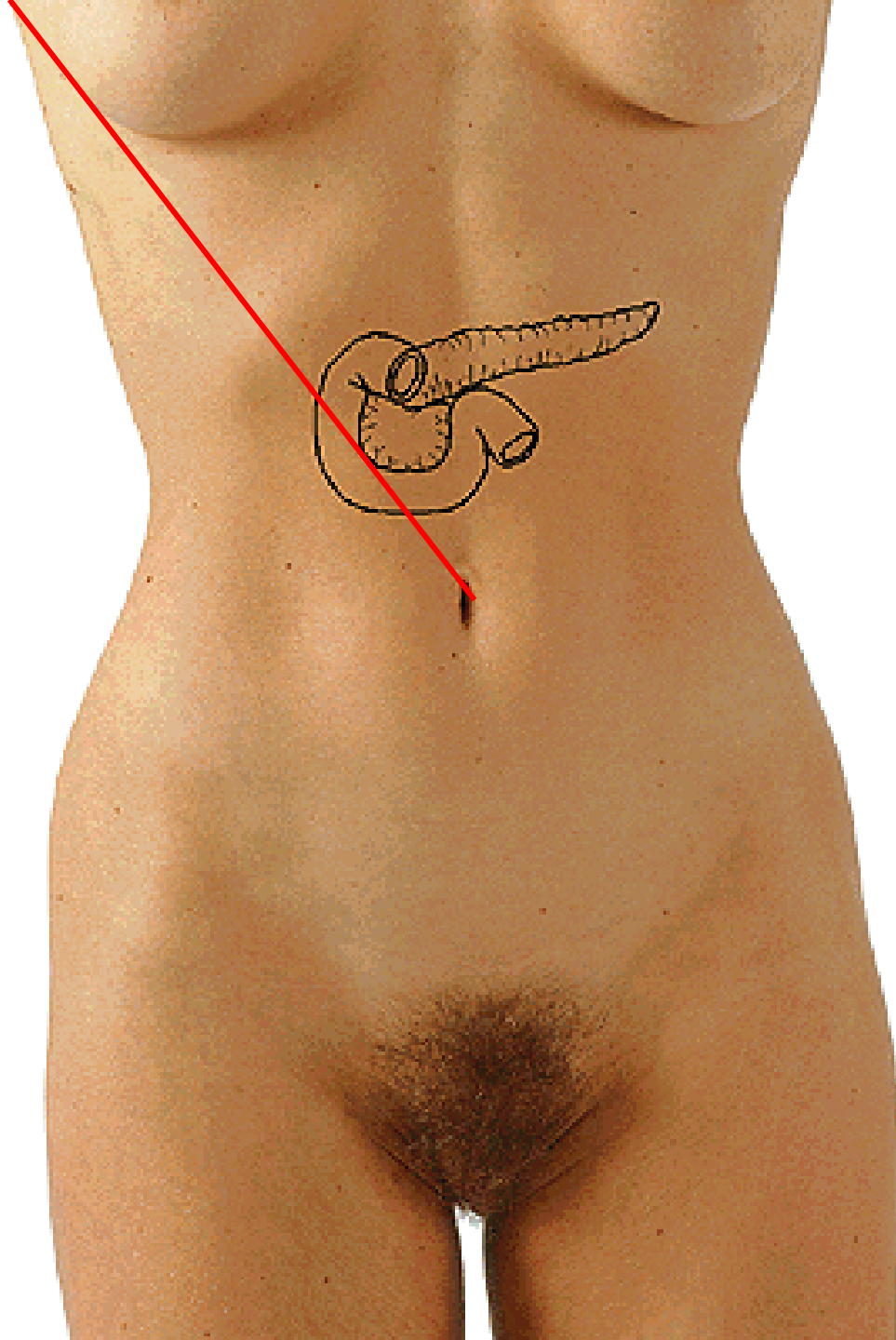
Žaludek:

Labbeův trojúhelník

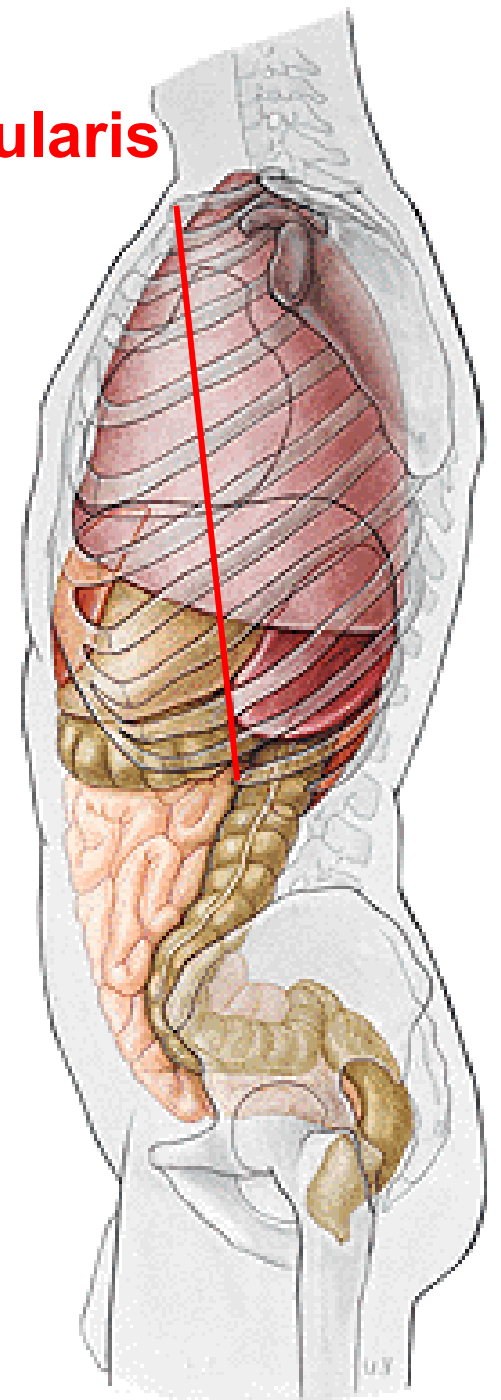
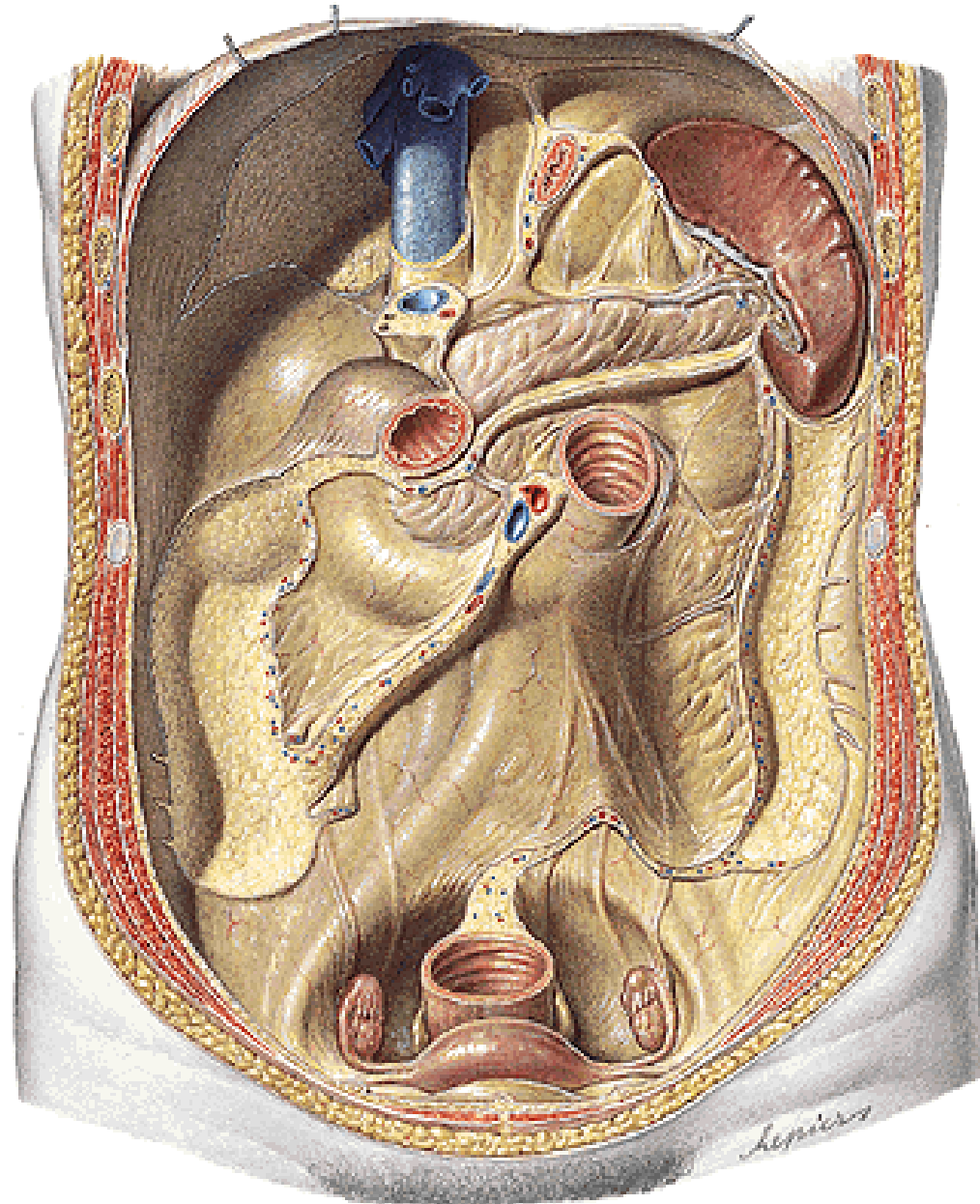
transpylorická čára



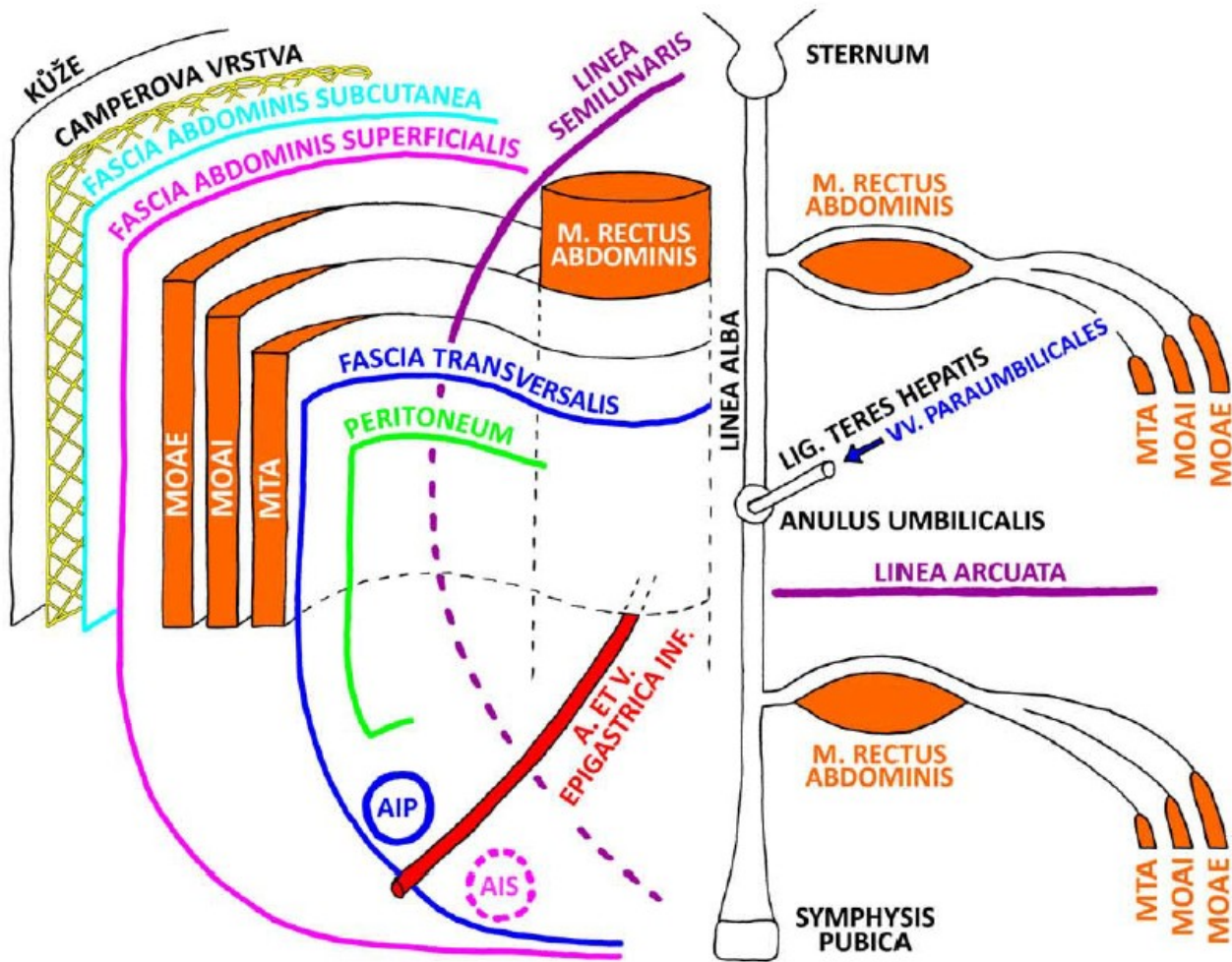
**Papilla Vateri:
Umbiliko-axilární čára
- Desjardinsův bod**



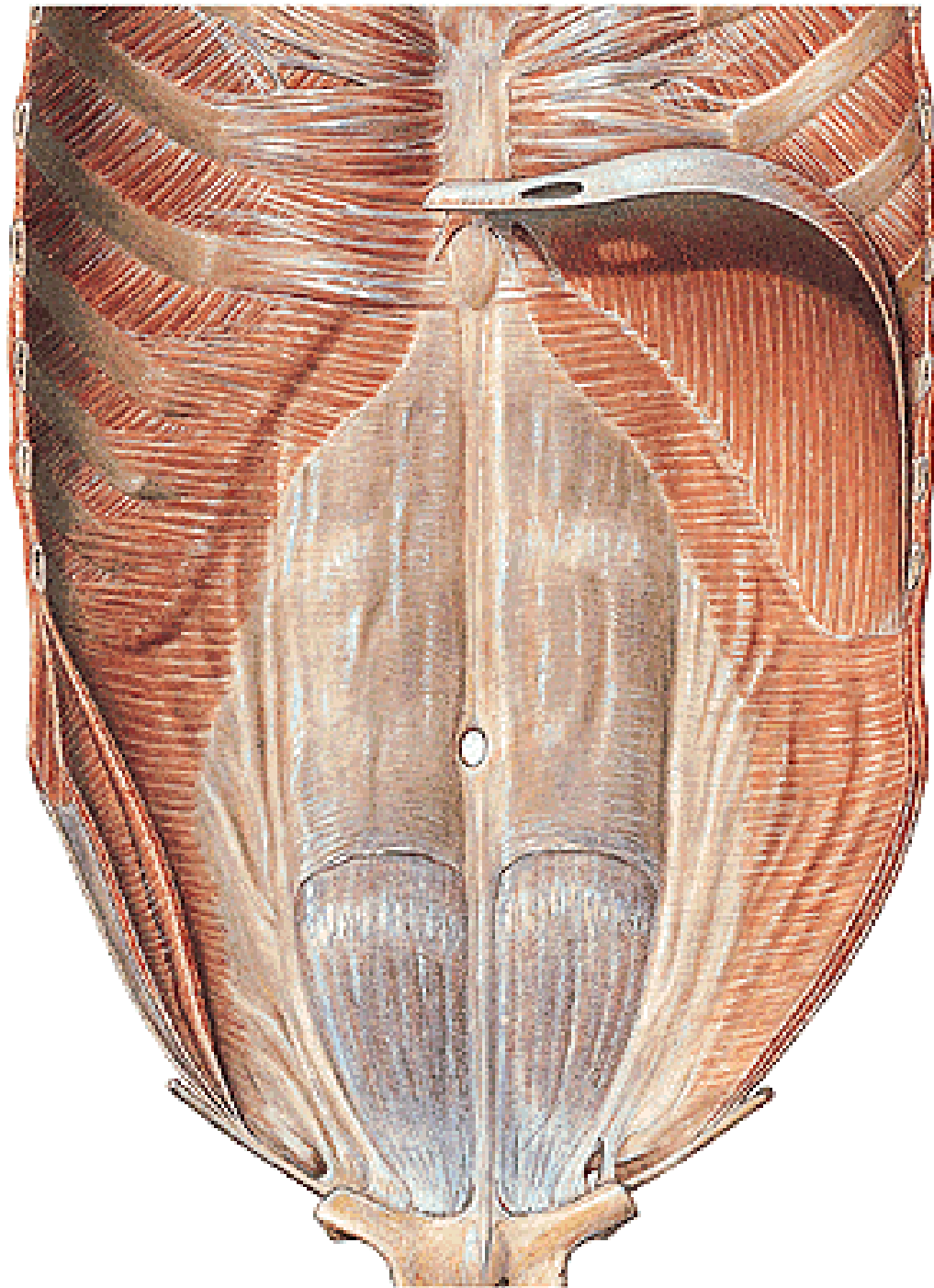
Linea costoarticularis



Břišní stěna

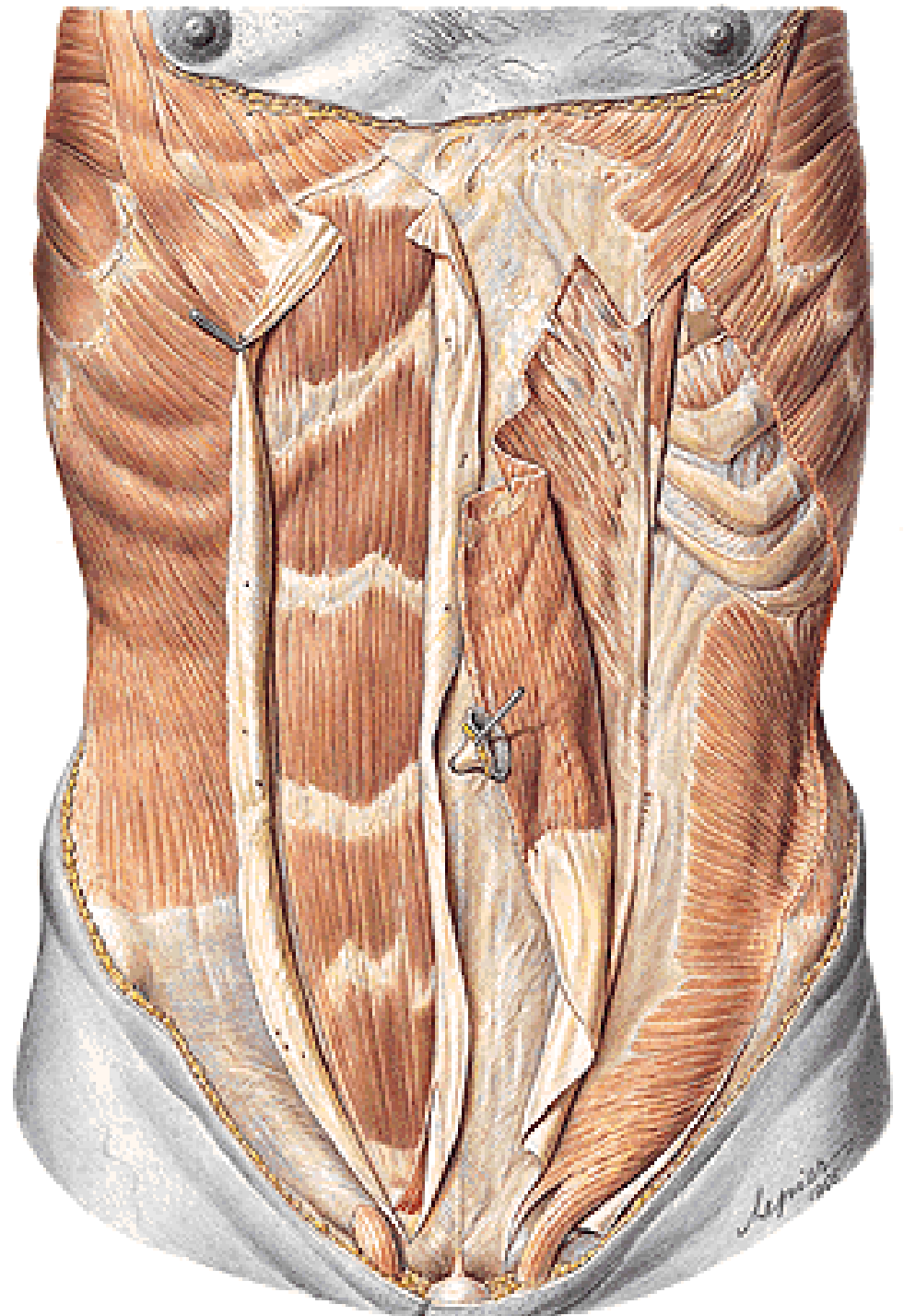


MOAE - M. OBLIQUUS ABDOMINIS EXTERNUS
 MOAI - M. OBLIQUUS ABDOMINIS INTERNUS
 MTA - M. TRANSVERSUS ABDOMINIS
 AIP - ANULUS INGUINALIS PROFUNDUS
 AIS - ANULUS INGUINALIS SUPERFICIALIS



LINEA ARCUATA

VAGINA
M. RECTI ABDOMINIS



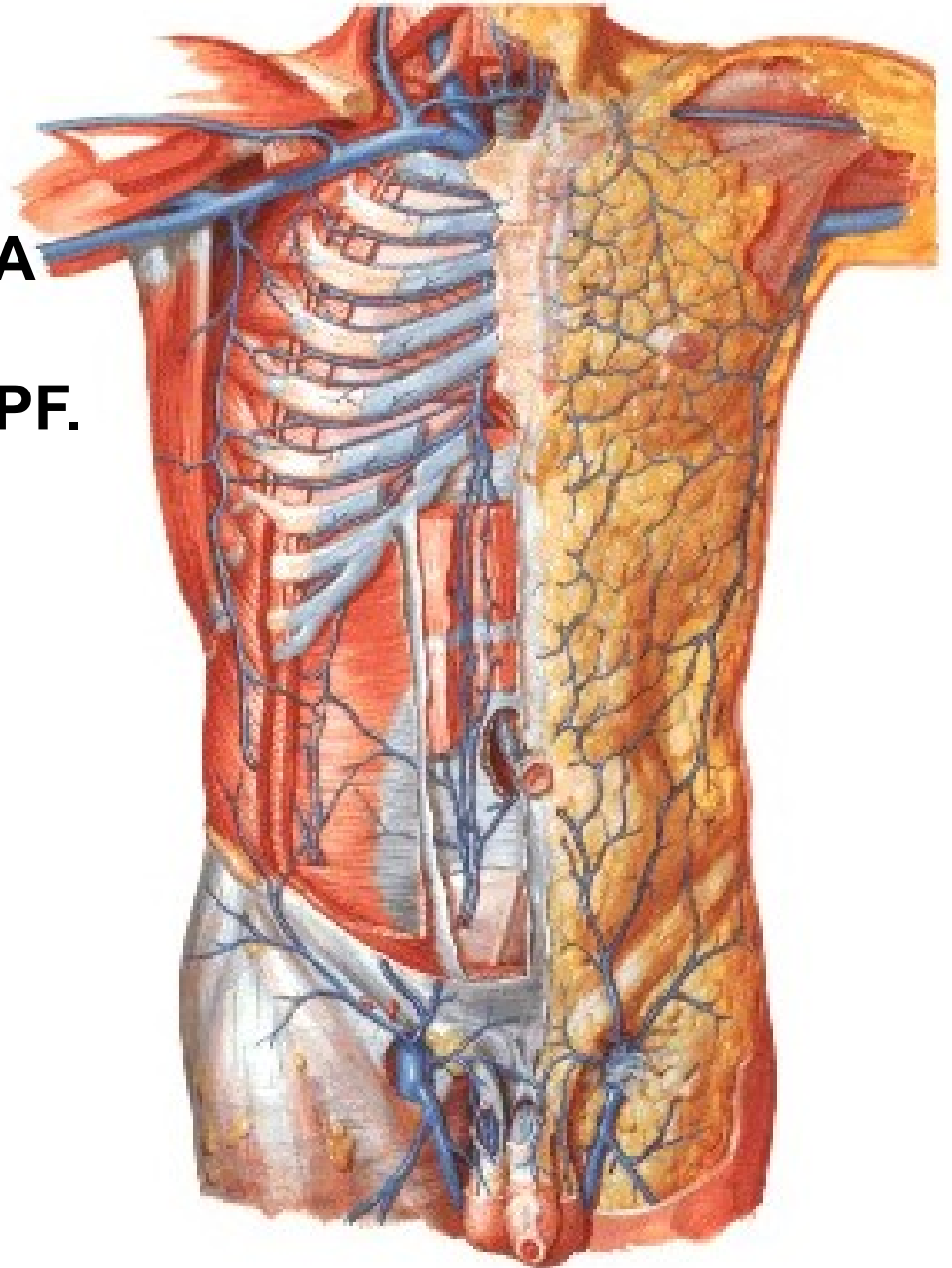
VV. SUBCUTANEAEE ABD.

V. THORACOEPIGASTRICA

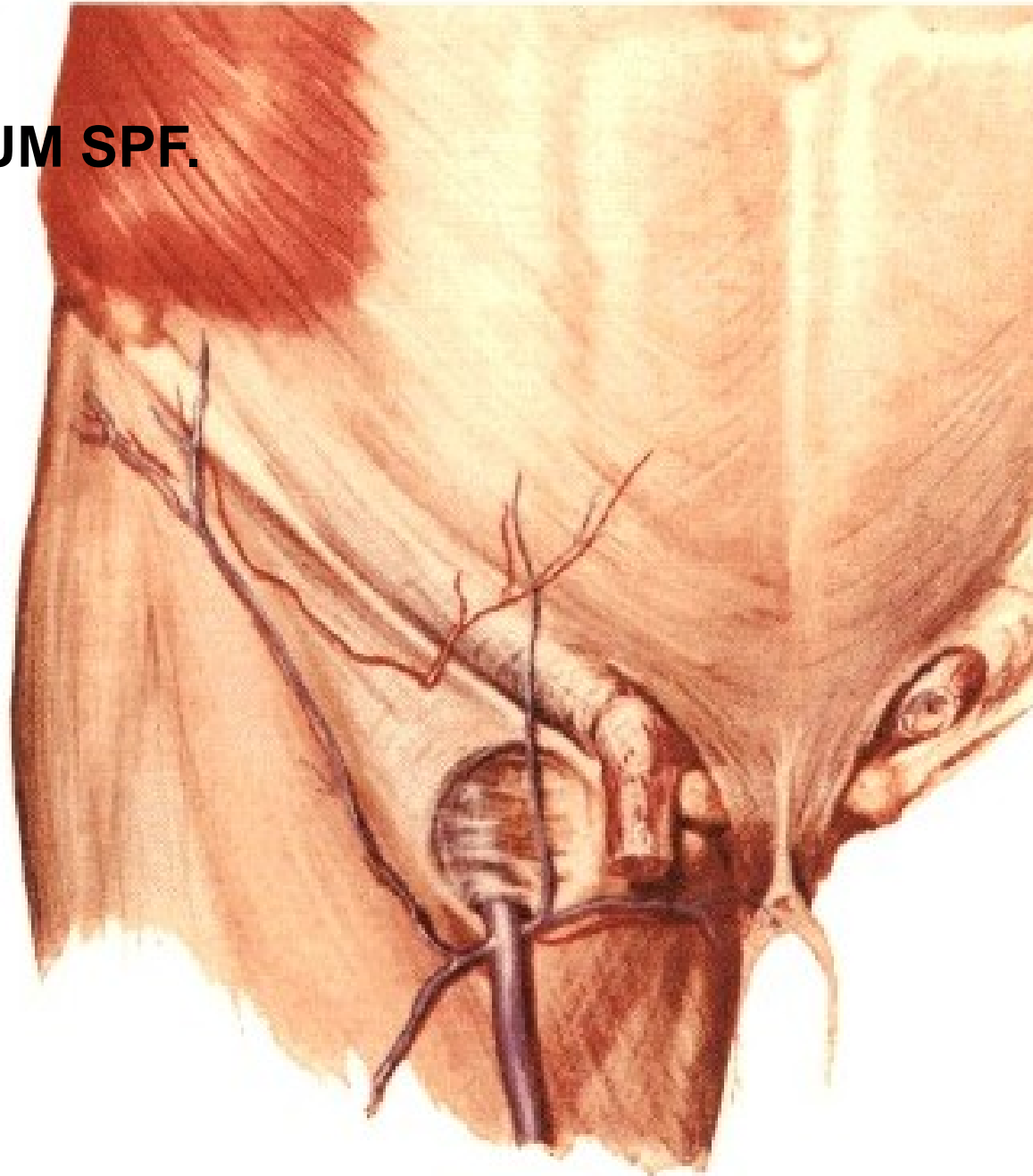
V. EPIGASTRICA SPF.

V. CIRCUMFLEXA ILIUM SPF.

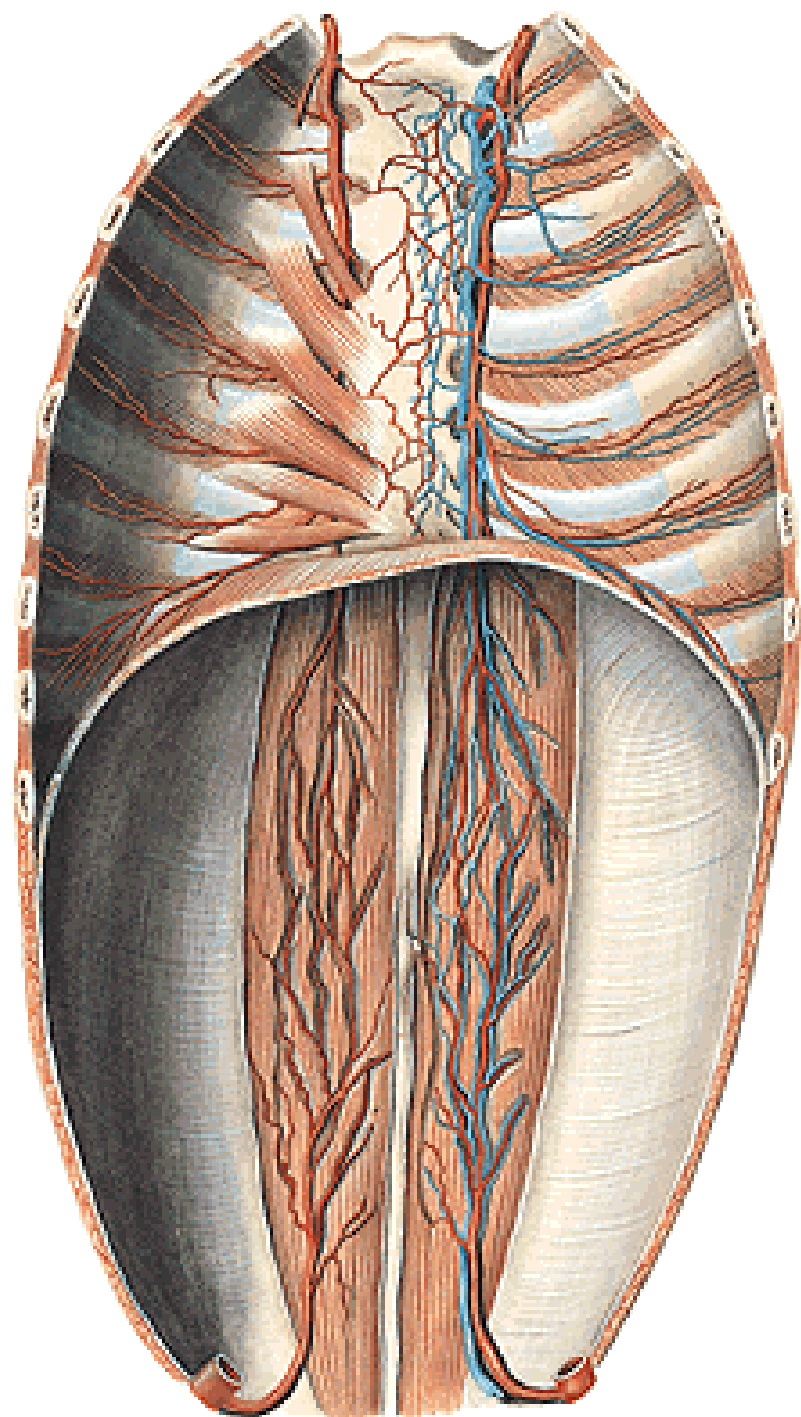
VV. PARAUMBILICALES



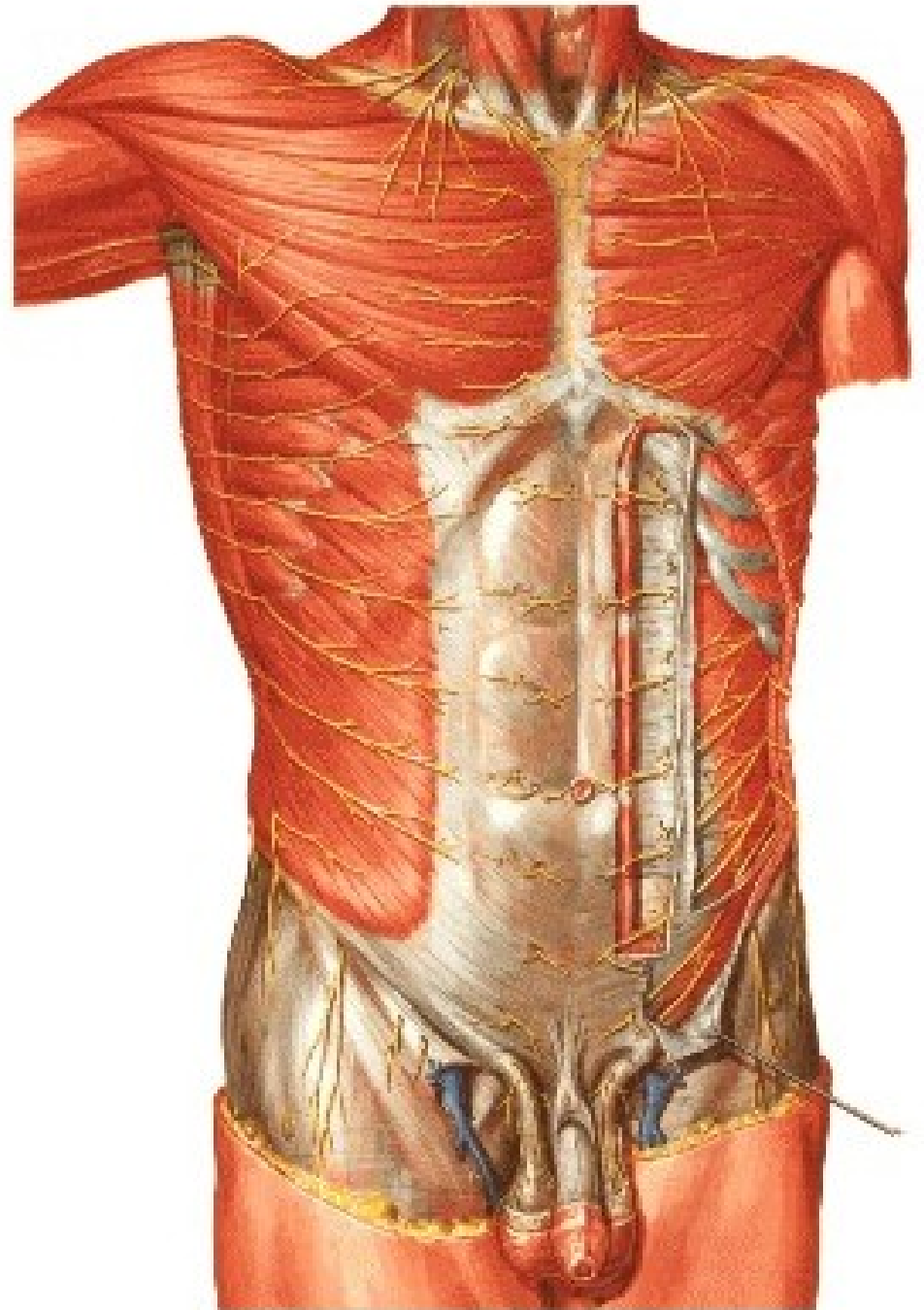
A. EPIGASTRICA SPF.
A. CIRCUMFLEXA ILIUM SPF.
AA. INTERCOSTALES
A. SUBCOSTALIS
AA. LUMBALES



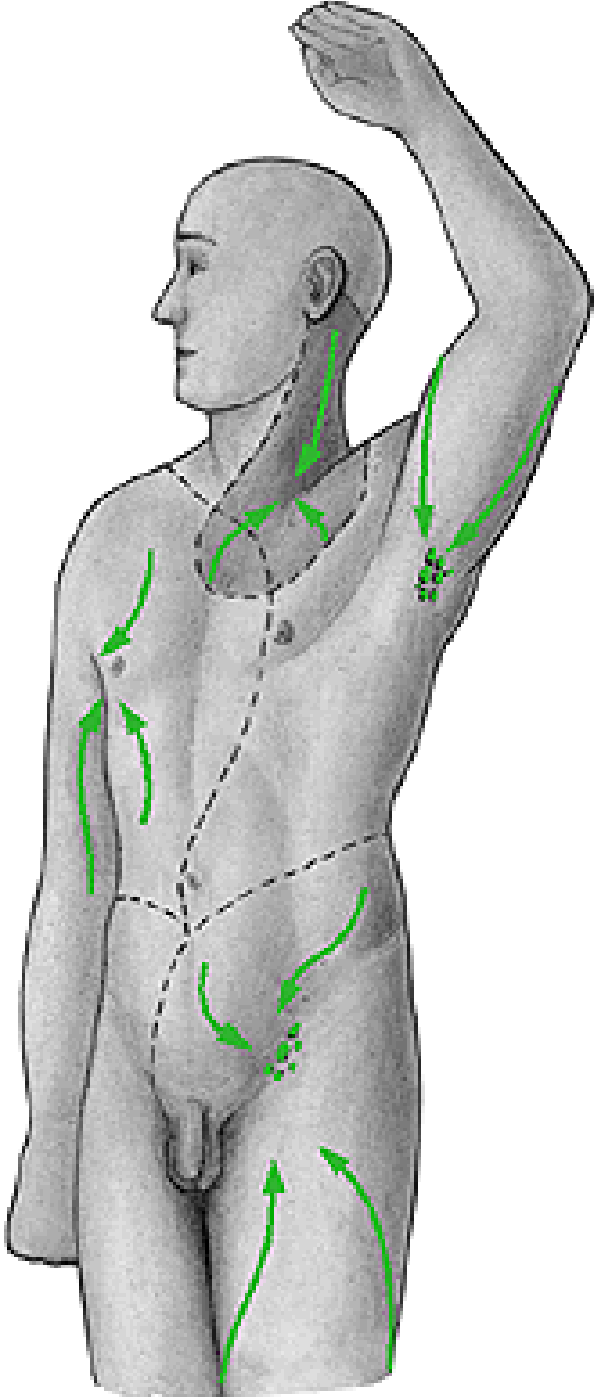
A. EPIGASTRICA SUP.
A. EPIGASTRICA INF.
A. CIRCUMFLEXA ILIUM PROF.
AA. INTERCOSTALES
A. SUBCOSTALIS
AA. LUMBales



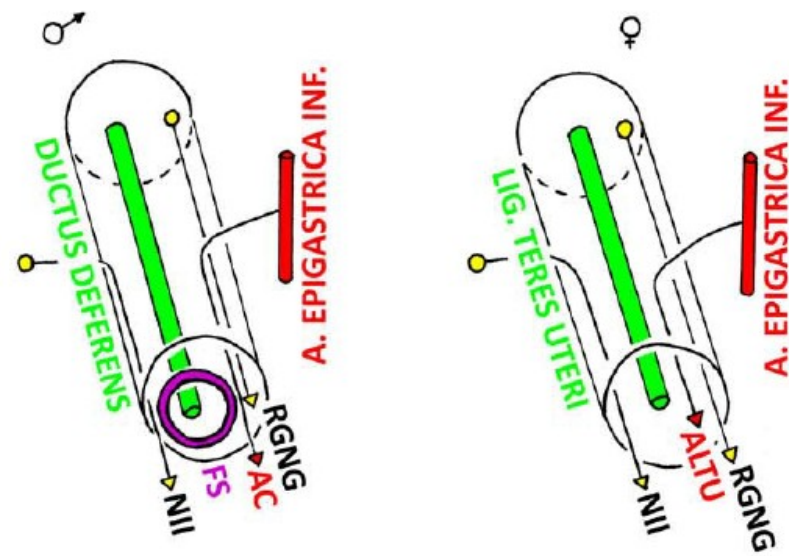
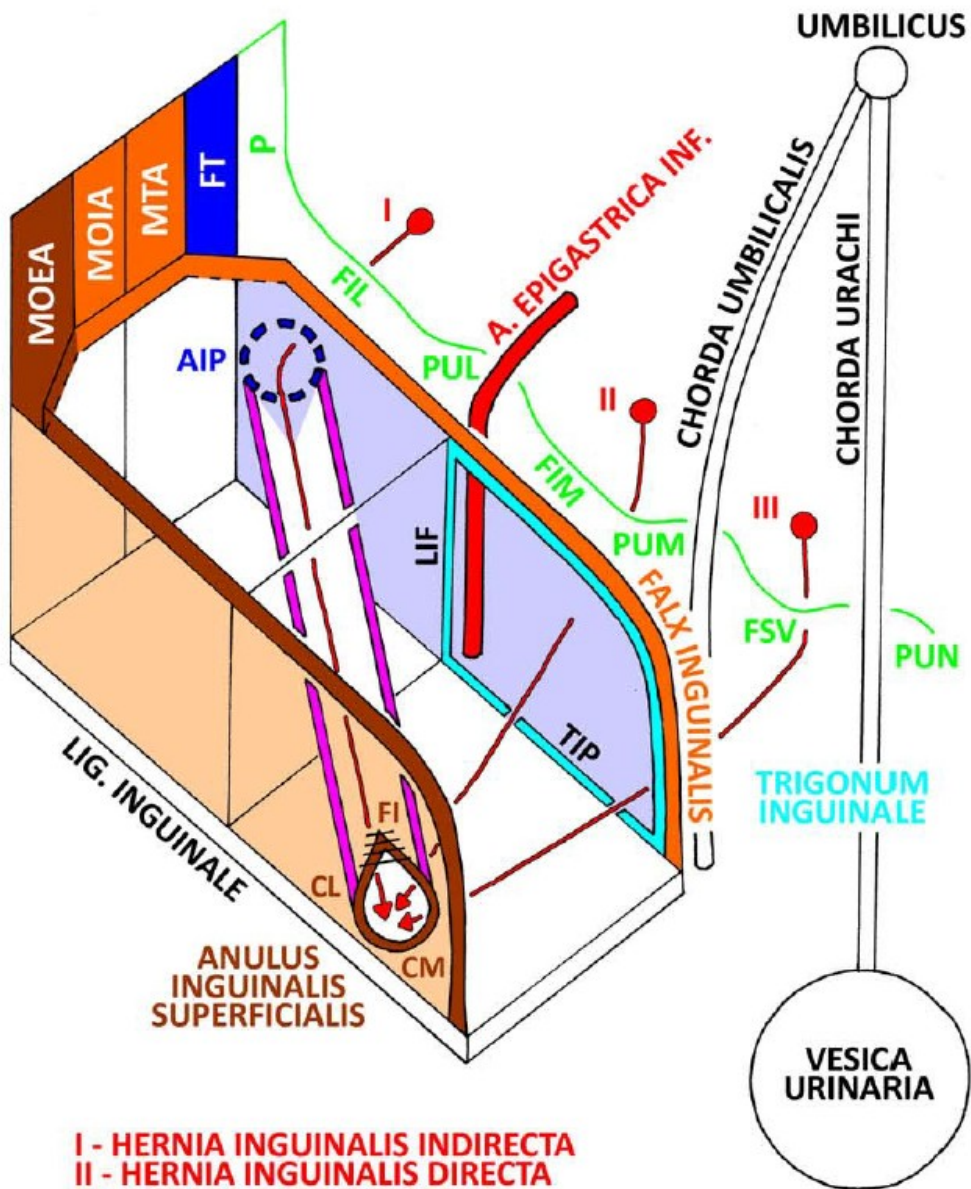
NN. INTERCOSTALES
N. SUBCOSTALIS
N. ILIOHYPOGASTRICUS
N. ILIOINGUINALIS



NODI LYMPHATICI AXILLARES
NODI LYMPHATICI INGUINALES SPF.



CANALIS INGUINALIS



I - HERNIA INGUINALIS INDIRECTA
 II - HERNIA INGUINALIS DIRECTA
 III - HERNIA SUPRAVESICALIS

- MOEA - M. OBLIQUUS EXTERNUS ABDOMINIS
- MOIA - M. OBLIQUUS INTERNUS ABDOMINIS
- MTA - M. TRANSVERSUS ABDOMINIS
- FT - FASCIA TRANSVERSALIS PROFUNDA
- AIP - ANULUS INGUINALIS PROFUNDUS
- P - PERITONEUM
- FIL - FOSSA INGUINALIS LAT.
- PUL - PLICA UMBILICALIS LATERALIS
- LIF - LIG. INTERFOVEOLARE
- FIM - FOSSA INGUINALIS MED.
- PUM - PLICA UMBILICALIS MEDIALIS
- FSV - FOSSA SUPRAVESICALIS
- PUN - PLICA UMBILICALIS MEDIANA
- TIP - TRACTUS ILIOPUBICUS
- FI - FIBRAE INTERCRURALES
- CL - CRUS LATERALE
- CM - CRUS MEDIALE
- NII - N. ILIOINGUINALIS
- FS - FUNICULUS SPERMATICUS
- AC - A. CREMASTERICA
- RGNG - R. GENITALIS N. GENITOFEMORALIS
- ALTU - A. LIGAMENTI TERETIS UTERI

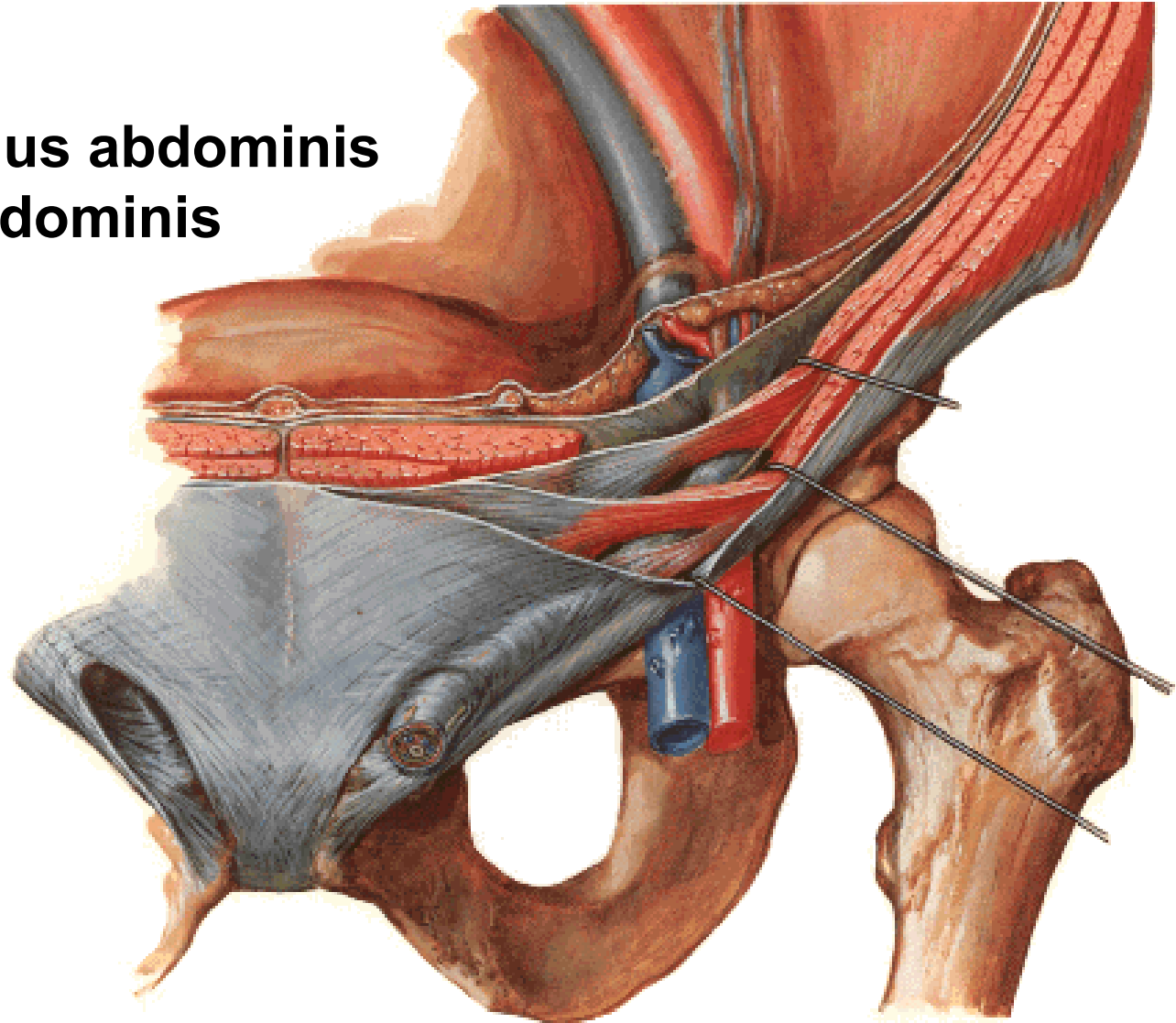
CANALIS INGUINALIS

Horní stěna:

M. obliquus internus abdominis

M. transversus abdominis

- **M. cremaster**



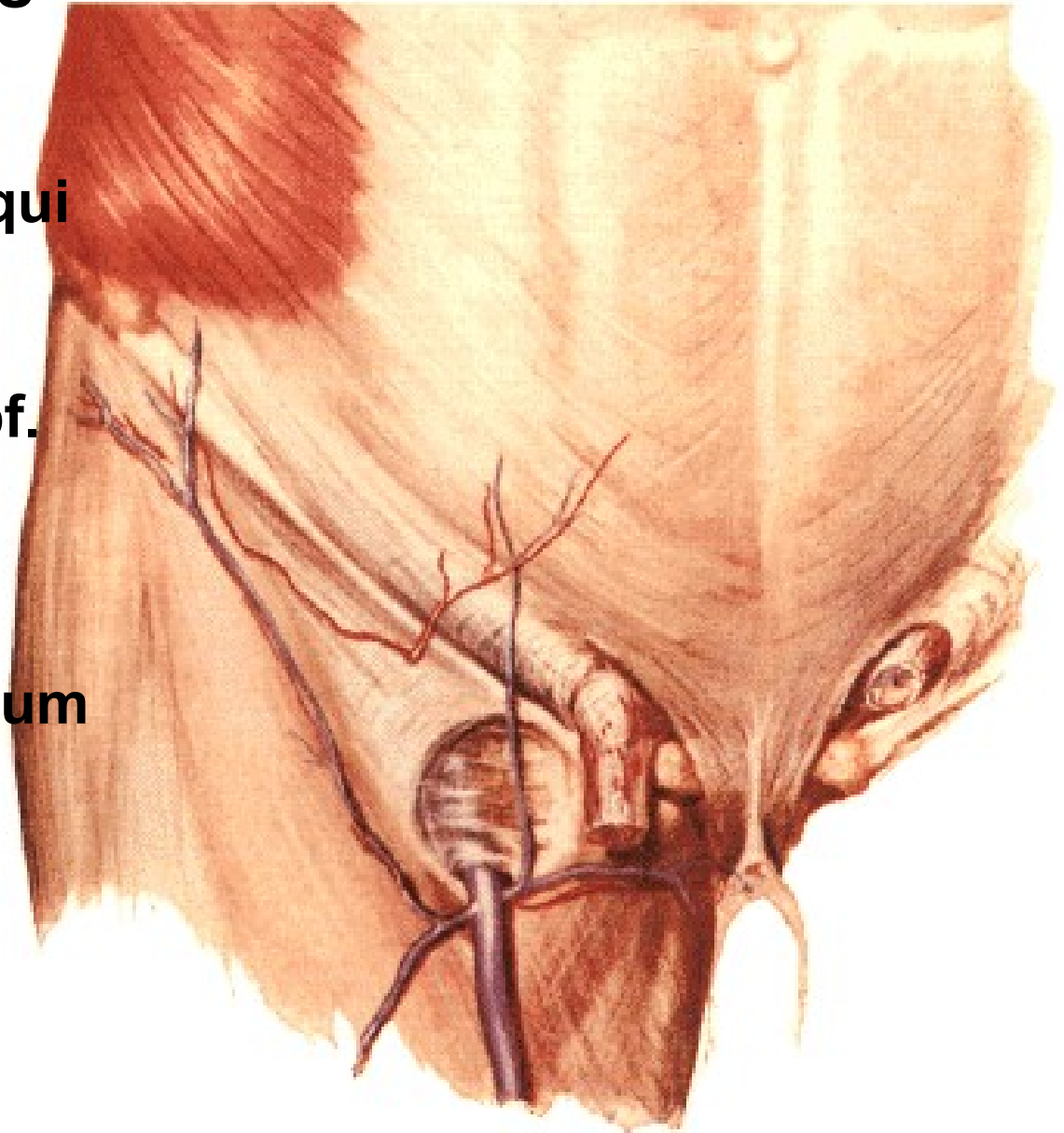
CANALIS INGUINALIS

Přední stěna:

**Aponeurosis m. obliqui
externi abdominis**

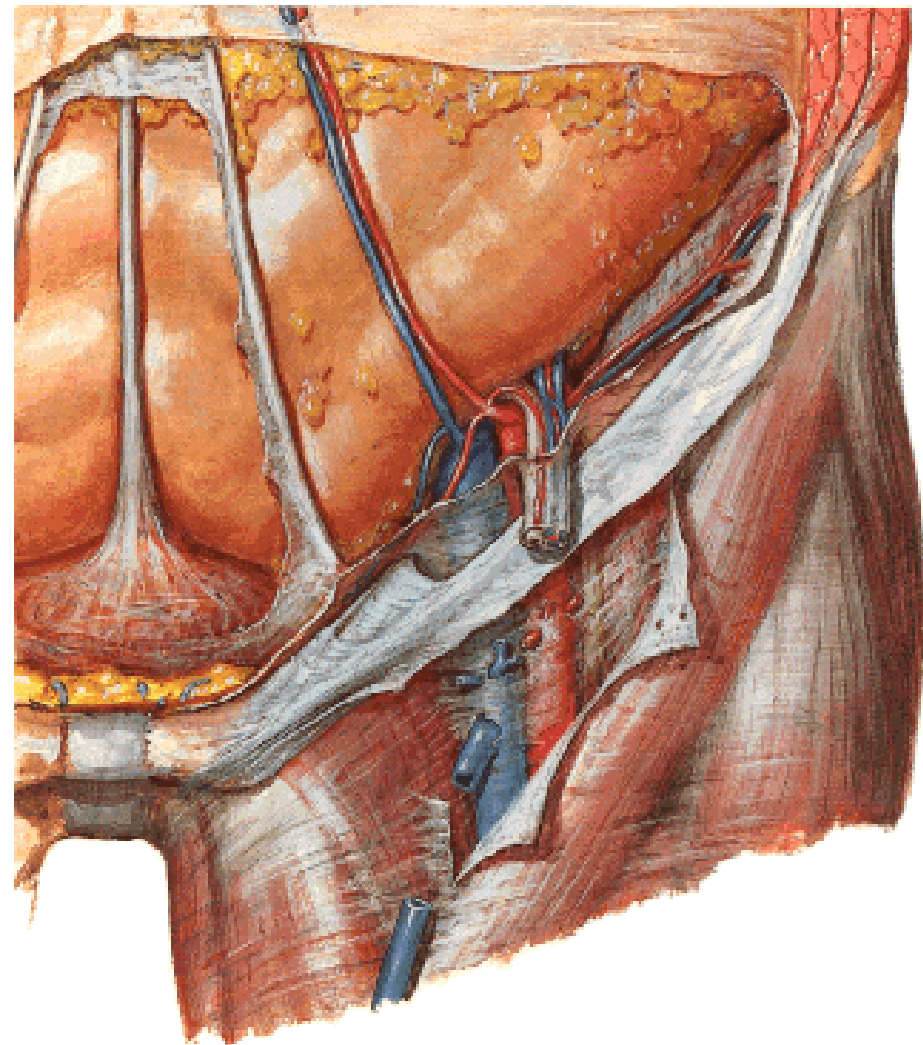
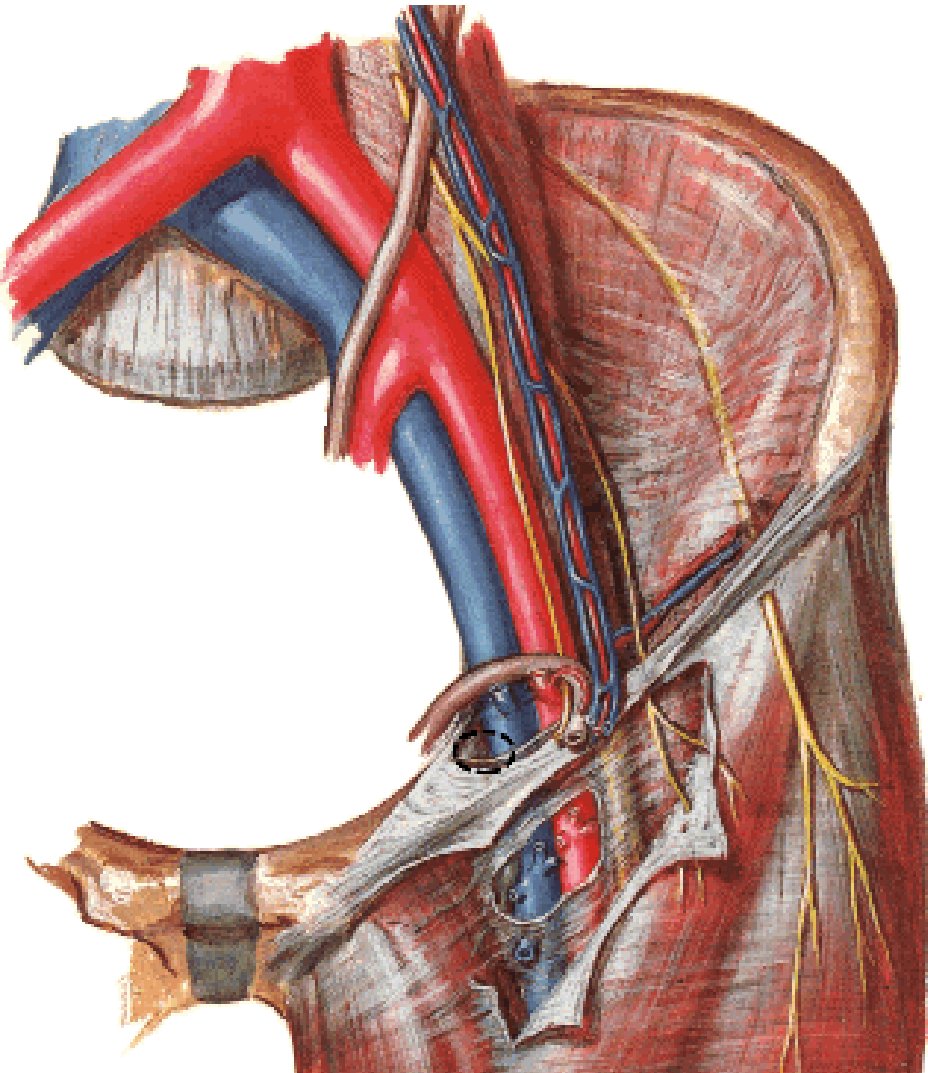
Anulus inguinalis spf.

- **crus mediale**
- **crus laterale**
- **fibrae intercrurales**
- **lig. inguinale reflexum**



CANALIS INGUINALIS

Spodní stěna:
Lig. inguinale



CANALIS INGUINALIS

Zadní stěna:

Fascia transversalis:

Anulus inguinalis prof.

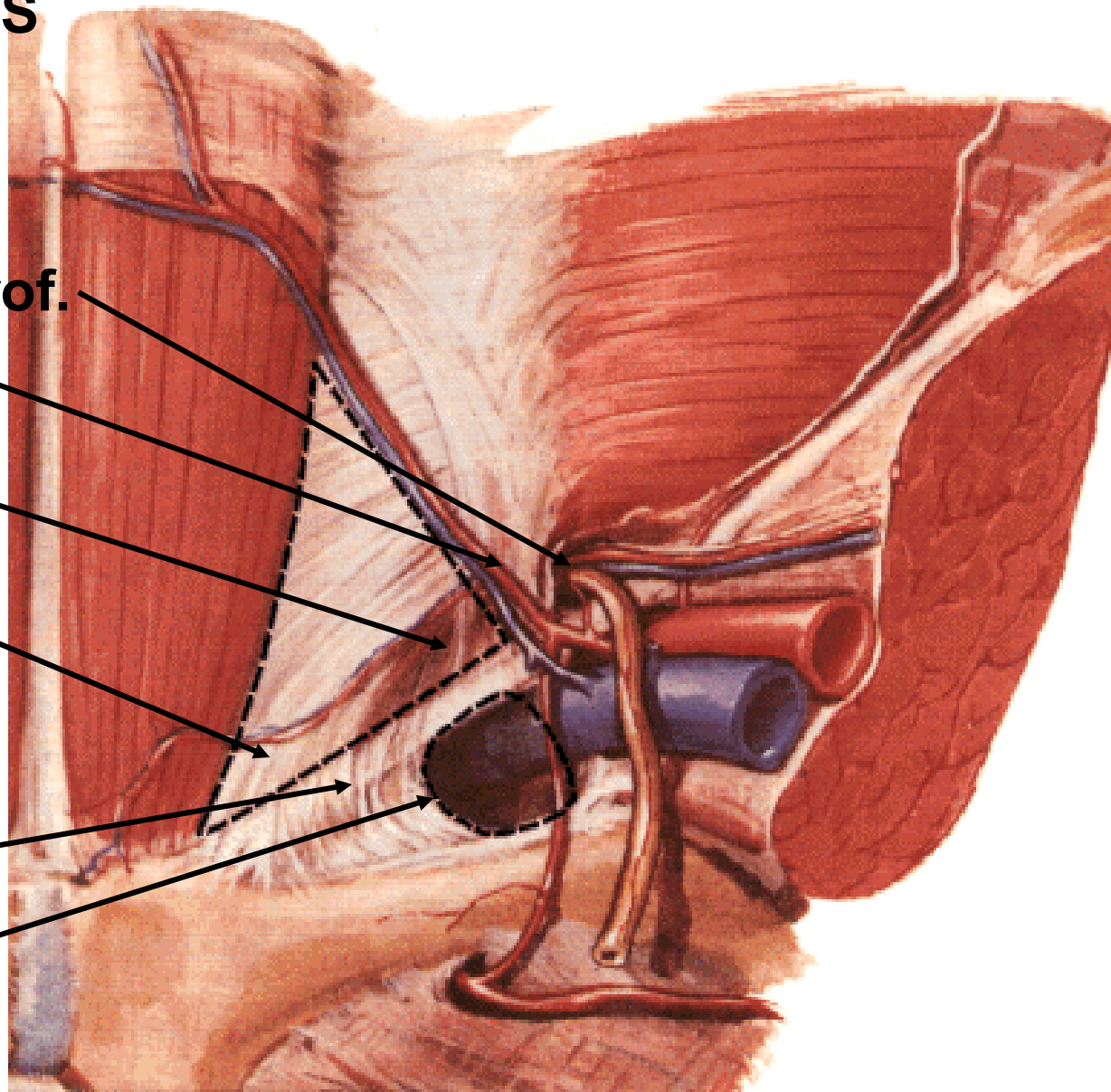
Lig. interfoveolare

**Trigonum inguinale
(Hesselbachi)**

Falx inguinalis

Tractus iliopubicus

Anulus femoralis



Plica umbilicalis mediana
- lig. umbilicale medianum
(chorda urachi)

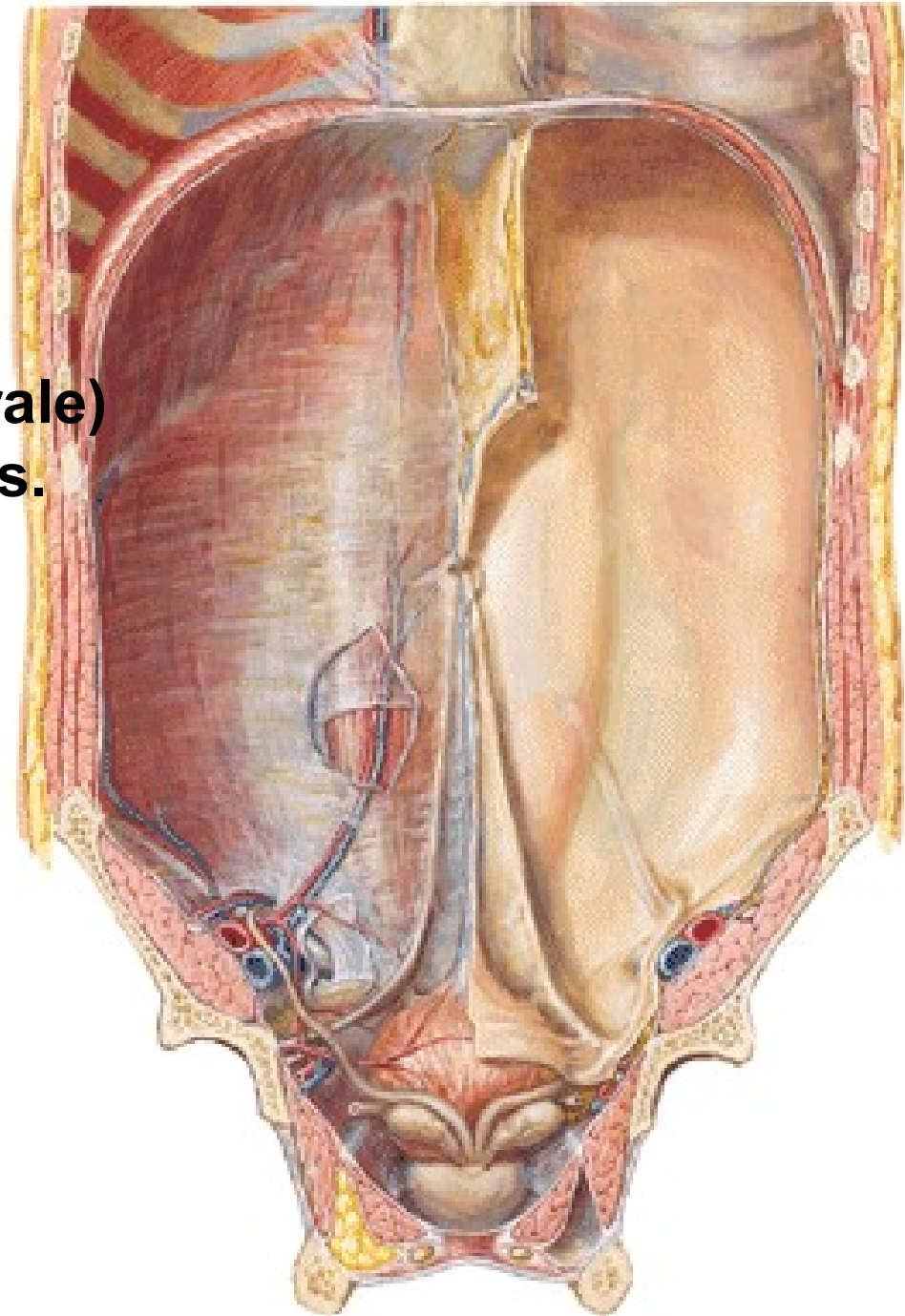
Fossa supravesicalis

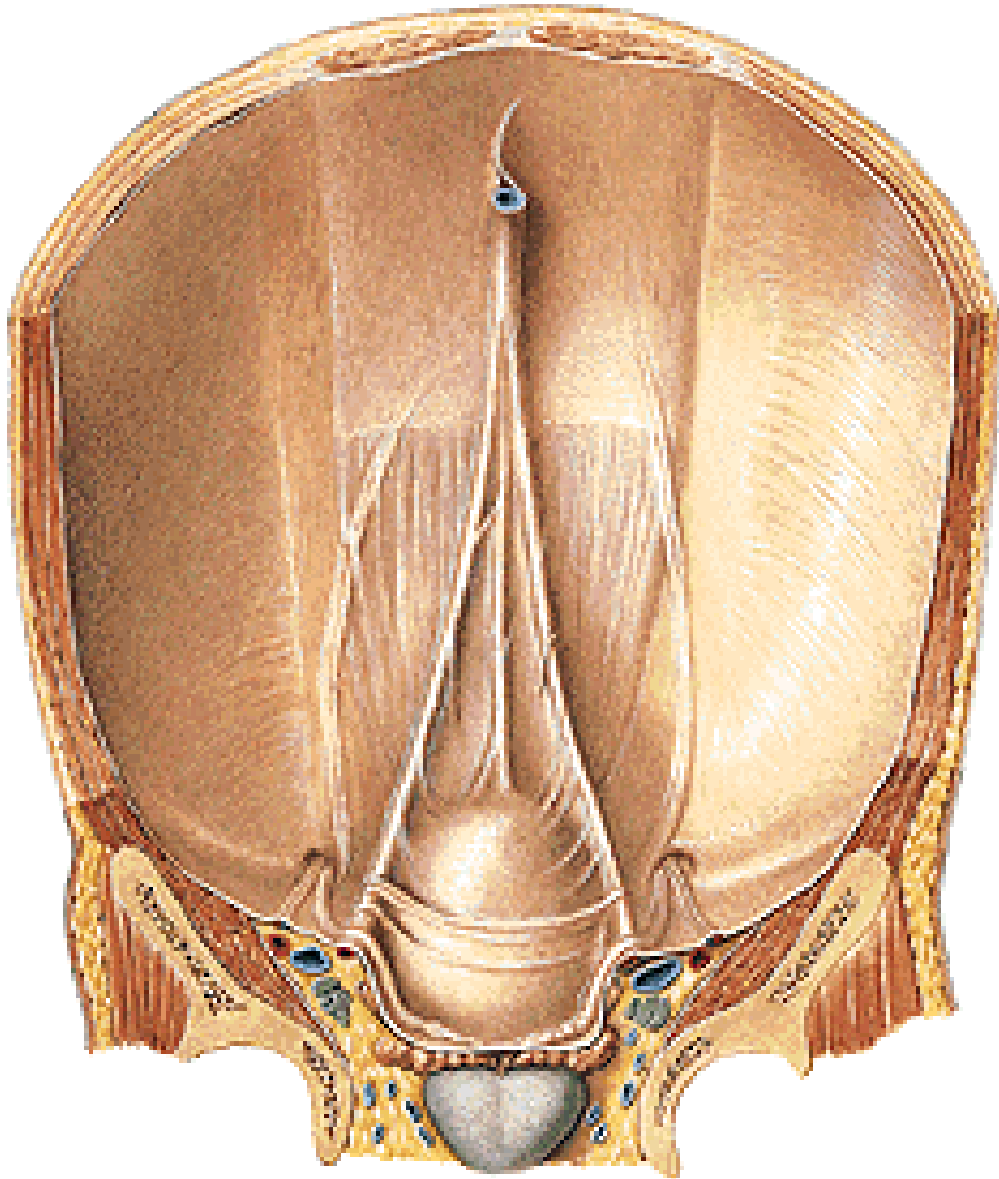
Plica umbilicalis medialis
- lig. umbilicale mediale (laterale)
(pars occlusa a. umbilicalis s.
chorda umbilicalis)

Fossa inguinalis medialis
- **direct inguinal hernia**

Plica umbilicalis lateralis
- vasa epigastrica inf.

Fossa inguinalis lateralis
- **indirect inguinal hernia**



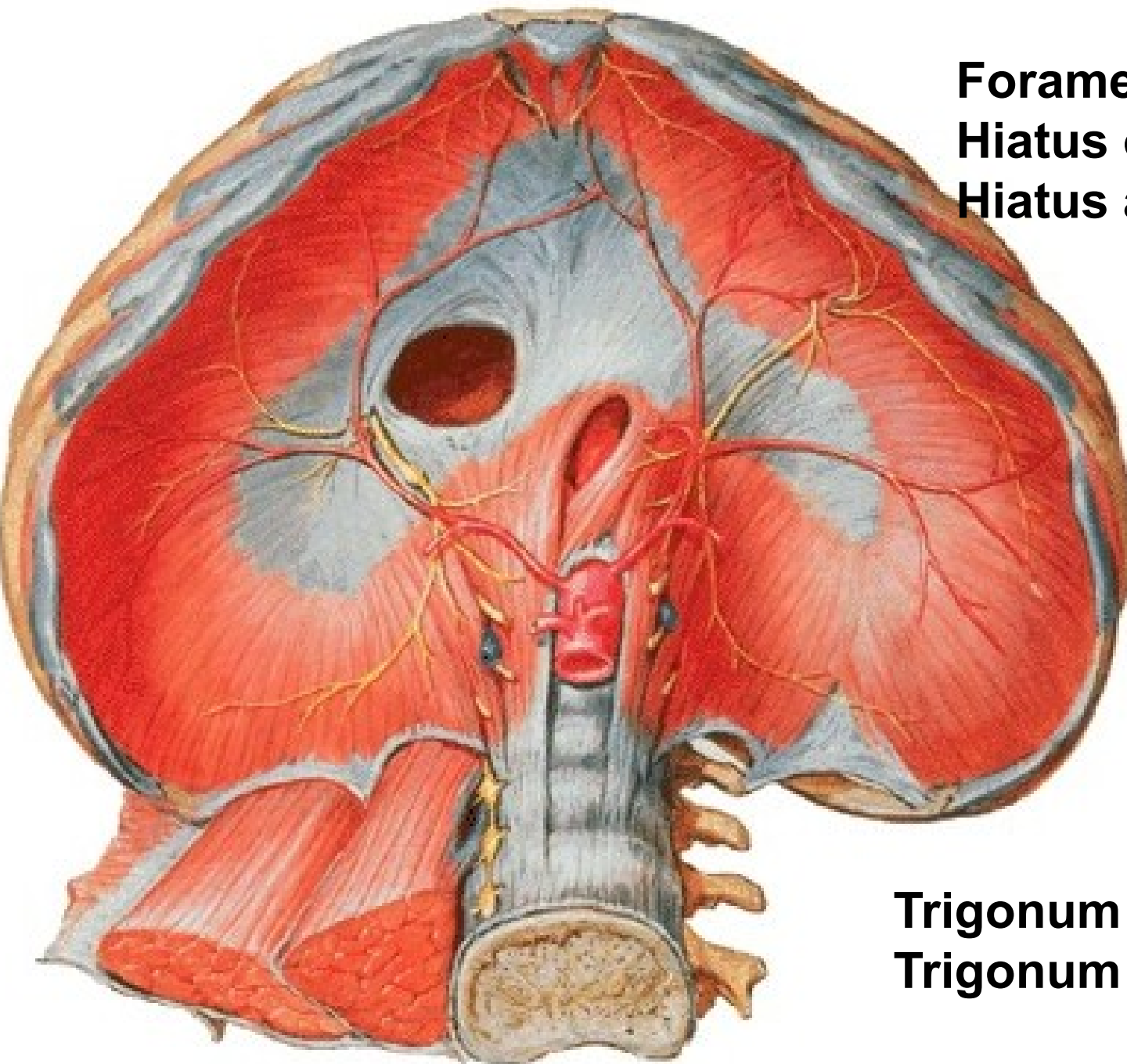


A. UMBILICALIS

→ chorda umbilicalis

V. UMBILICALIS

→ ligamentum teres
hepatis



Foramen v. cavae inf.
Hiatus oesophageus
Hiatus aorticus

Trigonum sternocostale
Trigonum lumbocostale

PERITONEALNÍ DUTINA

CAVITAS ABDOMINALIS

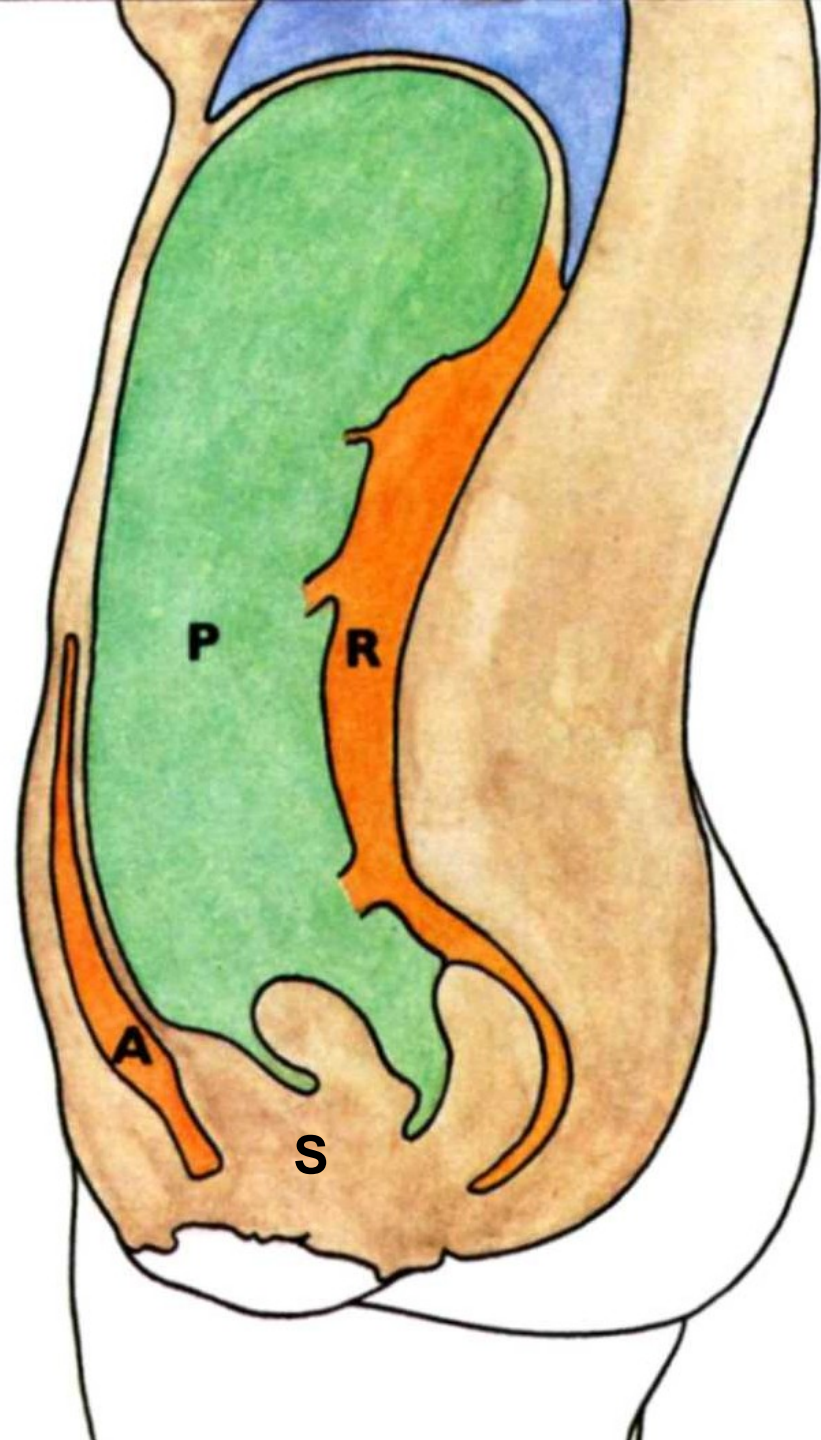
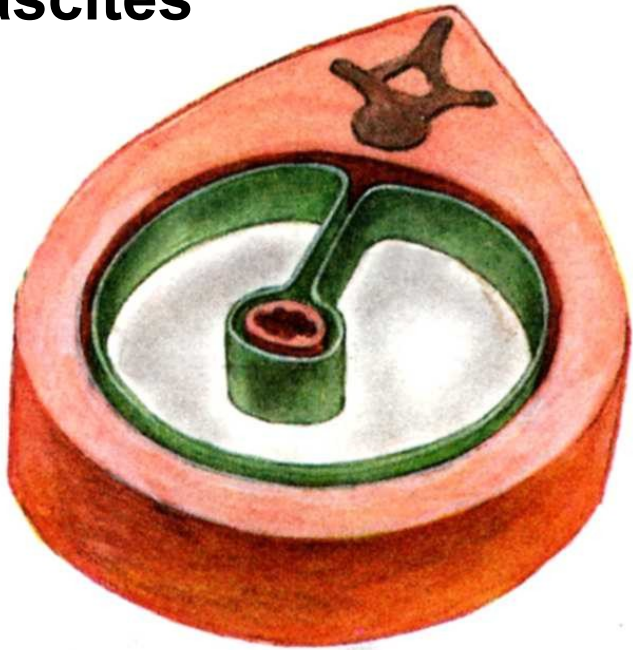
P – cavitas peritonealis

A – spatium preperitoneale

R – spatium retroperitoneale

**S – spatium subperitoneale
(infraperitoneale)**

ascites



Intraperitoneální orgány:

Břišní část oesophagu, žaludek, pars superior duodeni, jejunum, ileum, appendix vermiformis, colon transversum, colon sigmoideum, játra, slezina

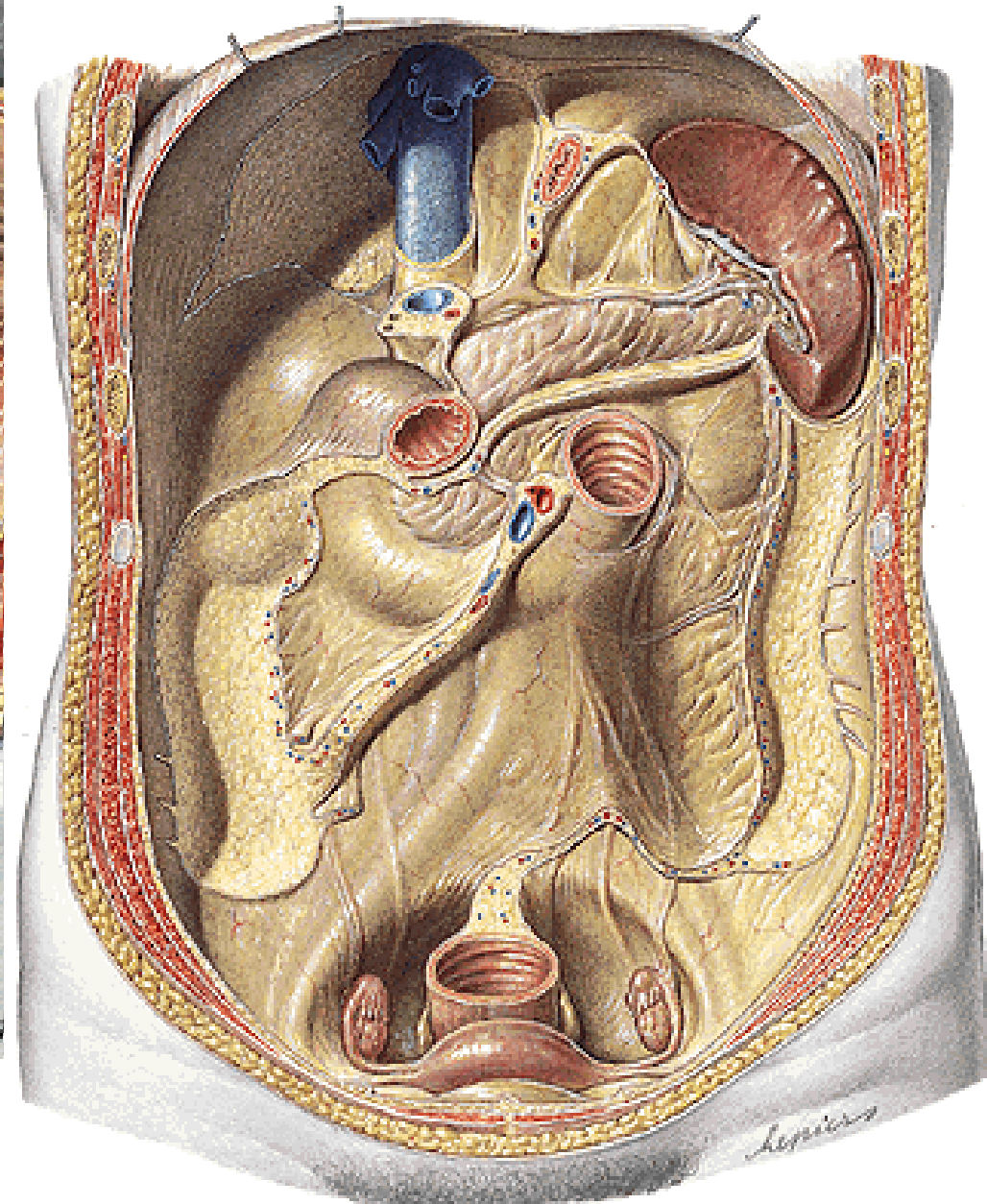
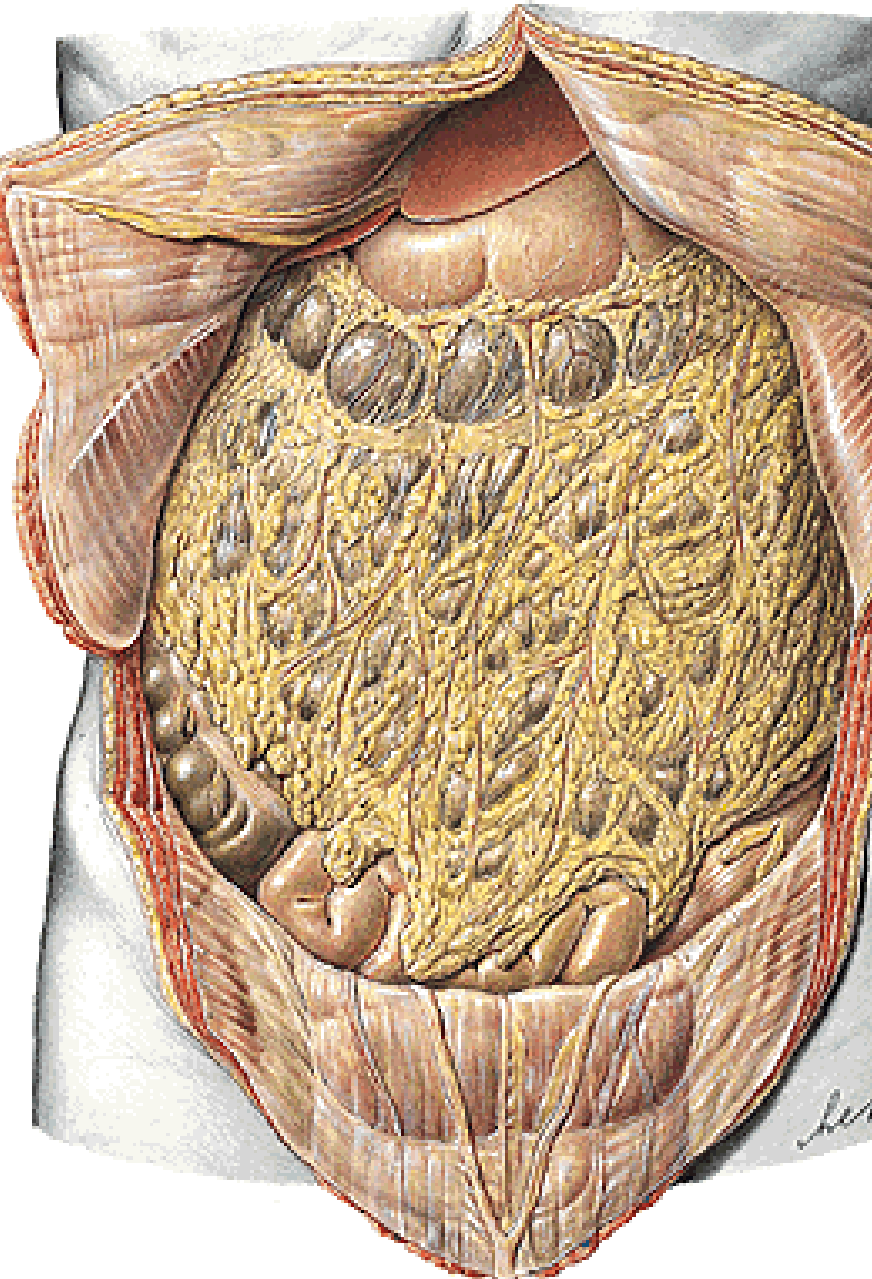
Sekundárně retroperitoneální orgány:

Větší část duodena, pancreas, caecum, colon ascendens, colon descendens

Primárně retroperitoneální orgány:

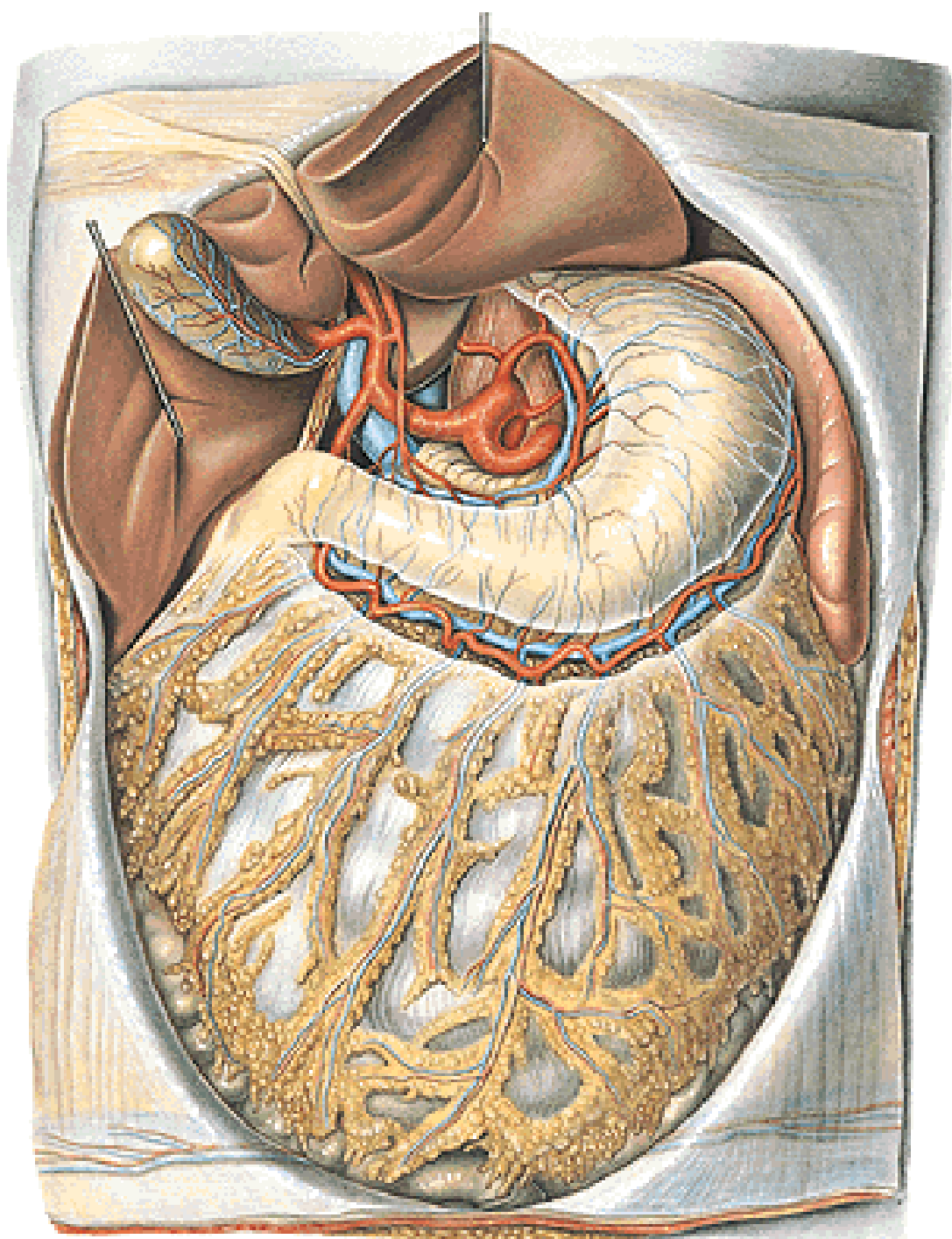
Ledviny, glandula suprarenalis, aorta, vena cava inf.

Cavitas peritonealis - pars supramesocolica, inframesocolica



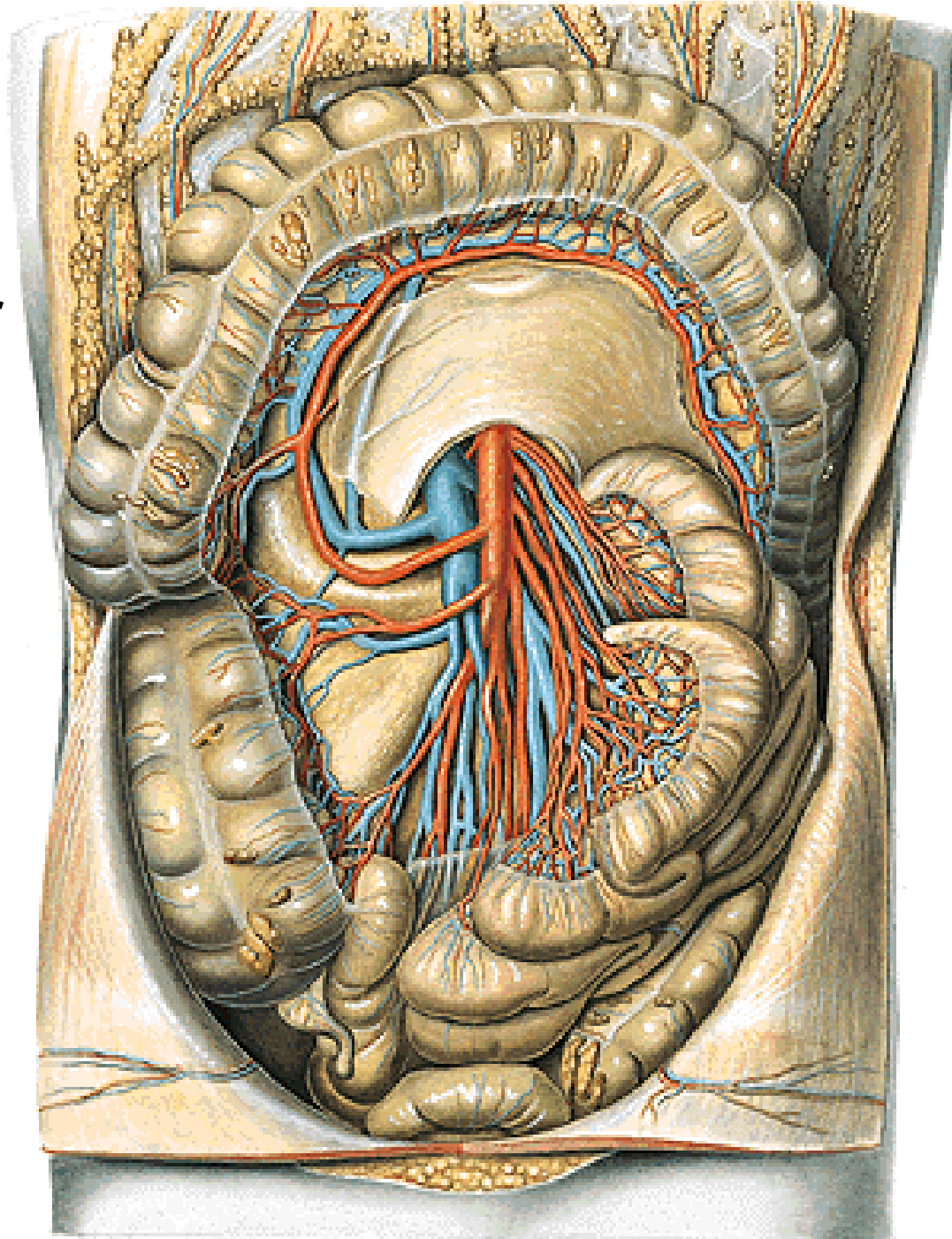
Pars supramesocolica

Truncus coeliacus



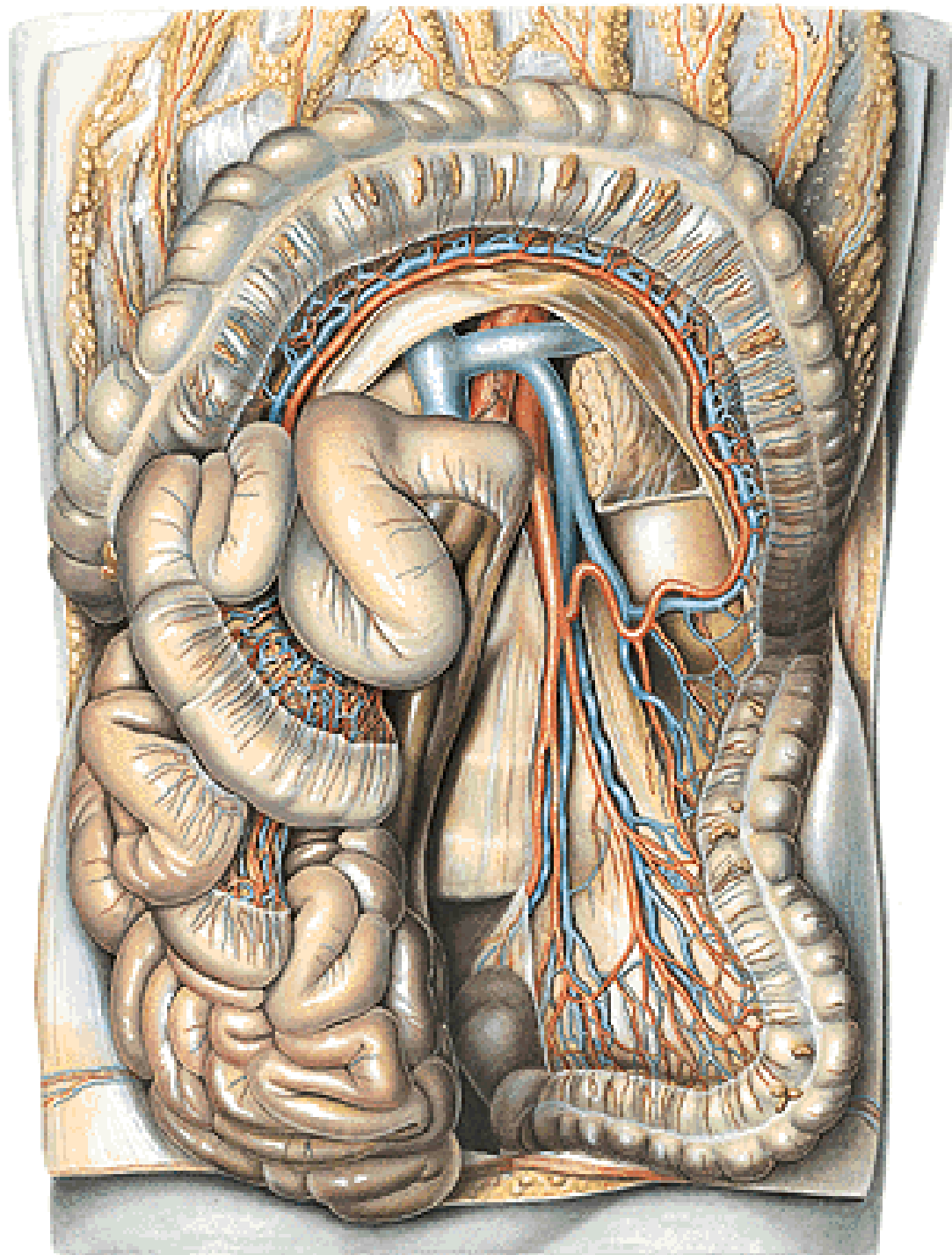
**Pravý inframesokolický
kompartment**

A. mesenterica superior

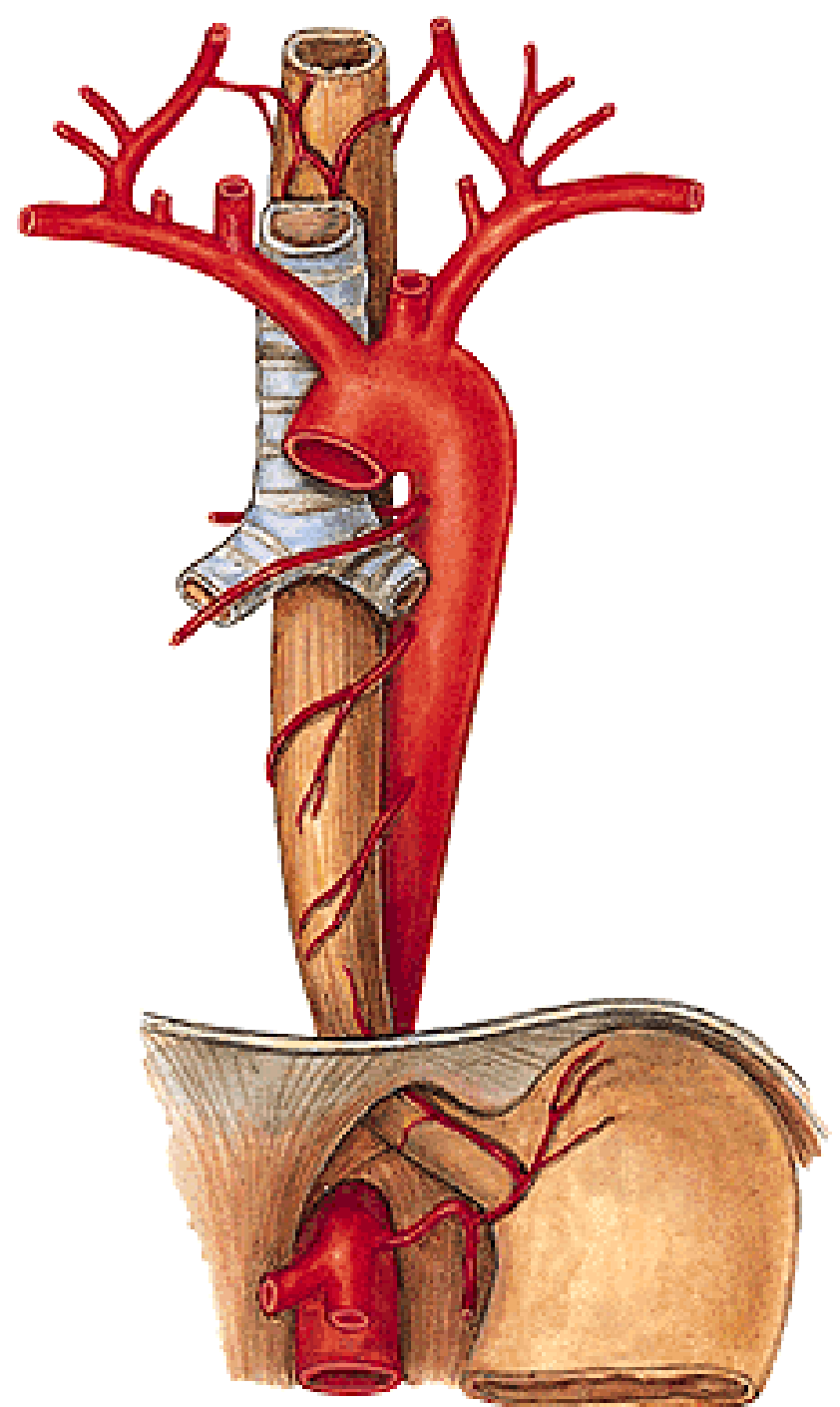


**Levý infrakolický
kompartiment**

A. mesenterica inferior



PARS ABDOMINALIS OESOPHAGEI



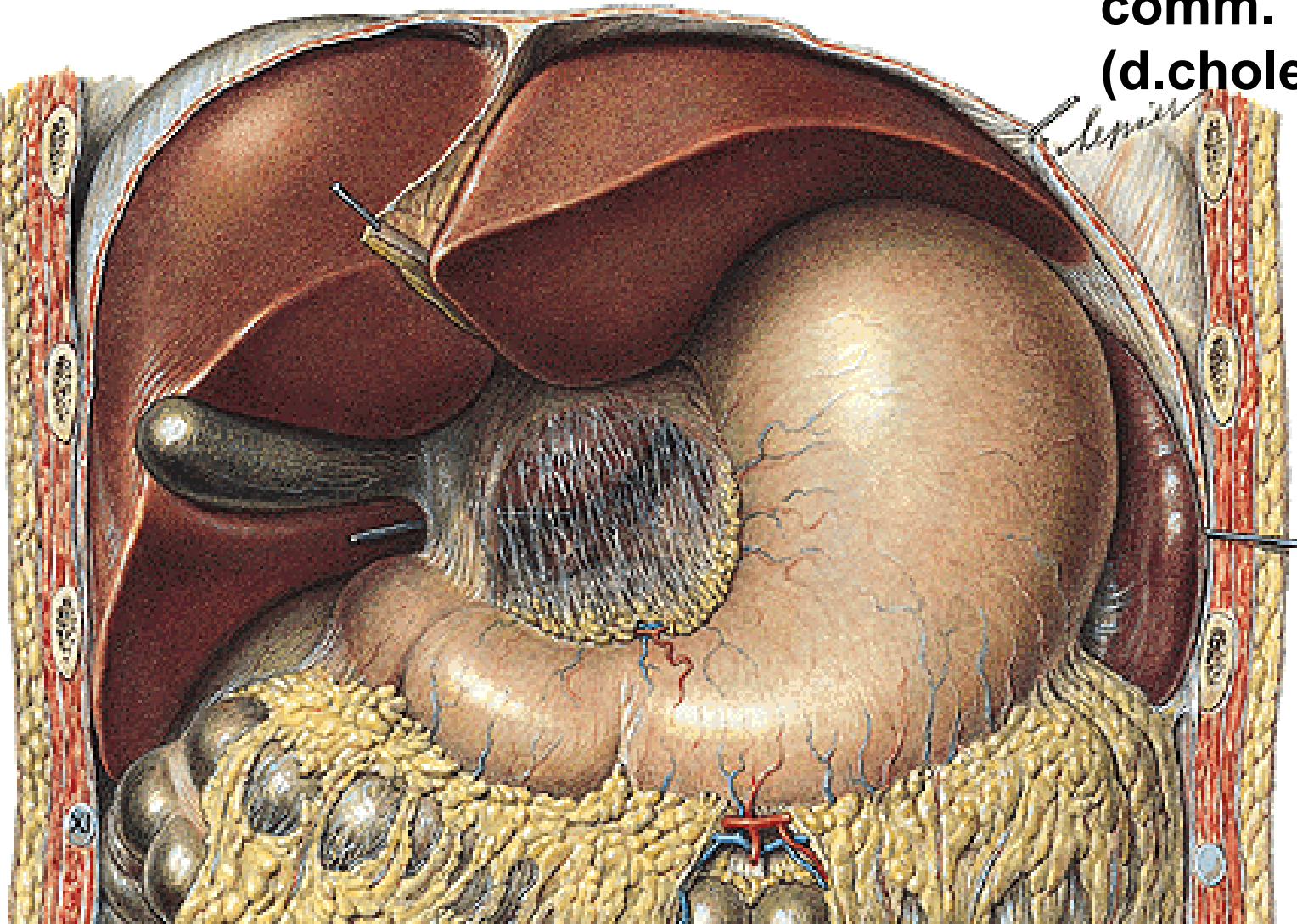
Omentum minus - lig. hepatogastricum

- lig. hepatoduodenale - a. hepatica propria

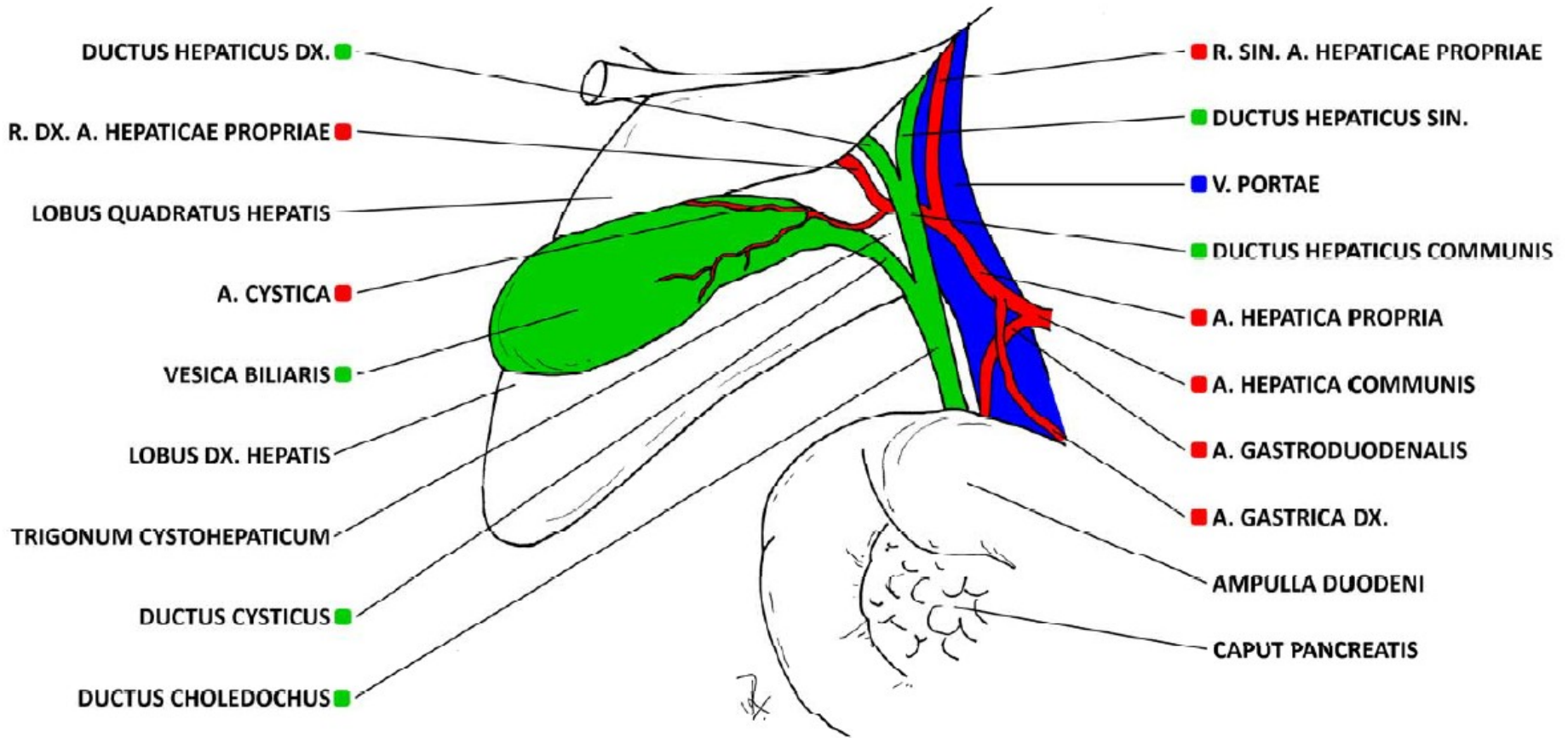
- v. portae

**- ductus hepaticus
comm.**

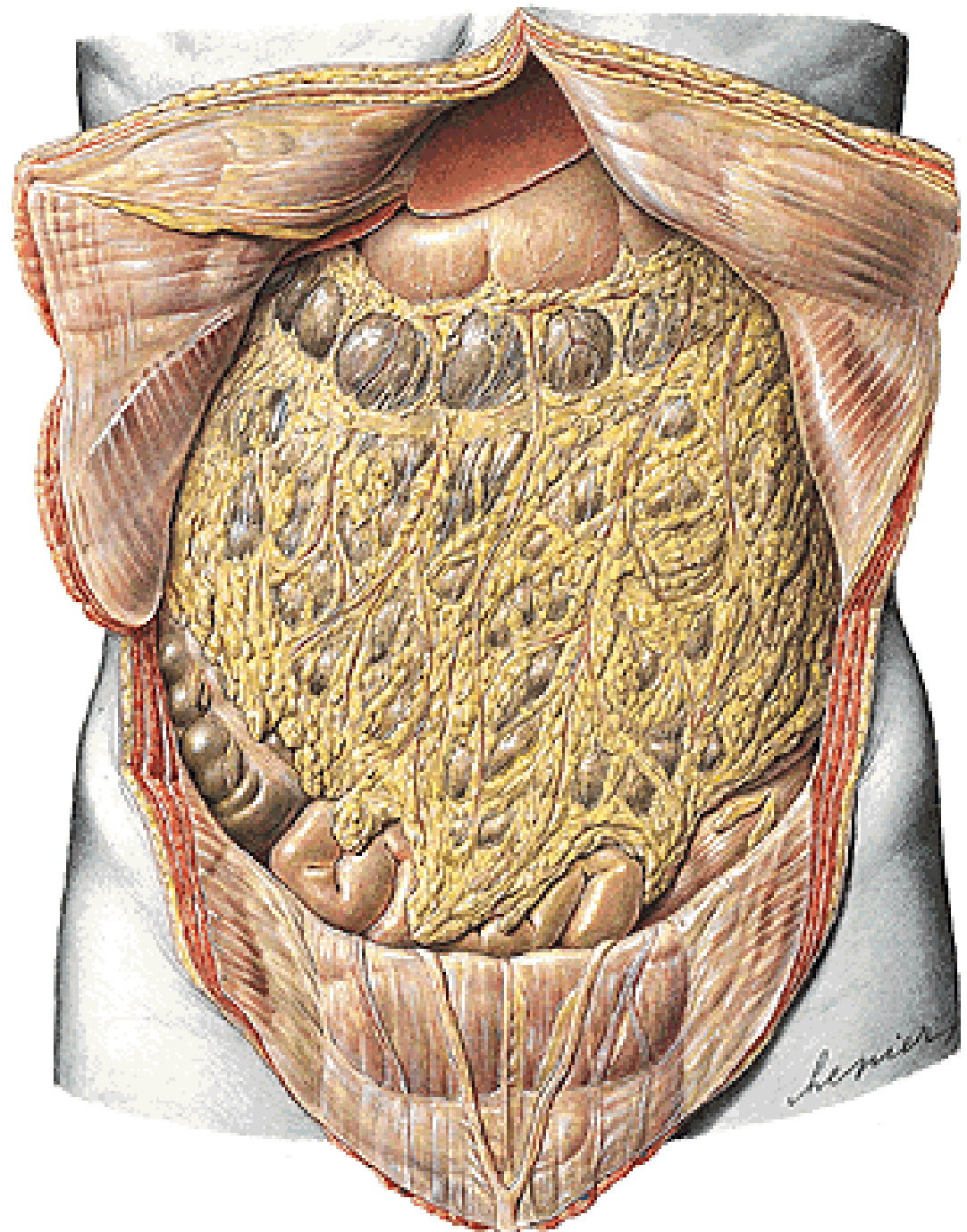
(d.choledochus)

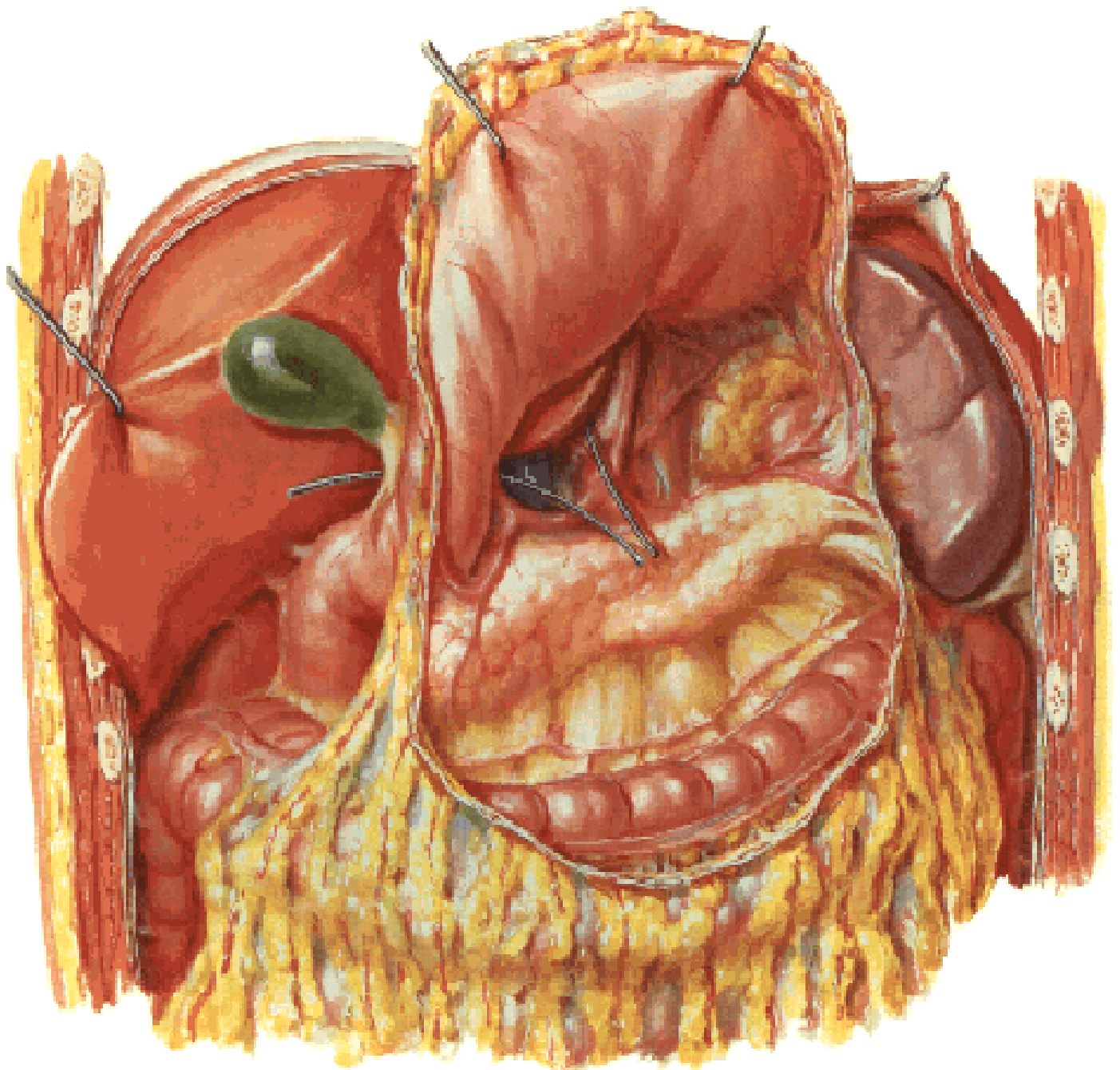

LIGAMENTUM HEPATODUODENALE

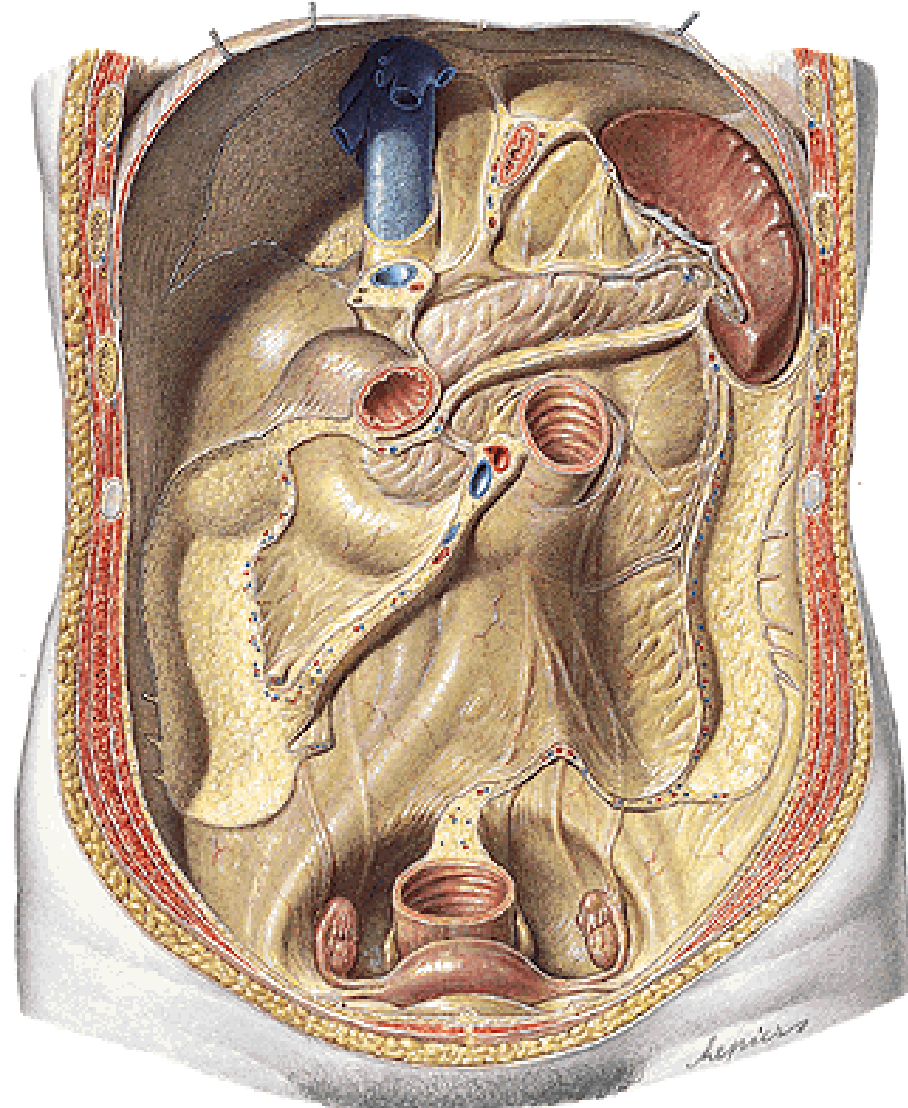
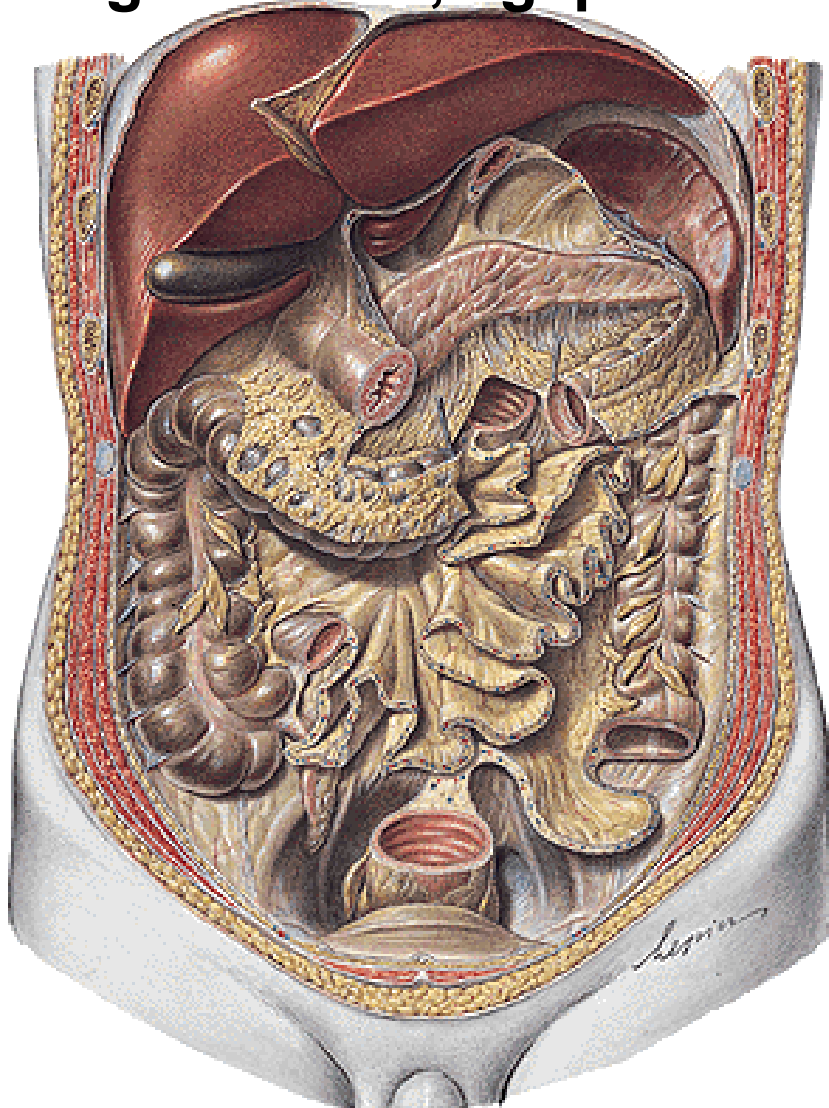


Omentum majus
- lig. gastrocolicum

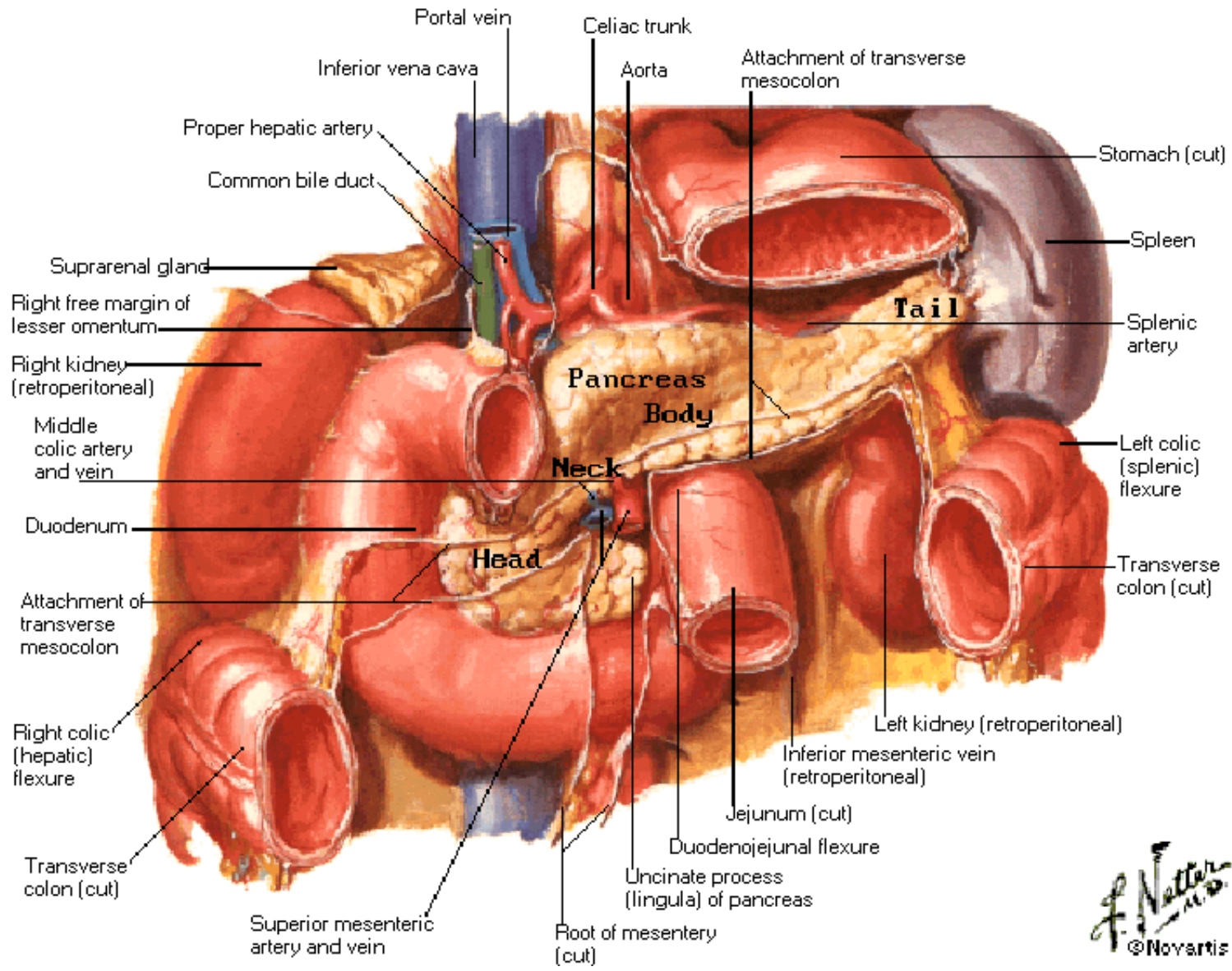




Lig. gastrosplenicum, phrenicosplenicum, splenorenale
Mesenterium – radix mesenterii
Mesocolon transversum, mesoappendix, mesocolon
sigmoideum, lig. phrenicocolicum



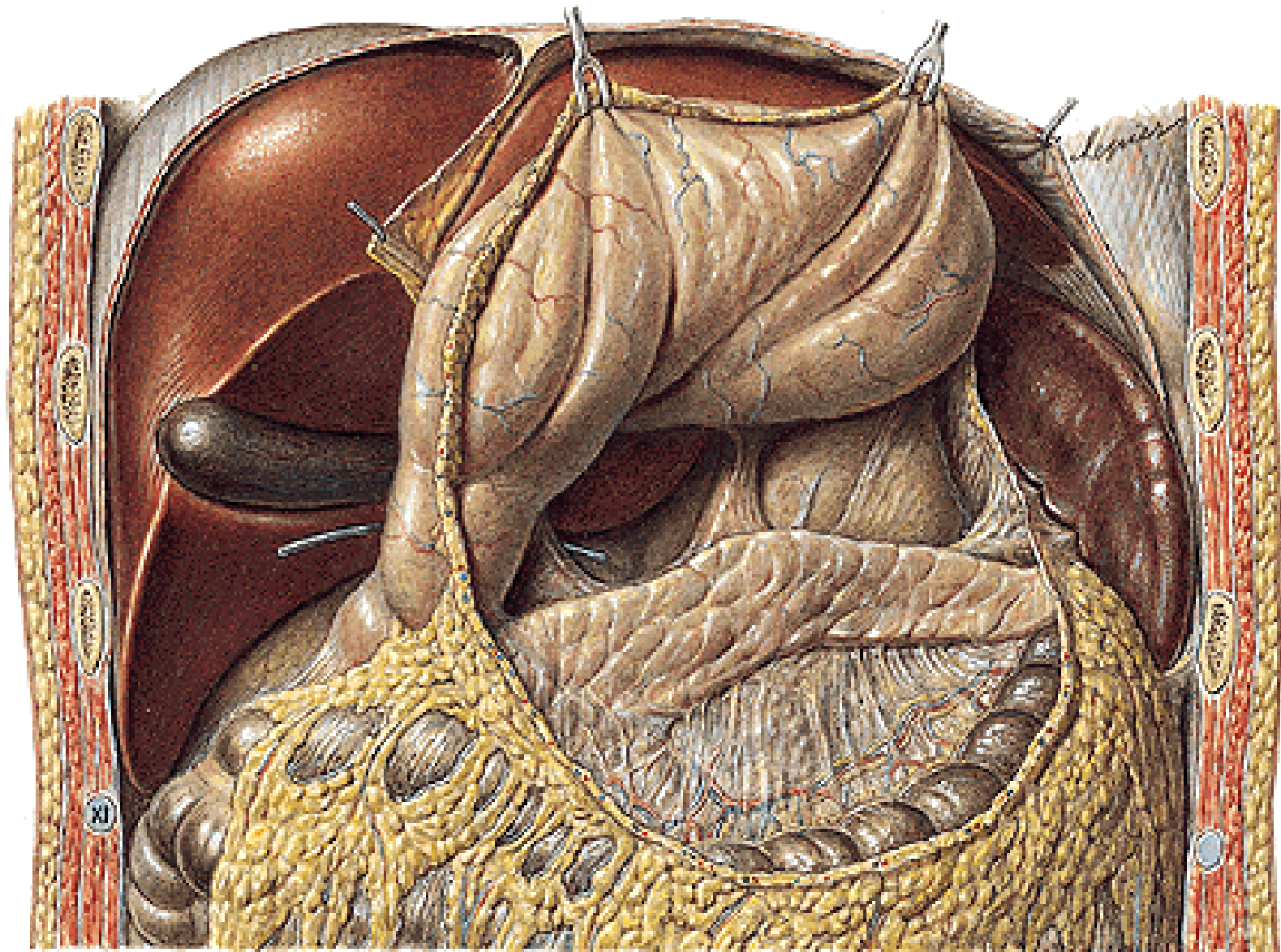
Pancreas in Situ



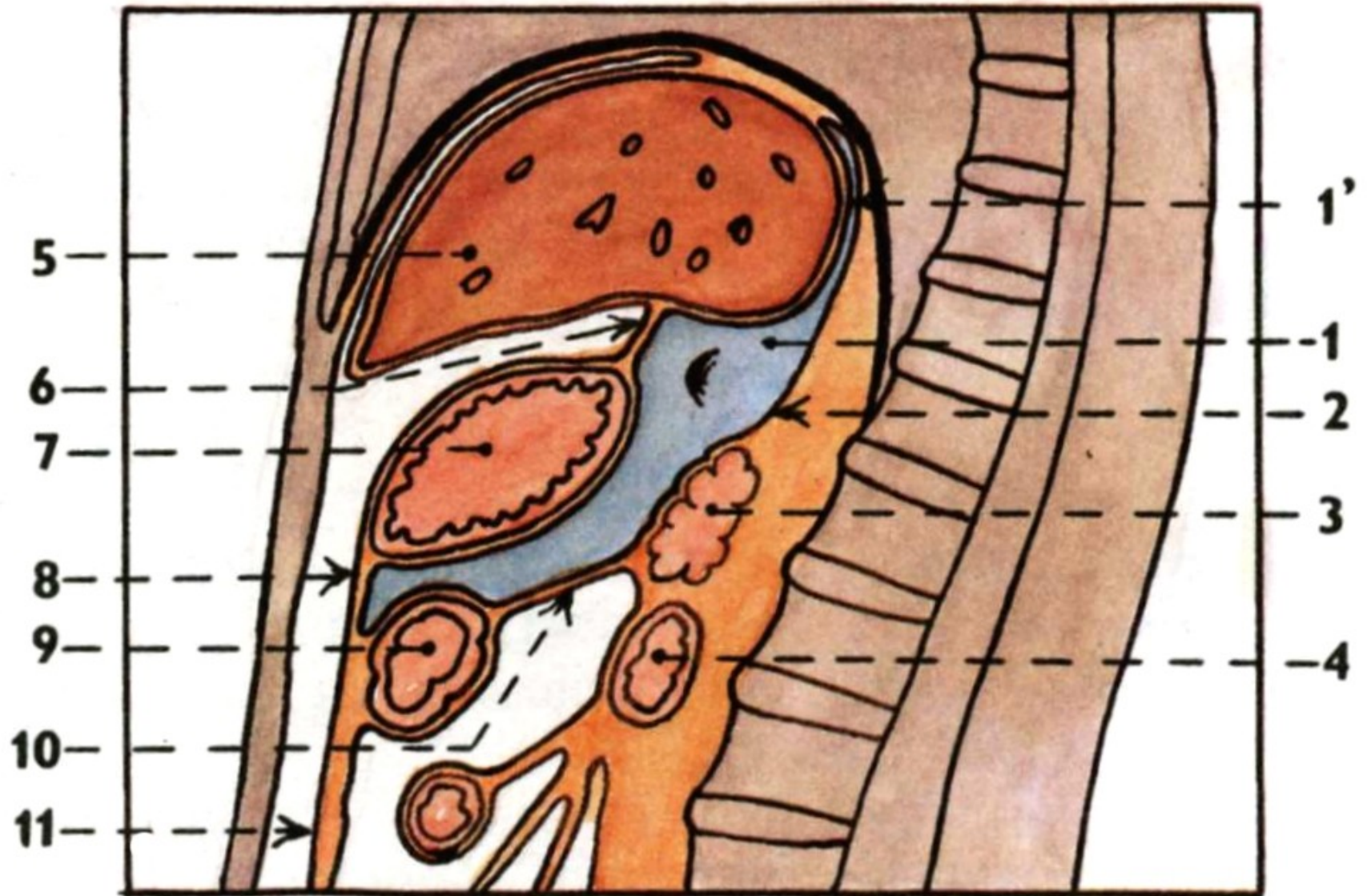
F. Netter M.D.
©Novartis

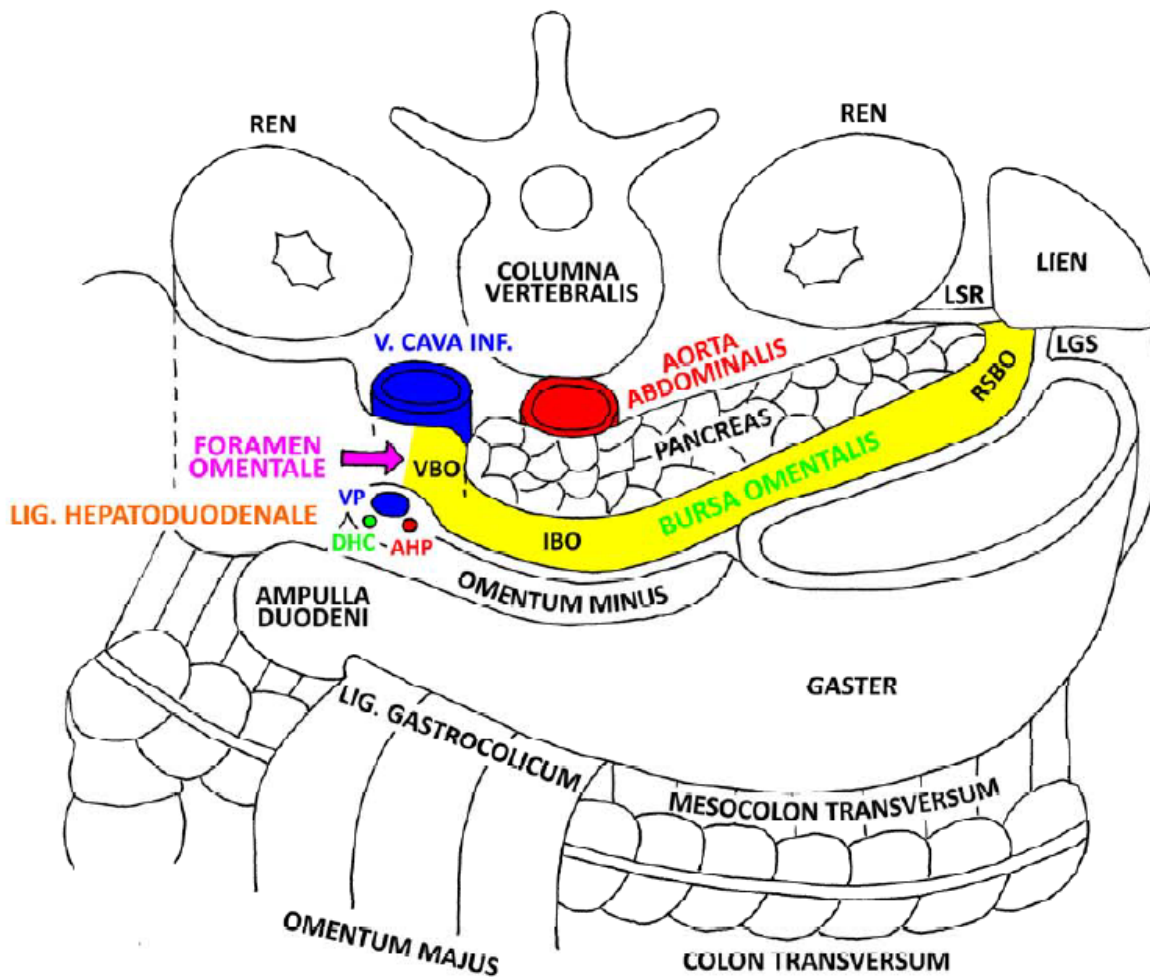
RECESSUS PERITONEI

Bursa omentalis



Bursa omentalis

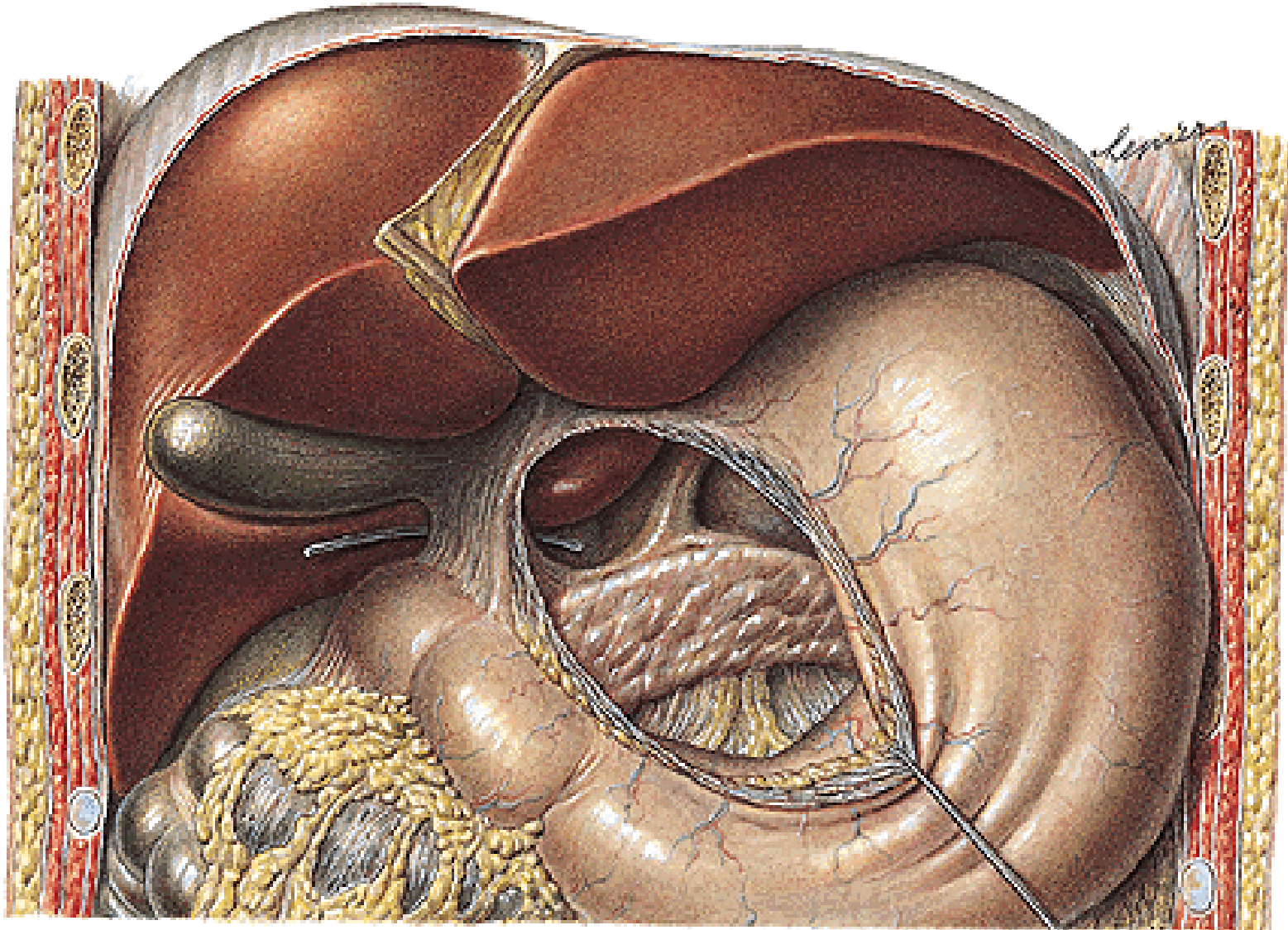




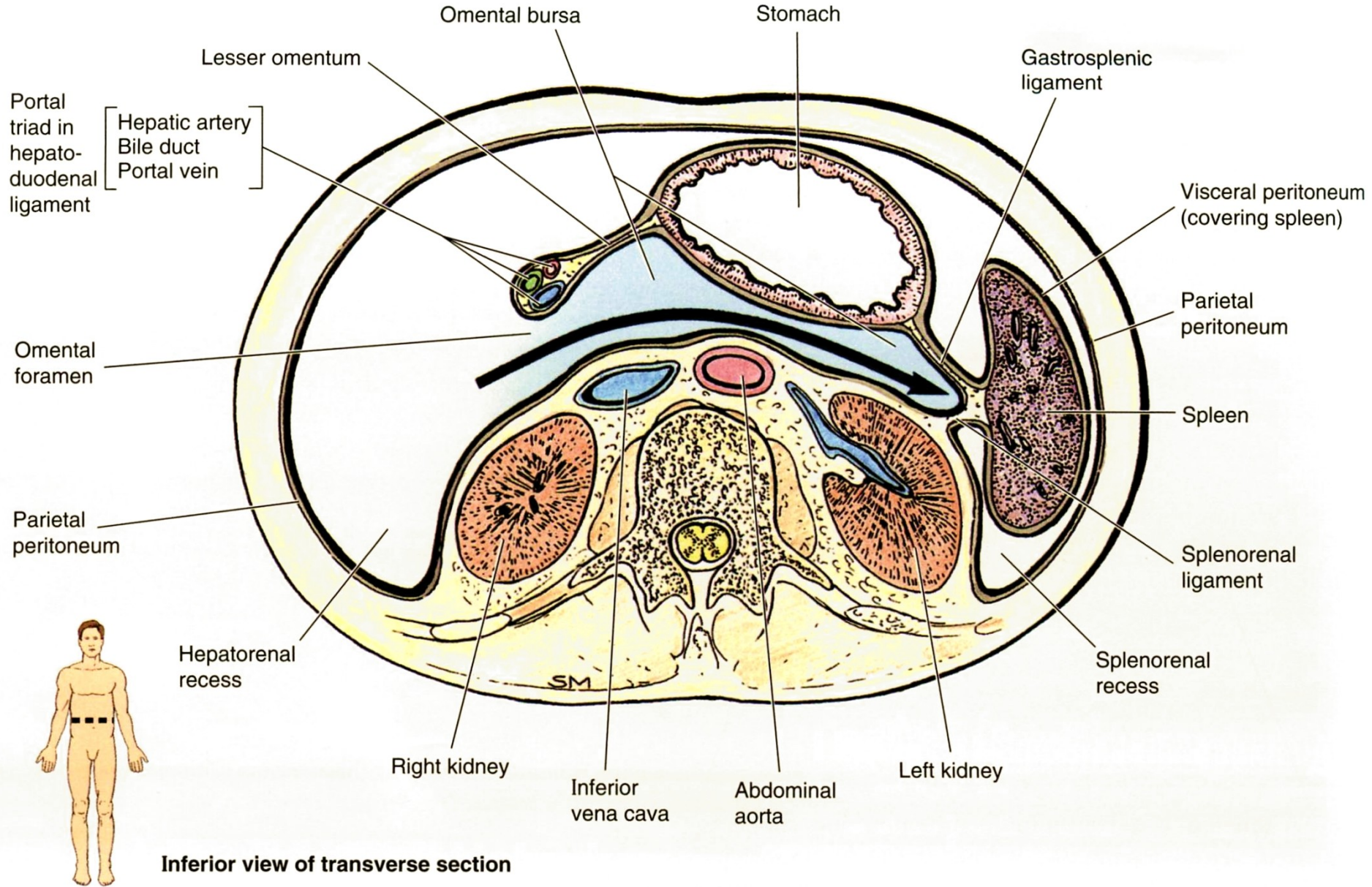
LSR - LIG. SPLENORENALE
 LGS - LIG. GASTROSPLENICUM
 RSBO - RECESSUS SPLENICUS BURSAE OMENTALIS
 IBO - ISTHMUS BURSAE OMENTALIS
 VBO - VESTIBULUM BURSAE OMENTALIS

VP - V. PORTAE
 DHC - DUCTUS HEPATICUS COMMUNIS
 AHP - A. HEPATICA PROPRIA

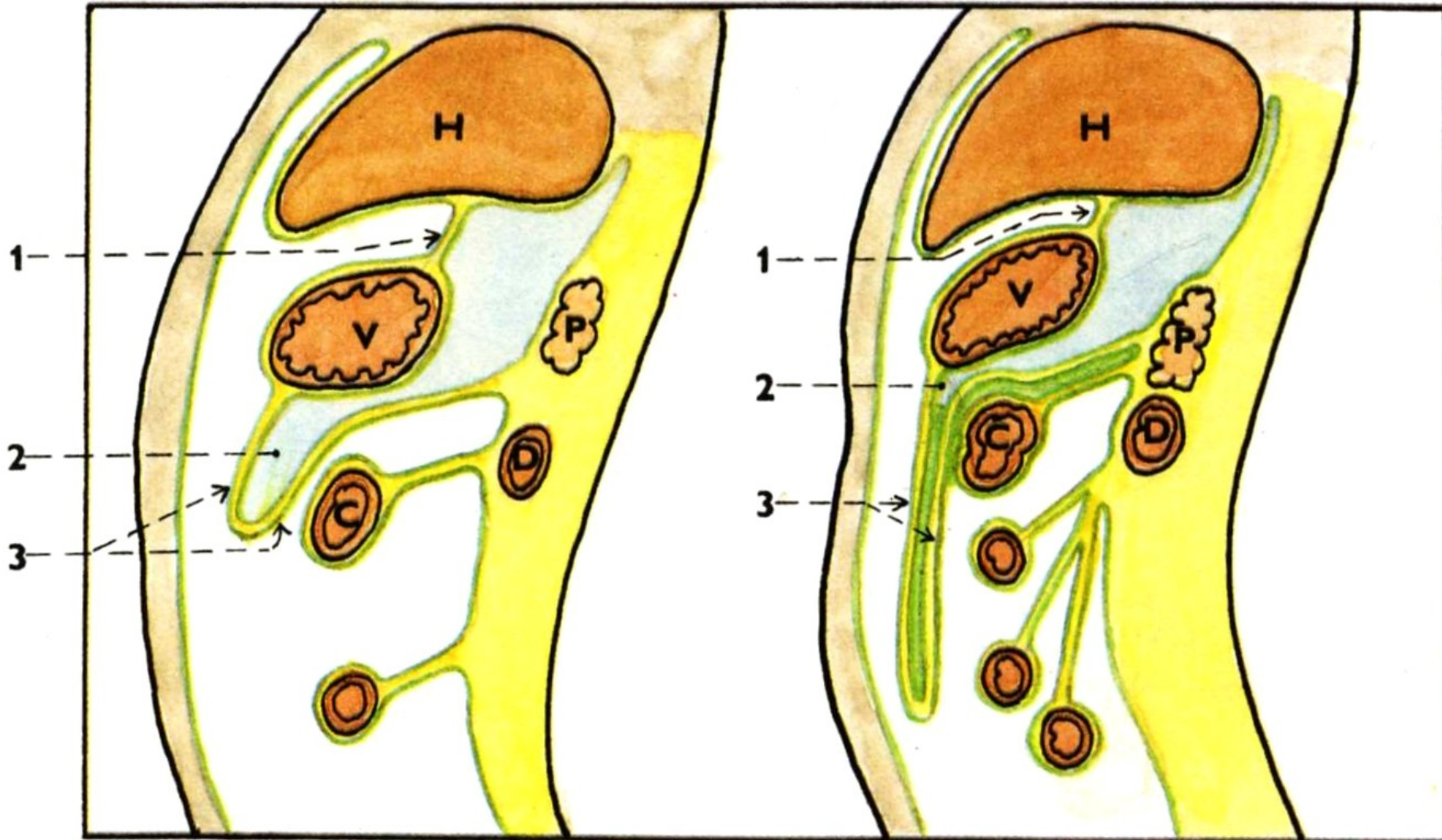
Foramen omentale/epiploicum (Winslow)
Recessus sup., splenicus, inf.



Abdominal Wall and Viscera

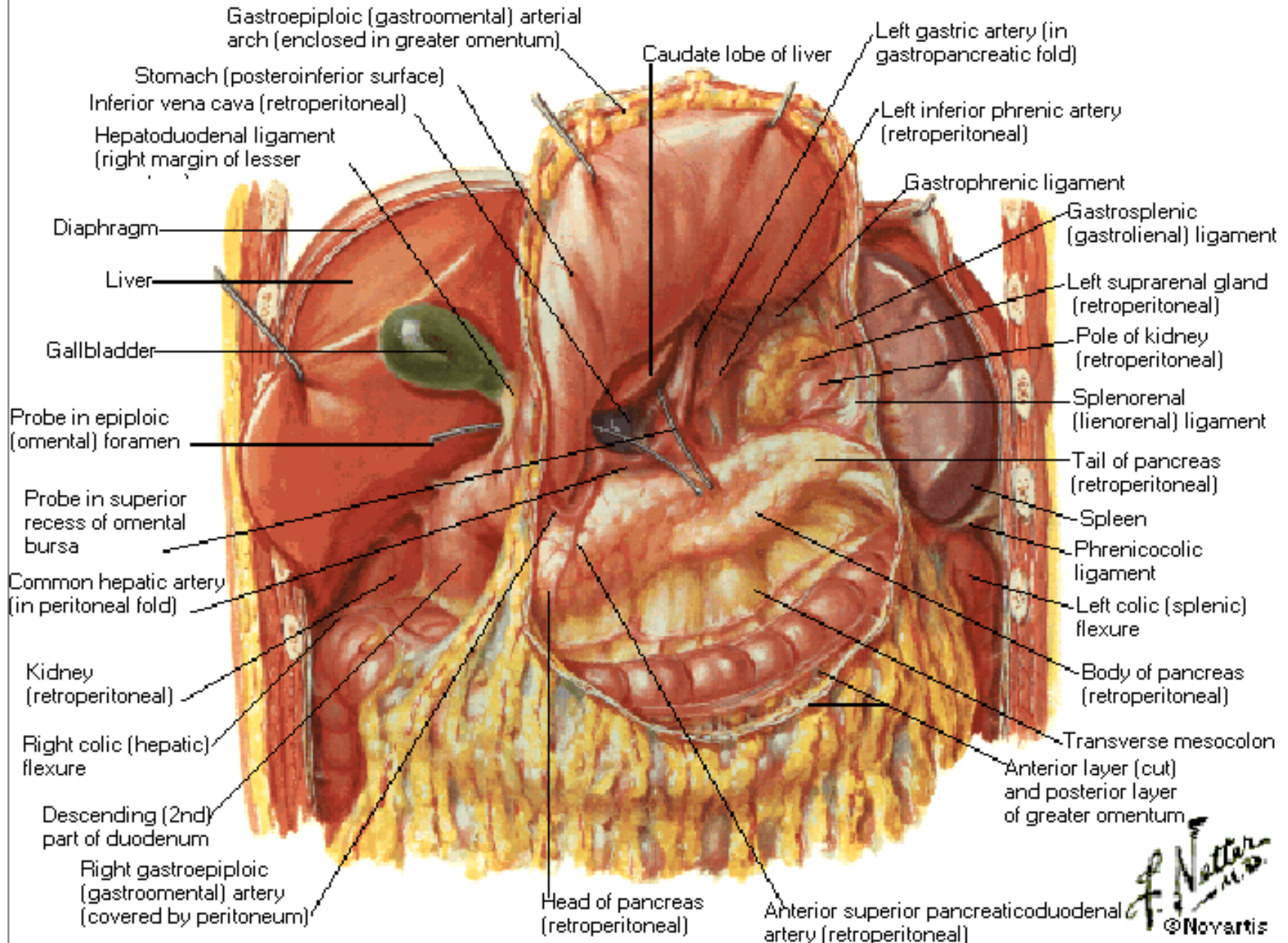


Recessus inferior bursae omentalis (2)



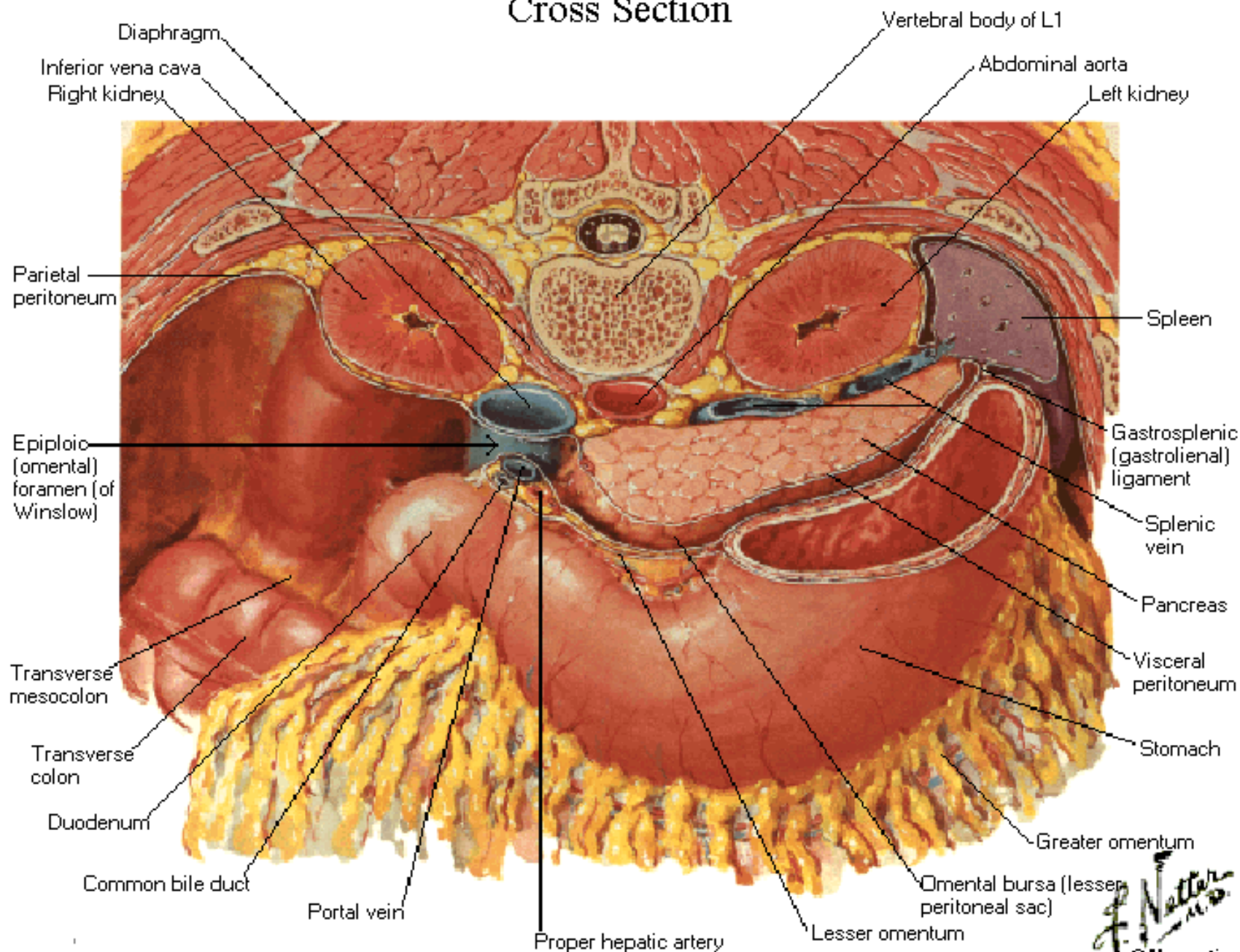
Omental Bursa

Stomach Reflected

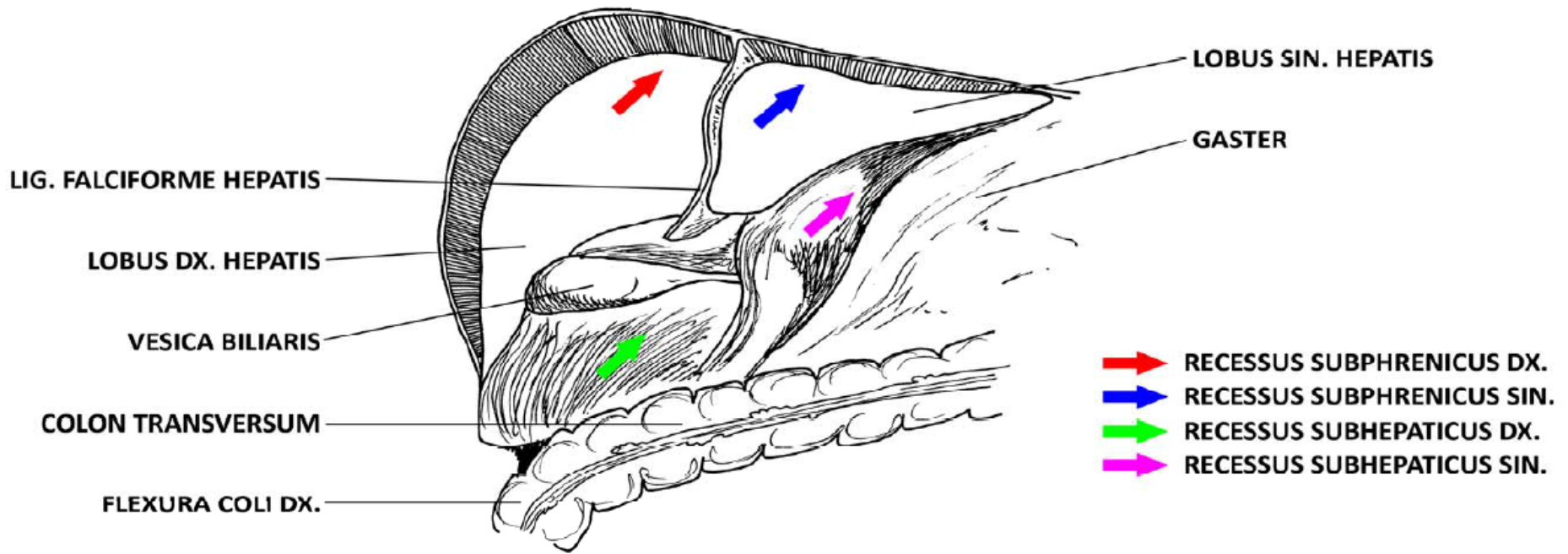


Omental Bursa

Cross Section



RECESSUS PERITONEALES

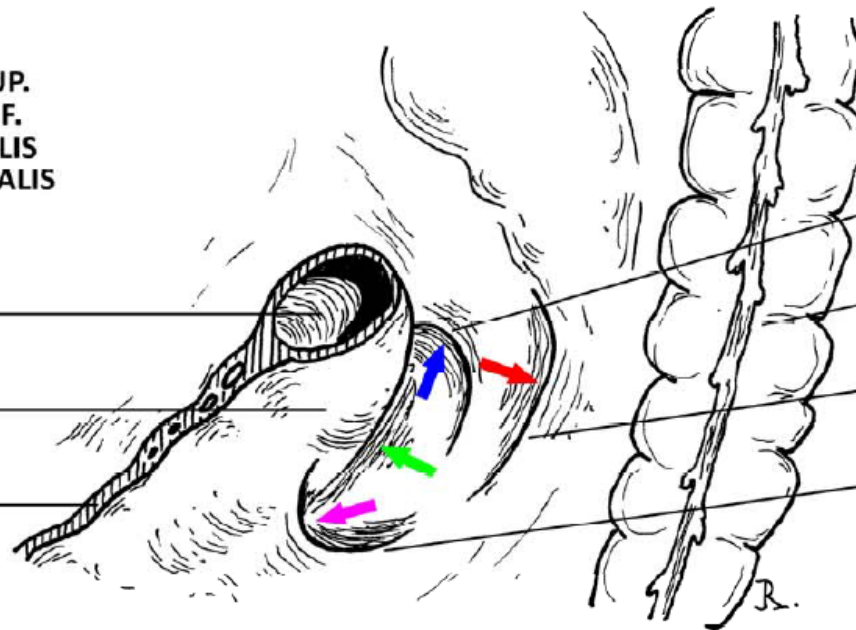


- ➔ RECESSUS DUODENALIS SUP.
- ➔ RECESSUS DUODENALIS INF.
- ➔ RECESSUS PARADUODENALIS
- ➔ RECESSUS RETRODUODENALIS

FLEXURA DUODENOJEJUNALIS

PARS ASCENDENS DUODENI

RADIX MESENTERII



PLICA DUODENALIS SUP.

COLON DESCENDENS

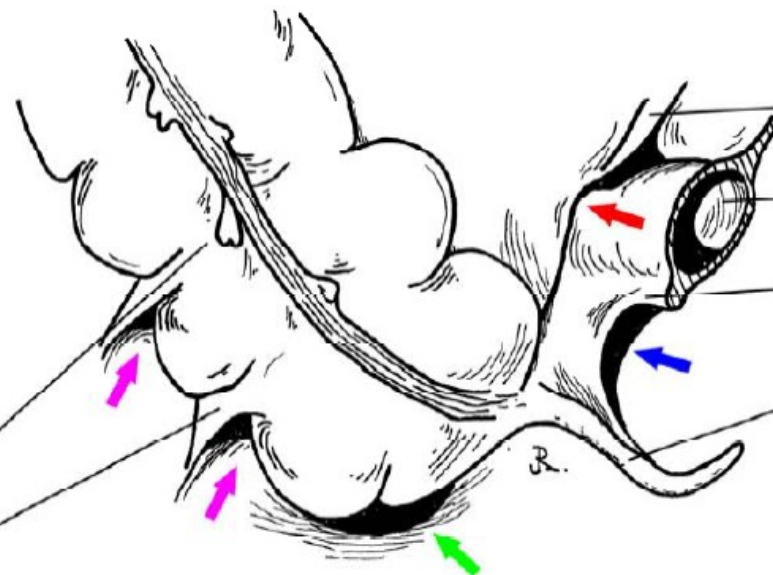
PLICA PARADUODENALIS

PLICA DUODENALIS INF.

- ➔ RECESSUS ILEOCAECALIS SUP.
- ➔ RECESSUS ILEOCAECALIS INF.
- ➔ RECESSUS RETROCAECALIS
- ➔ SULCI PARACOLICI

CAECUM

PLICA CAECALIS

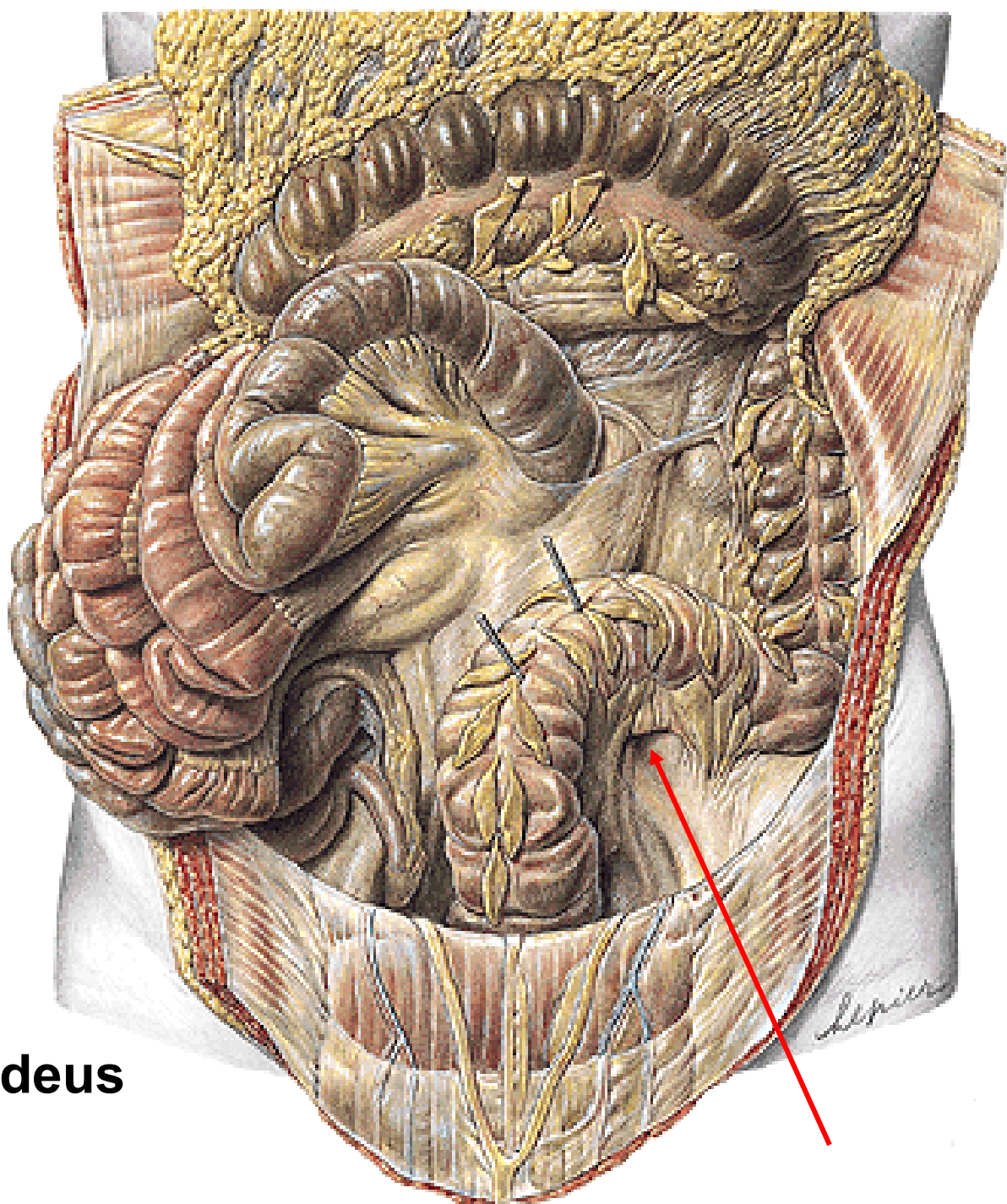


PLICA CAECALIS VASCULARIS

ILEUM

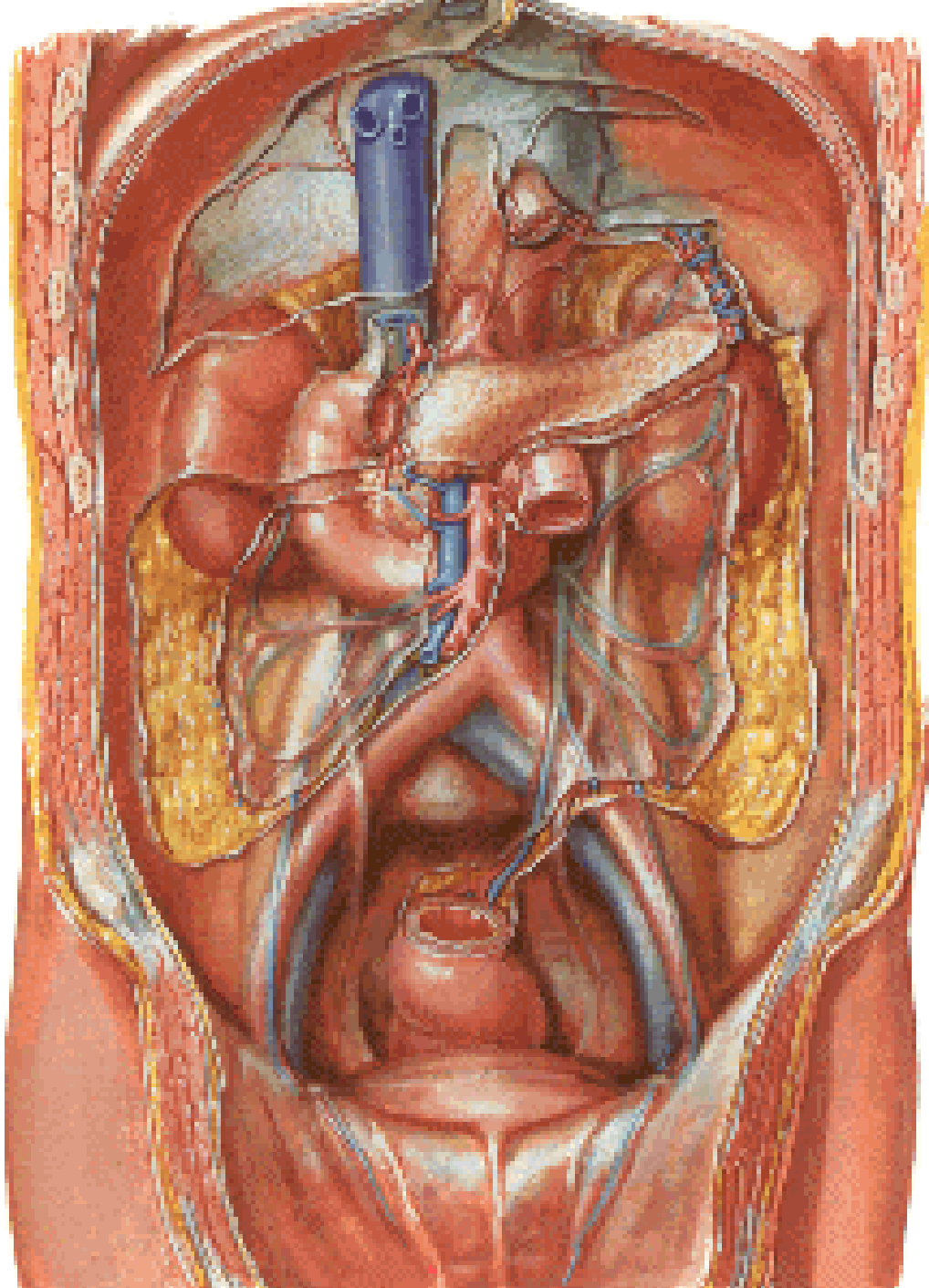
PLICA ILEOCAECALIS

APPENDIX VERMIFORMIS



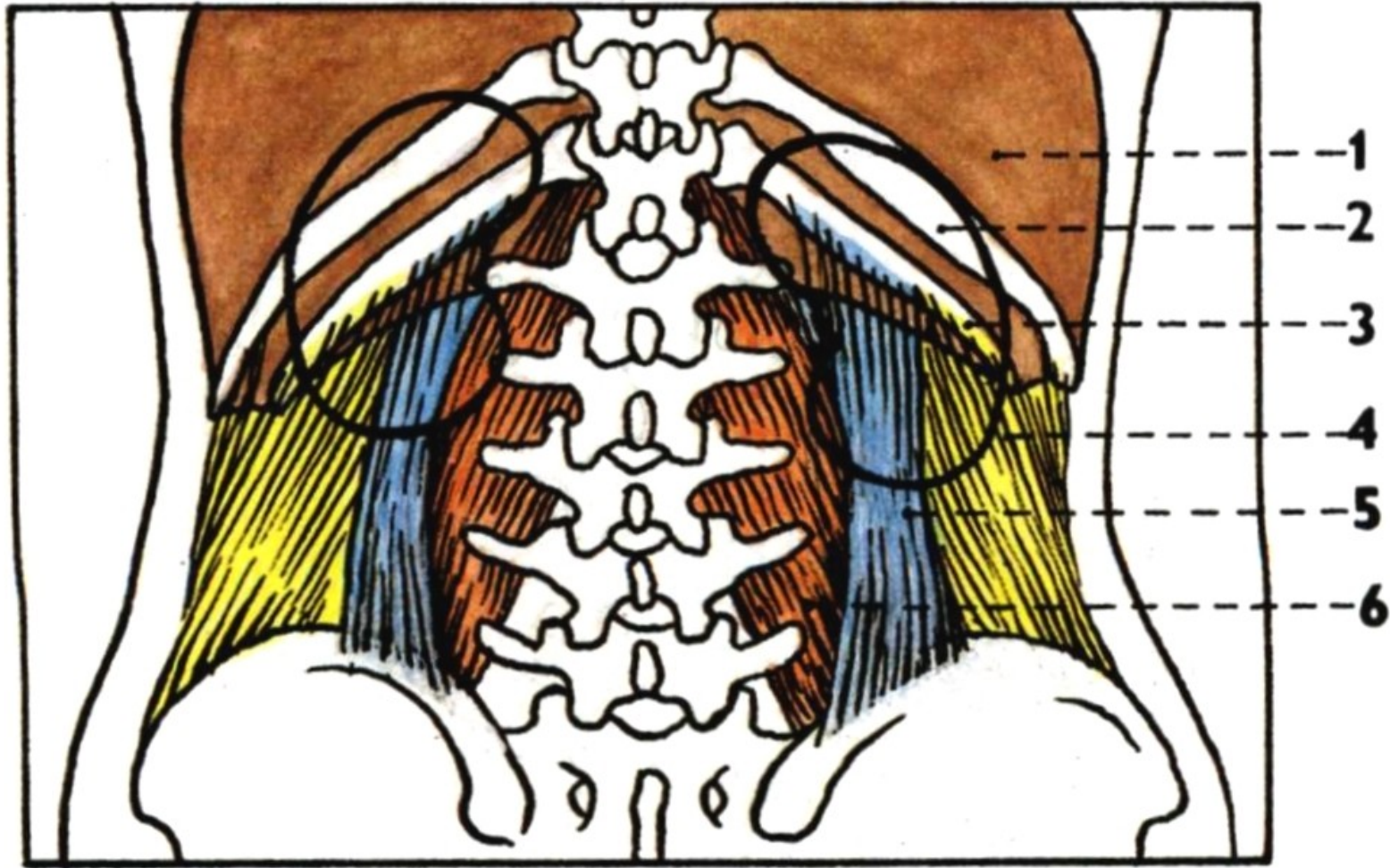
Recessus intersigmoideus

SPATIUM RETROPERITONEALE



- 1. diaphragma
- 2. 11th rib
- 3. 12th rib

- 4. m. transversus abdominis
- 5. m. quadratus lumborum
- 6. m. psoas major

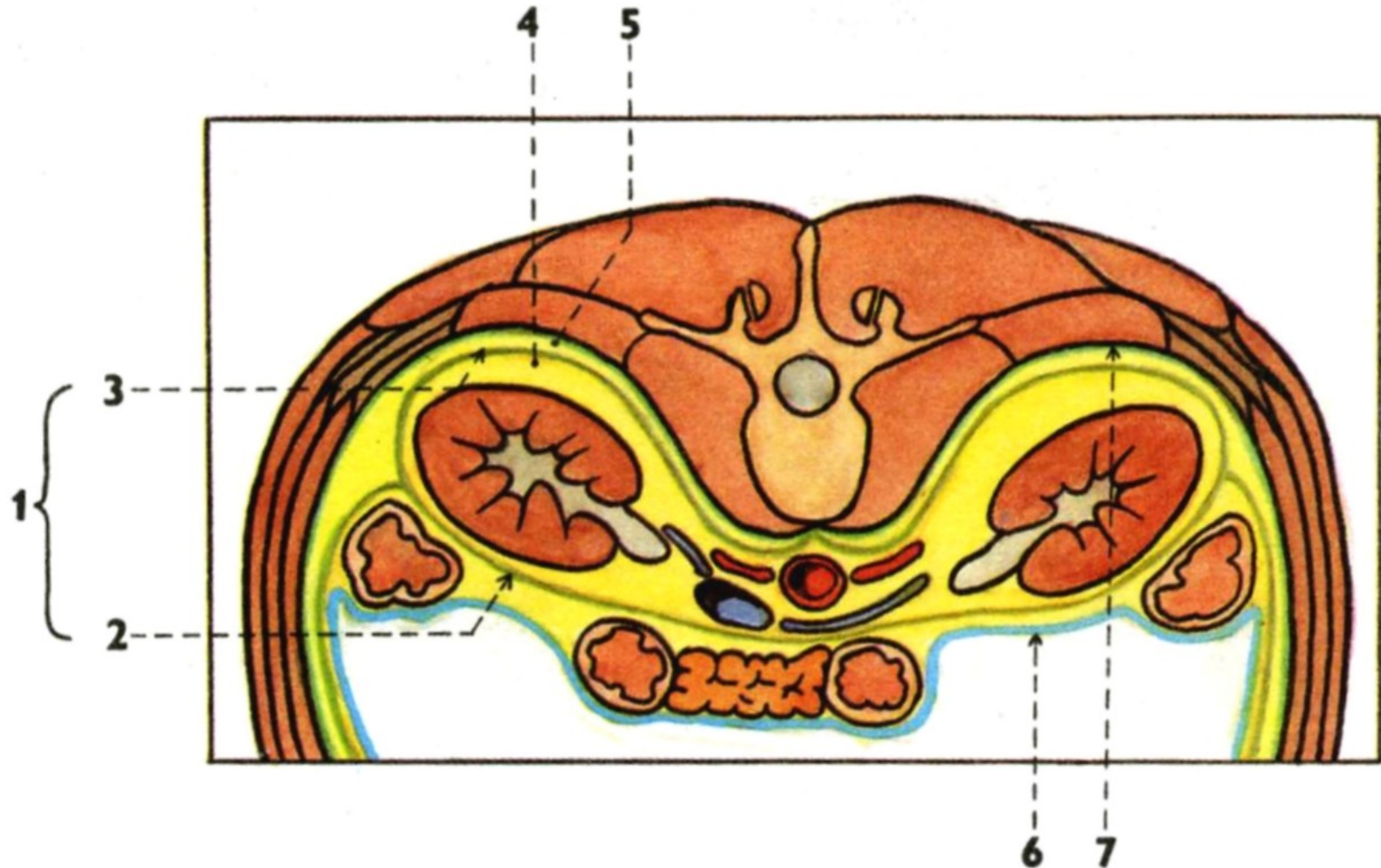


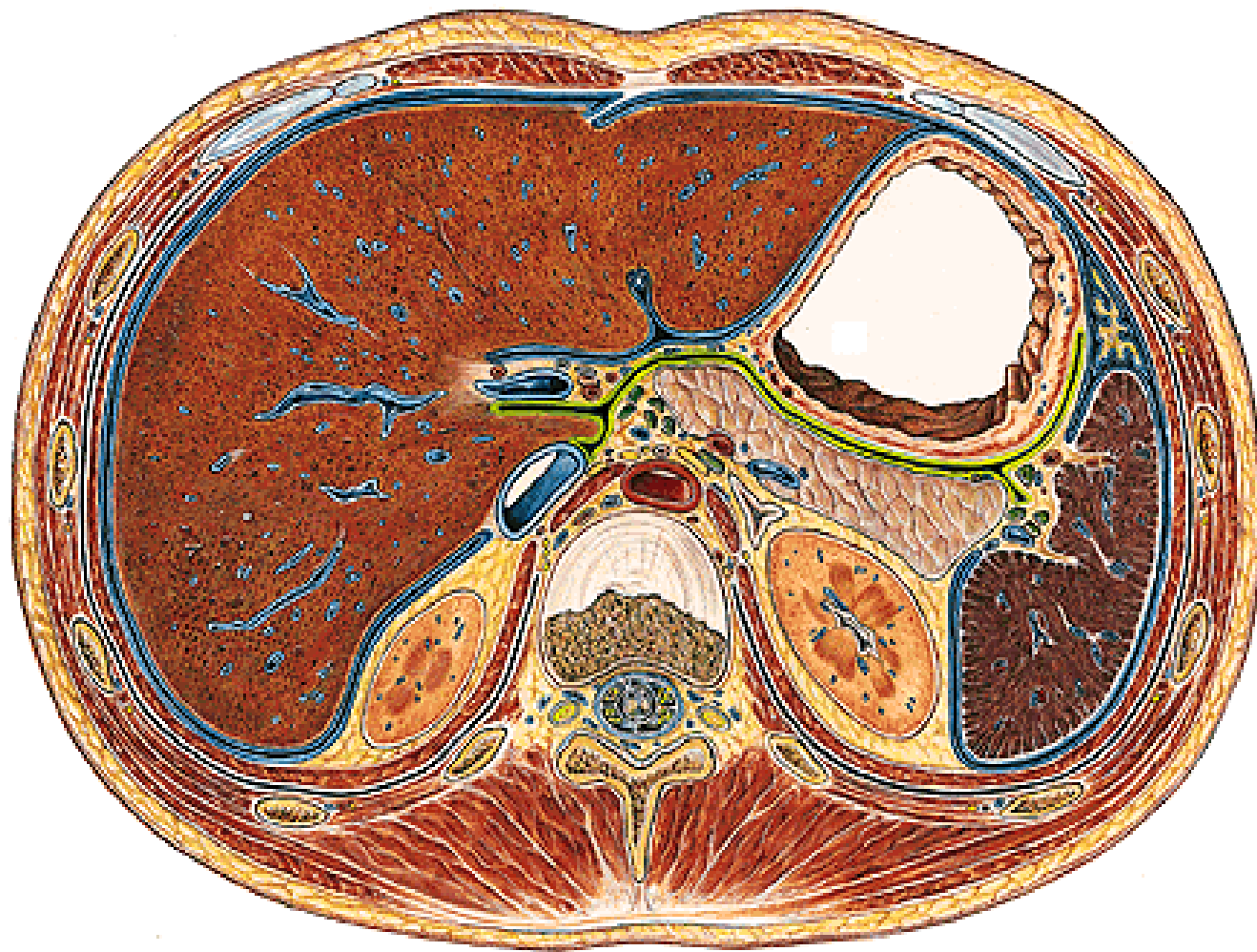
SIN.

DX.

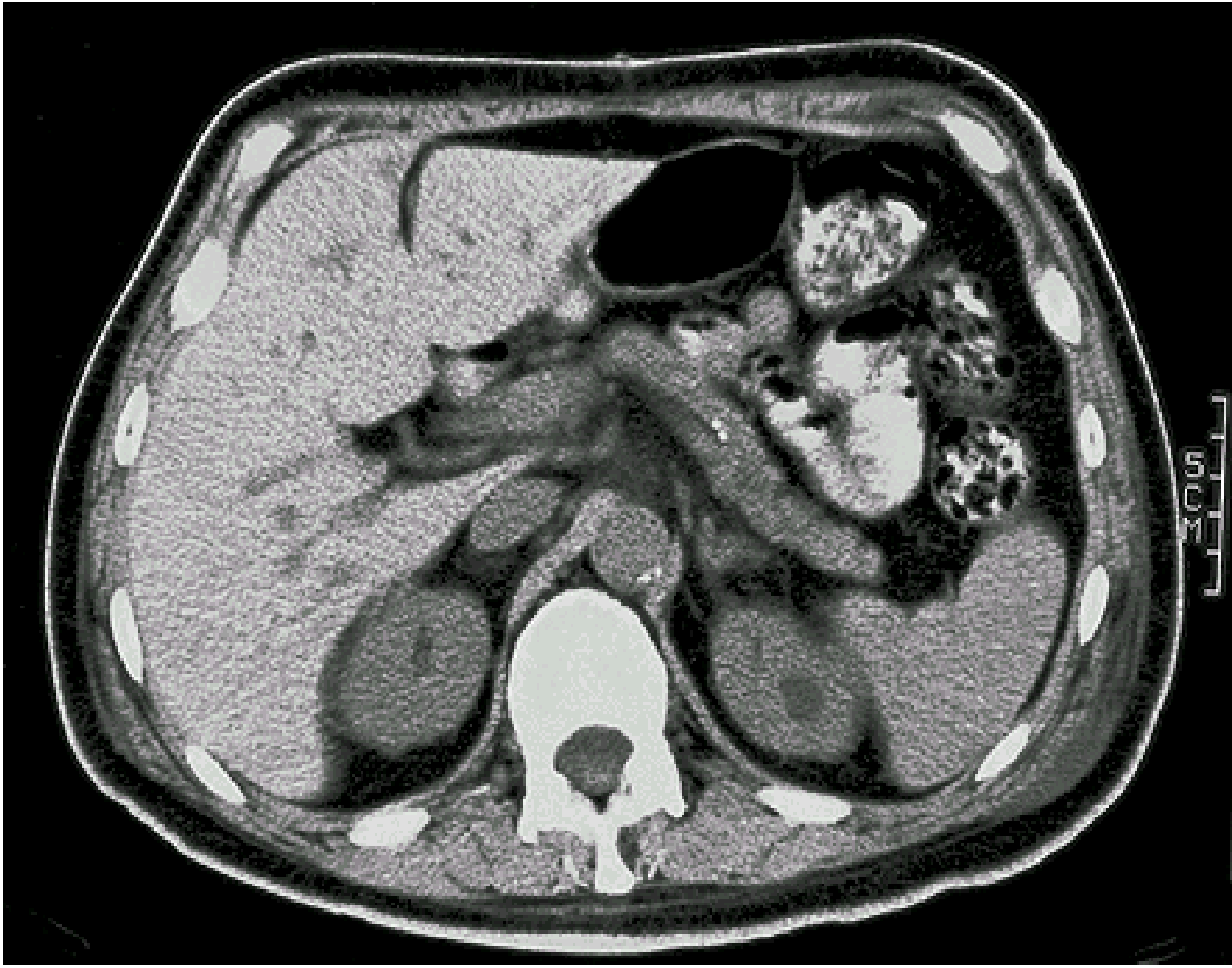
1. fascia renalis
2. lamina praerenalis
3. lamina retrorenalis
4. capsula adiposa

5. corpus adiposum pararenale
6. peritoneum
7. fascia transversalis





Th XII



Illustrations were copied from:

**Čihák R: Anatomie 2 (Splanchnologia). Avicenum,
zdravotnické nakladatelství, Praha, 1988.**

Atlas der Anatomie des Menschen/Sobotta.

Putz,R., und Pabst,R. 20. Auflage. München:

Urban & Schwarzenberg, 1993