

CHANGES AFTER DEATH

MUDr. Kateřina Stoklásková

Changes after death	early	late
physical	body cooling- algor mortis hypostasis- livor mortis desiccation diffusion of liquids and gases	mummification
chemical	autolysis stiffness- rigor mortis	putrefaction (decomposition) adipocere

Cessation of heartbeat and respiration

- traditionally, both the legal and medical communities determined death through the end of respiration and heartbeat
- but with the increasing ability of medicine to resuscitate patients, a need for better definition of death became obvious
- life support equipment can maintain body functions for a long time
- a demand for organ transplantation is rising

Patophysiology of death

It is conventional to describe two types of death:

Somatic death – the person is unconscious, unable to be aware of the environment, to communicate, unable to initiate any voluntary movement

- reflex nervous activity may persist, circulatory and respiratory functions continue either spontaneously or with artificial support

Cellular death – cells no longer function and have no metabolic activity

- it is a process- not an event- different tissues die at different rates, the cerebral cortex being vulnerable to only few minutes' anoxia, connective tissues surviving for many hours

Brain death

- equals somatic death
- the number of minutes for which total anoxia will cause cortical damage is estimated **8 minutes**
- hypothermia (e.g. immersion under water) reduces the oxygen needs of the tissues – even 40 minutes of hypoxia has been claimed as not leading to brain damage
- when the higher levels of cerebral activity are selectively lost (hypoxia, trauma, toxic insult), the victim will exist in **vegetative state** (coma vigile, apalic syndrome)
 - the victim can remain in deep coma certainly for years, is able to sustain circulation and respiration, control body temperature, excrete waste, heal wounds, gestate fetus

Terri Schiavo case

From Wikipedia, the free encyclopedia

The **Terri Schiavo case** was a legal struggle over *end-of-life care* in the *United States* from 1990 to 2005, involving Theresa Marie "Terri" Schiavo, a woman in an irreversible *persistent vegetative state*. Schiavo's husband and legal guardian argued that Schiavo would not have wanted prolonged artificial life support without the prospect of recovery, and elected to remove her *feeding tube*. Schiavo's parents argued in favor of continuing artificial nutrition and hydration and challenged Schiavo's medical diagnosis.^{[1][2]} The highly publicized and prolonged series of legal challenges presented by her parents, which ultimately involved state and federal politicians up to the level of *President George W. Bush*, caused a seven-year delay before Schiavo's feeding tube was ultimately removed.

Schiavo suffered a *cardiac arrest* in her *St. Petersburg, Florida*, home on February 25, 1990. She was resuscitated, but suffered massive *brain damage* due to *lack of oxygen to her brain* and was left *comatose*. After two and a half months without improvement, her diagnosis was changed to that of a *persistent vegetative state*. For the next two years doctors attempted speech and physical therapy and other experimental therapy, hoping to return her to a state of awareness, without success. In 1998 Schiavo's husband, Michael, petitioned the *Sixth Circuit Court of Florida* to remove her feeding tube pursuant to Florida law.^[3] He was opposed by Terri's parents, Robert and Mary Schindler, who argued that she was conscious. The court determined that Schiavo would not have wished to continue life-prolonging measures,^[4] and on April 24, 2001, her feeding tube was removed for the first time, only to be reinserted several days later. On February 25, 2005, a Pinellas County judge again ordered the removal of Terri Schiavo's feeding tube. Several appeals and federal government intervention followed, which included *U.S. President George W. Bush* returning to Washington D.C. to sign legislation designed to keep her alive. After appeals through the federal court system upheld the original decision to remove the feeding tube, staff at the *Pinellas Park* hospice facility disconnected the feeding tube on March 18, 2005, and Schiavo died on March 31, 2005.

Theresa Marie "Terri" Schiavo



Terri Schiavo with her mother, in 2001

Born	Theresa Marie Schindler December 3, 1963 Lower Moreland Township, Montgomery County, Pennsylvania, U.S.
Died	March 31, 2005 (aged 41) Pinellas Park, Florida, U.S.
Nationality	American
Occupation	Insurance clerk
Spouse(s)	Michael Schiavo (1984–2005; her death)
Parent(s)	Robert and Mary Schindler

1992: Hillsborough victim allowed to die

Doctors treating Hillsborough victim Tony Bland can disconnect feeding tubes keeping him alive, a judge at the High Court in London has ruled.

The president of the Family Division, Sir Stephen Brown, said there was no "reasonable possibility" that after three years Mr Bland would emerge from a coma known as a "persistent vegetative state" or PVS.

Mr Bland's parents, Allan and Barbara, supported the doctors' court action and said they were "relieved" at the ruling.

Tony Bland, 22, suffered severe brain damage when he and hundreds of other football supporters were crushed in an overcrowded stand at Hillsborough stadium in April 1989.

Ninety-five fans died in the disaster.

In the High Court Mr Bland's doctors at Airedale General Hospital, near Keighley in



Tony Bland was injured during the Hillsborough disaster

In Context

The Official Solicitor appealed the ruling all the way to House of Lords but in February 1993 the Law Lords ruled in favour of Tony Bland's doctors.

His life support machine was switched off on 22 February and he died on 3 March.

In April 1994 the High Court rejected an attempt by a pro-life campaigner, Father James Morrow, to get the doctor who withdrew food and drugs from Tony Bland charged with murder.

Up to October 2000 there had been 18 cases brought before the

case involved 14 appeals and numerous *motions*, petitions, and hearings in the Florida courts; five suits in *federal ve political intervention* at the levels of the Florida state legislature, then-governor *Jeb Bush*, the U.S. Congress, *Je W. Bush*; and four denials of *certiorari* from the *Supreme Court of the United States*.^[5] The case also spurred a from the *pro-life movement*, the *right-to-die* movement, and *disability rights* groups.^[6] Since Schiavo's death, and her family have written books on their sides of the case, and both have also been involved in activism over its larger issues.^{[7][8][9]}

t]

s born Theresa Marie Schindler on December 3, 1963, in *Lower Moreland Township, Montgomery County, Pennsylvania*, a suburb of *Philadelphia* throughout her childhood, as a teenager Terri stood 5' 3" (160 cm) tall and weighed 200 pounds (91 kg). She attended *Pinellas Park High School*. Through dieting she had lost 65 pounds (29 kg) by the time she attended college.^[10] She attended *Bucks County Community College*, where she met Michael Schiavo in 1982. The two began dating and were married on November 10, 1984. They moved to *Florida* and Terri's parents. Michael worked as a restaurant manager, while Terri took up a job with an insurance company.^[11]

I crisis: 1990 [edit]

On the evening of February 25, 1990, Terri Schiavo collapsed in a hallway of her *St. Petersburg, Florida*, apartment. Firefighters and paramedics responded to her husband Michael's 9-1-1 call found her face-down and unconscious. She was not breathing and had no *pulse*. They resuscitated her and she was transported to the Humana Northside Hospital. There, she was *intubated* and *ventilated*.^[12]

http://news.bbc.co.uk/onthisday/hi/dates/stories/november/19/newsid_2520000/2520581.stm
https://en.wikipedia.org/wiki/Terri_Schiavo_case

Žena po autonehodě zůstala v kómatu, přesto porodila zdravé dítě

9. února 2016 18:13    

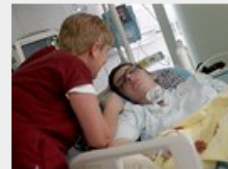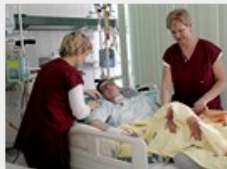V brněnské fakultní nemocnici si připsali unikátní lékařský úspěch. Těhotná žena, která byla po autohavárii tři měsíce v kómatu, tam porodila zdravého chlapečka. Podobné případy se šťastným koncem se počítají pouze na desítky v celém světě.



Třiatřicetiletá [žena](#), úspěšná manažerka nábytkářského řetězce, čekala svoje první dítě. Po vážné autonehodě u Jihlavy ji přivezla sanitka do brněnské nemocnice loni na konci října. „Utrpěla těžká poranění krční páteře a hlavy. Byla ale tehdy na začátku pátého měsíce těhotenství a dítěte se havárie nijak nedotkla. Rozhodli jsme se tedy těhotenství udržet co nejdéle,“ popsala Dagmar Seidlová, primářka anesteziologicko-resuscitačního oddělení fakultní nemocnice.

Na tři týdny proto lékaři uvedli ženu do umělého spánku, aby se mohl mozek lépe uzdravit. Když ji ale začali probouzet, ukázalo se, že nereaguje na žádné podněty a je ve vegetativním stavu, tedy bdělém kómatu. Jak ale dítě v děloze rostlo, organismus ženy strádal stále víc. Na začátku osmého měsíce těhotenství se proto lékaři rozhodli pro císařský řez. Rozhodnutí musel tým, který o ženu pečoval udělat narychlo. Donutila jej k tomu infekce, která začala ohrožovat dítě.

Fotogalerie



„Dvoukilový chlapeček se narodil zdravý, měl ale nezralé plíce, takže musel být zpočátku připojený na umělou [ventilaci](#),“ vysvětlil Ivo Borek, primář neonatologického oddělení brněnské porodnice.

Po měsíci v lékařské [péči](#) si jej mohla především odvézt rodina domů.

http://brno.idnes.cz/zena-porodila-v-komatu-0be-/brno-zpravy.aspx?c=A160209_164845_brno-zpravy_zde

Brainstem death

- it is another matter when the brain death spreads below the tentorium (midbrain, pons, upper medulla) – the victim is not only irreversibly comatose, but also incapable of spontaneous breathing
- without medical intervention, hypoxic cardiac arrest inevitably follows within minutes and then the usual progression of cellular death ensues

Diagnosis of brain death

- **panangiography, cerebral blood flow and echo-doppler-** can prove the death of “higher brain”, but not the brain stem
- irreversible brain stem dysfunction is diagnosed using **ABR** (auditory brain stem responses) and **SEP** (short latency somatosensory potentials)
- **EEG-** *in the United States a flat EEG test is not required to certify death, it is considered to have confirmatory value. In the UK it is not considered to be of value.*

dead...or not?

- vita minima- apparent death- hypnotics overdose, electricity injury, lightning strike, coma, drowning
- agony- vita reducta- the struggle that precedes death

- Uncertain signs of death- paleness, no pulse, no blood pressure, areflexia
- Certain signs of death- livores mortis, rigor mortis, putrefaction, ...

Body Cooling – Algor Mortis

- the rate of cooling is proportional to the difference in temperature between the body surface and its surroundings
- the ideal cooling curve would be exponential, but it is not in the real human body
- estimation of the time of death is complicated, there are many factors affecting cooling of the body:
 - initial body temperature (fever, hypotermia, diurnal variation, physical activity, ...)
 - body size (obesity, children)
 - body posture
 - clothing and coverings
 - **ambient temperature**
 - air movement and humidity
 - air x water

Body Cooling

- roughly the decrease in temperature is $1^{\circ}\text{C}/\text{hour}$, but without considering all the factors affecting cooling, this is highly inaccurate

Hypostasis

- hypostasis occurs when the circulation ceases and the gravity acts upon the stagnant blood and pulls it down to the lowest accessible areas
- **bluish red** discoloration begins as blotchy patches which soon coalesce, the color depending on the state of oxygenation at death
 - **darker tint** is a result of reduced haemoglobin in skin vessels – asphyxia
 - **pink or dark red** in hypothermia
 - **cherry pink** color of carboxyhaemoglobin in carbon monoxide poisoning
- pattern of hypostasis depends on the posture of the body after death
- pale areas are the result of pressure against a hard supporting surface
- hypostasis may start forming after **30 minutes**, reaches maximum within **8-12 hours**
- does not have much value for estimation of the time since death – in some cases may not be visible at all (infants, old people, anaemia, bleeding out...), in some cases it can be observed in the living if the heart action is failing

Hypostasis

Once hypostasis is established, it can undergo subsequent gravitational shift – if the body is moved into a different posture, the primary hypostasis may either:

- move completely to the newly lowest areas – can be examined by thumb pressure
- be partly relocated and partly fixed
- remain fixed due to staining of the tissues by haemolysis

Hypostasis

- blood also settles in the internal tissues and organs
- differentiation between hypostasis and bruising – the classic test is to incise the suspect area to see if the underlying blood is intravascular (hypostasis) or infiltrating the tissues outside the vessels (contusion), histological examination may be necessary

Desiccation

- caused by evaporation of fluids from the body's naturally wet regions (eyes, lips, genitals) or wounds

Autolysis

- cellular lysosomes disintegrate and hydrolases are released, which break down cells and cellular membranes
- starts in pancreas, stomach mucosa

Diffusion of liquids and gases

- result of autolysis
- natural barriers do not function anymore and liquids and gases spread freely through the tissues

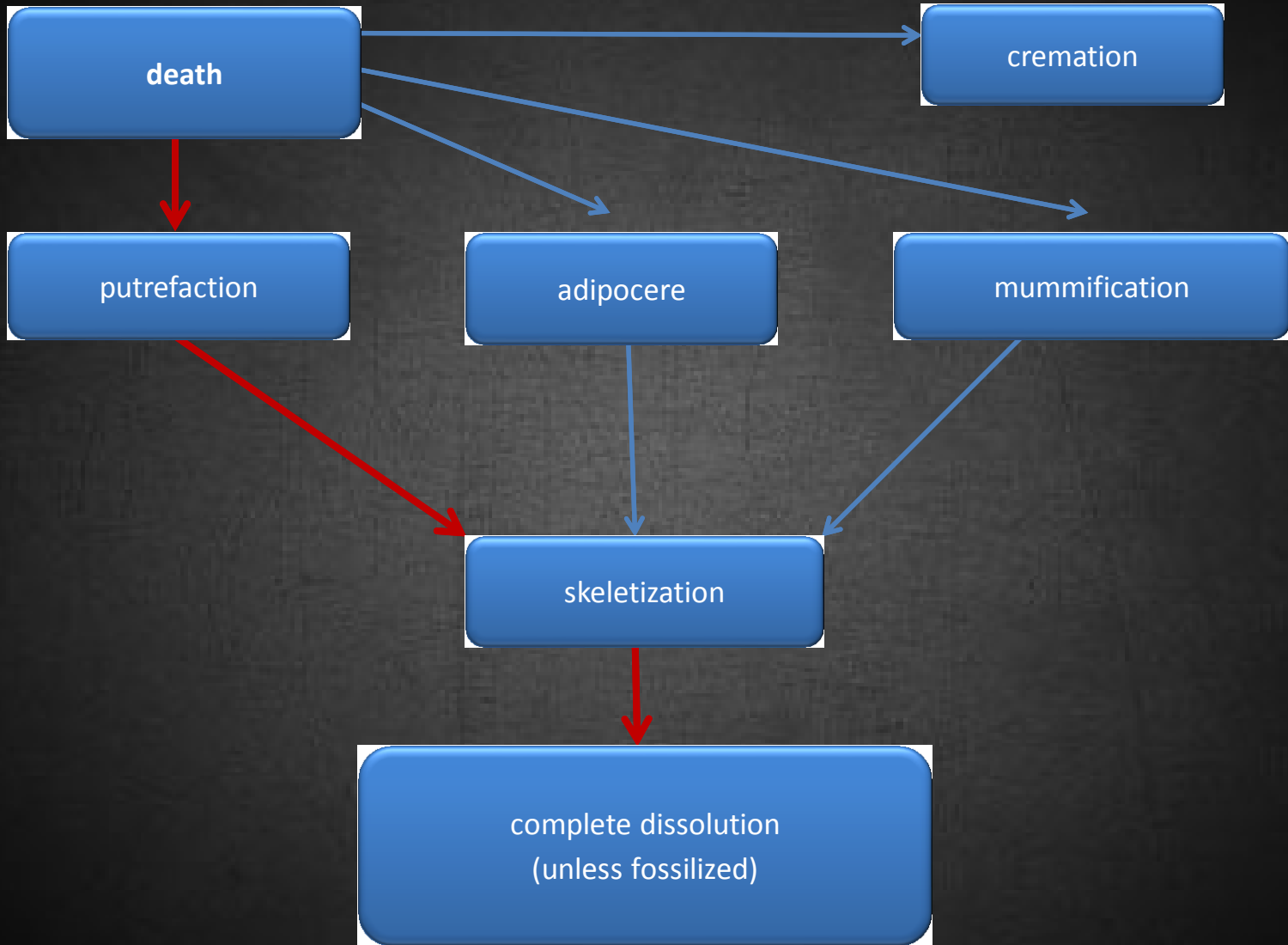
Rigor mortis

- immediately after death there is general muscular flaccidity, usually followed by a period of partial or total rigidity, which in turn passes off as the signs of decomposition appear
- rigor is initiated when the ATP concentration falls to 85 % of normal
- stiffness may start developing within **30 minutes** or may be postponed almost indefinitely (physical activity before death, electrocution X freezing)
 - reaches maximum within 6-12 hours
 - duration of full rigor may be 18-36 hours
- rigor is first apparent in the smaller muscle groups – jaw, facial muscles, neck
- fades in the same order of muscle groups as it appeared
- rigor can be “broken” during manipulation with the body
- rigor mortis in other tissues – iris, heart, dartos muscle, seminal vesicles, prostate, erector pili muscles
- poorly developed in infants, elderly, cachectic
- **cadaveric spasm** – a rare form of virtually instantaneous rigor that develops at the time of death with no period of post-mortem flaccidity (soldiers, falling from height)

A rough estimation of the post-mortem interval in average condition (18°C):

the body is:

- warm and flaccid – less than 3 hours
- warm and stiff – 3-8 hours
- cold and stiff – 8-36 hours
- cold and flaccid – more than 36 hours



Putrefaction (decomposition)

- onset depends on the environment, but in average conditions the putrefaction starts after approximately **3 days**
- first external naked-eye sign is discoloration of the lower abdominal wall (caecum)

1 week

- the color of the skin is green/ black/ reddish
- putrefactive bacteria spread through the venous system, hemolyze the blood and stain the vessels and adjacent tissues greenish-black
- the face and other soft tissues become swollen and pervaded by fluid and gas

2-3 weeks

- skin blisters appear, filled with clear, pink or red fluid
- later the skin starts peeling off, the hair and nails detach
- the scrotum and breasts are swollen
- bloody fluid (tissue liquefaction stained by haemolysis) leaks from body orifices

several months

- soft tissues disintegrate, leaving ligamentous and tendineous tissues attached to skeleton

Forensic Entomology

- animal, especially insect infestation depends on the ambient temperature and environment

Decomposition in immersed bodies

- the rate of decomposition is slower- approximately twice compared to decomposition in air
- water slows down putrefaction mainly because of the lower ambient temperature and protection from insect
- the epidermis becomes macerated and eventually detached
- gas formation is the reason for flotation of an unweighted body
- the usual posture of a freely floating body is face down

Decomposition in buried bodies

- the rate of decay of bodies buried in earth is much slower than those in either air (approximately eight times) or water- due to lower temperature, exclusion of animal and insect predators and lack of oxygen
- after **10 years** only bones should be found in the grave

...unless...

Adipocere

- the body tissues transform into a waxy substance derived from the body fat
- caused by hydrolysis and hydrogenation of adipose tissue by anaerobic bacteria (fatty acids + K, Na, Ca, Mg ions)
- the tissues are greasy or waxy, later brittle and chalky, white, pinkish, greenish or grey
- requires MOISTURE (usually wet soil or water), usually warmth and alcalic pH
- adipocere starts forming after approximately 3 months

Mummification

- dried out body, usually only some body parts (fingers, toes, ears, nose)
- the skin is dry, hard, brown
- secondary colonization by moulds causes white, green or black patches on the skin
- can only occur in a **DRY** environment, preferably with moving air current, which is usually also warm
- mummification can take weeks or months, depending on the environment

Damage caused by animals after death

- there is no bleeding, oedema or reddening of the edges of the wound, no other vital signs of injuries

References: Knight's Forensic Pathology, 2004