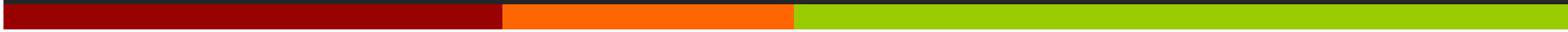



# Comparison of adjectives

Unit 8, Tasks 1-5



**1. SUPERIOR OR SUPERIUS?****MAIOR OR MAIUS?****ANTERIOR OR ANTERIUS?**

Vena cava

superior

Cornu

maius

Arteria

anterior

Membrum

superius

Ductus

maior

Ductus

anterior

Extremitas

superior

Ala

maior

Segmentum

anterius

Palpebra

superior

Musculus

maior

Margo

anterior

Labium

superius

Curvatura

maior

Bronchus

anterior

Facies

superior

Flexura

maior

Nucleus

anterior

Meatus

superior

Fossa

maior

Cornu

anterius

Arteria

superior

Foramen

maius

Nodus

anterior

Plexus

superior

Tuberculum

maius

Tuberculum

anterius

Segmentum

superius

Circulatio

maior

Radix

anterior

Regio

superior

Pelvis

maior

Crus

anterius

## 2. FORM PHRASES WITH COMPARATIVES/GIVE THE OPPOSITE

/TRANSFORM INTO ABLATIVE WITH PREPOSITION **IN**

Labium (superior)

\_\_\_\_\_

\_\_\_\_\_

Membra (inferior)

\_\_\_\_\_

\_\_\_\_\_

Tubercula (minor)

\_\_\_\_\_

\_\_\_\_\_

Circulatio (maior)

\_\_\_\_\_

\_\_\_\_\_

Dosis (maximus)

\_\_\_\_\_

\_\_\_\_\_

Partes (posterior)

\_\_\_\_\_

\_\_\_\_\_

Parietes (anterior)

\_\_\_\_\_

\_\_\_\_\_

Foramen (maior)

\_\_\_\_\_

\_\_\_\_\_

### 3. GIVE COMPARATIVES AND SUPERLATIVES

Musculus longus

m. longior

m. longissimus

Cavitas parva

c. minor

c. minima

Radix lata

r. latior

r. latissima

Defectus magnus

d. major

d. maximus

Gradus parvus

g. minor

g. minimus

Operatio acuta

o. acutior

o. acutissima

Foramen parvum

f. minus

f. minimum

Pulsus frequens

p. frequentior

p. frequentissimus

Os breve

o. brevius

s. brevissimum

Pars mollis

p. mollior

p. mollissima

Therapia longa

t. longior

t. longissima

Inferctus recens

i. recentior

i. recentissimus

#### 4. PUT COMPARATIVES AND SUPERLATIVES INTO THE PLURAL

Musculi longi

longiores

longissimi

Cavitates parvae

minores

minimae

Radices latae

latiores

latissimae

Defectus magni

majores

maximi

Gradus parvi

minores

minimi

O-tiones acutae

acutiores

acutissimae

Foramina parva

minora

minima

Infarctus recentes

recentiores

recentissimi

Ossa brevia

breviora

brevissima

Partes molles

molliores

mollissimae

Therapiae longae

longiores

longissimae

## 5. GIVE THE OPPOSITE



Meatus superior

inferior

Gradus minor

major

Phalanx proximalis

distalis

Segmentum anterius

posterius

Arteria suprema

infima/ima

Anomalia minima

maxima

Pars externa

interna

Pulsus durus

mollis

## 6. ADD WHAT IS MISSING



M. supraspinatus



M. infraspinatus



M. teres minor



M. teres major

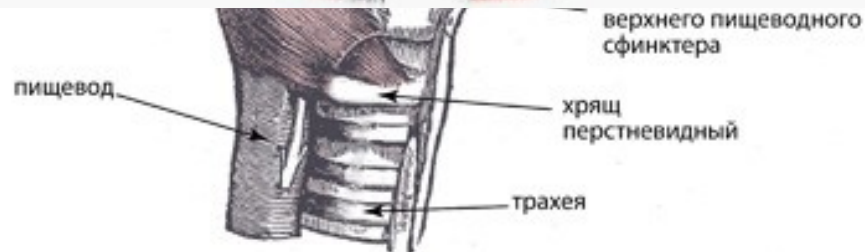


N. radialis= N. cutaneus brach.



Muscu

пищевод



Tuberculum majus

N. axillaris

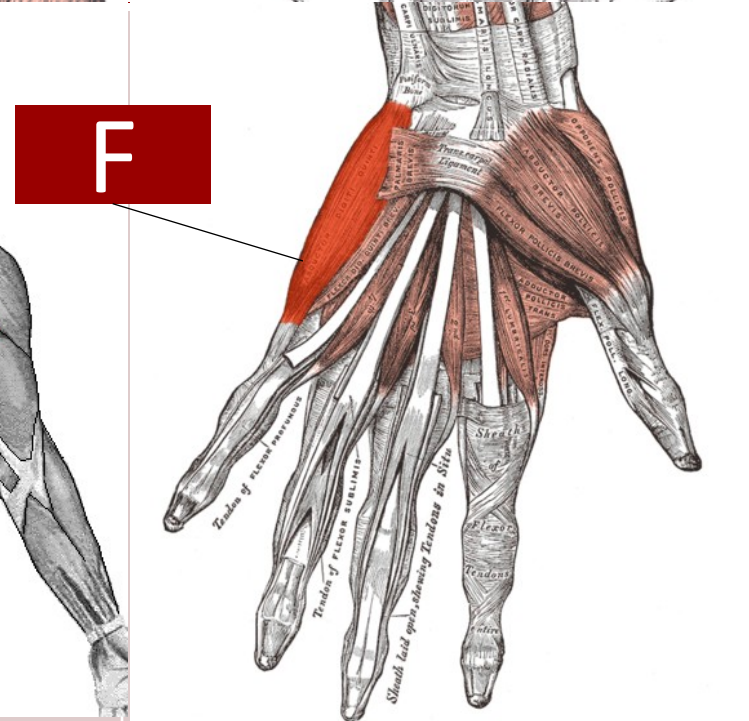
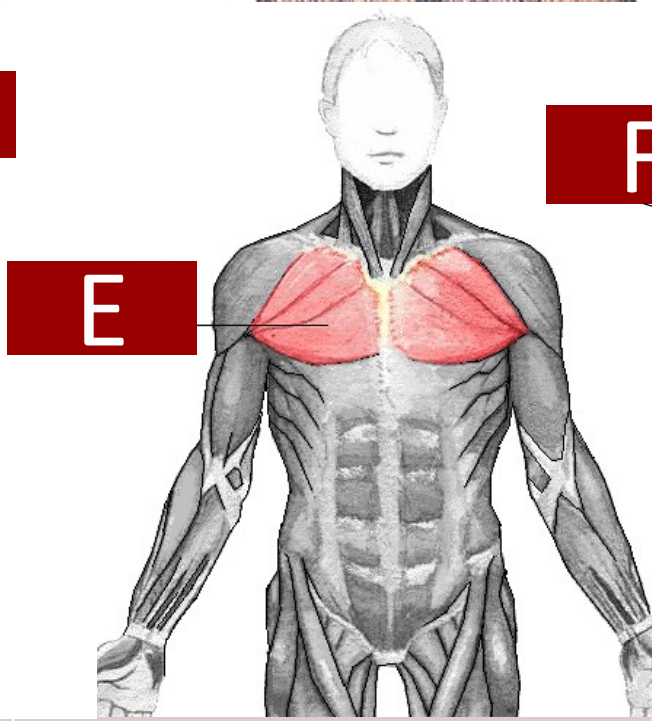
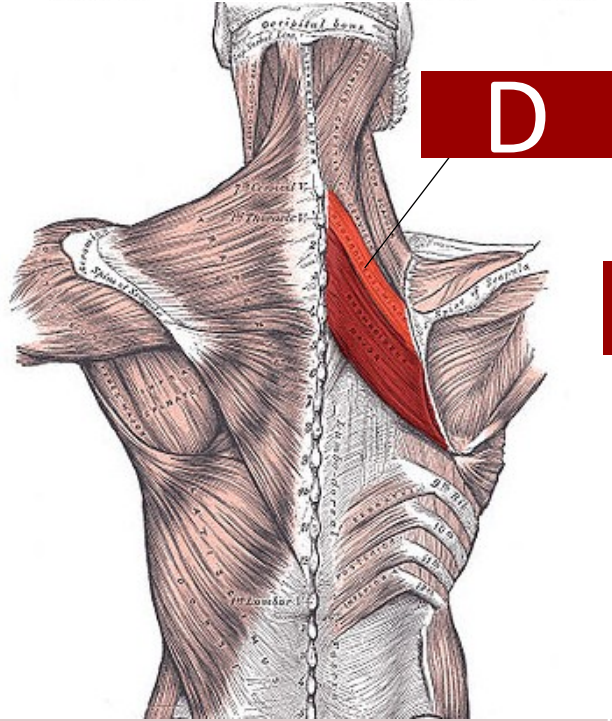
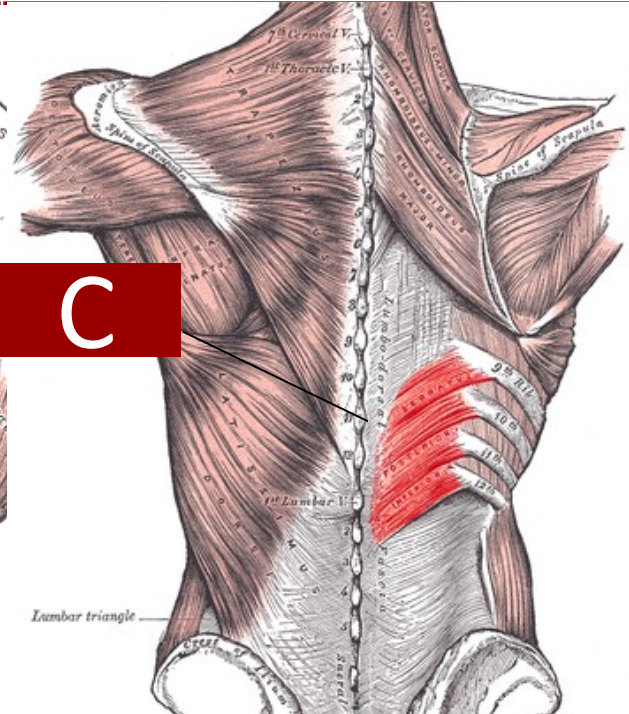
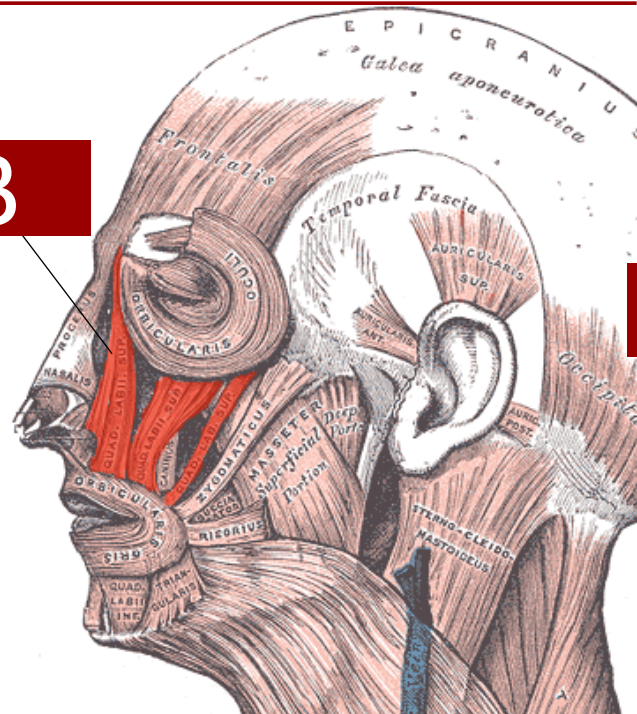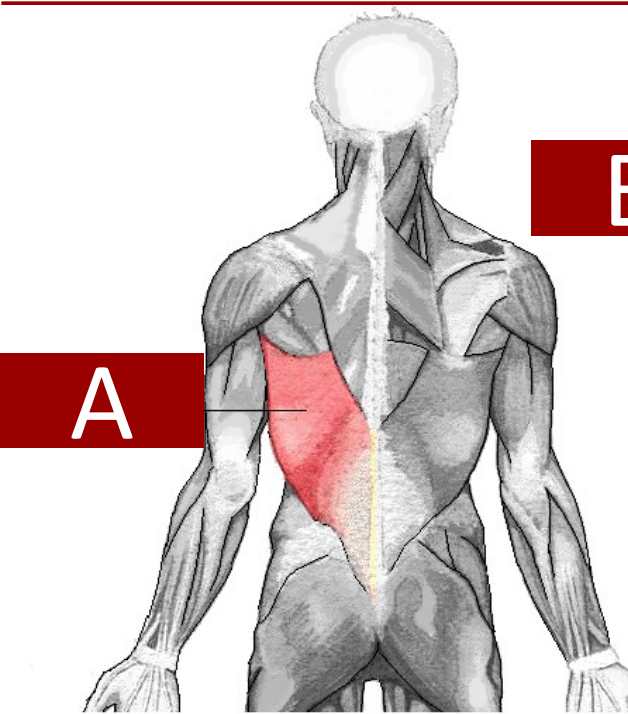
M. deltoideus

N. cutaneus brachii

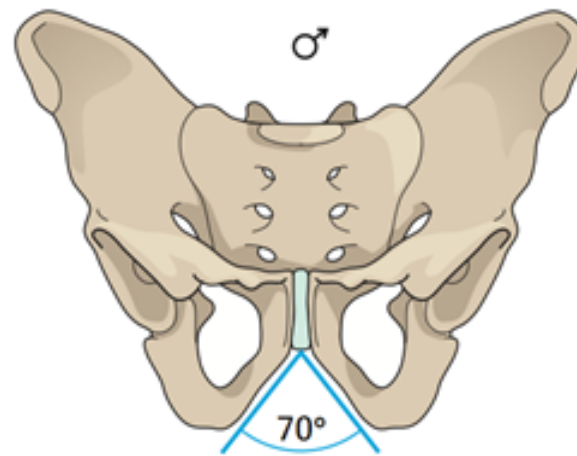
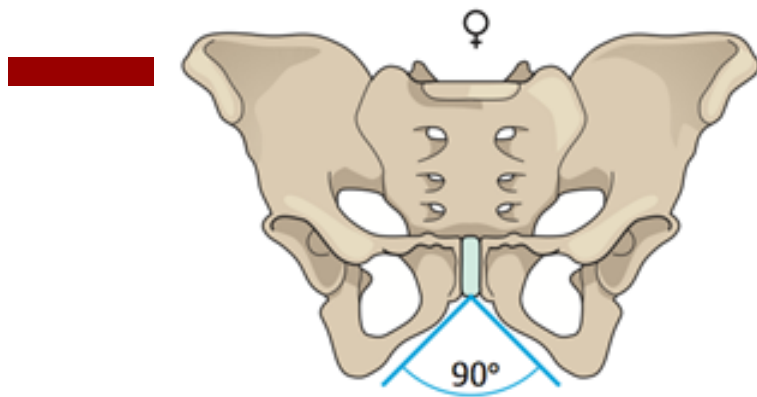
M. triceps brachii caput longum

M. triceps brachii caput laterale

Tendo M. triceps brachii







Ano Ne

1. Pelvis feminina levior est.
2. Pelvis masculina latior est.
3. Apertura superior pelvis femininae major est.
4. Cavitas pelvis femininae angustior est.
5. Os sacrum pelvis masculinae brevius est.
6. Os sacrum pelvis femininae latius est.
7. Foramina obturatoria pelvis femininae majora sunt.
8. Acetabula feminina majora sunt.
9. Coccyx feminina brevior est.
10. Angulus alarum ossis ilii masculini minor est.
11. Promontorium femininum minus est.
12. Symphysis pubica feminina longior est.

✓

✓

✓

✓

✓

✓

✓

✓

✓

✓

✓

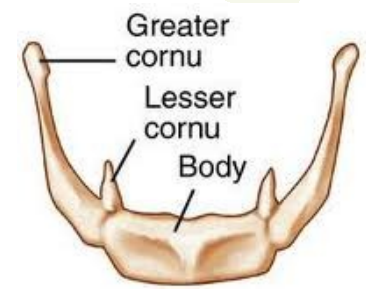
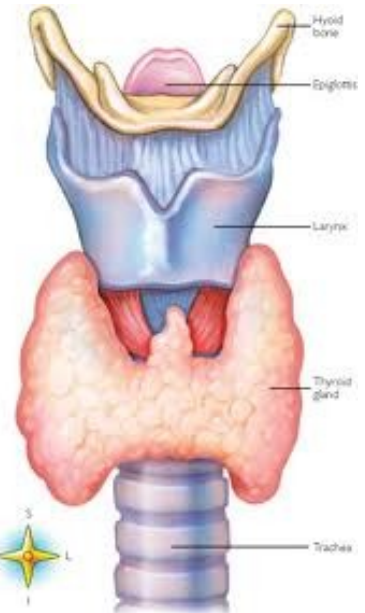
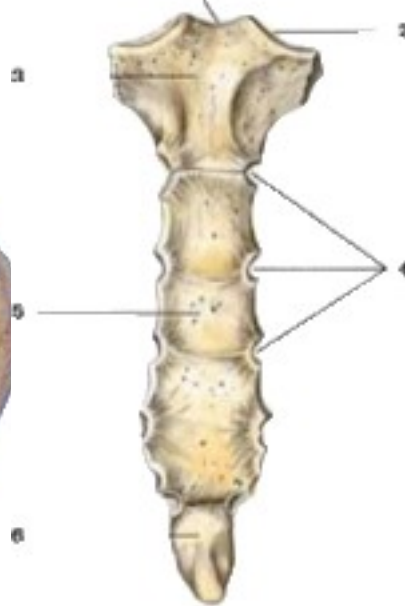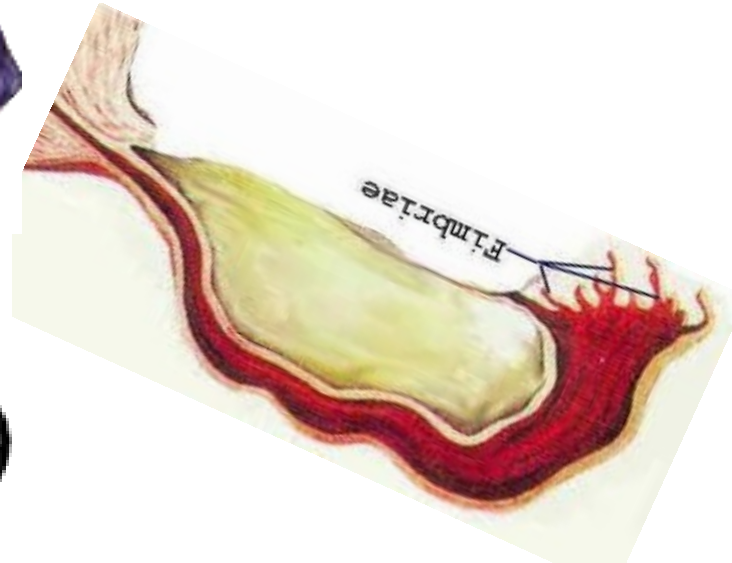
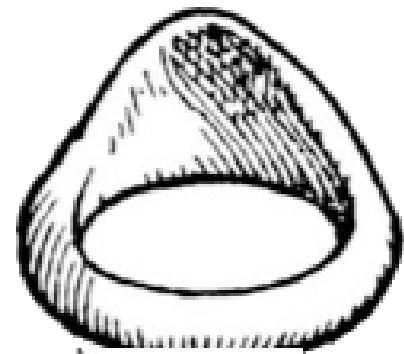
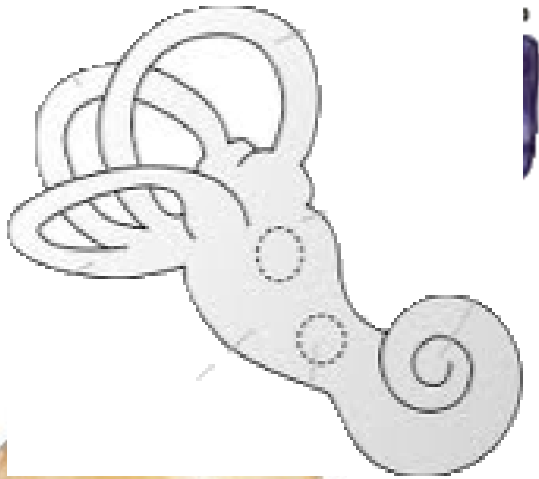
✓

**NAME AND LOCALIZE FOLLOWING OBJECTS WITHIN HUMAN BODY**



υ





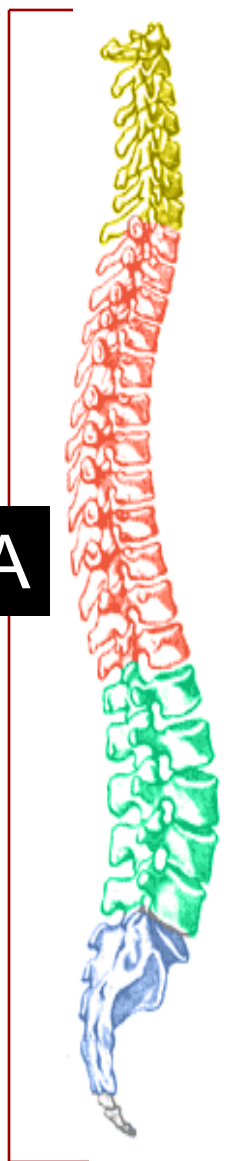# NUMERALS : INTRODUCTION

## TYPES:

1. **CARDINAL** unus, una, unum
2. **ORDINAL** secundus, a, um ←
3. **MULTIPLE** triplex, cis ←
4. **NUMERAL ADVERBS** quater ←
5. **DISTRIBUTIVE NUMERALS** singuli

1-10	11-12
primus, a, um	undecimus, a, um
secundus, a, um	duodecimus, a, um
tertius, a, um	
quartus, a, um	
quintus, a, um	
sextus, a, um	
septimus, a, um	
octavus, a, um	
nonus, a, um	
decimus, a, um	

**MATCH NUMBERS AND LETTERS, FILL IN MISSING ENDINGS, READ THE NUMERALS**



**B**

1. Vertebra cervical\_\_ C<sub>7</sub>

**C**

1. Fractura vertebra\_ coccyge\_\_ Co<sub>3</sub>

**A**

1. Contusio vertebr\_\_\_ lumbal\_\_\_ L<sub>1</sub>-L<sub>5</sub>

**D**

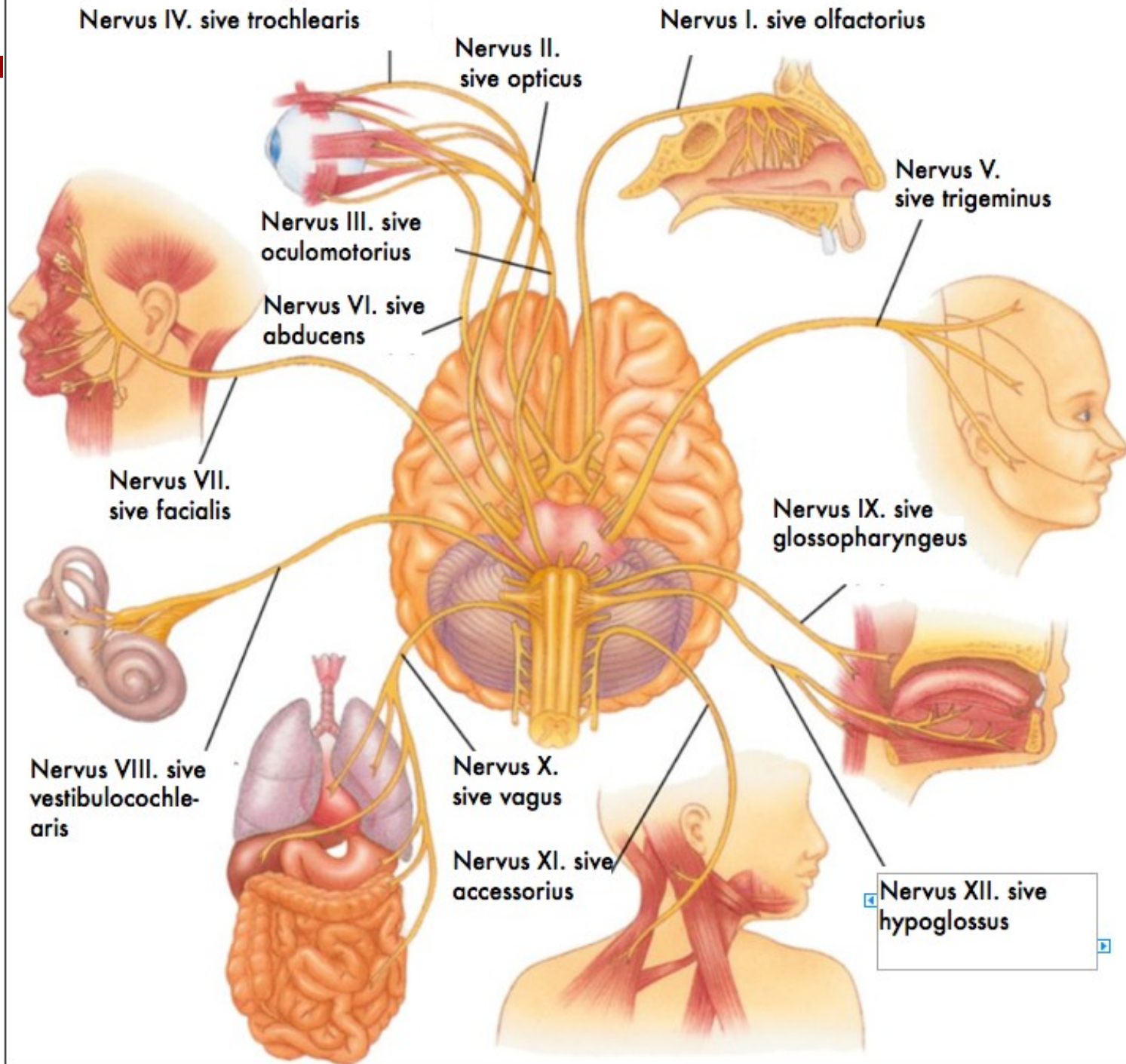
2. Vertebr\_\_ sacral\_\_\_ S<sub>1</sub>-S<sub>5</sub>

**E**

3. Operatio vertebr\_\_ thoracic\_\_ Th<sub>8</sub>-Th<sub>9</sub>

**F**

4. Columna vertebr\_\_\_ (=vertebralis)



1-4	many
Simplex, cis	Multiplex, cis
Duplex, cis	
Triplex, cis	

*St. p. hysterectomiam abdominalem simplicem anno 2012/05*

*Pelvis renis l. dx. et ureter l. dx duplex*

*Tumor lobi superioris pulmonis l. sin. triplex*

*Metastases hepatis multiplices susp.*



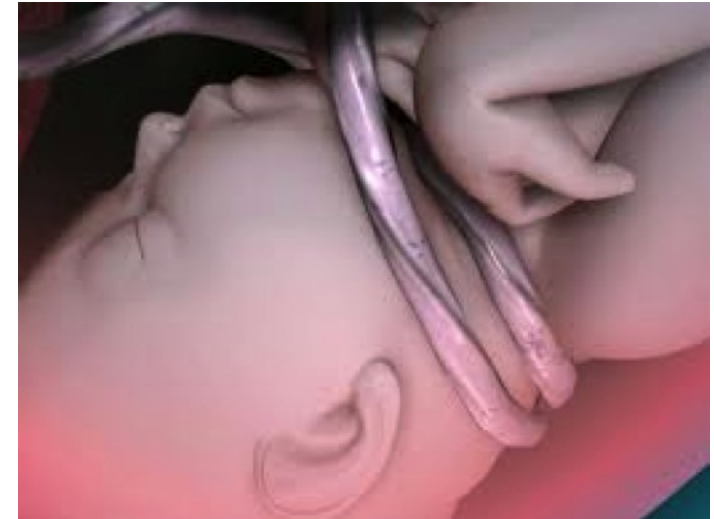1-4

semel

bis

ter

quater



*Funiculus umbilicalis circum collum fetus semel/bis/ter in grav.  
hebd. 40+4*