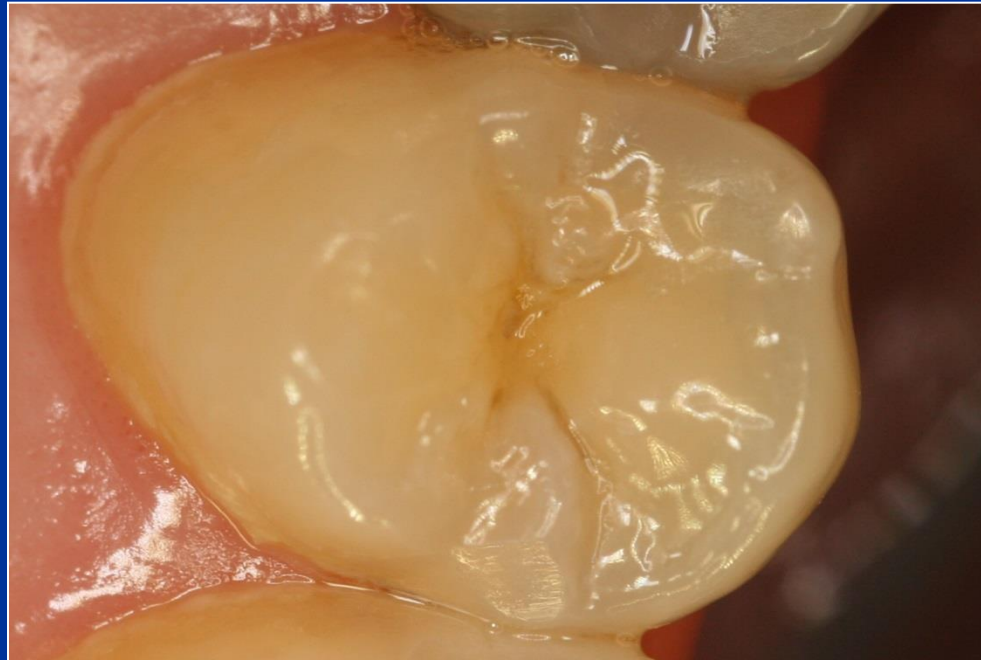

Class II. acc. to Black

Defects affecting one or both proximal surfaces of posterior teeth.

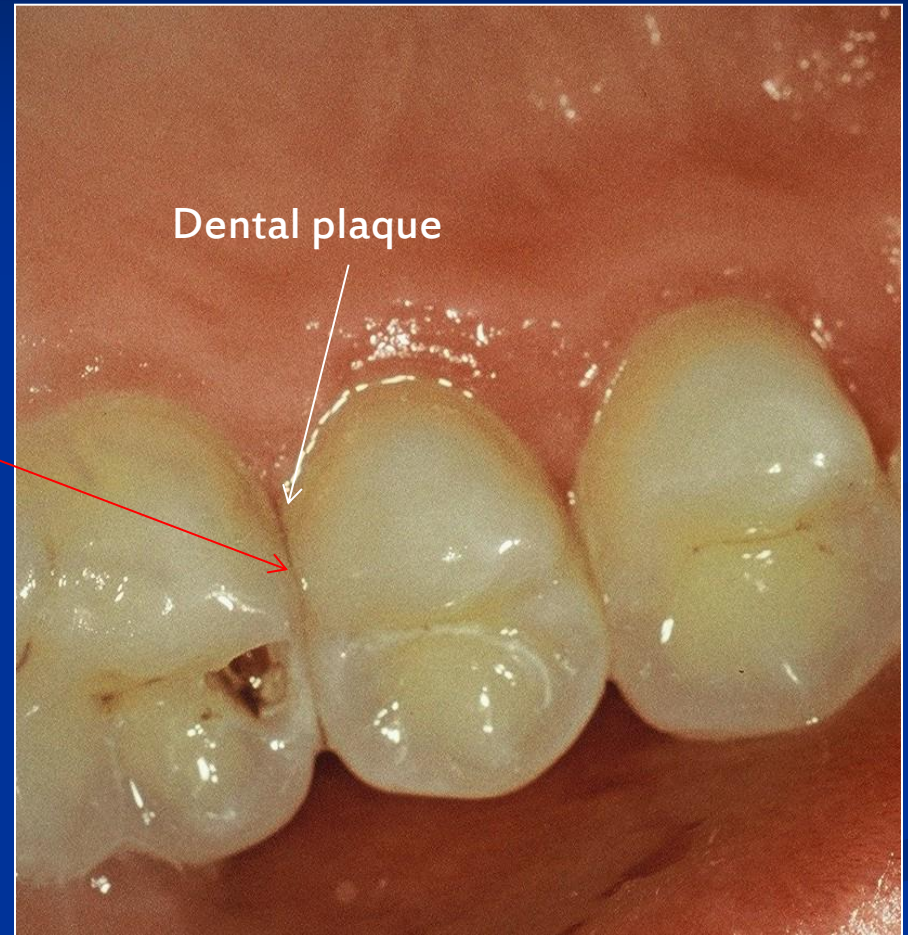

Morphology of proximal space

Contact point – area

The space below
(filled of interdental papilla,
the level of the papilla is decreasing
during the time)

The space above (habitually clean place)



Symptoms

- No symptoms
- Increased sensitivity (cold, sweet)
- Retention of food
- Defect (cariious lesion is open – the enamel is broken)
- Bite sensitivity (when cariious lesion is open)

Diagnosis

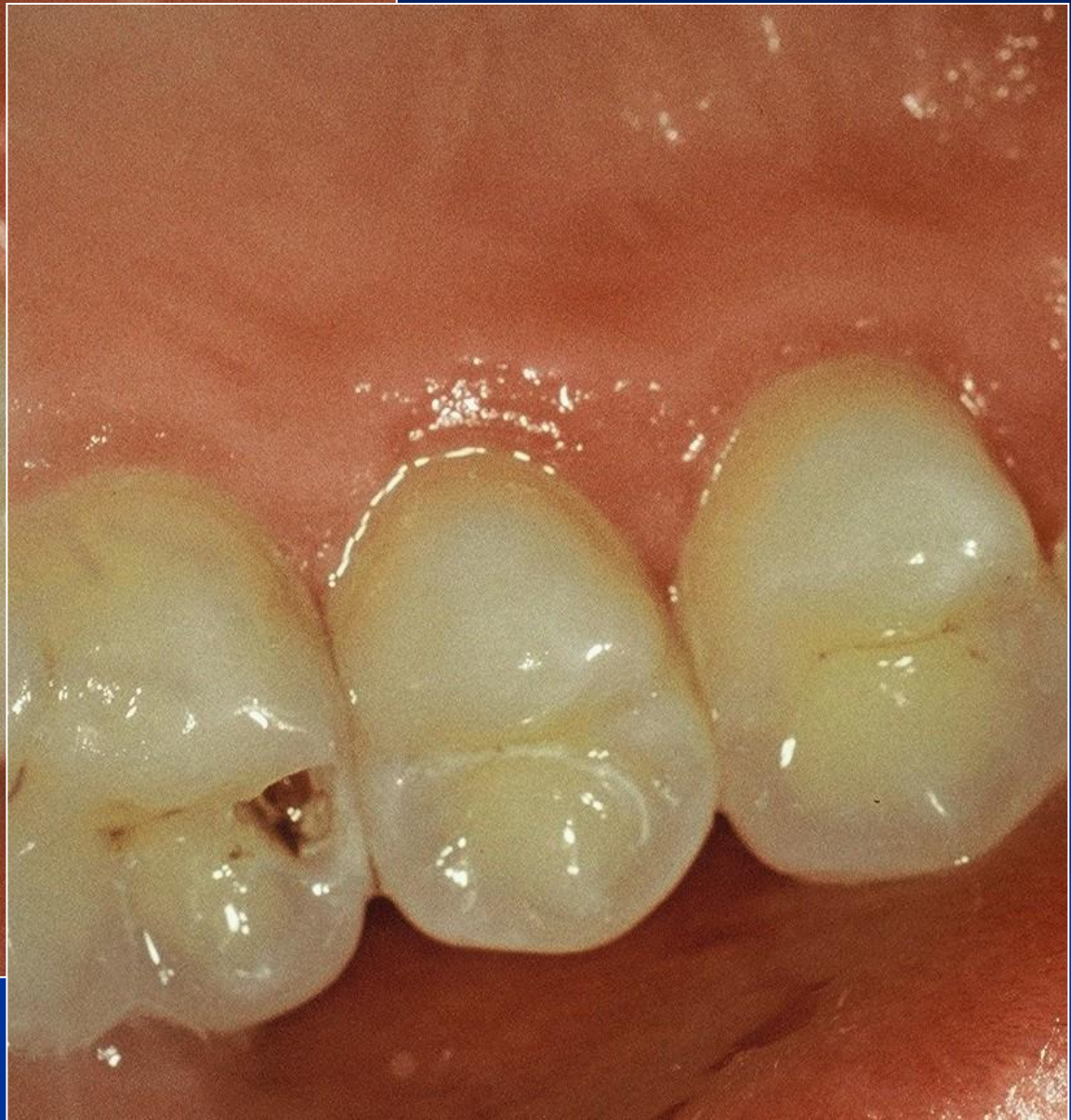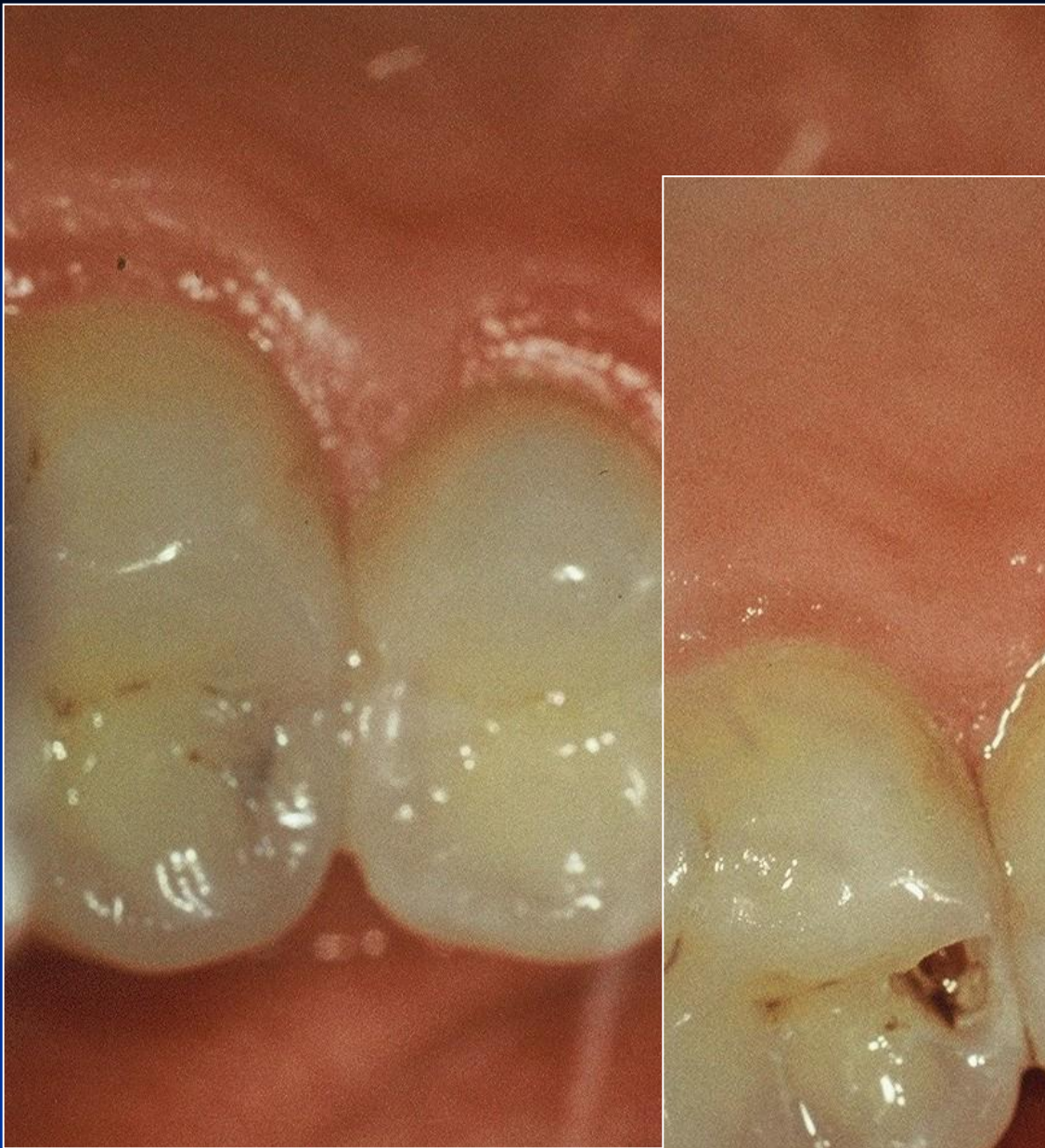- Visual changes of tooth structure

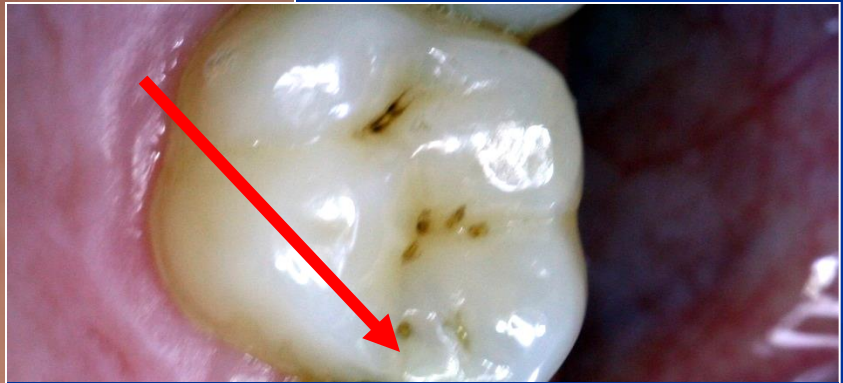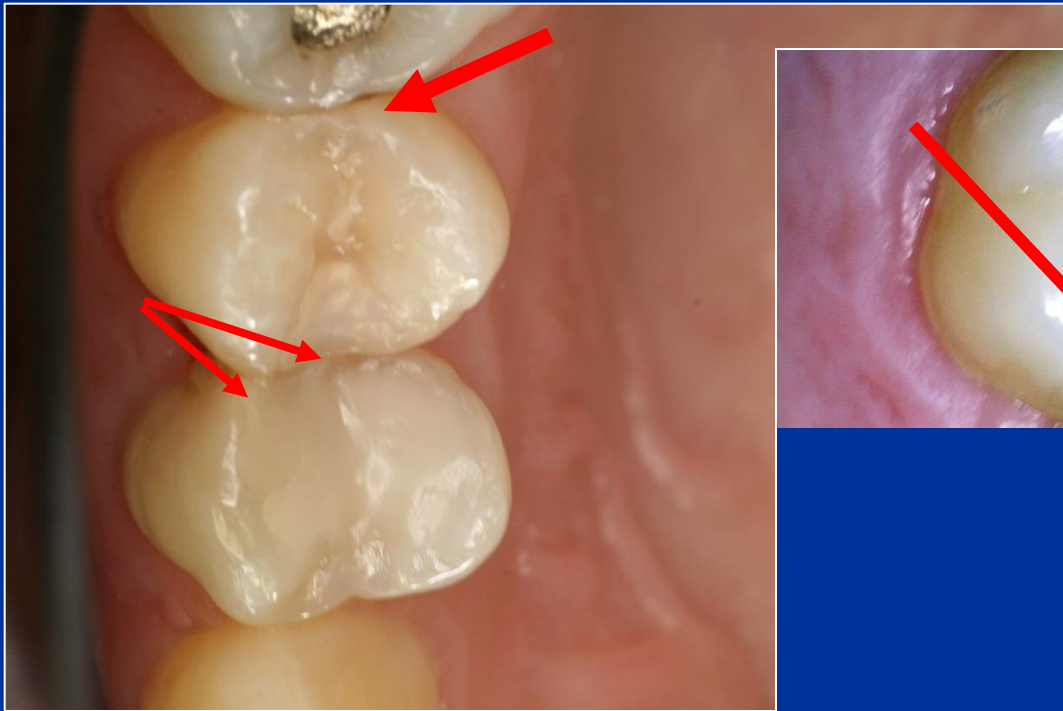
Inspection, good illumination, magnification

- Imaging methods

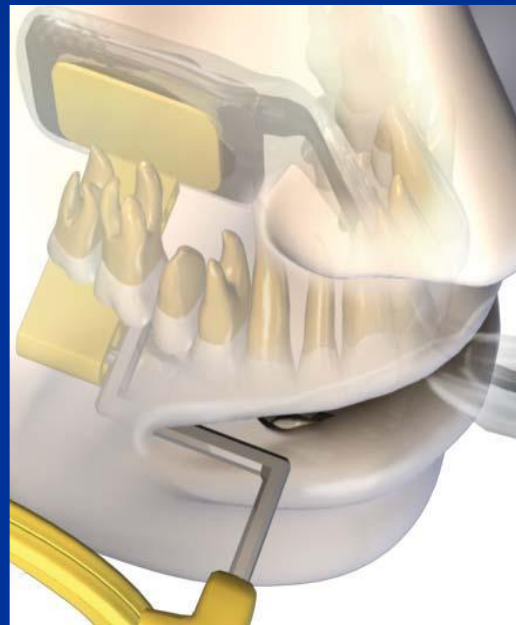
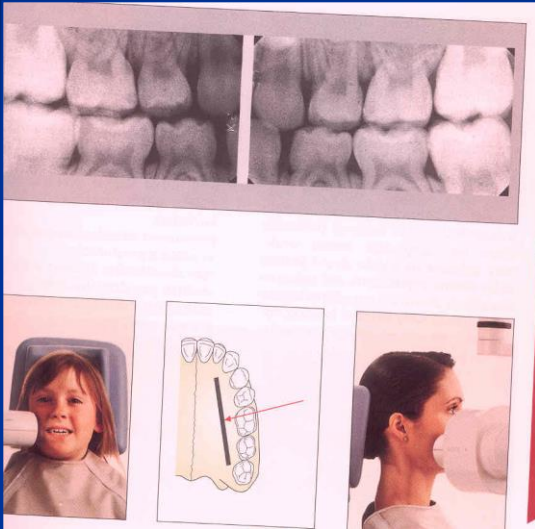
X ray - radiography

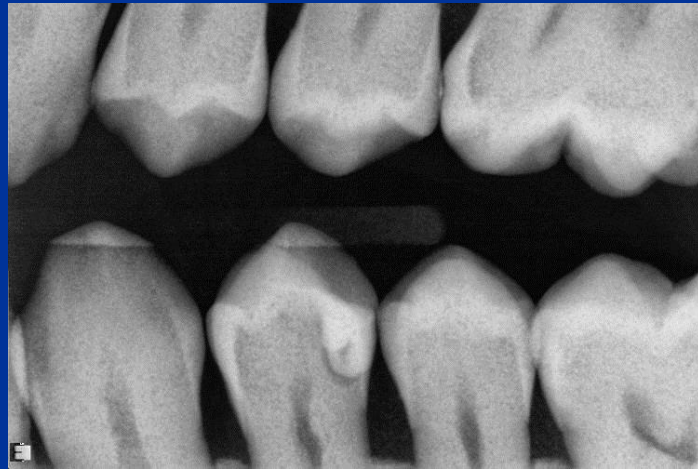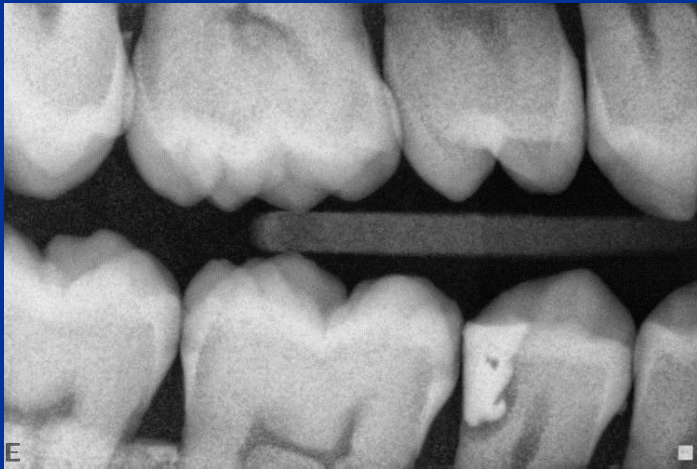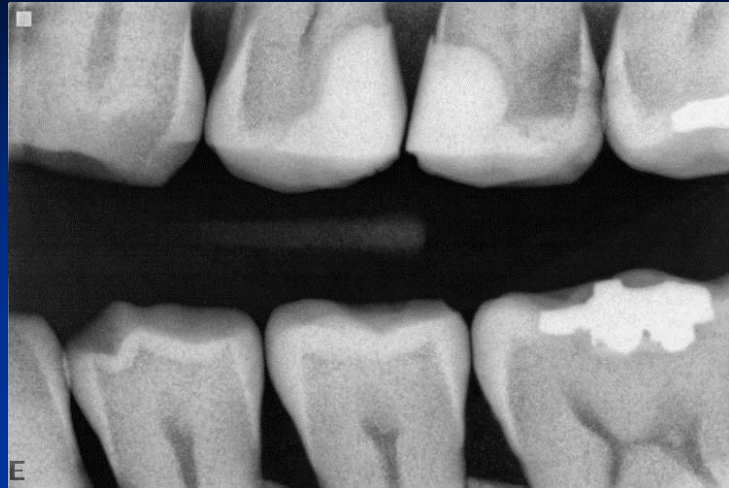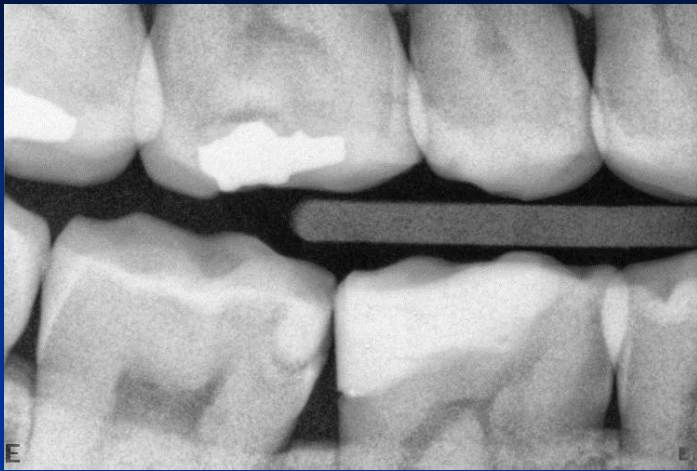Transillumination (DIFOTI)





Radiography





Bite wing

DIFOTI

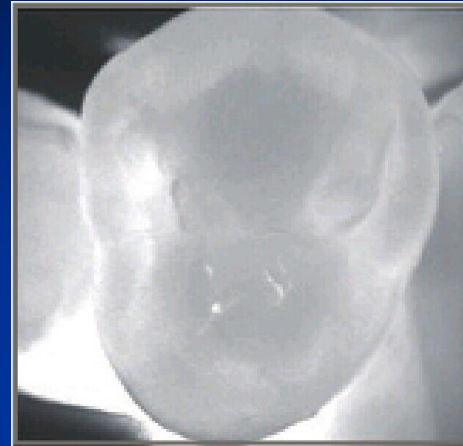(**D**igital **F**ibre **O**ptic
Trans-**I**llumination)

- Digitální forma FOTI – zdroj bílého světla – kamera s CCD senzorem – počítač – zobrazení jako obrázek

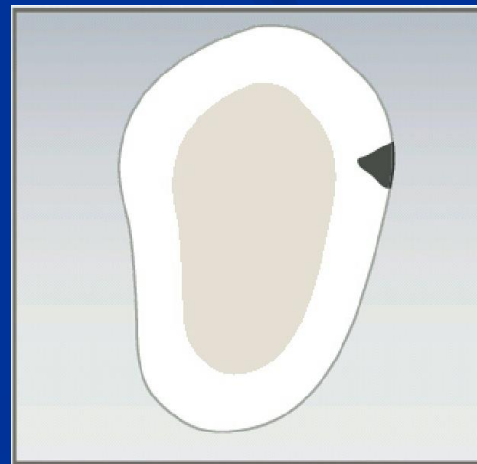
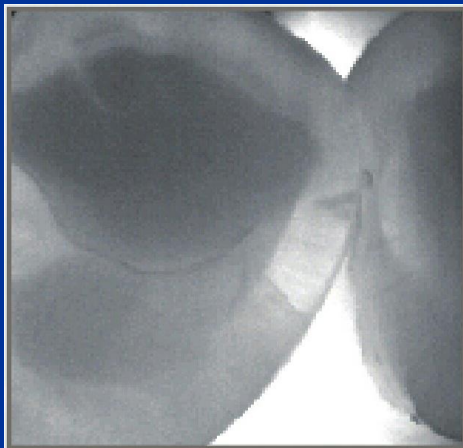


DIAGNOCam-

- 0 – no caries

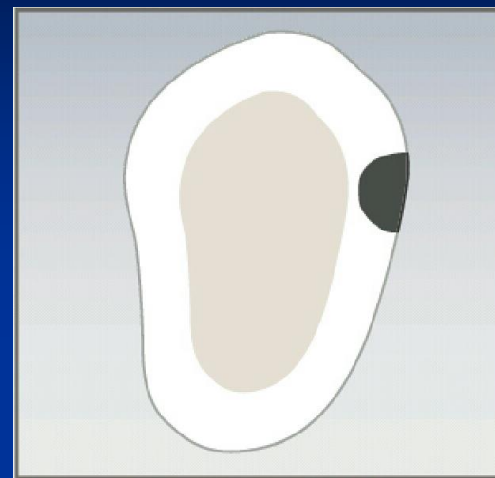
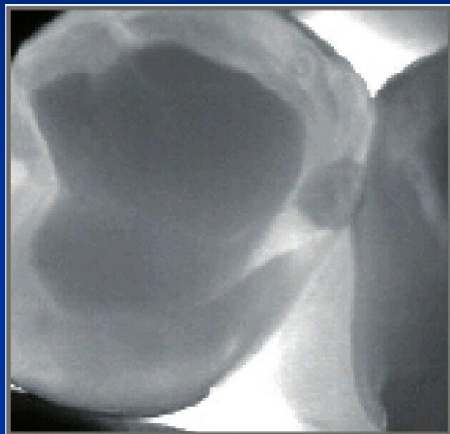
- 1-first visible changes

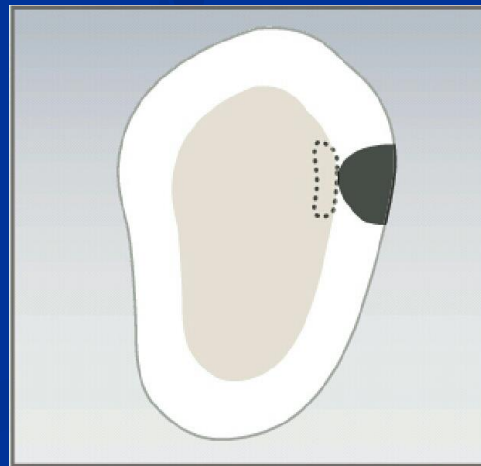
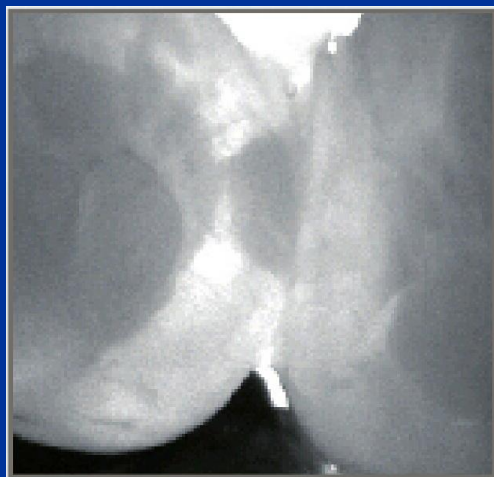


DIAGNOCam

- 2-caries in enamel

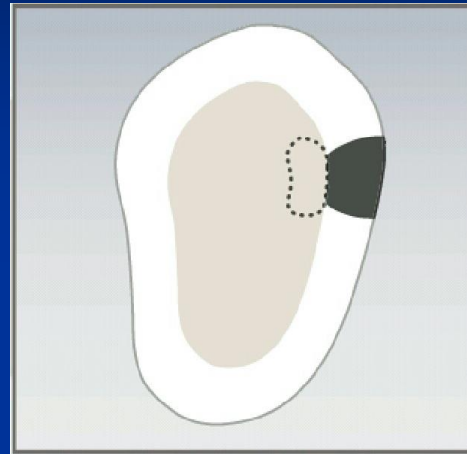
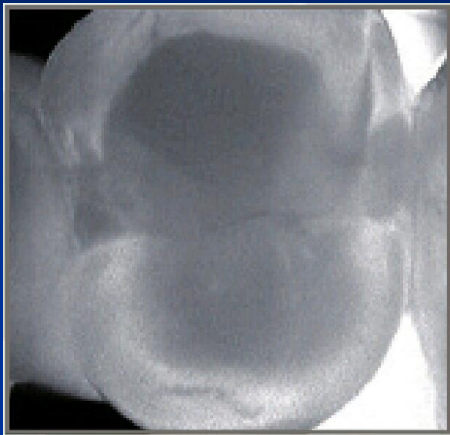


- 3 caries on dentino - enamel junction

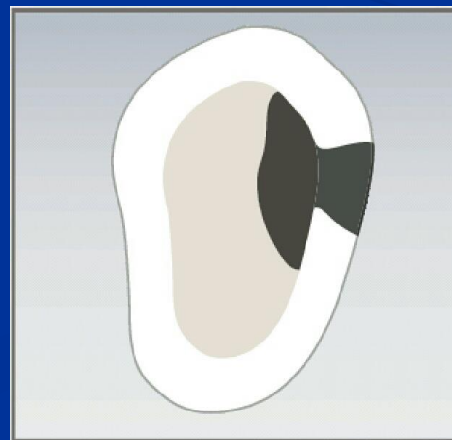
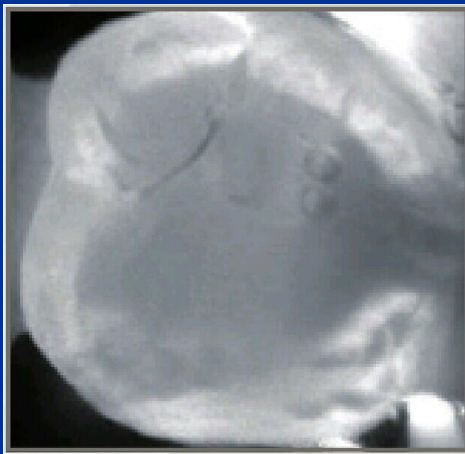


DIAGNOCam

- 4 – caries in dentin next to enamel



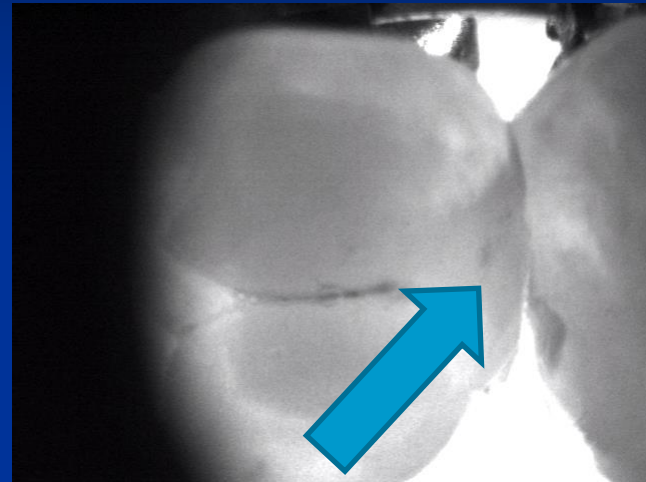
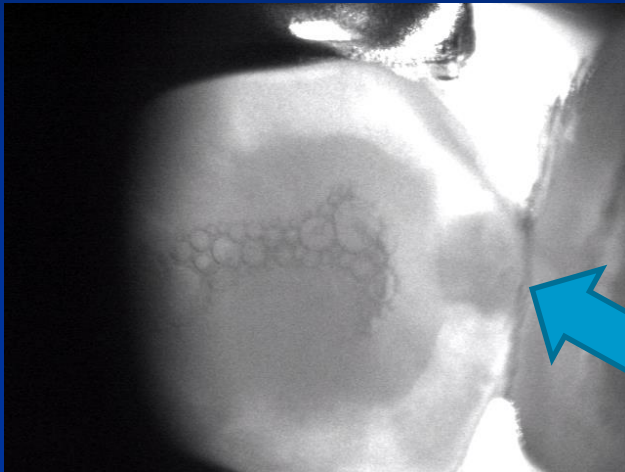
- 5 – large caries in dentin




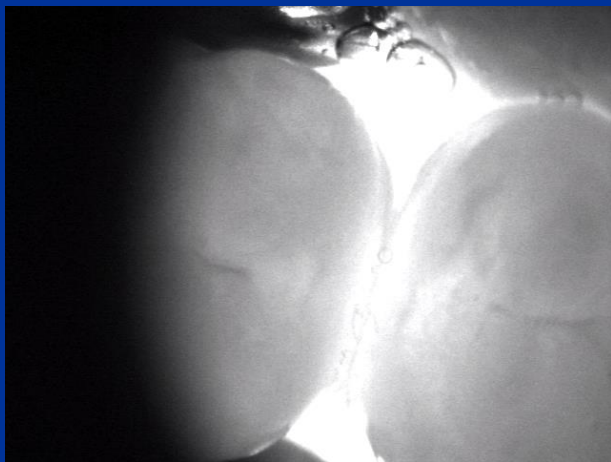
DIAGNOCam

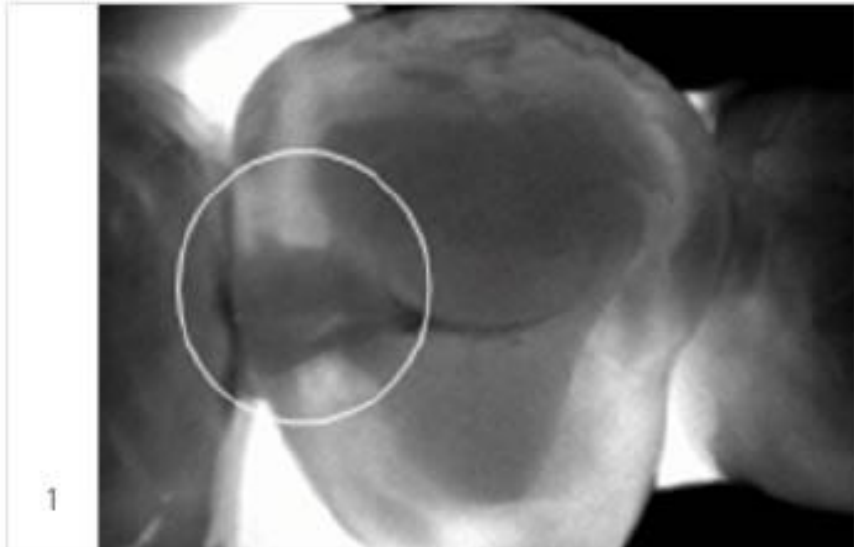

- Nález kazu

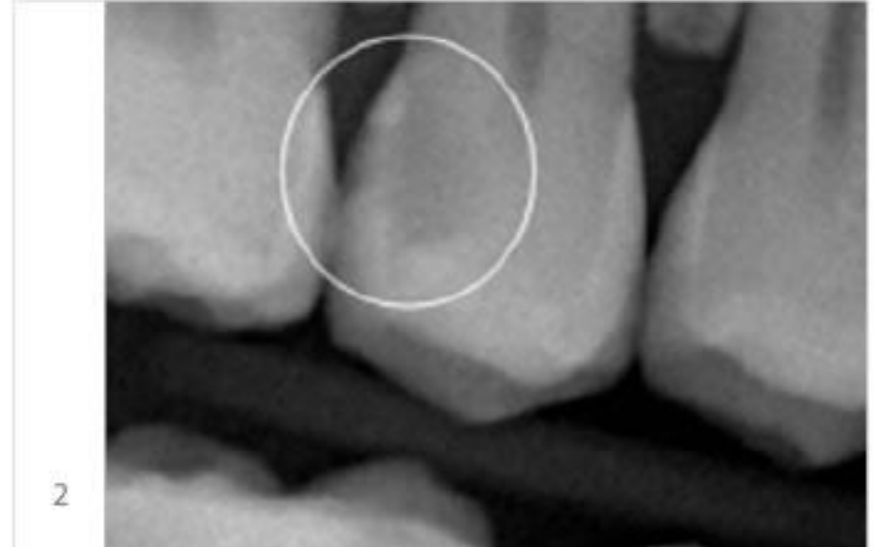

- ???

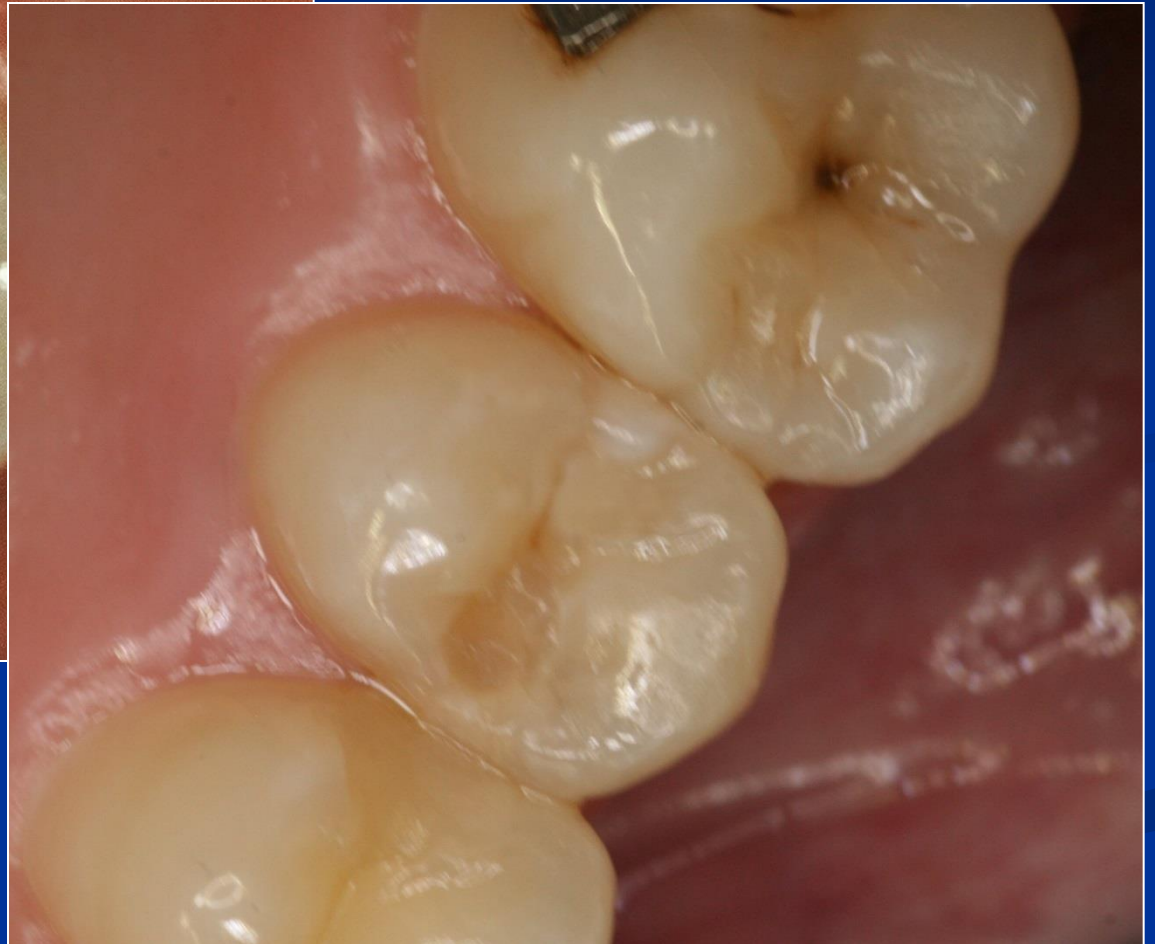
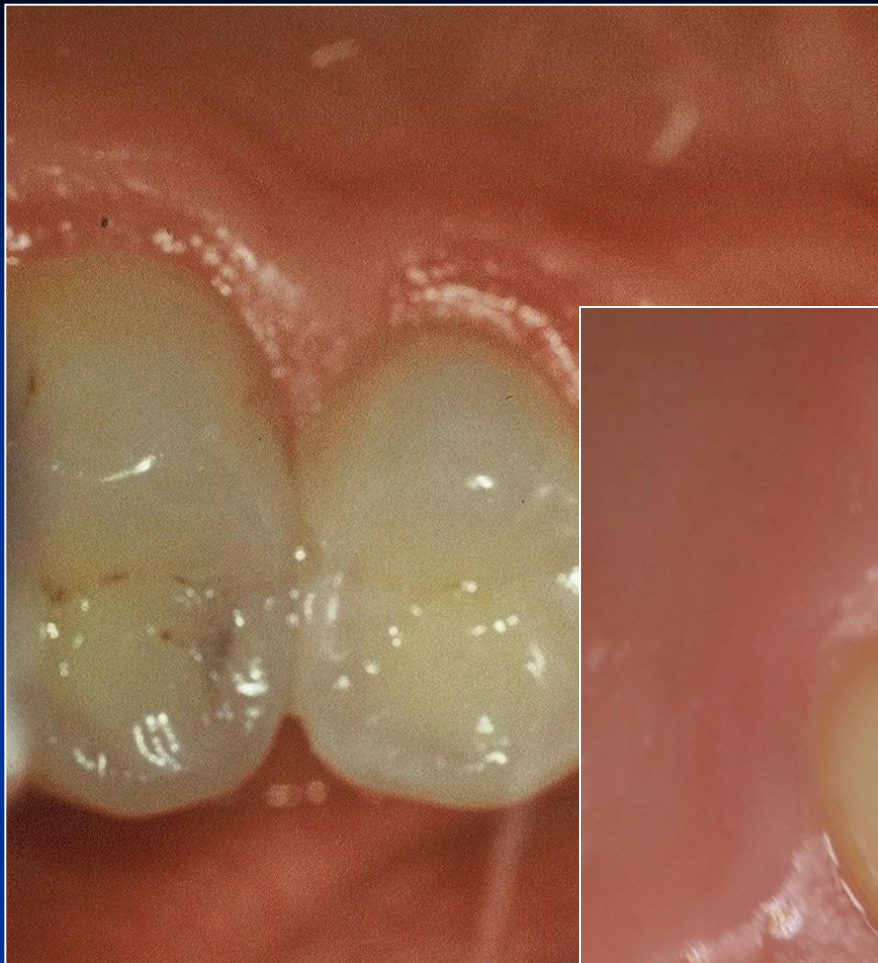


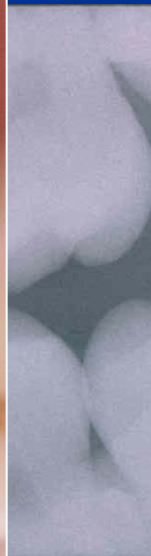
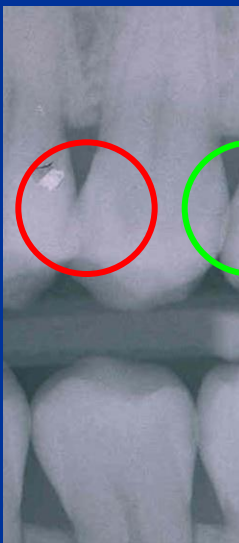
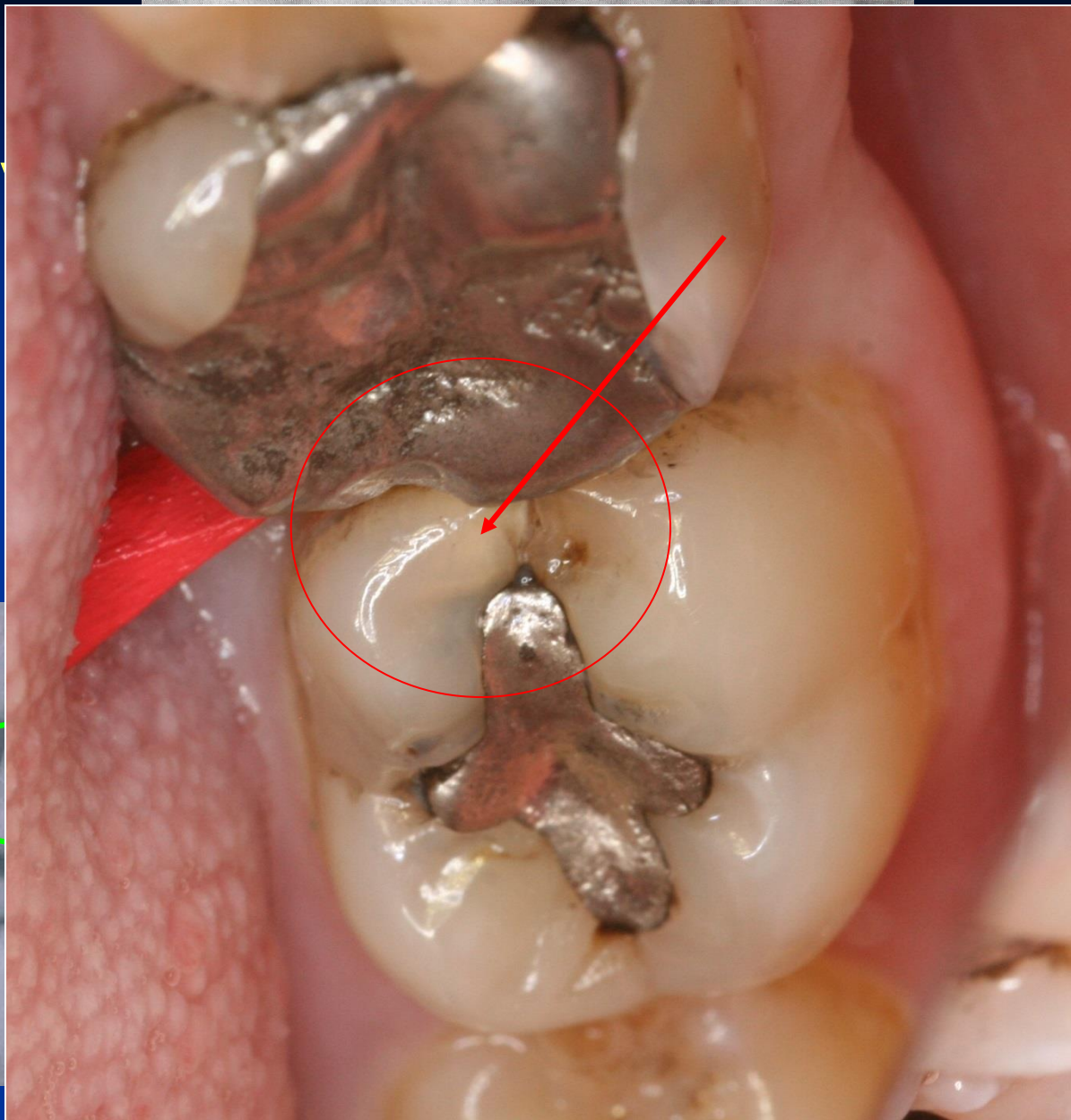
Diagnocam



Bitewing



4 stupňo
grading



KTG vyšetření – Bite wing

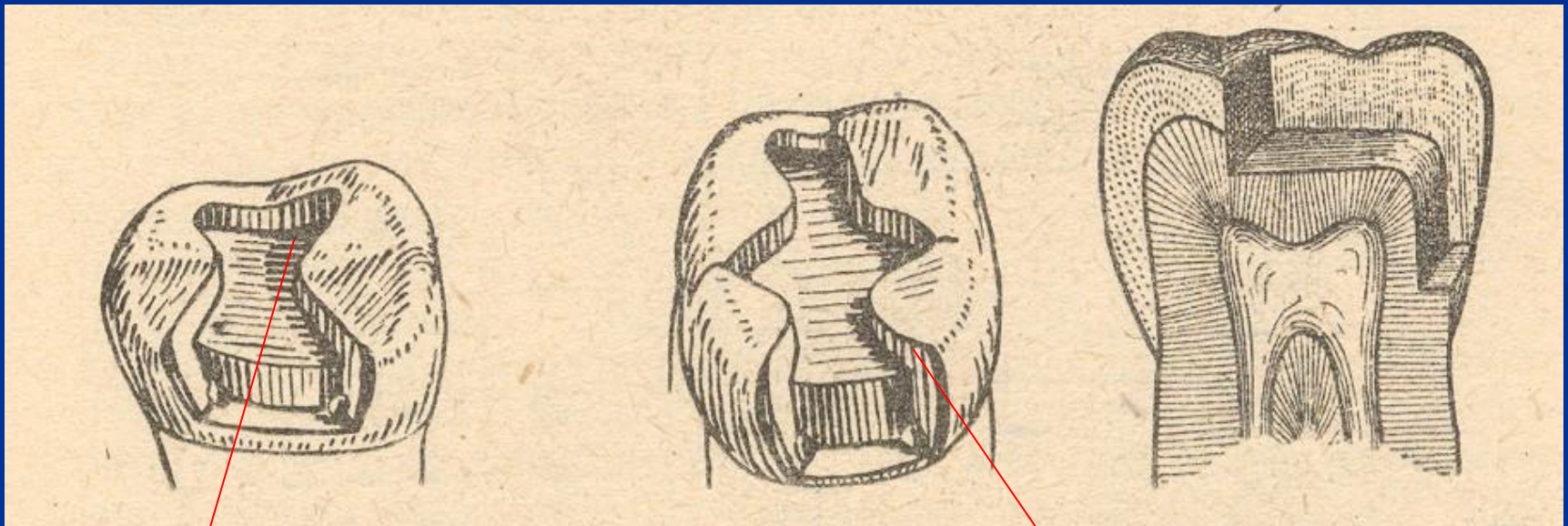
Preparation - amalgam

- Conventional preparation acc. to the Black's rules
- Slot preparation
- Large preparation – cusp(s) involved

Preparation - adhesive materials

- Conventional preparation for composites
- Adhesive slot
- Tunnel preparation

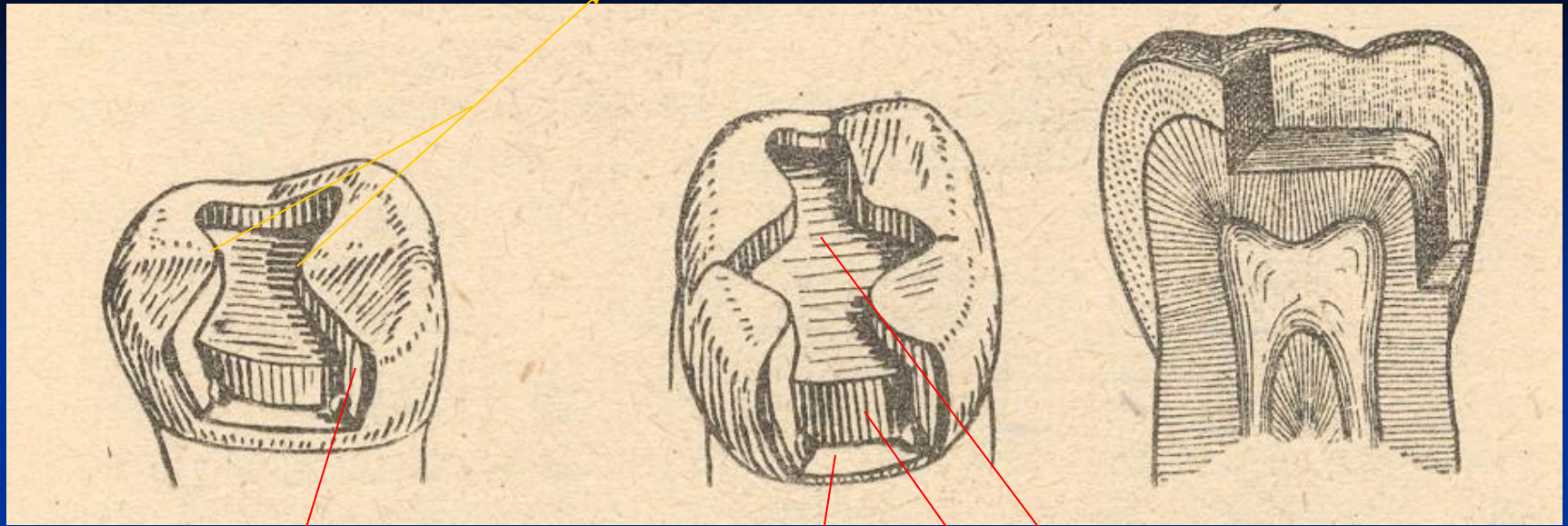
Conventional preparation



Occlusal cavity

Proximal cavity - box

Isthmus



Axial wall

Pulpal walls

Gingival wall

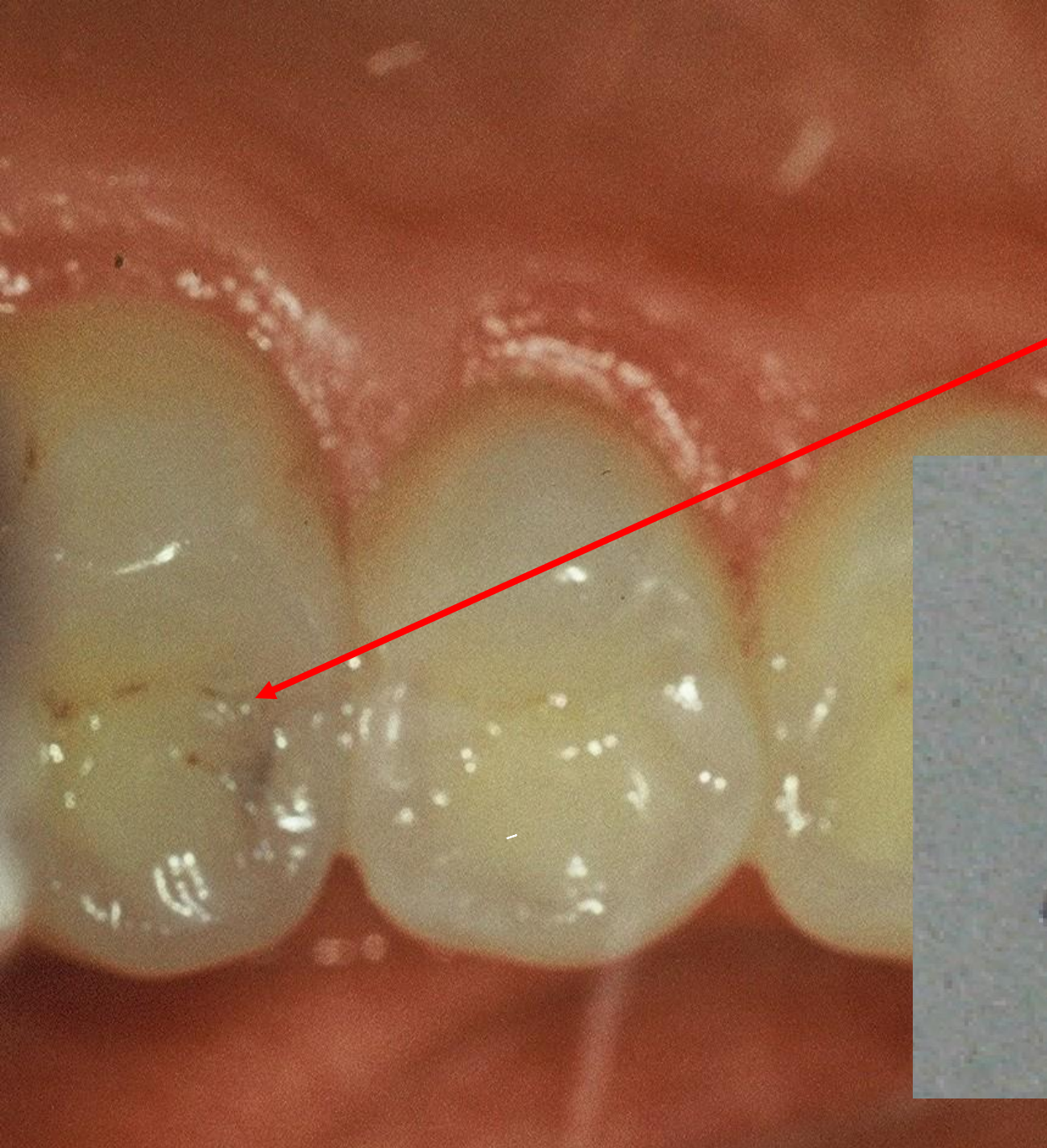
Access to the cavity

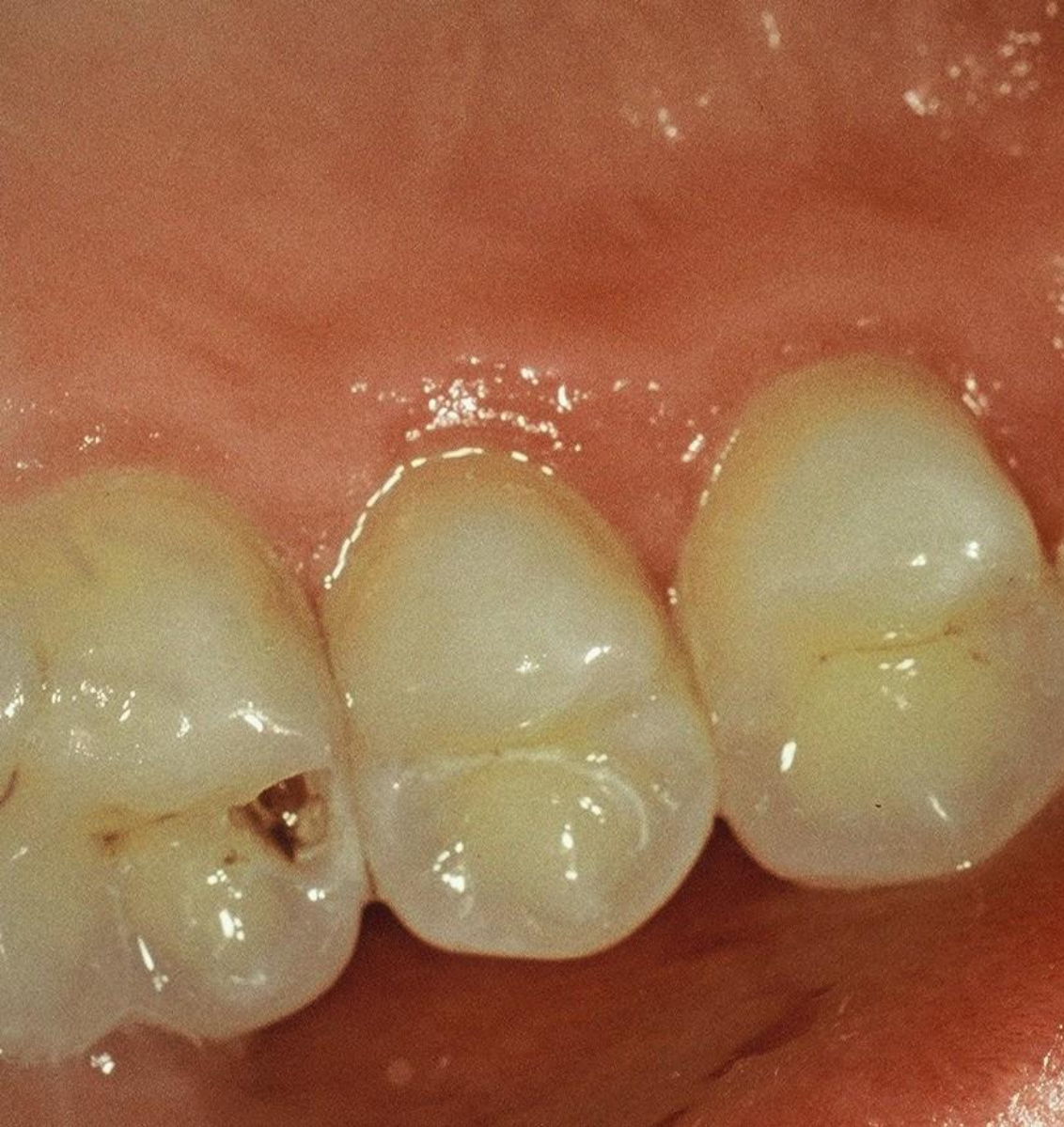From the occlusal surface

Through the undermined enamel

Separation using wooden wedges is useful

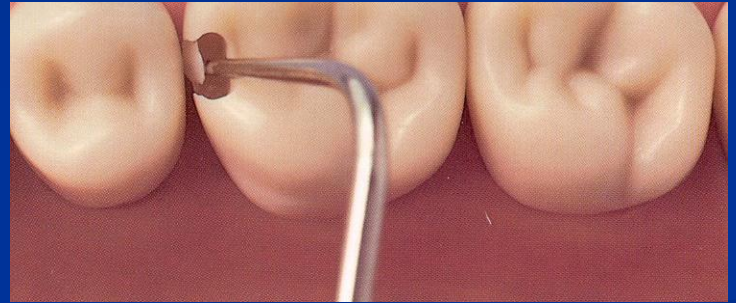
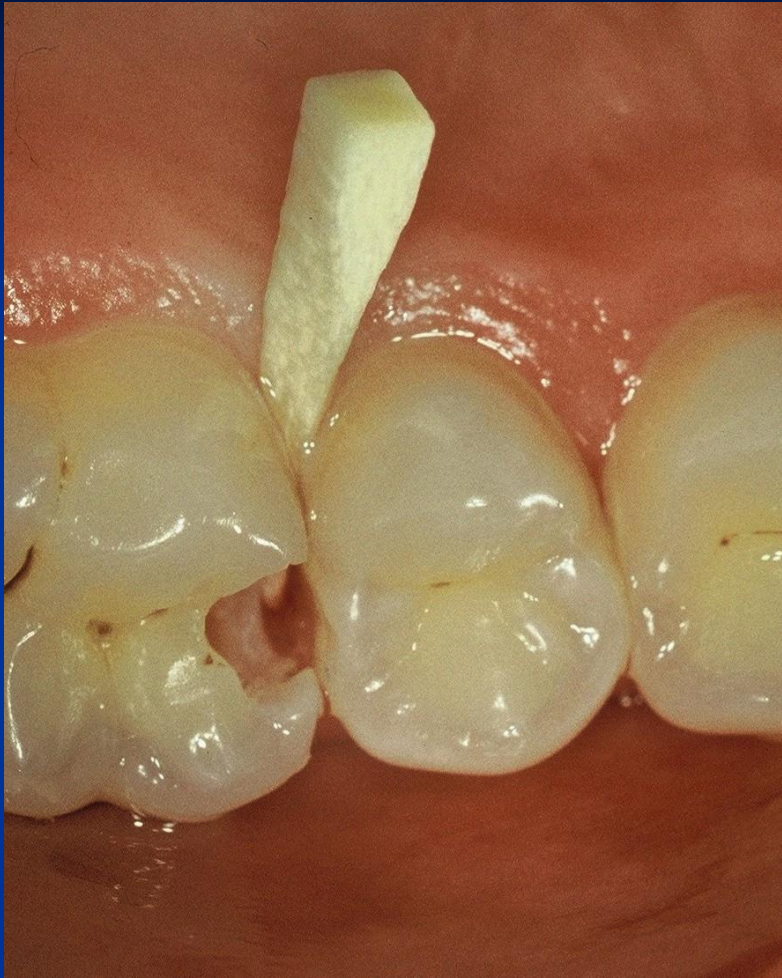Pre op

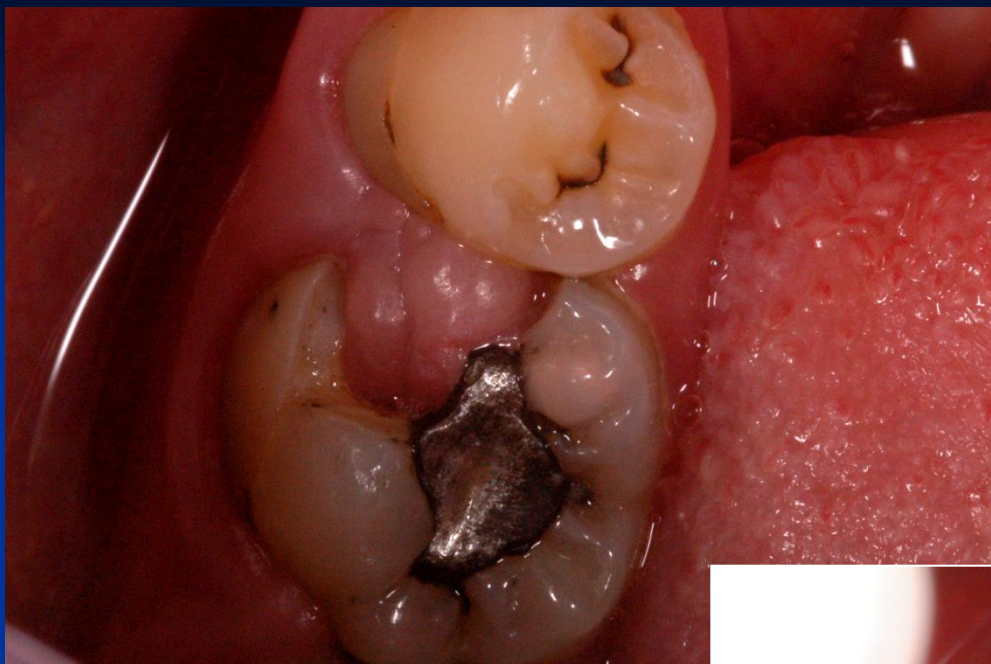




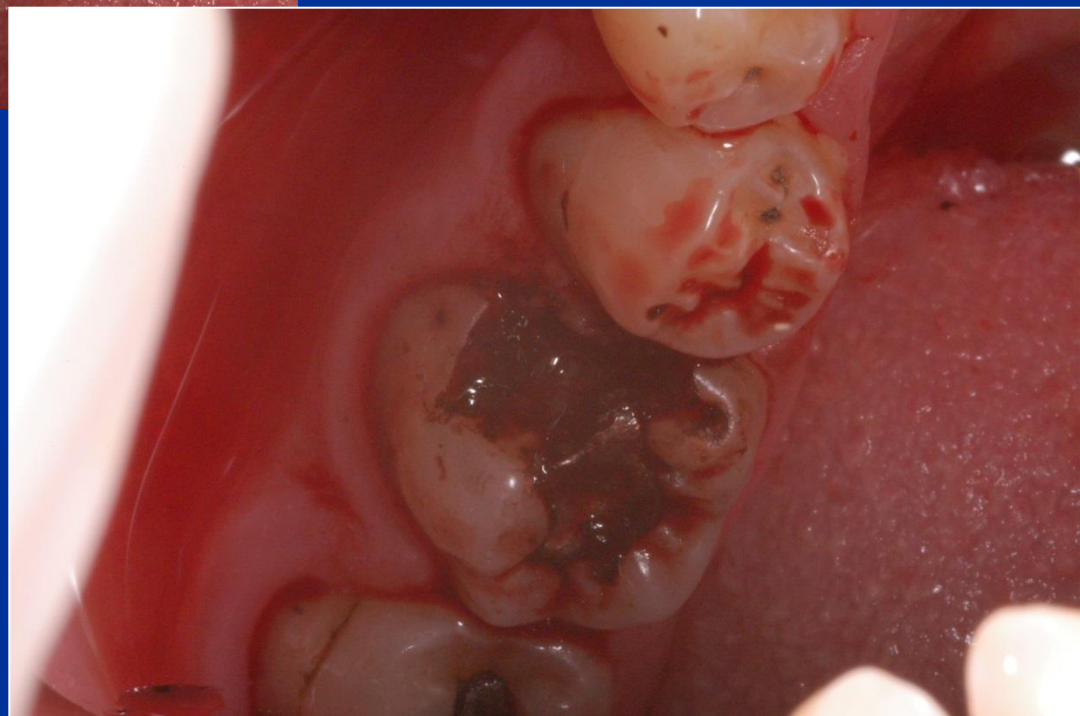
Access to the cavity

lroubal@med.muni.cz





- Skalpel
- Kauter
- Laser
- Temporary filling



Cavosurface margin and extention for prevention

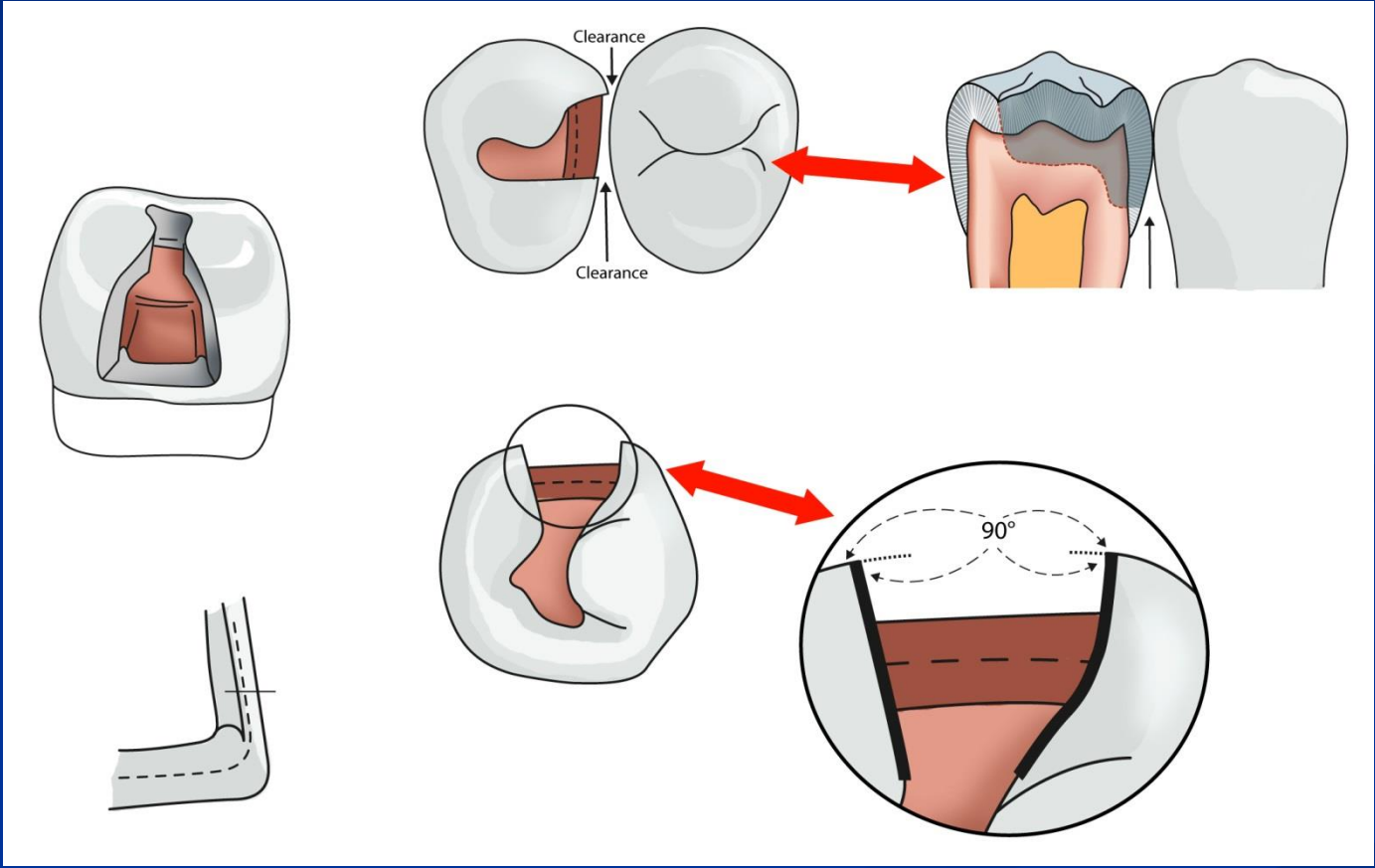
Proximal box:

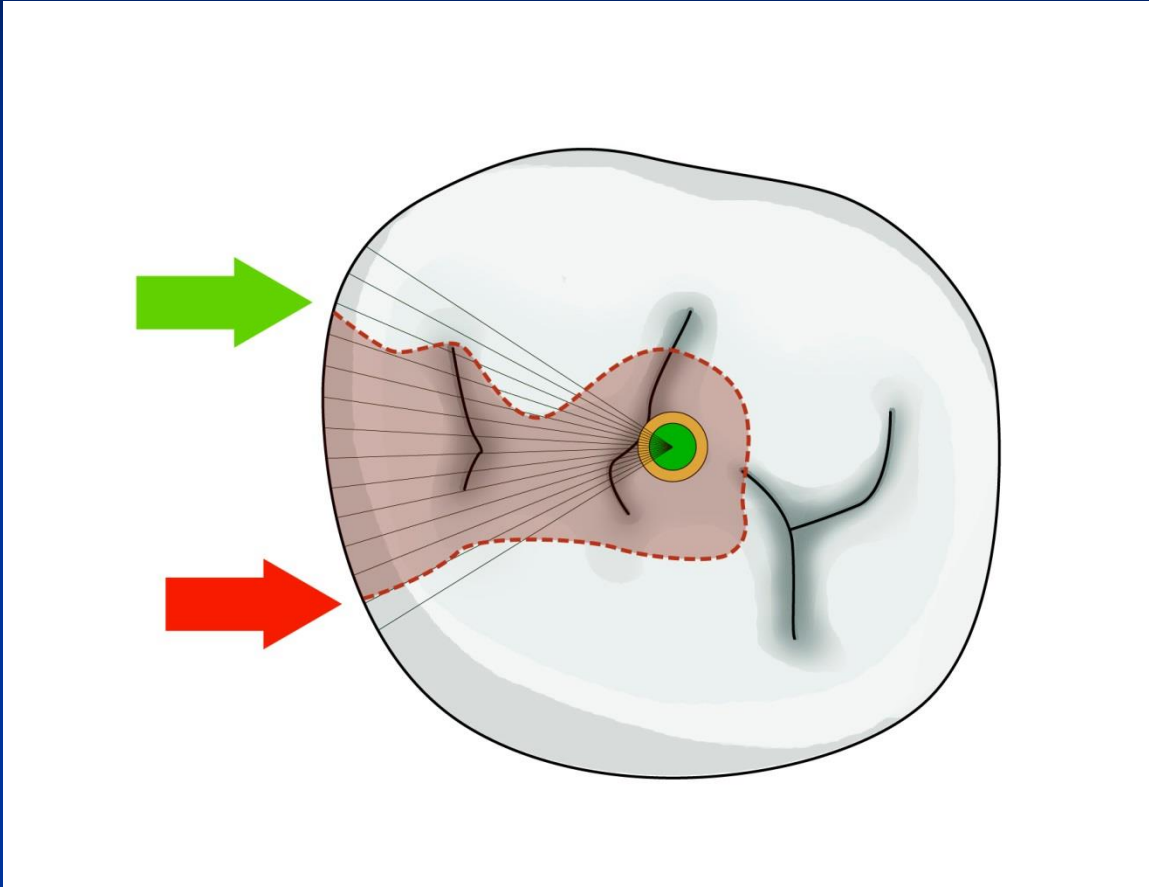
Axial walls

Gingival wall

Occlusally


Class I.





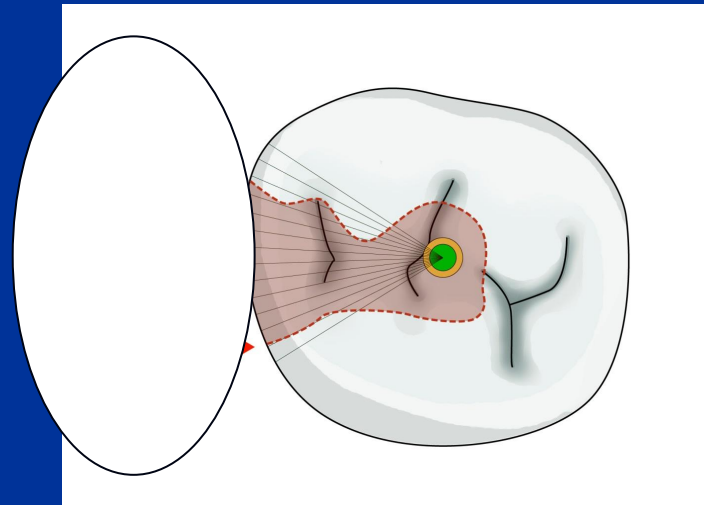
Cavosurface margin – axial walls

American rule obsolete



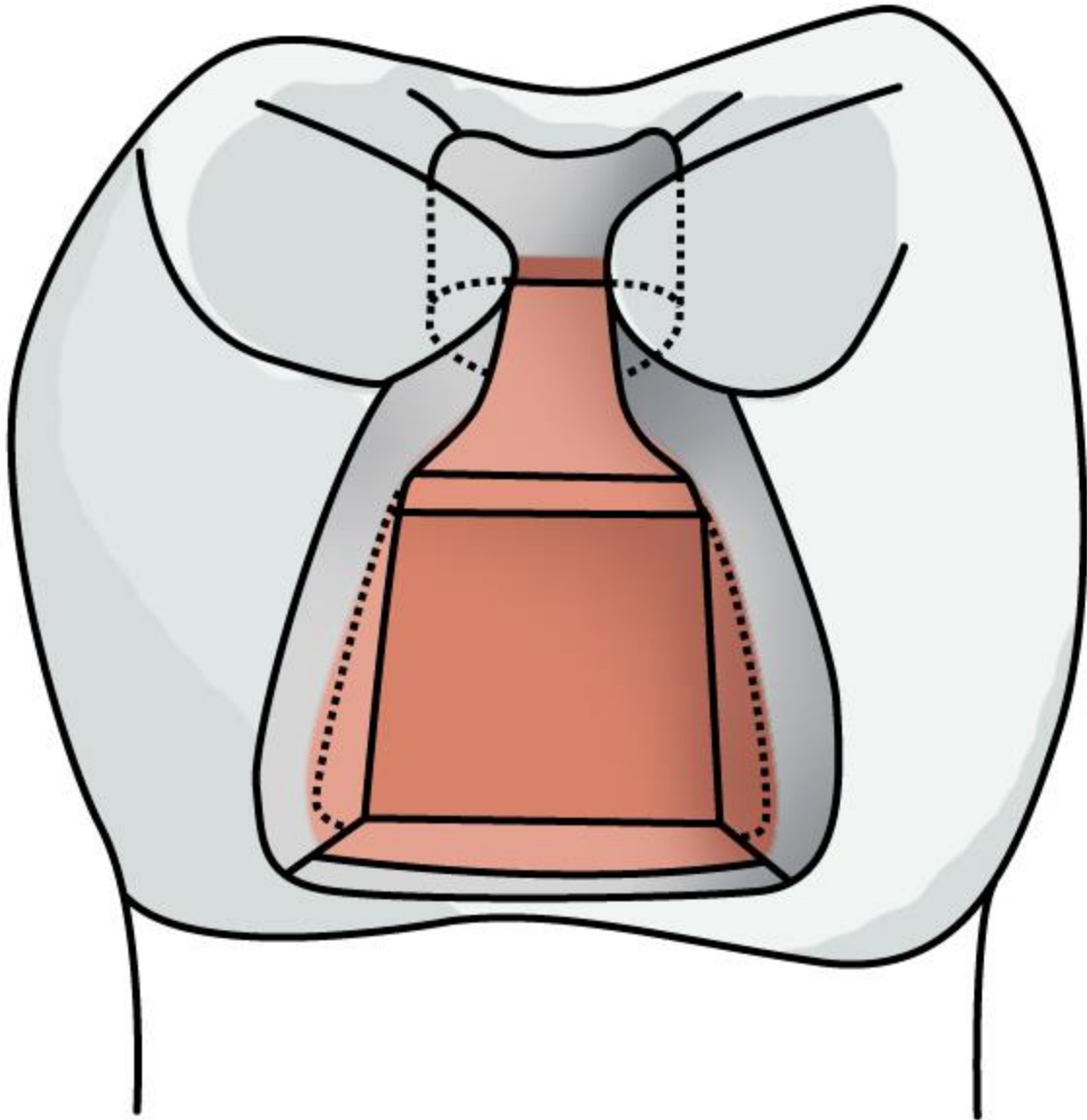
Cavosurface margin – axial walls

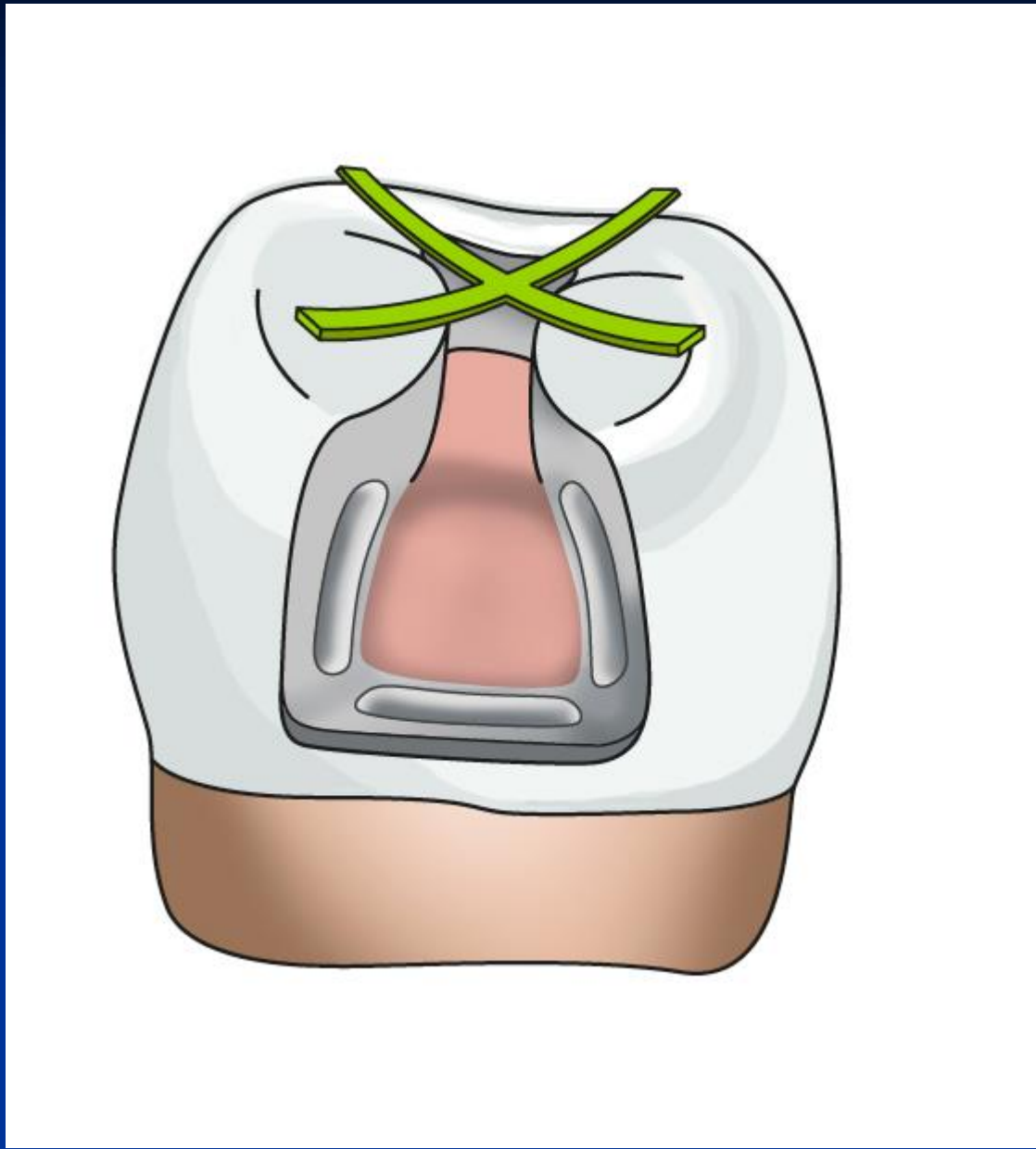
- Check the contact area – the filling must reconstruct the contact area –and be apprx. 0,5 mm over

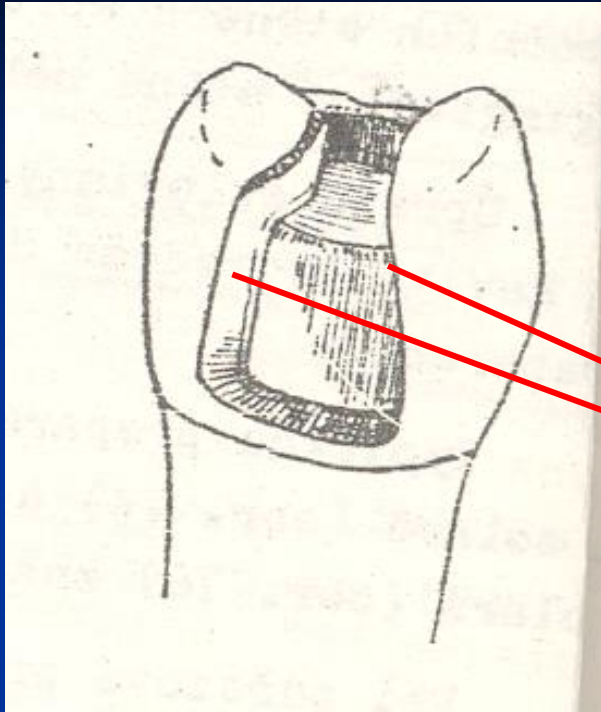


Retention

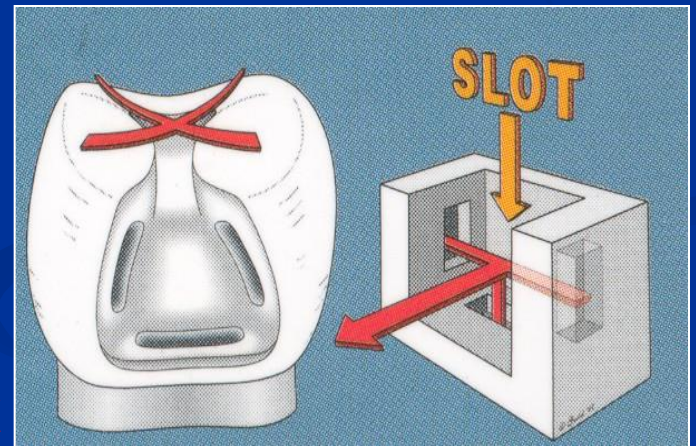
- Occlusal cavity – auxiliary cavity
- Undercuts
- Grooves



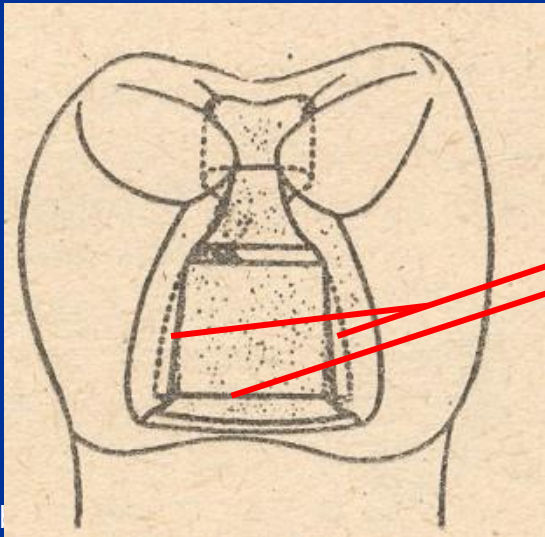




Autoretention



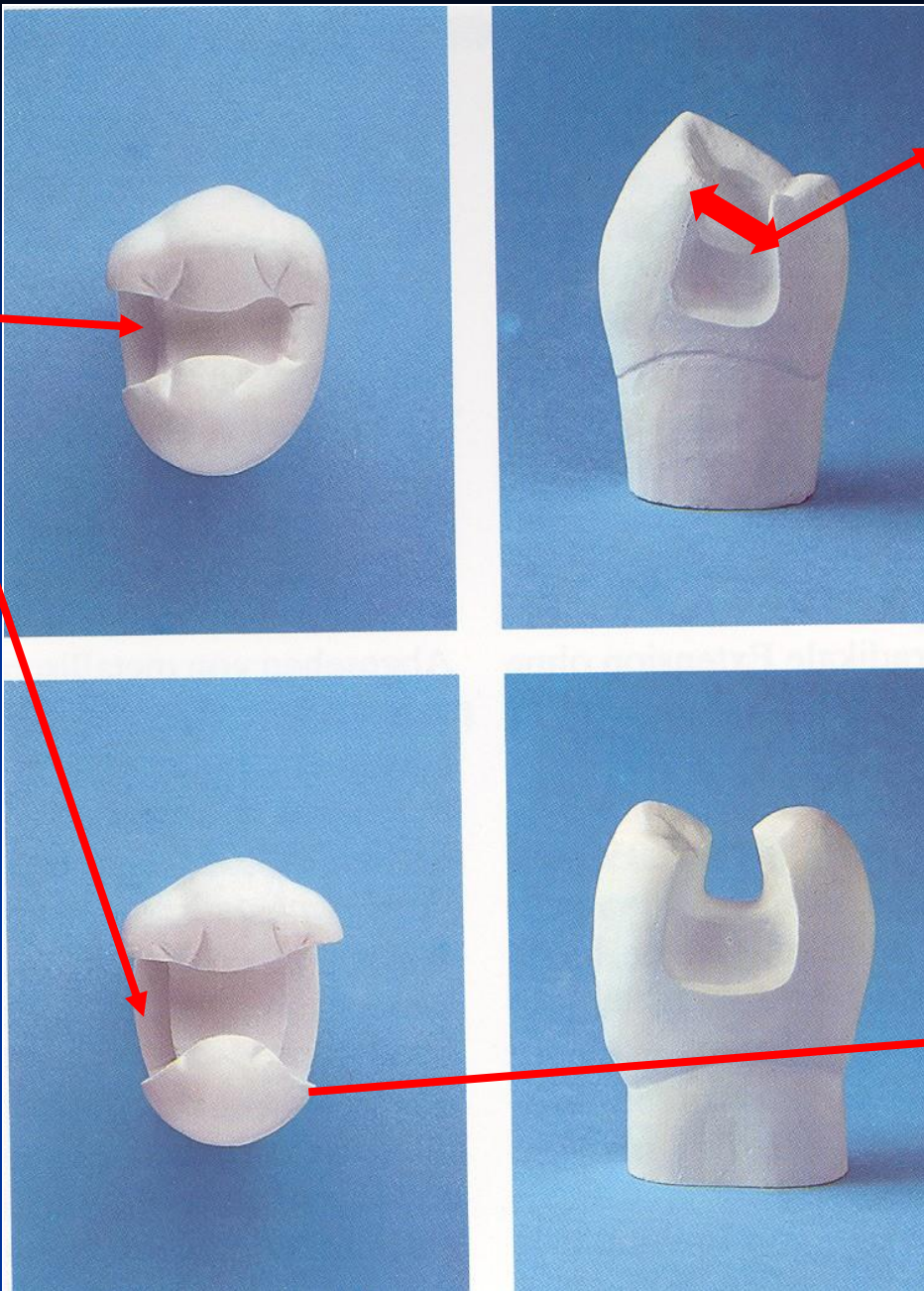
Grooves



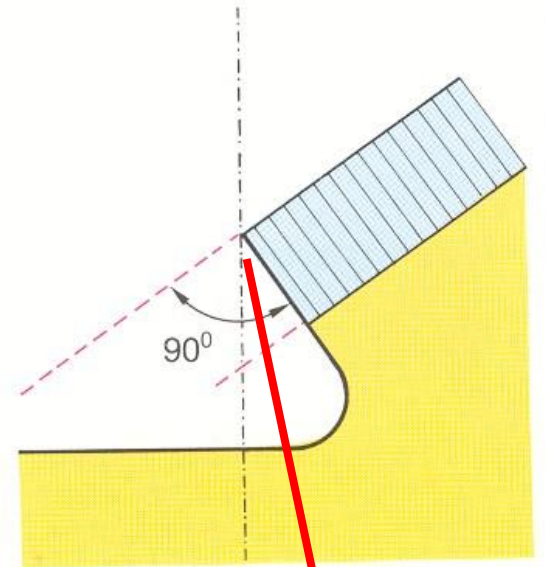
Resistance

- No undermined enamel
- No sharp wedges
- Isthmus is $1/3 - 1/4$ intercuspidal distance
- Angle between axial and gingival wall: 90° , or 85°
- Width of gingival wall is 1 mm at least
- Thickness of the filling 2 – 4 mm (4mm cusp replacing)

G. wall



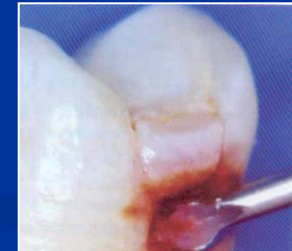
Isthmus



Cavosurface angle

Excavation of carious dentin

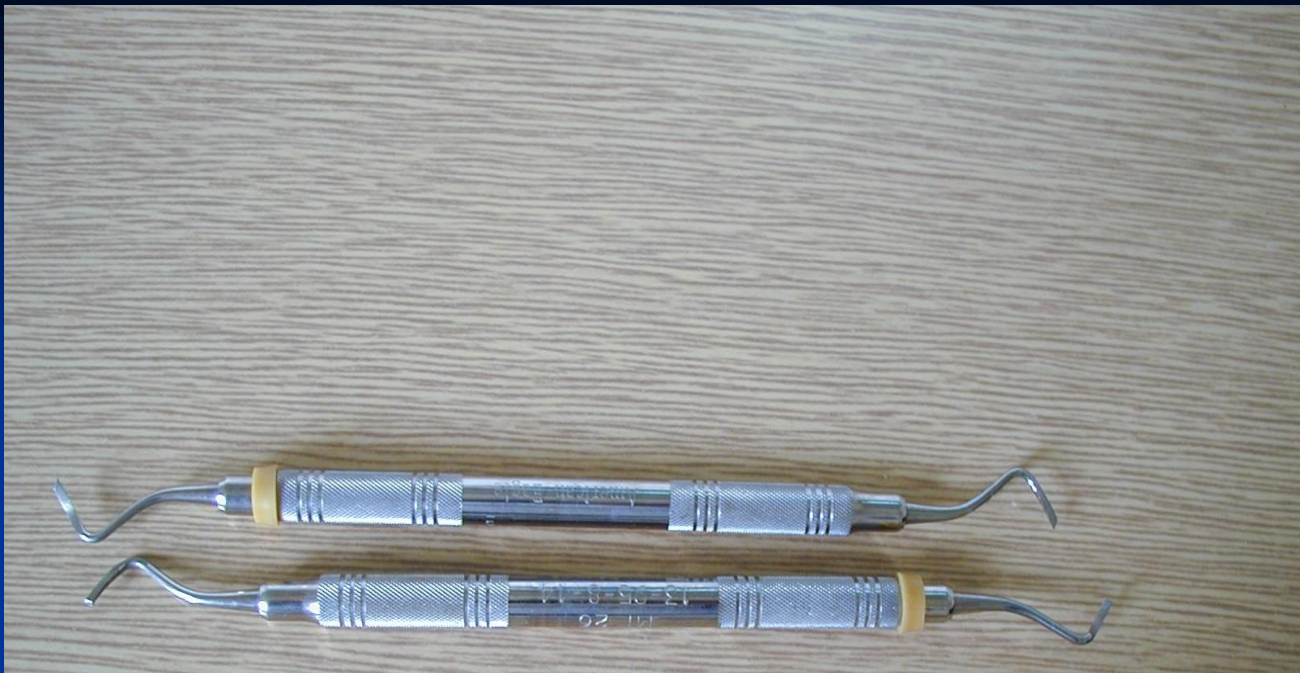
Rounded bur

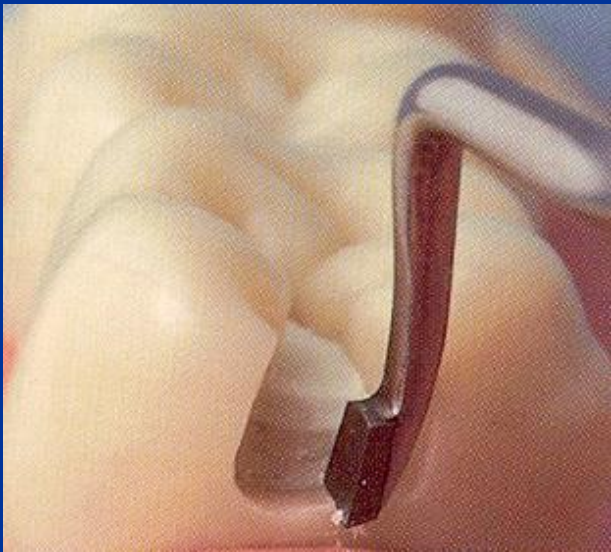
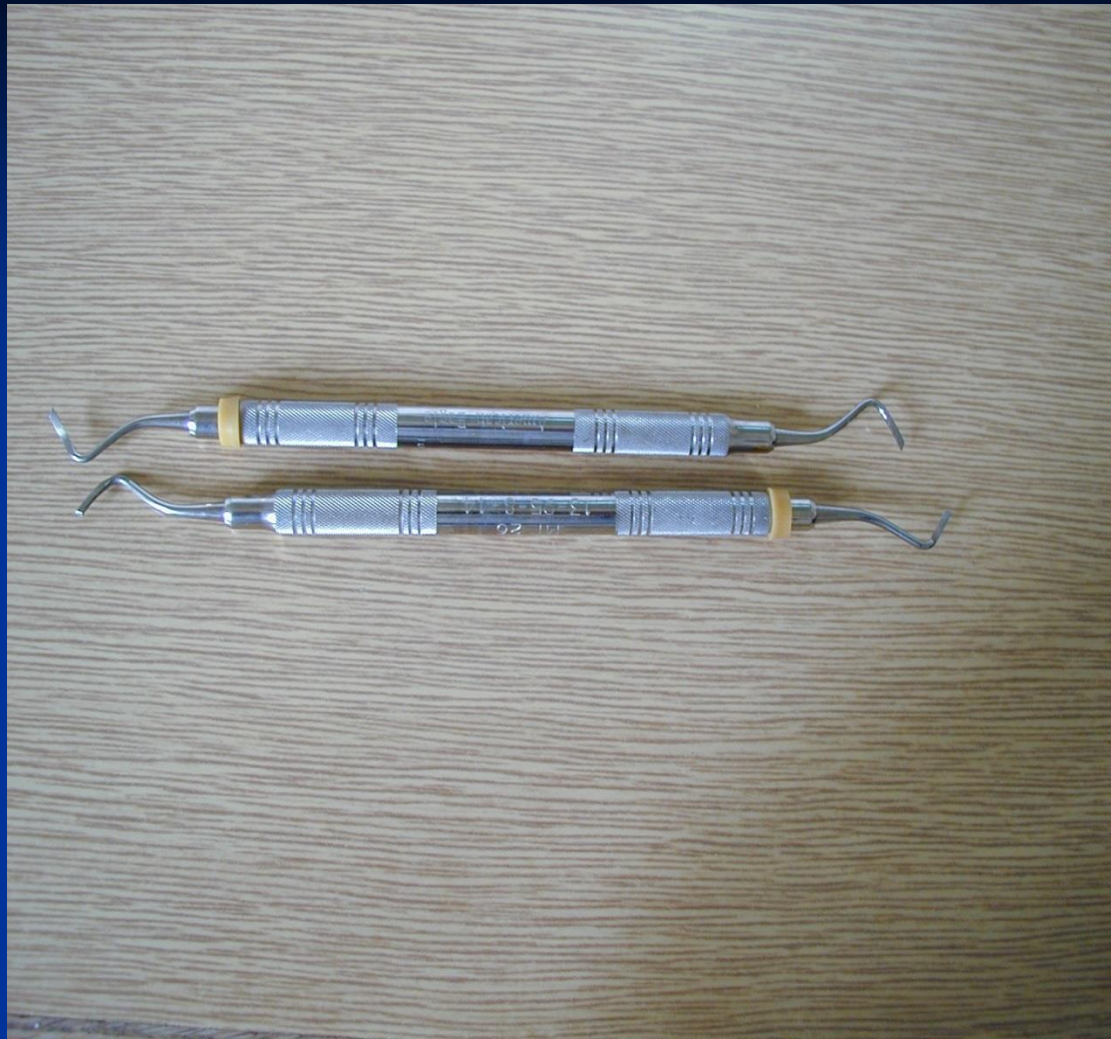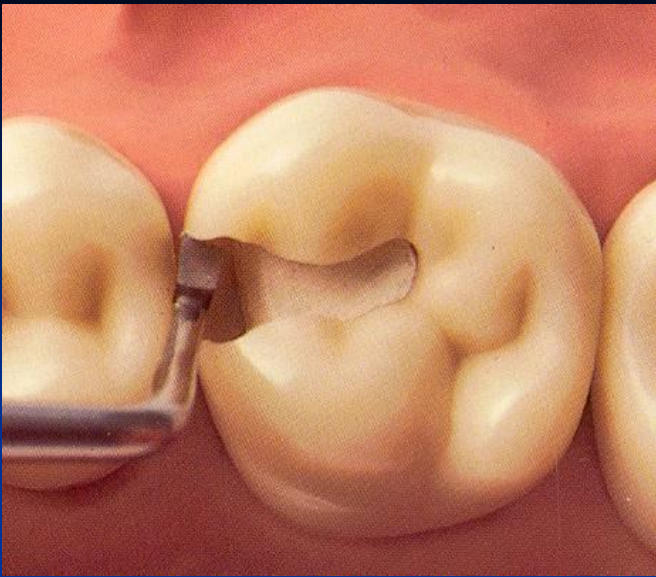


(Caries Detector, Kuraray, Japonsko; Caries Marker, VOCO, Německo)

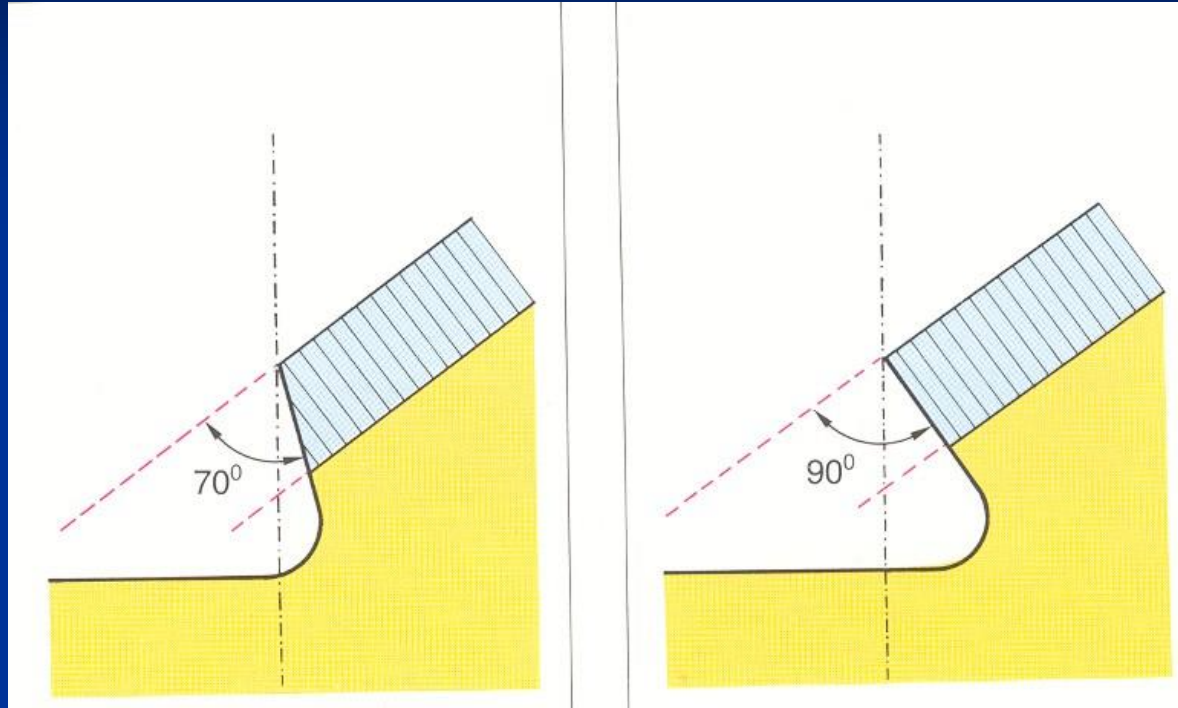
Finishing of cavity walls

- Red coded diamond bur
- Chisel on the gingival wall (if in enamel)





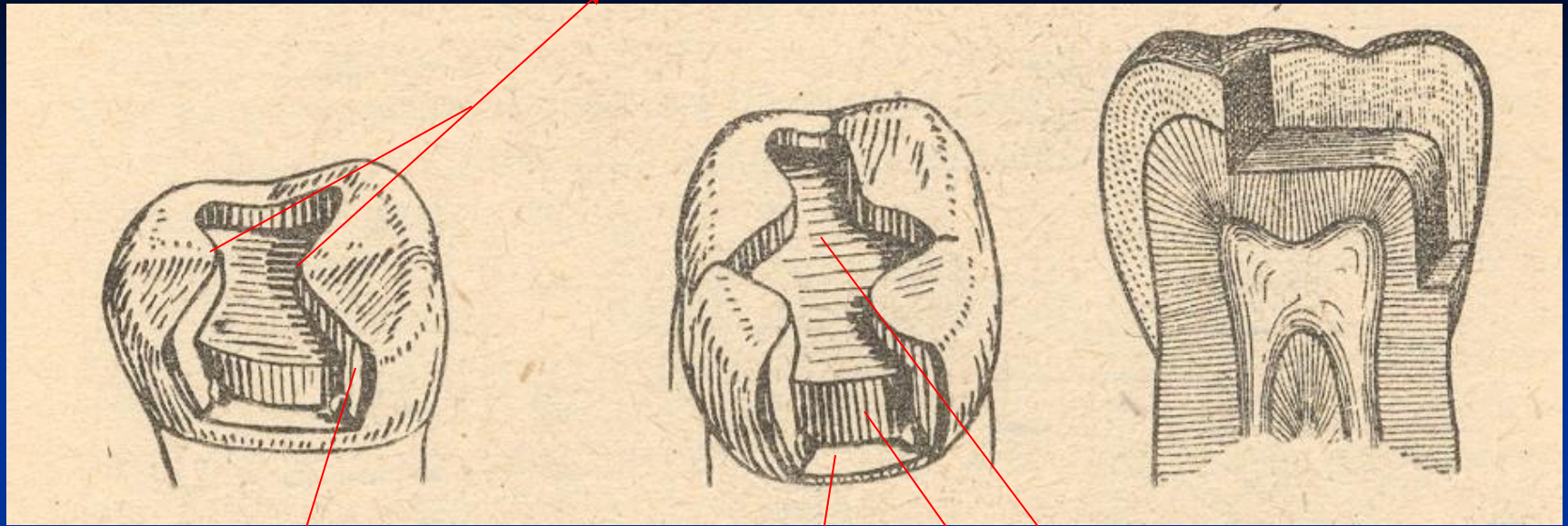




Cavity control

➤ Goog light, miror

Isthmus



Axial wall

Pulpal wall

Gingival wall

Matrix placement

- Matrix primarily is used when a proximal surface is to be restored

The objectives:

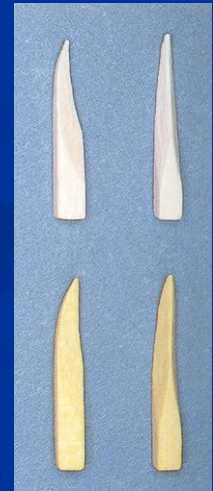- Provide proper contact
- Provide proper contour
- Confine the restorative material
- Reduce the amount of excess material

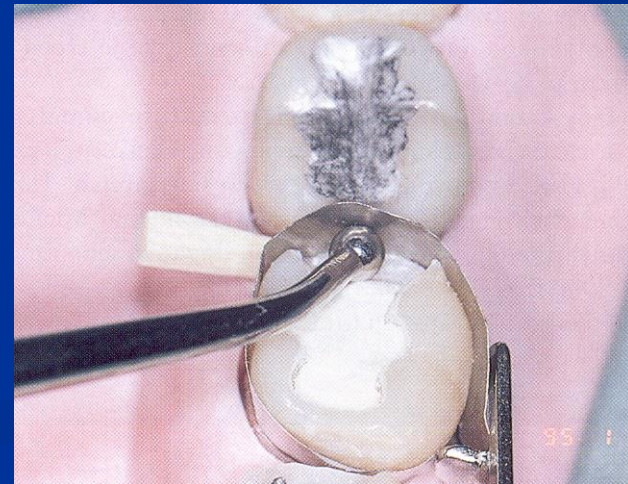
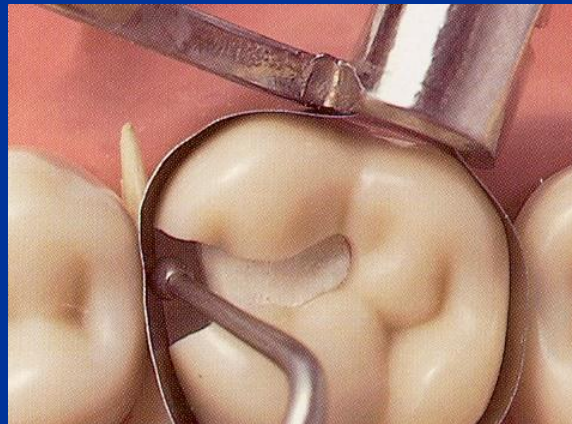
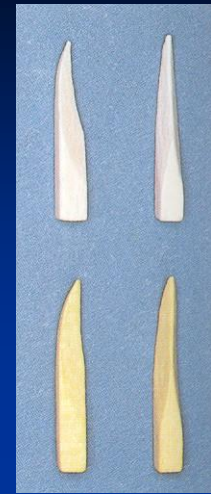Matrices

- Ivory I retainer Ivory 1
- Hawe Neos retainer Ivory 8
- Tofelmire matix and retainer

Wedges

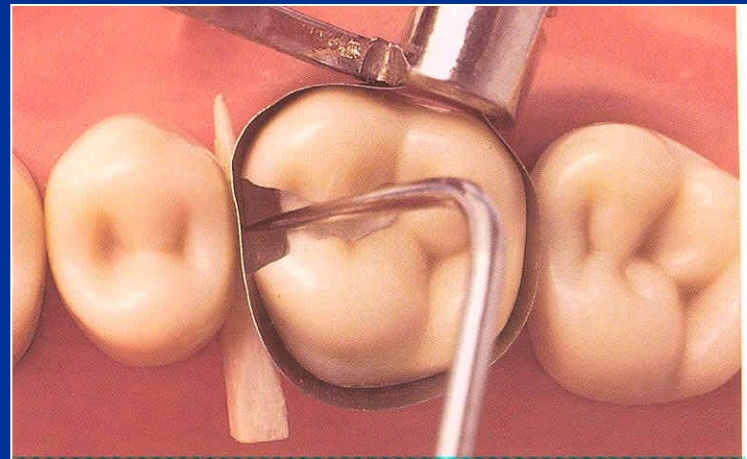
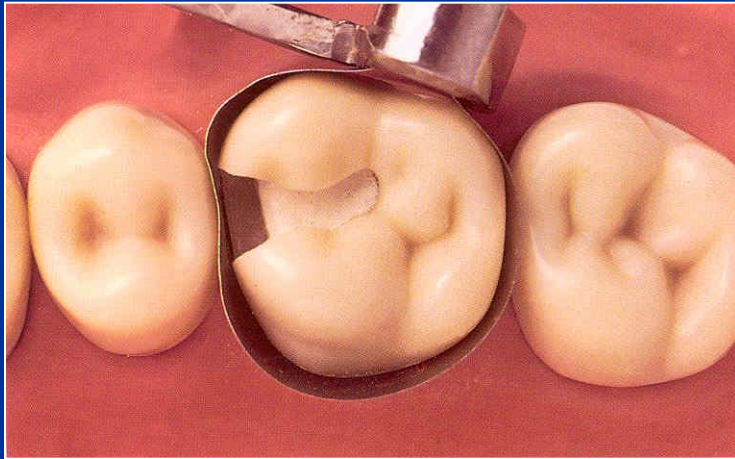

- Wooden wedges
 - tighten the matrix band
 - compress the gingiva
 - separate the teeth







Wedging

- Slip the matrix band over the tooth (apical to the gingiva margin – 0,5, - 1 mm)
- Tighten the matrix, check it with probe
- Place a wedge
- Turn the retainer $\frac{1}{4}$ counterclockwise
- Contour the band



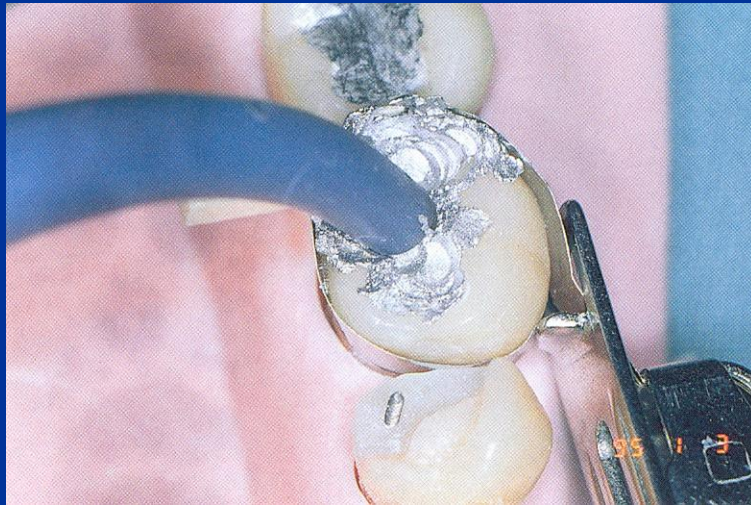
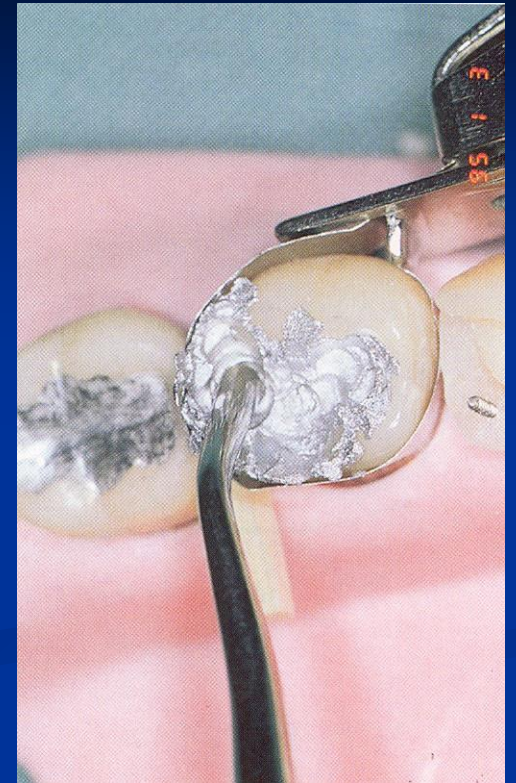


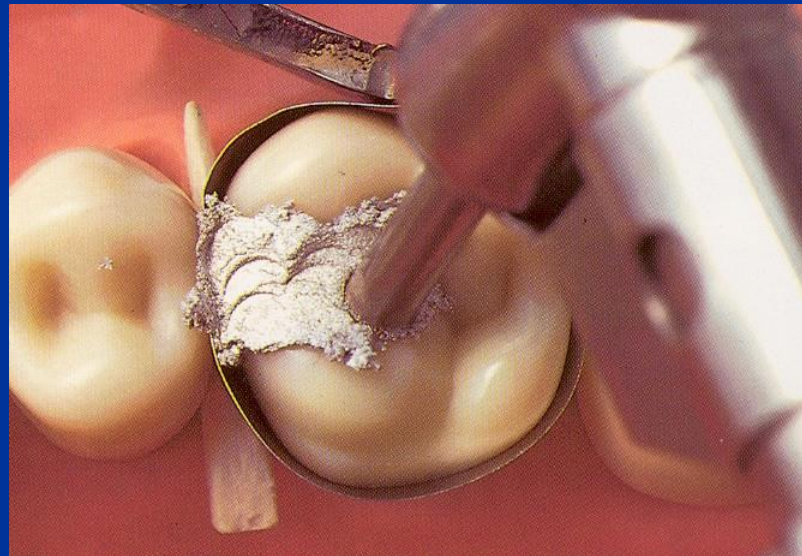
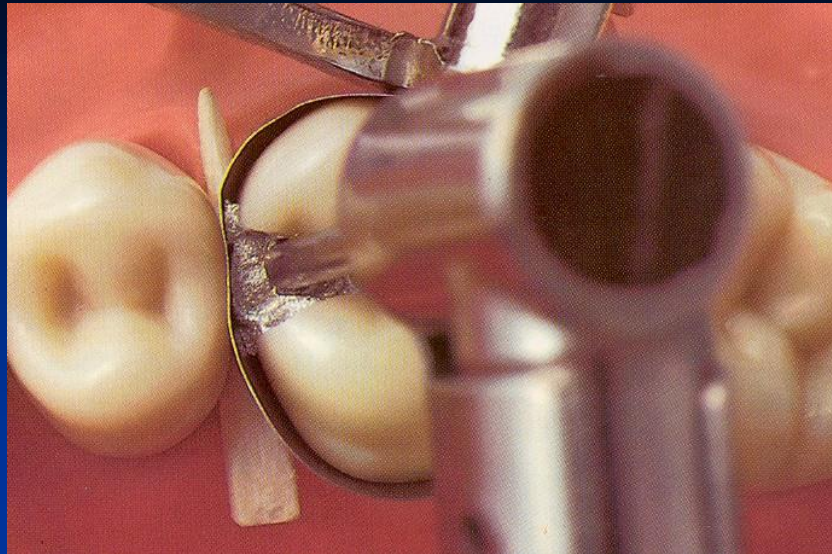
Trituration!

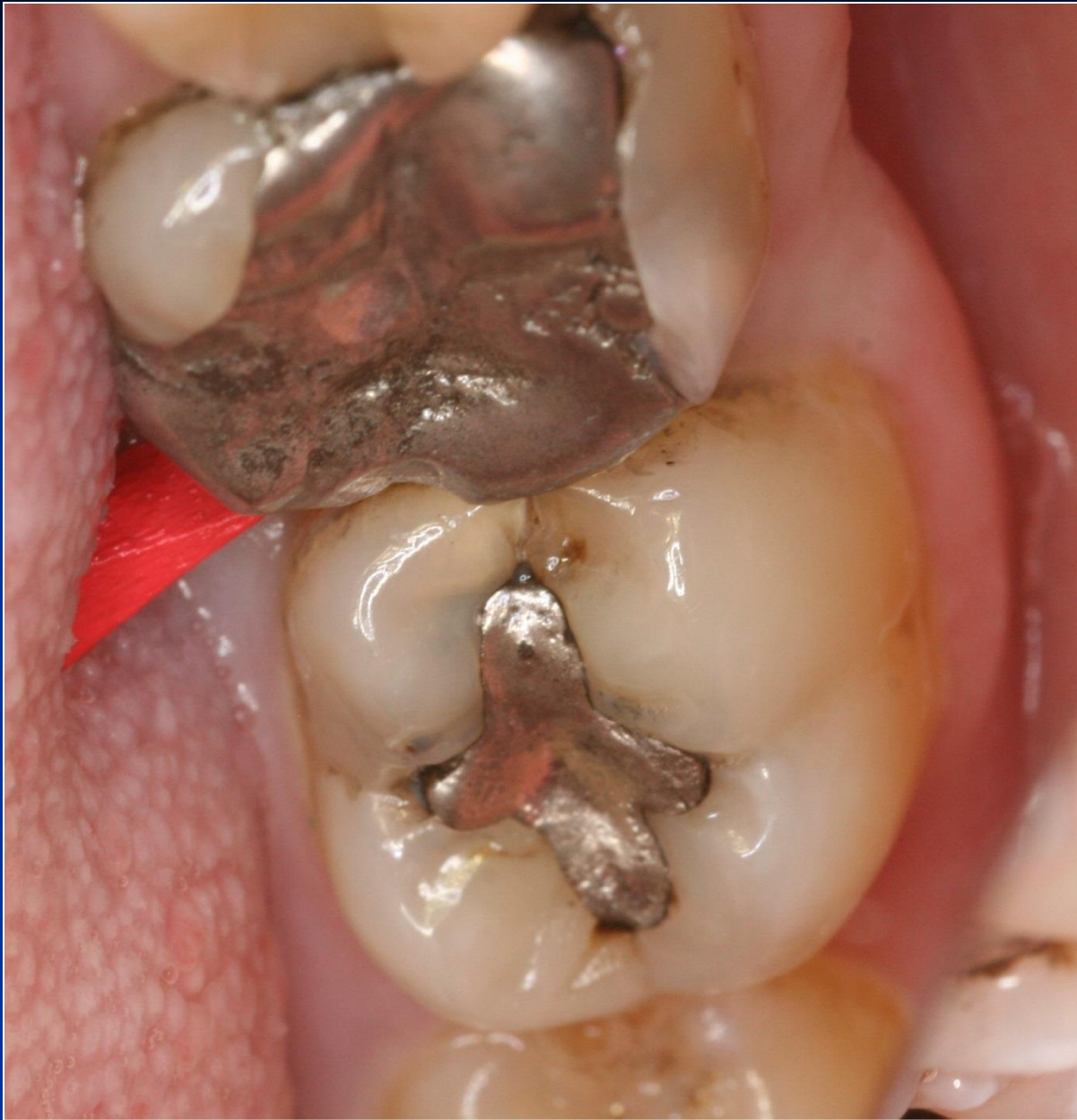Condensation of amalgam

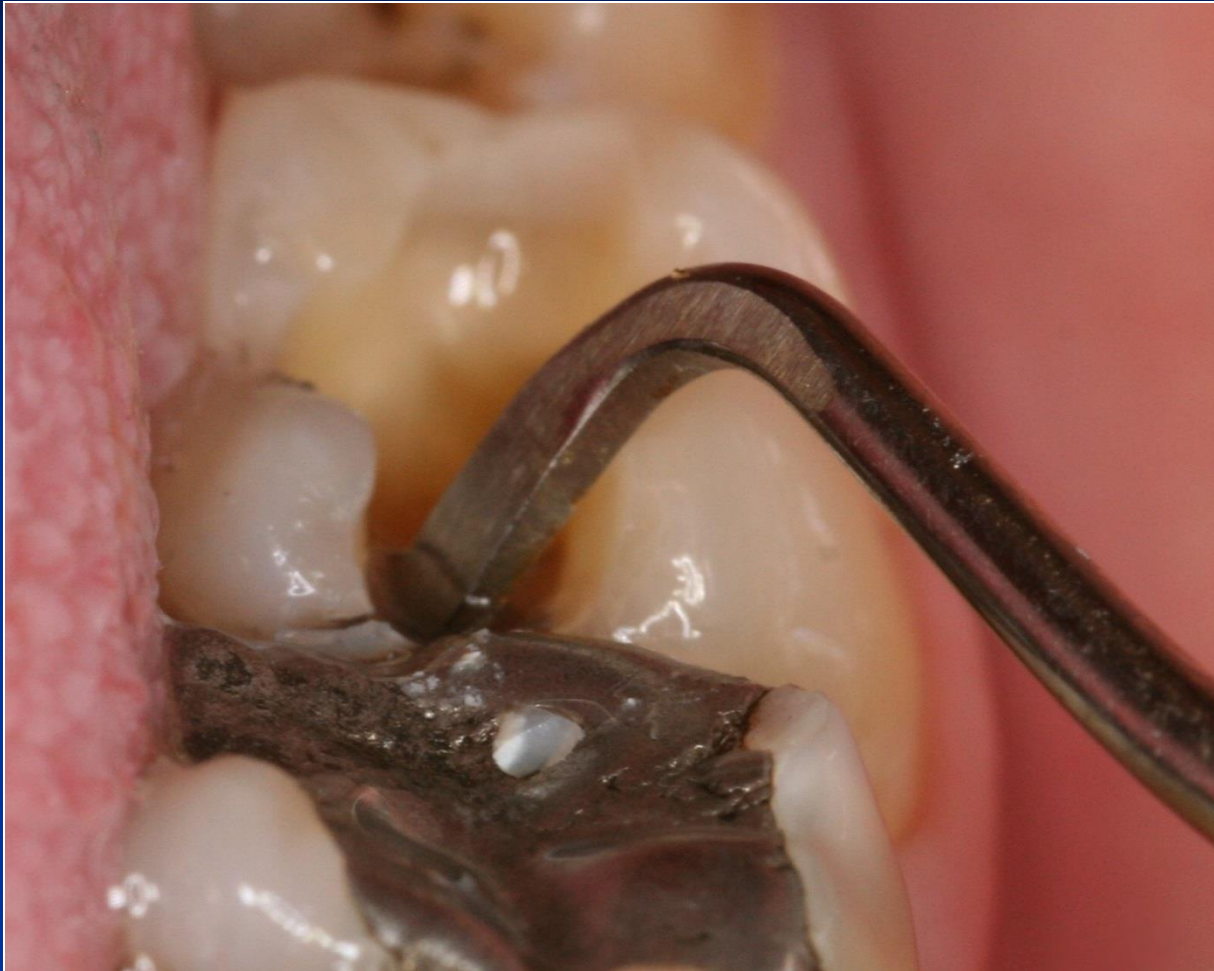- Condensor – stamen is the best one
- Power driven condensation

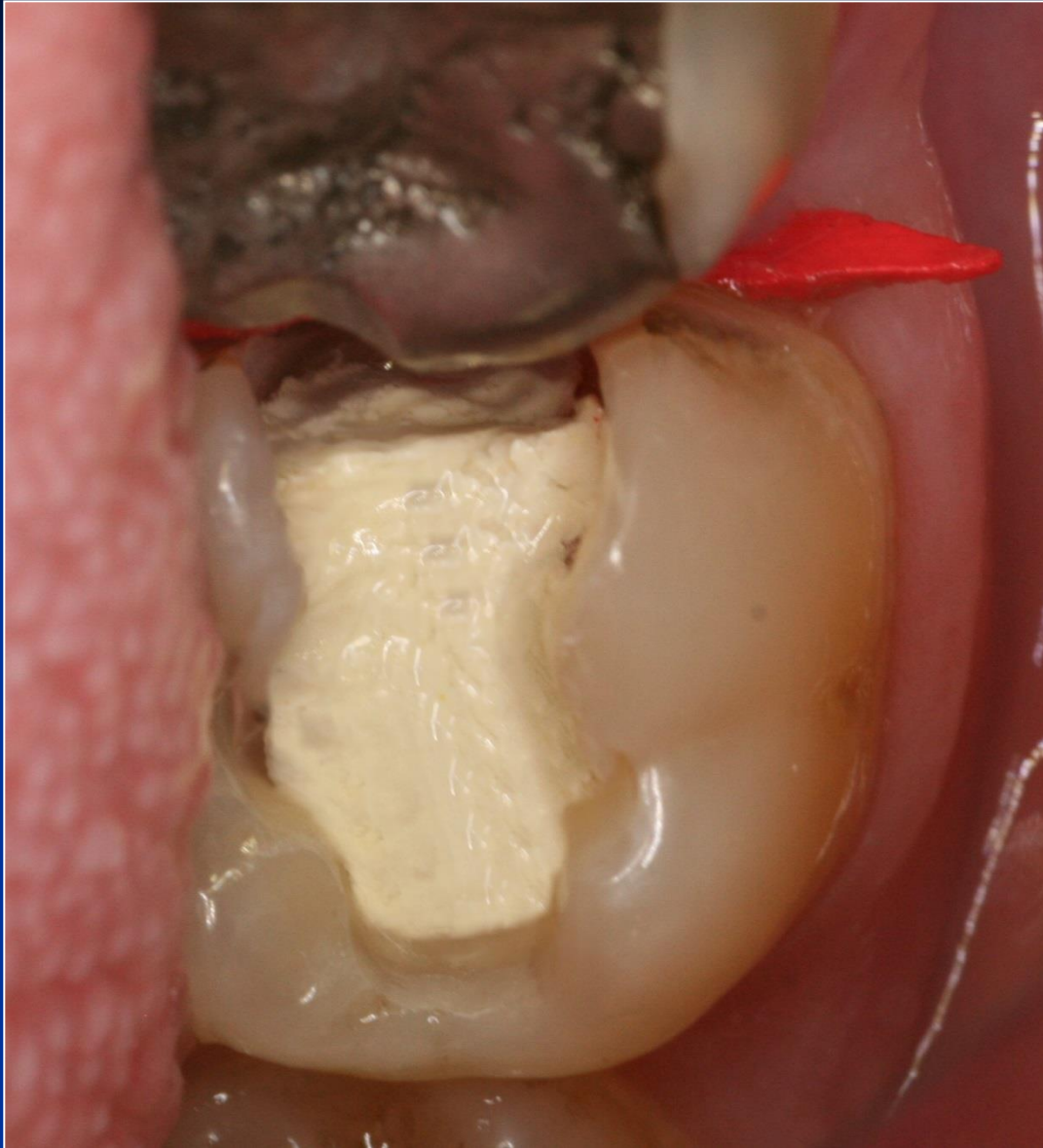How big the stamen should be??

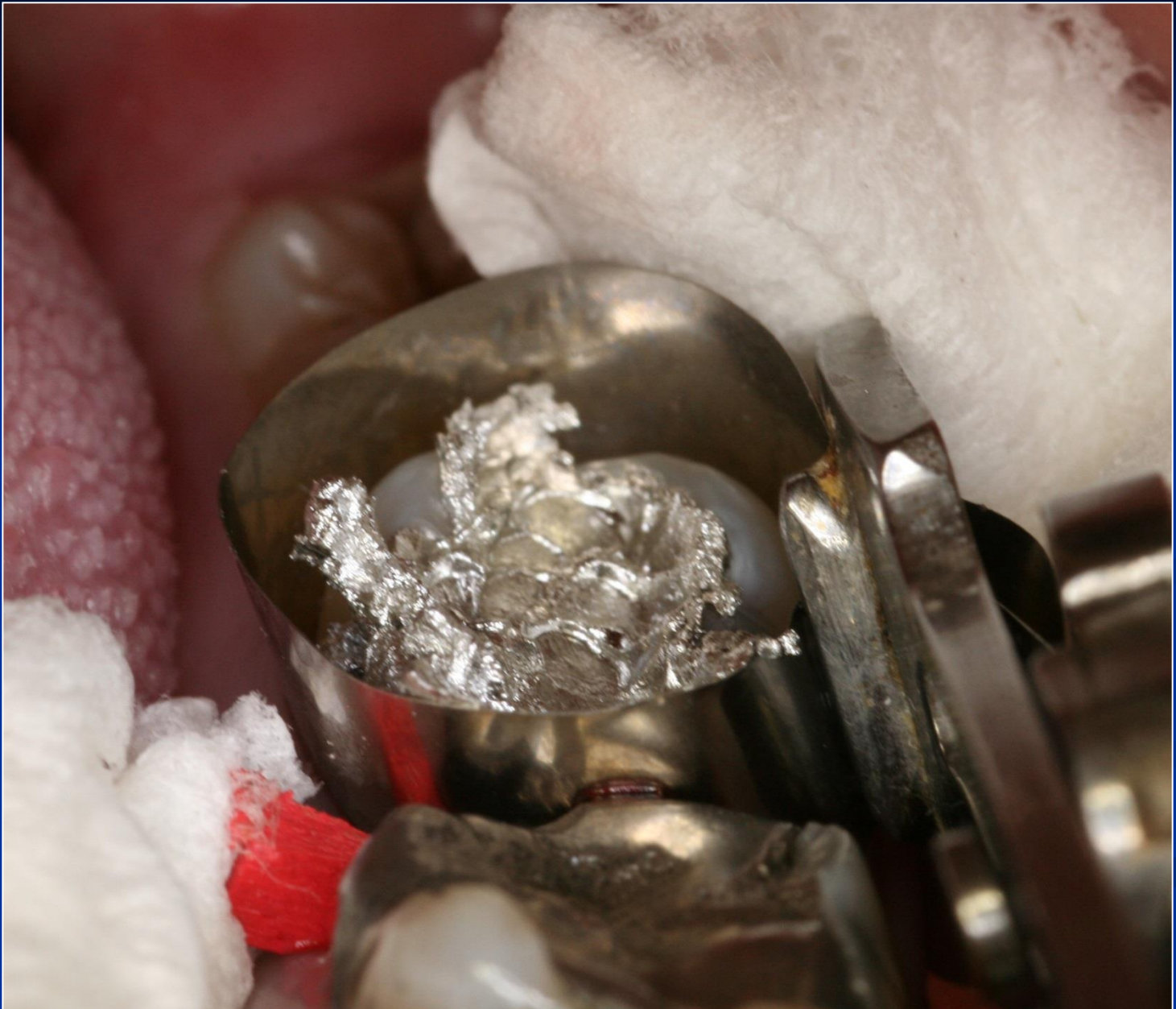


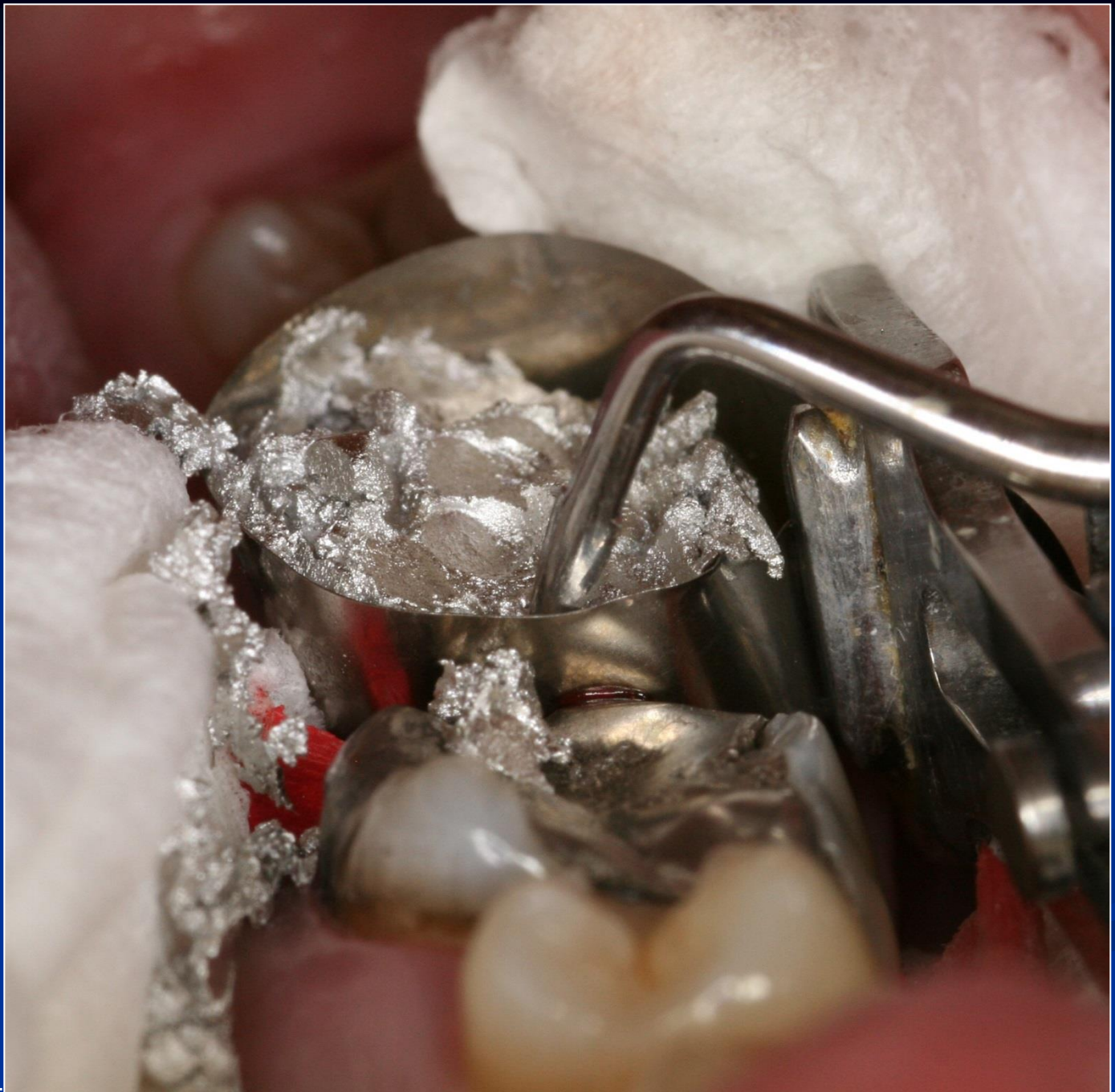


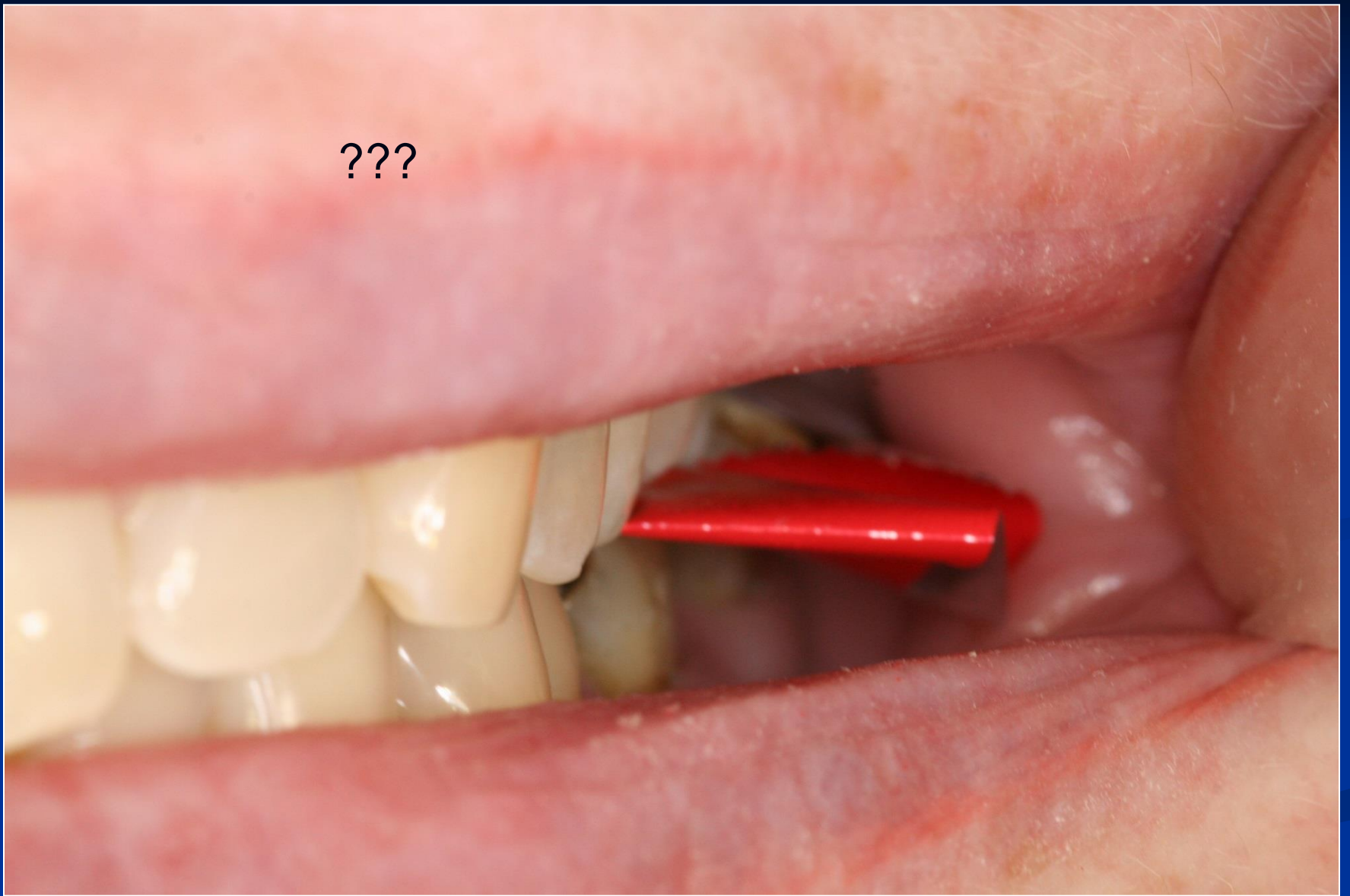




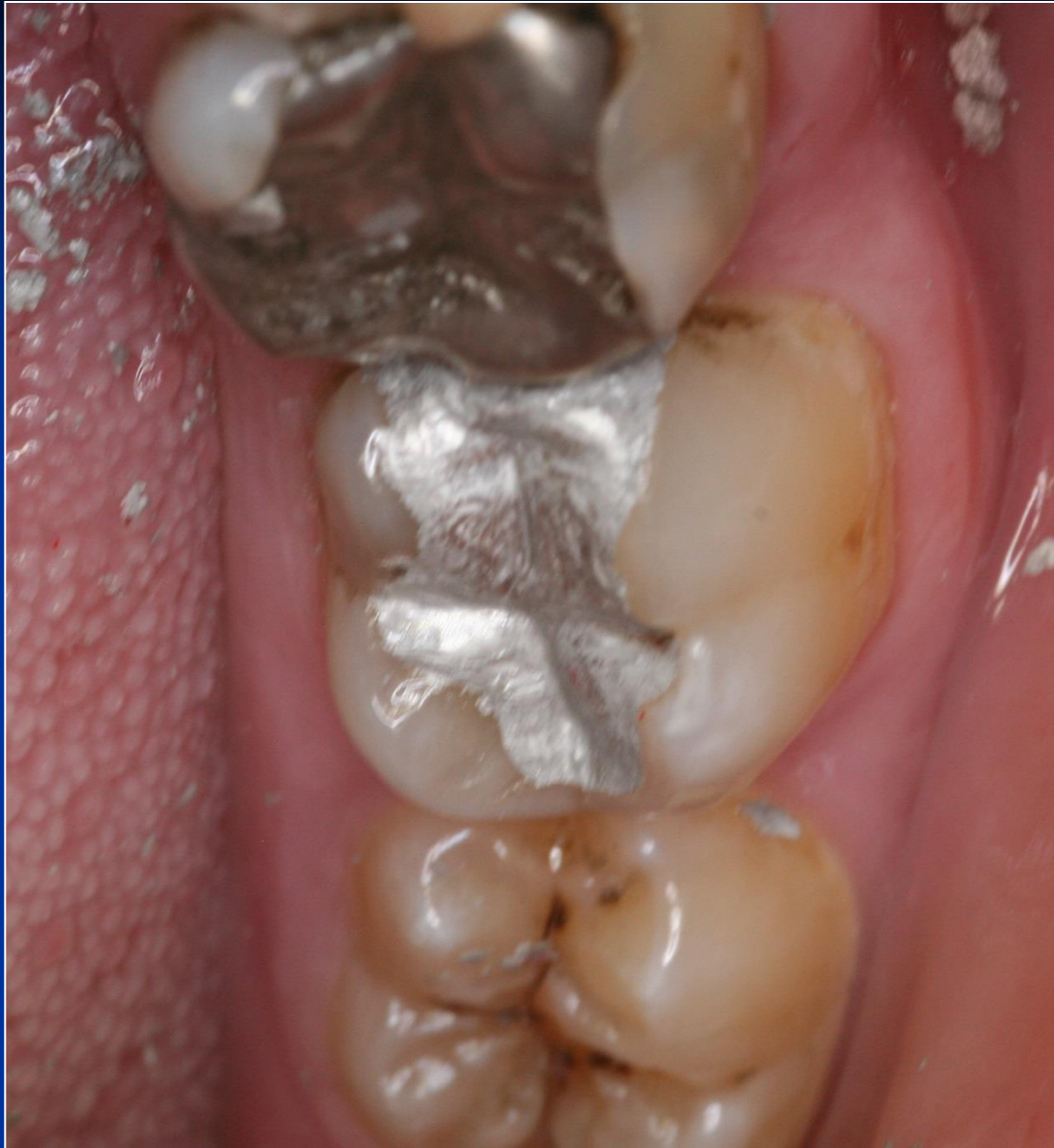



???

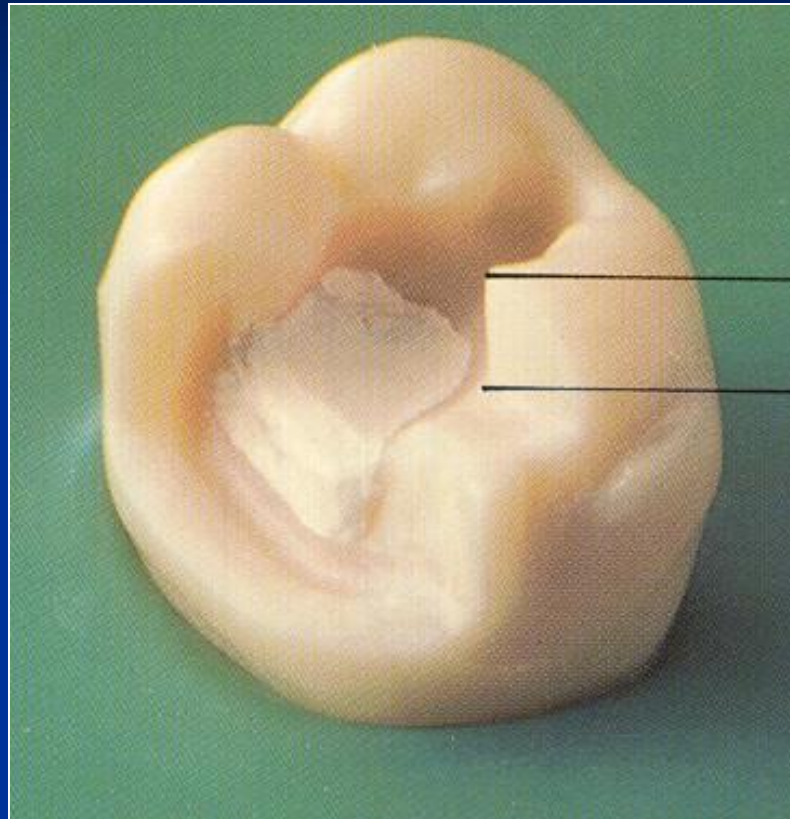


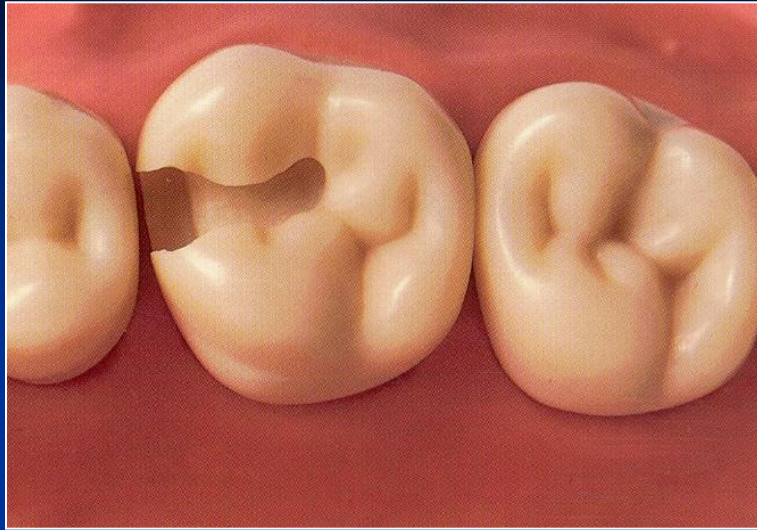


Base

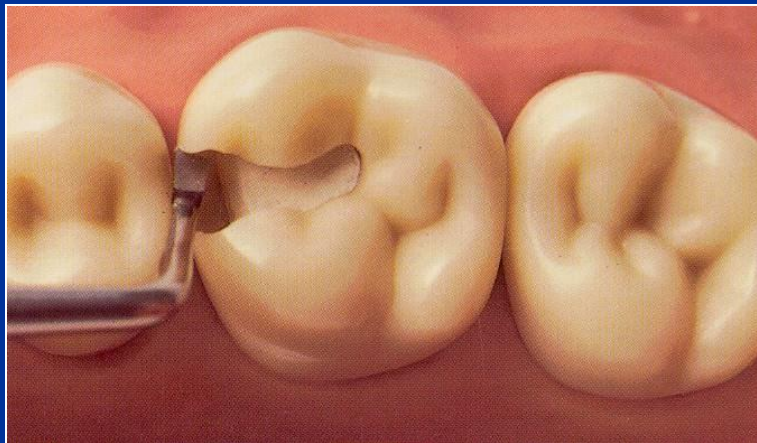
- Zinkoxidphosphate cement
- Zinkoxidkarboxylate cement
- Glass ionomer cement
- Zinkoxideugenol

On pulpal walls only!



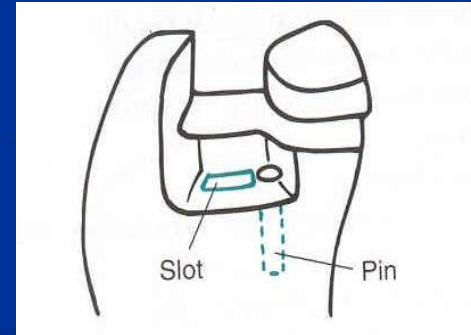
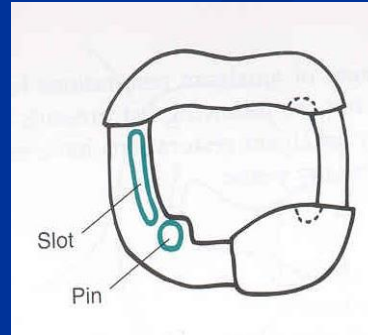
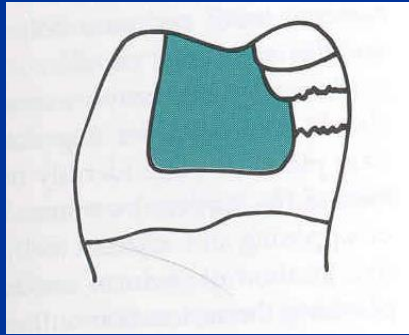
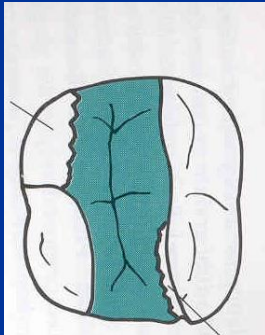


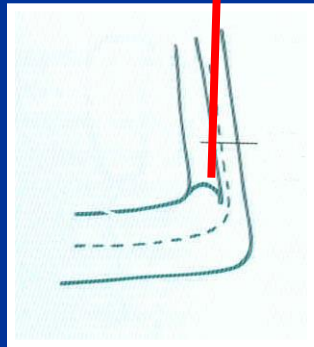
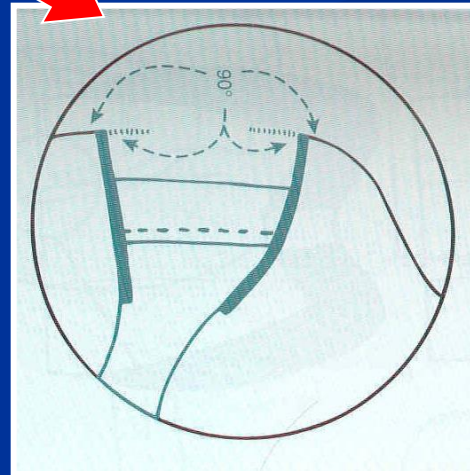
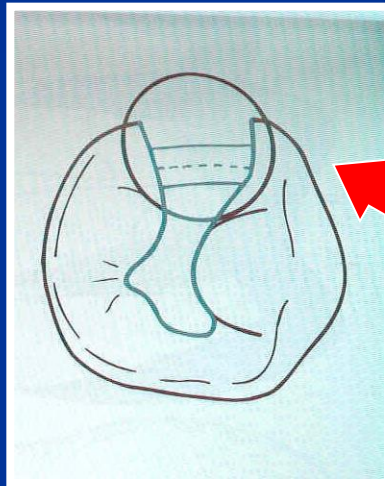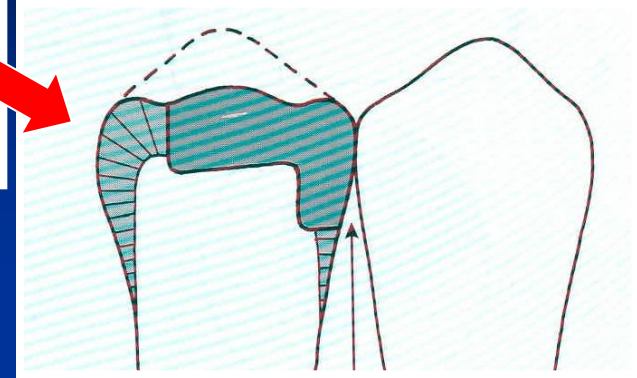
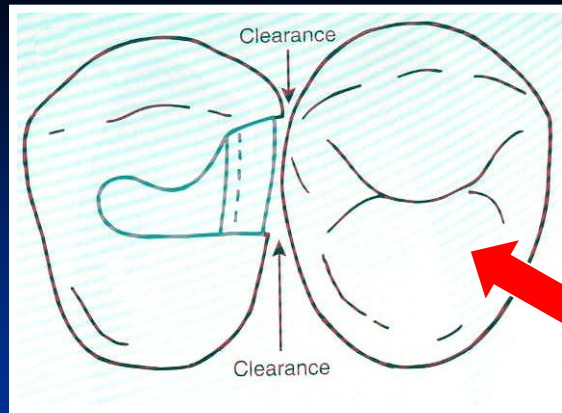
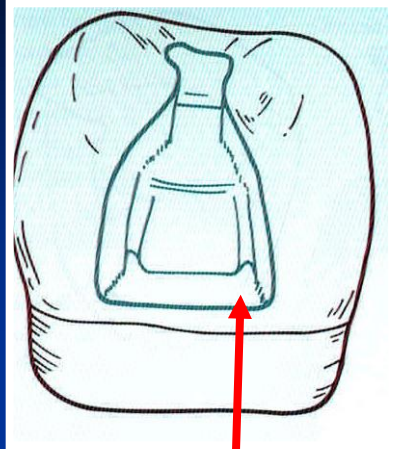
The base must be hardened


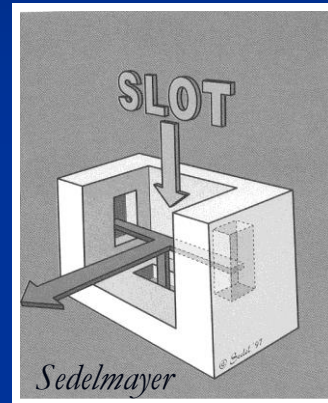
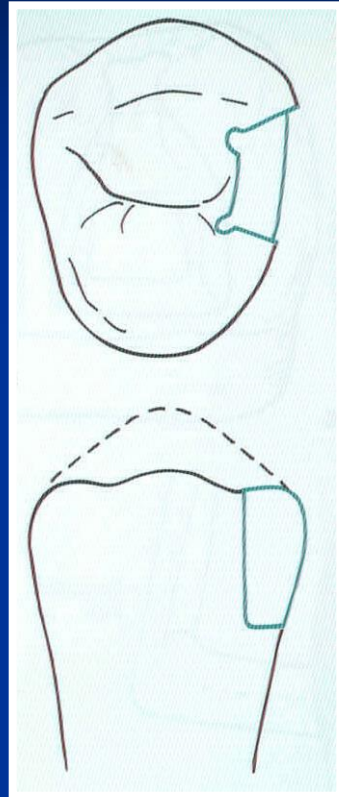
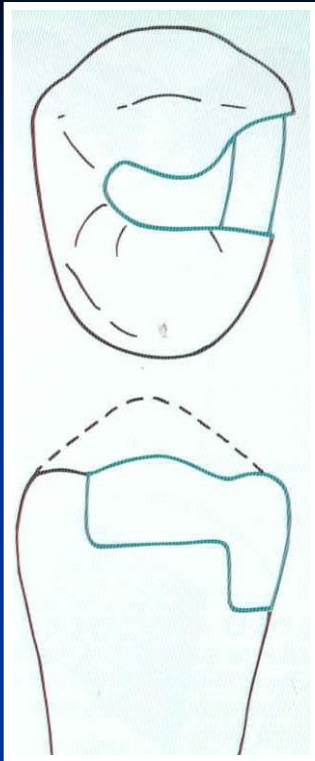


Amalgam

Retention








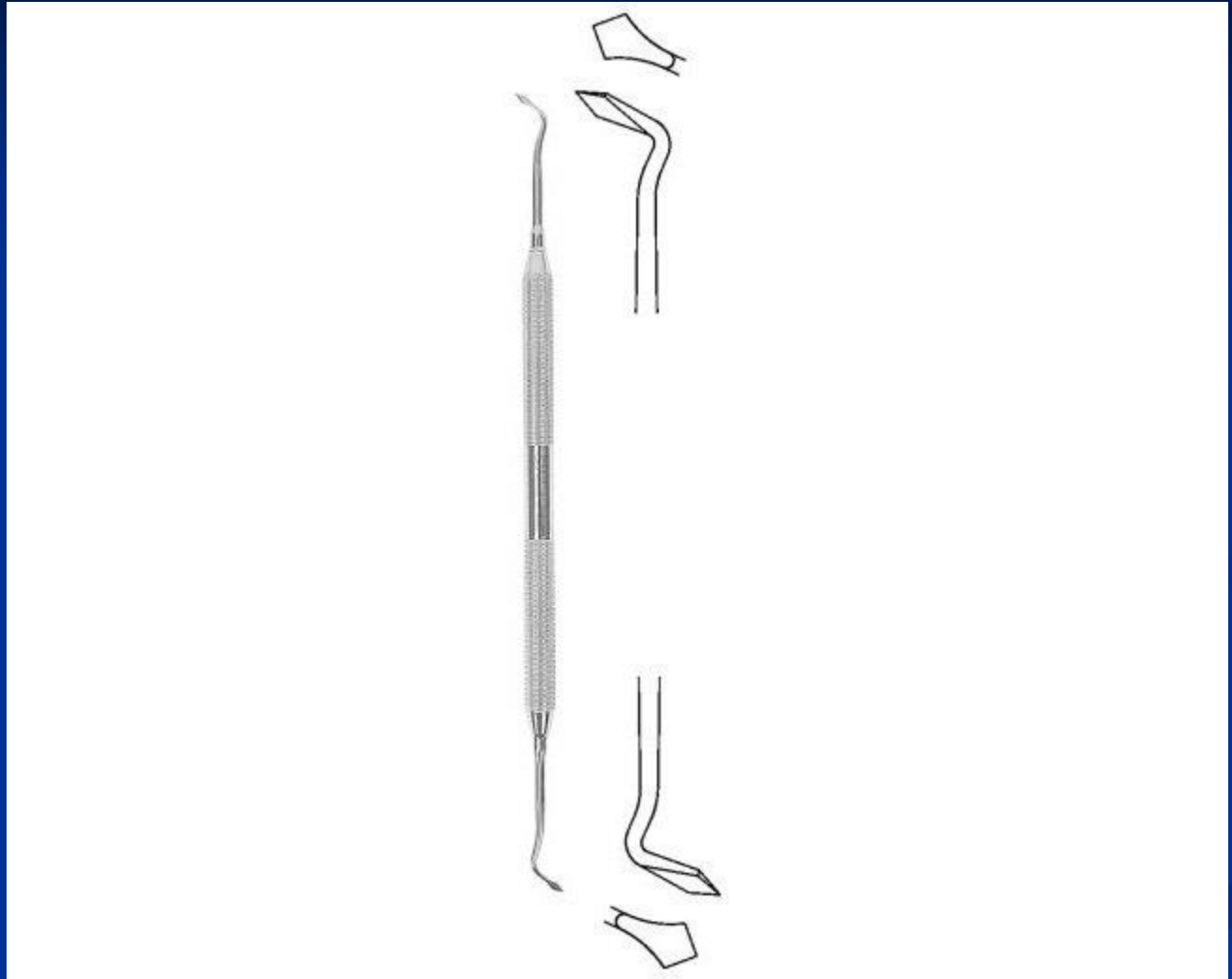
Instruments

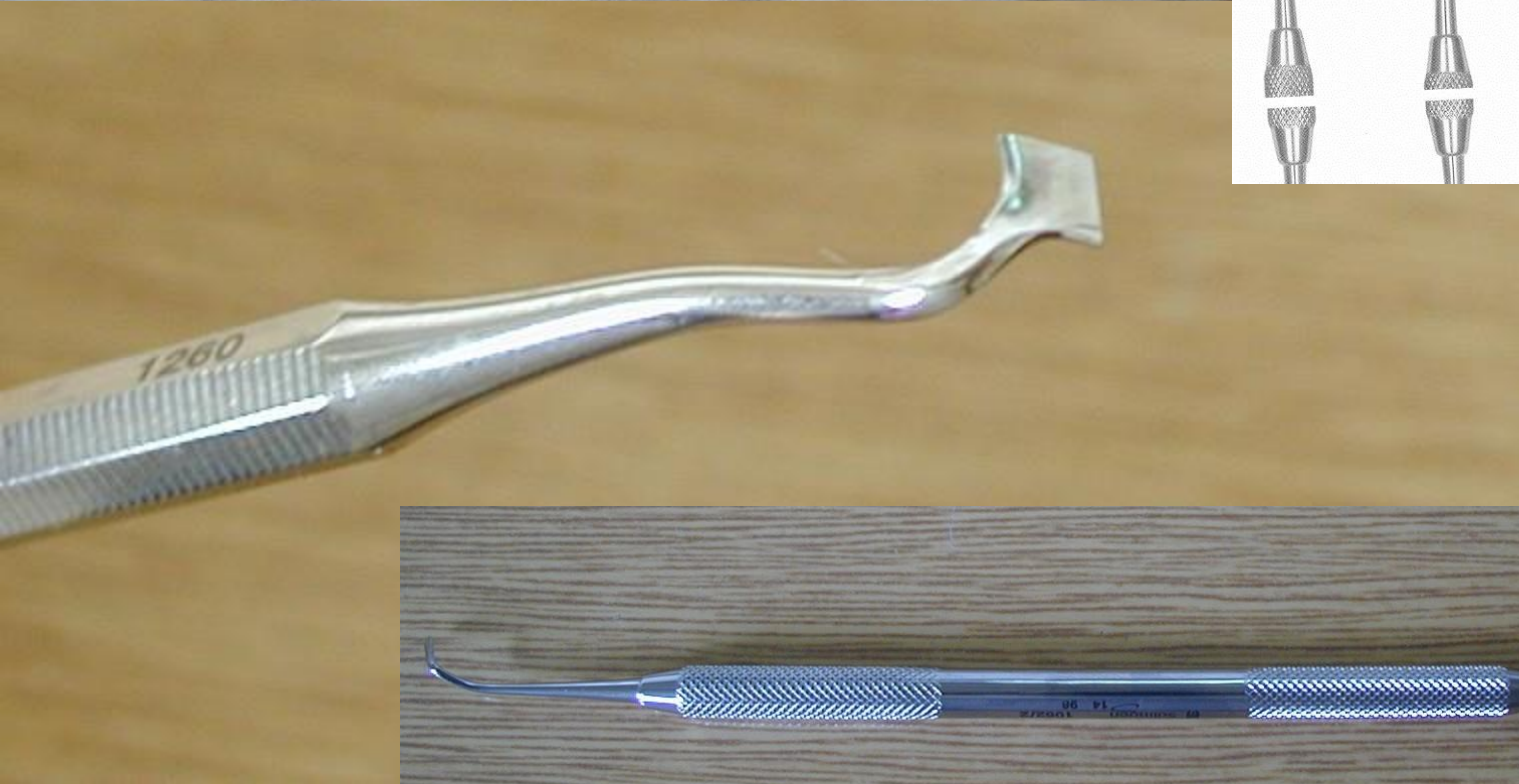
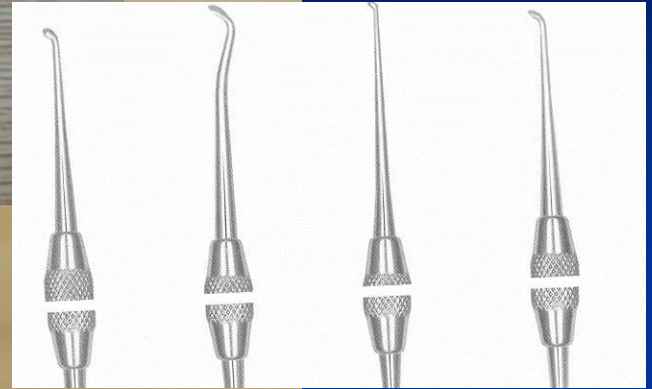
- Preparation
- Filling
- Finishing and polishing

Cpátko tyčinkové



Ořezávač -Frahm






Ořezávač - Sapin



Ořezávač discoid-cleoid



Nosič amalgámu

