

# The respiratory system

# The respiratory system

## Functions:

- **external respiration:** exchange of respiratory gases (CO<sub>2</sub>, O<sub>2</sub>) between external environment and the blood, (**internal respiration** between the blood and the tissues)
- Nasal cavity contains olfactory cells - regio olfactoria
- In larynx: generating of the voice
- Inner opening of Eustachian tube into the nasopharynx

## The upper respiratory tract (head part)

Cavum nasi

Pharynx (hltan)

## The lower respiratory tract (neck and chest part)

The larynx

The trachea (the windpipe)

The bronchi

The lungs

# 1. The upper respiratory tract

## The external nose (nasus externus)

radix nasi

dorsum nasi

apex nasi

alae nasi, nares

septum nasi

### Bony skeleton

ossa nasalia

maxillae

(apertura piriformis)

### Cartilagineous skeleton

cartilago septi nasi

cartilago nasi lateralis

cartilago alaris major

cartilagine alares minores

# **Cavum nasi**

Nares - vestibulum nasi - cavitas nasi propria – choanae

---

## **Septum nasi**

**Bony part- lamina perpendicularis ossis ethmoidalis,  
vomer (bone)**

**Cartilagineous part – cartilago septi nasi (cartilage)**

**Membranous part (skin)**

## **The roof of the nasal cavity**

- **os frontale**
- **lamina cribrosa ossis ethmoidalis**
- **corpus ossis sphenoidalis**

## **The bottom of the nasal cavity**

- **lamina horizontalis ossis palatini**
- **processus palatinus maxillae**

## The lateral wall of the nasal cavity

proc. frontalis maxillae, os lacrimale, os ethmoidale, lamina perpendicularis ossis palatini

**Concha nasalis superior (os ethmoidale)**

**Concha nasalis media (os ethmoidale)**

**Concha nasalis inferior**



They enlarge  
the surface of  
the nasal cavity

## The nasal cavity

meatus nasi (superior, medius, inferior) – are bordered by conchae, in elongation of the meatus inf. lies *ostium pharyngeum tubae auditivae*

choanae – openings of the nasal cavity to the nasopharynx

## The mucosa

Regio olfactoria – on the roof, yellowish colour, olfactory cells (**large as a coin**)

Regio respiratoria – grey-pink colour, ciliated epithelium, rich vascular plexus (plexus cavernosi concharum) - easily bleeds– epistaxis

**The paranasal sinuses**: open out into the nasal cavity, form during the embryonic development

Function: resonance chamber

**Sinus maxillaris – meatus nasi medius**

**Sinus frontalis – meatus nasi medius**

**Sinus ethmoidalis – meatus nasi medius et superior**

**Sinus sphenoidalis – meatus nasi superior**

---

**Ductus nasolacrimalis – meatus nasi inferior**



**Sinus paranasales have clinical importance– inflammations**

**Pharynx (the gullet)** crossing of the respiratory and digestive tract

## **Nasopharynx**

From the base of skull till the soft palate (tuba auditiva, tonsilla pharyngea)

## **Oropharynx (C2-4)**

communication with oral cavity  
(Waldeyer's lymphoepitelial circle)

## **Pars laryngea pharyngis**

(at the level of C6 transition to oesophagus) aditus laryngis in its anterior wall

## **2. The lower respiratory tract**

### **Larynx**

# The cartilages of the larynx

Cart. thyroidea (laminae, cornua,  
linea obliqua)

Cart. epiglottica (petiolus)

Cart. cricoidea (arcus, lamina)

Cartt. arytenoideae (proc.muscularis  
and vocalis)

Cartt. cuneiformes

Cartt. corniculatae

# The joints of the larynx

## Membrana thyrohyoidea

---

## Membrana quadrangularis

(from epiglottis till the arytenoid cartilage, ligg. vestibularia)

## Conus elasticus

(between ligg. vocalia and arcus cartilagineus cricoideae), Lig. cricothyroideum (coniotomy)

## Membrana fibrocartilaginea laryngis

conus elasticus + membrana quadrangularis

---

Ligg. vestibularia (reinforced margin of membrana quadrangularis)

Ligg. vocalia (reinforced margin of conus elasticus)

- stratifies squamous epithelium, yellowish colour
- 



**Ligamentum hyoepiglotticum**

**Ligamentum thyroepiglotticum**

**Joints:**

**Art. cricothyroidea (the oscillative motions)**

**Art. cricoarytenoidea (rotation and sliding movements– base of the abduction and adduction of the vocal cords)**

# The muscles of the larynx

- affect the position, length and tension of the vocal cords and the position of the *epiglottis*

## 1) The muscles regulating the epiglottic cartilage:

- a) Musculus thyroepiglotticus  
opens up *aditus laryngis*
- b) Musculus aryepiglotticus  
encloses *aditus laryngis*



## 2) The muscles regulating the vocal cords:

- a) **Musculus cricoarytaenoideus lateralis**  
adduction of vocal cords – phonatory position
- b) **Musculus cricoarytaenoideus posterior**  
(musculus posticus) abduction of vocal cords – respiratory position
- c) **Musculus arytaenoideus**  
the strongest adductor

---

**m. cricoarytaenoideus  
lateralis**

**m. cricoarytaenoideus  
posterior**

**m. arytaenoideus**

**3) Muscles regulating tension of the vocal cords:**

**a) Musculus cricothyroideus stretches the vocal cords (tensor)**

**b) Musculus thyroarytaenoideus releases tension of the vocal cords**

**c) Musculus vocalis fine regulation of the shape and tension of the vocal cords**

The muscles of the larynx are innervated by *nervus vagus* through:

*nervus laryngeus superior*  
(*musculus cricothyroideus*)

*nervus laryngeus inferior*  
(all other laryngeal muscles)

## Respiratory position

Vocal cords are in  
**abduction**

m. cricoarytaenoideus  
posterior

m. cricoarytaenoideus  
lateralis

## Phonatory position

Vocal cords are in  
**adduction**

---

**Releasing** of v.c. - m. thyroarytenoideus

**Tension** of v.c. - m. cricothyroideus

m. arytaenoideus

---

m. thyroarytaenoideus

m. cricothyroideus

# Larynx

## 1) Vestibulum laryngis

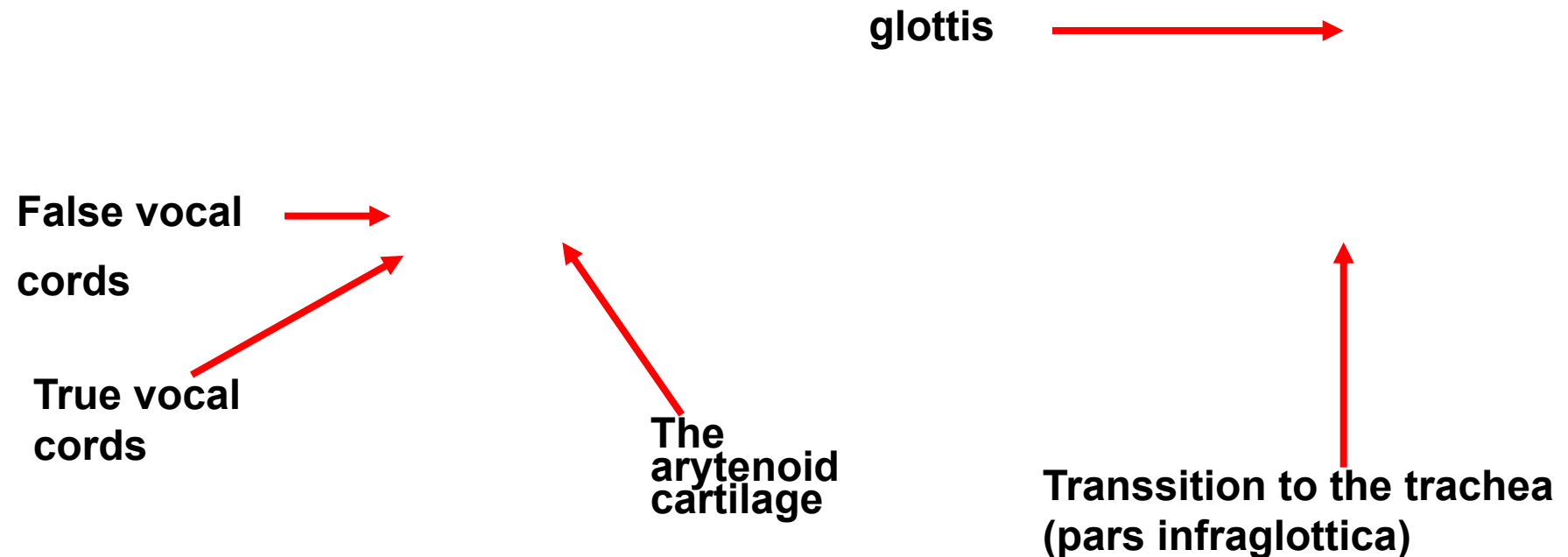
from epiglottis (aditus laryngis) till plicae vestibulares

## 2) Glottis

from plicae vestibulares till plicae vocales

**rima glottidis** – sagittal fissure between the vocal cords

## 3) Cavitas infraglottica



# The laryngoscopic view

**laryngoscopy**

**Respiratory  
position**

**Phonatory  
position**

# Trachea (The windpipe)

Pars cervicalis (C6- C7)

Pars thoracica (Th1-Th4)

*Newborn from C4*

*Child from C5*

---

Bifurcatio tracheae (Th4)

= 1. division of the bronchial tree

Carina tracheae

length 10-11 cm, diameter 12 mm

# Trachea (C6–Th4 or 5)

**Cartilagine tracheales (15-20, horsehoe shape)**

**Ligamenta anularia**

**Paries membranaceus (fibrous tissue, smooth muscles)**

**Ciliated columnar epithelium**

**Trachea divides by Th<sub>4-5</sub> into: main (primary) bronchi**

**Bronchus principalis dexter**

**Bronchus principalis sinister**

shorter, wider

→ **Foreign body intrudes in  
75% to the right bronchus**

**(bronchial tree– arbor  
bronchiales)**



**Syntopy: *in front* thyroid gland, *behind* oesophagus**

**Infrahyoid muscles**



**Thyroid gland**



**Prevertebral muscles**



**Cervical vertebra**



**oesophagus**



# The coniotomy, The tracheotomy

← Coniotomy (lig. cricothyroideum)  
← Tracheotomy superior and inferior  
←

Coniotomy  
Tracheotomy superior  
Tracheotomy inferior

# Arbor bronchiales

**Bronchi principales** divide into:

- **bronchi lobares** (right 3, left 2) - secondary bronchi
- **bronchi segmentales** ( 9-10 sin., 10 dx.) – tertiary bronchi

(the pulmonary segment is of pyramidal shape, the apex is located in the area of the pulmonary hilus, segmentectomy)

The last section form:

- **bronchioli terminales** (<1mm, have no reinforcement, the wall is formed by smooth muscles – they can enclose the bronchial lumen)

---

## Arbor alveolaris – breathing compartment of the lungs–

exchange of breathing gases

- **bronchioli respiratorii**
- **ductuli alveolares** – atrium - **sacculi alveolares** - **alveoli pulmonis**

Thin-walled tubules

Alveolar sacs

alveoli

**Bronchography**

**Bronchoscopy**

# The lungs - pulmo

## Position of the lungs:

Thorax cavity– pleural cavities

height 20-24 cm, weight 600 – 700g

colour pink– marbling – grey/black

# The lungs (*Pulmo, Pneumon*)

## **Description of the lungs:**

**facies diaphragmatica** - base

**apex pulmonis** - top (reaches above apertura thoracis superior)

**facies costalis** - (impressions of the ribs)

**facies mediastinalis** (hilus pulmonis—dx. BAV, sin. ABV)

**radix pulmonis** – root of the lung

## **Impressions**

**The heart**

**Aorta**

**The oesophagus**

**1. rib**

**Other vessels**

## The left lung

A  
B  
V

## The right lung

B  
A  
V

# HILUM PULMONALE

The left lung

The right lung

A  
B  
V

B  
A  
V



# The lungs (*Pulmo*) - *division*

**fissura obliqua (Th4 – VI.rib)**

**fissura horizontalis (along IV. rib)**

Pulmo dex. 3 lobes (sup., medius, inf.)

Pulmo sin. 2 lobes (sup., in.)

–Incisura cardiaca- lingula pulmonis

**Segments:**

Dextra - 10

Sinistra -10 (smt 8) I. and II. joined  
and VII. v 90% misses

# *The nutritive and functional circulation*

## *The nutritive circulation*

### Aorta thoracica (+ intercostal arteries)

- **rami bronchiales** (1 right – most often from a. intercostalis tertia, 2 left directly from thoracic aorta)  
along the bronchi till bronchioli respiratorii
- **venae bronchiales**  
to v. azygos, v. hemiazygos accessoria, vv. intercostales

## ***The functional circulation – small blood circulation***

right ventricle ➡ truncus pulmonalis ➡ arteriae pulmonales dx.+ sin. (**blood with low content of oxygen**) ➡ capillars ➡ 4 **venae pulmonales** (2 dx., 2 sin.) (**blood with high content of oxygen**) ➡ left ventricle of the heart

# Pneumothorax

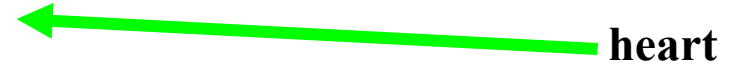# **Xray of the thorax**

# Transsection through the thorax on the level of hilus

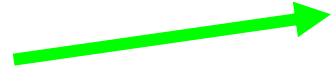pulmonis

(bottom view)


sternum



heart




rib



v. azygos



oesophagus



aorta

**CT of the thorax (Th<sub>4</sub>)**  
**bottom view**

**sternum**




**bifurcatio  
tracheae**



**rib**




**Th<sub>4</sub>**



**oesophagus**



**aorta**



**PLEURA** – serous membrane (simple squamous epithelium)

**pleura visceralis** (covers the surface of the lungs)

**pleura parietalis** (covers the pleural cavities)

Both lungs are located in the separate cavities  
**cavum pleurae dextrum et sinistrum**

a) **Pleura costalis**

b) **Pleura mediastinalis**

c) **Pleura diaphragmatica**

**Recessus pleurales**

– parts of pleura pass into each other

**Cupula pleurae**

– protrudes above 1. rib and the clavicle



## **Recessus pleurae**

- 1) Recessus costodiaphragmaticus–pathological effusions collect there**
- 2) Recessus costomediastinalis**
- 3) Recessus phrenicomediastinalis**

## The mechanism of the breathing

Breathing in (inspiration) using the diaphragm and mm. intercostales ext.

Breathing out (expiration) used mm. intercostales int. and intimi

### Inspiration- active

- Contraction of the diaphragm – enlargement of thorax in the longitudinal direction
- Contraction of mm. intercost. ex. – enlargement of thorax in the sagittal direction
- Pressure drop in pleural cavity
- The lungs follow the movement of the thorax and the air goes to the lungs

## **Expiration - passive**

- **Relaxation of the diaphragm (contraction of abdomen muscles)**
- **Contraction of mm. intercostales interni and intimi, decrease of the ribs – expiration**

# Respiratory muscles

- **Muscles of inspiration**

- **Main:** mm. **intercostales externi**, **diaphragma** (mm. **scaleni**, mm. **levatores costarum**)
- **Auxiliary:** m. **pectoralis major + minor**, m. **latissimus dorsi**, m. **serratus anterior + post. sup.**, m. **sternocleidomastoideus**, m. **subclavius**, (m. **sternothyroideus**, m. **sternohyoideus**)

- **Muscles of expiration**

- **Main:** mm. **intercostales interni (+ intimi**, m. **subcostales**)
- **Auxiliary:** m. **rectus abd.**, m. **obliquus abd. ext. + int.**, m. **transversus abd.**, m. **serratus post. inf.**, m. **transversus thoracis**, (m. **quadratus lumborum**)

## **Orientation lines:**

**linea mediana ant.**

**linea sternalis**

**linea parasternalis**

**linea medioclavicularis**

**linea axillaris ant., med., post.**

**linea scapularis**

**linea paravertebralis**

**linea mediana post.**

# **The borders of the pleura**

**Cupula pleurae - 1-2 cm above the clavicle**

**Area interpleuralis superior**

**2. rib – 4. rib parallel, dx till 6. rib, sin. incisura cardiaca**

**Area interpleuralis inferior**

**Medioclavicular line 7. rib**

**Middle axillary line 9. rib**

**Scapular line 11. rib**

**Paravertebral line 12. rib – then to C<sub>7</sub> and to cupula pleurae**

# The borders of the pleura

# The borders of the lungs

- *apex pulmonis* fills *cupula pleurae*, reaches 1–2 cm over the clavicle
- **Anterior margin**: corresponds during the inspiration with the anterior margin of the pleura
- **Inferior margin**: projects about 1 till 2 ribs more cranially than the inferior border of the pleura
- **Posterior margin**: projects laterally from the spinous processes within the range Th11 till Th2.



## The lungs of a newborn

- a newborn can survive the preterm labor between 24. and 28. week (formerly lungs are not yet sufficiently prepared for gas exchange, do not produce surfactant)
- The lungs of a newborn, who done the inspiration, keep afloat, the lungs of stillborn sink to the bottom
- The importance in the forensic pathology

# Regional anatomy of the thorax

## Pleural cavities

Mediastinum: space between the pleural cavities: it contains organs, vessels and nerves, there is also the loose fibrous connective tissue present

## Dividing of the mediastinum:

(border: horizontal plane going through the upper margin of the heart)

1. mediastinum superius (thymus, layer of veins, layer of arteries, trachea)

2. mediastinum inferius

mediastinum anterius (lymph nodes)

mediastinum medium (heart)

mediastinum posterius (oesophagus, aorta, ductus thoracicus, v. azygos et hemiazygos, truncus sympaticus, lymph nodes)

**Obrázky:**

**Atlas der Anatomie des Menschen/Sobotta.**

**Putz,R., und Pabst,R. 20. Auflage. München:**

**Urban & Schwarzenberg, 1993**

**Netter: Interactive Atlas of Human Anatomy.**

**Naňka, Elišková: Přehled anatomie. Galén, Praha 2009.**

**Čihák: Anatomie I, II, III.**

**Drake et al: Gray's Anatomy for Students. 2010**