

Autonomic nervous system

AUTONOMIC NERVOUS SYSTEM

- autonomic nervous system participates in innervation of the visceral part of body, it controls autonomic functions, which takes place independently of our will
- It consists of visceromotor nerve fibers
- It makes sensory innervation of visceral organs, vessels, motor innervation of smooth muscle and myocardium and glandular cells
- It includes neurons of CNS and PNS
- **central part** – **hypothalamus**, reticular formation, medulla oblongata, spinal cord, cortex
- **peripheral part** – nerve fibers (cranial nerves, spinal nerves)

Types of stimuli

- Nuclei within CNS → **visceromotor fibers** – through anterior roots of spinal cord → autonomic ganglia along the spine – to the organs of abdomen, thorax, pelvis
- Free nerve endings in the wall of organs → pressure, thrust, pain- **viscerosensory** → autonomic ggl.- to posterior roots of spinal cord - ggl. spinale or ggl. VII., IX., X. and into visceromotor nuclei

- **Autonomic tracts don't go from CNS directly – they switch over in ganglia outside CNS**
- They are formed at least by two neurons, which switch over in so-called **autonomic ganglion**
- **Preganglionic neuron** : myelinated axon that goes from CNS to autonomic ganglion
- **Postganglionic neuron**: unmyelinated axon that goes from autonomic ganglion as a proper autonomic nerve

- autonomic (visceromotor) nerve fibers are of two types
sympathetic *pars sympathica*
parasympathetic *pars parasympathica*
- Glands and smooth muscle of almost each visceral organ are innervated by both sympathetic and parasympathetic
- One system is usually activating and the other inhibiting
- Exception are **smooth muscle of the skin and skin glands**, which are innervated only by sympathetic

Main functions

- Contraction and relaxation of smooth muscle
- Function of all exocrine and some endocrine glands
- Heart rhythm
- Some metabolic processes

Division of autonomic nerve system

- sympathetic – *fight or flight*
- parasympathetic – *rest or digest*
- enteric system

Sympathetic

fight or flight

Parasympathetic

rest or digest

Pars sympathica: nuclei in CNS and in the spinal cord (C8 – L3)

Pars parasympathica: nuclei in CNS (which belong to the cranial nerves), spinal cord (S2 – S4)

craniosacral system (parasympathetic)

thoracolumbar system (sympathetic)

cranio-sacral system (parasympathetic)

Sympathetic and parasympathetic system differ in the arrangement of ganglia:

Sympathetic ganglia:

- are far from **target organs (at spine)** – paravertebral ganglia – **truncus sympathicus dexter et sinister**

Parasympathetic ganglia:

- **closer to organs (ganglion ciliare, pterygopalatinum, oticum, submandibulare + scattered within organ walls)**

Mediators of sympathetic and parasympathetic system:

- preganglionic – the same (from CNS) – acetylcholine
- postganglionic - sympathetic – noradrenalin
- postganglionic - parasympathetic - acetylcholine

SYMPATHETIC

„thoracolumbar system“

- Arises from the thoracic and lumbar parts of the spinal cord – from nucl. intermediolateralis C8-L3- so-called **thoracolumbar system**
- it leaves the spinal nerve as *ramus communicans albus* - it ends in sympathetic ganglion next to the spine - **preganglionic** section - to **paravertebral ganglia**
- single paravertebral ganglia form *truncus sympathicus*
- from the ganglia arise proper sympathetic nerves, **postganglionic** section
- Sympathetic nerves enter through different way the innervated organs

Functions

- It controls the **catabolic** functions, activates functions of the visceral organs
 - **it accelerates** the heart activity and breathing
 - It causes **contraction** of smooth muscle of vessels within the skin and visceral organs and thereby increases blood pressure
 - **It increases** level of sugar in blood
 - **It expands** pupils (mydriasis)
 - It conversely slows digestion
 - It induces a **state of wakefulness** and it is used in stress reactions

Truncus sympathicus

- ganglion trunci sympathici (21-25) = *paravertebral ganglia*
- rr. intergaglionares
- rr. communicantes albus + griseus
- rr. vasculares – periarterial plexuses
- rr. viscerales=nn. splanchnici - to **prevertebral ganglia**

Cervical part

Thoracic part

Abdominal part

Pelvic part

Cervical part

Ganglion cervicale superius

Ganglion cervicale medium

**Ganglion cervicothoracicum /
stellatum**

- It forms periarterial plexuses around a. carotis ext. et int. – intake of sympathicus to neck and head
- ***nn. cardiaci*** – innervation of the heart

Ganglia thoracica (thoracic part)

- 10 pairs of ganglia
- nn. splanchnici – for smooth muscle of GIT and its vessels
- rr. communicantes grisei - to intercostal nerves
- Branches to heart, lungs, esophagus

Ganglia lumbalia (lumbar, abdominal part)

- 4-5 pairs of ganglia
- rr. communicantes grisei
- nn. splanchnici lumbales
- rr. vasculares

Ganglia sacralia (pelvic part)

- 4 pairs of ganglia
- rr. communicantes grisei – for pelvic organs
- Periarterial plexuses

Prevertebral ganglia and plexuses

- They are formed by fibers arising from paravertebral ganglia
- On the anterior wall of abdominal aorta
- Mixed plexus—
nn. splanchnici + n. vagus

Abdominal aortal ganglia

PARASYMPATHETIC

- **pars cranialis- III.,VII.,IX.,X.** (cranial parasympathetic)
- **pars sacralis S2-S4** (sacral parasympathetic) - **craniosacral system** - ganglia are located close to the innervated organs, preganglionic section is therefore long and postganglionic section is short
- mediator is **acetylcholin** in whole section - cholinergic system

Functions

- **pars cranialis:** most important is parasympathetic part of *nervus vagus* – it innervates the digestive tract till the border between colon transversum and colon descendens in the abdominal cavity
- **pars sacralis:** it innervates the digestive tract from the border between colon transversum and colon descendens till rectum and visceral organs located in the pelvis (urinary bladder, genital organs except gonads)

It controls **anabolic reactions** – preservation of energy, it induces **inhibition of organism:**

- **It slows** heart activity and breathing
- **It decreases** blood pressure
- **It narrows** pupils (miosis)
- **It accelerates digestion**, sweating and salivation
- It is used especially **at rest (sleep)** and during digestion

Parasympathetic = craniosacral system

- **Nuclei of cranial nerves:**
 - ncl. oculomotorius accessorius** to ganglion ciliare (m. sphincter pupillae, m. ciliaris)
 - ncl. salivatorius superior** (VII.) to ganglion pterygopalatinum and submandibulare (lacrimal gland, mucosa of nasal cavity, palate, tongue, gl. sublingualis and submandibularis)
 - ncl. salivatorius inferior** (IX.) to ganglion oticum (glandula parotis and small salivatory glands of cheek)
 - ncl. dorsalis n. X** (together with n. vagus to organs)
- **ncl. intermediolateralis S2-4** (pars sacralis, pelvica) – to pelvic organs nn. **splanchnici pelvici**

ganglia are located within the skull or organs walls

Ganglion ciliare

- Here end preganglionic fibers of *n. oculomotorius*
- **parasympathetic** (*m. sphincter pupillae, m. ciliaris*)
sympathetic (*m. dilatator pupillae*)

Ganglion pterygopalatinum

- Here end preganglionic fibers of *n. facialis*
- *Mucosa of posterior part of nasal cavity, upper teeth, mucosa of hard palate, lacrimal gland*

Ganglion submandibulare

- Here end preganglionic fibers of *n. facialis*
- *gl. sublingualis, gl. submandibularis, salivary glands of tongue and bottom of oral cavity*

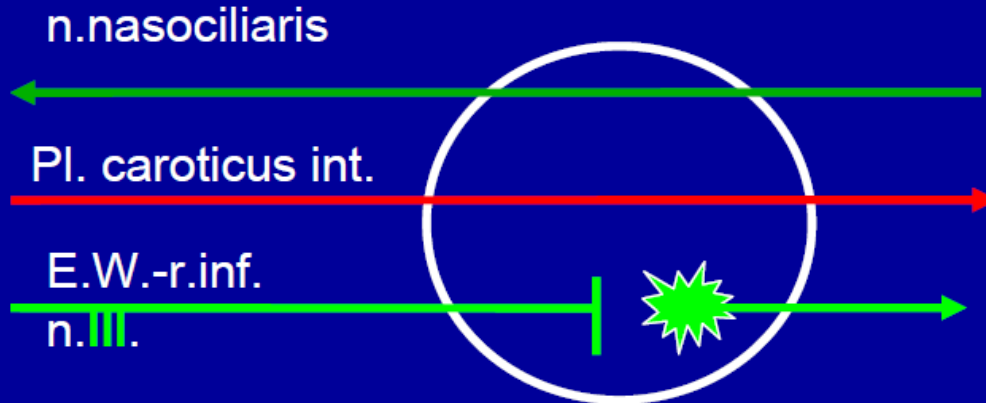
Ganglion oticum

- Here end preganglionic fibers of *n. glossopharyngeus*
- *skin, mucosa, teeth and gingiva of lower jaw, gl. parotidea*

Preganglionic fibers of ***n. vagus*** end in prevertebral ganglia of thoracic and abdominal cavity

Preganglionic fibers of ***sacral parasympathetic*** are switched over in pelvic plexuses

Ggl. ciliare



nn.ciliares breves

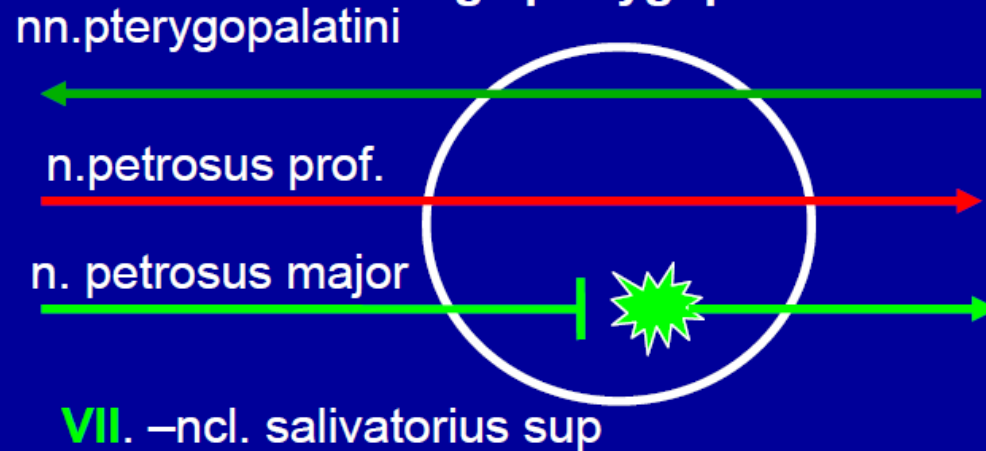m.dilator pupillae

mydriasa

m.sphincter pupillae, m. ciliaris

Miosa, akomodace

Ggl. pterygopalatinum



rr.nasales posteriores sup. et inf.

n.palatinus major

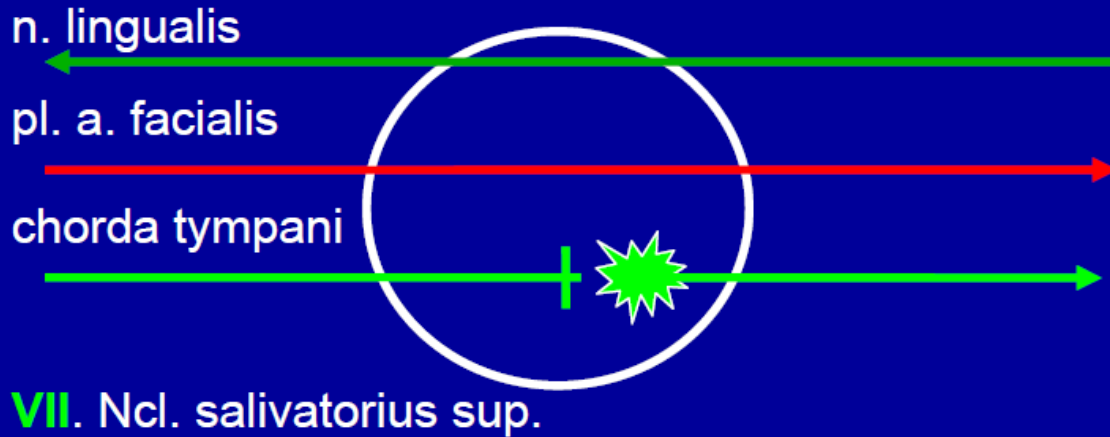
nn.palatini minores

Žlásky dutiny nosní a patra

r.communicans cum n. lacrimali

Glandula lacrimalis

Ggl. submandibulare



rr. glandulares pro

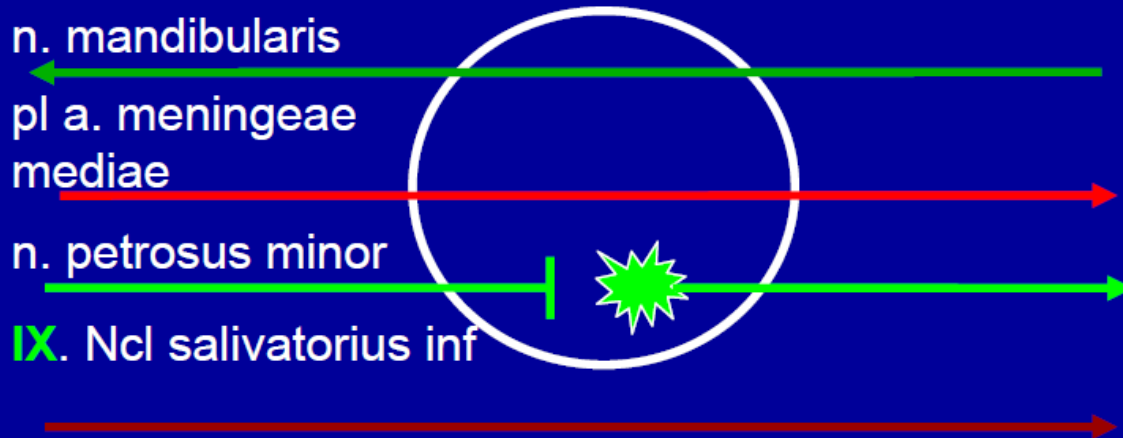
**gl. submandibularis a
sublingualis**

Spojky do n. lingualis

Drobné slinné žl. jazyka

VII. Ncl. salivatorius sup.

Ggl. oticum



rr. comm. cum n. auriculotemporalis

Glandula parotis

r. comm. cum n. buccali

Slinné žl. tváře

IX. Ncl salivatorius inf

Motorická vlákna pro m. tensor veli palatini a m. tensor tympani **VII**

m. pterygoideus medialis **V**

Enteric system

- In the wall of digestive tract
- **plexus submucosus**
- **plexus myentericus**
- Separate and independent of connection with sympathetic and parasympathetic
- It works also after interruption of connections with **ANS**
- It controls tension and mobility of digestive tract, it regulates secretion of all glands and blood flow
- innervation and regulation of function of gall bladder and pancreas

CNS

- The highest autonomic headquarters=
hypothalamus
- It is controlled by
limbic system

- The posterior root leads both somatosensory,



and
viscerosensory



The neural tracts tractus nervosi

THE SENSORY TRACTS

- **receptor→CNS**
- **A) specific:specific information**
- **B) nonspecific: through interneurons, general information, preparation of CNS for income of specific information**
- **1th neuron: pseudounipolar cell of spinal ganglion (ganglion of cranial nerves)
→(cerebellum)→thalamus→cortex**
- **SOMATOSENSORY TRACTS: protopathic sensibility
epicritic sensibility
proprioception**
- **VISCEROSENSORY TRACTS**

- **Protopathic sensibility**: tactile information (warmth, cold, pressure, pain, rough skin sensibility)

1) Limbs and trunk: *tractus spino-thalamo-corticalis*

1st Pseudounipolar neuron of spinal ganglion → 2nd nucleus proprius → 3rd thalamus → cortex (gyrus postcentralis, area 1, 2, 3)

2) Head area: *tractus trigemino-thalamo-corticalis*

1st Pseudounipolar neurons of sensory ganglia of CN (V., VII., IX., X.) → 2nd nucleus tractus spinalis (V.) → 3rd thalamus → cortex

- **Epicritic sensibility**: discriminatory sensation (tactile resolution of shape of object etc.)

1) Limbs and trunk: *tractus spino-bulbo-thalamo-corticalis*

1st Pseudounipolar neuron of spinal ganglion → fasciculus gracilis, fasciculus cuneatus → 2nd nucleus gracilis, cuneatus medialis → 3rd thalamus → cortex (gyrus postcentralis, area 1, 2, 3)

2) Head area: *tractus trigemino-thalamo-corticalis*

1st Pseudounipolar neurons of sensory ganglia of CN (V., VII., IX., X.) → 2nd nucleus principalis (V.) → 3rd thalamus → cortex

- **Proprioception**: from the locomotor system to the cerebellum

1) LL and trunk: 1st Pseudounipolar neuron of spinal ganglion → 2nd nucleus thoracicus → 3rd cerebellum → 4th thalamus → cortex

2) UL: 1st Pseudounipolar neuron of spinal ganglion → fasciculus cuneatus → 2nd nucleus cuneatus lateralis → 3rd cerebellum → 4th thalamus → cortex

3) Head area: *tractus trigemino-thalamo-corticalis*

1st Pseudounipolar neurons of nucleus mesencephalicus nervi V. → 2nd cerebellum → 3rd thalamus → cortex

- **VISCEROSENSORY TRACTS**

1st Pseudounipolar neuron of spinal ganglion → 2nd nucleus intermediomedialis

→ nucleus intermediolateralis

→ FR → thalamus → cortex

MOTOR TRACTS

- Set of all neural tracts, which are are connected into the regulation of movement. To them belong **pyramidal** and **extrapyramidal tracts**.

PYRAMIDAL TRACTS (direct)

- projection **direct** motor tracts of **voluntary movement**
- They interconnect motor cortex of hemisphere with motoneurons of anterior spinal horns and with motoneurons of nuclei of cranial nerves
- It is only one-neuron way
- They start in primary motor cortex, to them belong **tractus cortico-spinalis (tract of voluntary movement of trunk and limbs)** and **tractus cortico-nuclearis (tract of voluntary movement of striated muscles of the head)**.

EXTRAPYRAMIDAL TRACTS (indirect)

- Control of involuntary movement
- **Projection extrapyramidal tracts** (connect motor cortex of hemisphere with motoneurons of anterior spinal horns; they are switched over in motor nuclei of brainstem)
- **Connections of (motor) basal ganglia** (BG are interconnected with each other and with other motor structures of brain (e.g. motor cortex and motor parts of thalamus))
- **Tracts of cerebellum**
- They further interconnect **motor nuclei of thalamus, RF and e.g. nucleus ruber, substantia nigra etc.**

- **Association tracts:**
- The same hemisphere: *fibrae arcuatae*, *fasciculus longitudinalis superior*, *et inferior*, *fasciculus uncinatus*, *fasciculus arcuatus*
- **Commissural tracts:**
- Right and left side of CNS: *commissura anterior et posterior*, *commissura fornicis*, *corpus callosum*