

# **The regional anatomy of the upper limb**

r. palmaris  
digiti

palma  
manus

r. carpi palm.

r. antebrachii  
ant.

r. cubiti  
ant.

r. brachii ant.

r. axillaris

r. deltoidea

r. scapularis

r. brachii post.

r. cubiti  
post.

r. antebrachii post.

r. carpi dors.

dorsum  
manus

dorsum  
digiti

# r. scapularis


*acromion*

X

*spina scapulae* X

X

*angulus inf.*



n. suprascapularis  
a. et v. suprascapularis

n. axillaris  
a. et v. circumflexa humeri post.

a. circumflexa scapulae

foramen  
humerotricipitale

foramen  
omotricipitale

*incisura scapulae*

**r. deltoidea**



*nn. supraclaviculares*

*n. cutaneus brachii lat. sup.*  
*(n. axillaris)*  
*a. et v. circumflexa humeri post.*  
*(rr. cutanei)*

*Left extremity*  
*from behind*

n. axillaris

a. et v. circumflexa humeri post.

*From behind*

*nn. supraclaviculares*

*From the  
front*

trigonum  
deltoideopectorale





**fossa axillaris**

*v. thoracoepigastrica*  
*lymphatic vessels*

*a. et v. thoracica lat.*  
*n. thoracicus longus*

*a. et v. axillaris*  
*plexus brachialis*  
*nl. axillares*

**fasciculus post.:**

n. radialis  
n. axillaris

**fasciculus med.:**

r. med. n. mediani  
n. ulnaris  
n. cutaneus brachii med.  
n. cutaneus antebrachii med.

**fasciculus lat.:**

n. musculocutaneus  
r. lat. n. mediani



## r. brachii

*Right one , from below*

*v. cephalica*  
*n. cutaneus*  
*brachii lat. inf.*

*n. medianus*  
*n. ulnaris*  
*a. et vv. brachiales*  
*n. musculocut.*  
*n. cut. antebr. med.*

*v. basilica*  
*n. cutaneus*  
*brachii med.*

*n. radialis*

*n. cutaneus brachii*  
*post.*

**r. brachii ant.**

Lef one

*n. cutaneus brachii med.*

*v. cephalica*

*n. cutaneus antebrachii med.*  
*v. basilica*

a. et. v. brachialis  
n. musculocutaneus  
n. medianus  
n. ulnaris

**r. brachii post.**

Left one

*n. cutaneus brachii lat. sup.*  
(*n. axillaris*)

*cutaneus brachii lat. inf.*  
*n. cutaneus brachii post.*  
*n. cutaneus antebrachii post.*  
(*n. radialis*)

n. radialis

a. et. v. profunda brachii

**r. cubiti**

*n. cutaneus  
antebr. med.  
v. basilica*

*n. cutaneus  
antebr. lat.  
v. cephalica*

*n. cutaneus  
antebr. post.*



*From the front*

n. ulnaris  
a. et v. ulnaris

n. medianus  
n. radialis (r. superf.)  
a. et v. radialis

**r. antebrachii**

*Right one, from below*

*n. cut. antebr. med.*  
*v. basilica*

**r. antebrachii ant.**



*n. cutaneus antebr. med.*  
*v. basilica*

*n. cutaneus antebr. lat.*  
*v. cephalica*

Left one

a. et v. radialis  
(palpable puls)

n. medianus

n. ulnaris  
a. et v. ulnaris

n. radialis (r. superf.)  
a. et v. radialis

n. medianus

n. interosseus ant. (n. medianus)  
a. et v. interossea ant.



**r. antebrachii post.**

*n. cutaneus antebrachii post.*

*v. cephalica*

*n. radialis (r. superf.)*

*v. basilica*

*n. ulnaris (r. dorsalis)*

Left one

**n. radialis**

(r. prof., n. interosseus post.)

a. et v. interossea post.

**r. carpi palm.**

**r. carpi dors.**

**palma manus**

*n. ulnaris (r. palmaris)*

*n. medianus (r. palmaris)*

*superficial veins*

*aponeurosis palmaris*

n. ulnaris (r. superf.)  
a. et v. ulnaris

n.  
medianus

a. et v. radialis

**arcus palmaris superf.**

aa. digitales palm. comm.

aa. digitales palm. propriae

nn. digitales palmares comm.

nn. digitales palmares propriae



n. ulnaris (r. prof.)

**arcus palmaris prof.**

aa. metacarpeae palm.

*Tributaries of v. cephalica*  
*n. radialis (r. superf.)*

*Tributaries of v. basilica*  
*n. ulnaris (r. dorsalis)*

**dorsum manus**

*rete venosum*  
*nn. digitales dorsales*

n. interosseus post.

**rete carpi dorsale**

(a. interossea ant., a. interossea post.,  
r. carpeus dors a. radialis et a. ulnaris)

aa. metacarpeae dors.

## digiti manus

nn. digitales dors. (n. radialis et n. medianus)  
aa. digitales dors.

*phalanx proximalis*

nn. digitales palm. propr. (n. medianus et n. ulnaris)  
aa. digitales palm. propr.

# Lymphatic drainage of UL

**The medial collectors– 10-15, along v. basilica, into axilla – nn. l. axillares centrales et laterales**

**The lateral collectors– 6-7, along v. cephalica into axilla**

**The frontal collectors– from the palm, 4-5, within the cubital fossa they connect to the previous two systems**

# **The regional anatomy of the lower extremity**

trig. femorale

r. femoris ant.

r. genus ant.

r. cruris ant.

dorsum pedis

r. glutea

r. femoris post.

r. genus post.

r. cruris post.

planta pedis



**r. femoris  
ant.**

*v. saphena magna + tributaries*

*n. cutaneus femoris lat.*

*n. cutaneus femoris post.*

*rr. cutanei ant. (from n. femoralis)*

*r. cutaneus (from n. obturatorius)*

*n. femoralis → n. saphenus*

*a. et v. femoralis*

*n. obturatorius*

*a. et v. obturatoria*

*n. ischiadicus*

**v. saphena magna + tributaries**

*a. epigastrica superf.*

*a. circumflexa ilium superf.*

*aa. pudendae ext.*

*n. cutaneus femoris lat.*

*r. femoralis (from n. genitofemoralis)*

*rr. cutanei ant. (from n. femoralis)*

*r. cutaneus (from n. obturatorius)*

*nll. inguinales superf.*

## trig. femorale

*m. sartorius, lig. inguinale, m. adductor longus*

## v. saphena magna

*v. saphena accessoria*

*v. epigastrica superf. a. epig. superf.*

*v. circumfl. ilium superf. a. circumfl. ilium superf.*

*vv. pudendae ext. aa. pudendae ext.*

## nll. inguinales superf.

n. ilioinguinalis

n. genitofemoralis (r. femoralis)

fossa  
iliopectinea

a. et v. femoralis

n. femoralis

nll. inguinales prof.

**lacuna musculorum:**

m. iliopsoas

n. femoralis

**lacuna vasorum:**

n. genitofermoralis (r. femoralis)

a. femoralis

v. femoralis

nl. Cloqueti

*Femoral hernia*

## **canalis adductorius**

*(m. vastus med. and m. adductor magnus)*

a. et v. femoralis

n. saphenus

## **hiatus tendineus**

**r. glutea**

**r. femoris post.**



*nn. clunium sup.*  
*nn. clunium medii* } rr. dors. nn. spinalium  
*nn. clunium inf. (z n. cutaneus fem. post.)*

*n. cutaneus femoris post.*

foramen suprapiriforme

n. gluteus sup.

a. et v. glutea sup.

foramen infrapiriforme

n. gluteus inf.

a. et v. glutea inf.

n. pudendus

a. et v. pudenda int.

n. cut. femoris post.

n. ischiadicus

n. ischiadicus

rr. perforantes (*from a. prof. femoris*)

r. genus

v. saphena magna

n. saphenus

rr. cut. ant. (*from n. femoralis*)

v. saphena parva  
(ev. v. femoropoplitea)

n. tibialis  
n. peroneus comm.  
a et v. poplitea  
nll. poplitei

**r. cruris**

*v. saphena magna*

*n. saphenus* → *rr. cut. cruris med.*

*v. saphena parva*

*n. suralis*

*n. cut. surae lat.*

*n. cut. surae med.*

*n. peroneus superf.*

*n. peroneus prof.*

*a. et v. tibialis ant.*

*n. tibialis*

*a. et v. tibialis post.*

*v. saphena magna*  
*rr. cut. cruris med (z n. saphenus)*

*n. peroneus superf.*



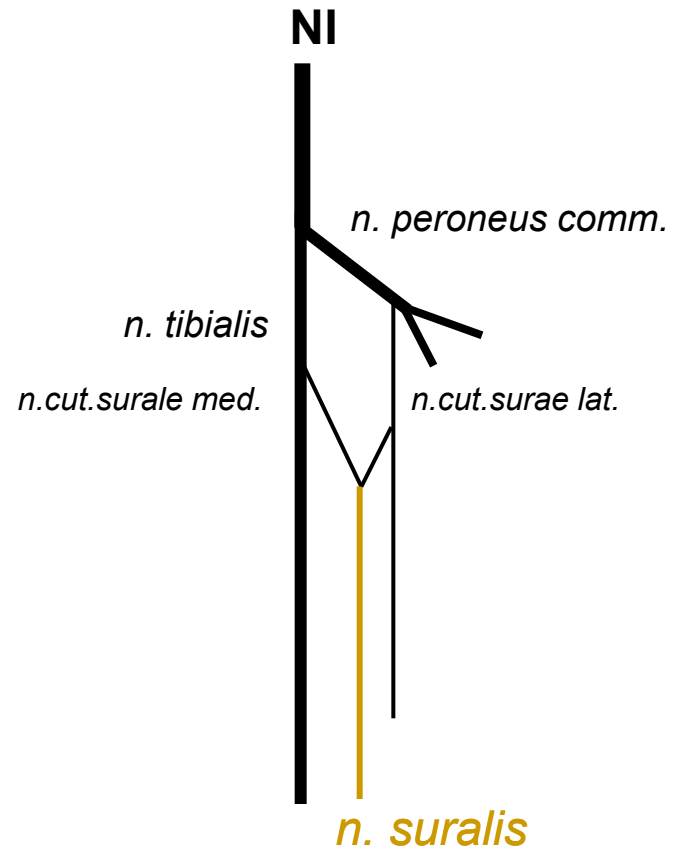
n. peroneus prof.  
a. et v. tibialis ant.

**n. peroneus comm.:**

*n. peroneus prof.*

*n. peroneus superf.*

*v. saphena parva*  
*n. cutaneus surae med.*  
+ *n. cutaneus surae lat.* =  
***n. suralis***



n. tibialis

a. et v. tibialis post.

**dorsum pedis**

## dorsum pedis

*rete venosum dorsale pedis*

*n. cut. dorsalis med.*  
*n. cut. dors. intermed.* } *from n. peroneus superf.*

*n. cut. dors. lat. (from n. suralis)*

*nn. dig. dors. (from n. peroneus prof.)*

*fascia dorsalis – retinaculum extensorum*

*a. et v. dorsalis pedis*

*n. peroneus prof.*

*Left extremity, transsection through  
foot, from distal view*

*rete venosum dorsale pedis*

***v. saphena magna***

***v. saphena parva***

*n. cut. dorsalis med.* } (from *n. peroneus superf.*)  
*n. cut. dors. intermed.* }

*n. cut. dors. lat. (z n. suralis)*

*n. peroneus prof.*

a. et v. dorsalis pedis  
n. peroneus prof.



n. peroneus prof.  
a. dorsalis pedis

**a. arcuata + a. tarsea lat.**

aa. metatarsae dors.

*aa. digitales dorsales*

**a. metatarsa dors. prima**

**planta pedis**

*aponeurosis plantaris*

*rr. superf. (from n. plantaris med. et lat.)*

*rr. superf. (from a. et v. plantaris med.)*

*a. et v. plantaris med. et lat.*

*n. plantaris med. et lat.*

rr. superf. (z *n. plantaris med. et lat.*)

n. tibialis

a. et v. tibialis

n. plantaris med. et lat.

a. et v. plantaris med. et lat.

a. plantaris lat. + r. plantaris prof (*from a. dorsalis pedis*) + branch from a. plantaris med.

**arcus plantaris**

*aa. metatarsae plant.*

*aa. digitales plant.*

## digiti pedis

Dorsal aponeurosis

nn. digitales dorsales

aa. et vv. digitales dorsales

Tendons of m. flexor digitorum brevis et longus, vaginae fibrosae et synoviales

nn. digitales plantares

aa. et vv. digitales plantares



# Lymphatic drainage of lower extremity

**The lateral collectors**- from dorsum pedis toward the knee, connect to the medial ones

**The medial collectors**- from planta pedis, along v. saphena magna onto thigh, they enter nodi lymph. ing. sup.

**The posterior collectors**- from heel, along v. saphena parva, inside fossa poplitea they enter nodi lymph. poplitei and then added to the deep lymphatic vessels

# The regional anatomy of the back

- regio nuchae
- regio  
vertebralis
- regio  
infrascapularis
- regio lumbalis

# Trigonum suboccipitale

# Trigonum lumbale petiti

Trigonum Grynfeldti/Tetragon  
Krausei

Thank you for your attention!