

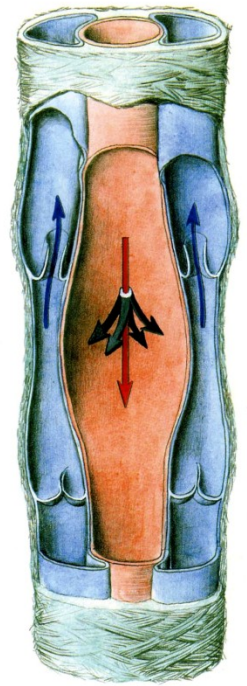
***ARTERIES**

Arteriae
Arteriolae
Vasa capillaria
(sinusoids)

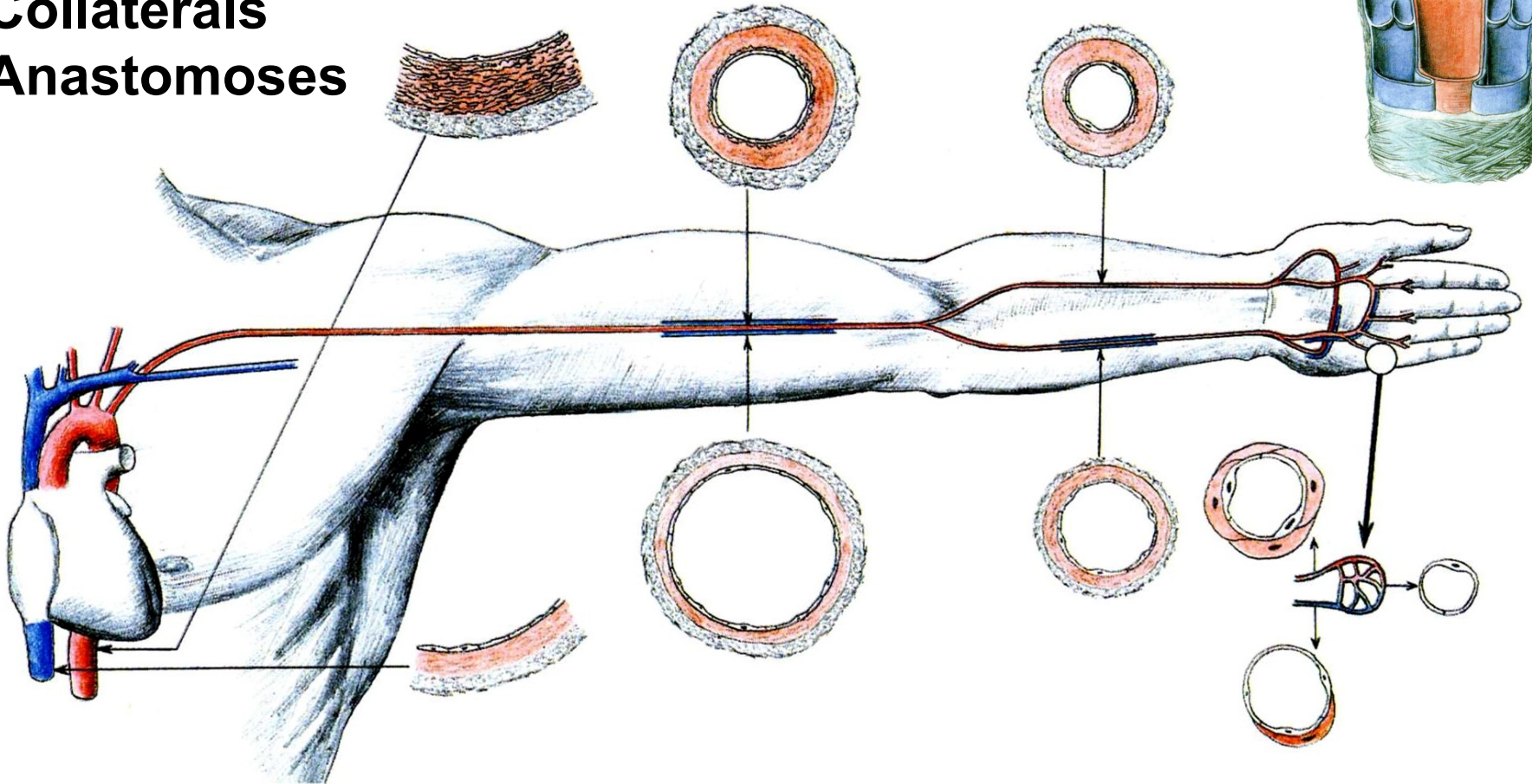
Venulae
Venae

Tunica intima
Tunica media
Tunica adventitia

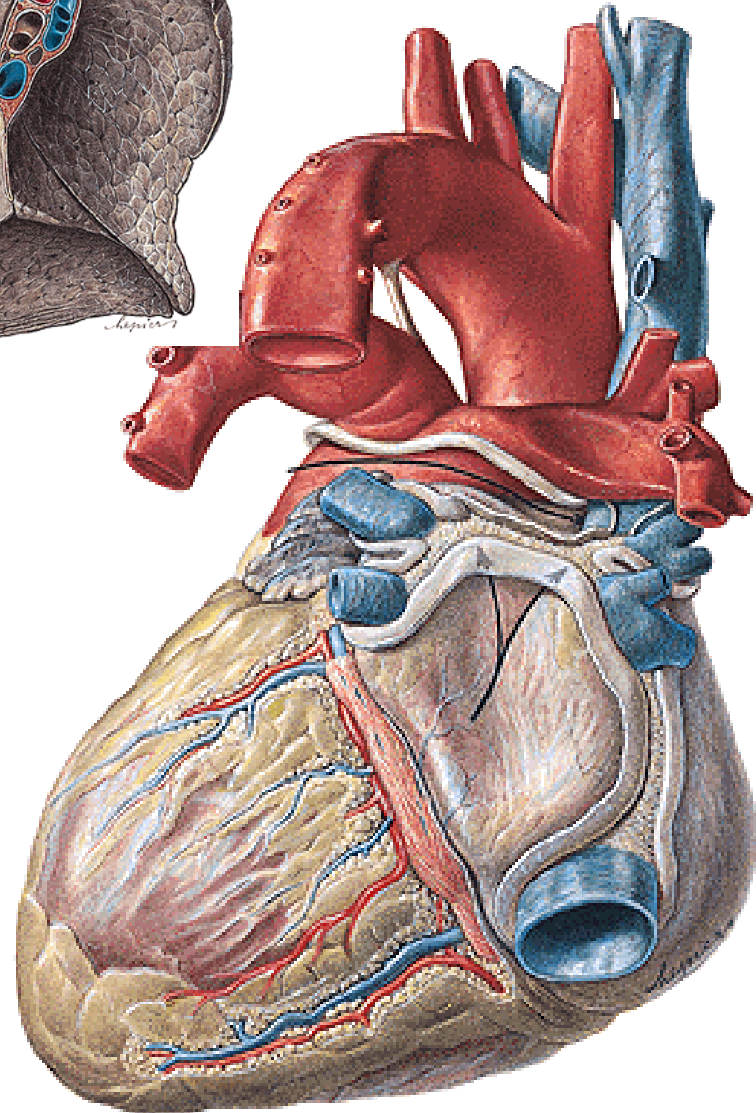
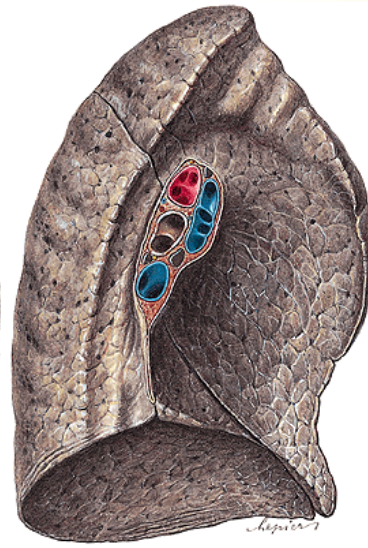
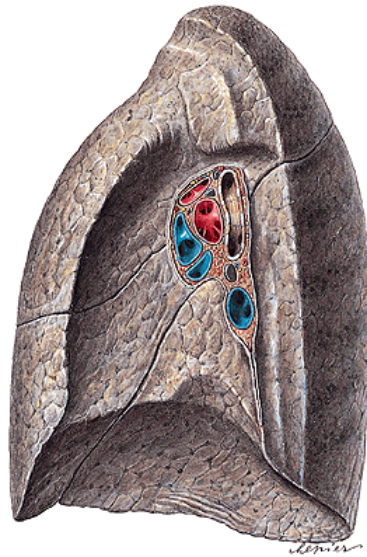
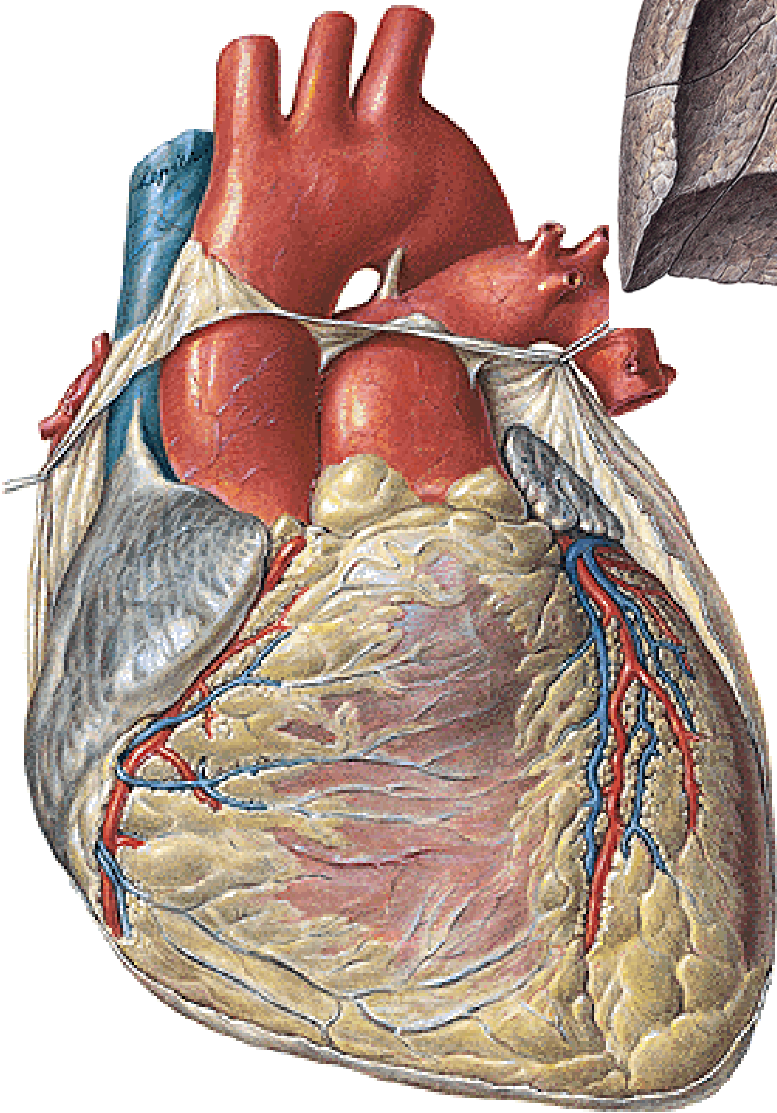
Vasa vasorum



Collaterals
Anastomoses

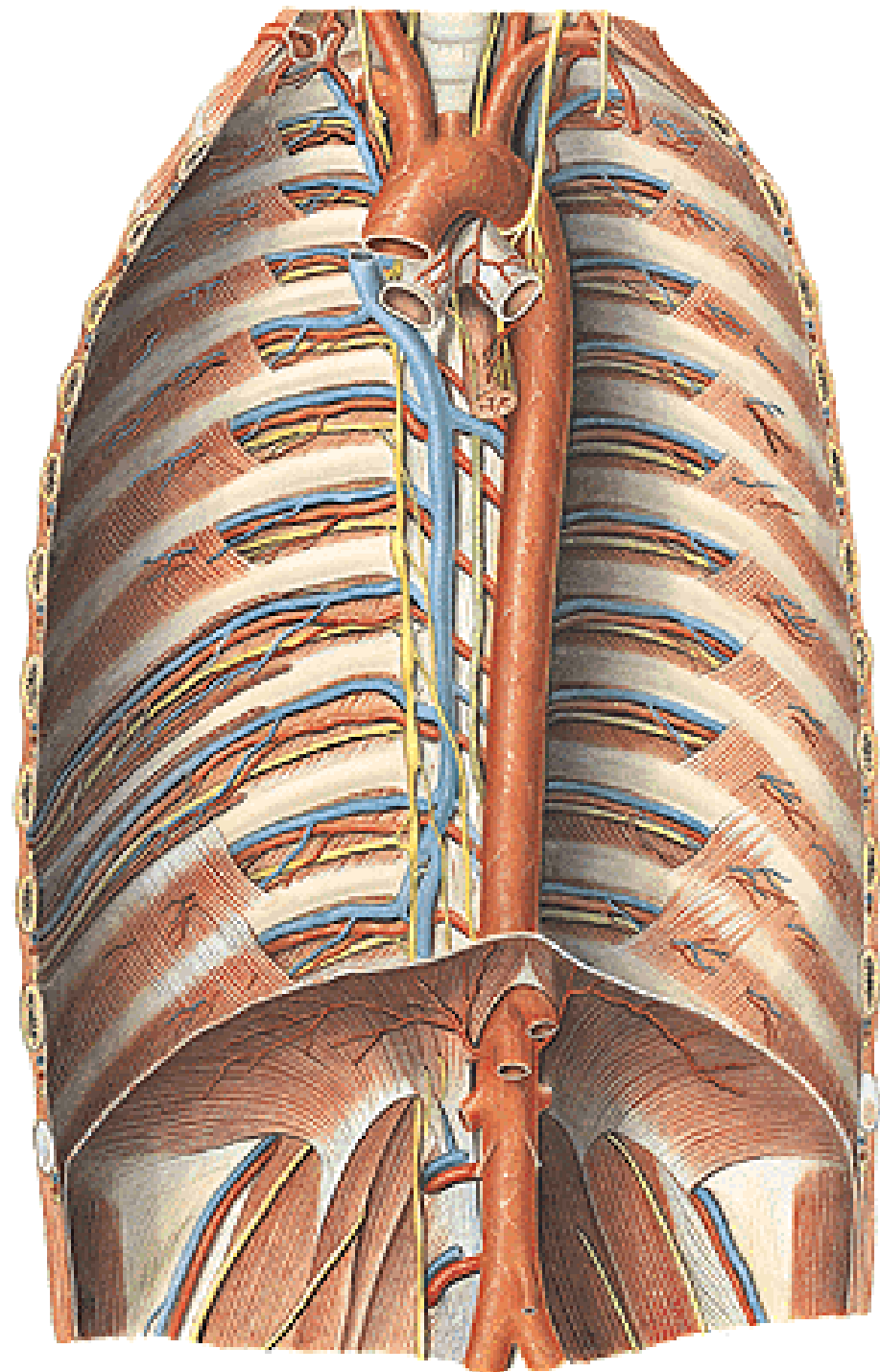


TRUNCUS PULMONALIS – a. pulmonalis dx. et sin. Lig. arteriosum



AORTA

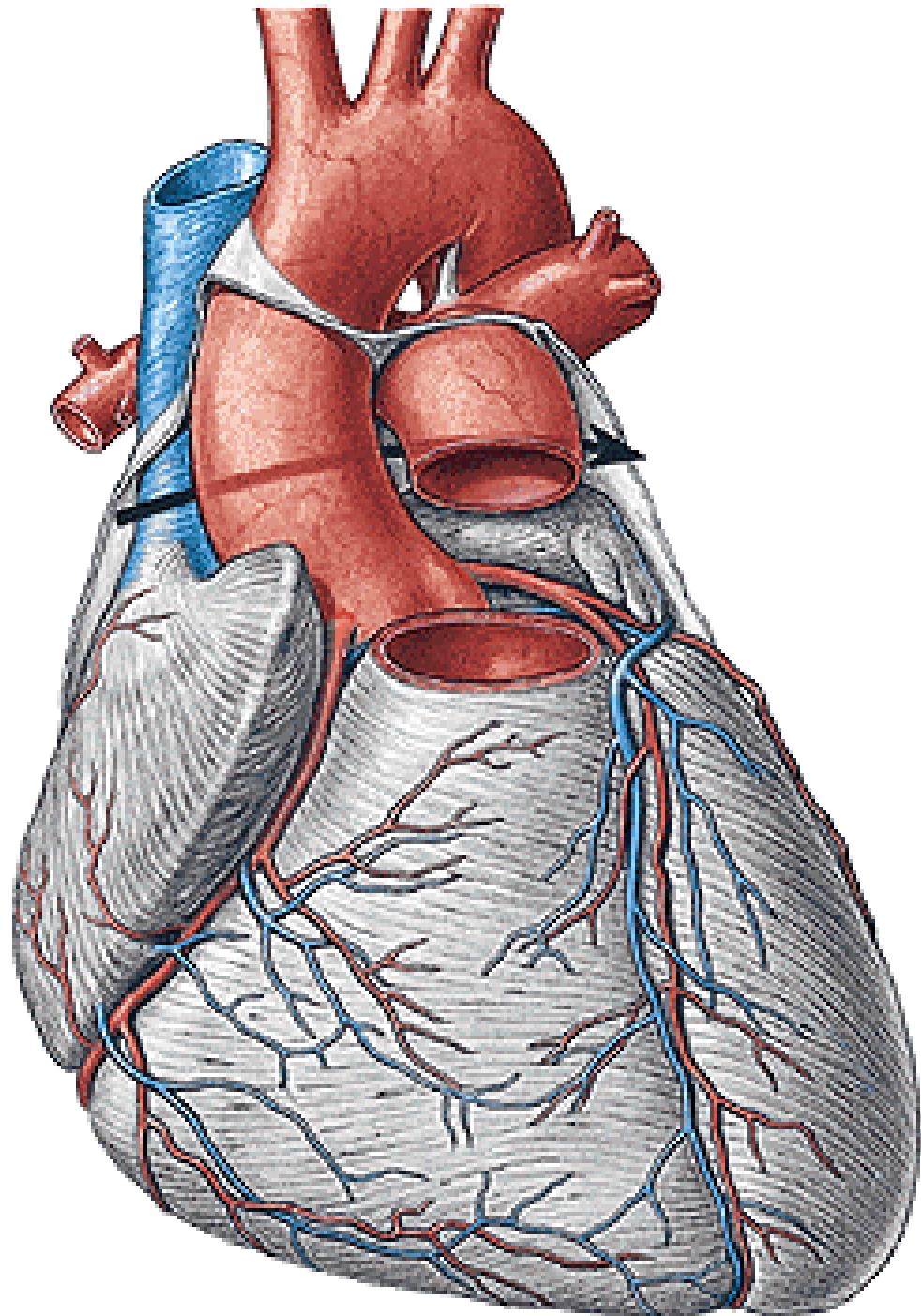
- AORTA ASCENDENS
- ARCUS AORTAE
- AORTA DESCENDENS
 - Aorta thoracica
 - Aorta abdominalis



AORTA ASCENDENS

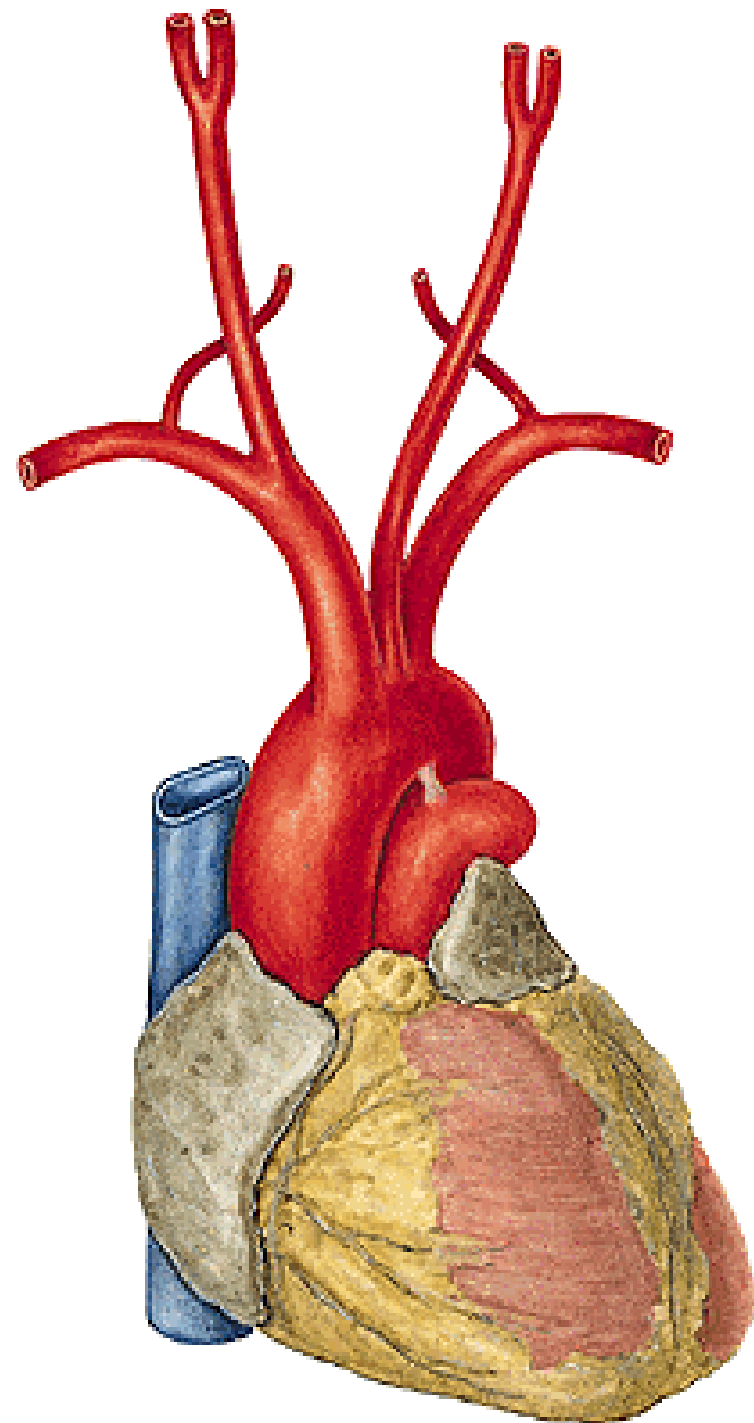
Bulbus aortae

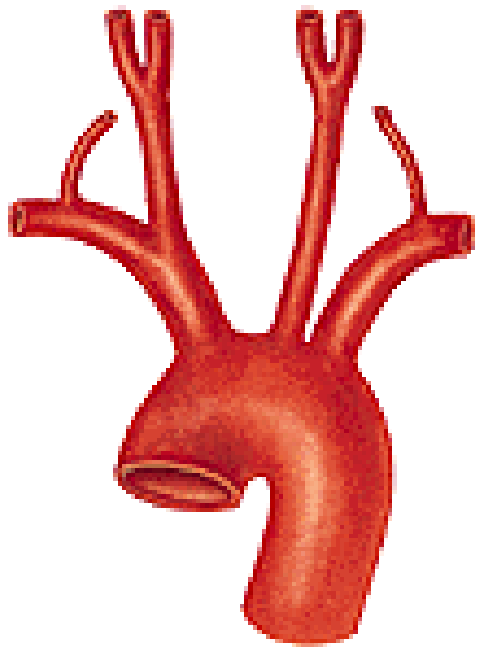
- a. coronaria cordis dx.
- a. coronaria cordis sin.



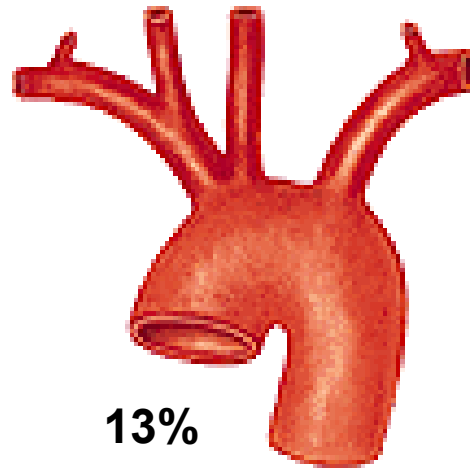
ARCUS AORTAE

- truncus brachiocephalicus
- a. carotis communis sin.
- a. subclavia sin.

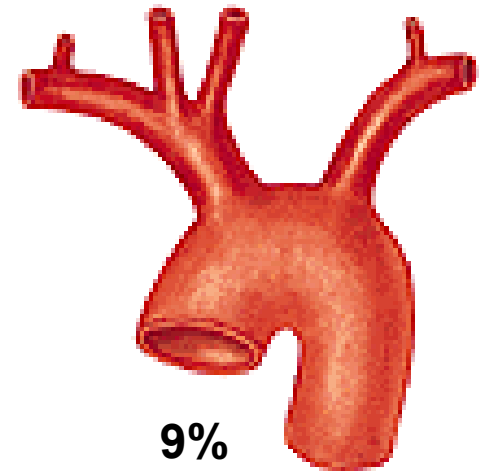




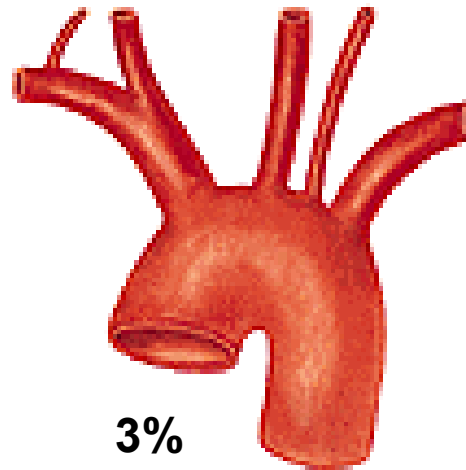
70%



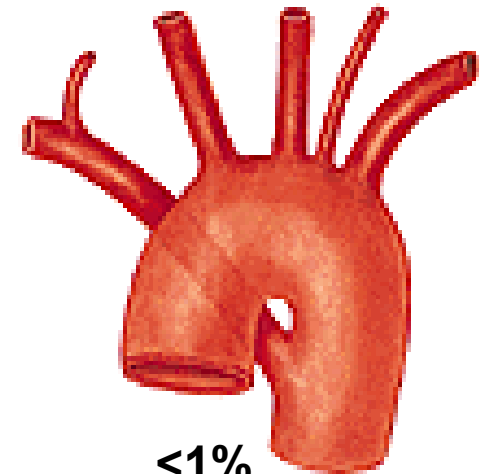
13%



9%

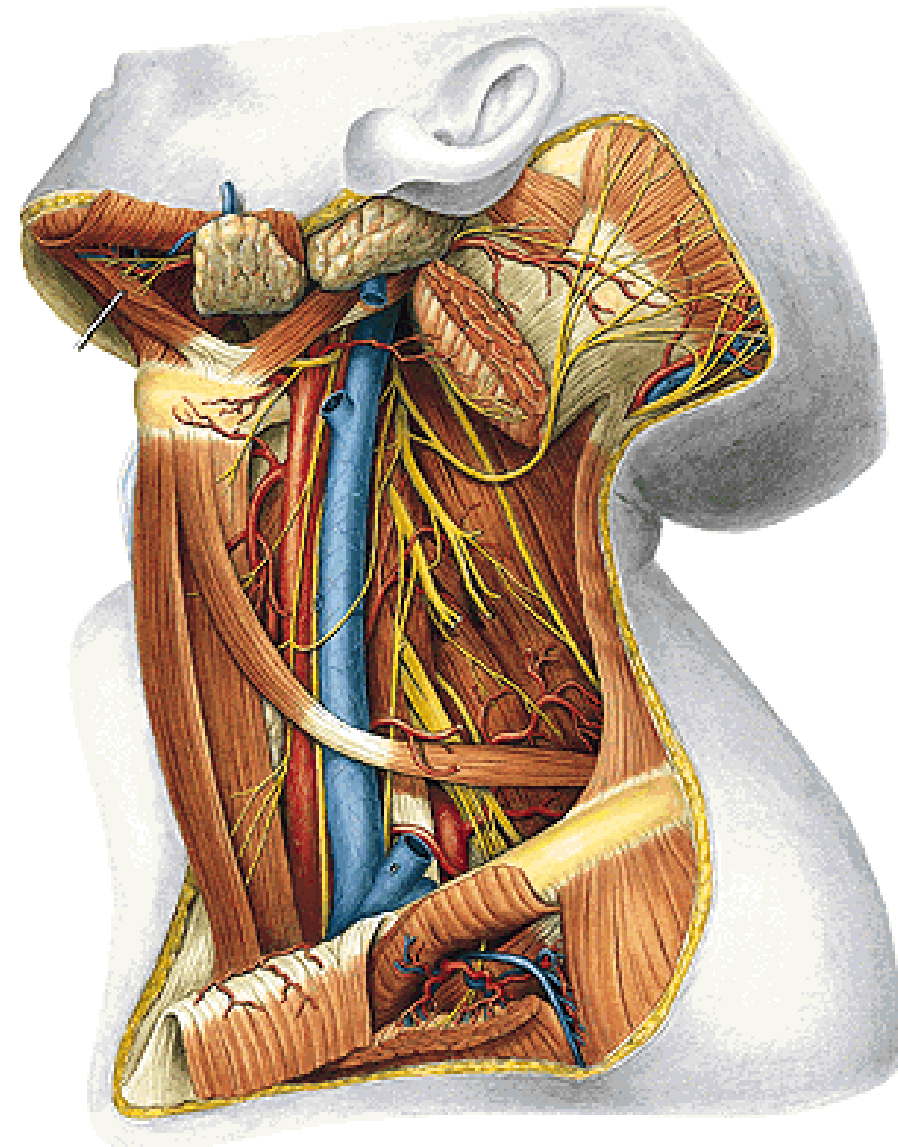
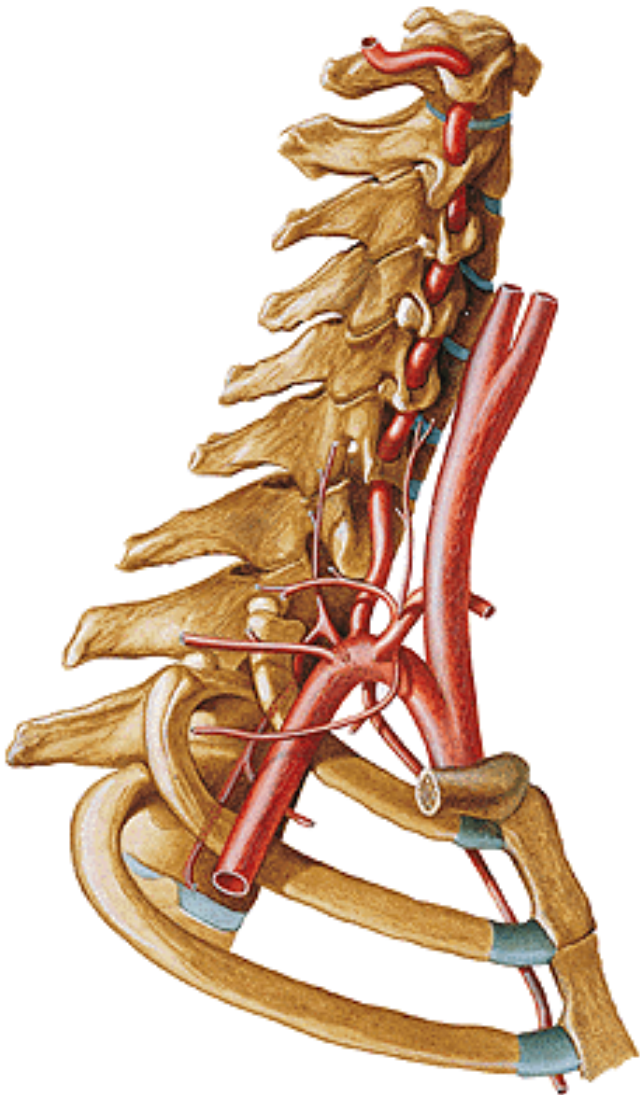


3%



<1%

A. CAROTIS COMMUNIS – a. carotis interna et externa



A. CAROTIS EXTERNA:

ventral branches:

- a. thyroidea sup.
- a. lingualis
- a. facialis

dorsal branches:

- a. occipitalis
- a. auricularis post.

medial branch:

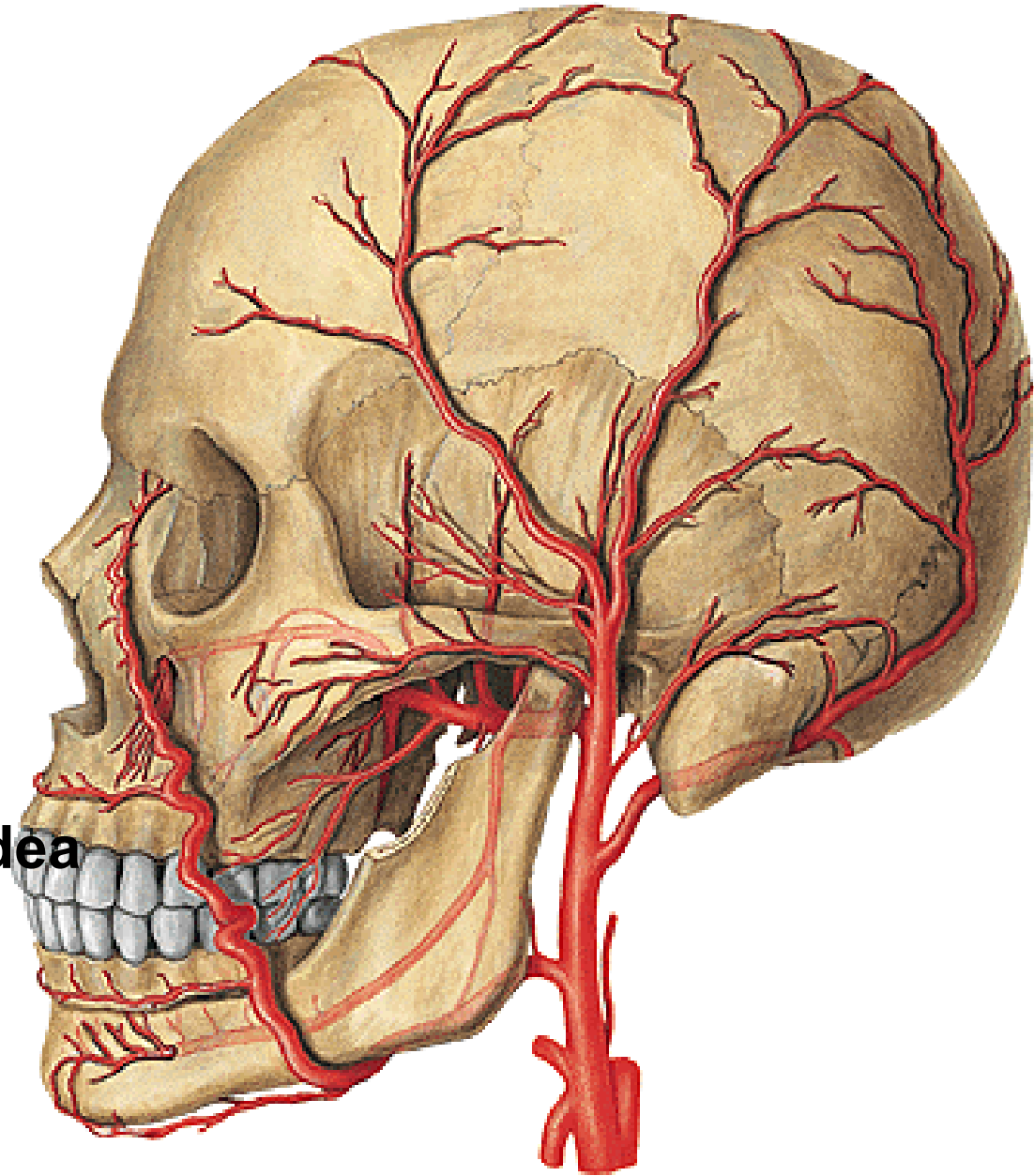
- a. pharyngea asc.

lateral branch:

- a. sternocleidomastoidea

terminal branches

- a. maxillaris
- a. temporalis spf.

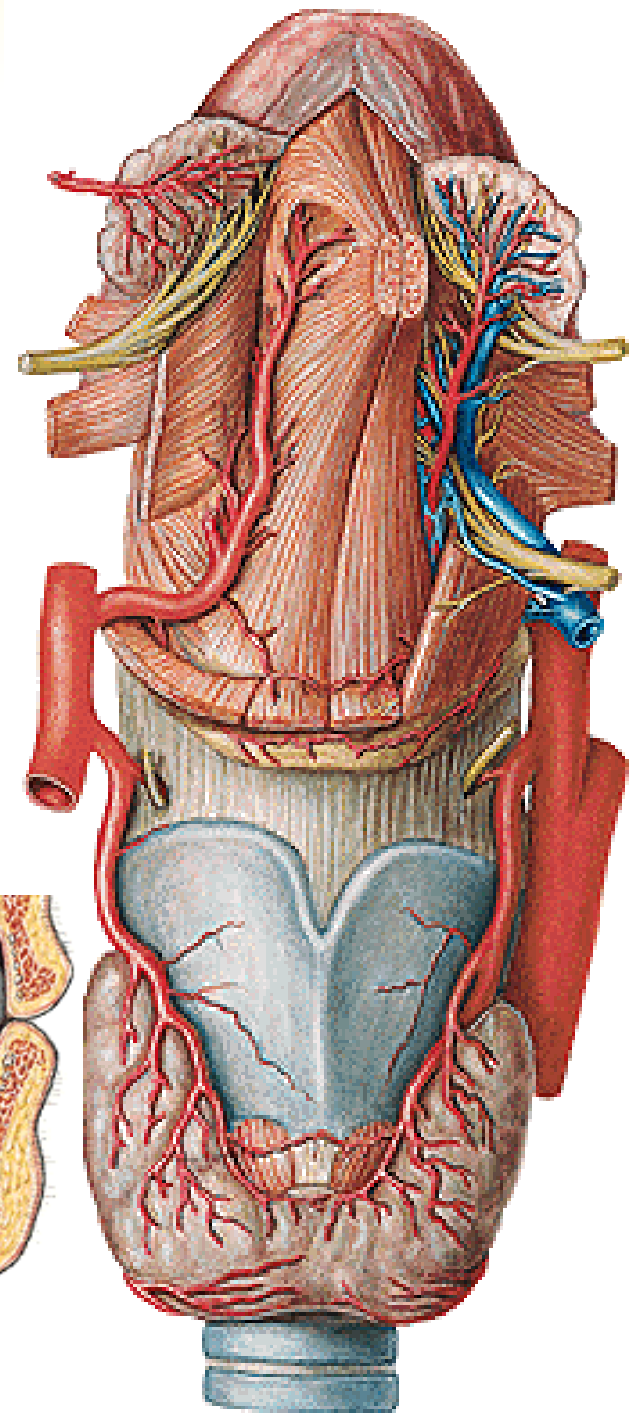
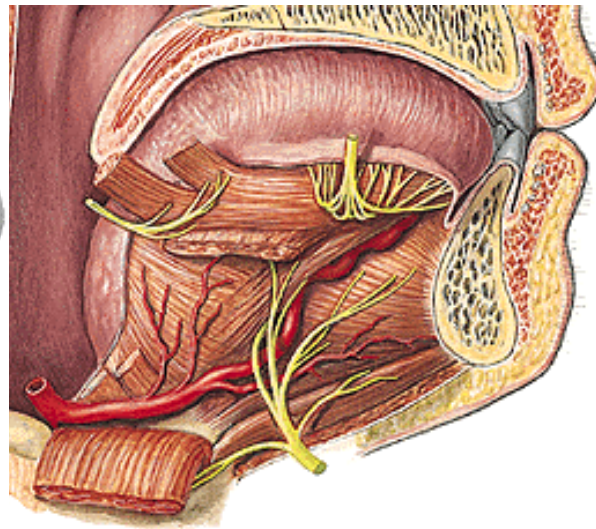
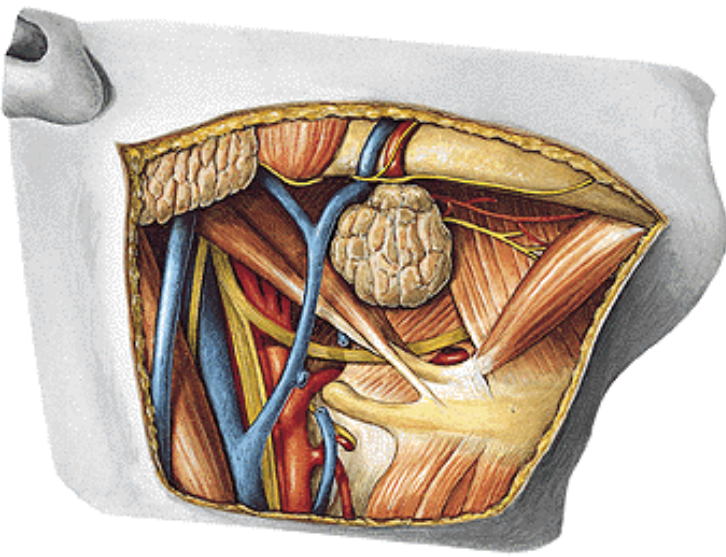


A. THYROIDEA SUP.:

- a. laryngea sup.
- rr. glandulares

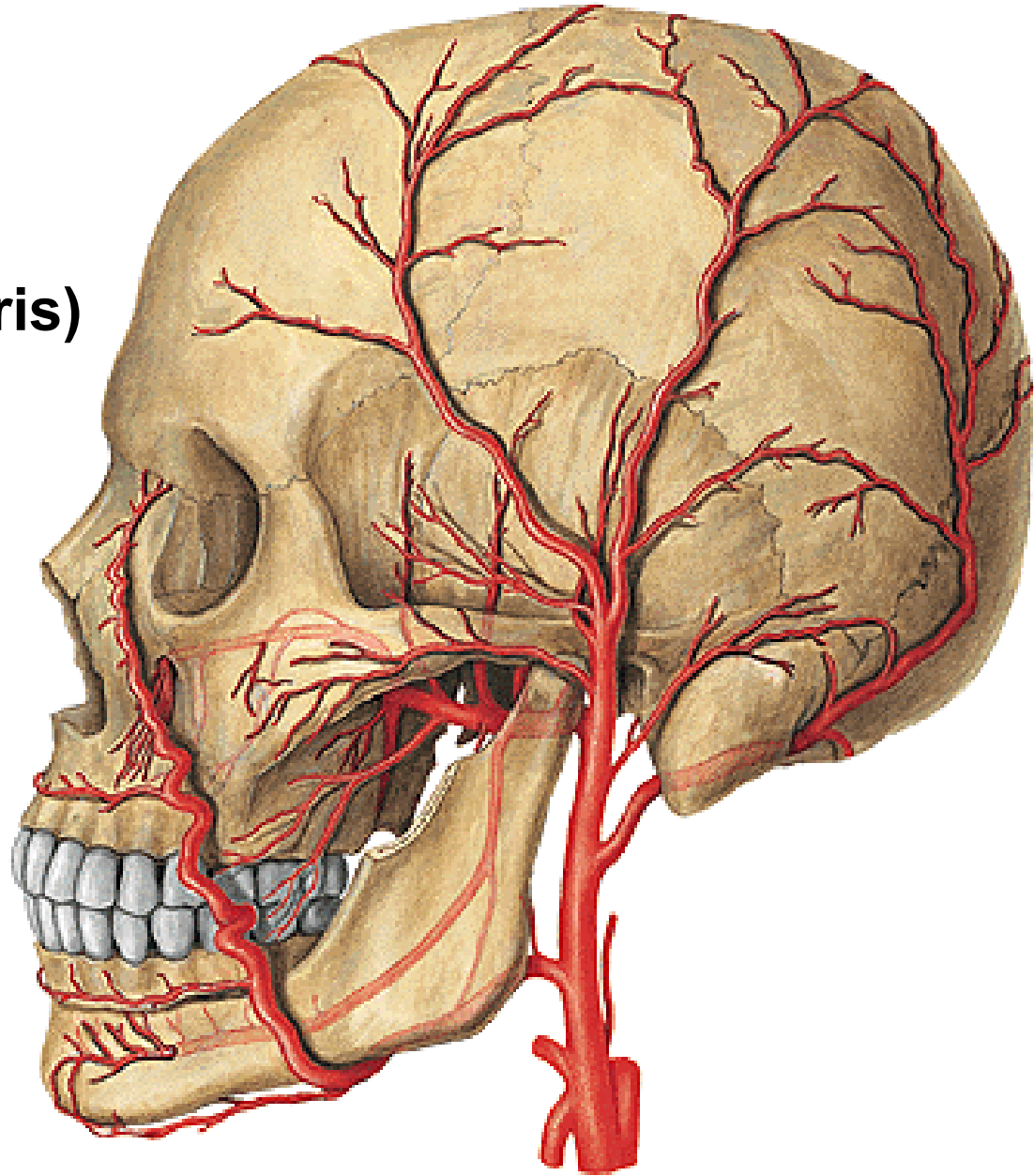
A. LINGUALIS:

- a. sublingualis
- rr. dorsales linguae
- a. profunda linguae



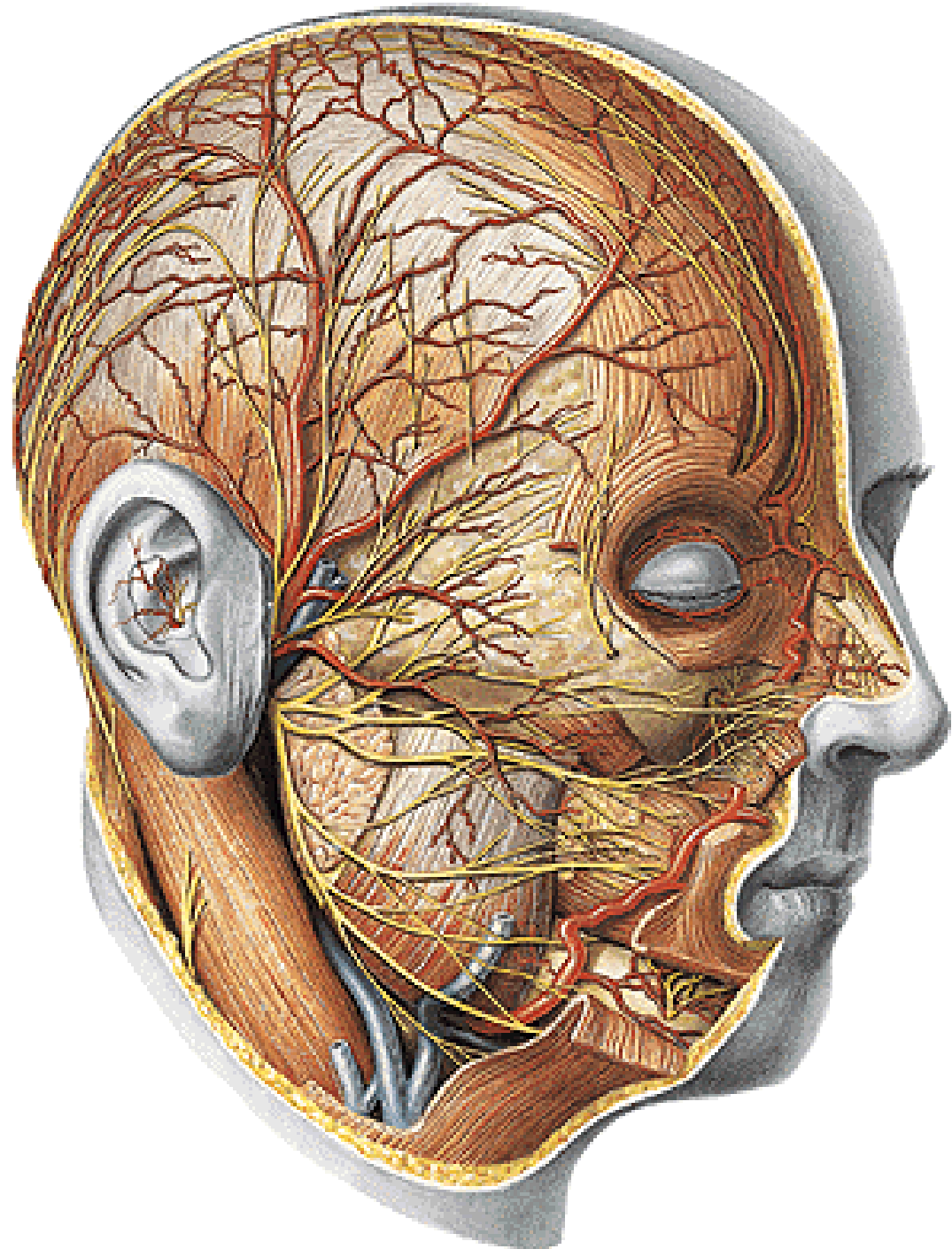
A.FACIALIS:

- a. palatina ascendens
- a. submentalis
- a. labialis sup. et inf.
(circulus arteriosus oris)
- a. angularis



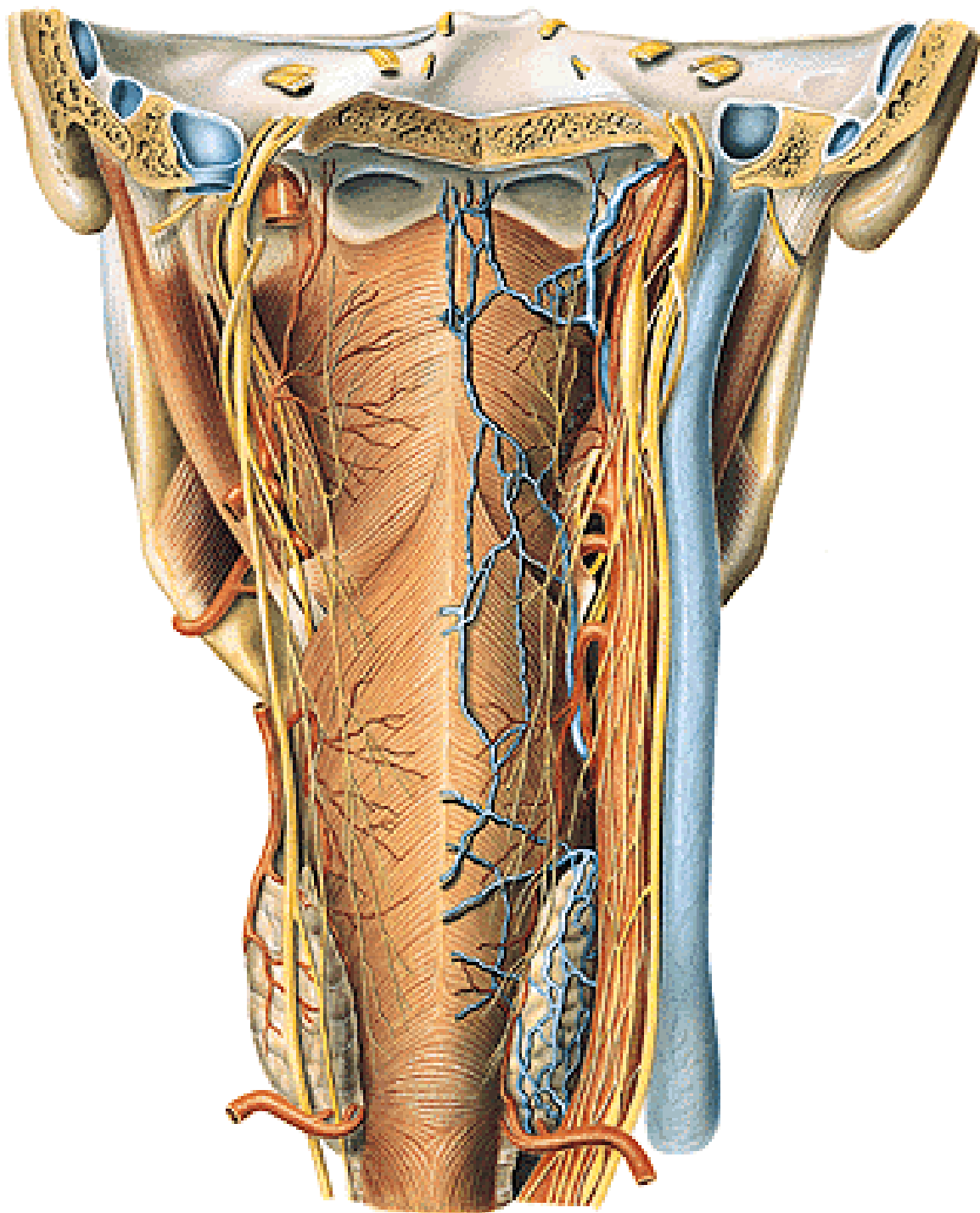
A. TEMPORALIS SPF.:

- a. transversa faciei
- a. zygomaticoorbitalis
- r. frontalis
- r. parietalis

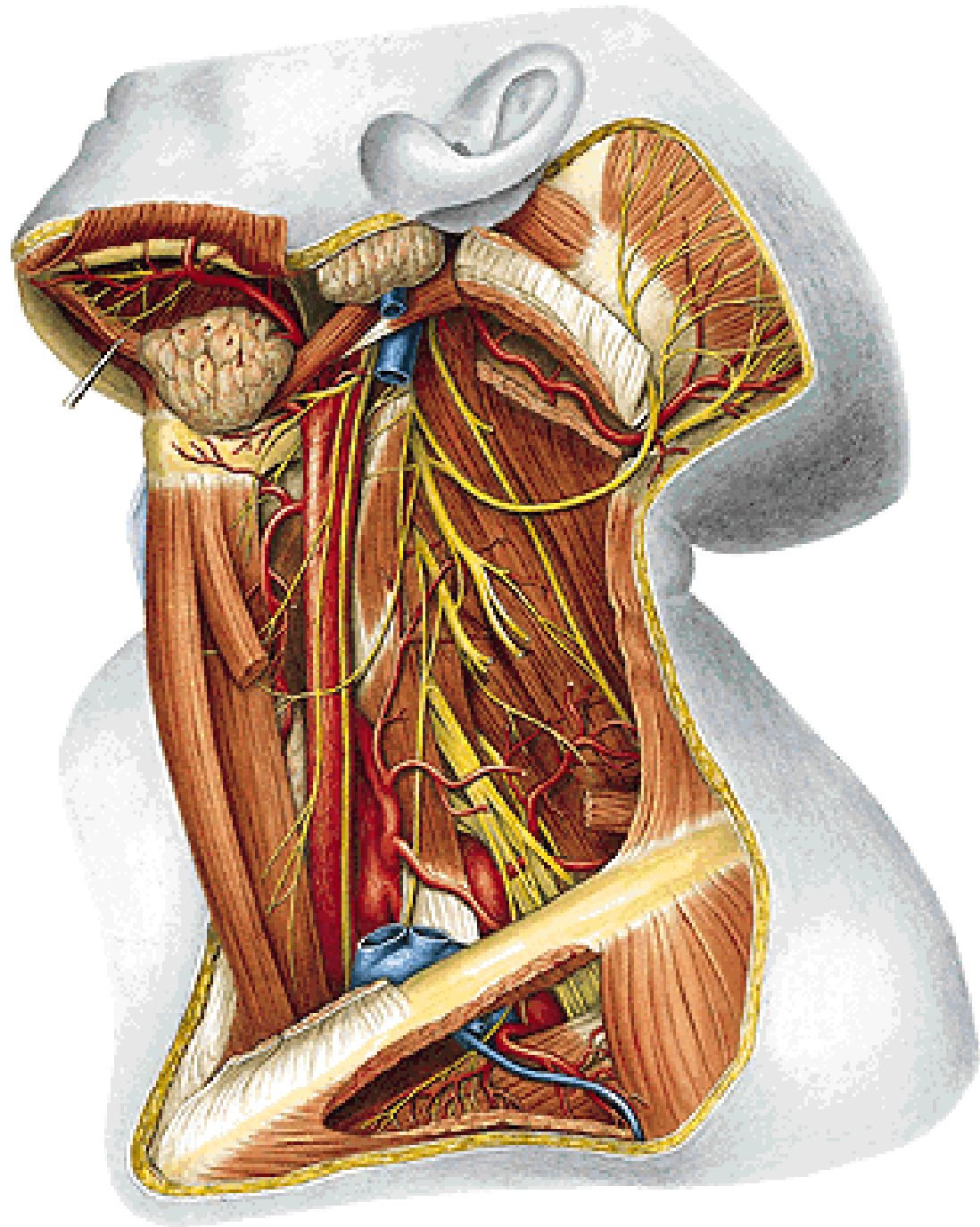


A. PHARYNGEA ASC.:

- rr. pharyngei
- a. meningea post.



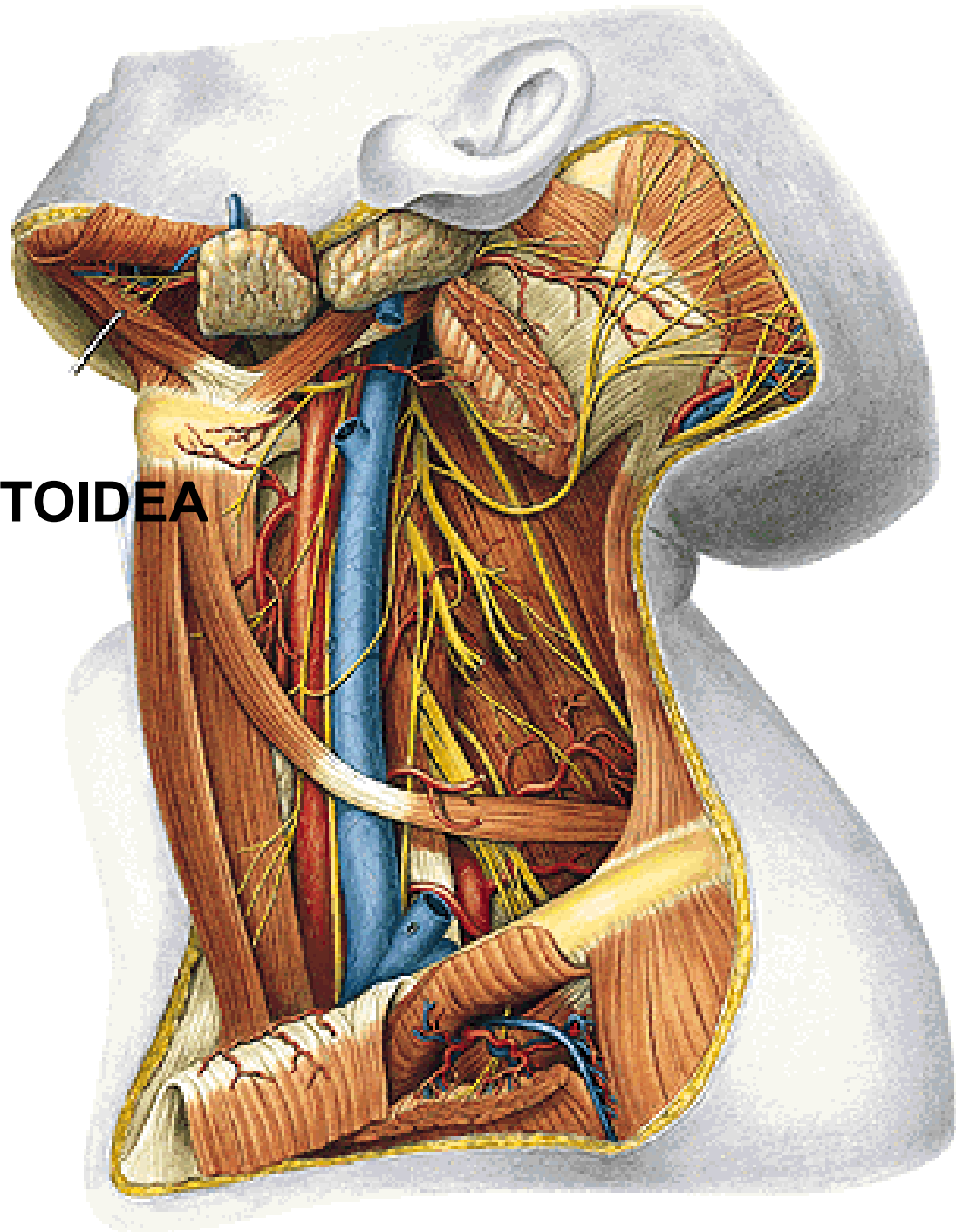
A. OCCIPITALIS:
- rr. musculares
- rr. occipitales



A. AURICULARIS POST.:

- rr. musculares
- a. stylomastoidea

A. STERNOCLEIDOMASTOIDEA



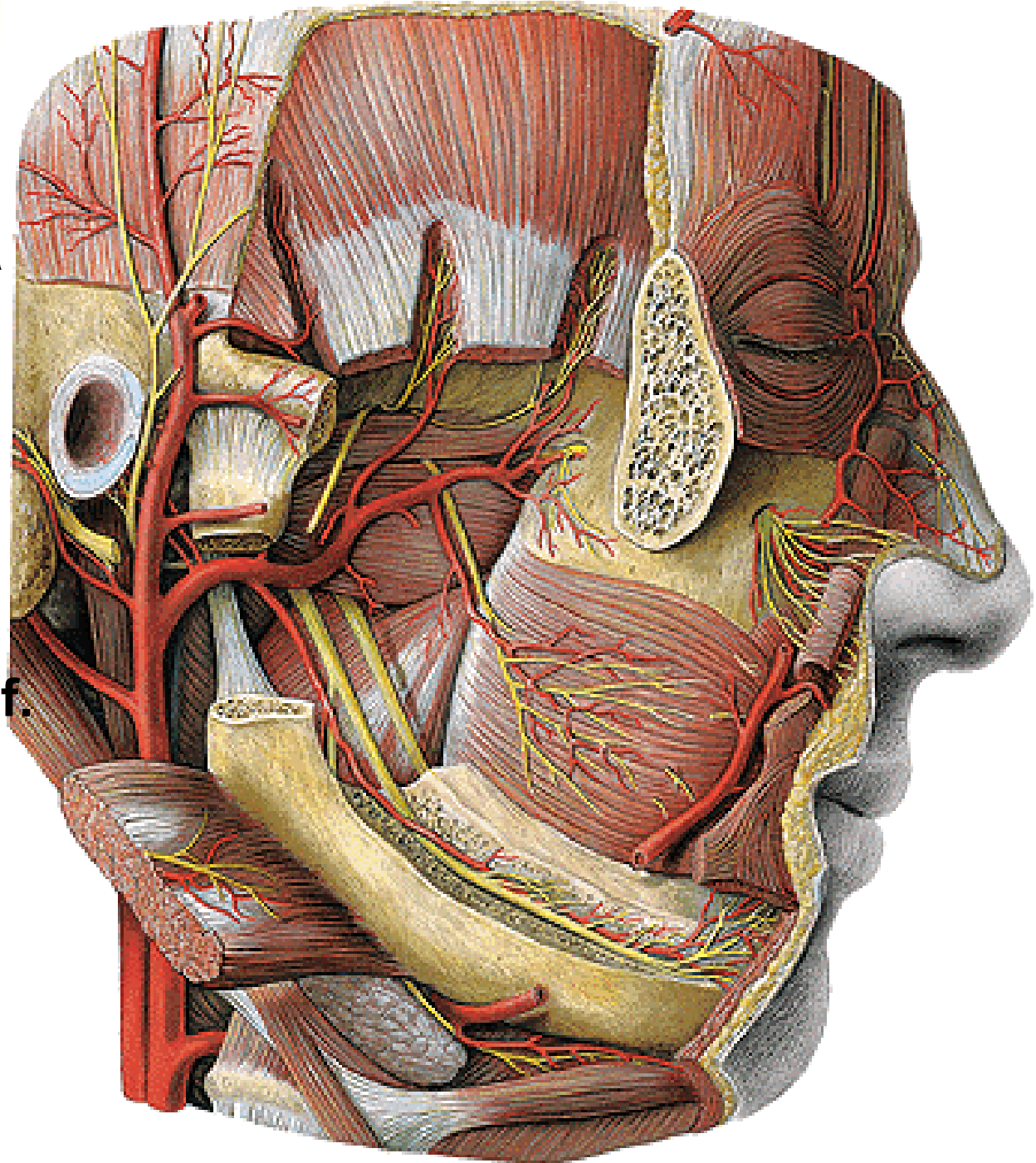
A. MAXILLARIS:

Pars mandibularis:

- a. meningea media
- a. alveolaris inf.
 - rr. dentales
 - a. mentalis

Pars pterygoidea:

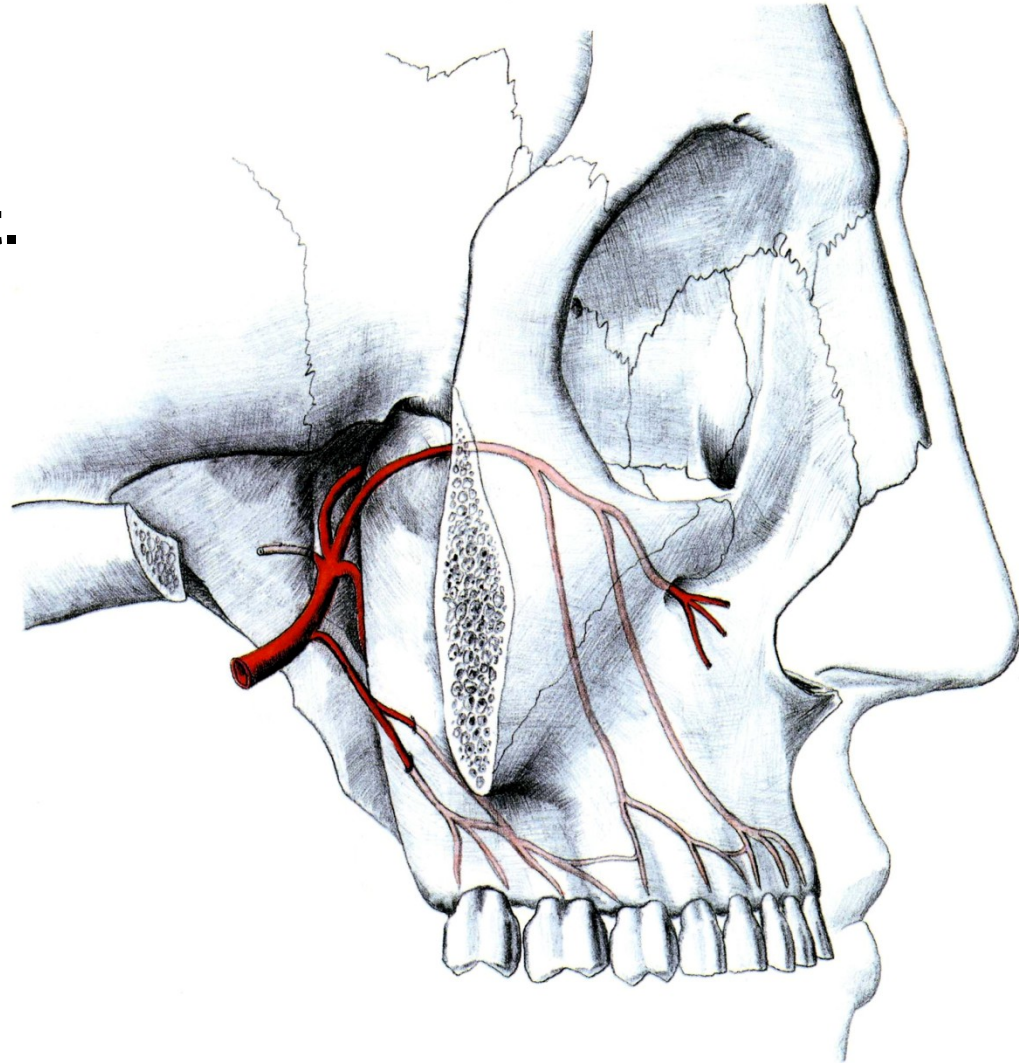
- a. masseterica
- aa. temporales prof.
- rr. pterygoidei
- a. bucalis



A. MAXILLARIS (continuation):

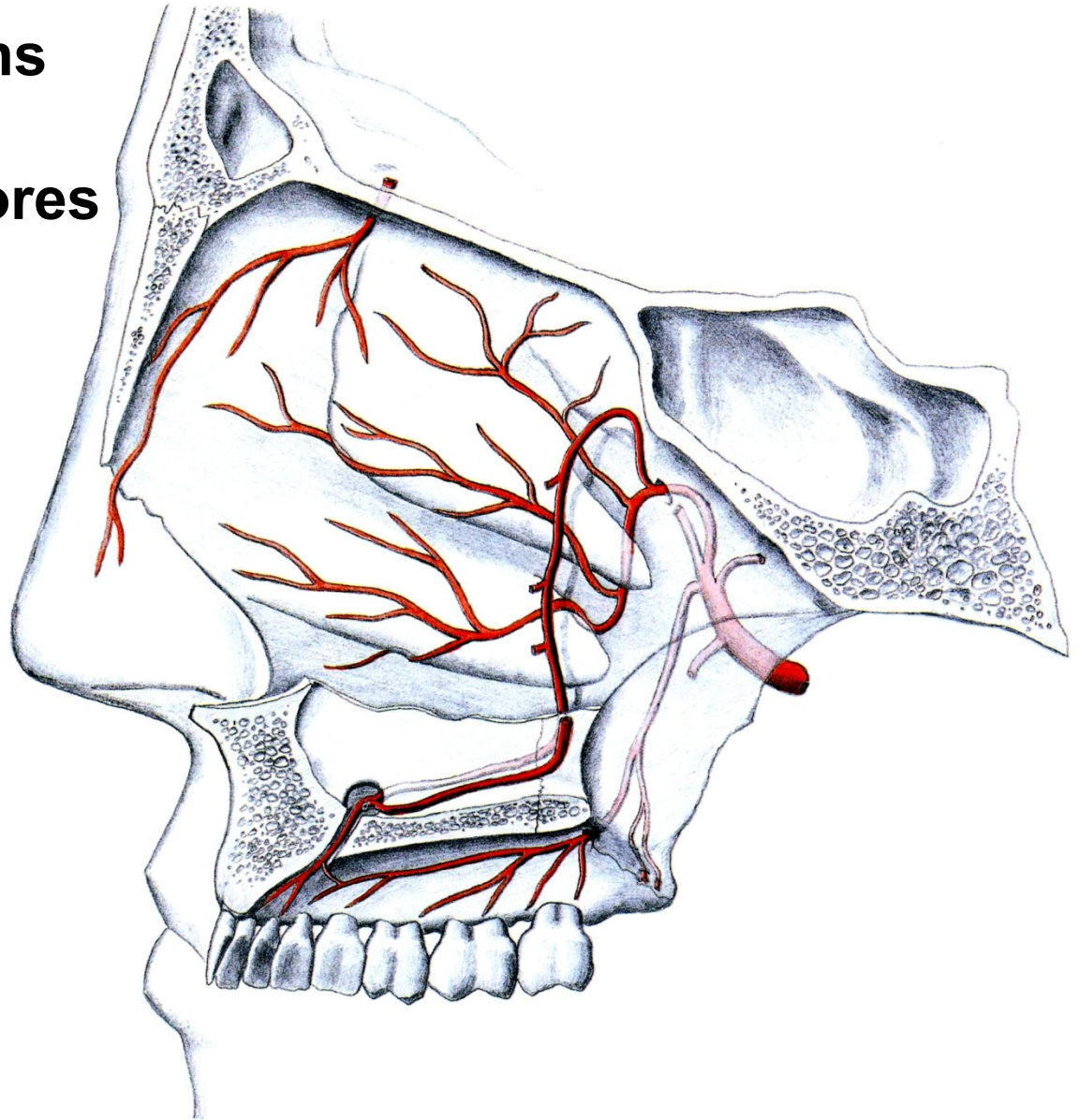
Pars pterygopalatina:

- a. alveolaris sup. post.
- a. infraorbitalis
 - aa. alveolares sup. ant.



A. MAXILLARIS (continuation):

- a. palatina descendens
 - a. palatina major
 - aa. palatinae minores
- a. sphenopalatina



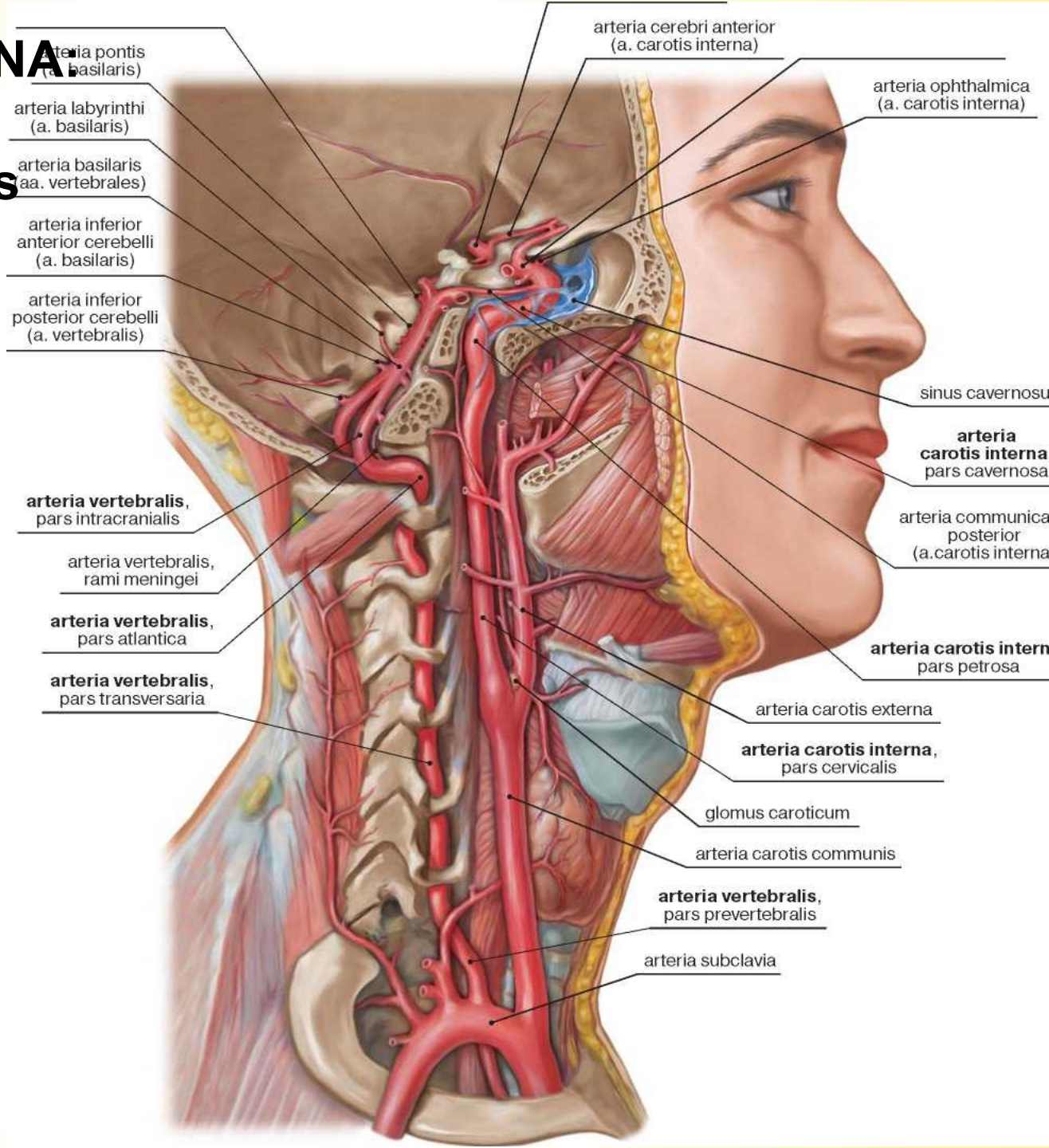
A. CAROTIS INTERNA

- aa. hypophysiales
- a. ophthalmica
- a. cerebri ant.
- a. cerebri media

Carotid syphon

Sinus caroticus

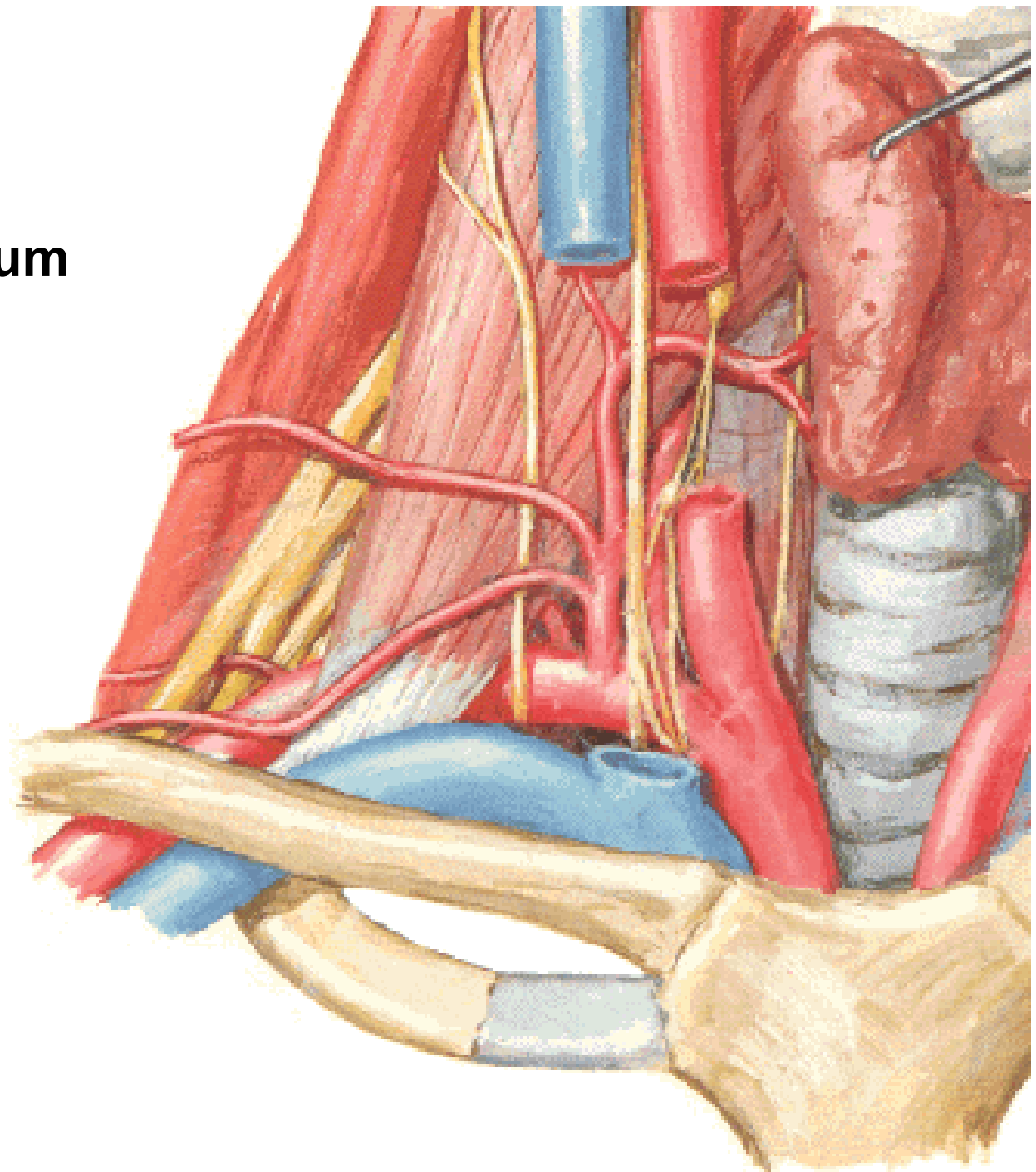
Glomus caroticum

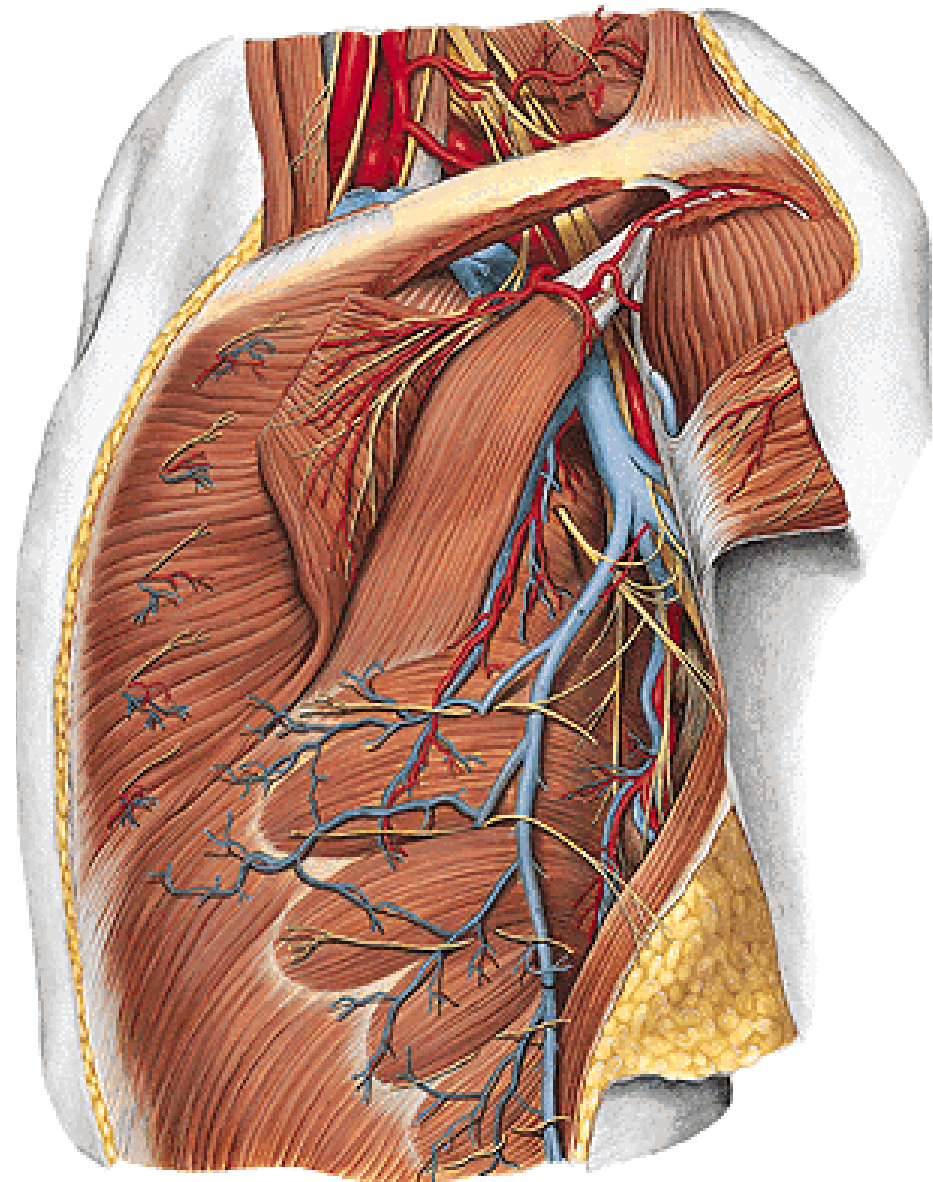
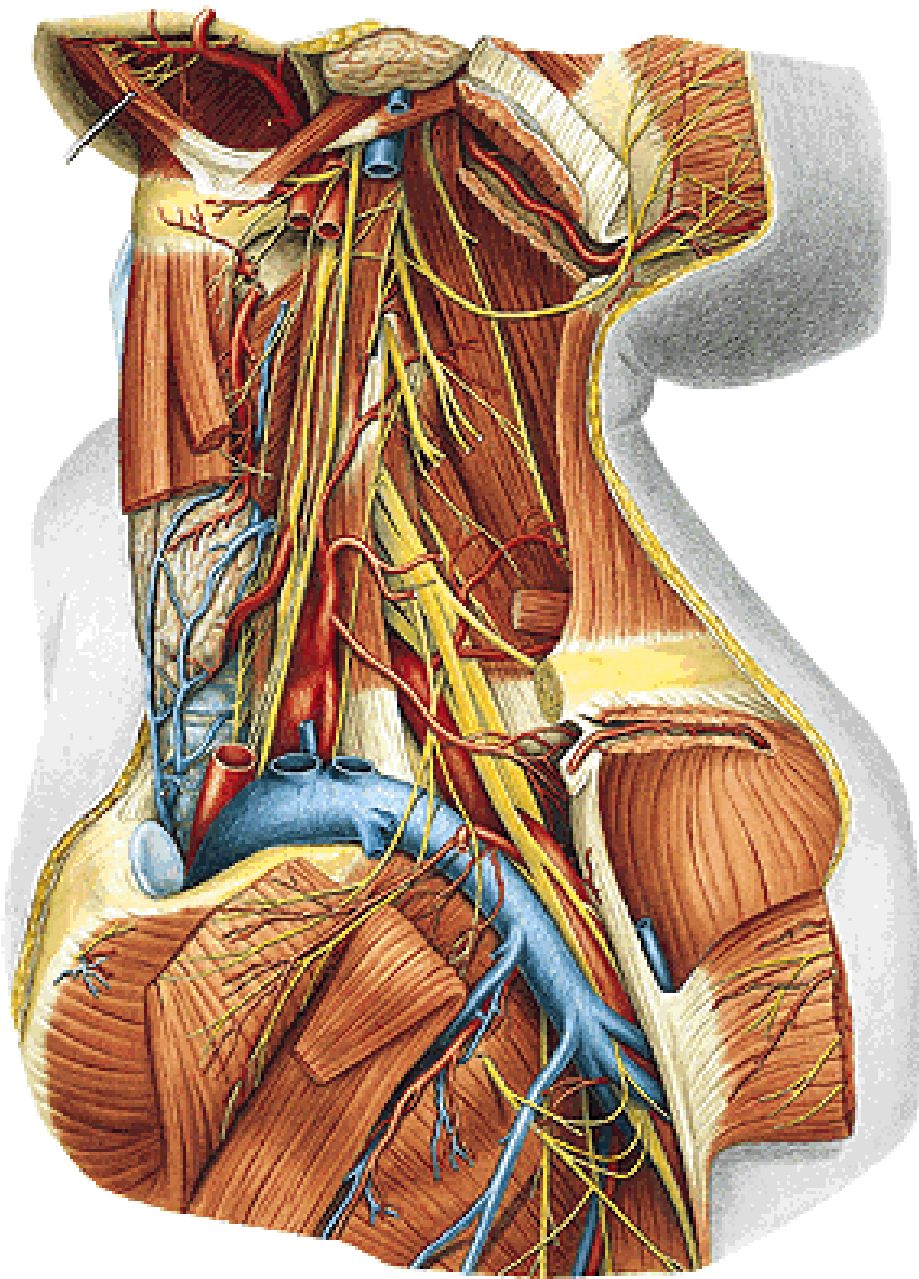


A. SUBCLAVIA

Cupula pleurae

Fissura scalenorum

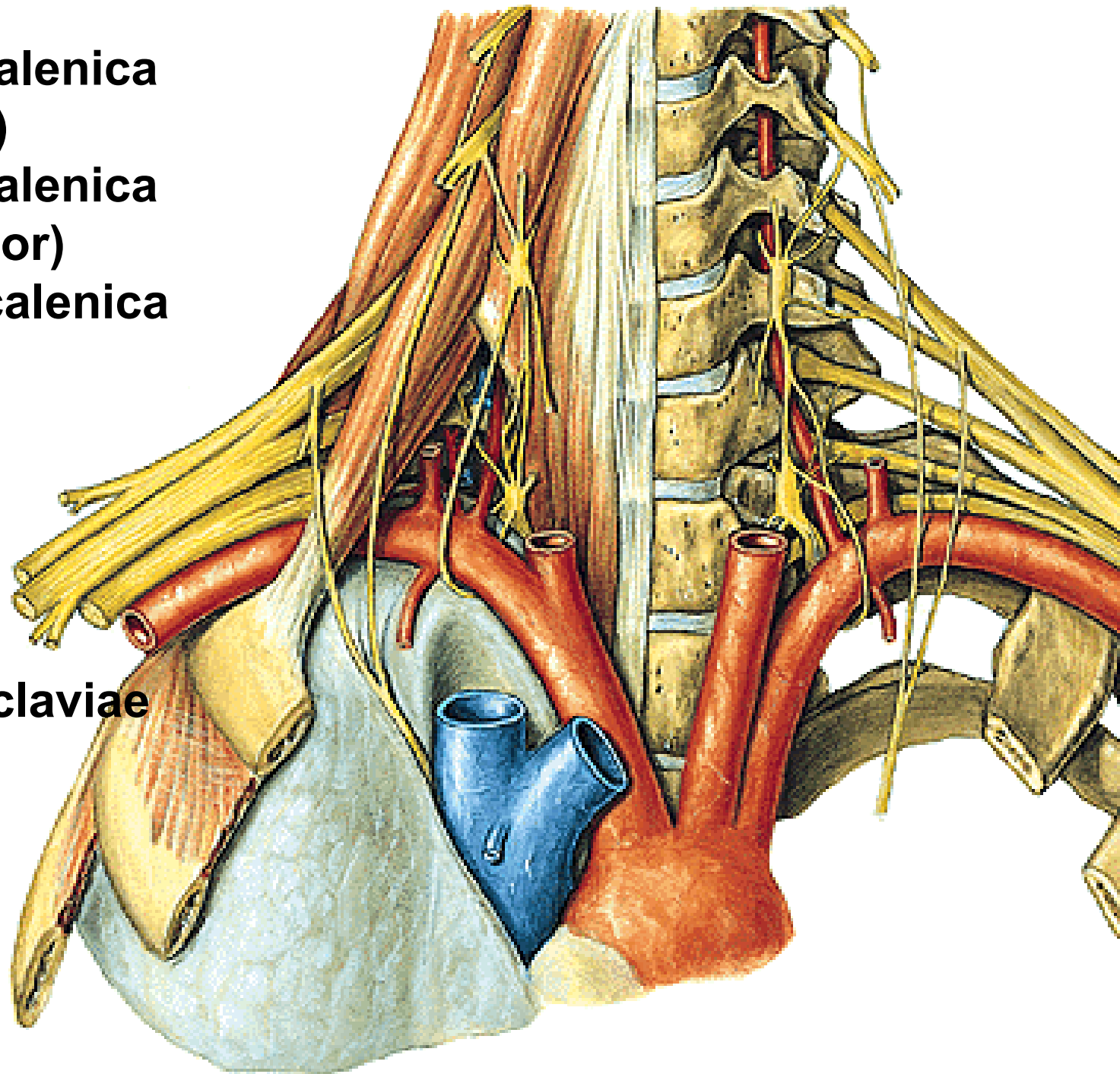




**Pars intrascalenica
(medial)**

**Pars interscalenica
(posterior)**

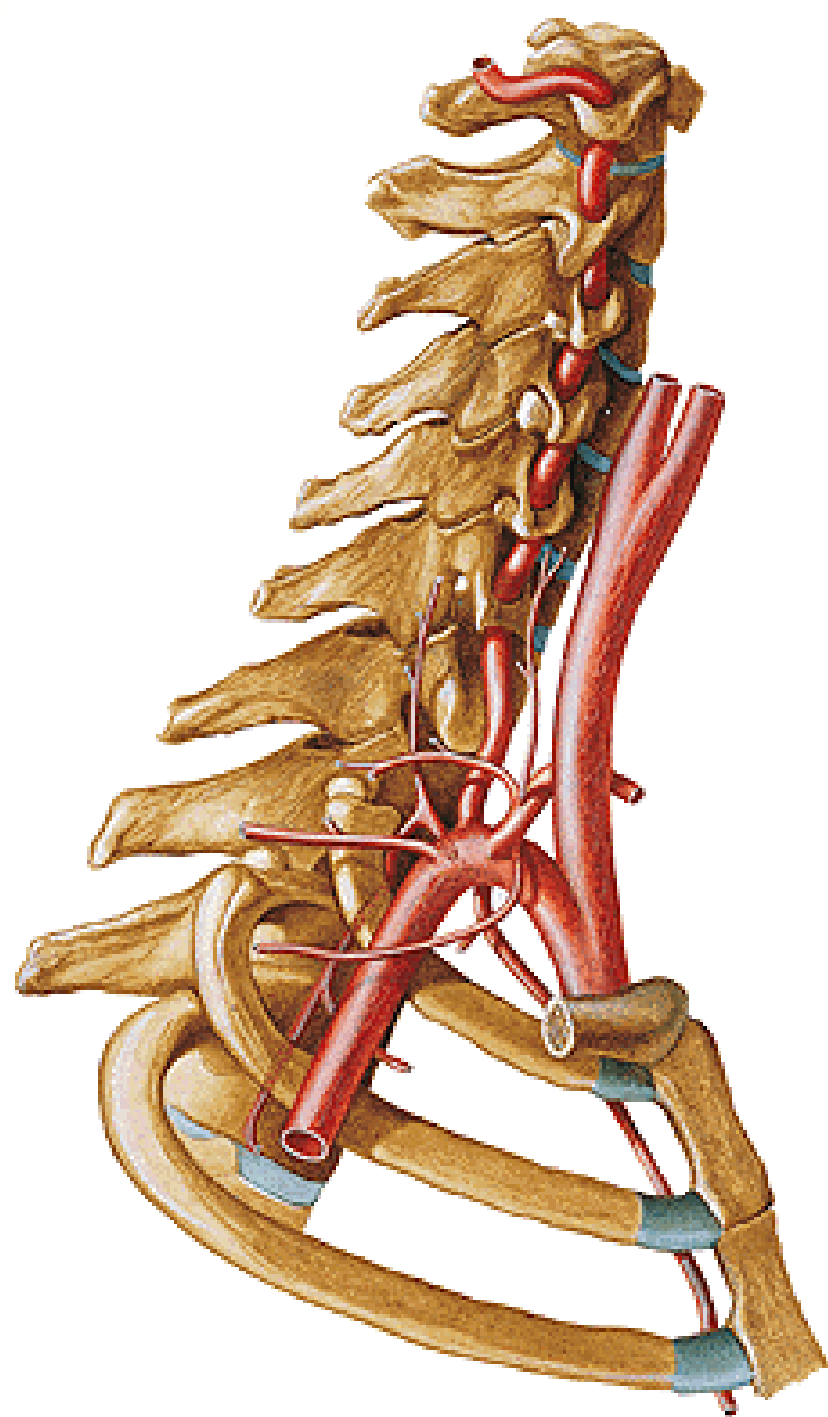
**Pars extrascalenica
(lateral)**



Sulcus a. subclaviae

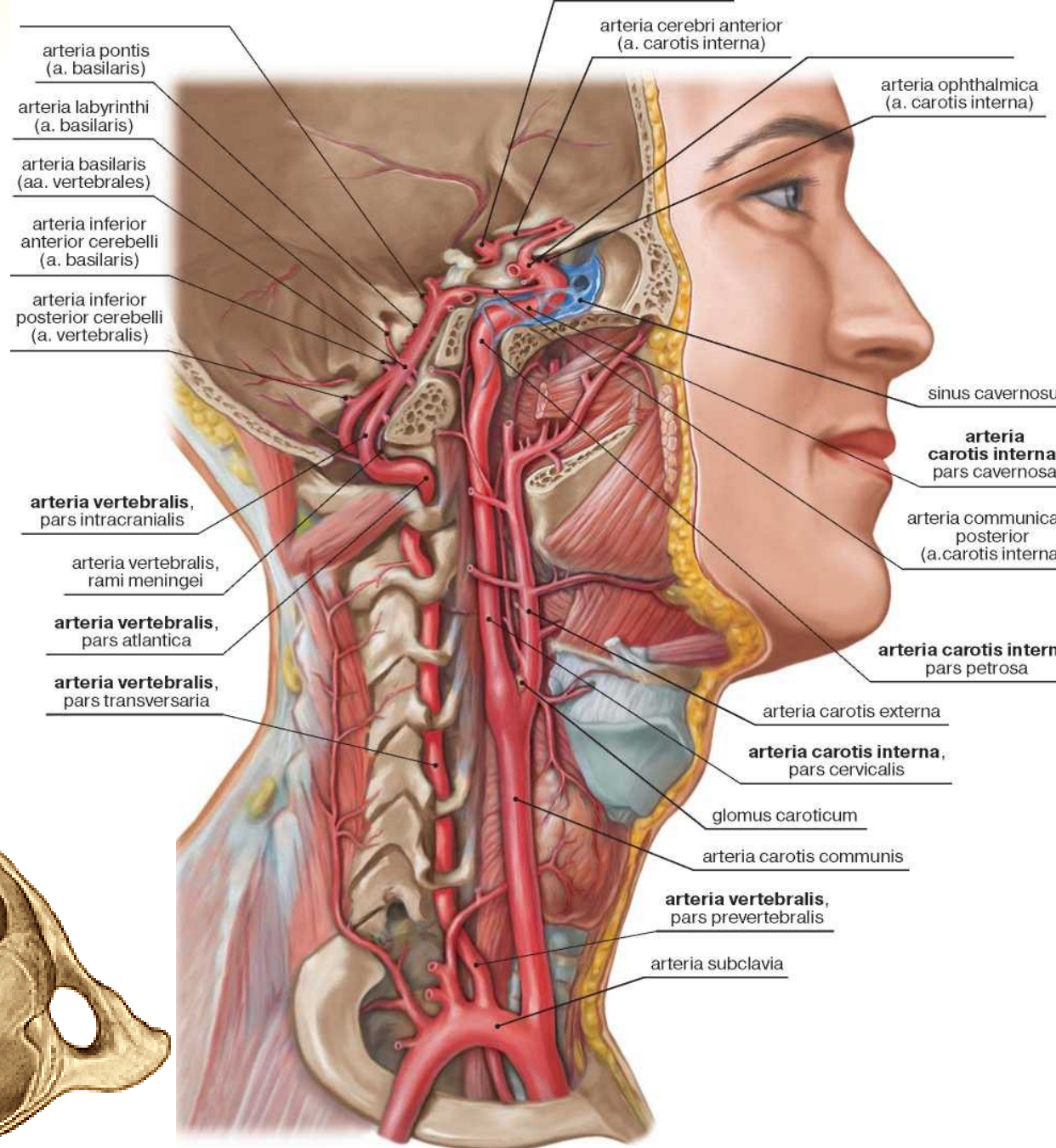
A. SUBCLAVIA

- a. vertebralis
- a. thoracica interna
- tr. thyrocervicalis
- tr. costocervicalis

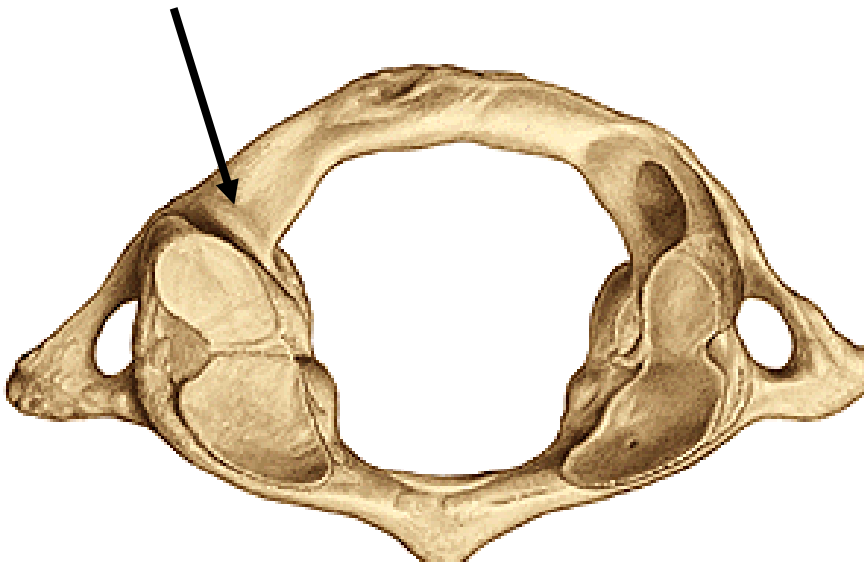


A. VERTEBRALIS

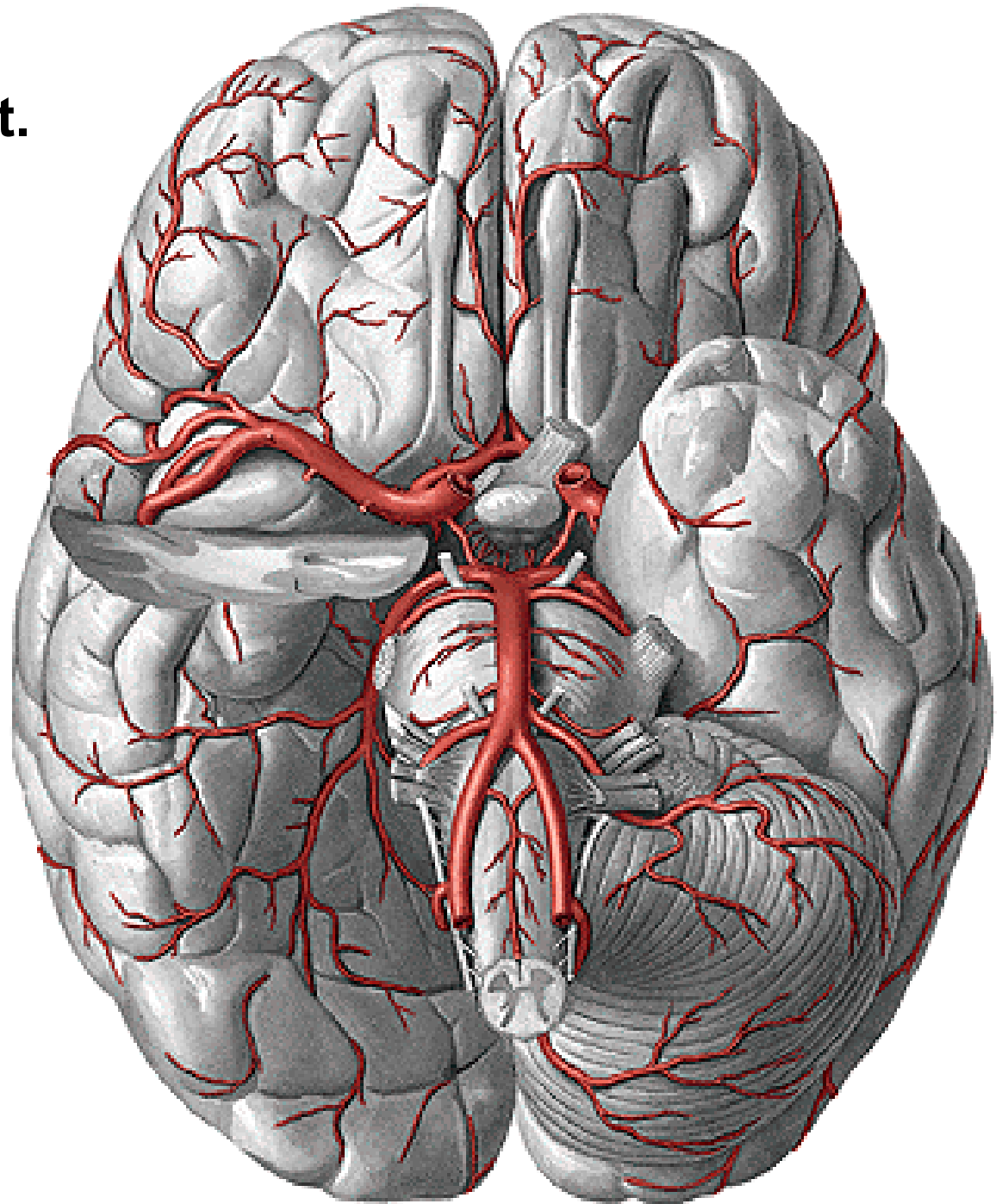
- rr. spinales
- rr. musculares



Sulcus a. vertebralis

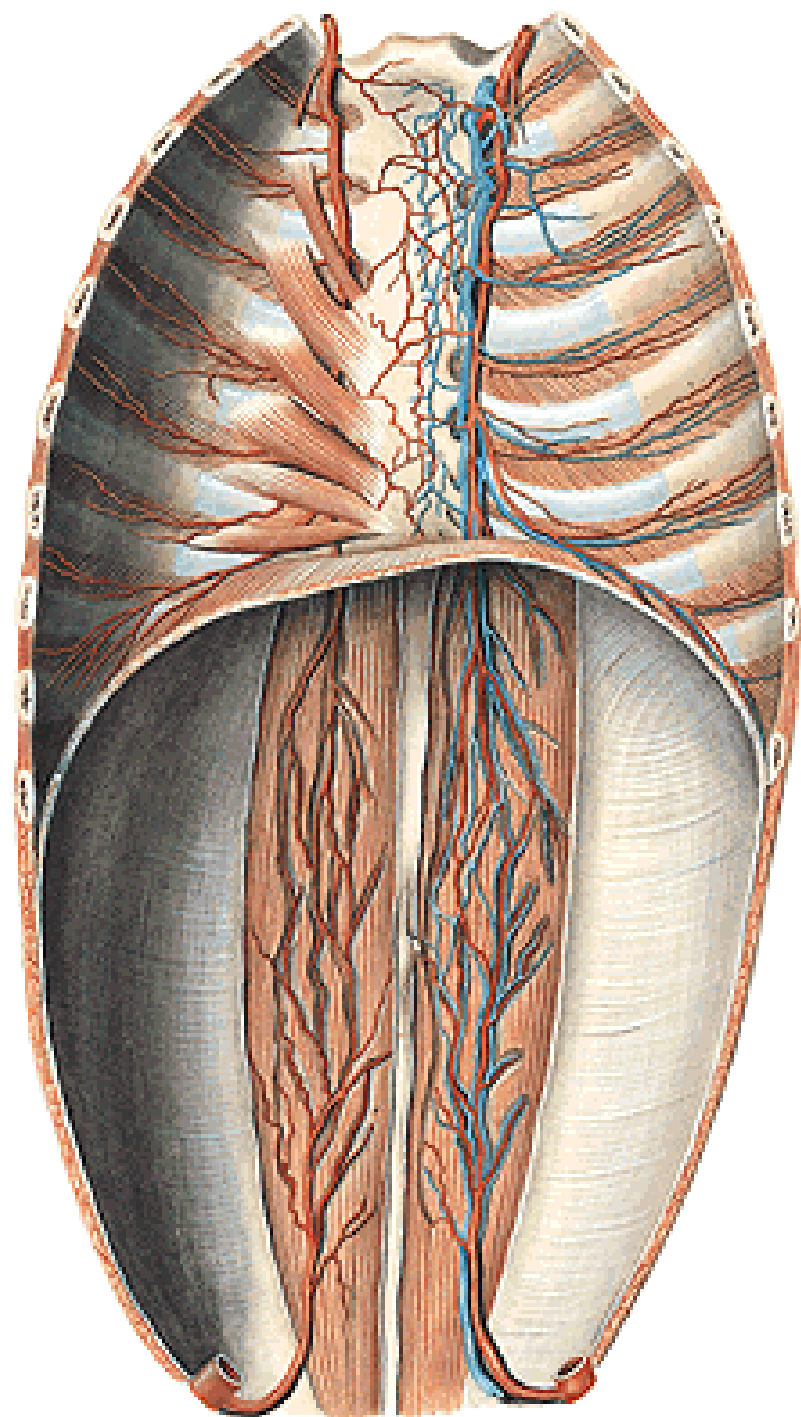


- a. cerebelli inf. post.
- a. basilaris

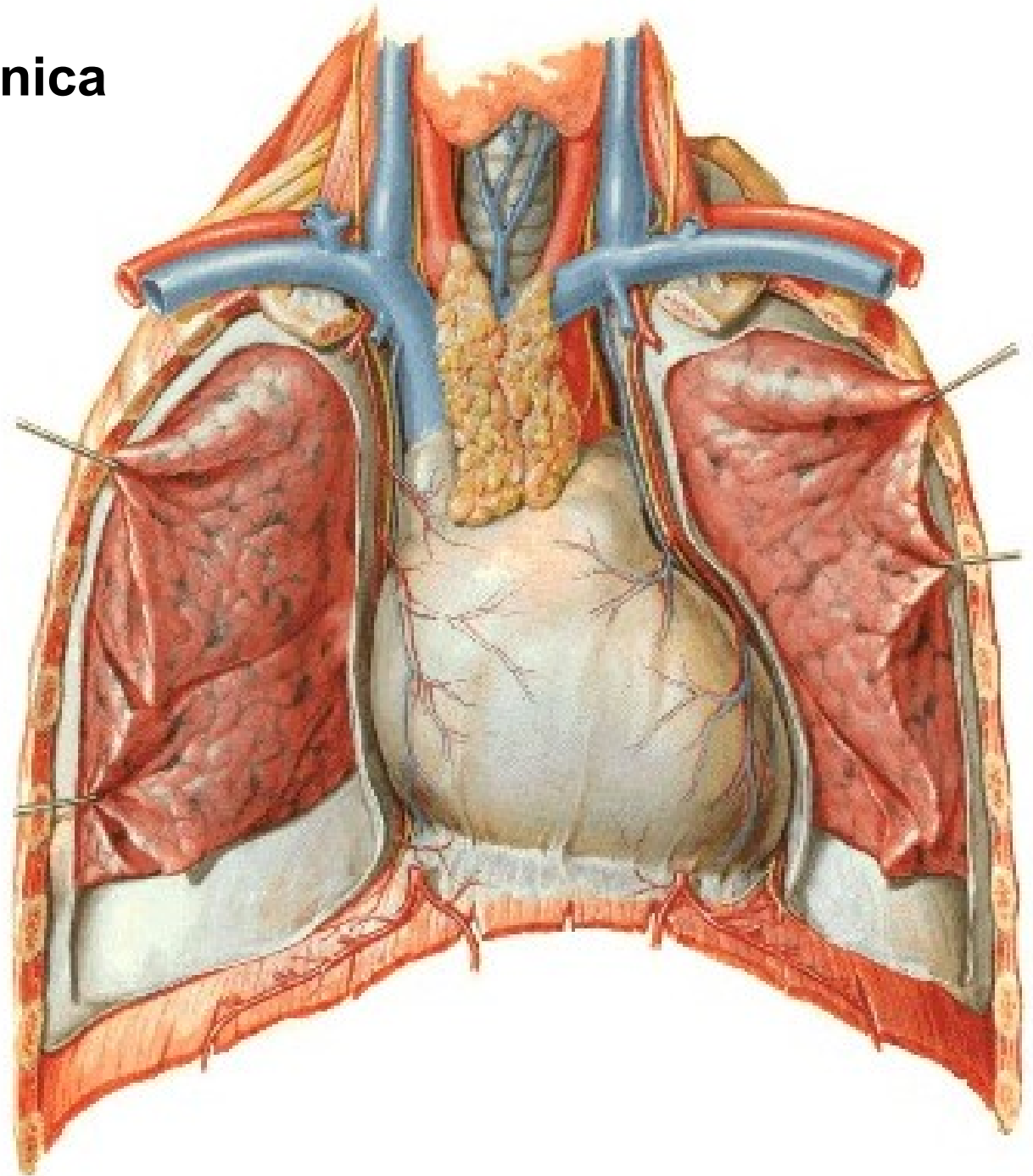


A. THORACICA INTERNA

- rr. mediastinales
- a. pericardiophrenica
- rr. intercostales ant.
- a. musculophrenica
 - rr. intercostales ant.
- a. epigastrica sup.

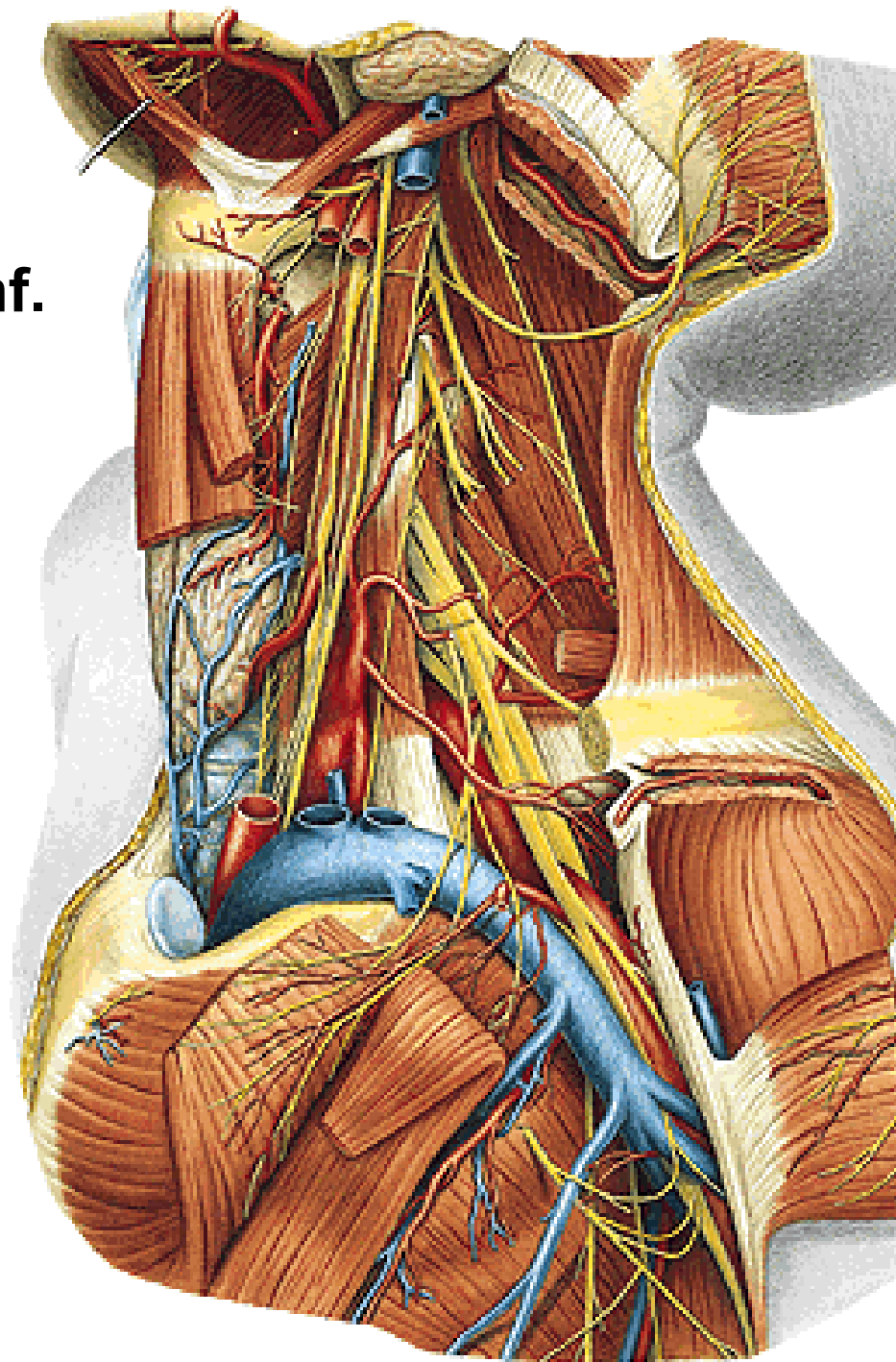


A. pericardiacophrenica

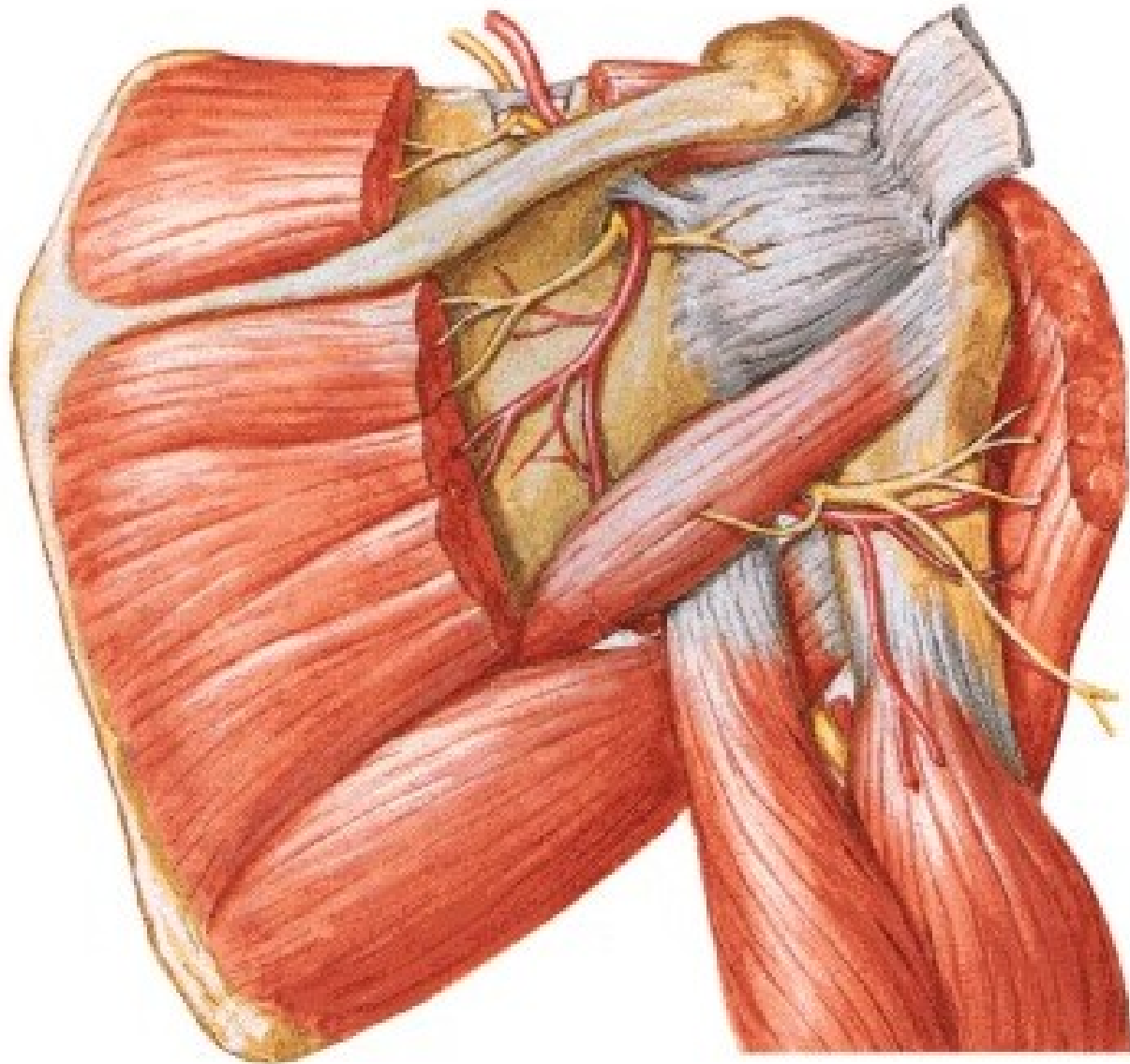


TRUNCUS THYROCERVICALIS

- a. thyroidea inf. - a. laryngea inf.
- a. cervicalis ascendens
- a. transversa colli
- a. suprascapularis

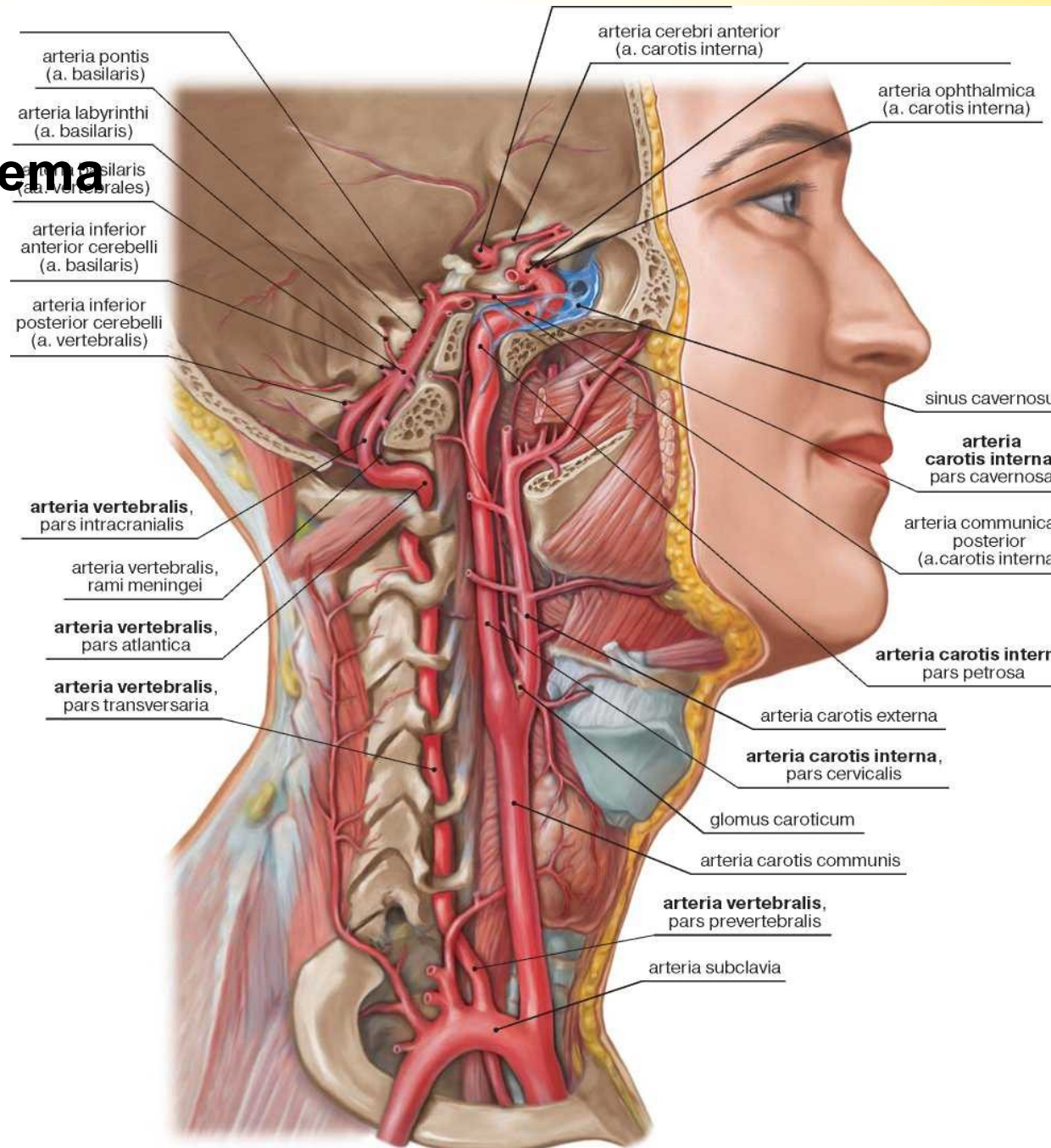


A. suprascapularis



TRUNCUS COSTOCERVICALIS

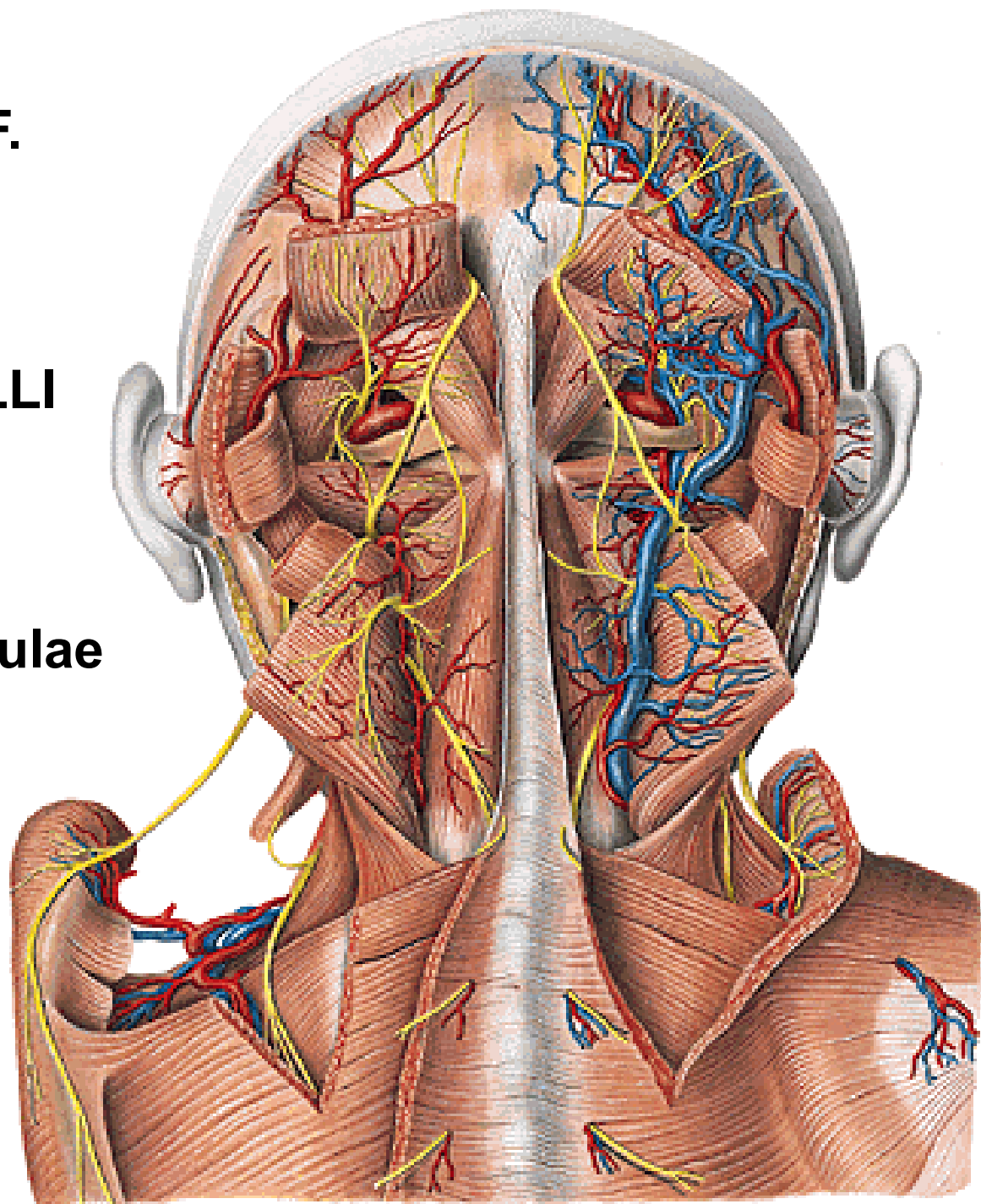
- a. cervicalis prof.
- a. intercostalis suprema



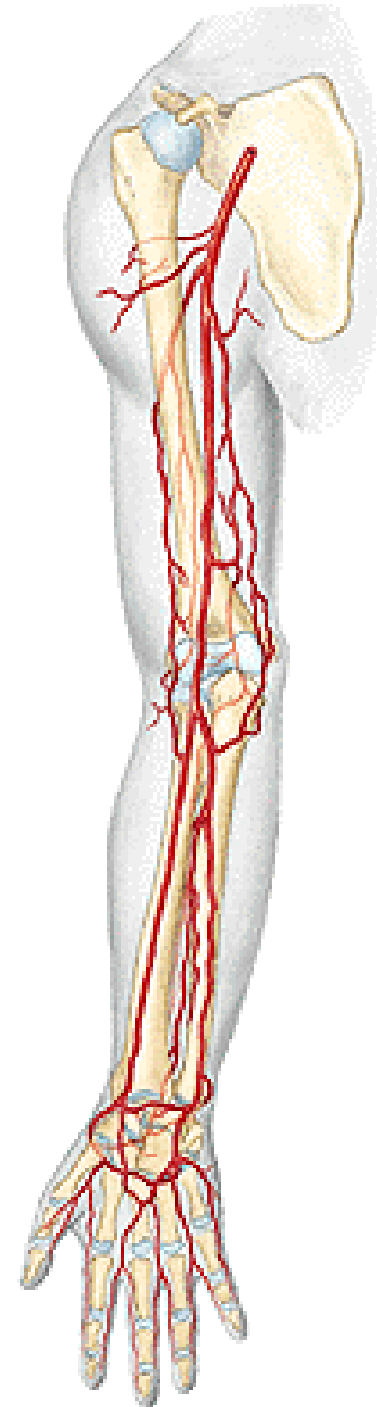
A. CERVICALIS PROF.

A. TRANSVERSA COLLI

- r. superficialis
- r. profundus
= a. dorsalis scapulae

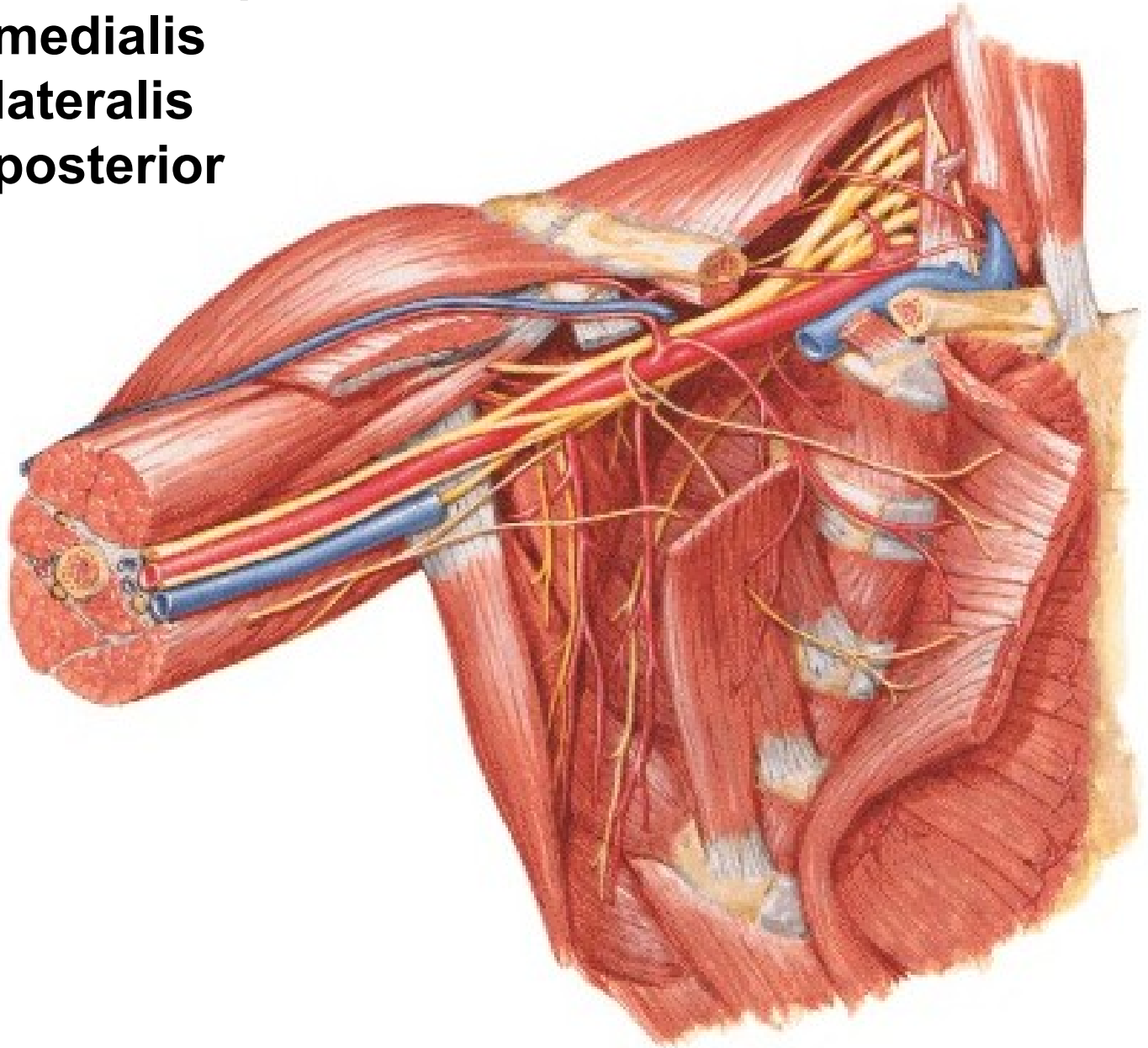


**A. axillaris – a. brachialis –
a. radialis + a. ulnaris**



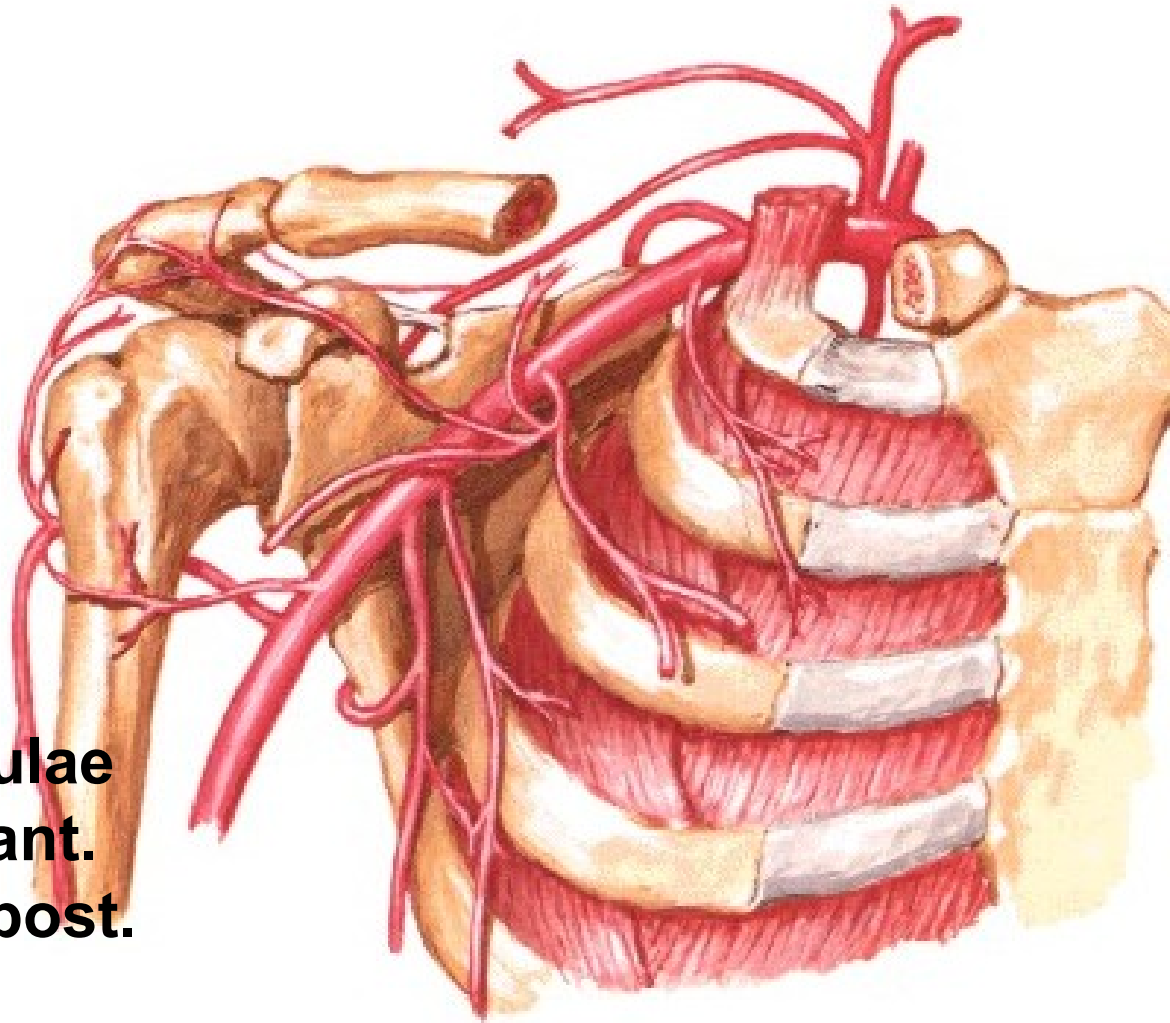
Pars infraclavicularis plexus brachialis

- fasciculus medialis**
- fasciculus lateralis**
- fasciculus posterior**



A. AXILLARIS

- a. thoracica superior
- a. thoracoacromialis
 - r. deltoideus
 - r. acromialis
 - rr. pectorales
- a. thoracica lateralis
 - rr. mammarii lat.
- a. subscapularis
 - a. thoracodorsalis
 - a. circumflexa scapulae
- a. circumflexa humeri ant.
- a. circumflexa humeri post.

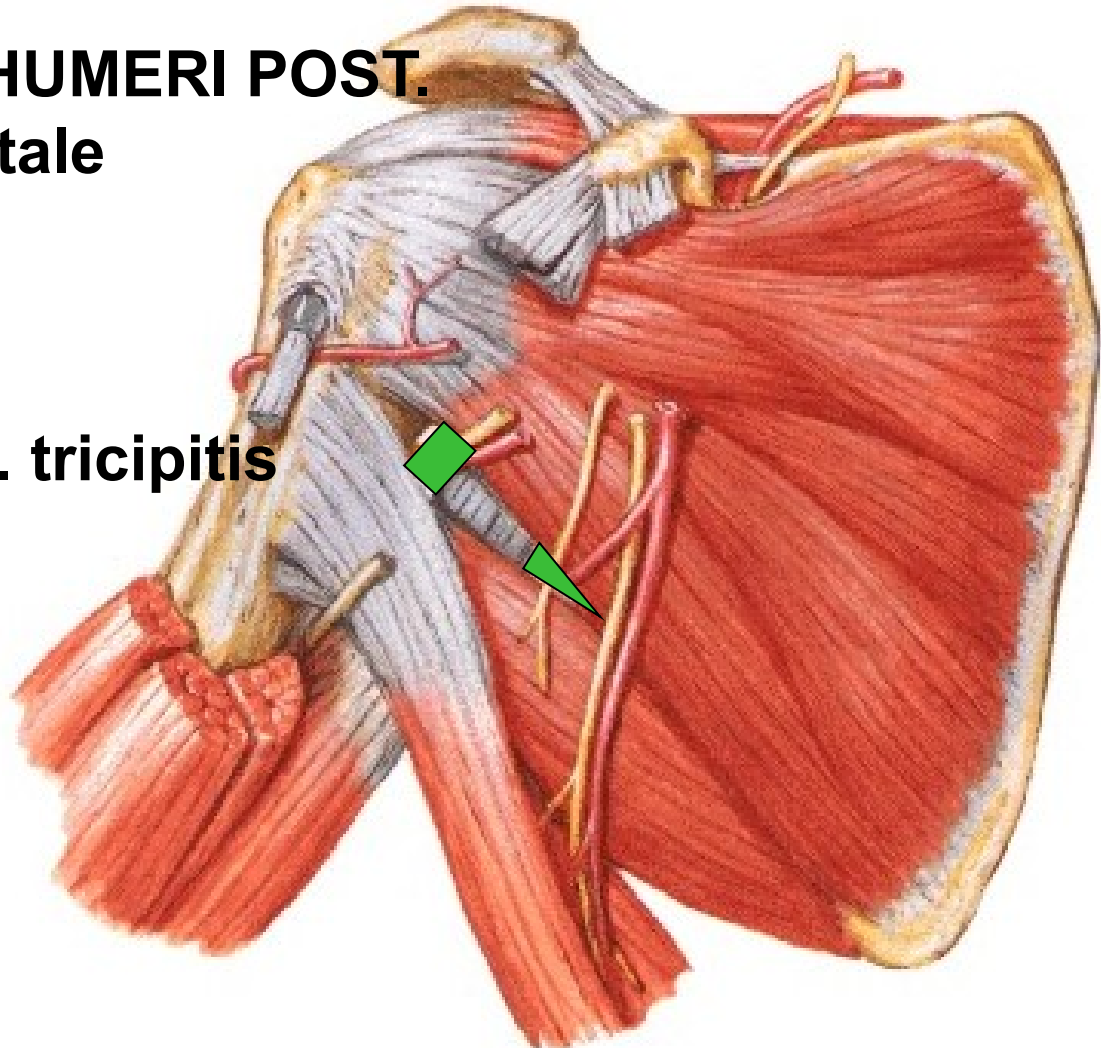


A. CIRCUMFLEXA SCAPULAE

- foramen omotricipitale (trilaterum):** m. teres minor
m. teres major
caput longum m. tricipitis

A. CIRCUMFLEXA HUMERI POST.

- for. humerotricipitale (quadrilaterum):**
m. teres minor
m. teres major
caput longum m. tricipitis
humerus

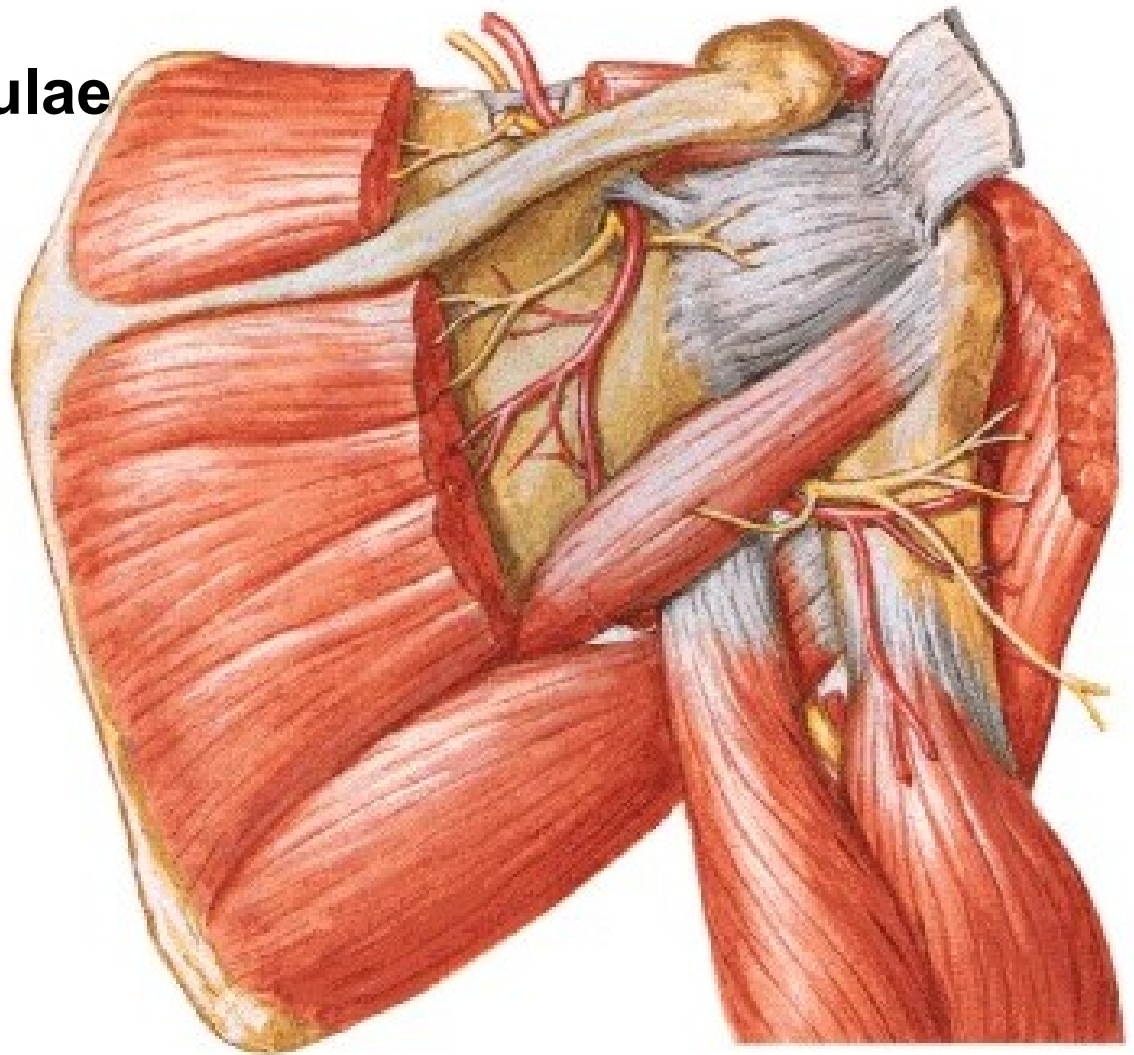


Fossa infraspinata:

anastomosis

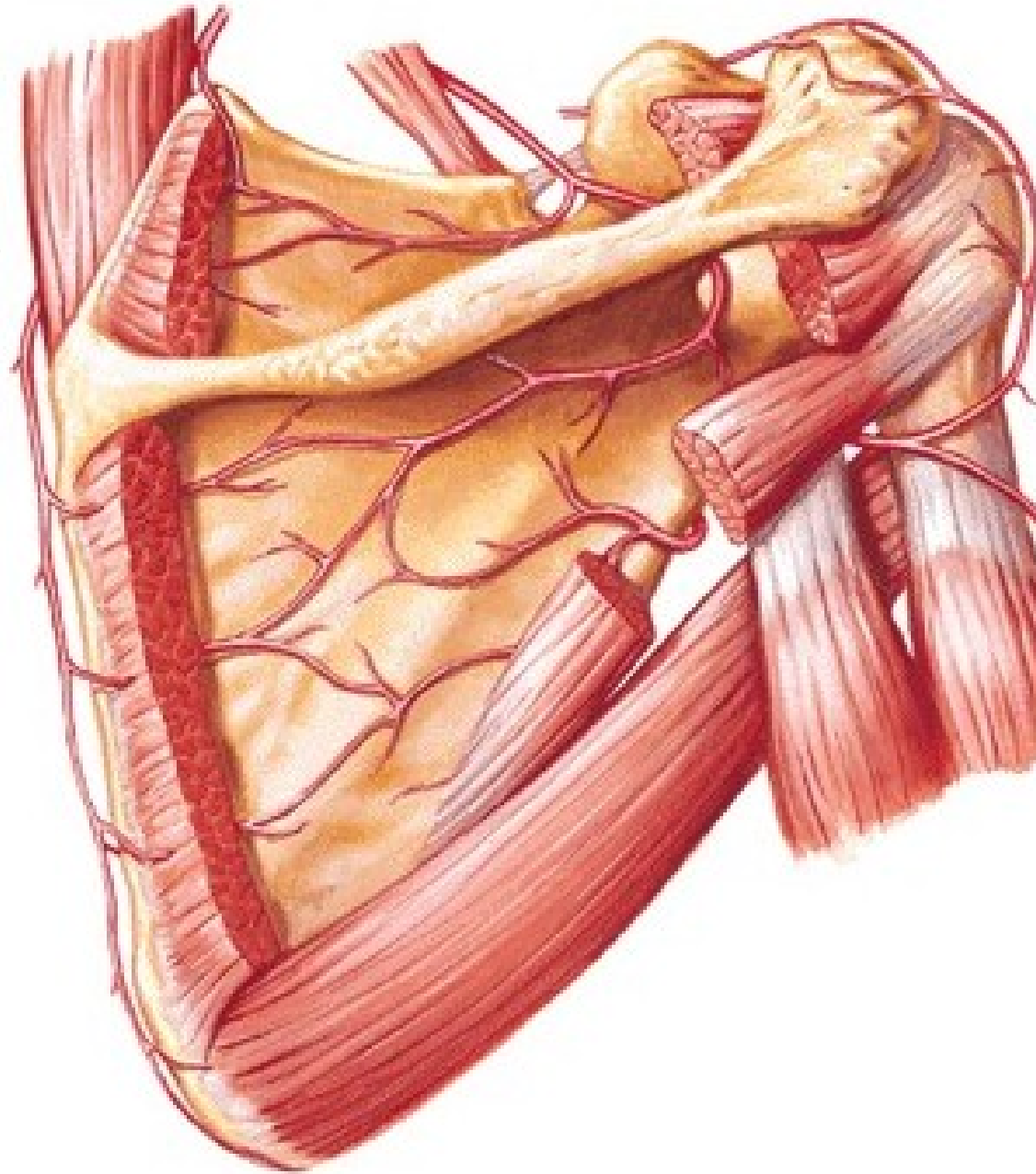
a. suprascapularis

+ a. circumflexa scapulae



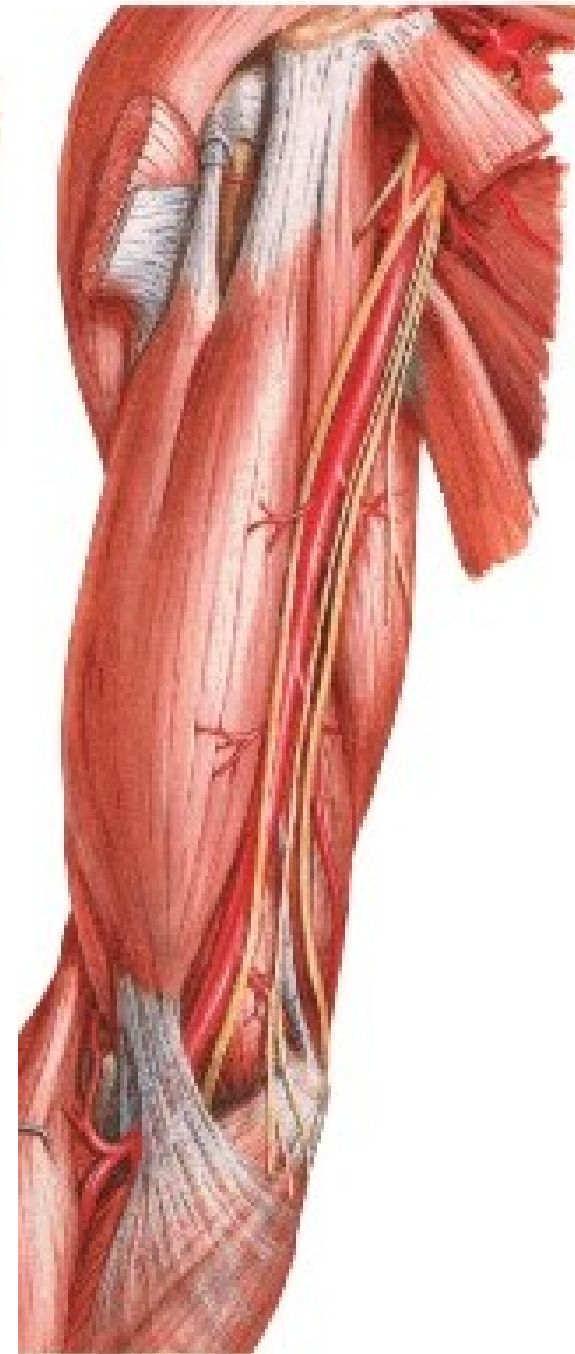
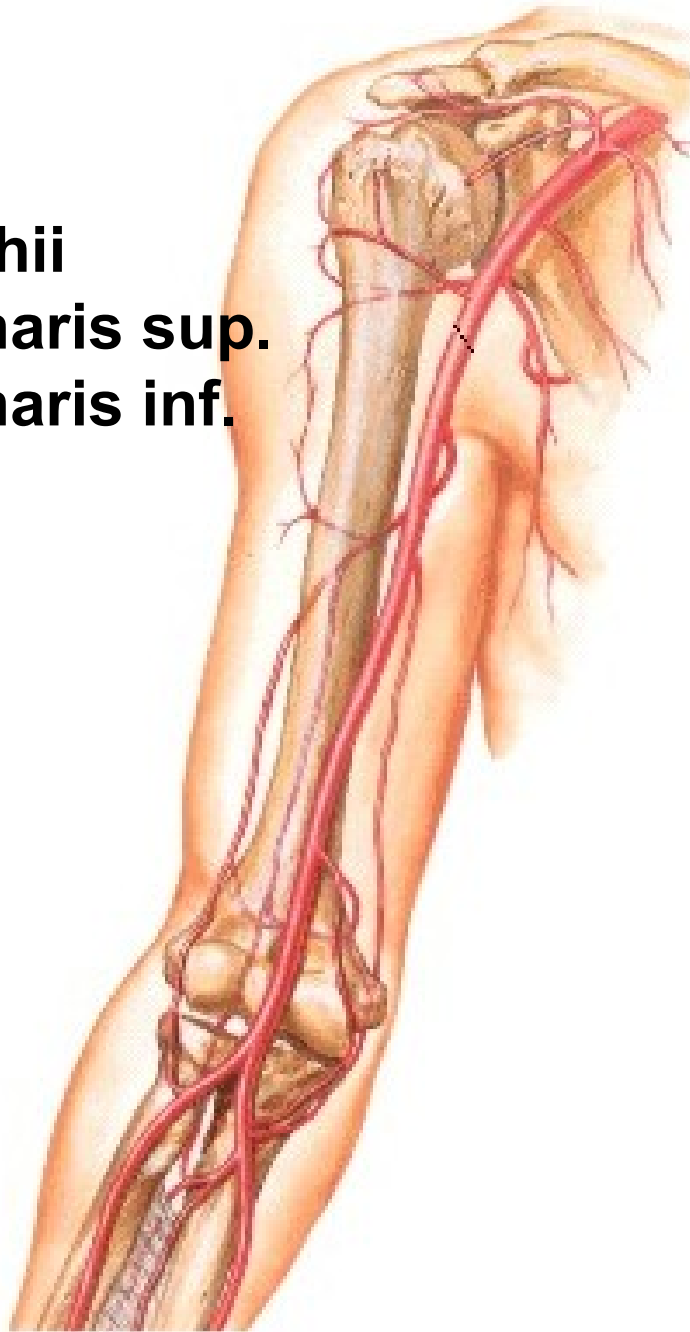
ARTERIAL ANASTOMOSES AROUND THE SCAPULA

- A. transversa colli**
- A. suprascapularis**
- A. circumflexa scapulae**
- Aa. intercostales**



A. BRACHIALIS

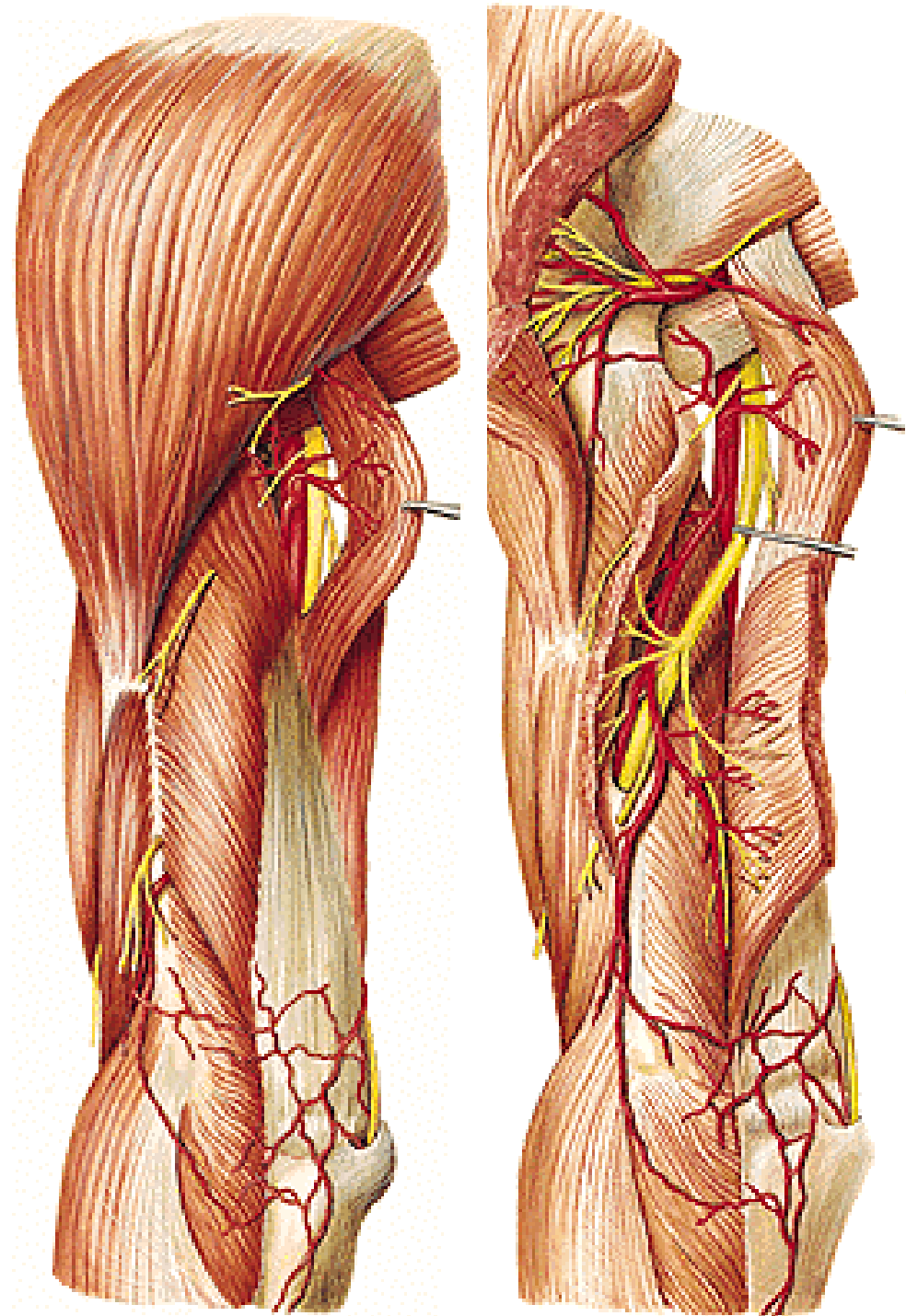
- a. profunda brachii
- a. collateralis ulnaris sup.
- a. collateralis ulnaris inf.
- a. radialis
- a. ulnaris



A. PROFUNDA BRACHII

- r. deltoideus
- a. nutricia humeri
- a. collateralis media
- a. collateralis radialis

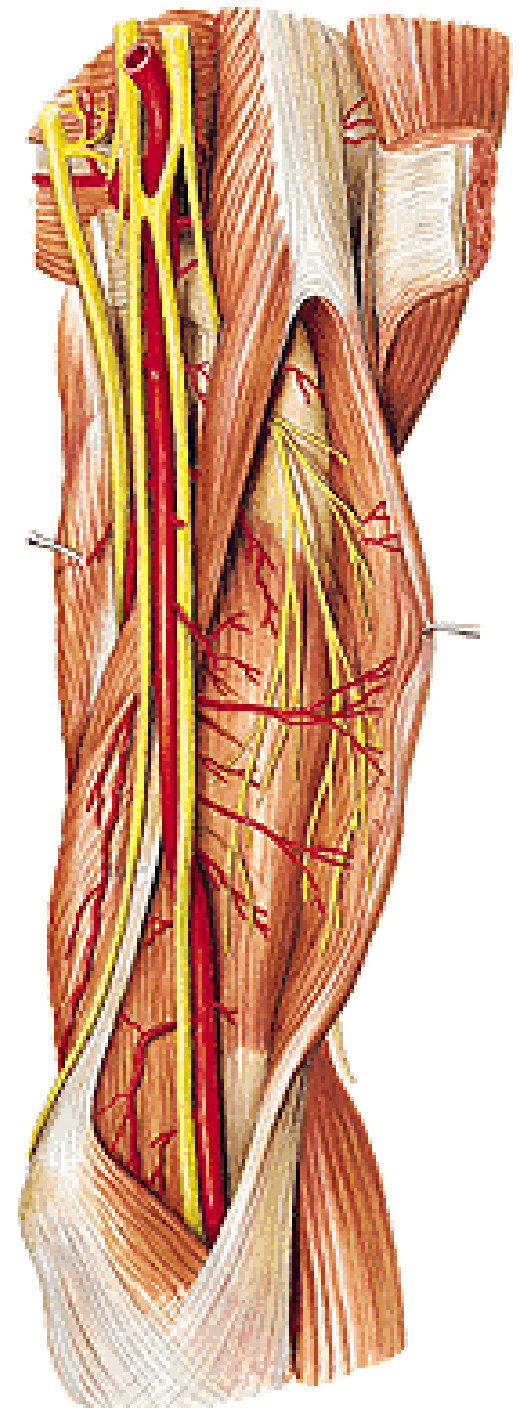
Rete articulare cubiti



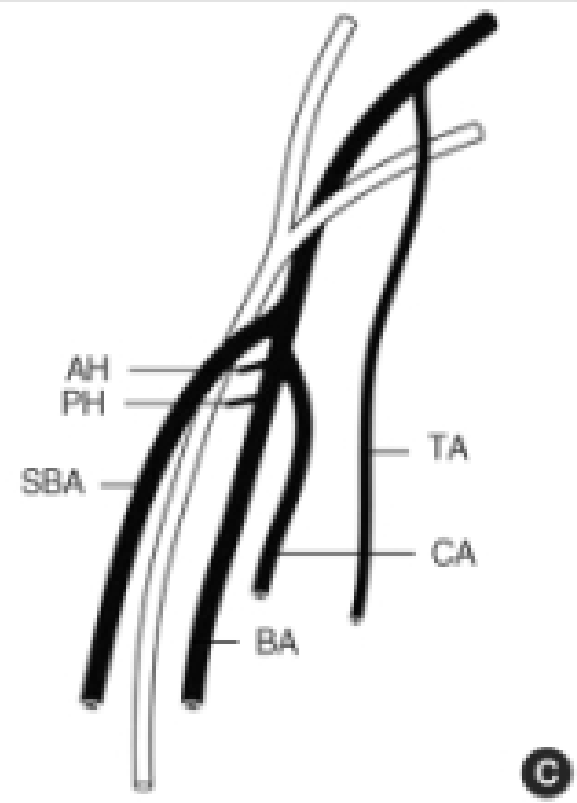
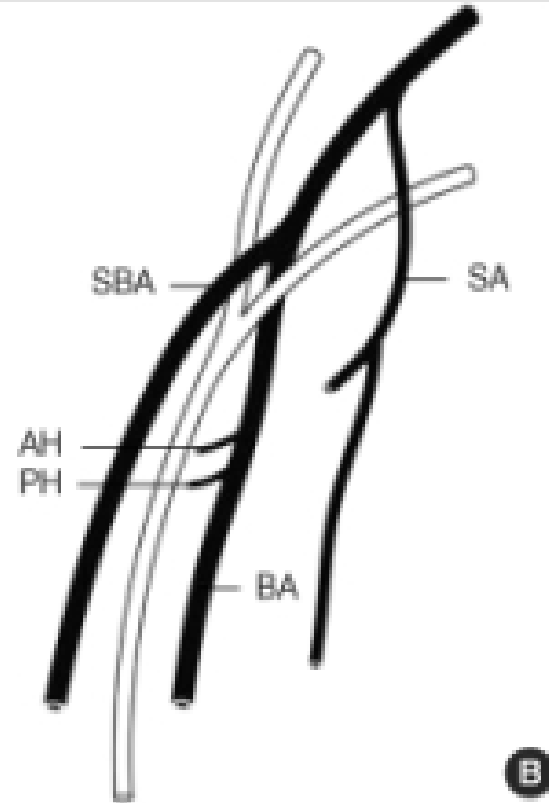
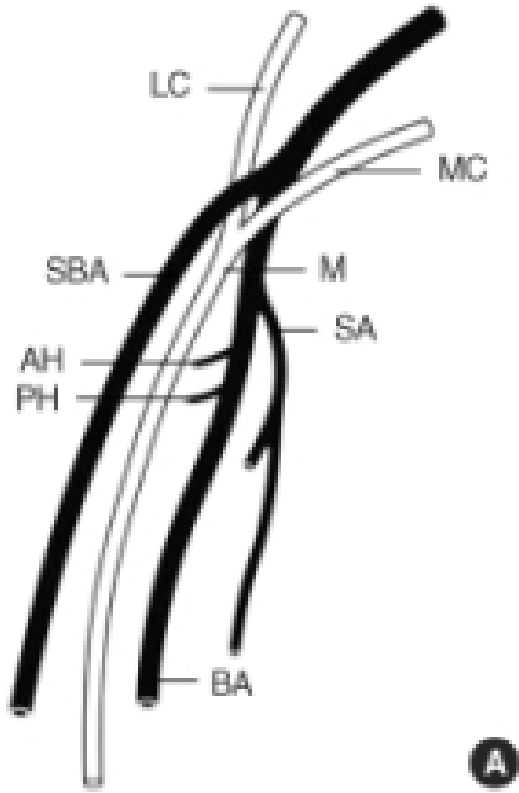
A. collateralis ulnaris sup.

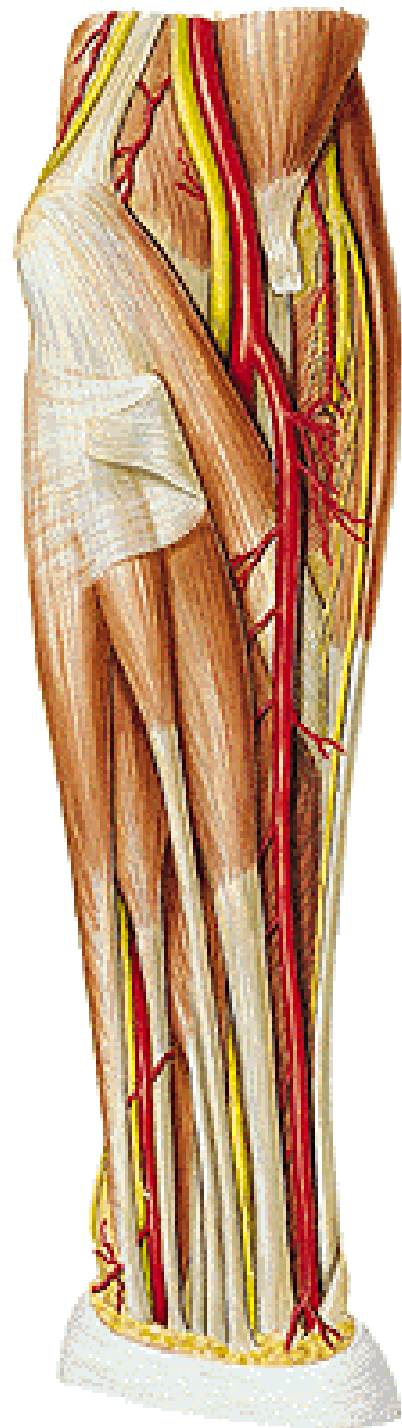
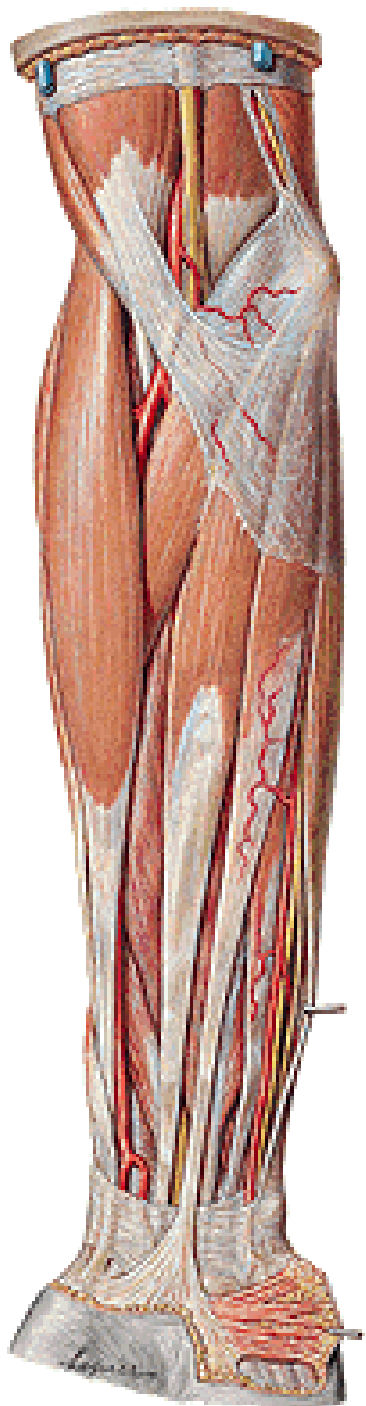
A. collateralis ulnaris inf.

Rete articulare cubiti



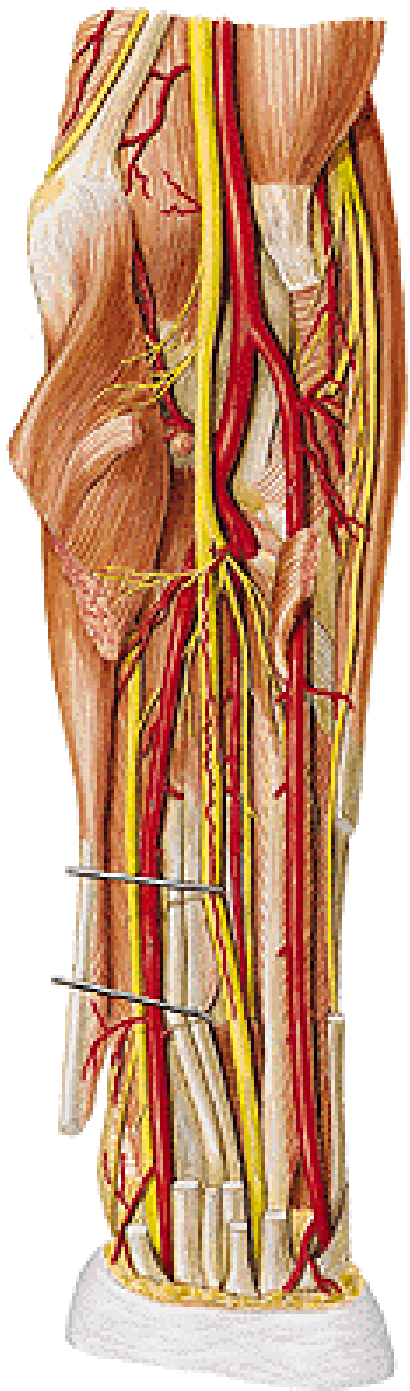
A. brachialis superficialis (12%)





A. RADIALIS

m. pronator teres
m. brachioradialis
m. flexor carpi radialis



Posteriorly:

tendon of m. biceps brachii

m. supinator

insertion of m. pronator teres

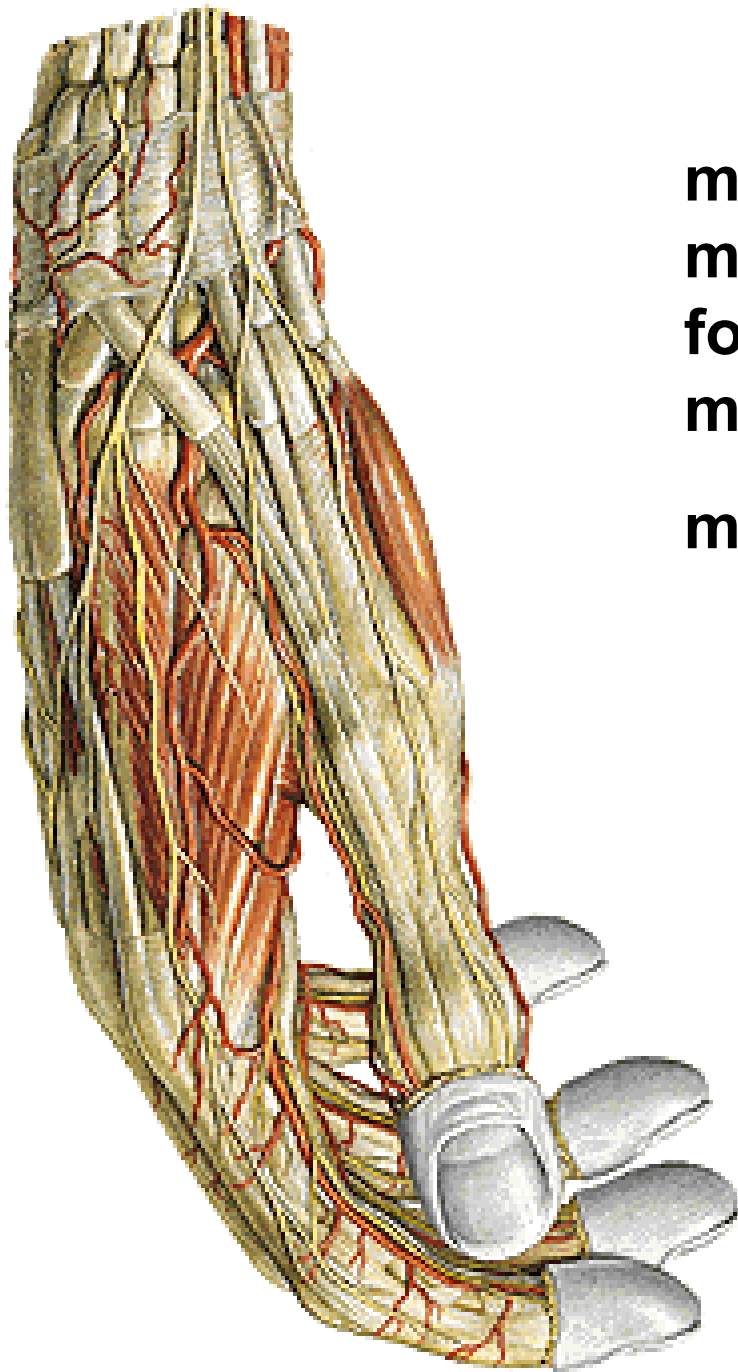
caput radiale m. flexoris digitorum spf.

m. flexor pollicis longus

m. pronator quadratus

distal end of the radius

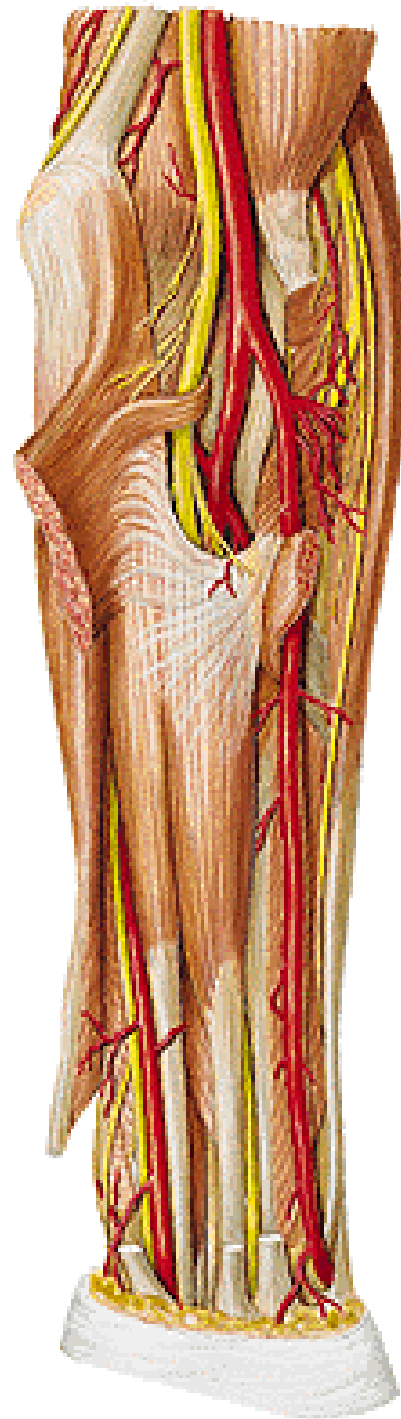
r. superficialis n. radialis



m.abductor pollicis longus
m. extensor pollicis brevis
foveola radialis
m. extensor pollicis longus
m. interosseus dorsalis I.

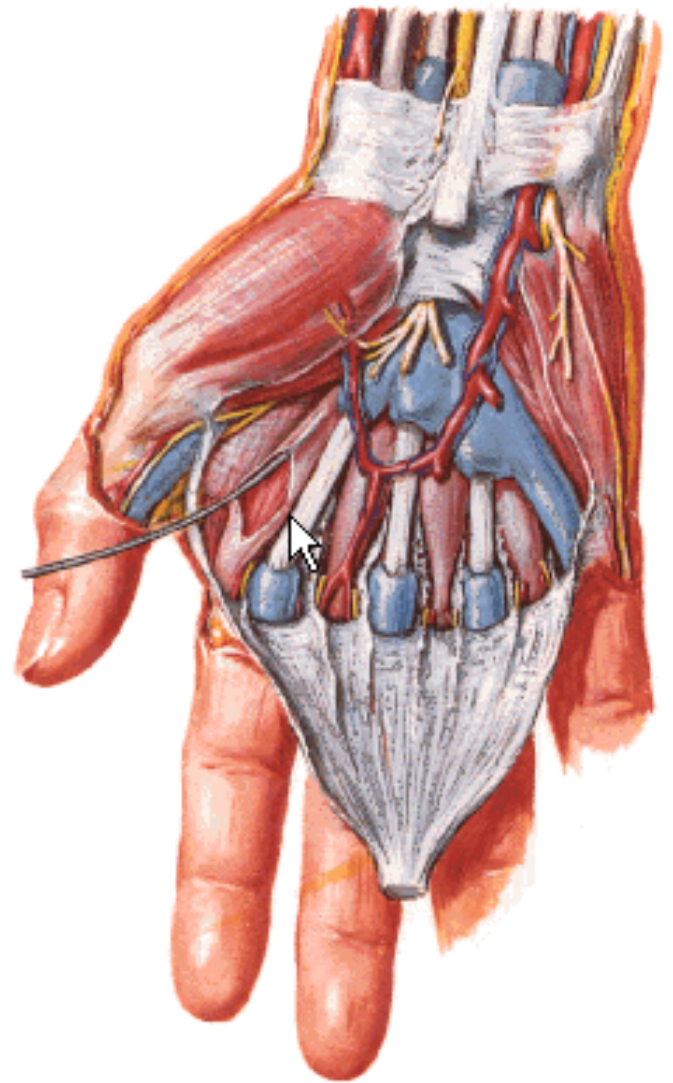
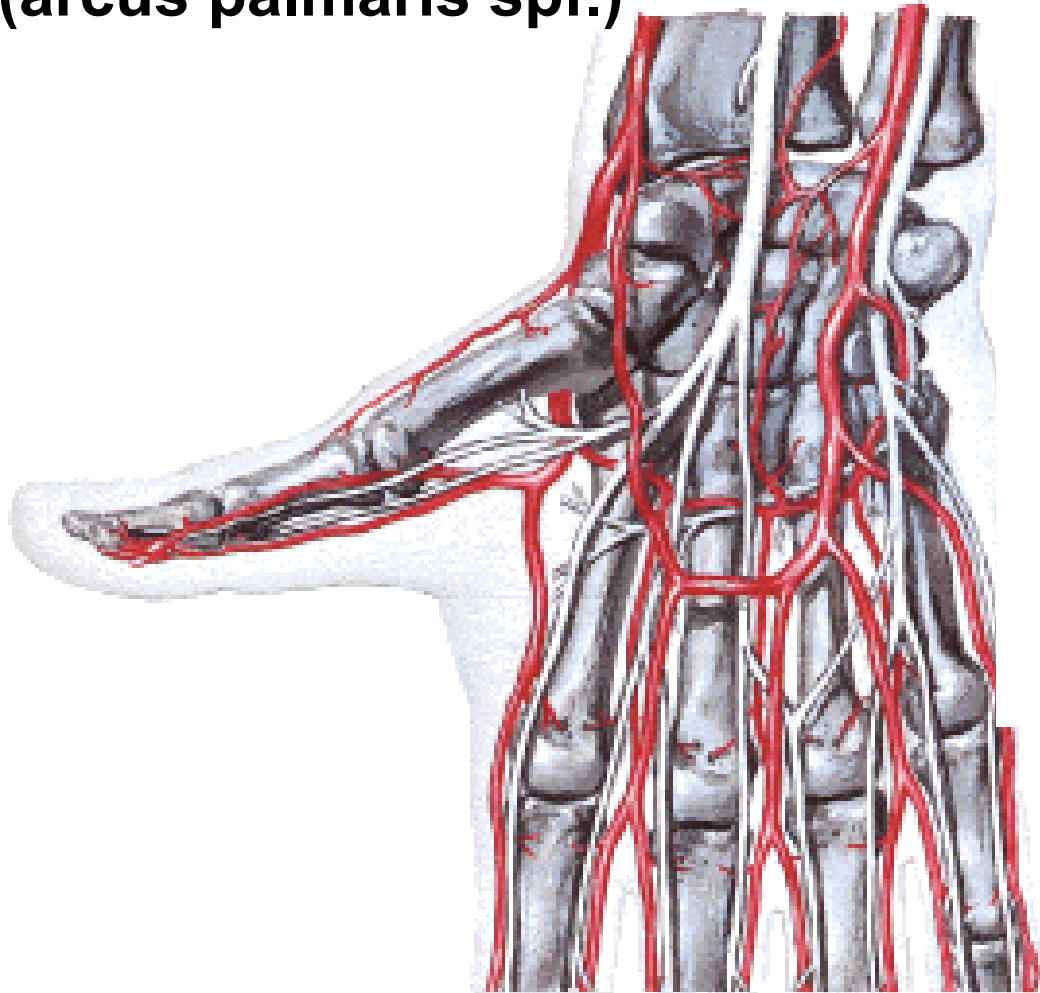A. RADIALIS - branches:

- a. recurrens radialis
(rete articulare cubiti)**
- rr. musculares**



A. RADIALIS – branches:

- r. carpalis palmaris
(rete carpi palmare)
- r. palmaris spf.
(arcus palmaris spf.)



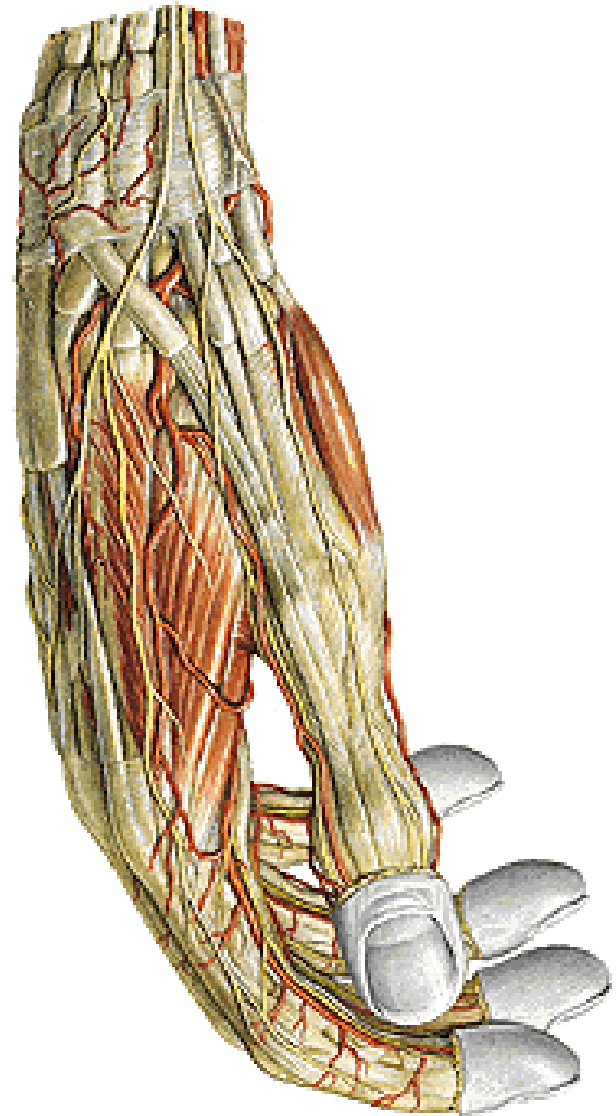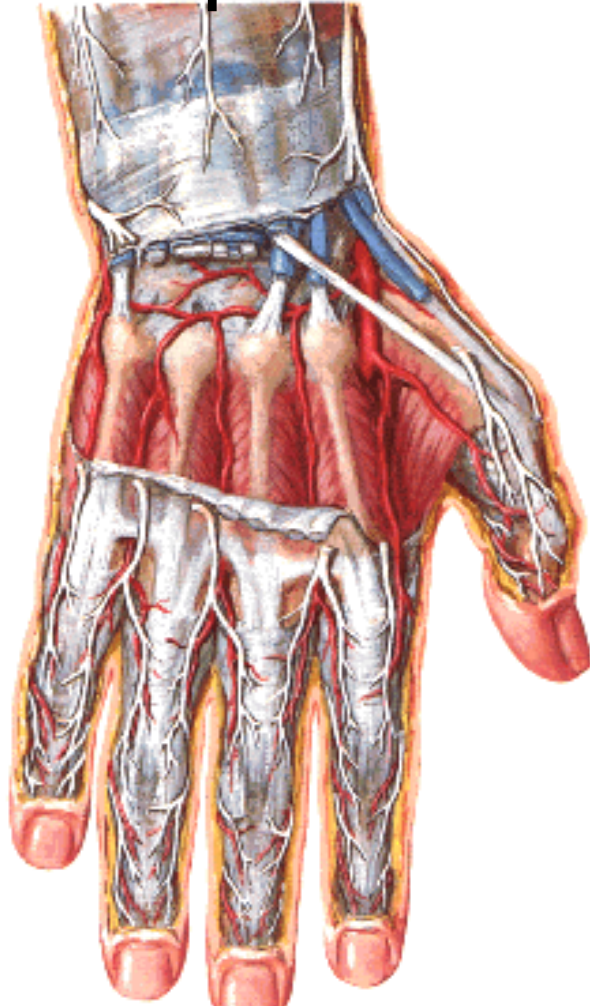
A. RADIALIS – branches:

-r. carpalis dorsalis

(rete carpi dorsale – 3 aa. metacarpales dorsales

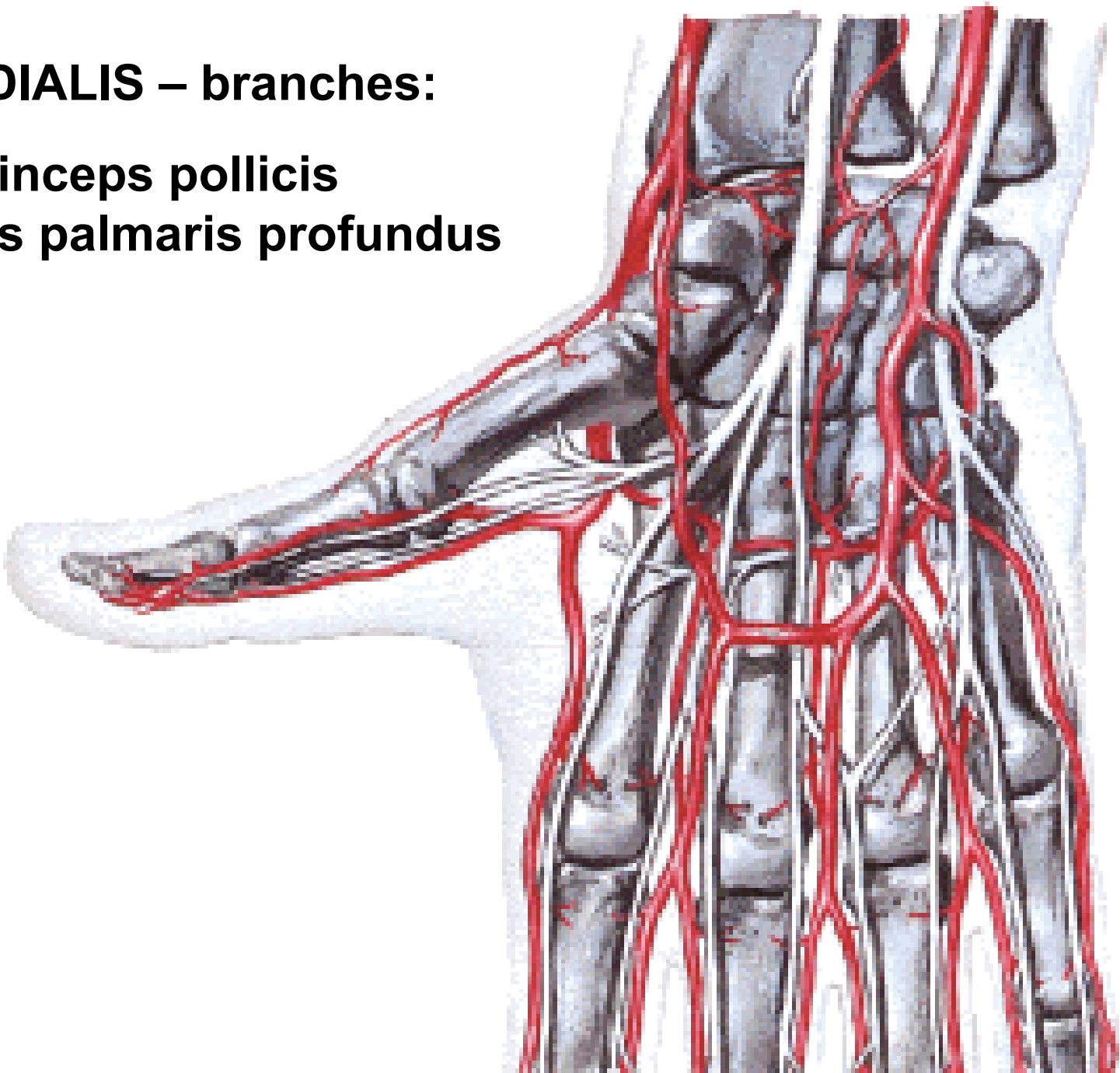
– aa. digitales dorsales)

- a. metacarpalis dorsalis I.



A. RADIALIS – branches:

- a. princeps pollicis**
- arcus palmaris profundus**



A. ULNARIS

Anteriorly:

m. pronator teres

m. flexor carpi radialis

m. palmaris longus

m. flexor digitorum spf.

m. flexor carpi ulnaris

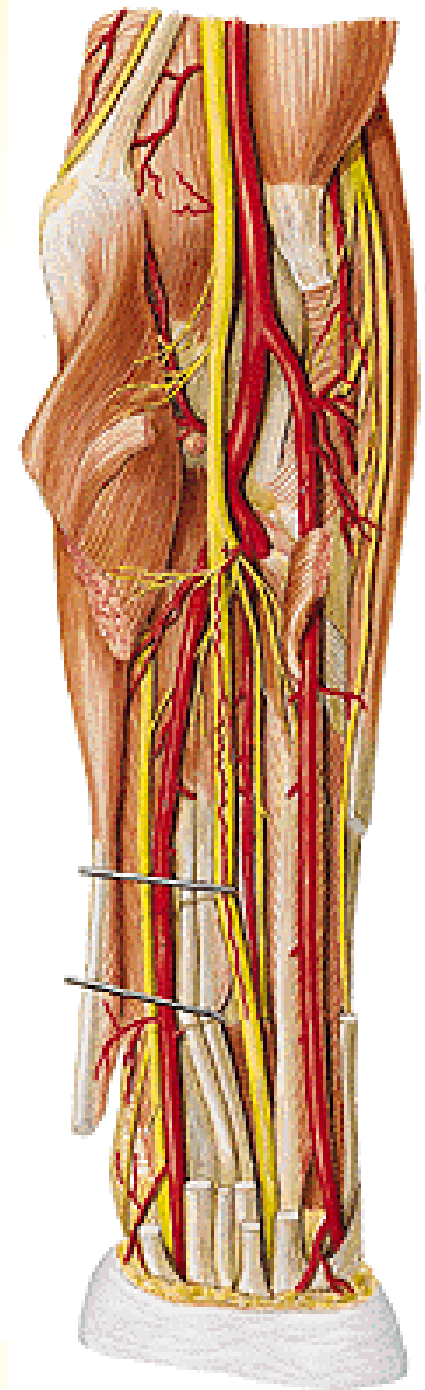
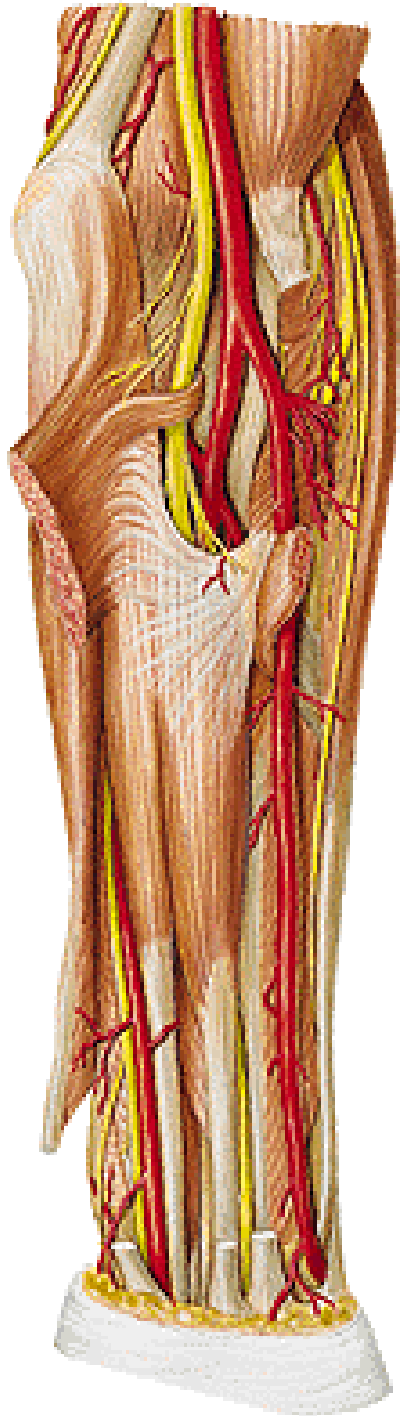
Posteriorly:

m. brachialis

m. flexor digitorum prof.

n. medianus

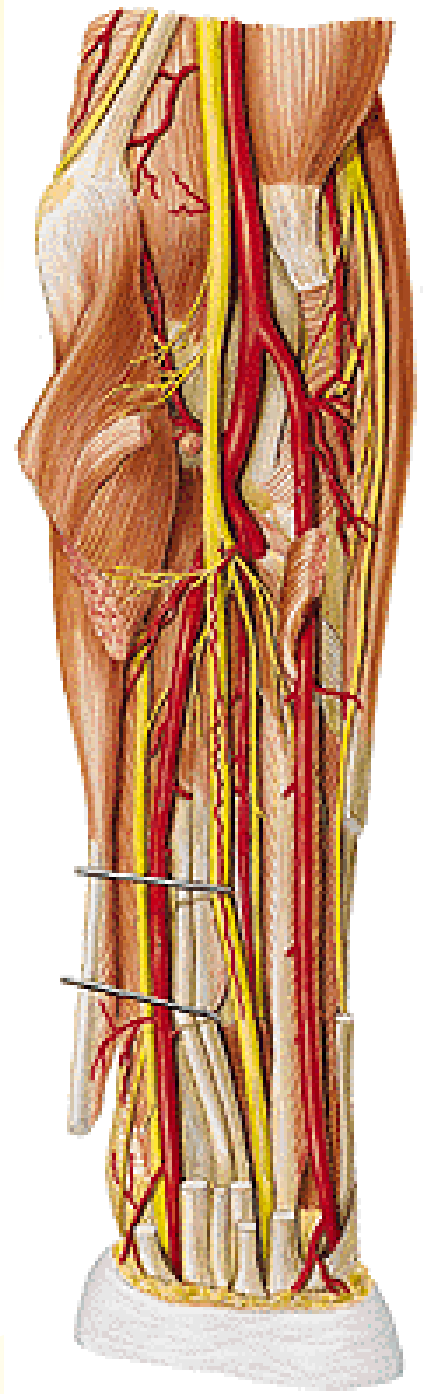
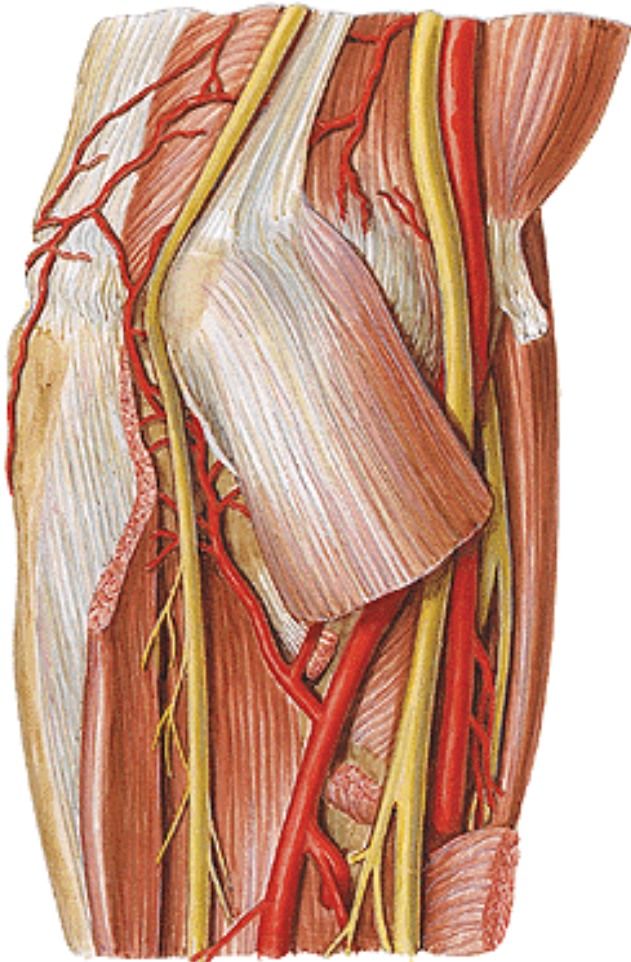
n. ulnaris



A. ULNARIS – branches:

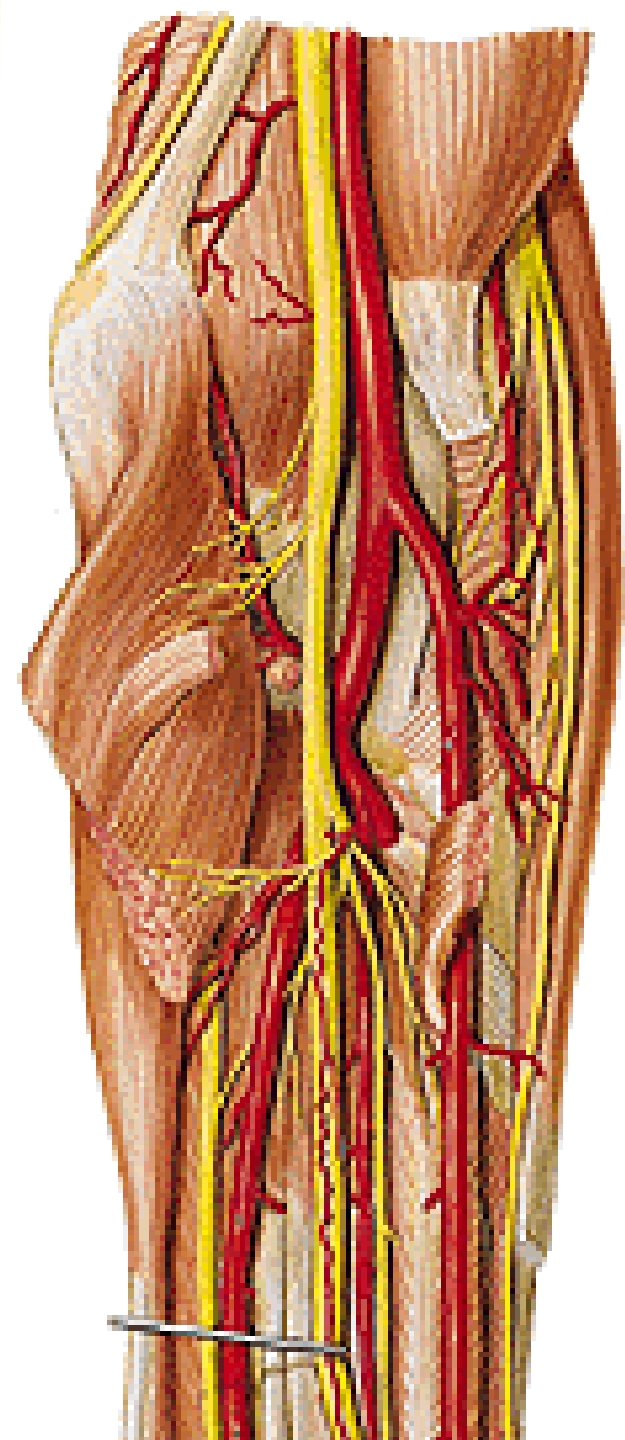
-a. recurrens ulnaris
(rete articulare cubiti)

- rr. musculares



A. ULNARIS – branches:

- **a. interossea communis**
 - **a. interossea ant. (n. interosseus anterior)**
 - **a. mediana (n. medianus)**
 - **a. interossea post.**



A. ULNARIS – branches:

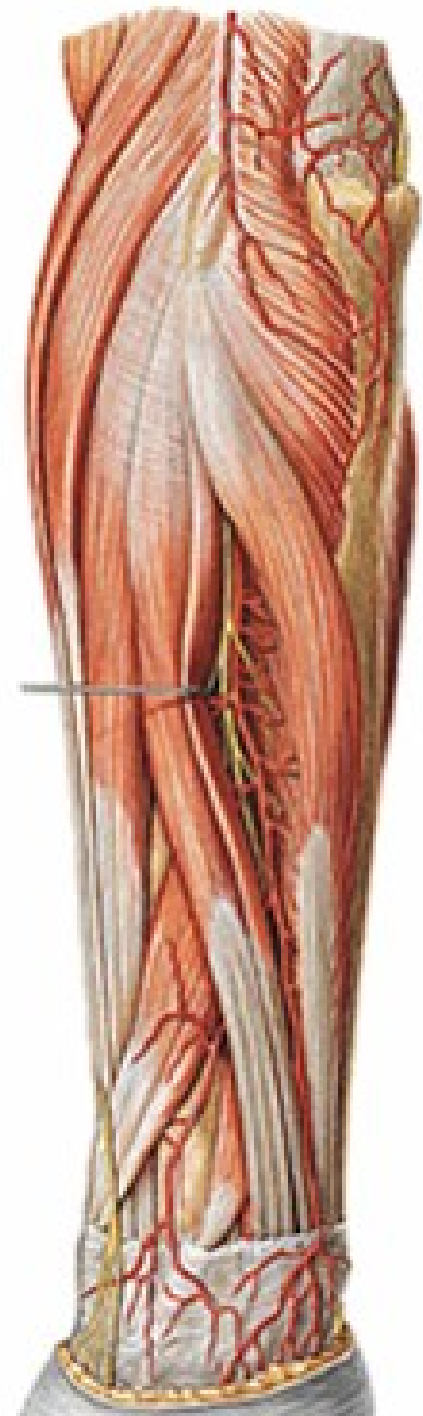
a. interossea post.

- a. recurrens interossea

m. supinator

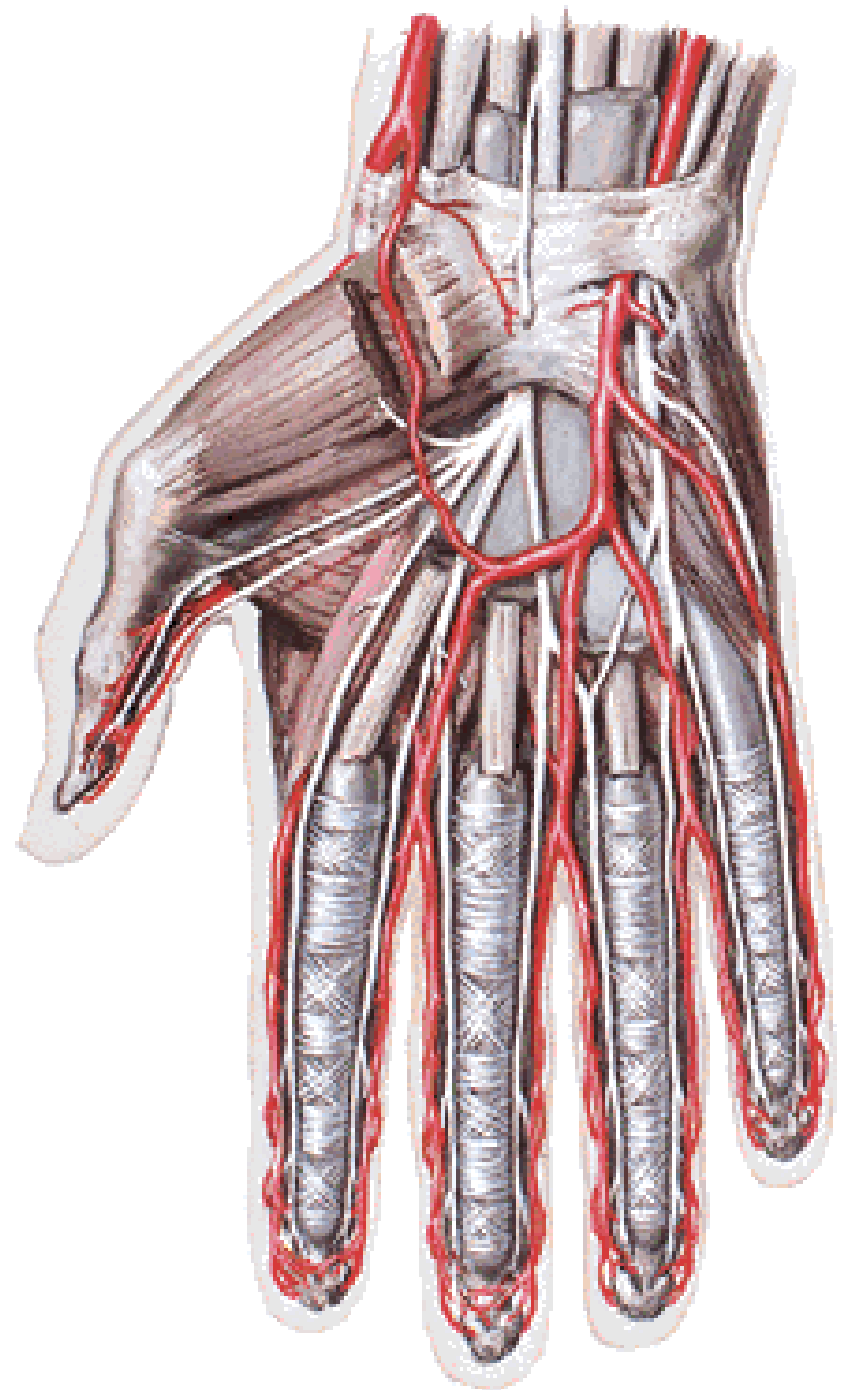
m. abductor pollicis longus

r. profundus n. radialis



A. ULNARIS

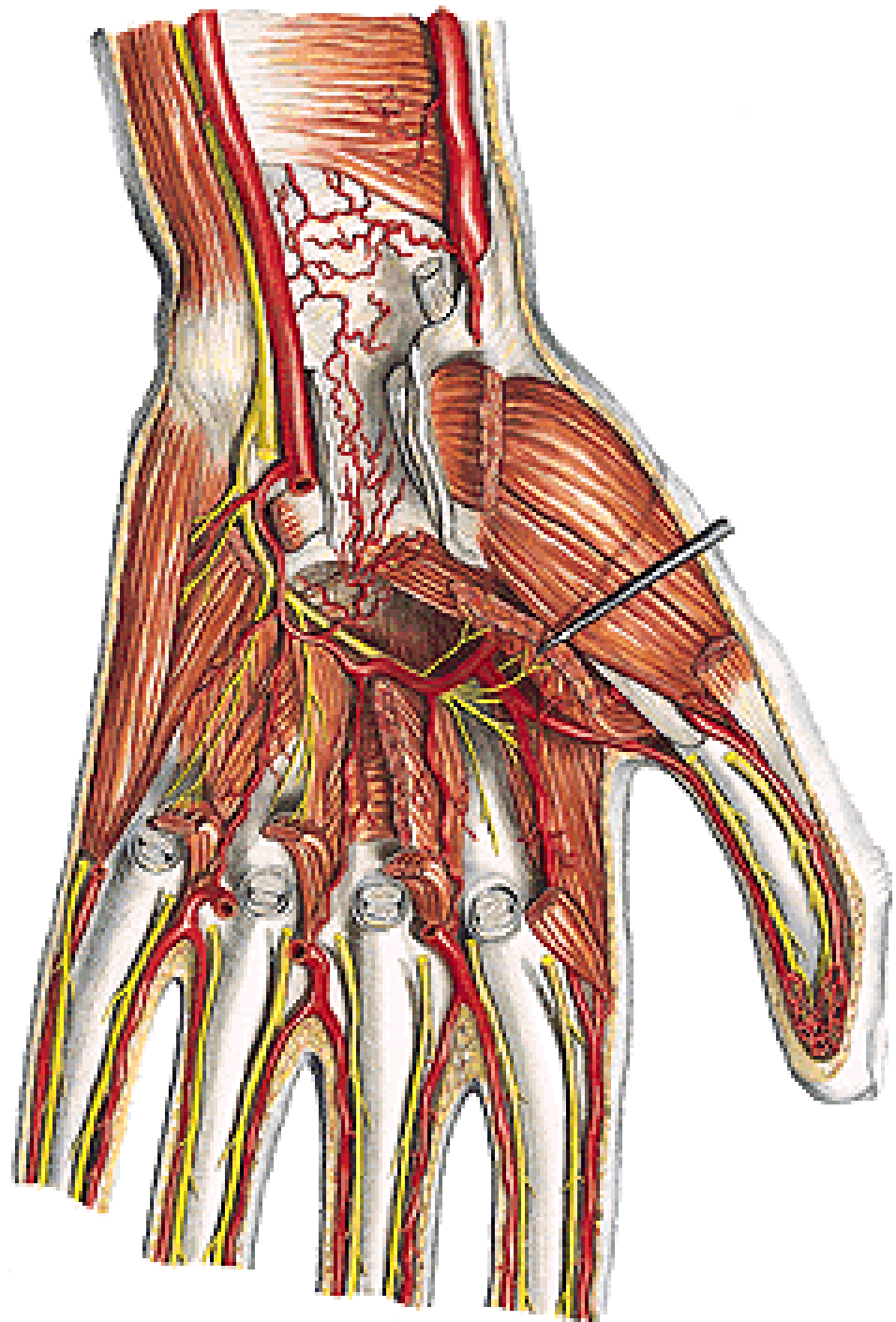
retinaculum flexorum



A. ULNARIS – branches:

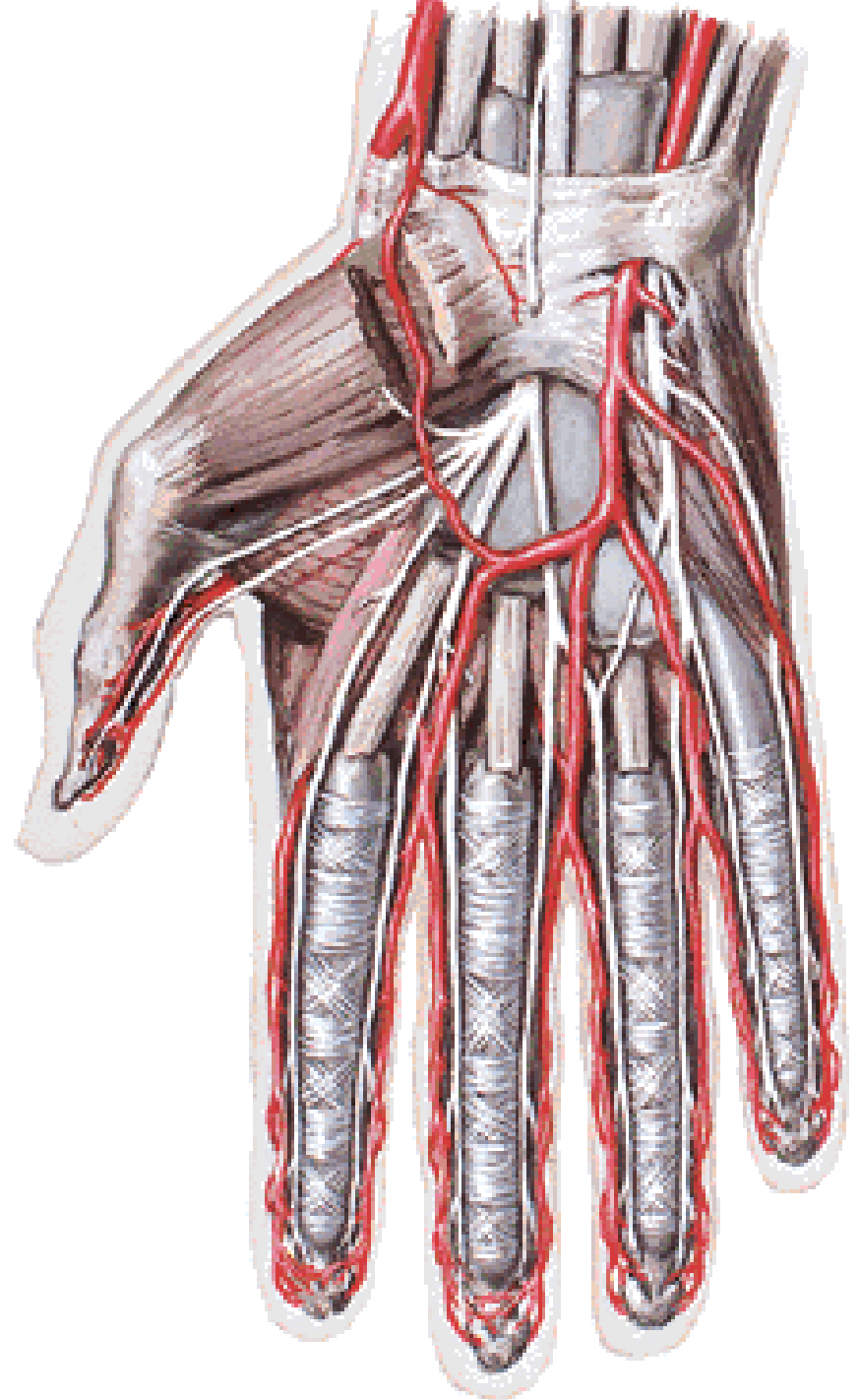
- r. carpalis palmaris
(rete carpi palmare)**
- r. carpalis dorsalis
(rete carpi dorsale)**
- r. palmaris prof.**

- m. abductor digiti minimi**
- m. flexor digiti minimi**
- m. opponens digiti minimi**



A. ULNARIS – branches:

- arcus palmaris spf.

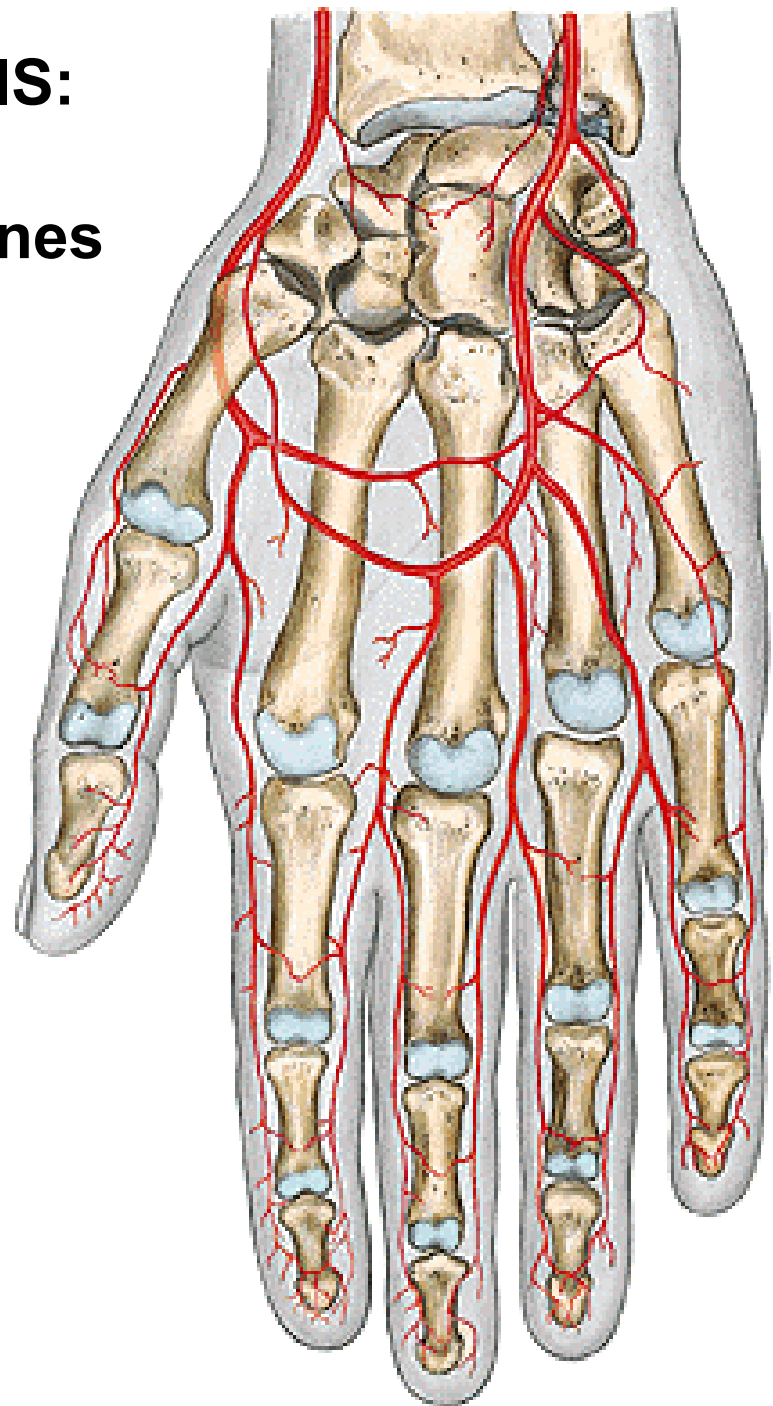


ARCUS PALMARIS SUPERFICIALIS:

- 3 aa. digitales palmares communes
 - 2 aa. dig. palmares propriae
 - a. palmaris digiti quinti ulnaris

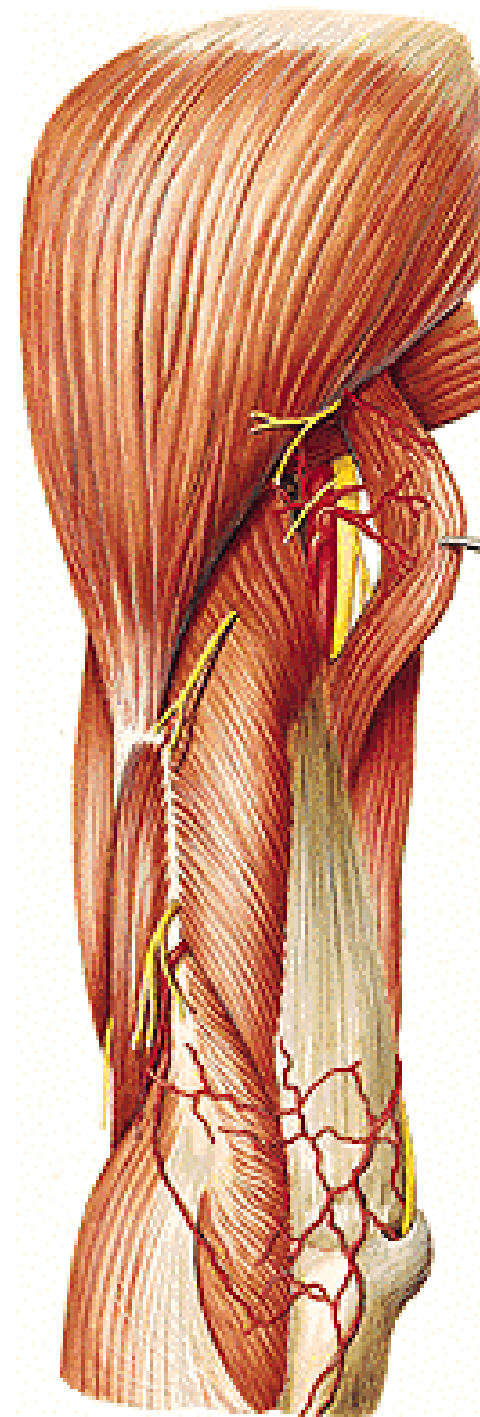
ARCUS PALMARIS PROFUNDUS:

- aa. metacarpales palmares
- rr. perforantes



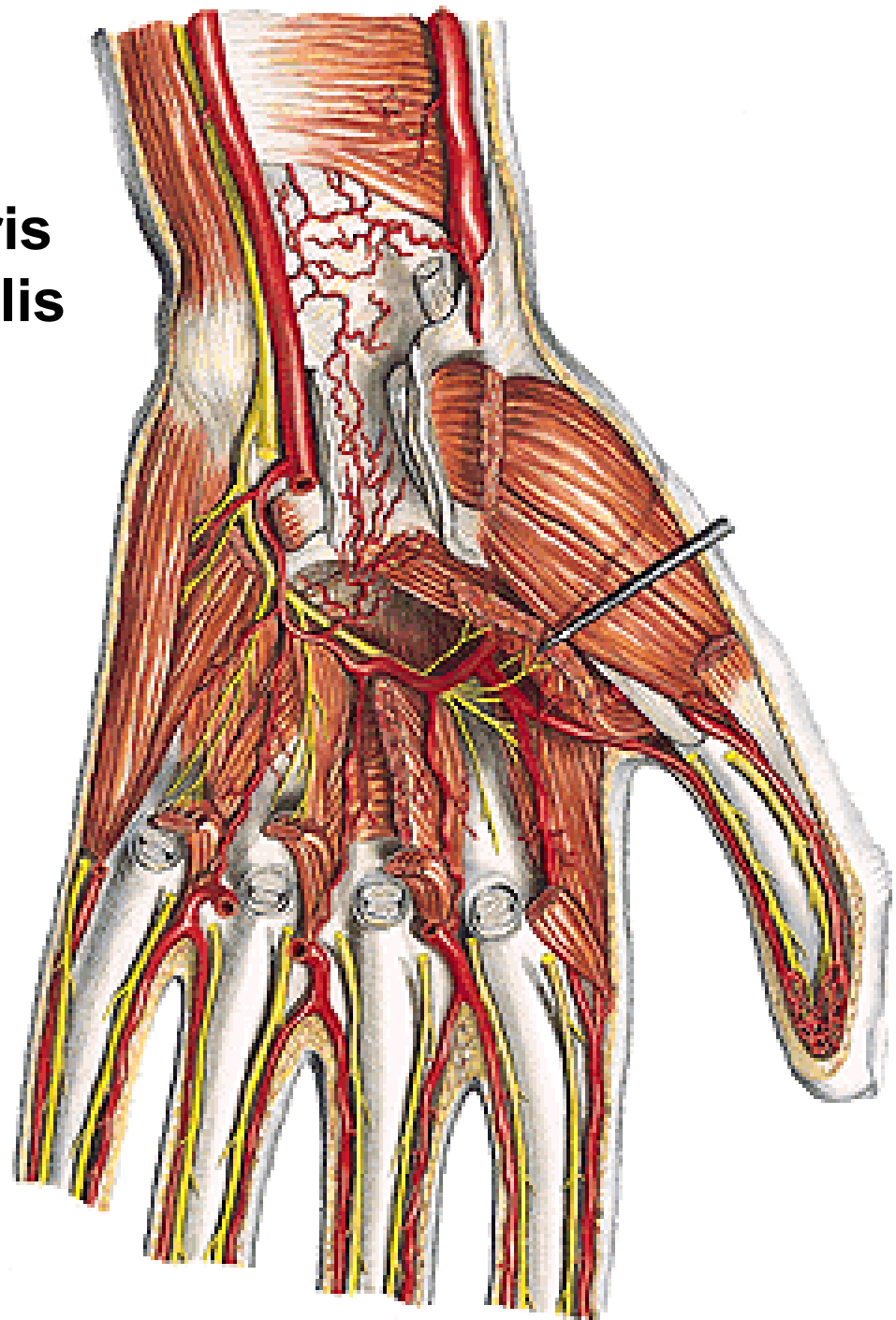
RETE ARTICULARE CUBITI:

- a. collateralis media et rad. (a. prof. brachii)
- a. collateralis ulnaris sup. (a. brachialis)
- a. collateralis ulnaris inf. (a. brachialis)
- a. recurrens radialis (a. radialis)
- a. recurrens interossea (a. interossea post.)
- a. recurrens ulnaris (a. ulnaris)



RETE CARPI PALMARE:

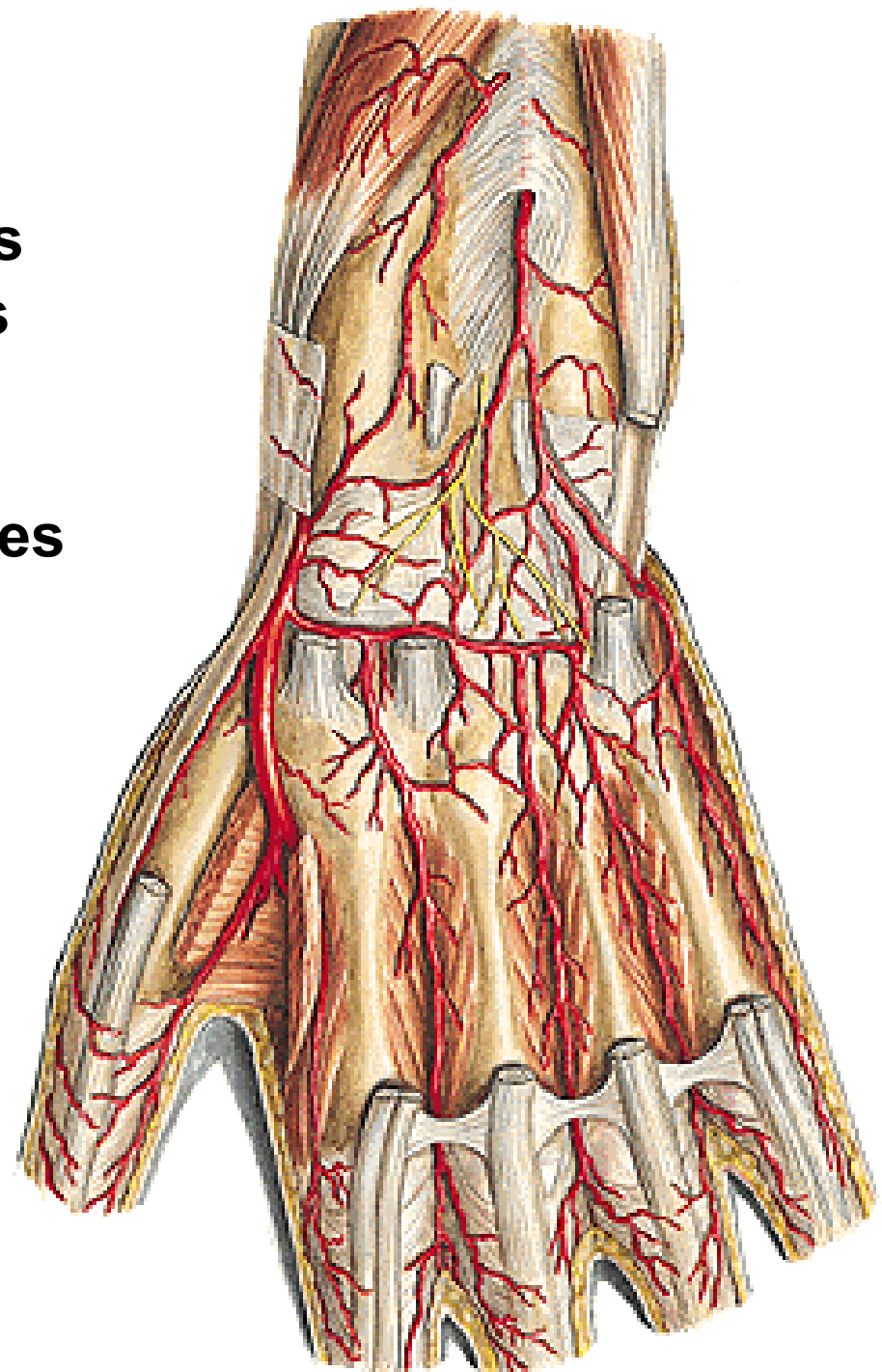
- r. carpalis palmaris a. ulnaris
- r. carpalis palmaris a. radialis
- a. interossea ant.
- arcus palmaris prof.



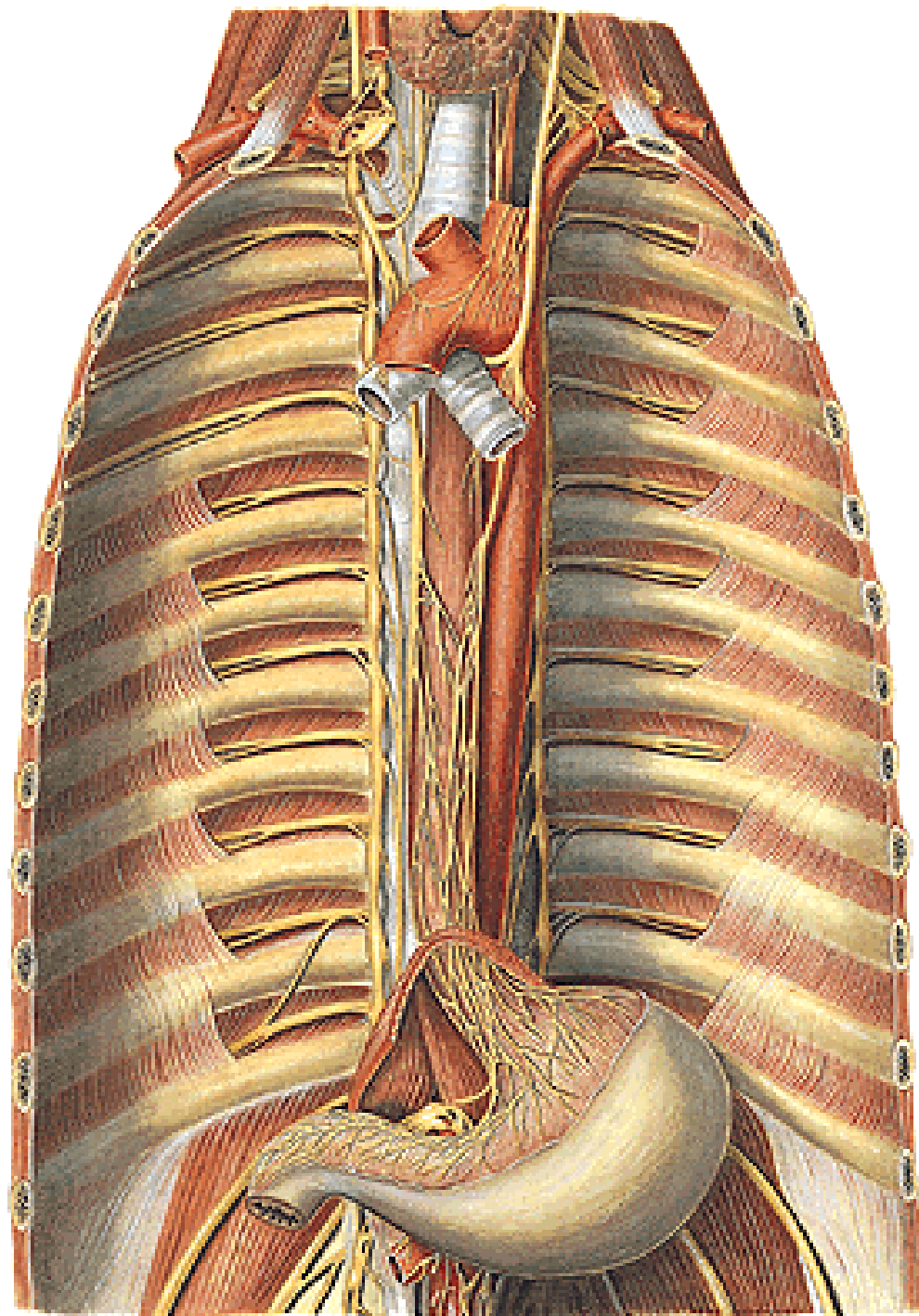
RETE CARPI DORSALE:

- r. carpalis dorsalis a. radialis
- r. carpalis dorsalis a. ulnaris
- a. interossea ant. et post.

→ 3 aa. metacarpales dorsales
2 aa. digitales dorsales



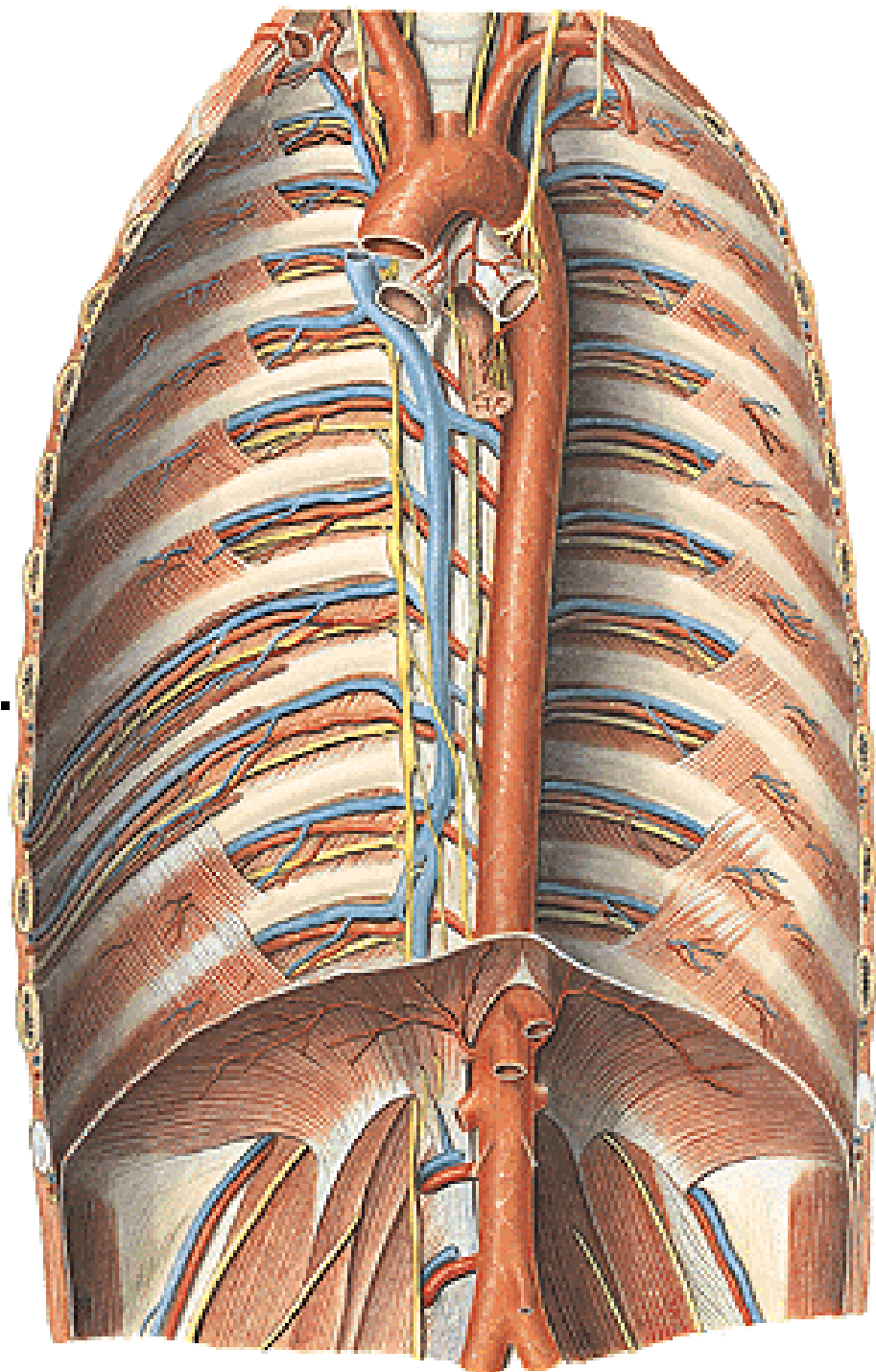
AORTA THORACICA



AORTA THORACICA

Parietal branches:

- aa. intercostales post. (9)
 - r. dorsalis
 - rr. musculares
 - r. spinalis
 - rr. cutanei med. et lat.
 - rr. musculares
 - r. collateralis
 - r. cutaneus lat.
 - rr. mammarii lat.
- a. subcostalis
- a. phrenica sup.

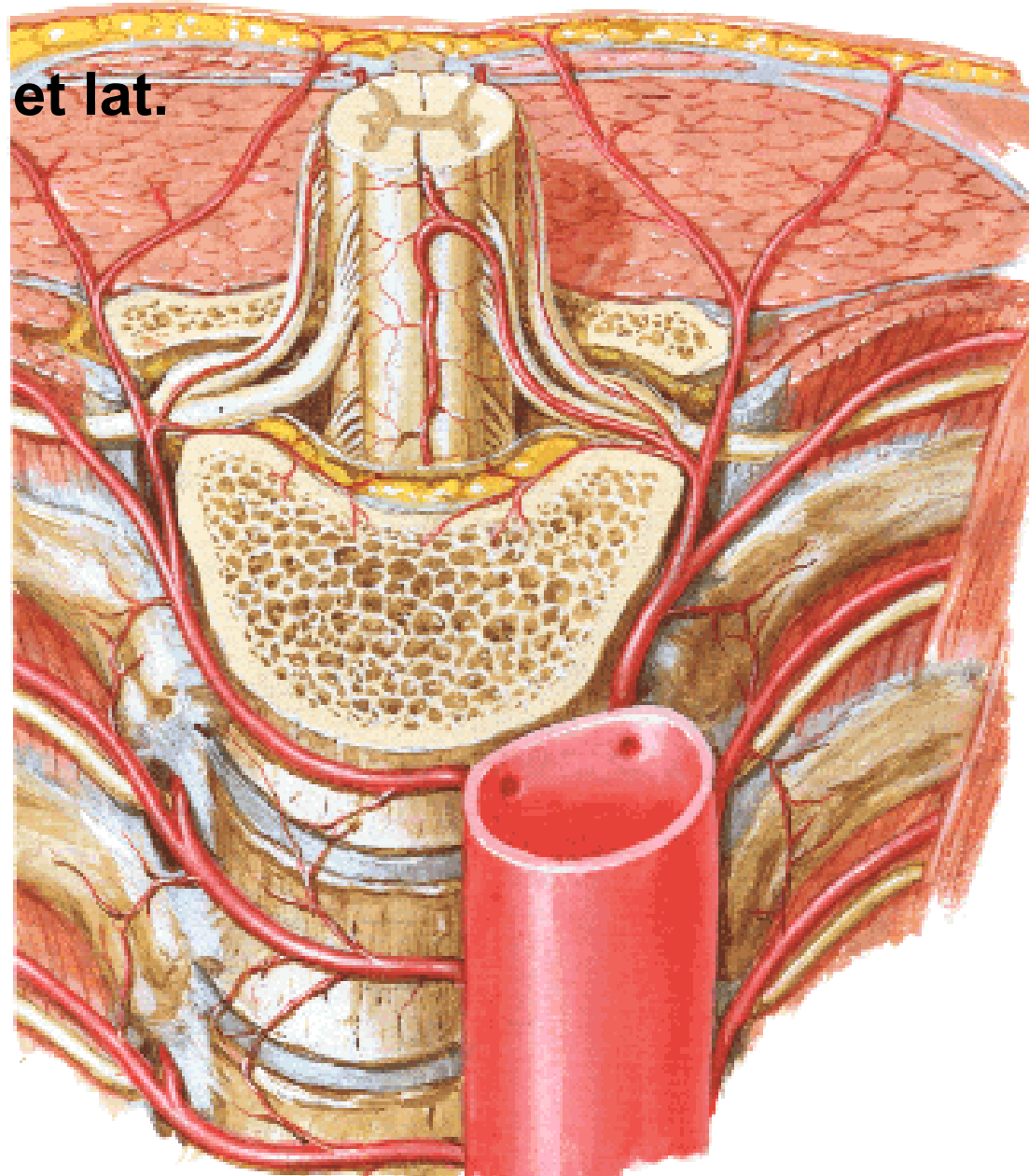


- r. dorsalis

- rr. musculares

- r. spinalis

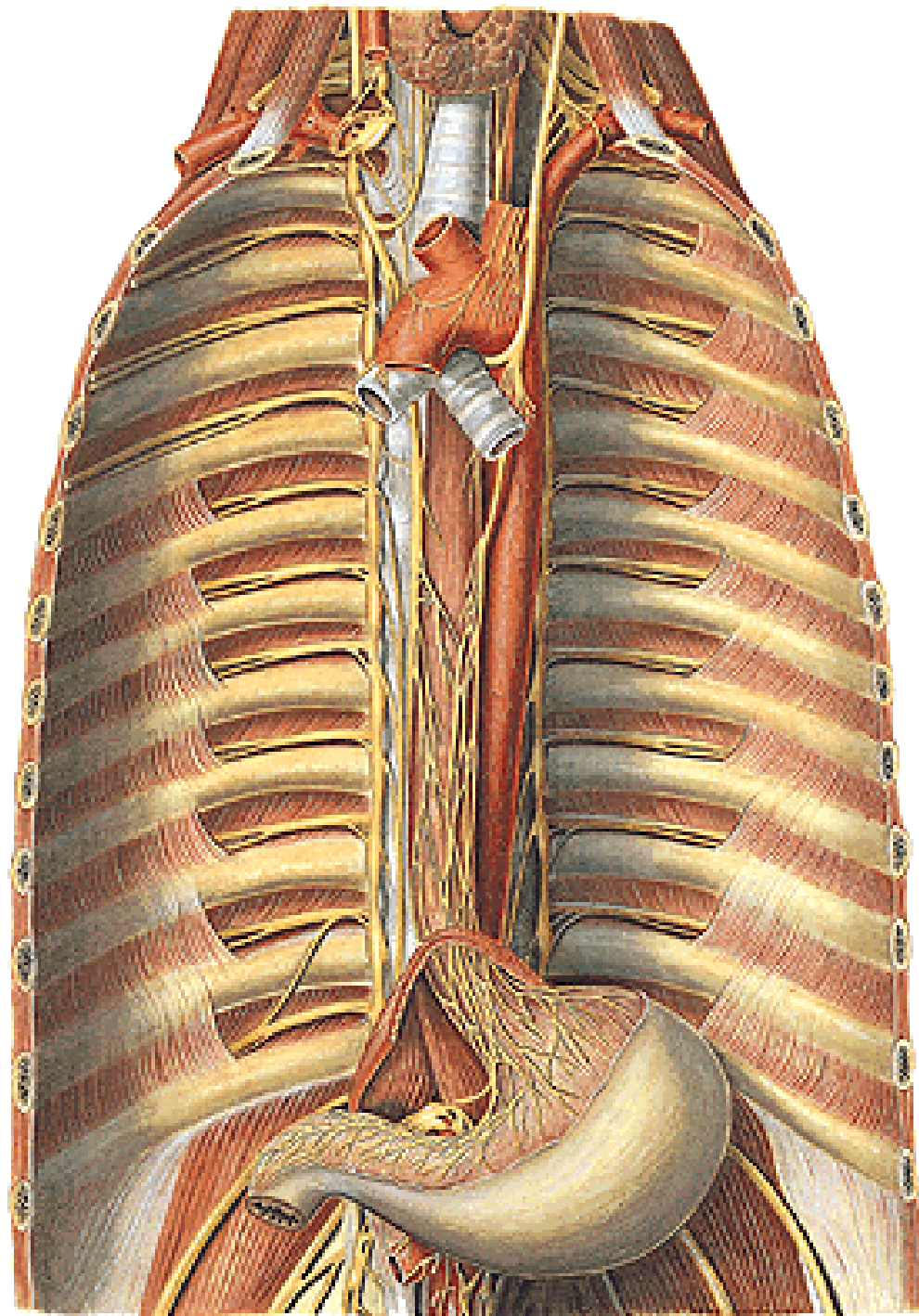
- rr. cutanei med. et lat.



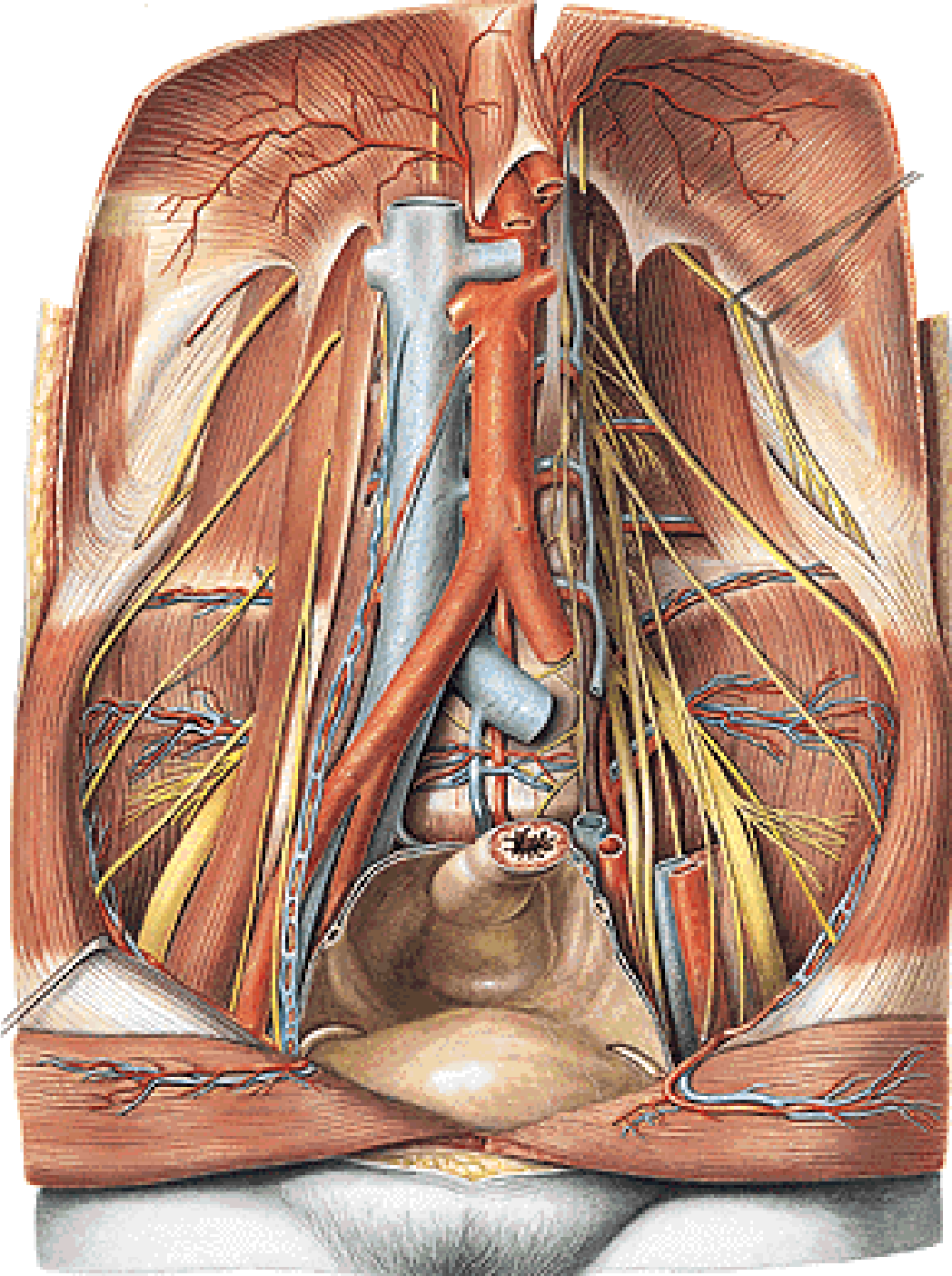
AORTA THORACICA

Visceral branches:

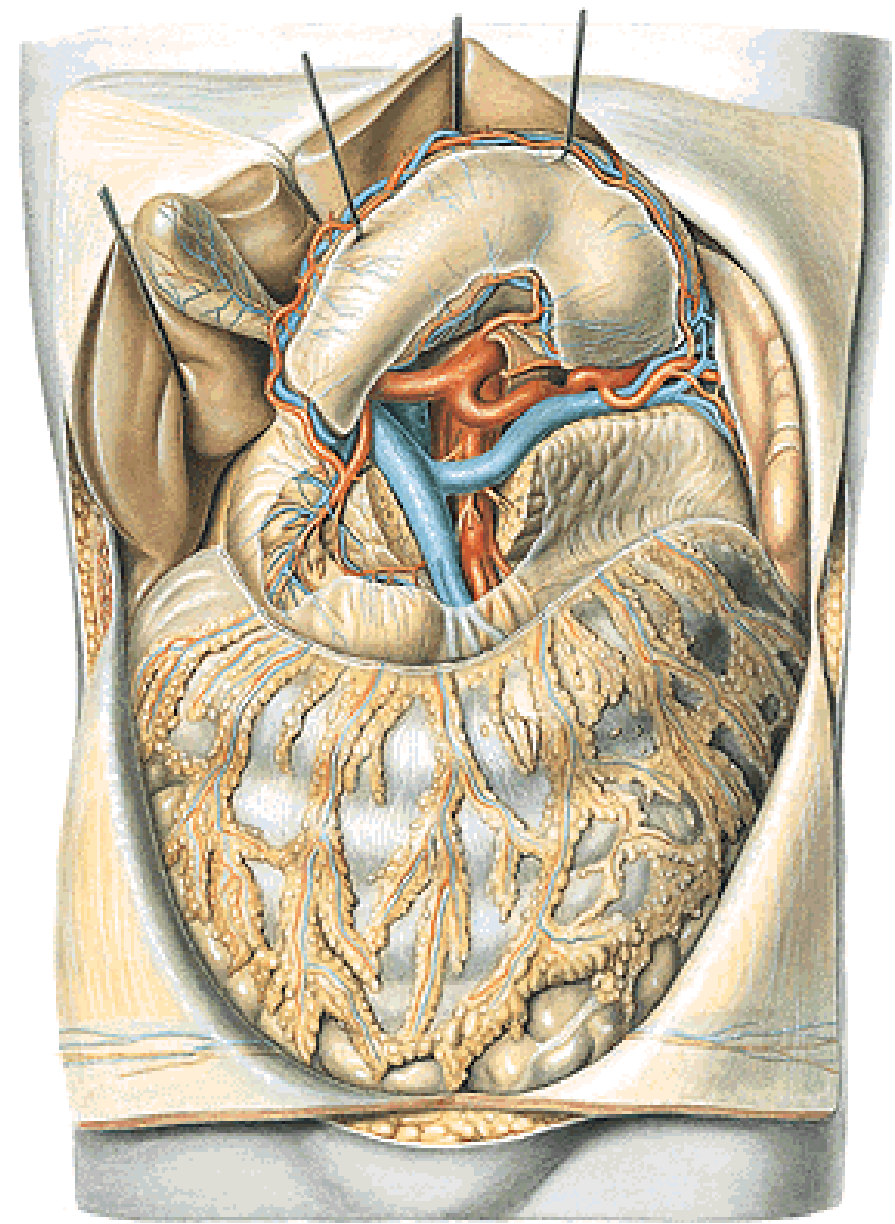
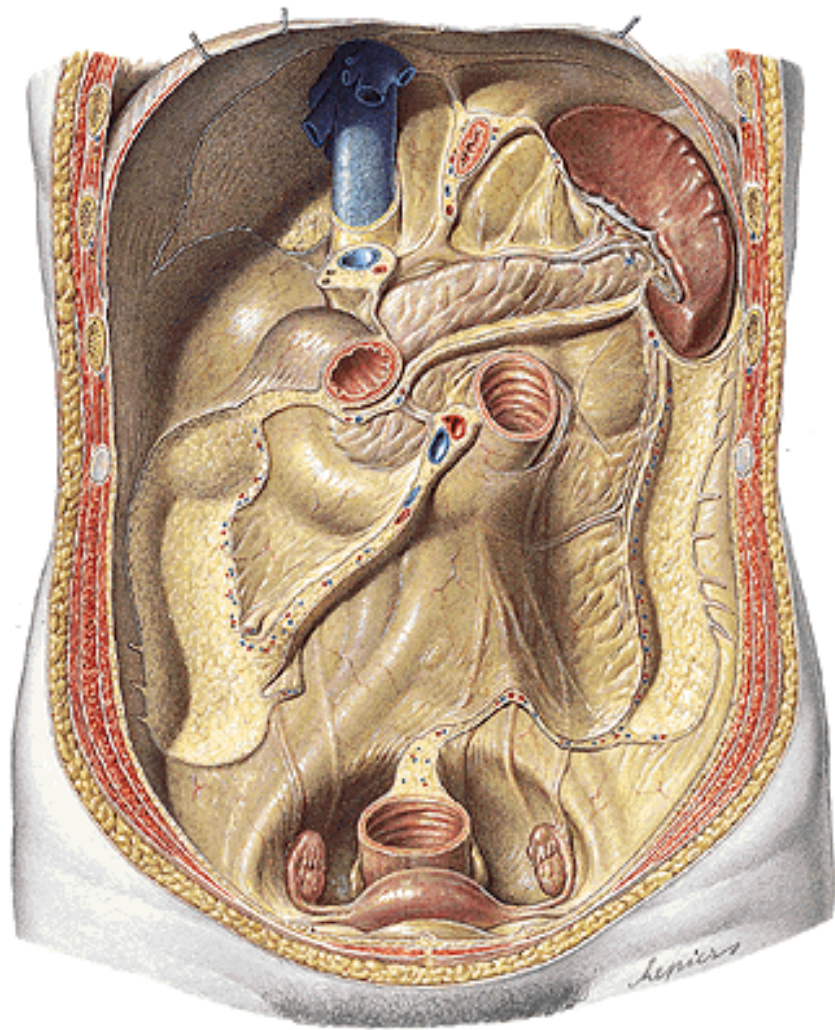
- rr. bronchiales
- rr. oesophagei
- rr. pericardiaci



AORTA ABDOMINALIS



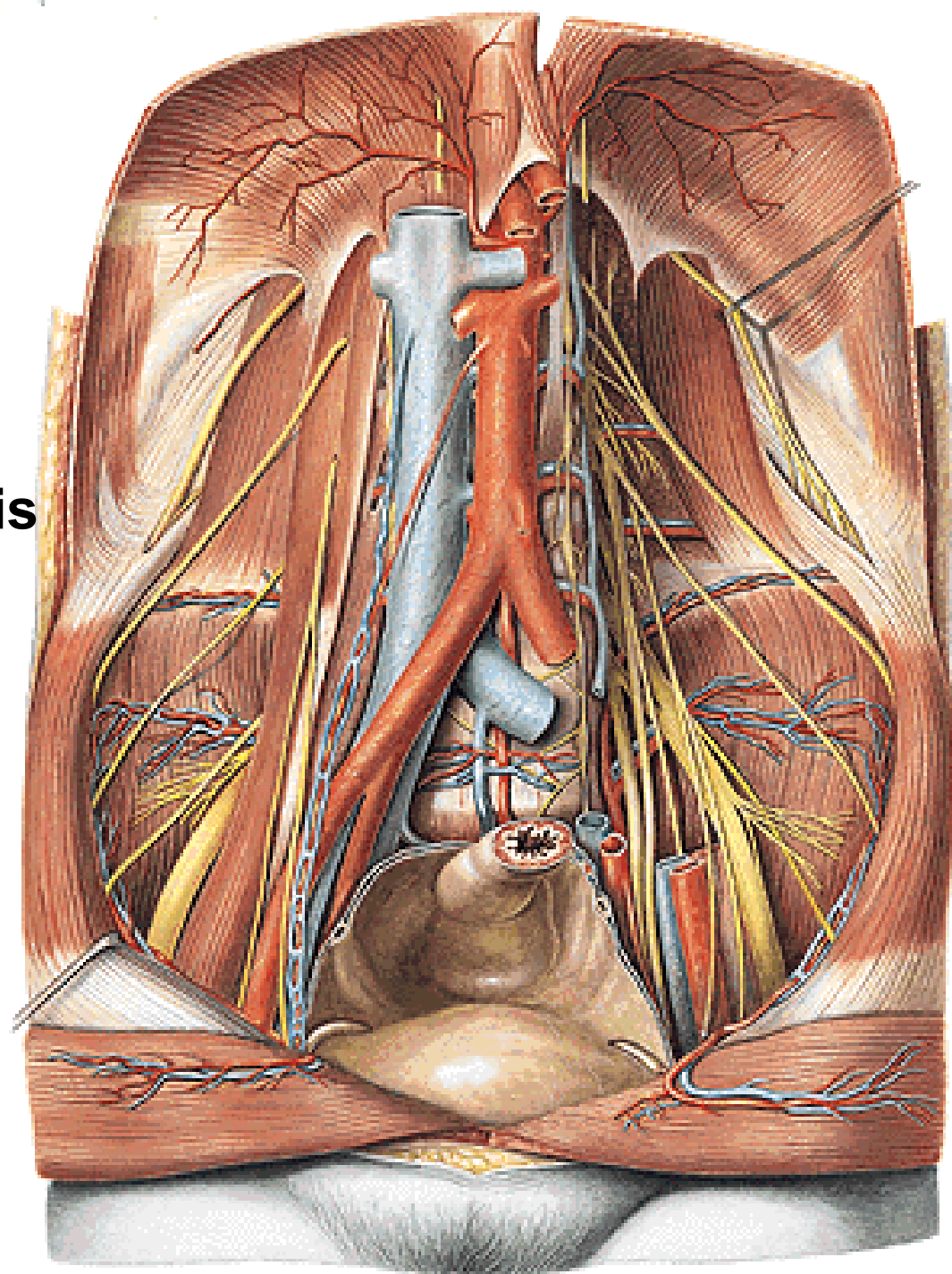
AORTA ABDOMINALIS



AORTA ABDOMINALIS

Parietal branches

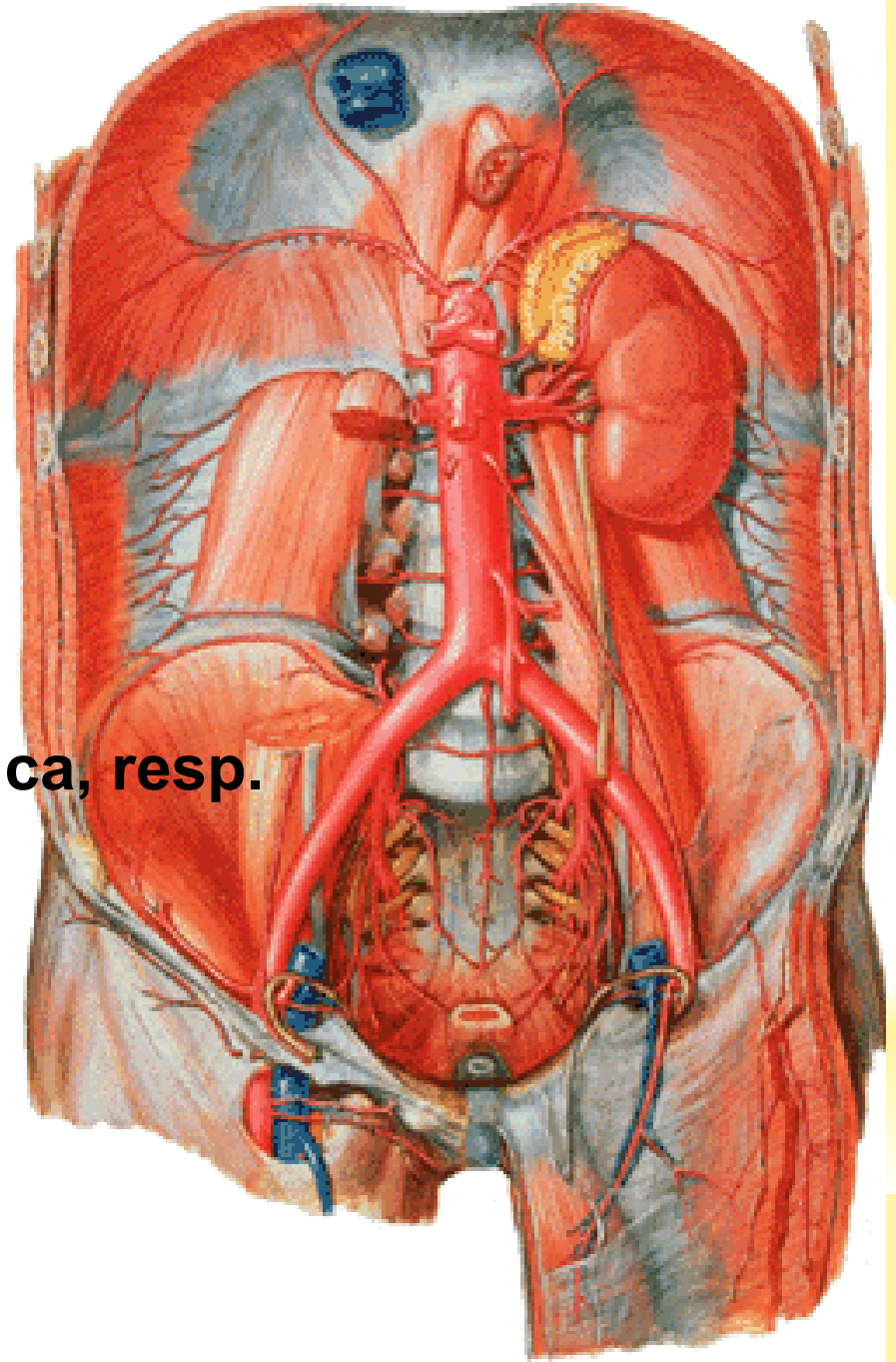
- a. phrenica inf.
- a. suprarenalis sup.
- aa. lumbales (4)
- r. dorsalis – r. spinalis



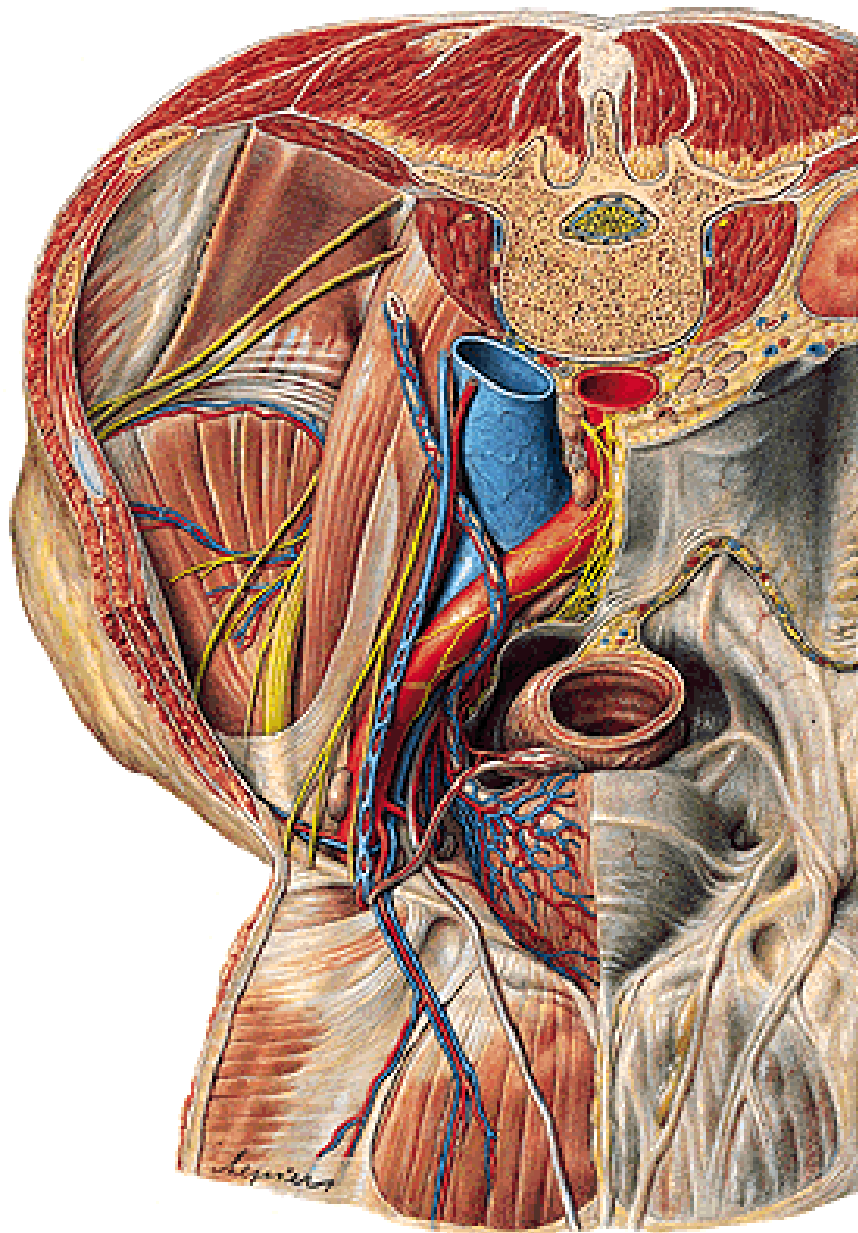
AORTA ABDOMINALIS

Visceral branches - paired

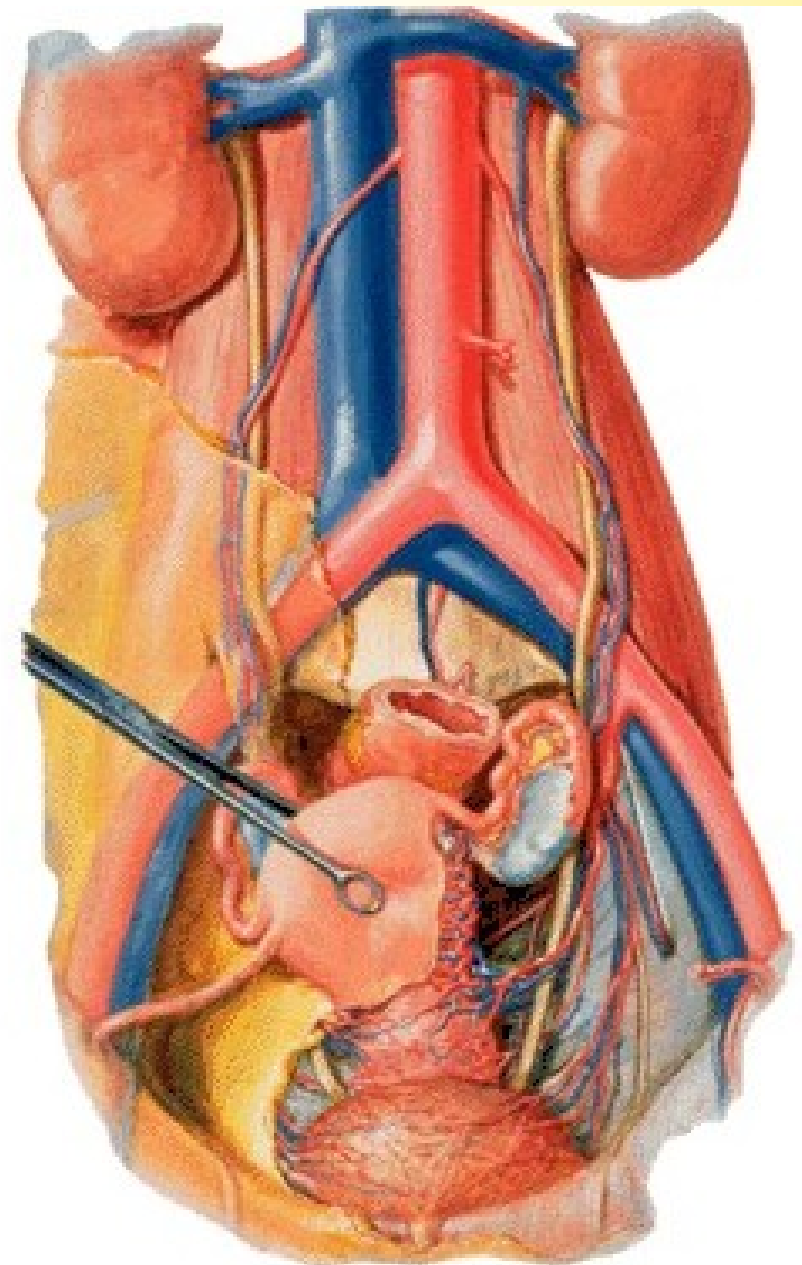
- a. suprarenalis media
- a. renalis
 - r. uretericus
 - a. suprarenalis inf.
 - rr. praepelvici
 - r. retropelvicus
- a. testicularis and a. ovarica, resp.
 - rr. ureterici
 - r. tubarius



A. testicularis



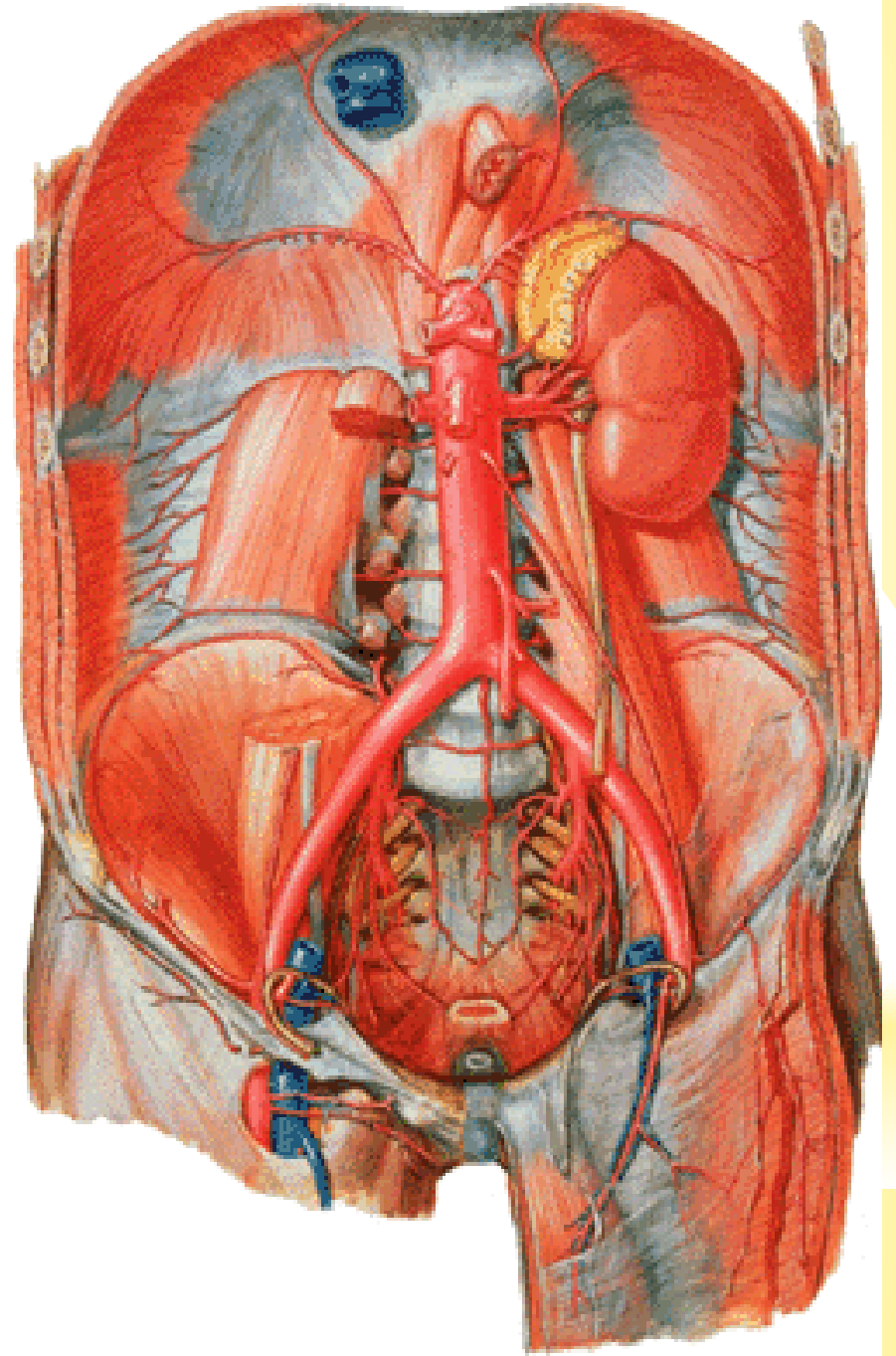
A. ovarica



AORTA ABDOMINALIS – cont.

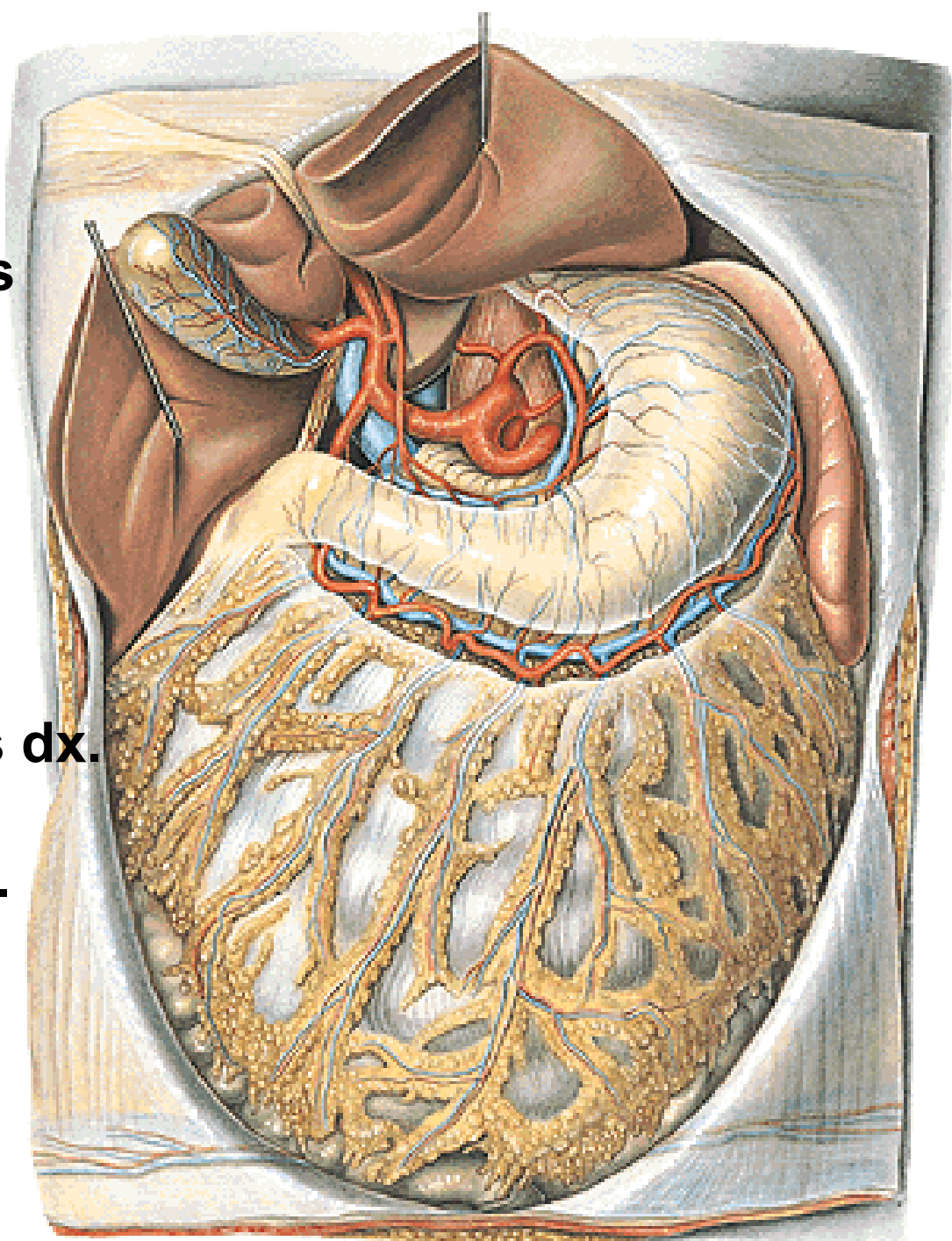
Visceral branches – unpaired

- truncus coeliacus
- a. mesenterica sup.
- a. mesenterica inf.



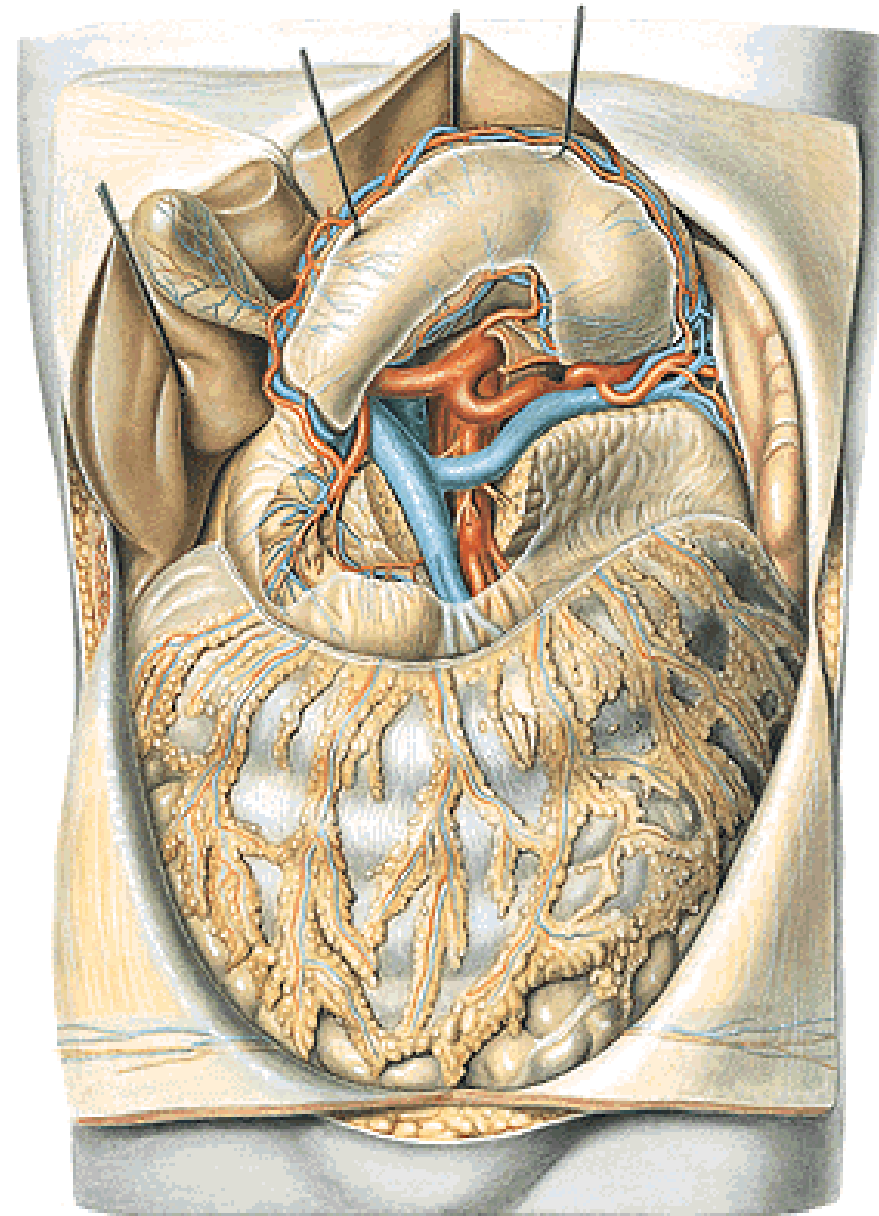
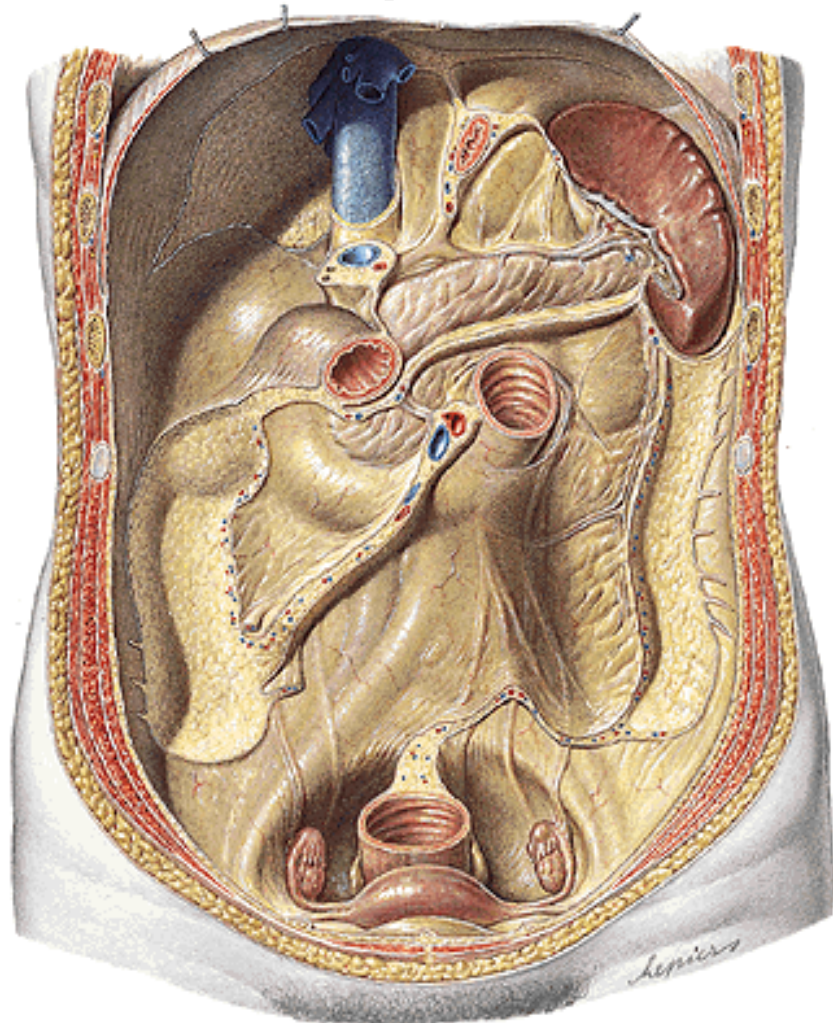
TRUNCUS COELIACUS

1. a. gastrica sin.
 - rr. oesophageales
2. a. hepatica communis
 - a. hepatica propria
 - a. gastrica dx.
 - r. dexter
 - a. cystica
 - r. sinister
 - a. gastroduodenalis
 - a. gastromentalis dx.
 - aa. pancreatico-duodenales sup.
3. a. splenica



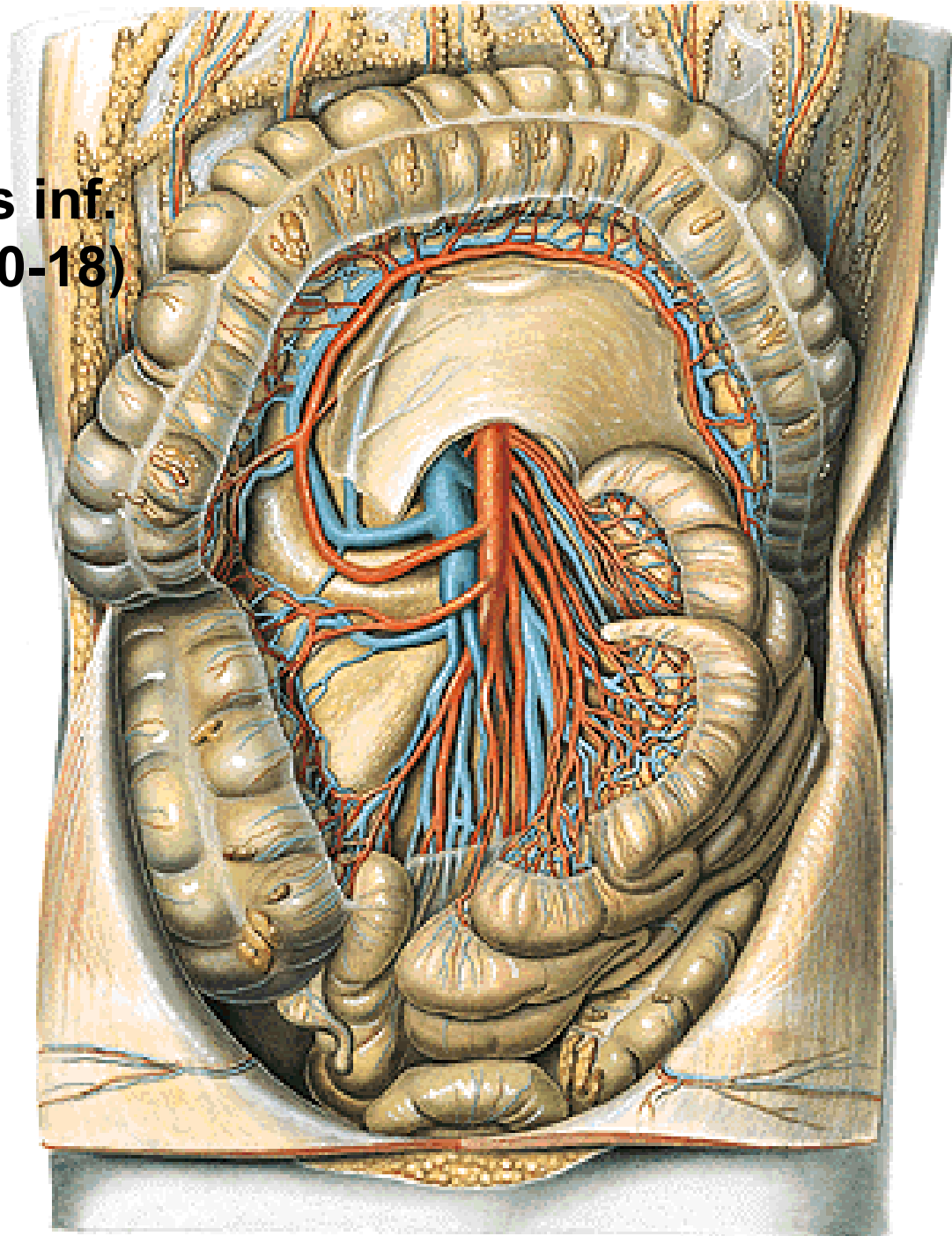
A. SPLENICA/LIENALIS

- rr. pancreatici
- a. gastromentalis sin.
- aa. gastricae breves
- rr. splenici



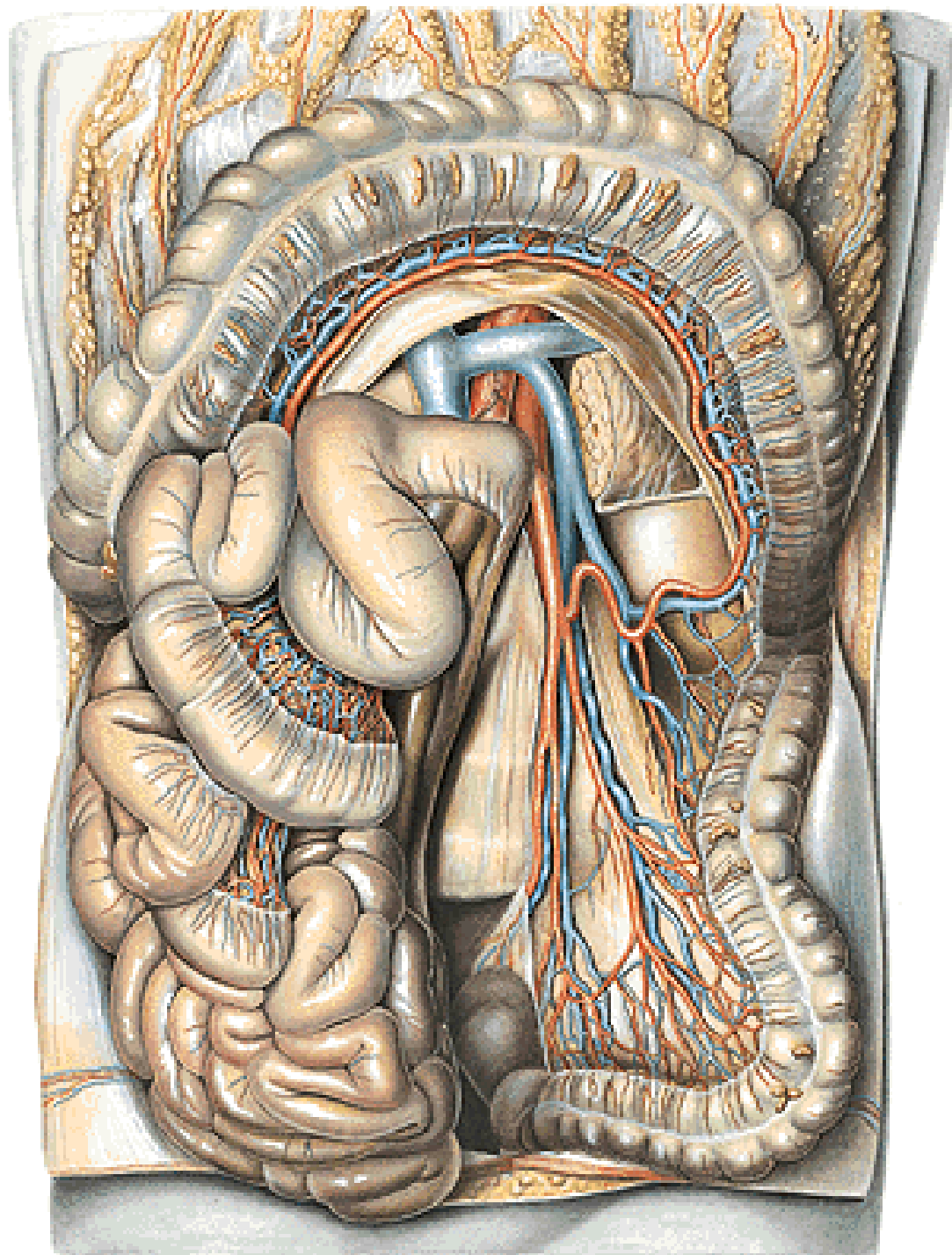
A. MESENTERICA SUP.

- a. pancreaticoduodenalis inf.
- aa. jejunales et ileales (10-18)
- a. ileocolica
 - r. ilealis
 - r. colicus
 - r. appendicularis
- a. colica dx.
- a. colica media



A. MESENTERICA INF.

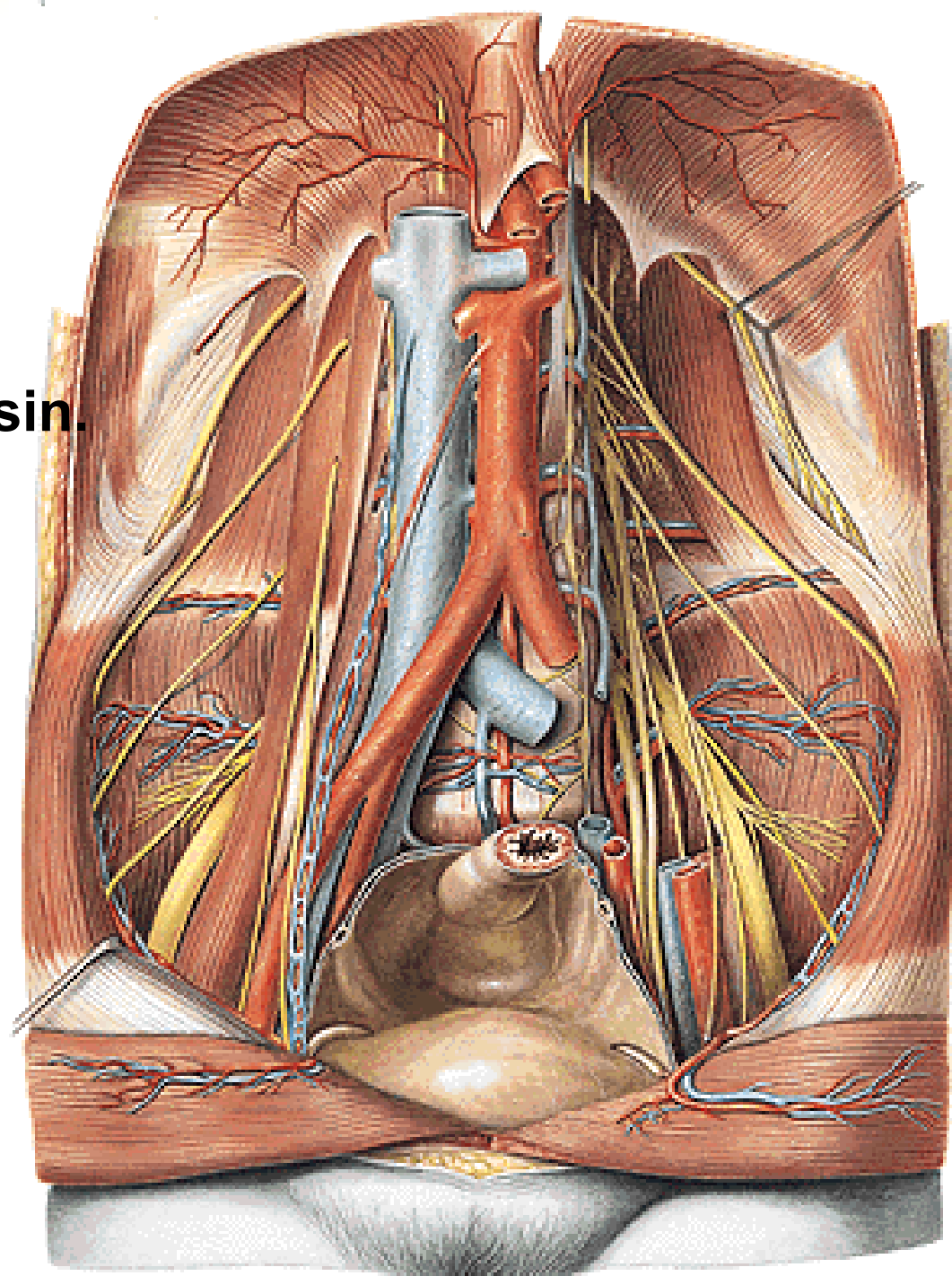
- a. colica sinistra
- aa. sigmoideae
- a. rectalis sup.



AORTA ABDOMINALIS

Terminal branches (bifurcatio aortae)

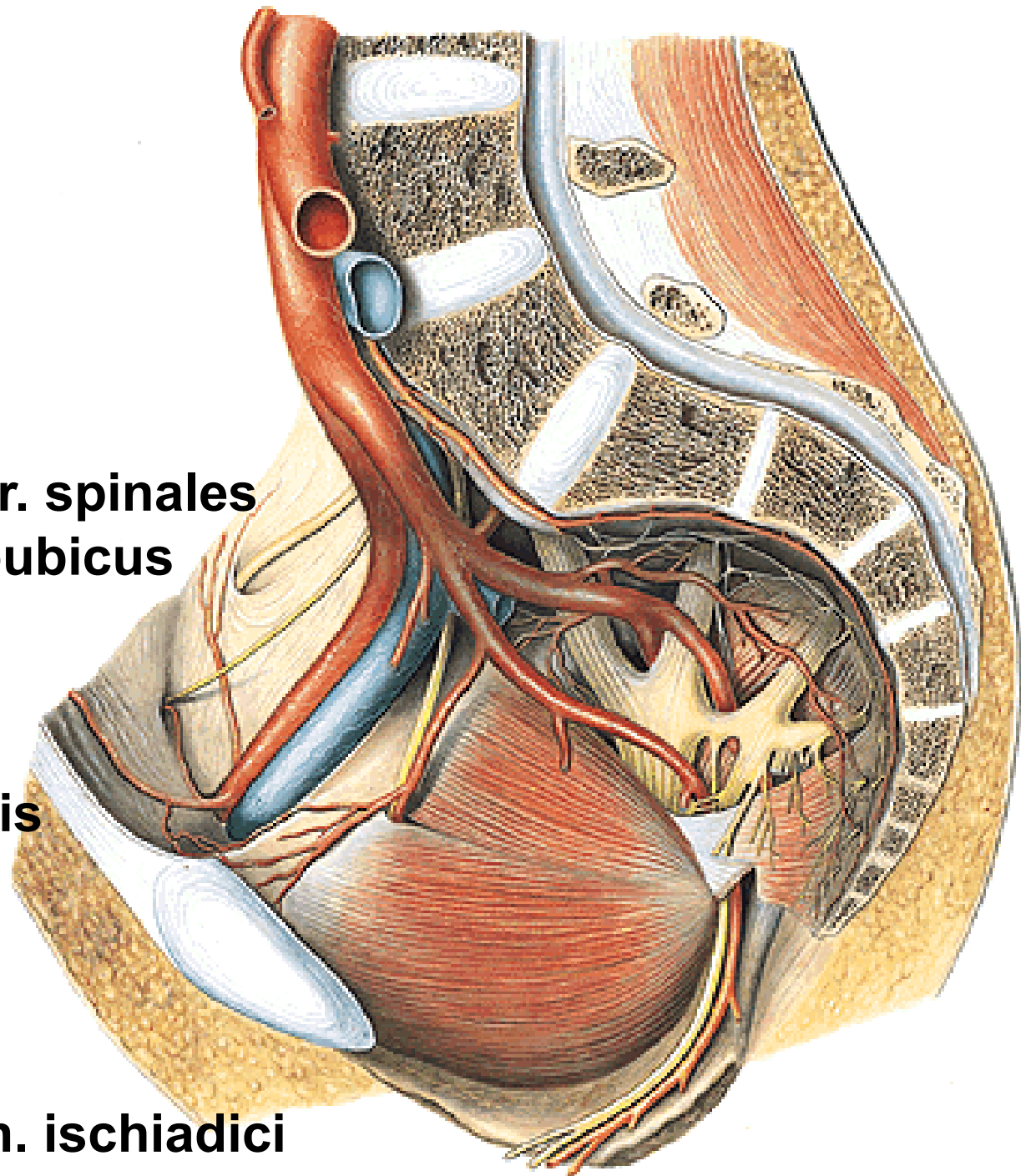
- a. iliaca communis dx. et sin.
 - a. iliaca externa
 - a. iliaca interna
 - a. sacralis mediana
 - a. lumbalis ima
 - rr. sacrales
- (glomus coccygeum)



A. ILIACA INTERNA

Parietal branches

- a. iliolumbalis
 - r. iliacus
 - r. lumbalis
 - r. sacralis
- aa. sacrales lat. – rr. spinales
- a. obturatoria – r. pubicus (corona mortis)
 - r. anterior
 - r. posterior
 - r. acetabularis
- a. glutea sup.
 - r. superficialis
 - r. profundus
- a. glutea inf.
 - a. commitans n. ischiadici



A. ILIACA INTERNA

Parietal branches:

A. iliolumbalis

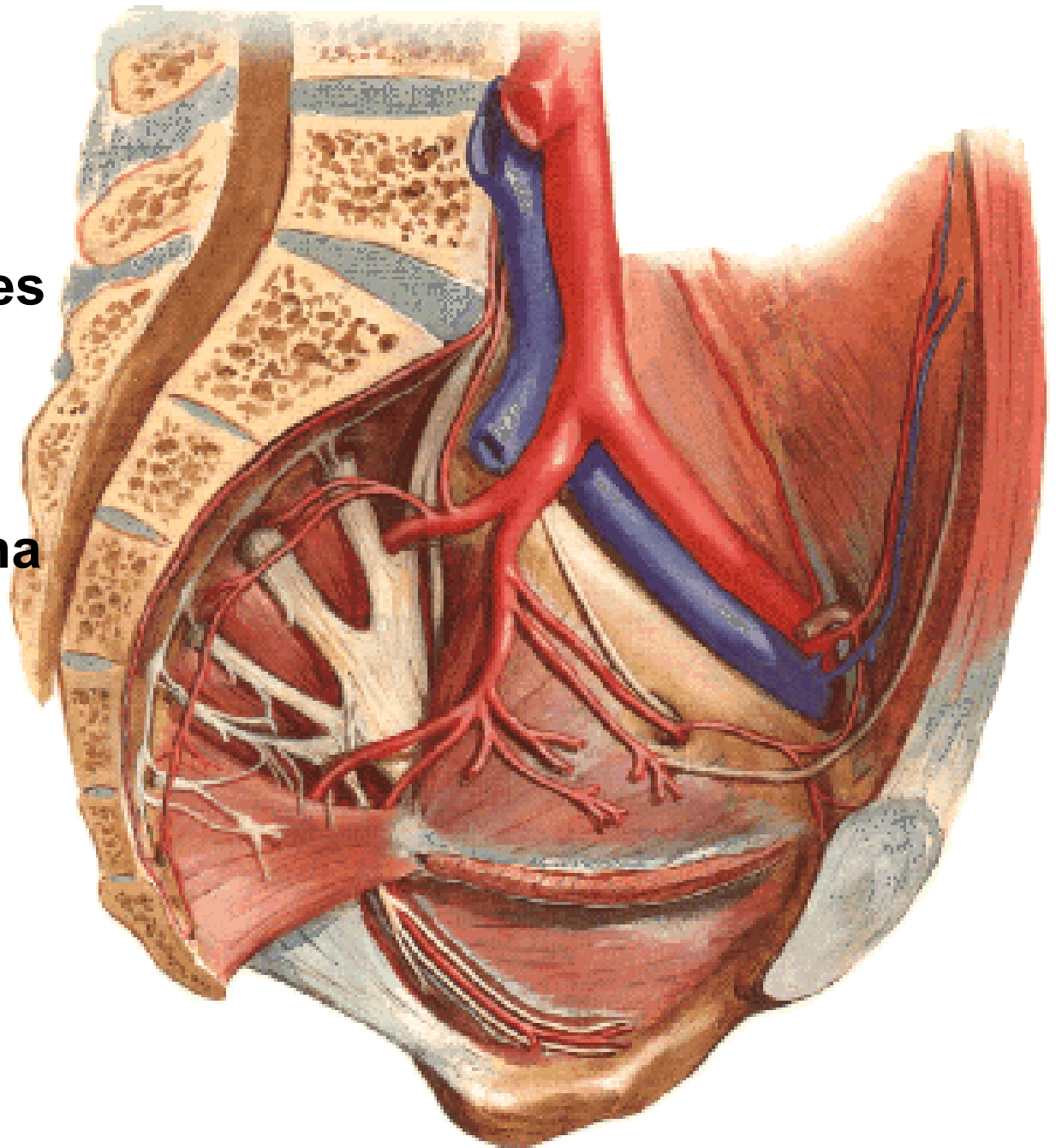
Aa. sacrales laterales

A. glutea sup.

A. glutea inf.

A. obturatoria

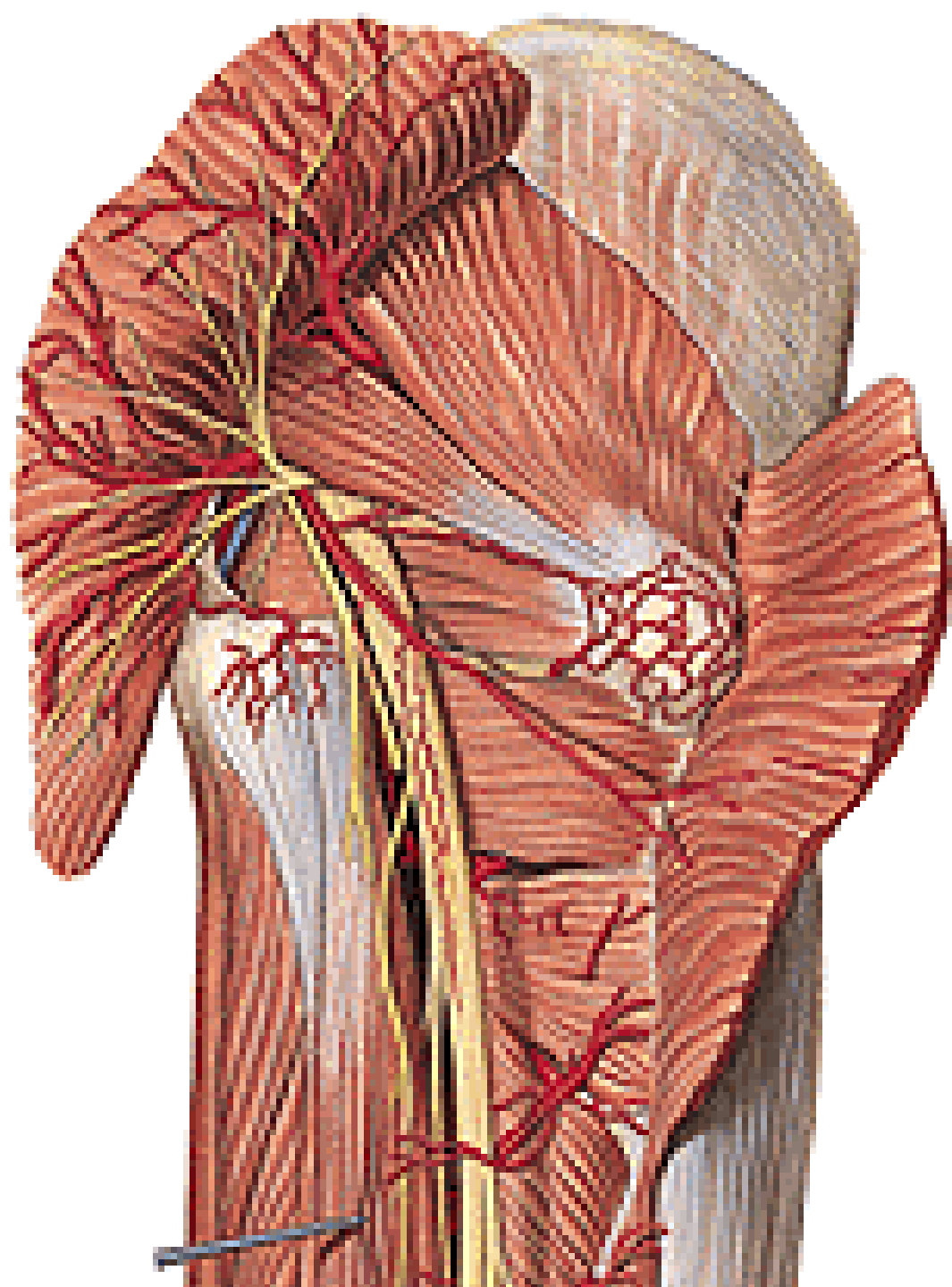
- r. pubicus (corona
mortis)



A. GLUTEA SUP.

A. GLUTEA INF.

- A. comitans n. ischiadici

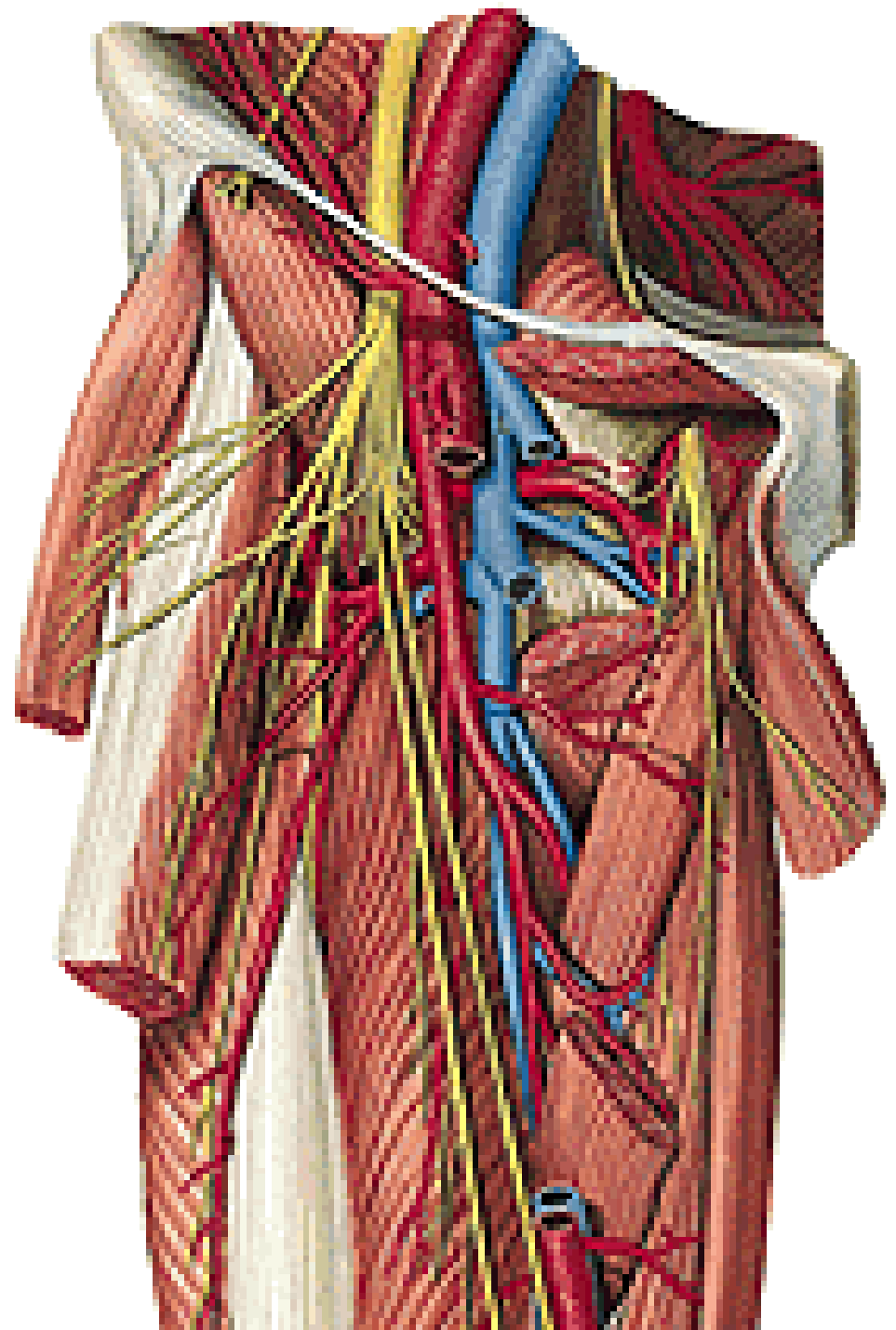
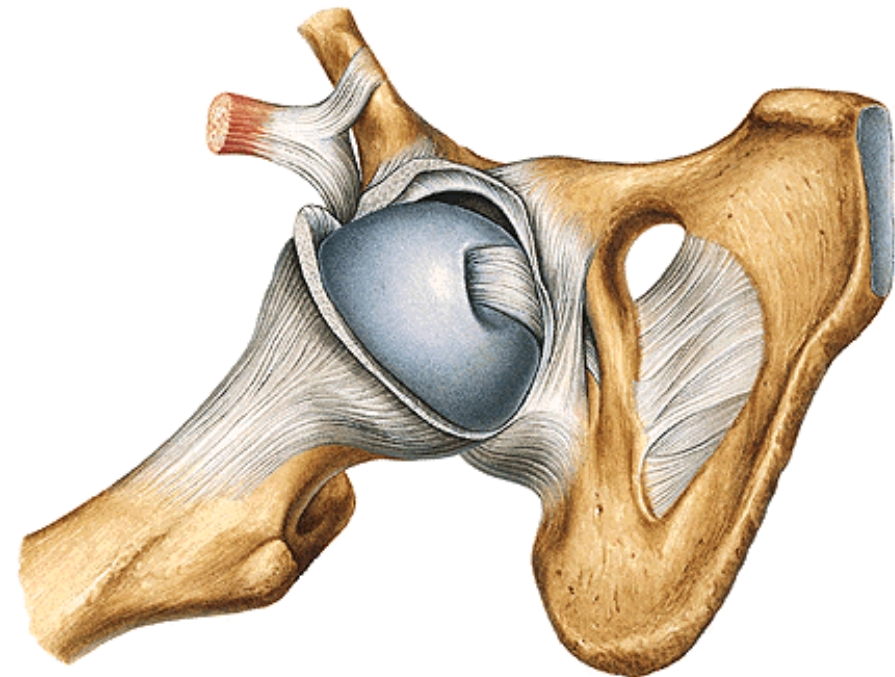


A. OBTURATORIA

R. anterior

R. posterior

R. acetabularis

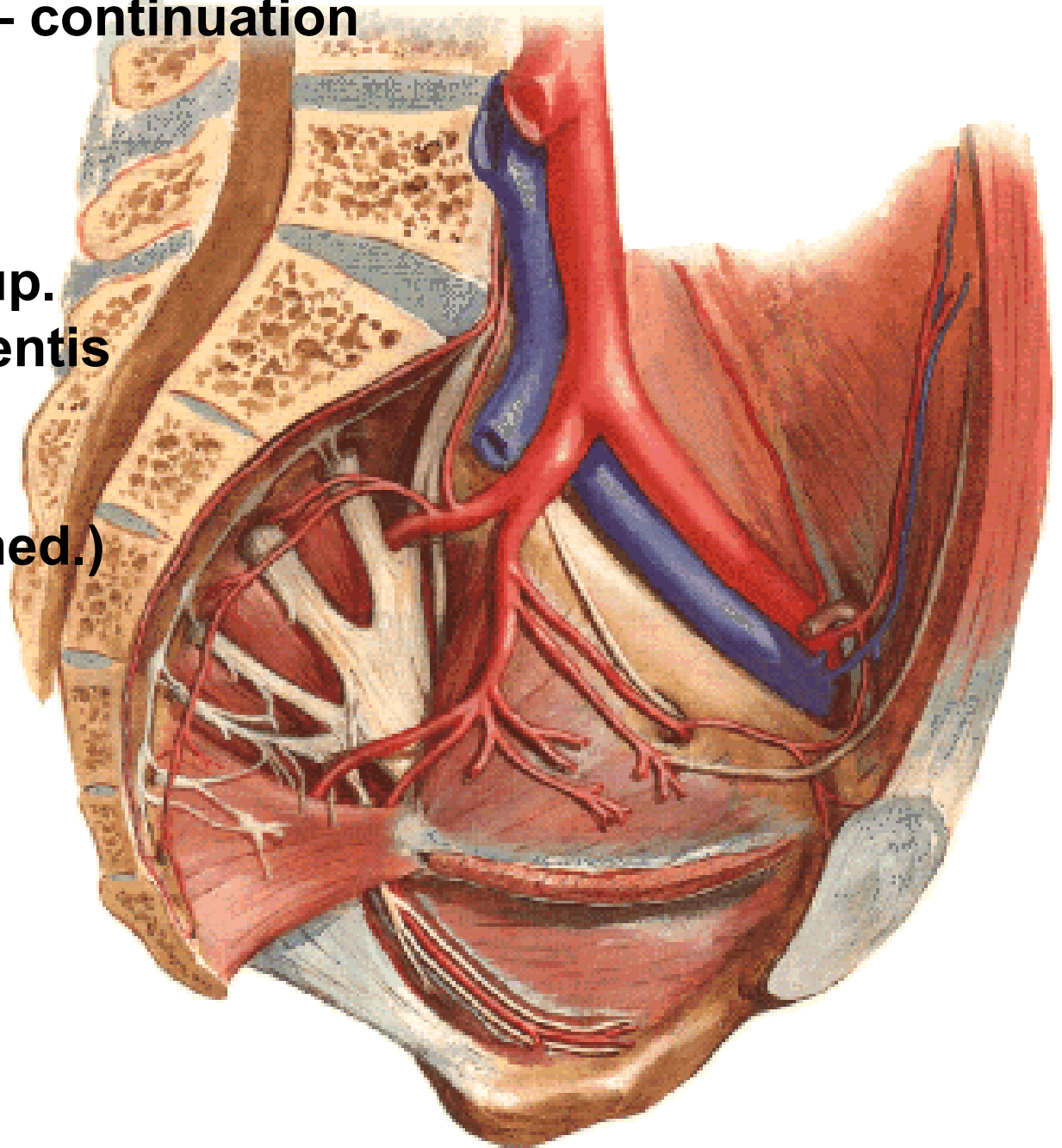


A. ILIACA INTERNA – continuation

Visceral branches

- a. umbilicalis
 - aa. vesicales sup.
 - a. ductus deferentis
 - rr. ureterici

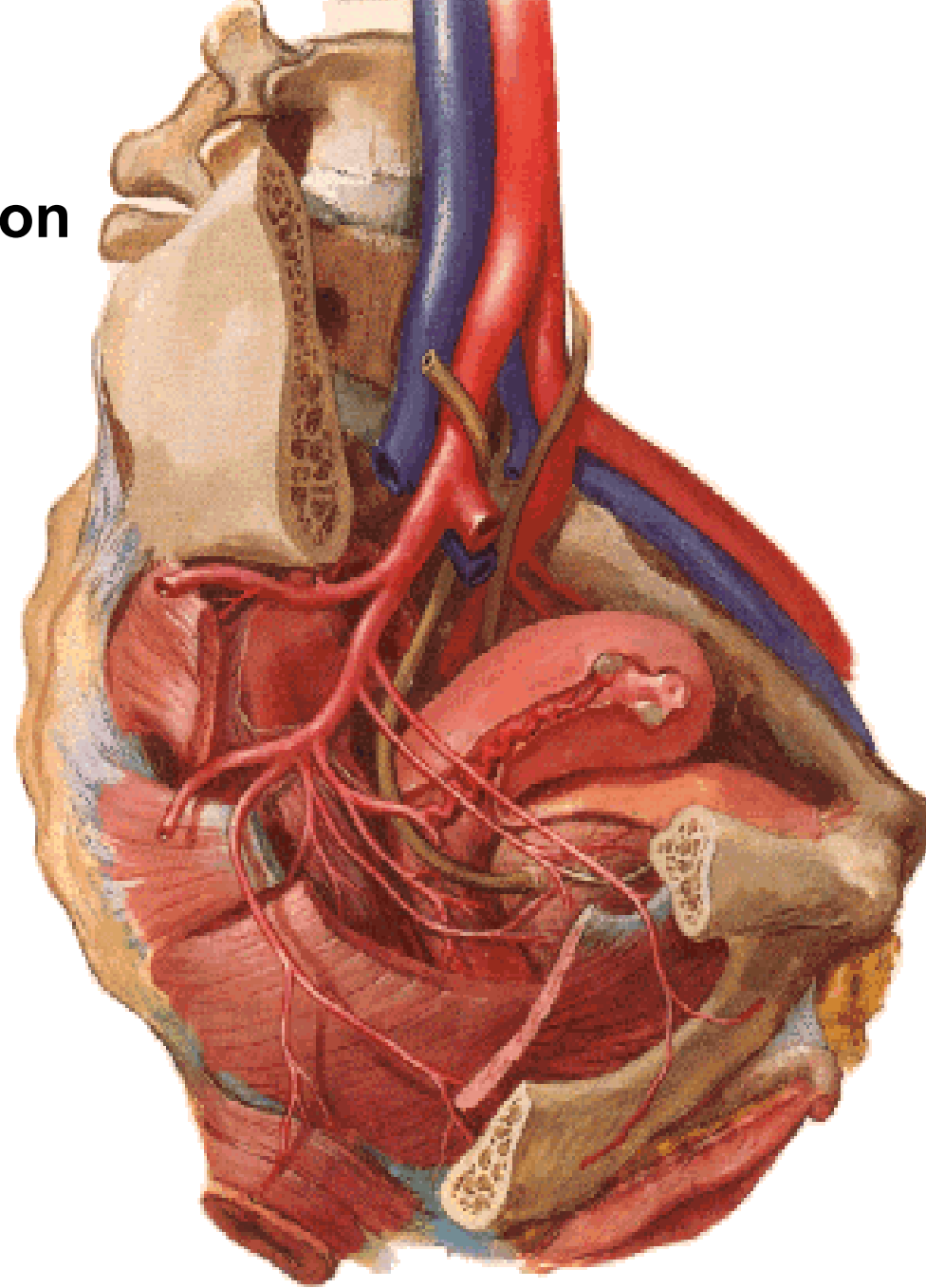
(lig. umbilicale lat./med.)



A. ILIACA INTERNA

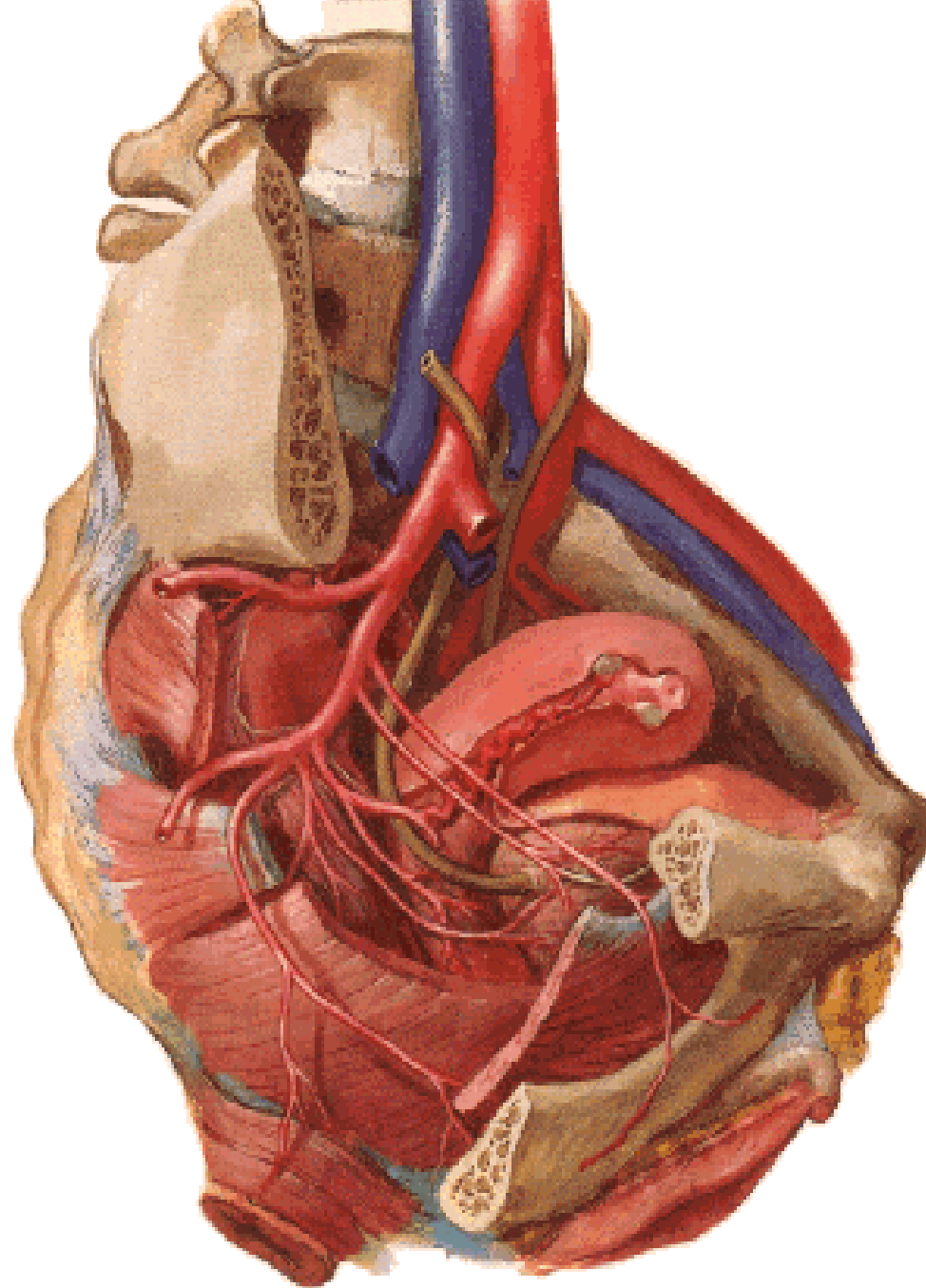
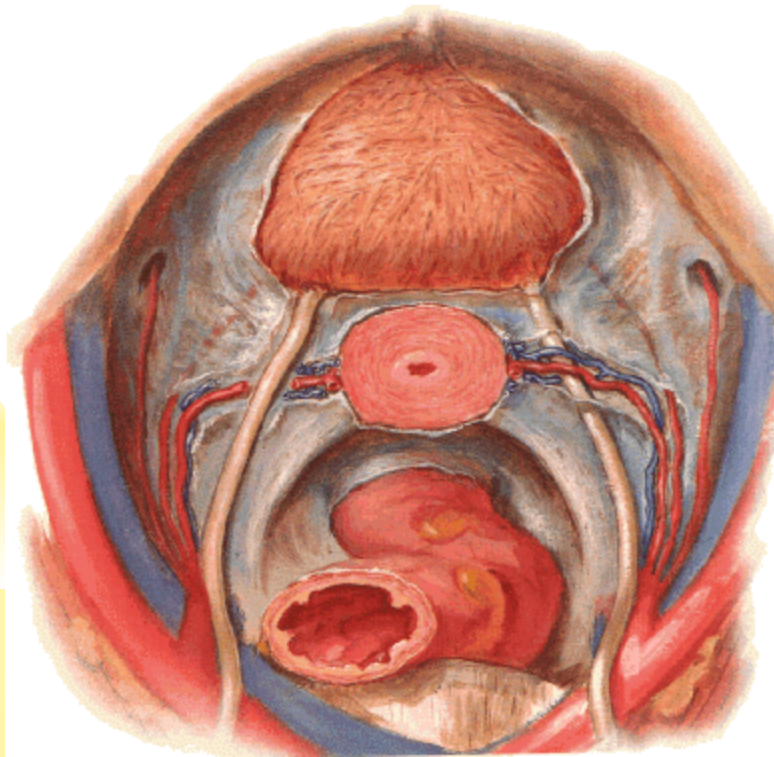
Visceral branches – continuation

- a. vesicalis inf.
- a. rectalis media
- a. uterina
- a. vaginalis
- a. pudenda interna



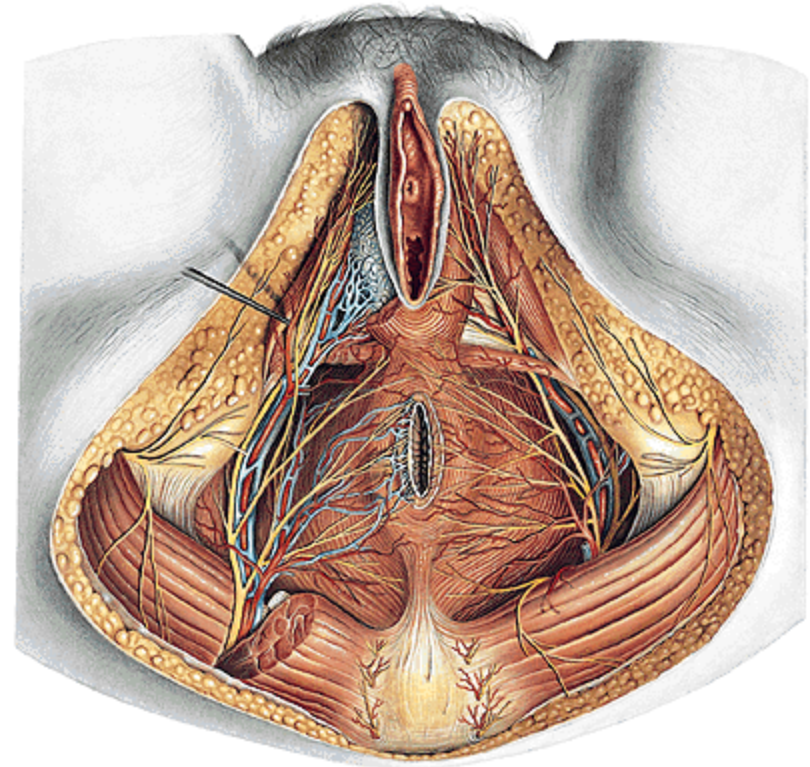
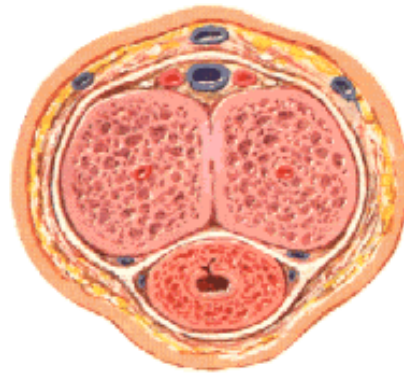
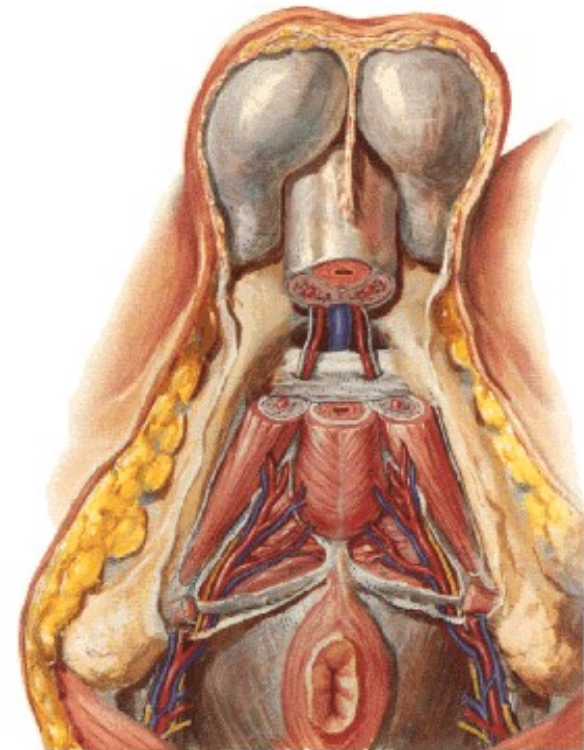
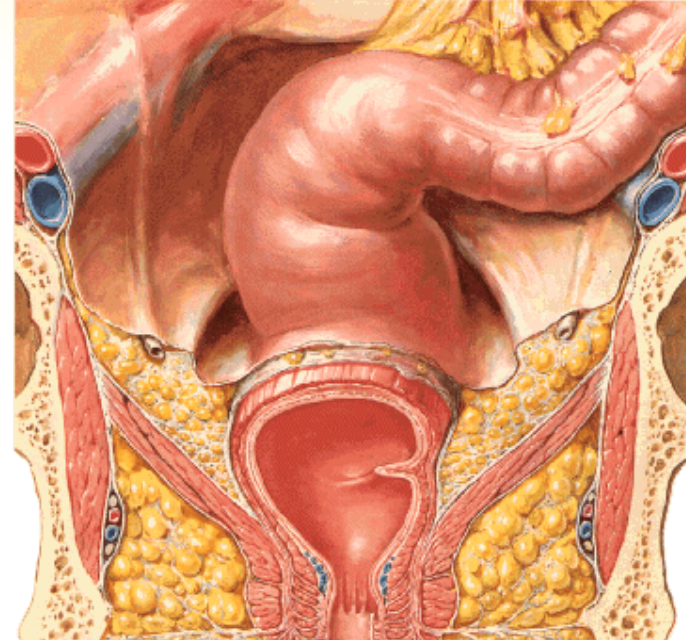
A. UTERINA

- r. uretericus
- rr. vaginales
- rr. helicini
- r. tubarius
- r. ovaricus



A. PUDENDA INTERNA

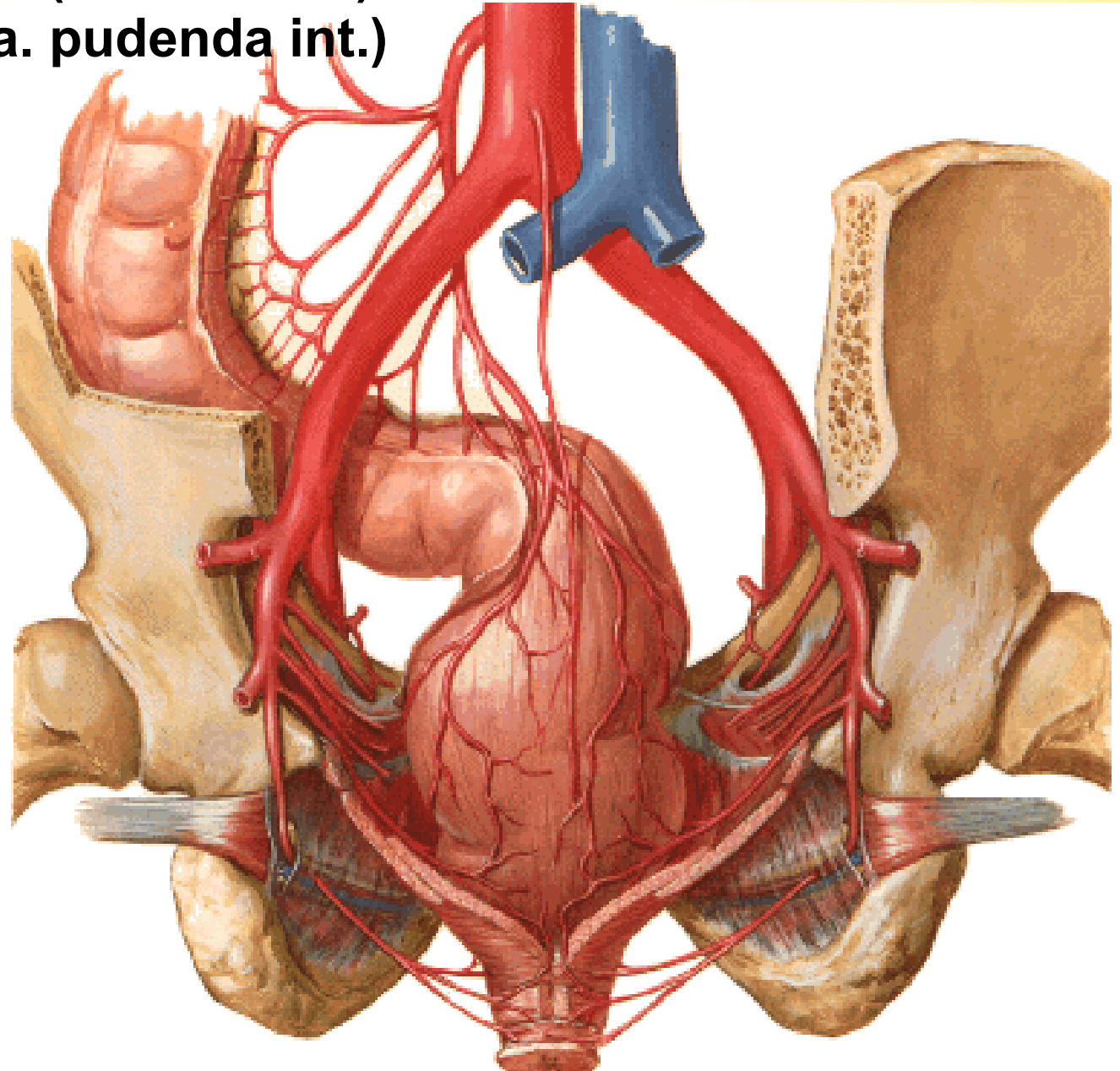
- a. rectalis inf.
- a. perinealis
- a. urethralis (male)
- rr. scrotales (labiales) post.
- a. bulbi penis (bulbi vestibuli)
- a. dorsalis penis (clitoridis)
- a. profunda penis (clitoridis)
 - aa. helicinae



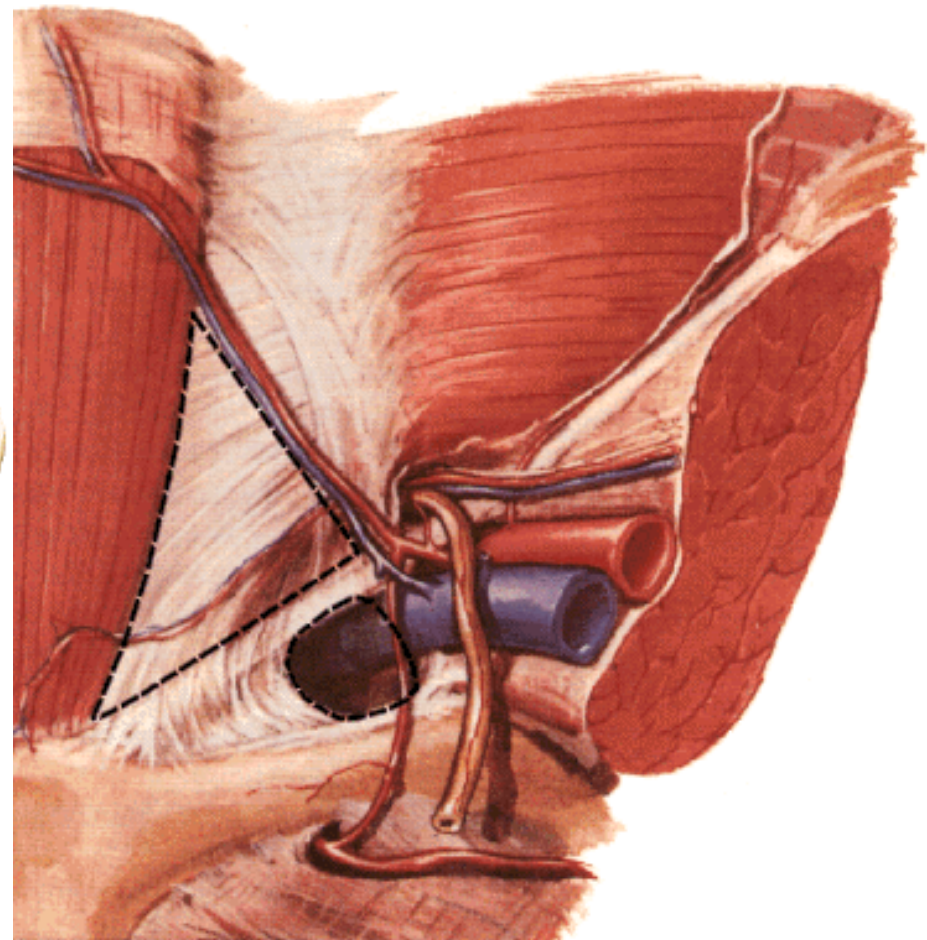
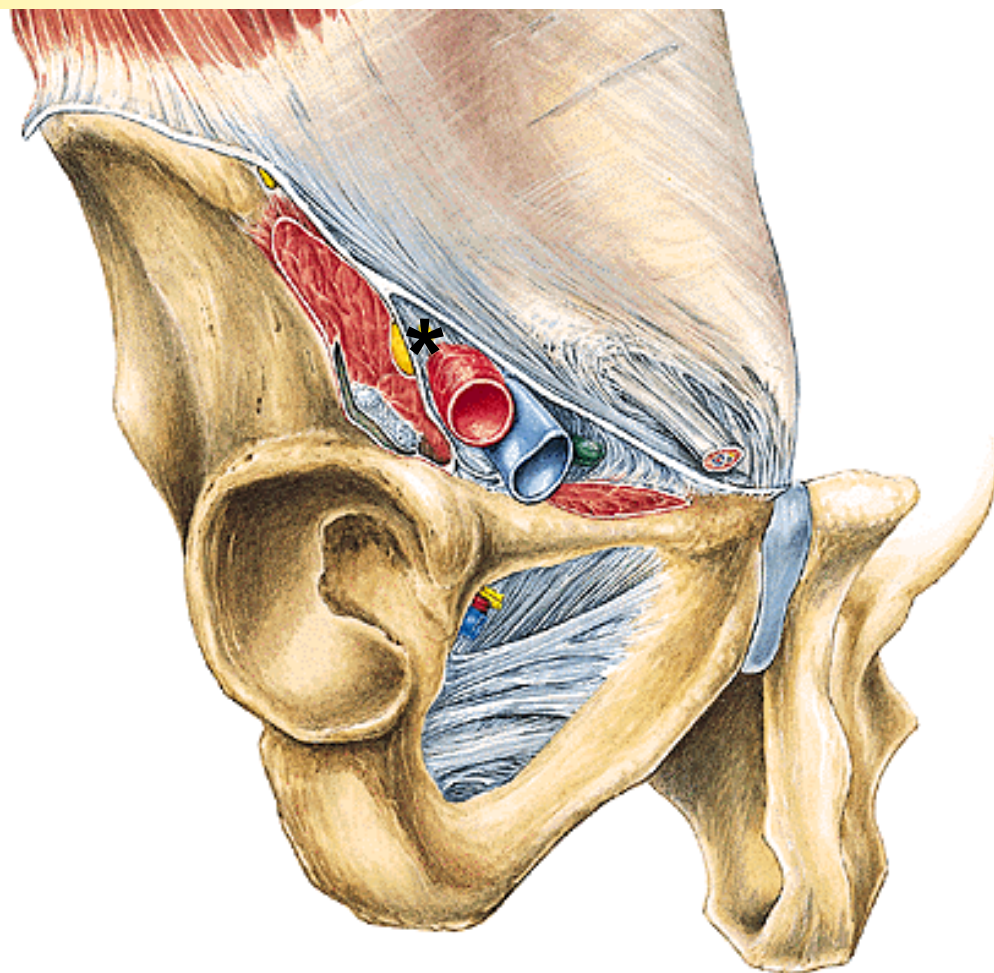
A. rectalis sup. (a. mesenterica inf.)

A. rectalis media (a. iliaca int.)

A. rectalis inf. (a. pudenda int.)

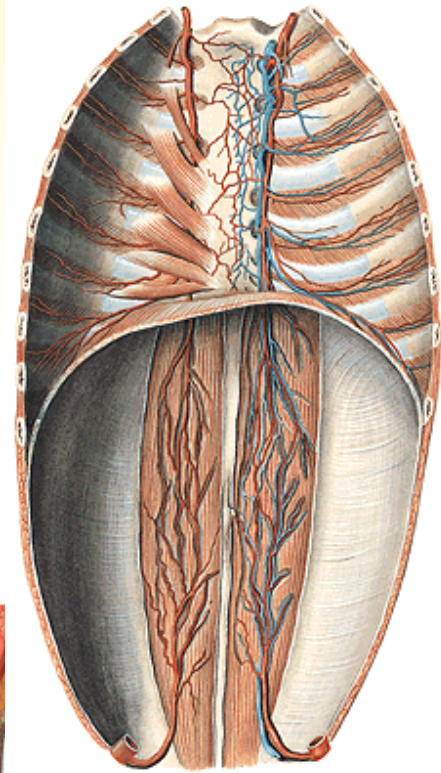
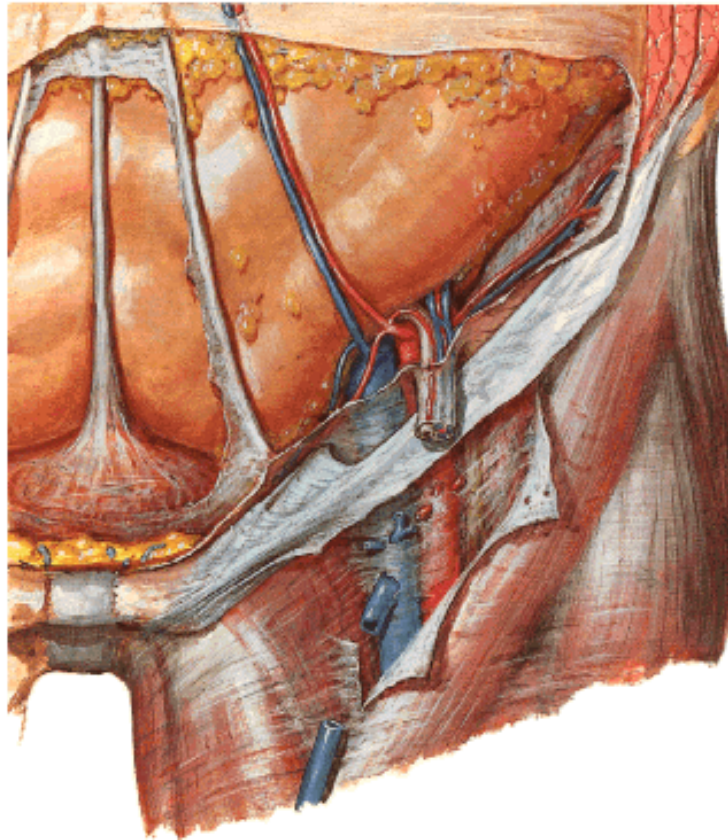
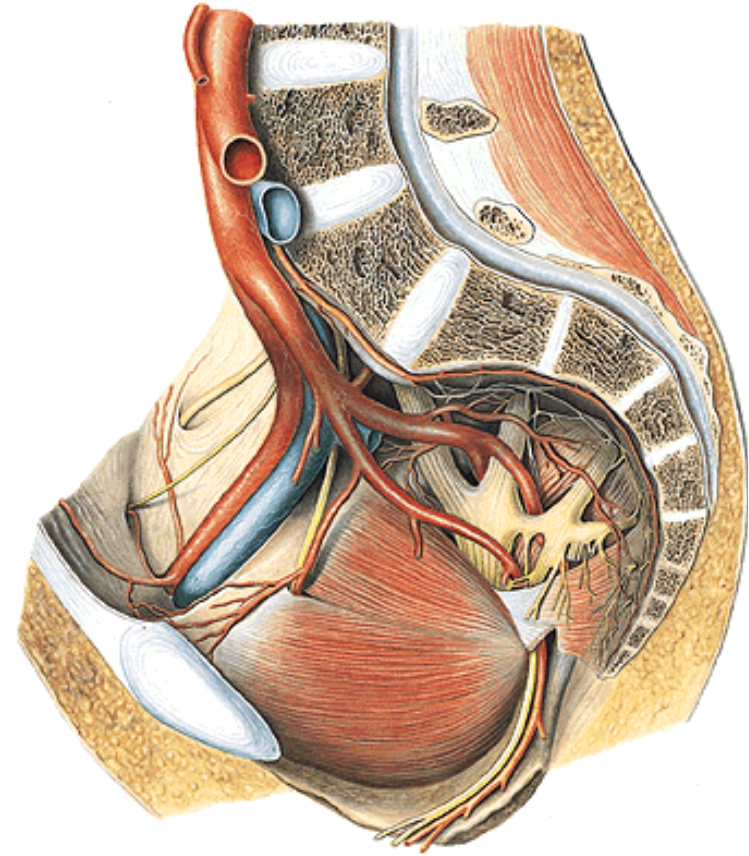


***Lacuna vasorum – anulus femoralis**
Lacuna musculorum



A. ILIACA EXTERNA

- A. epigastrica inf. (ligamentum interfoveolare)
- r. pubicus
- a. cremasterica (ligamenti teretis)
- A. circumflexa ilium profunda



A. FEMORALIS

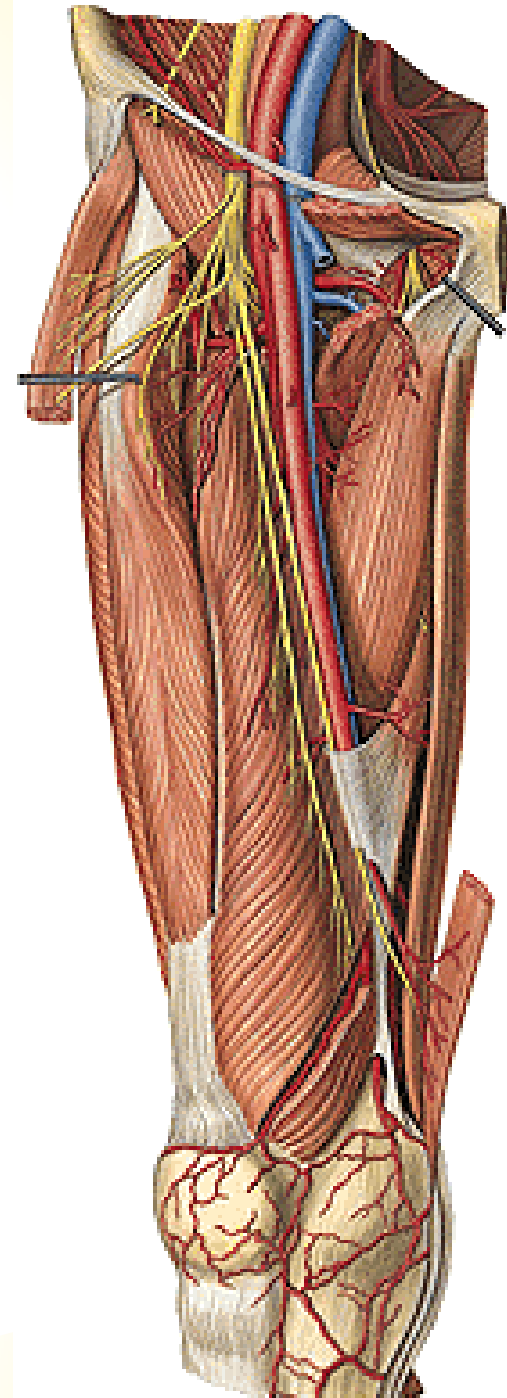
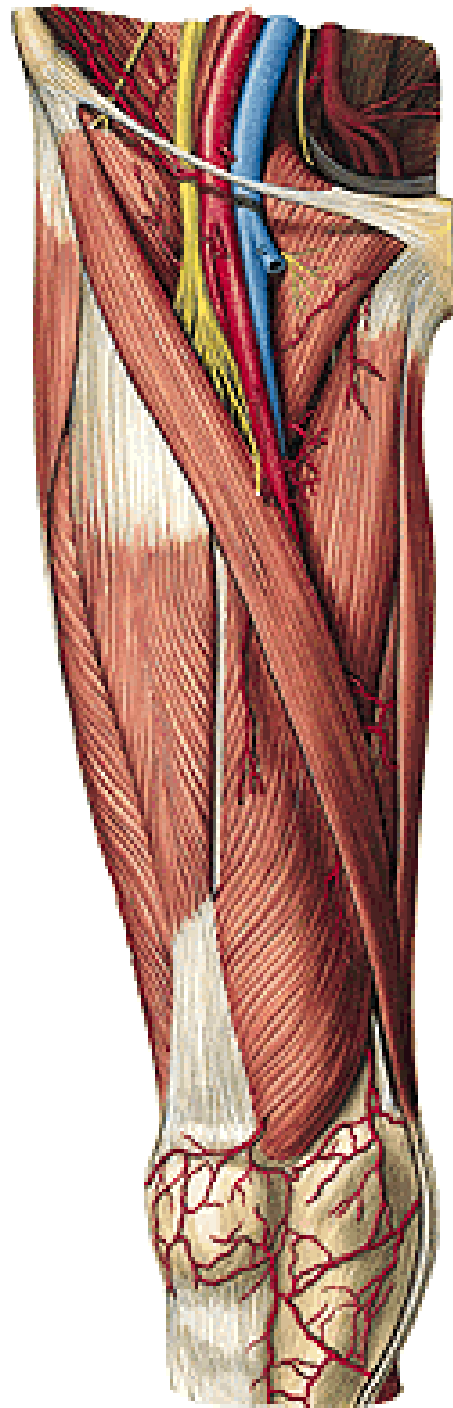
Trigonum femorale

Canalis adductorius

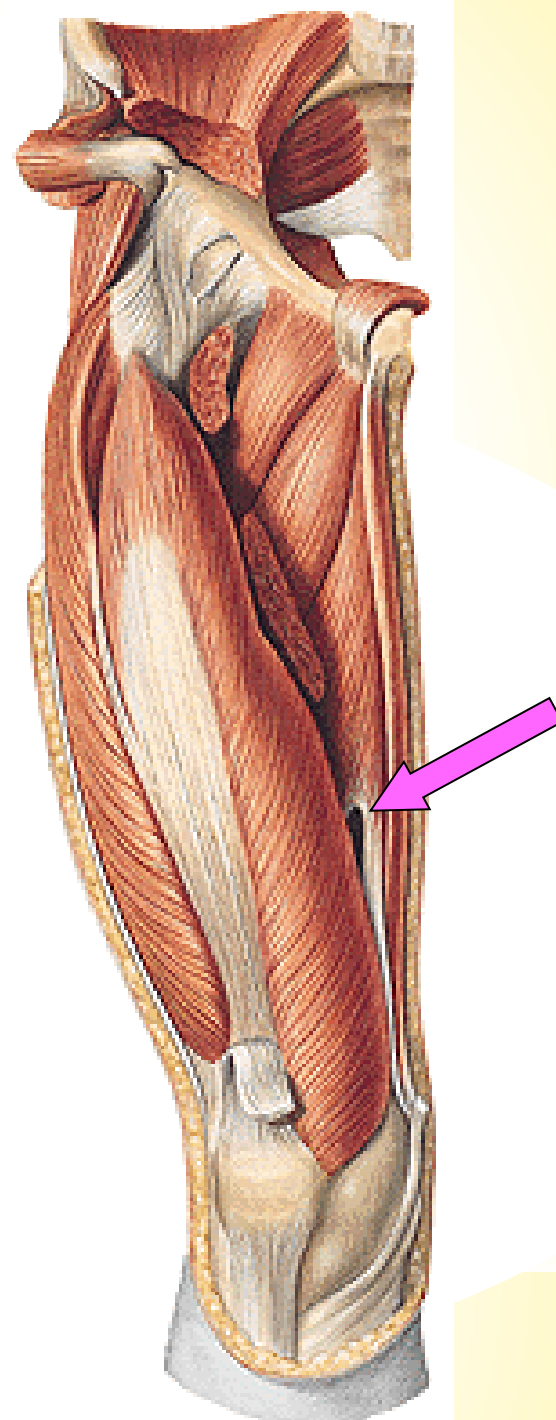
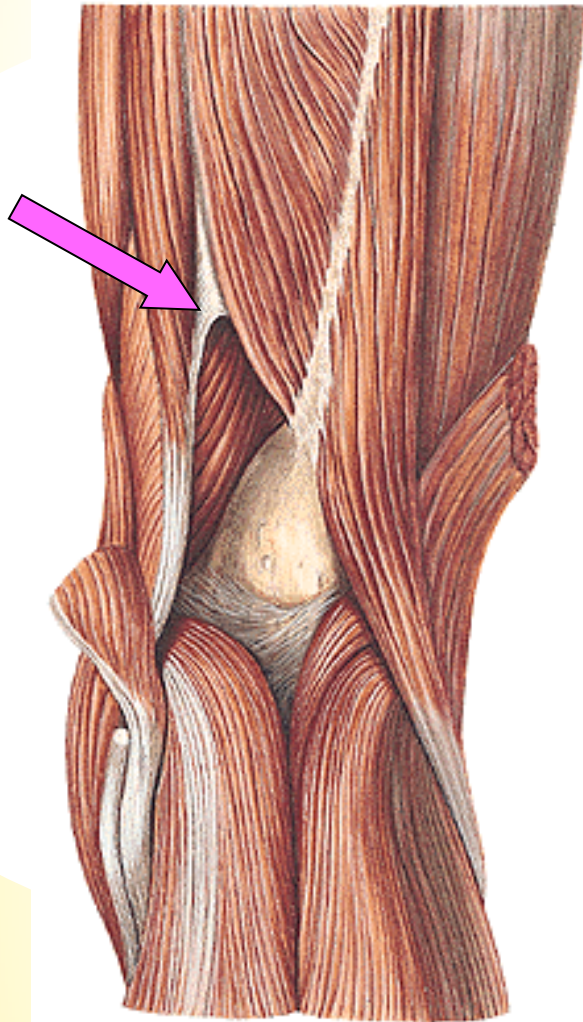
Lamina vastoadductoria

Hiatus tendineus/
adductorius

N. saphenus



Hiatus tendineus/adductorius (Hunter)



A. FEMORALIS

A. epigastrica superficialis

A. circumflexa ilium spf.

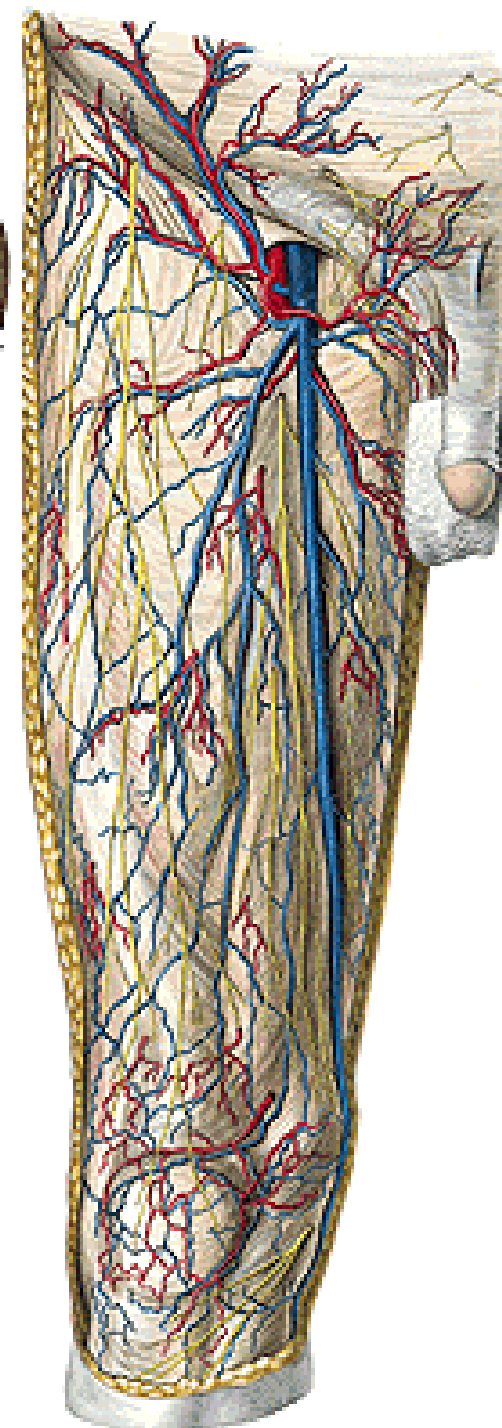
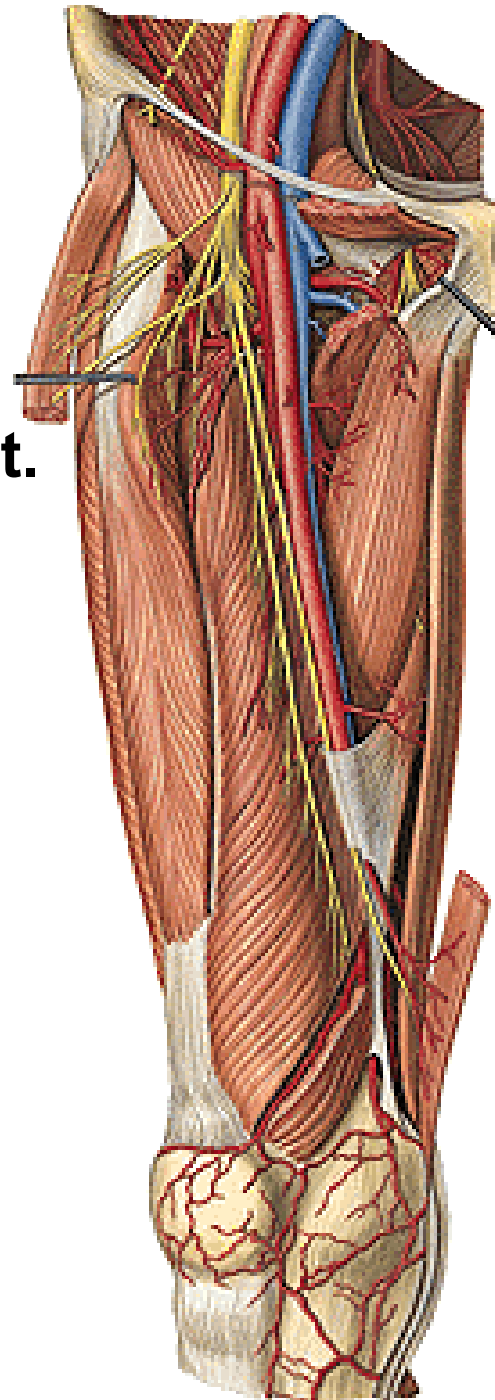
Aa. pudendae ext.

- rr. scrotales (labiales) ant.

A. profunda femoris

Rr. musculares

A. descendens genus



A. PROFUNDA FEMORIS

A. circumflexa femoris medialis

- r. spf.
- r. prof.

A. circumflexa femoris lat.

- r. ascendens
- r. descendens

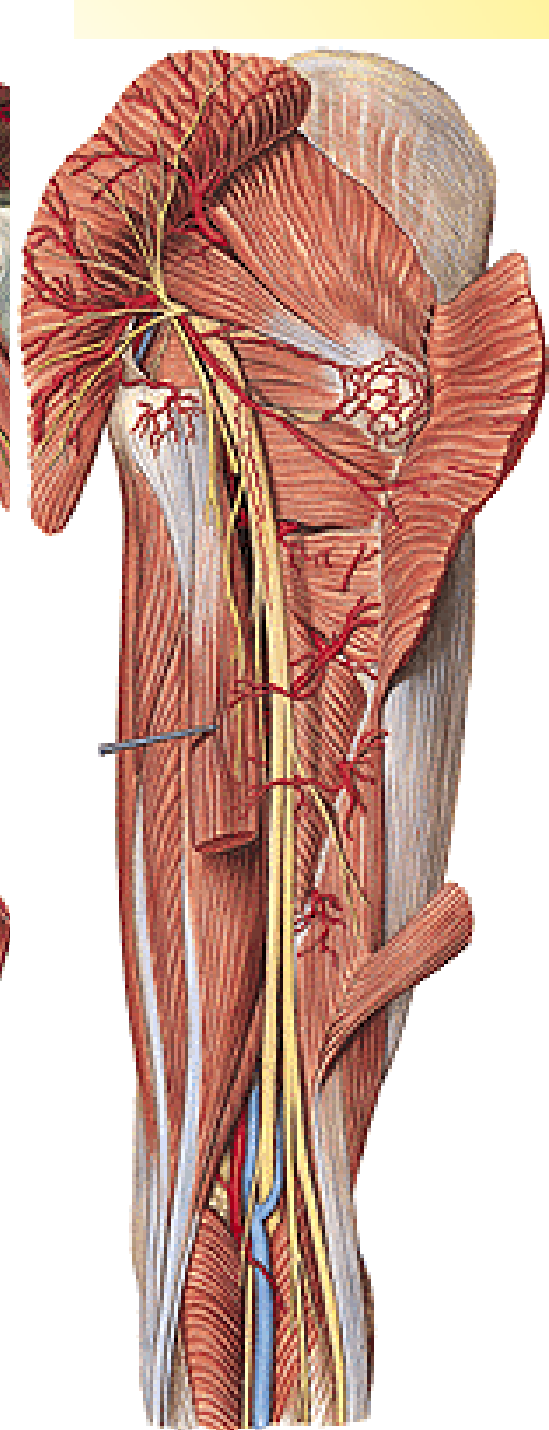
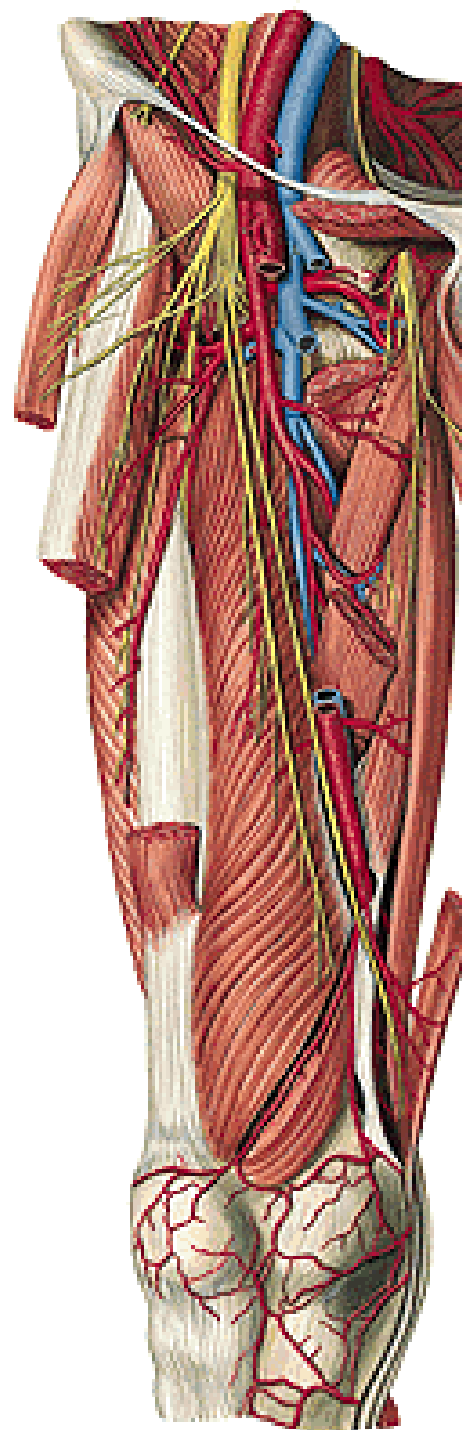
A. perforans prima

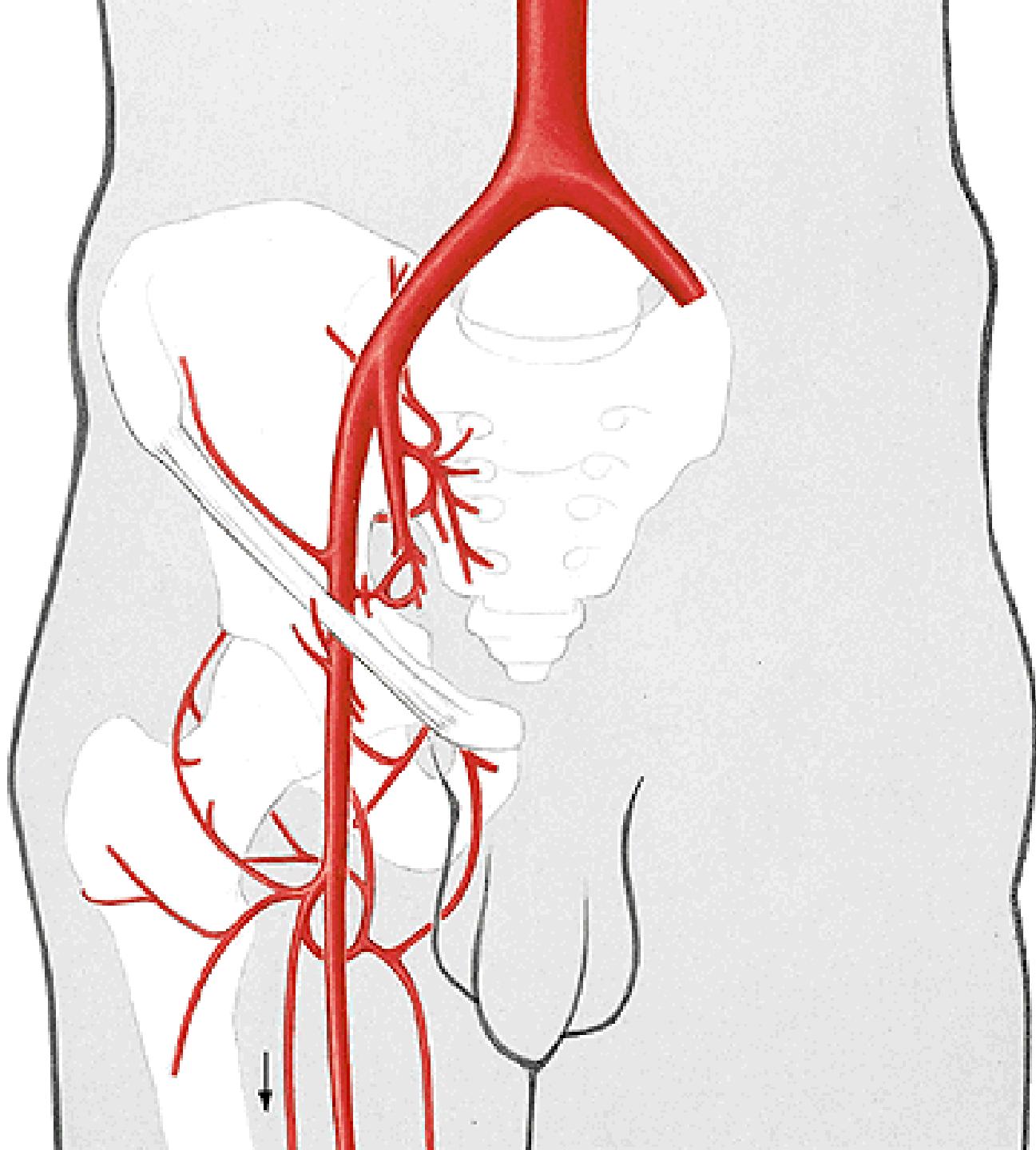
- a. nutricia femoris sup.

A. perforans secunda

A. perforans tertia

- a. nutricia femoris inf.





A. POPLITEA

Aa. surales

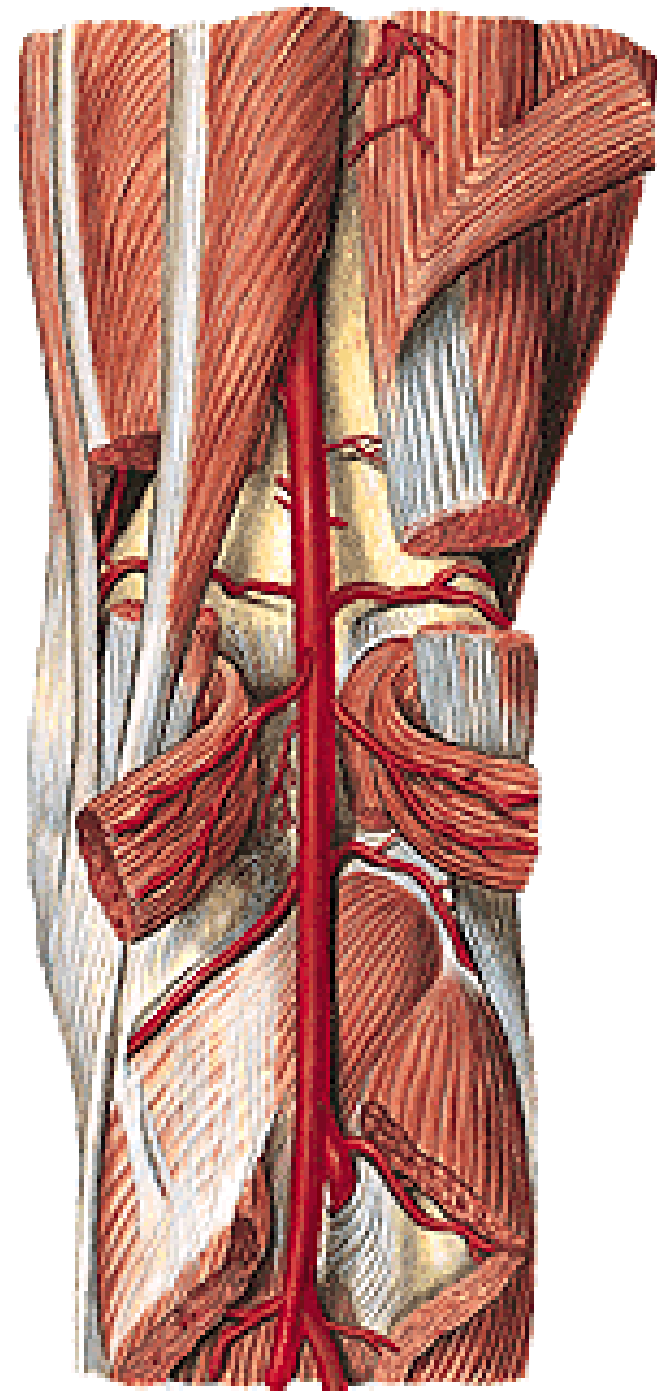
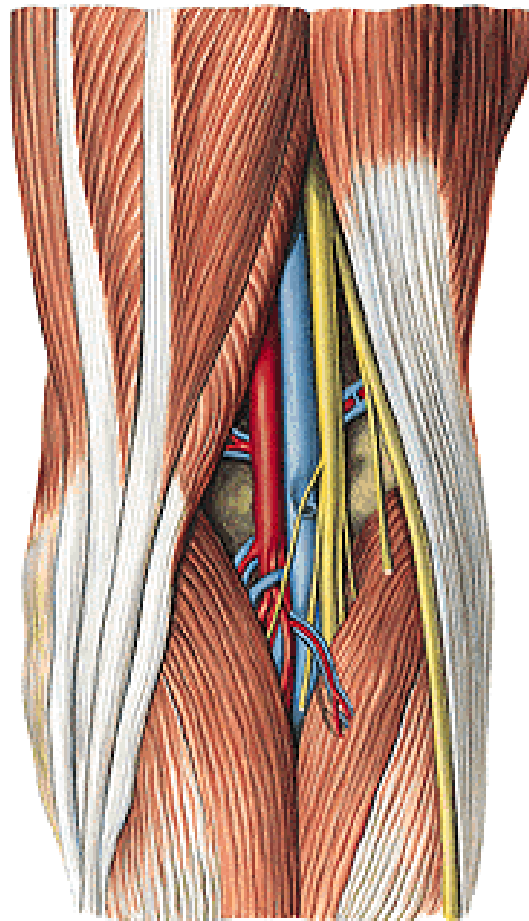
A. sup. med. et lat. genus

A. media genus

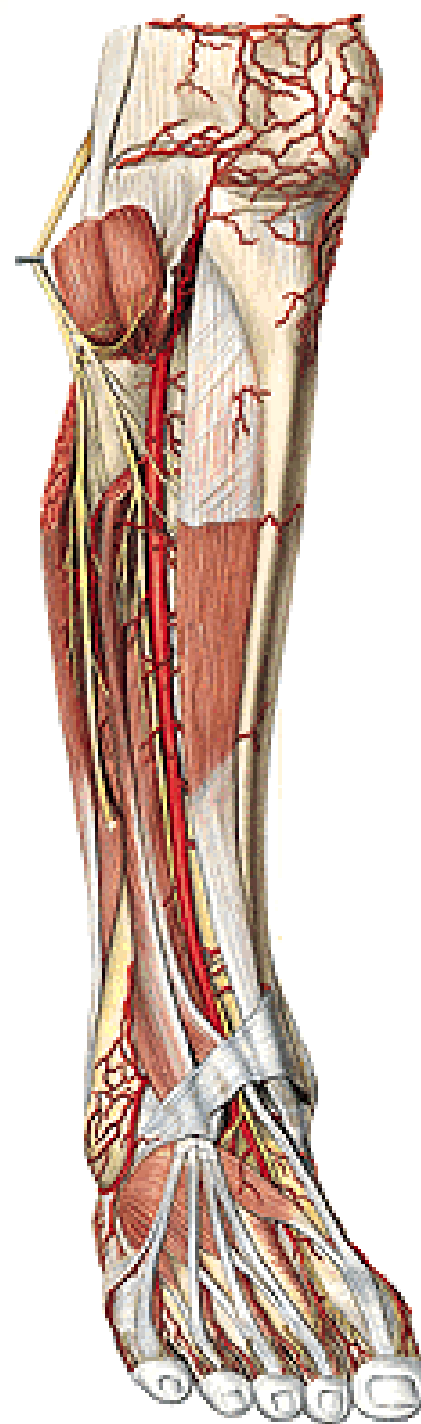
A. inf. med. et lat. genus

A. tibialis ant.

A. tibialis post.



Rete articulare genus



A. TIBIALIS ANT.

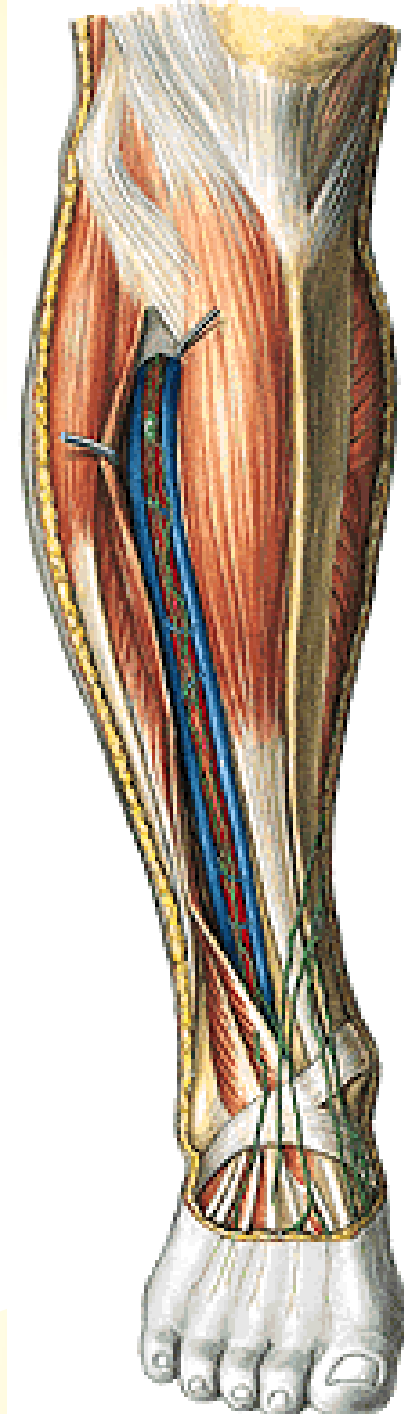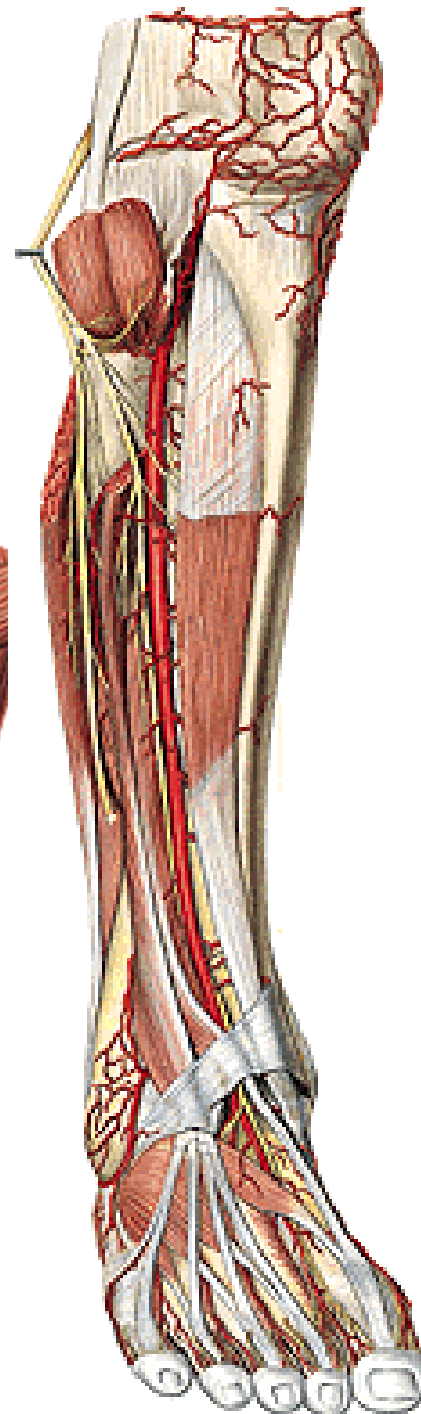
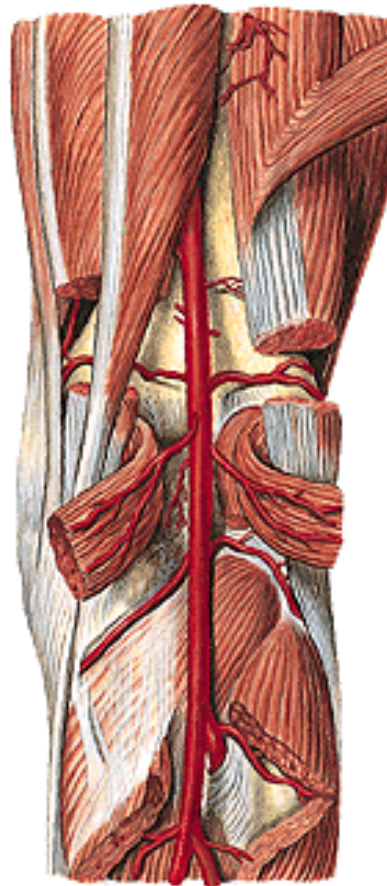
A. recurrens tibialis post.

A. recurrens tibialis ant.

Rr. musculares

A. malleolaris ant. med. et lat.

A. dorsalis pedis



A. DORSALIS PEDIS

A. tarsales med.

A. tarsalis lat.

A. arcuata

- 3 aa. metatarsales dorsales

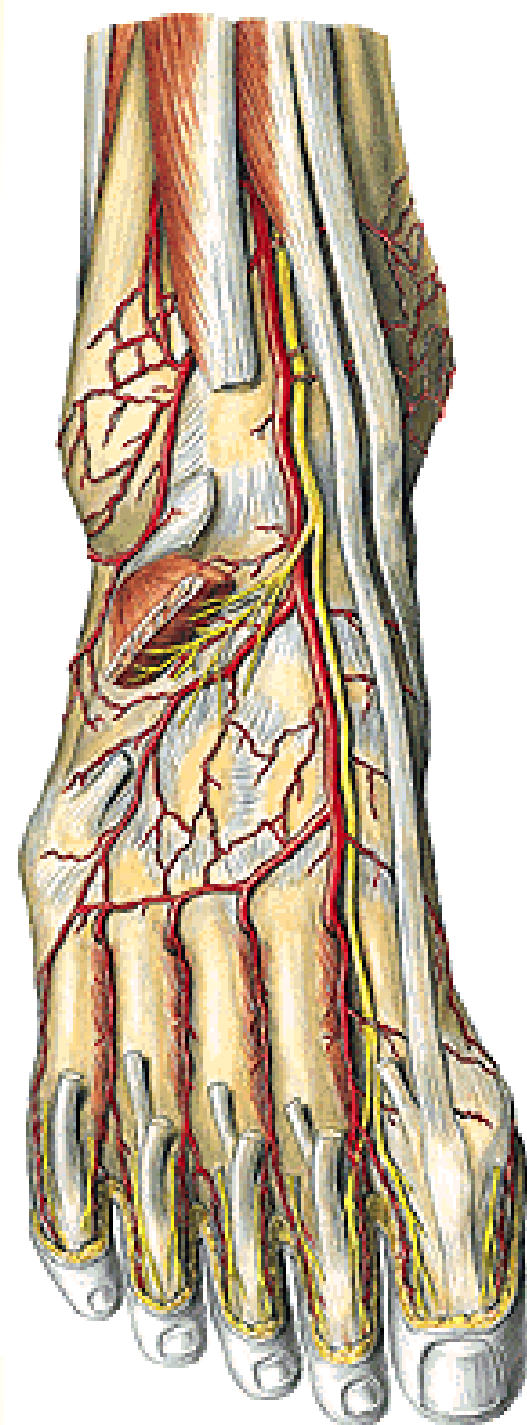
- 2 aa. digitales dorsales

- a. digitalis dorsalis V.

A. metatarsalis dorsalis prima

- aa. digitales dorsales

A. plantaris prof.



A. TIBIALIS POST.

R. circumflexus fibularis

A. fibularis/peronea

Rr. musculares

A. nutricia tibiae

Rr. malleolares med.

Rr. calcanei

A. plantaris lat.

A. plantaris med.

A. FIBULARIS/PERONEA

Rr. musculares

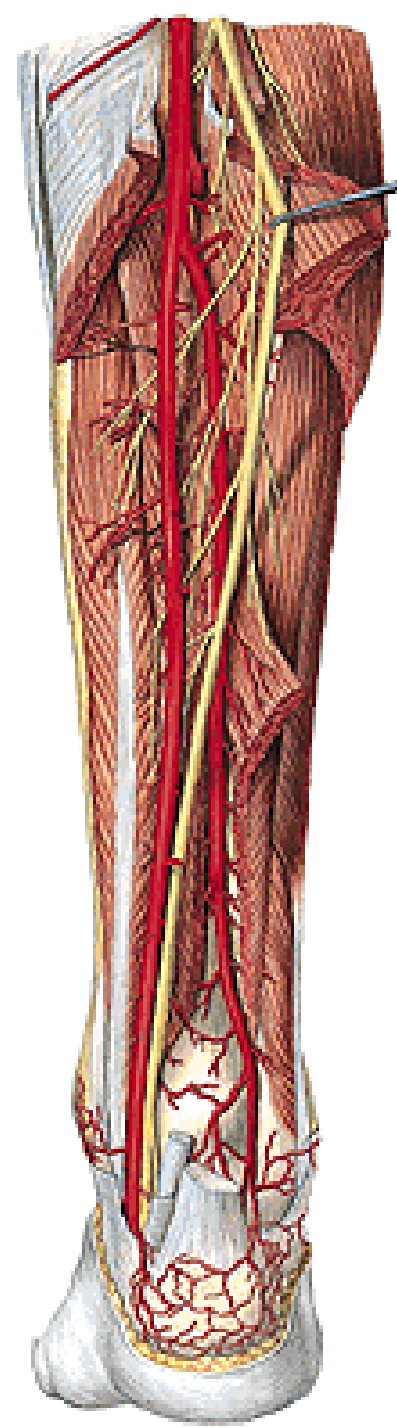
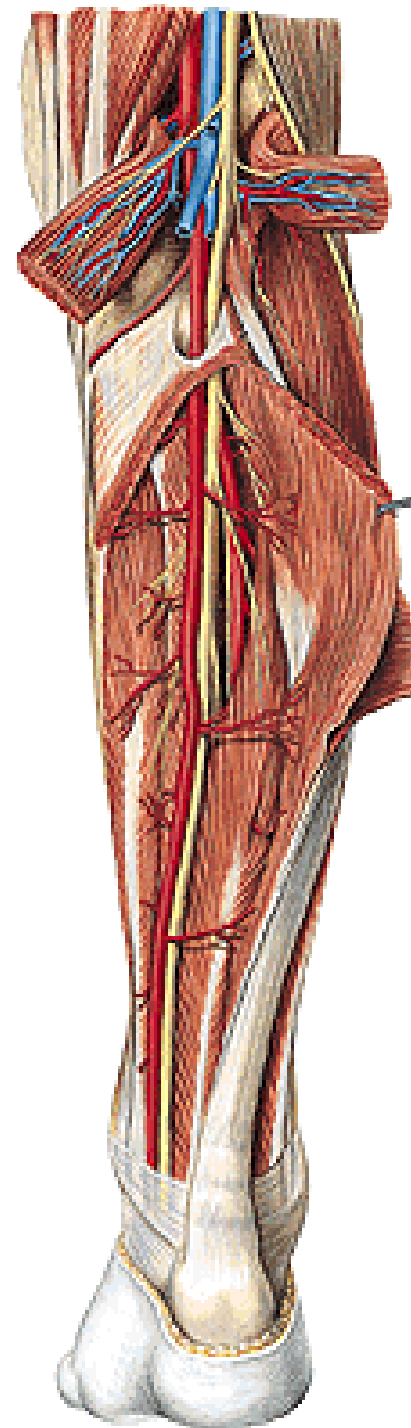
A. nutricia fibulae

R. communicans

R. perforans

Rr. malleolares lat.

Rr. calcanei

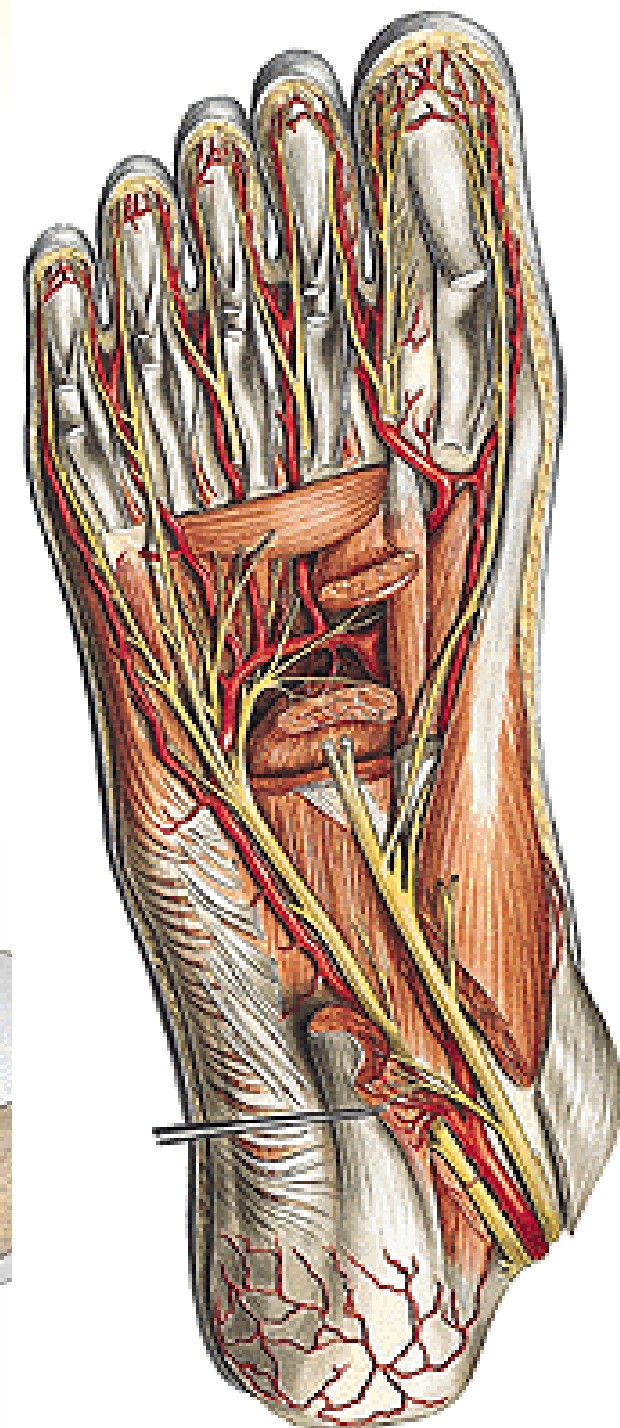
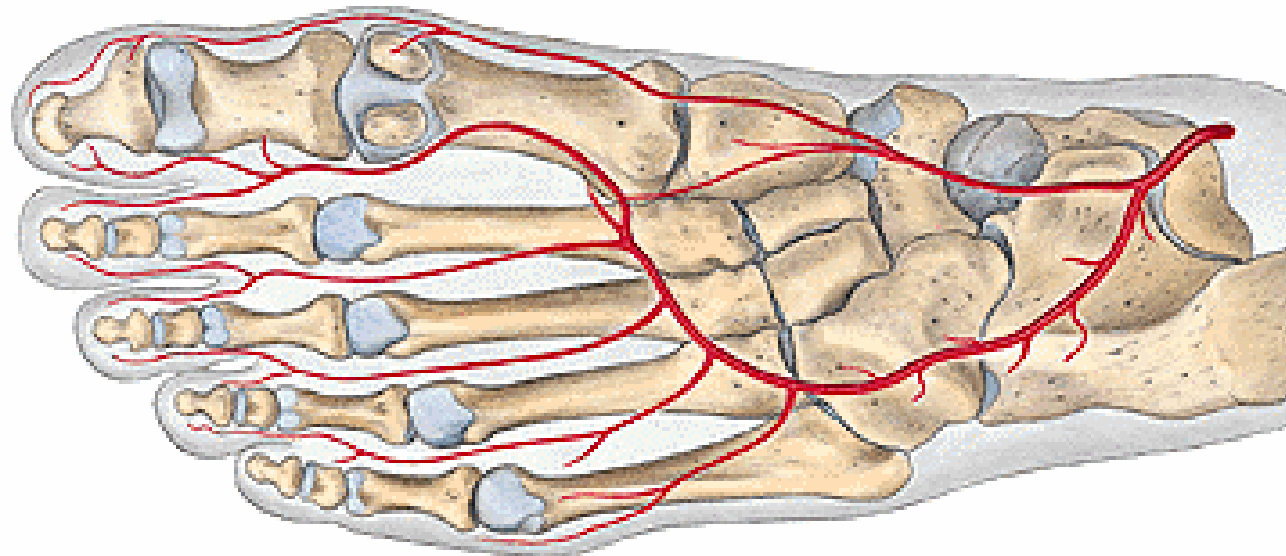


A. PLANTARIS LAT.

- arcus plantaris prof.
- 4 aa. metatarsales plantares
 - a. digitalis plantaris communis
 - 2 aa. digitales plantares propriae
- rr. perforantes

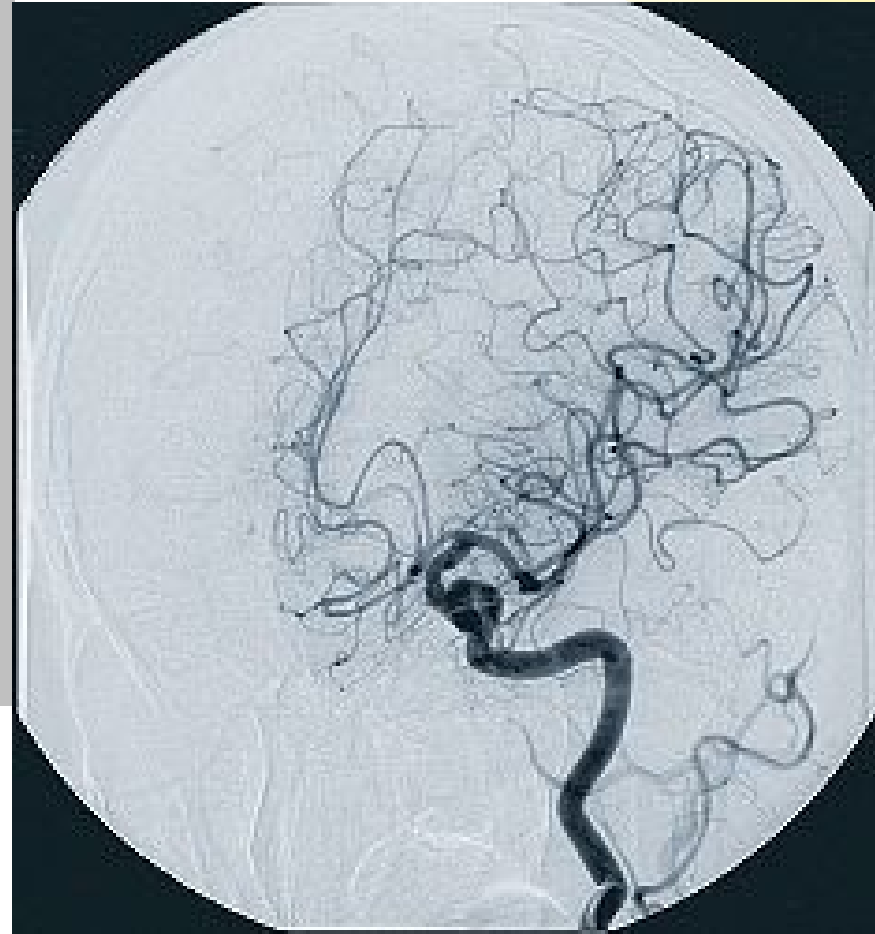
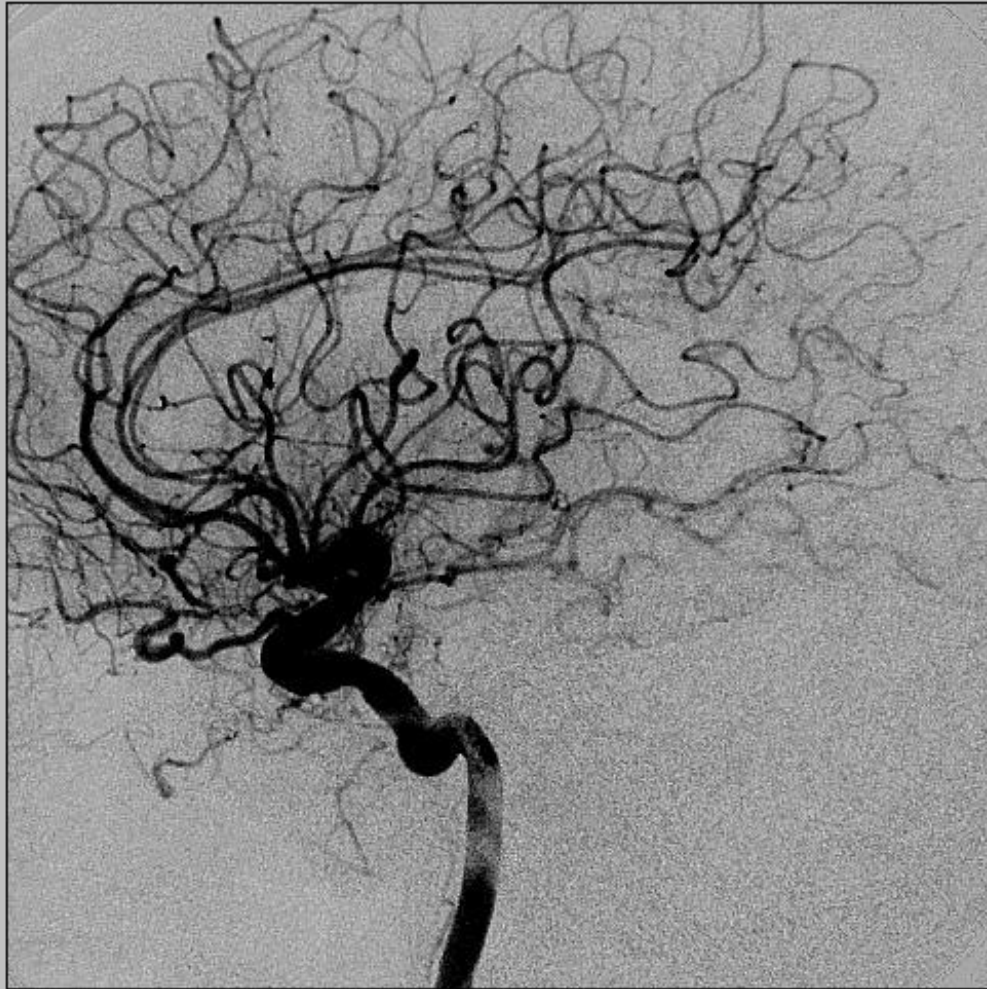A. PLANTARIS MED.

- r. spf.
- r. prof.

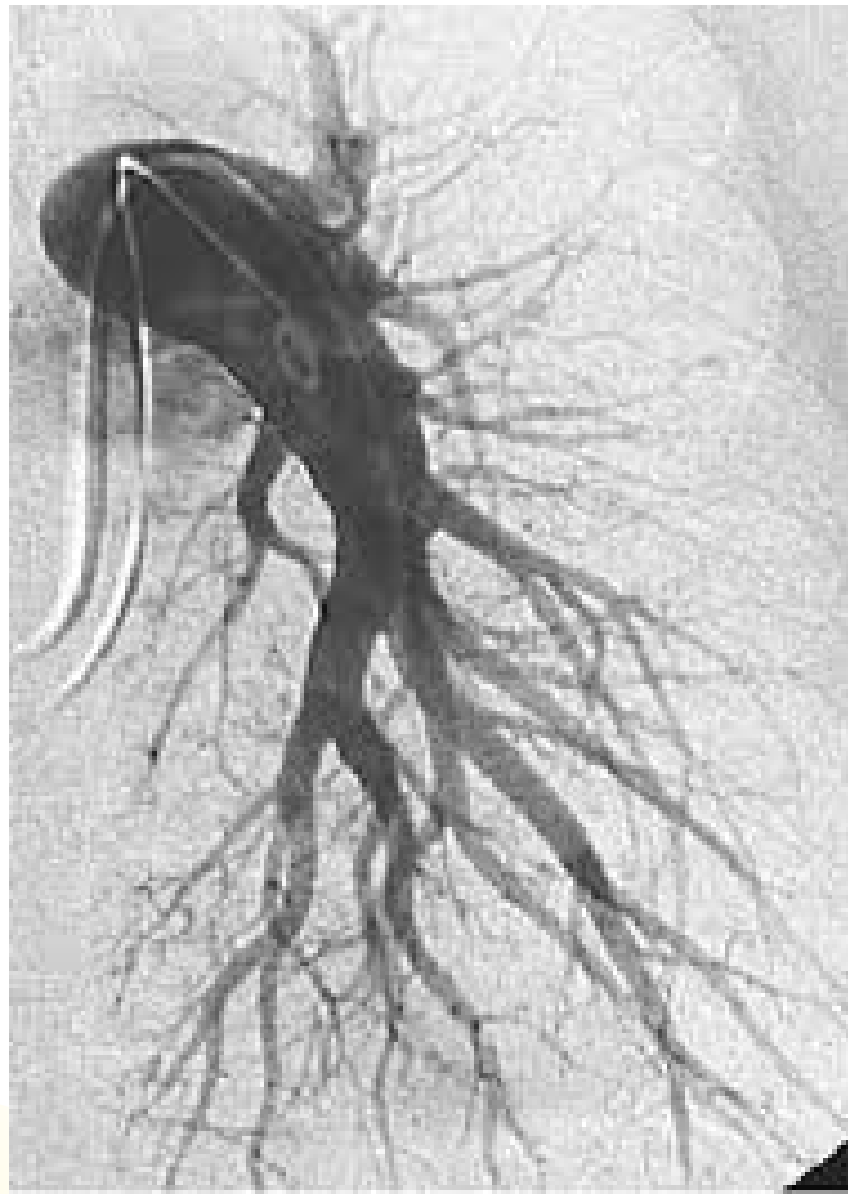


- **Rete articulare genus**
- **Rete malleolare mediale**
- **Rete malleolare laterale**
- **Rete calcaneum**
- **Rete dorsale pedis**

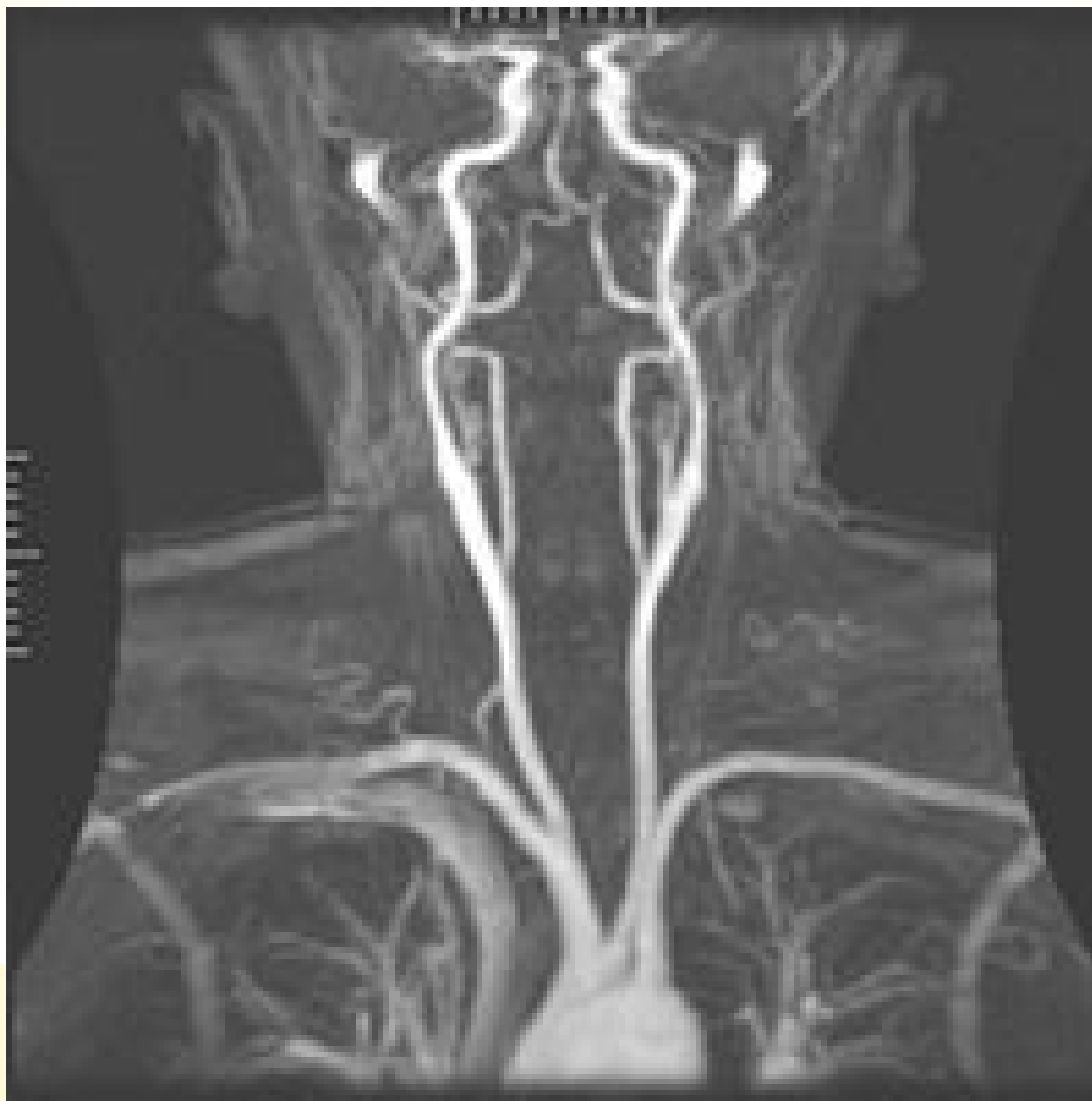Digital subtraction arteriogram – a. carotis int.



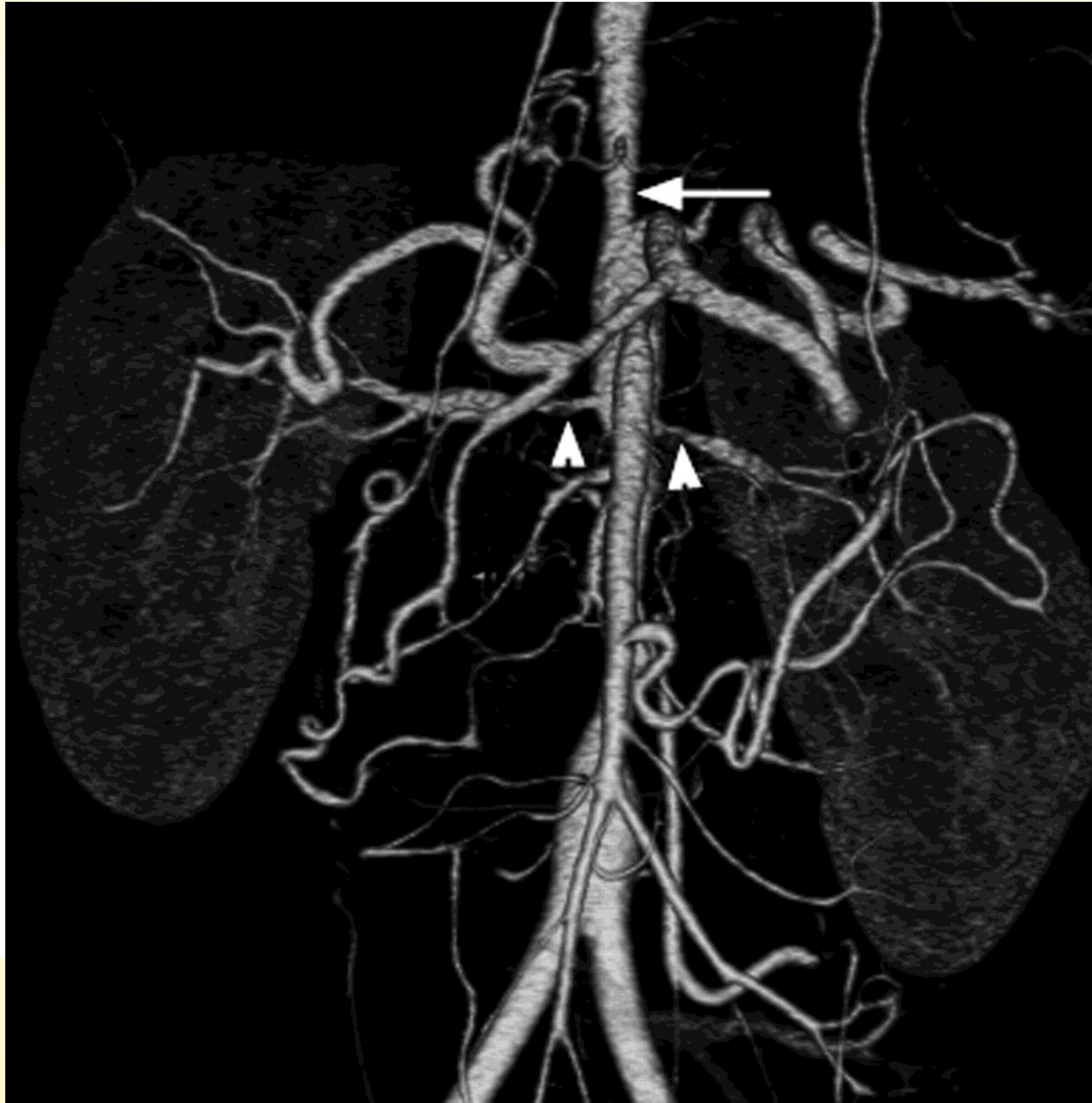
Pulmonary angiography



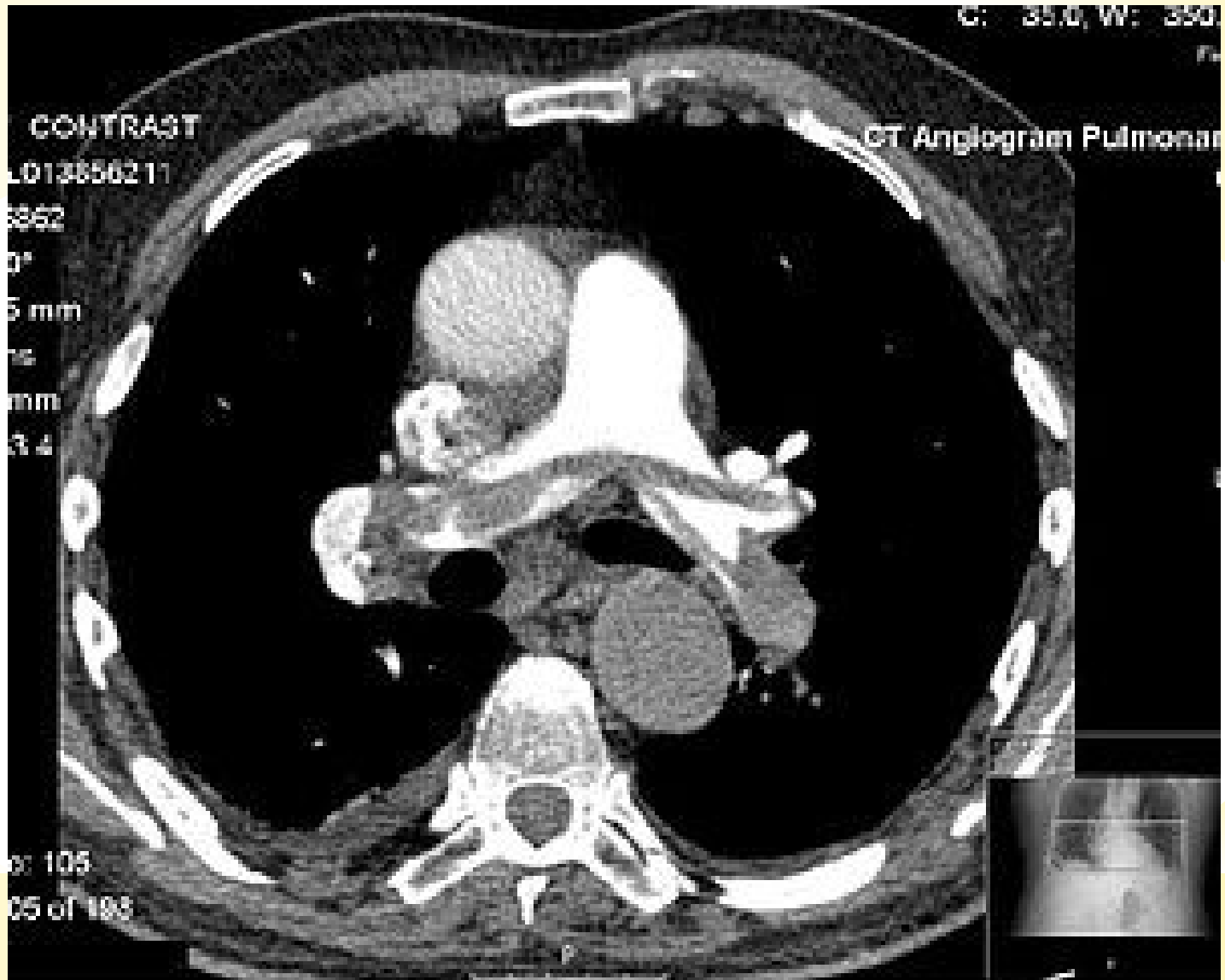Magnetic resonance angiography



CT angiography



CTPA



Illustrations were copied from:

**Atlas der Anatomie des Menschen/Sobotta.
Putz,R., und Pabst,R. 20. Auflage. München:
Urban & Schwarzenberg, 1993)**

**Netter: Interactive Atlas of Human Anatomy.
Windows Version 2.0**

**Čihák R: Anatomie 2 (Splanchnologia). Avicenum,
zdravotnické nakladatelství, Praha, 1988.**