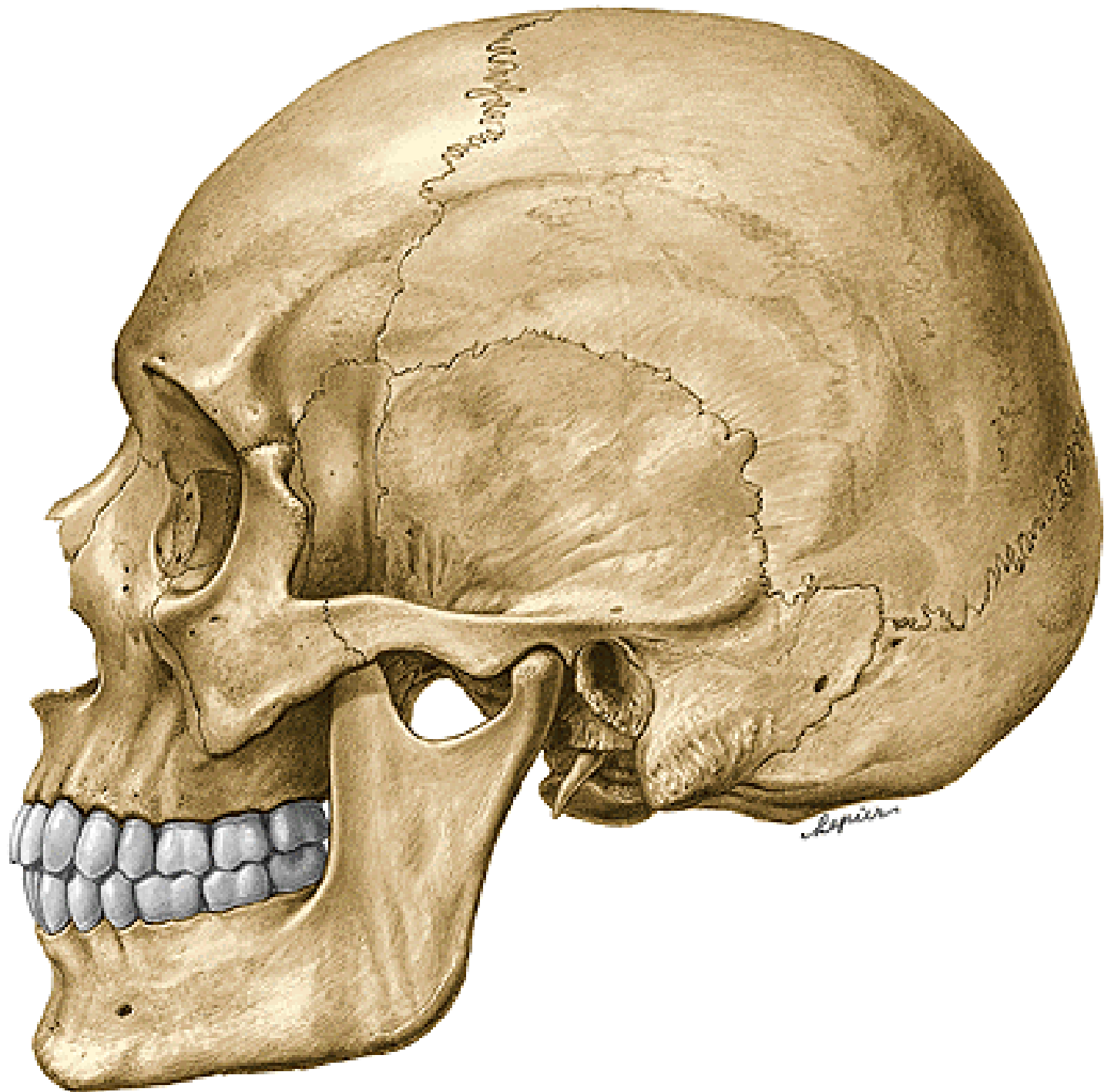
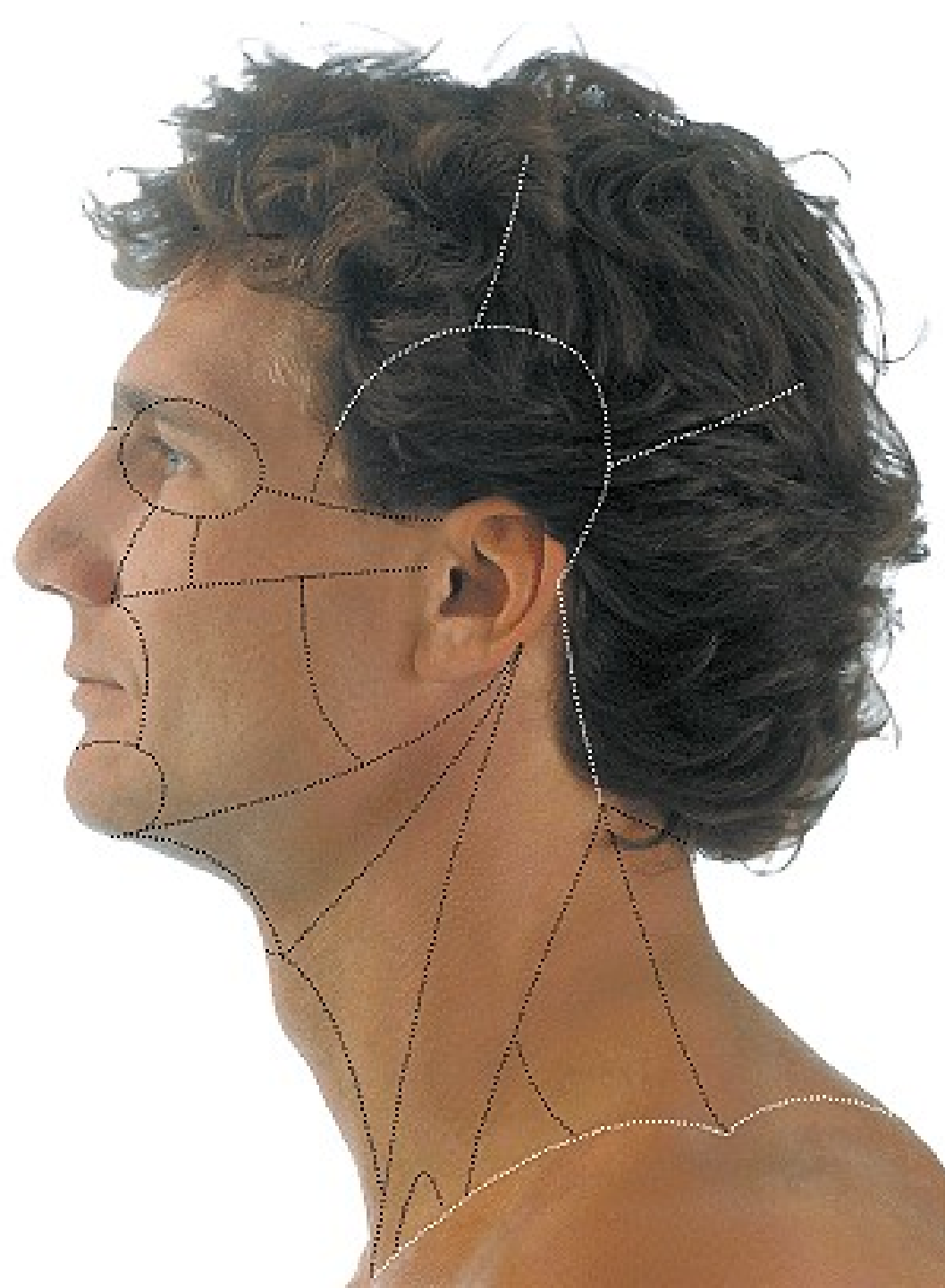
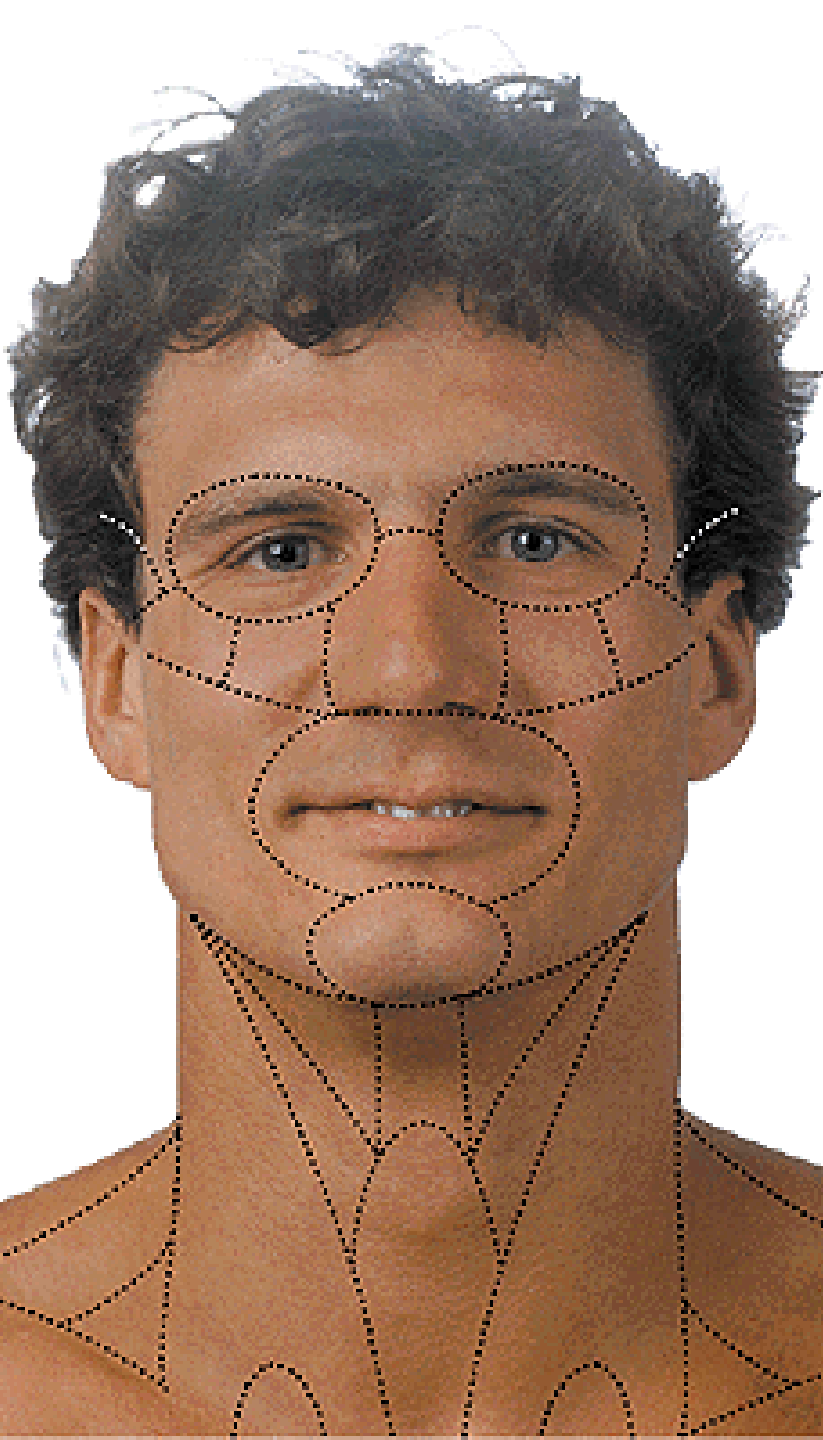


**REGIONAL ANATOMY**

**OF THE HEAD**

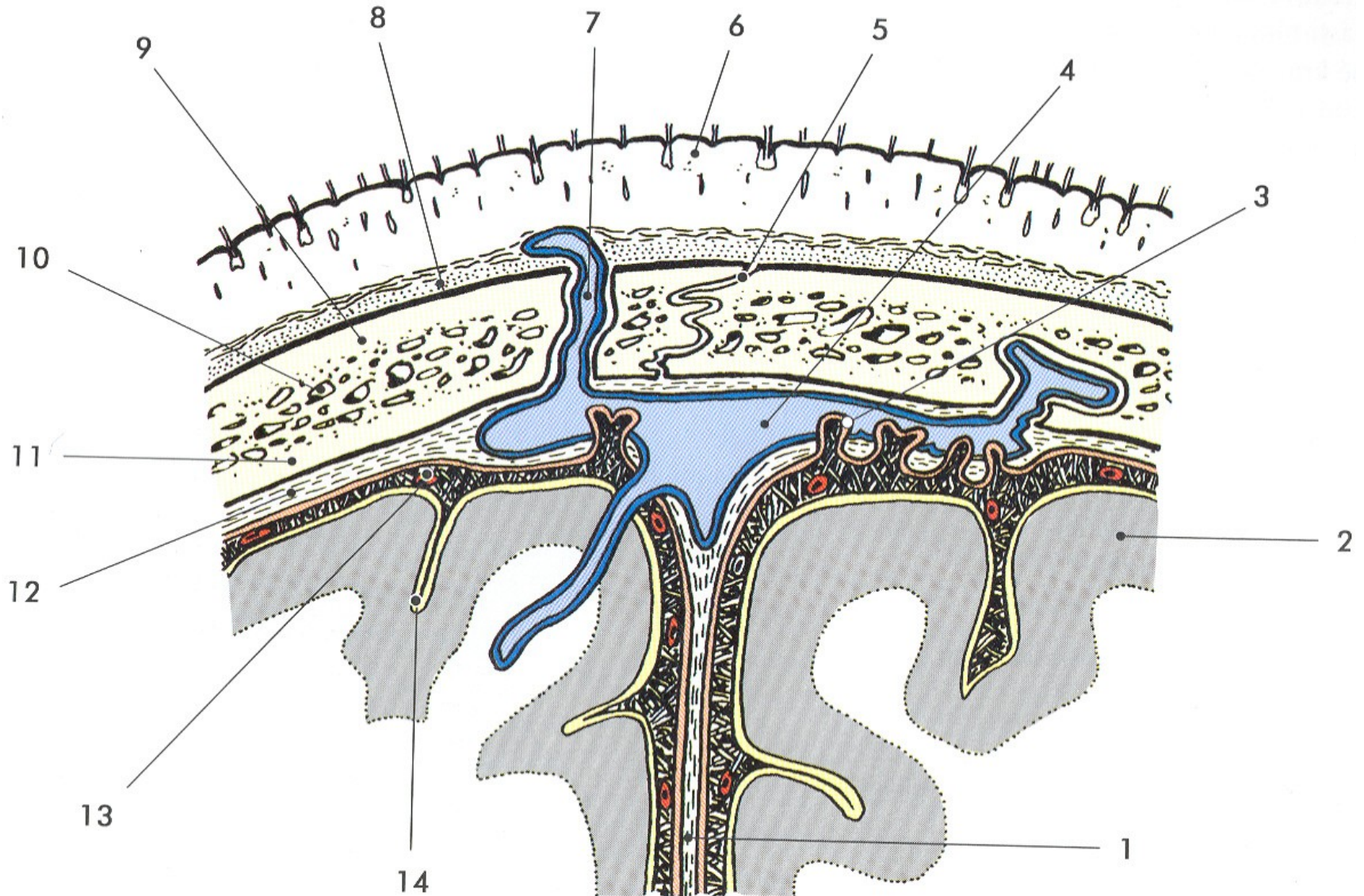


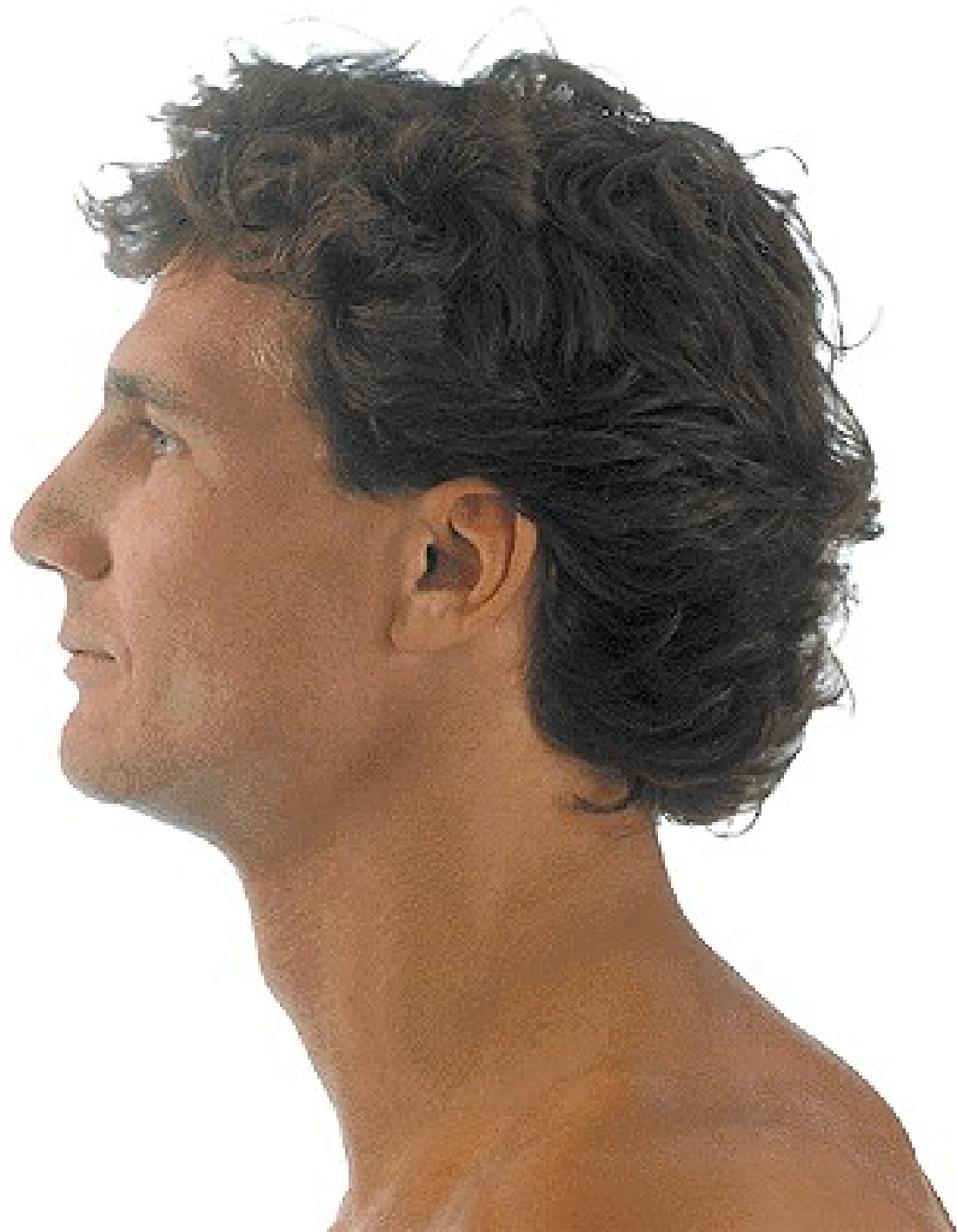


# **CALVARIA**

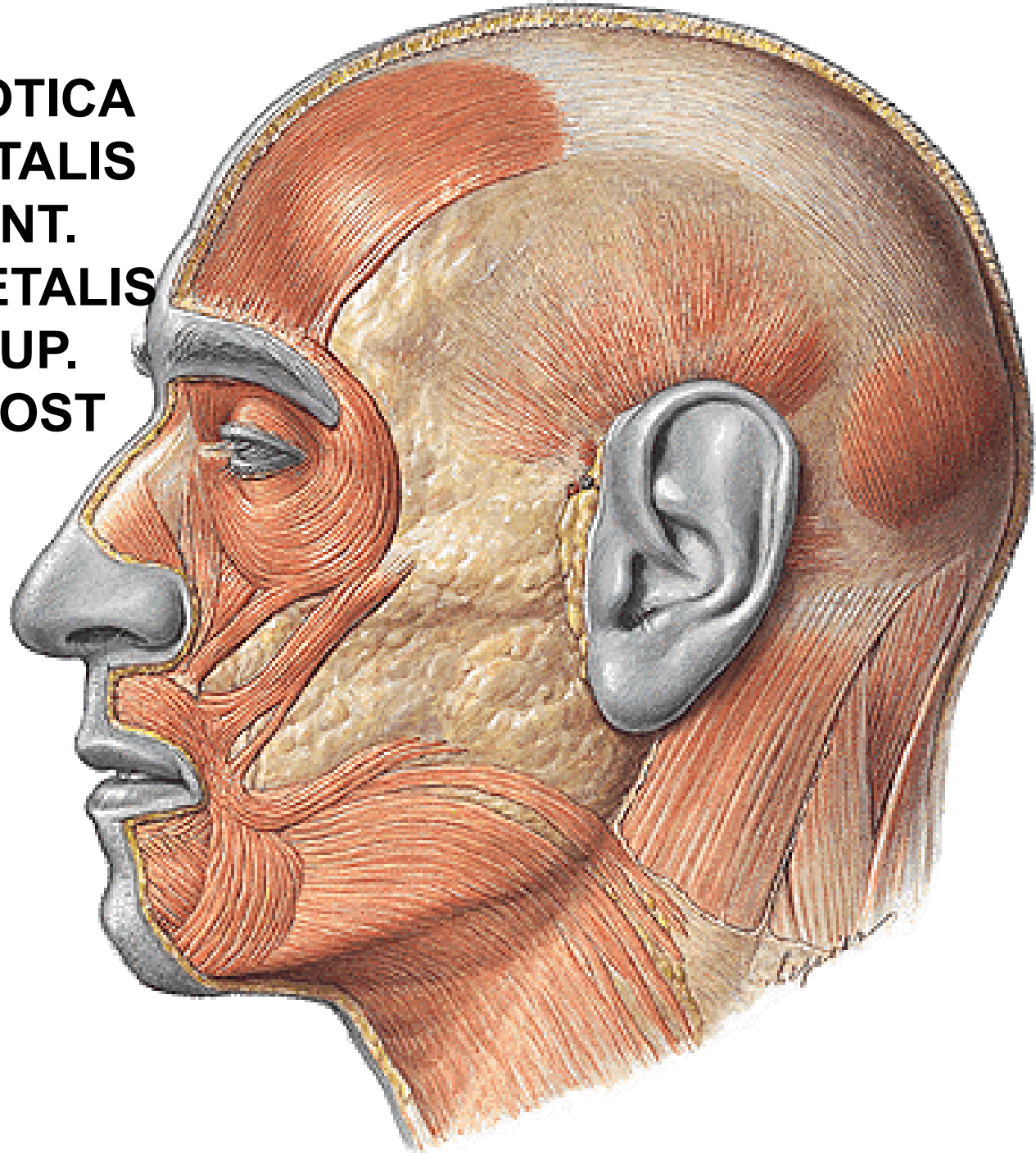
**Regio frontalis, parietalis,  
occipitalis, temporalis**

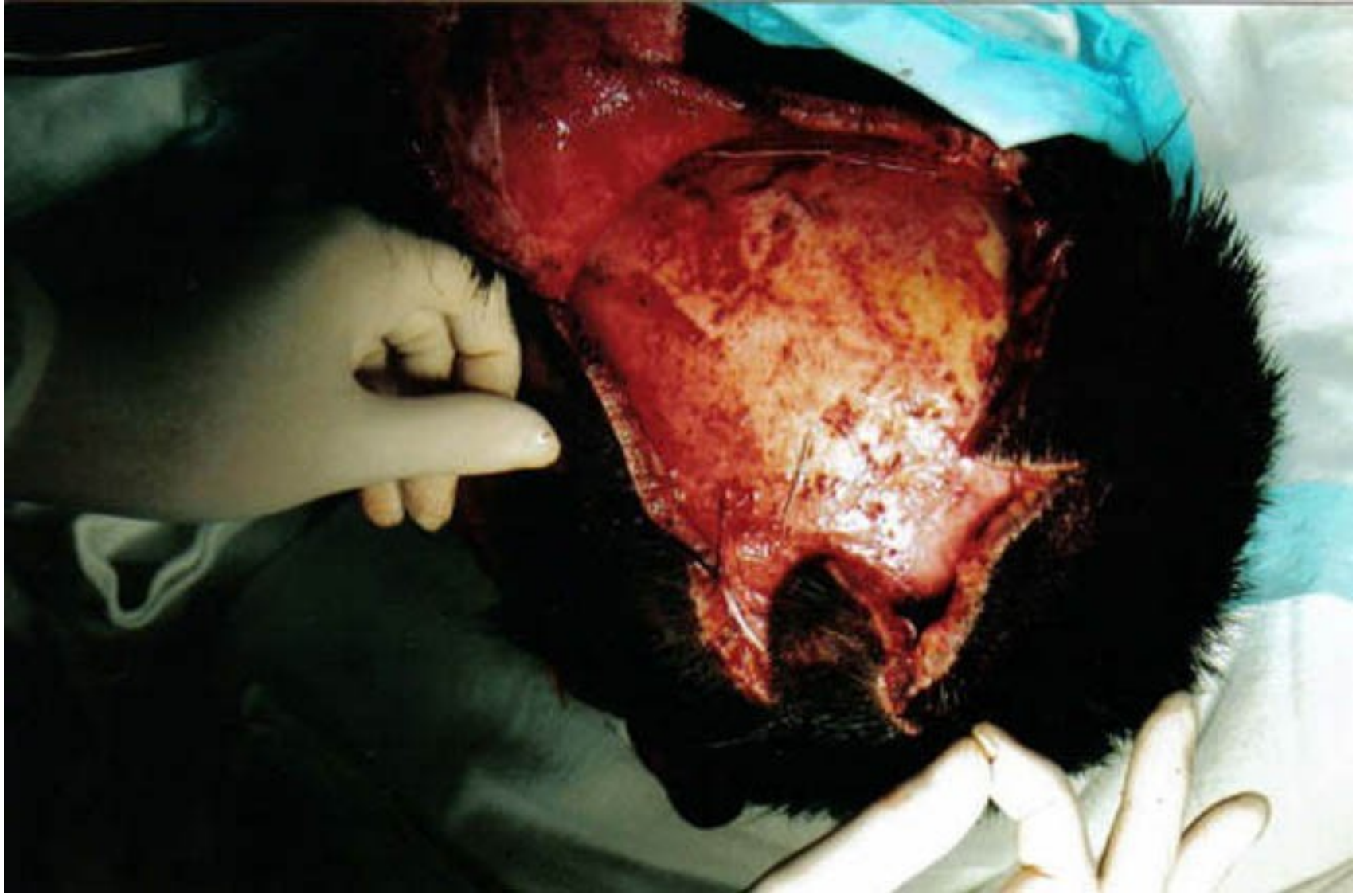# SCALP: skin, connective tissue, aponeurosis, loose connective tissue, periosteum



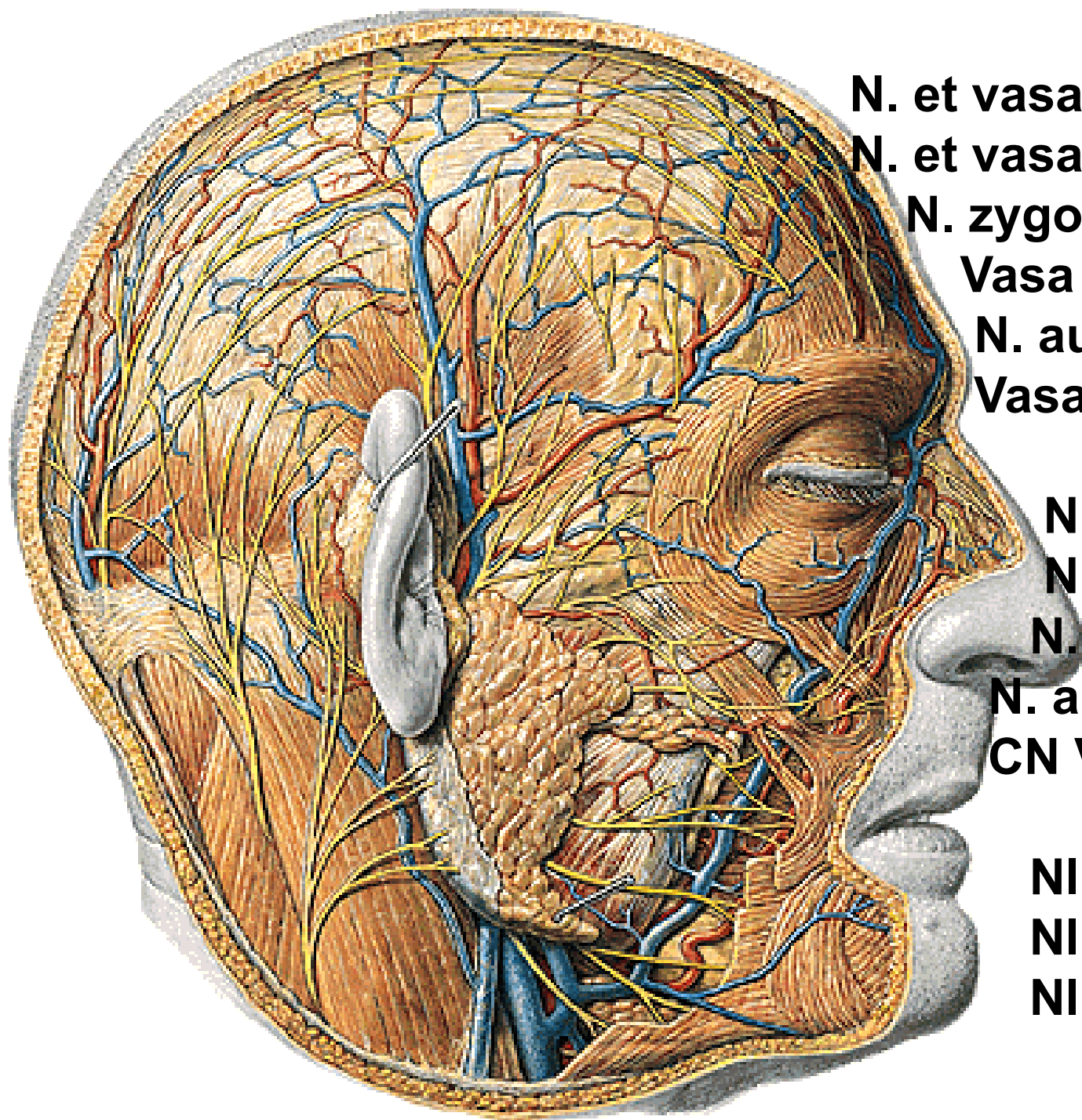


**GALEA APONEUROTICA**  
**M. OCCIPITOFRONTALIS**  
**M. AURICULARIS ANT.**  
**M. TEMPOROPARIETALIS**  
**M. AURICULARIS SUP.**  
**M. AURICULARIS POST**









**N. et vasa supraorbitalia**

**N. et vasa supratrochlearia**

**N. zygomaticotemporalis**

**Vasa temporalia spf.**

**N. auriculotemporalis**

**Vasa auricularia post.**

**Vasa occipitalia**

**N. occipitalis major**

**N. occipitalis minor**

**N. occipitalis tertius**

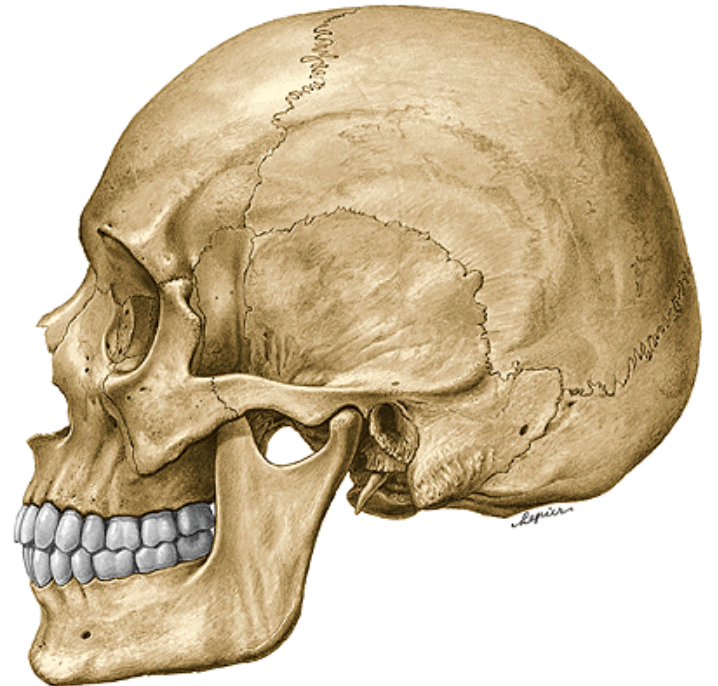
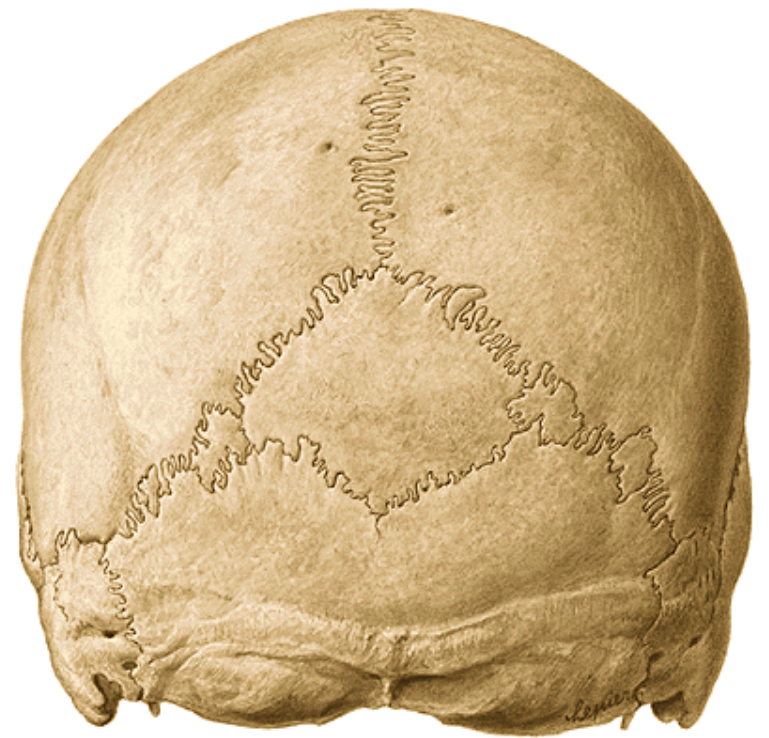**N. auricularis magnus**

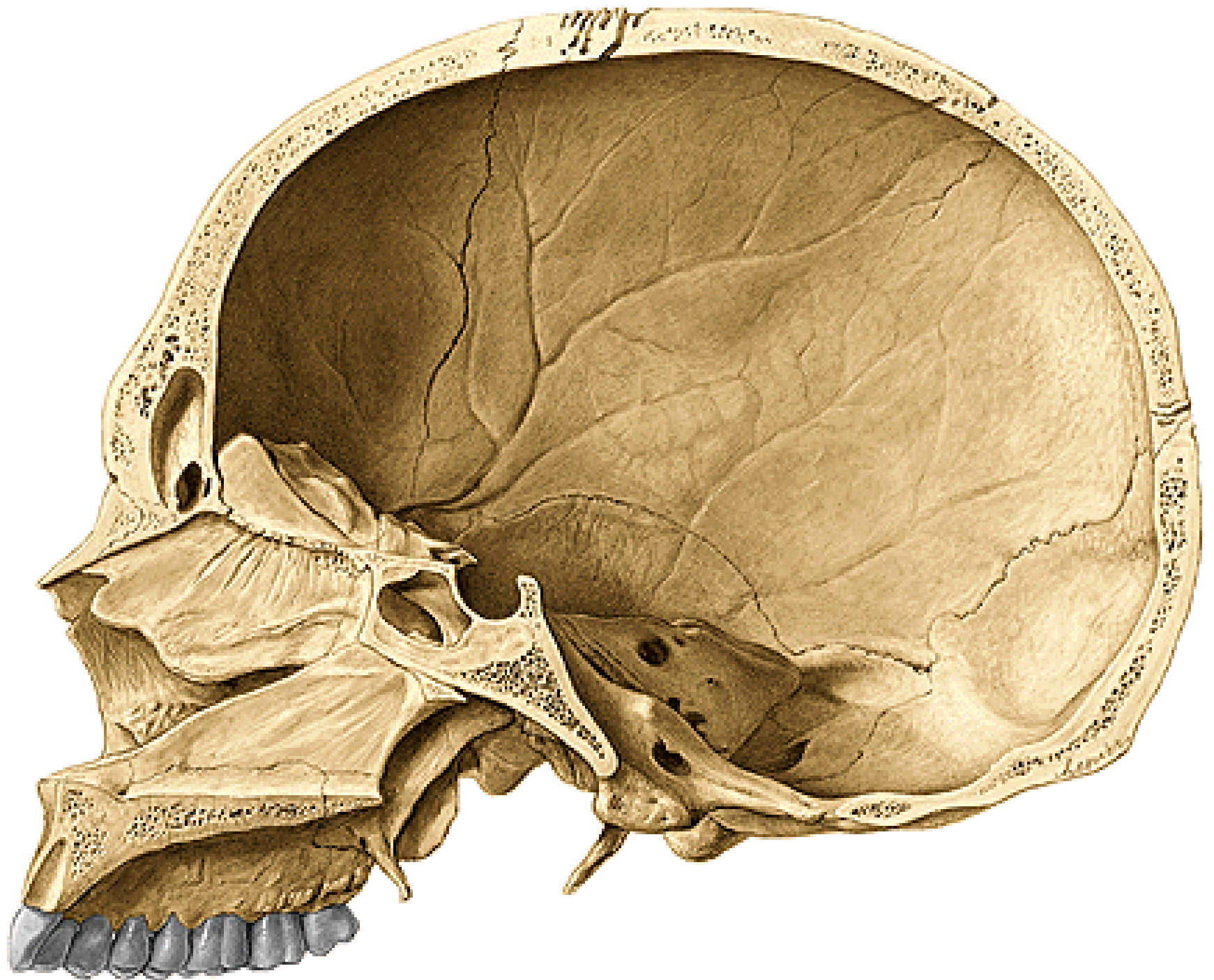
**CN VII**

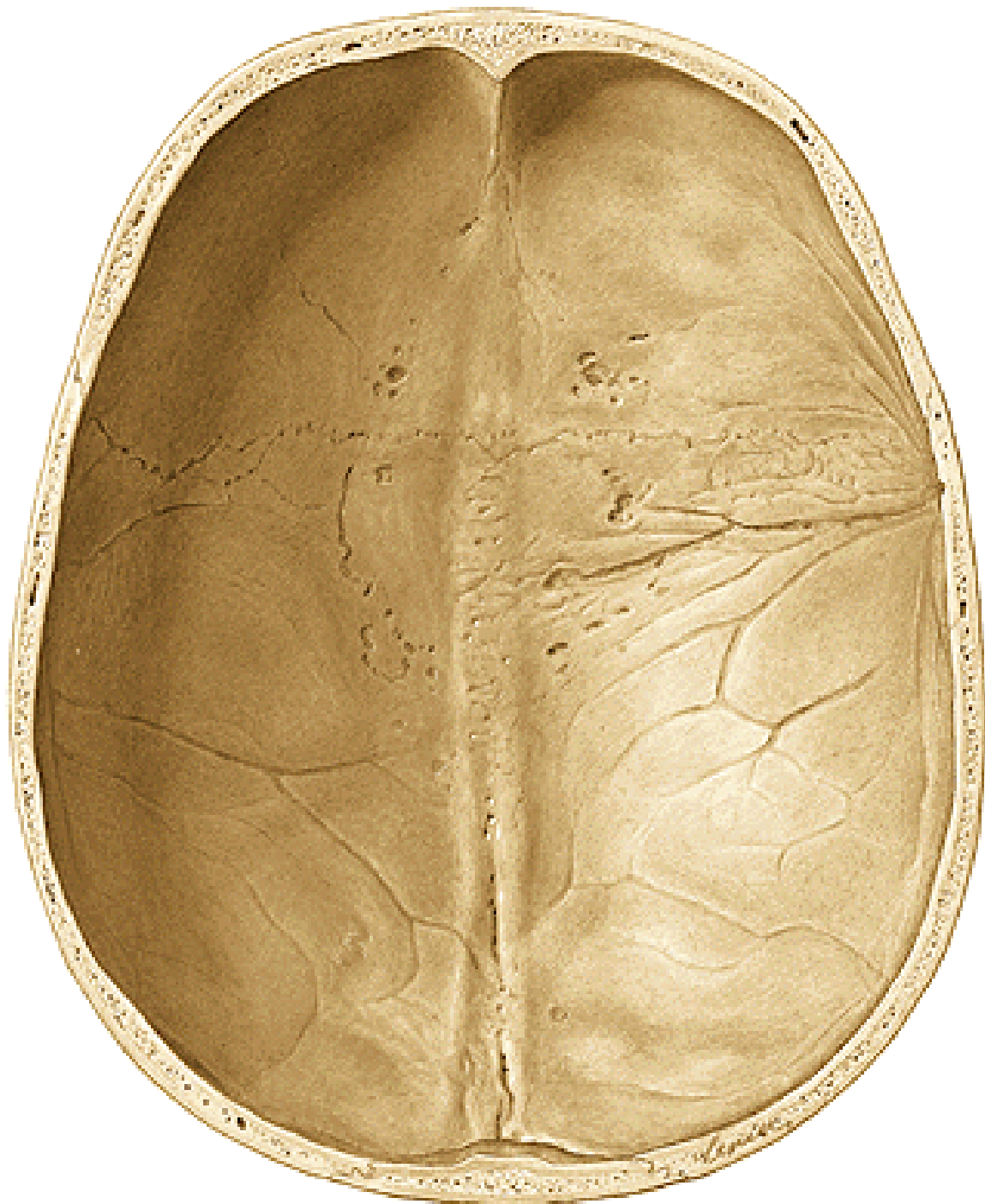**Nll. parotidei**

**Nll. retroauriculares**

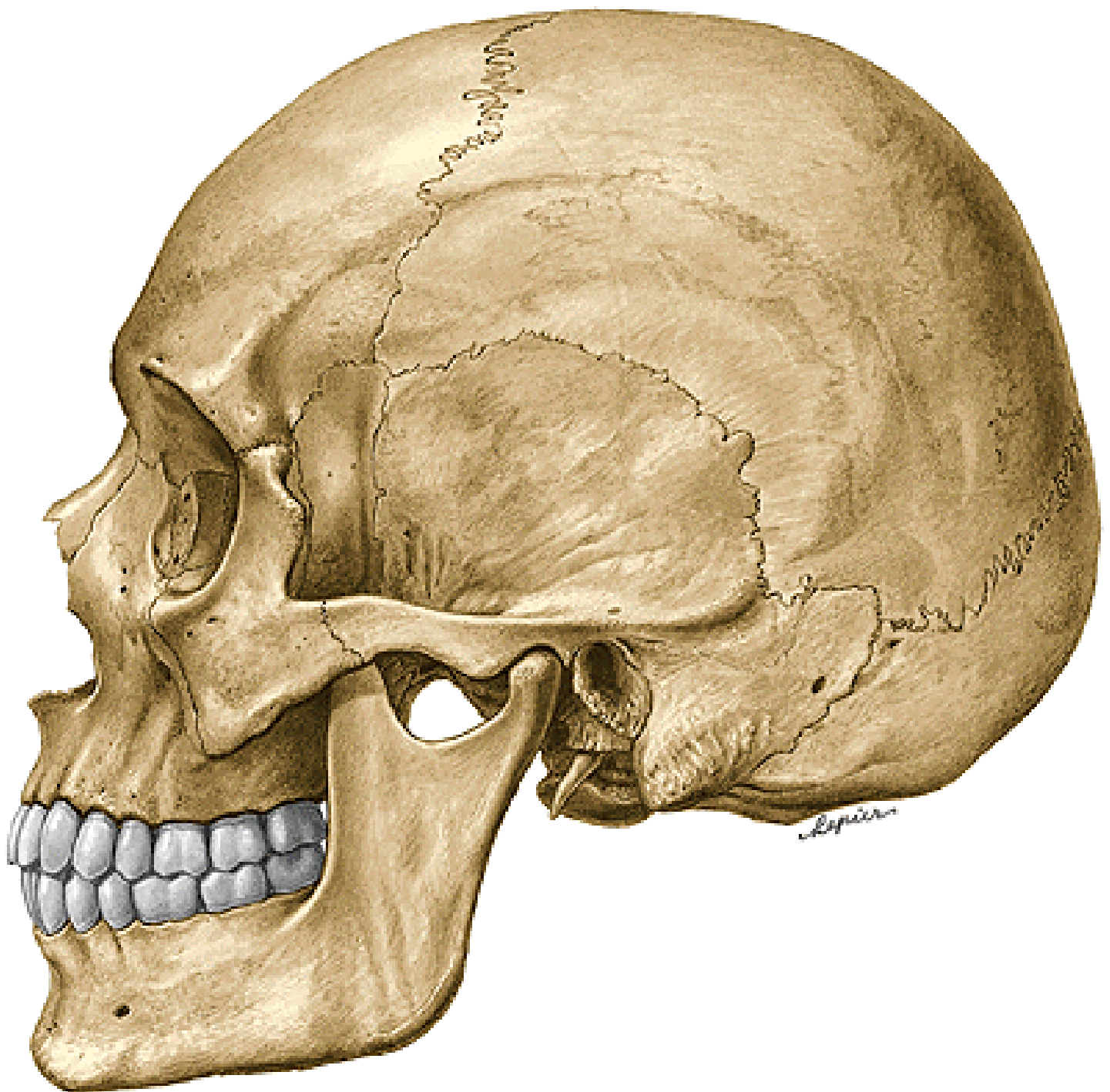
**Nll. occipitales**

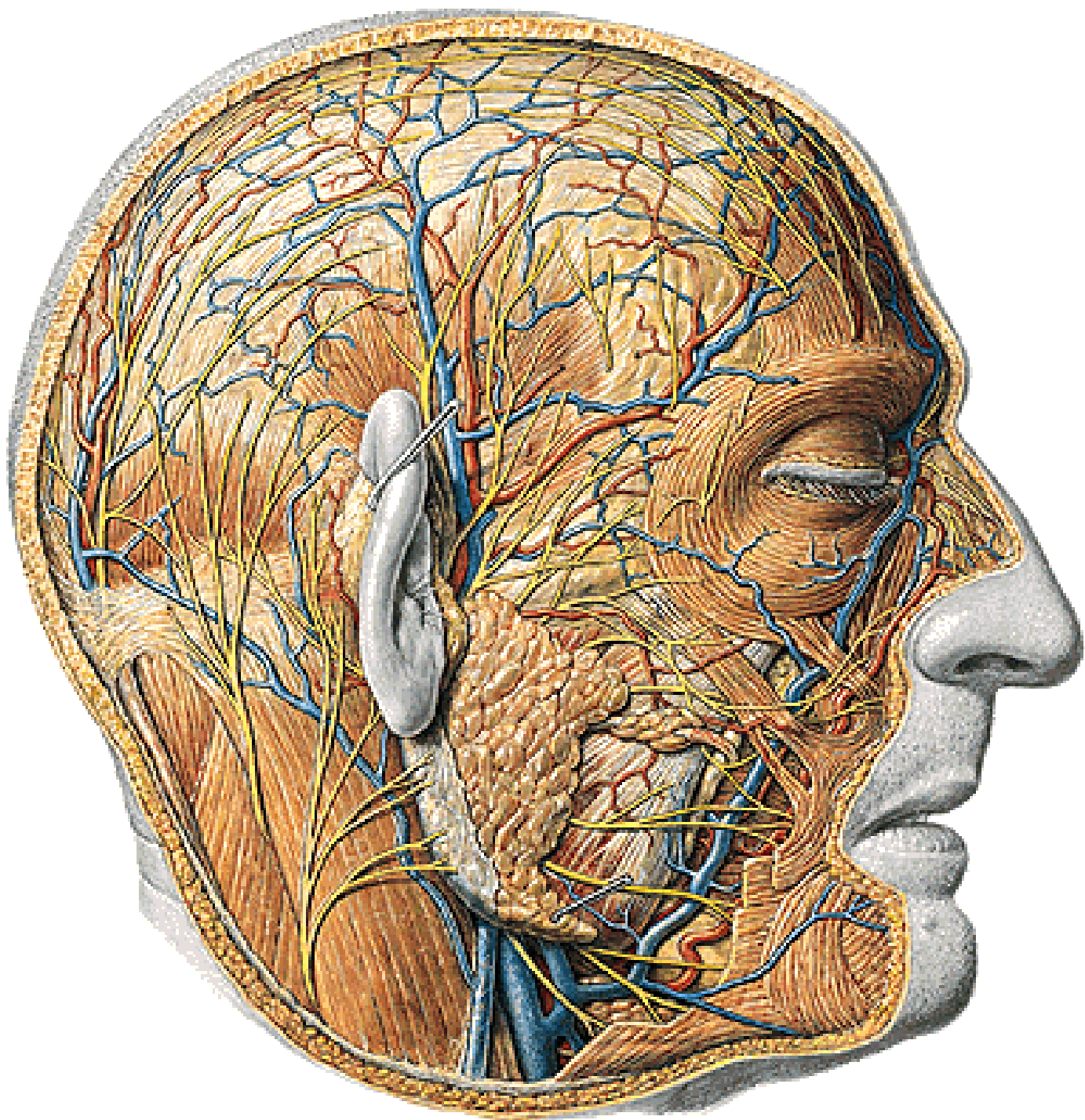


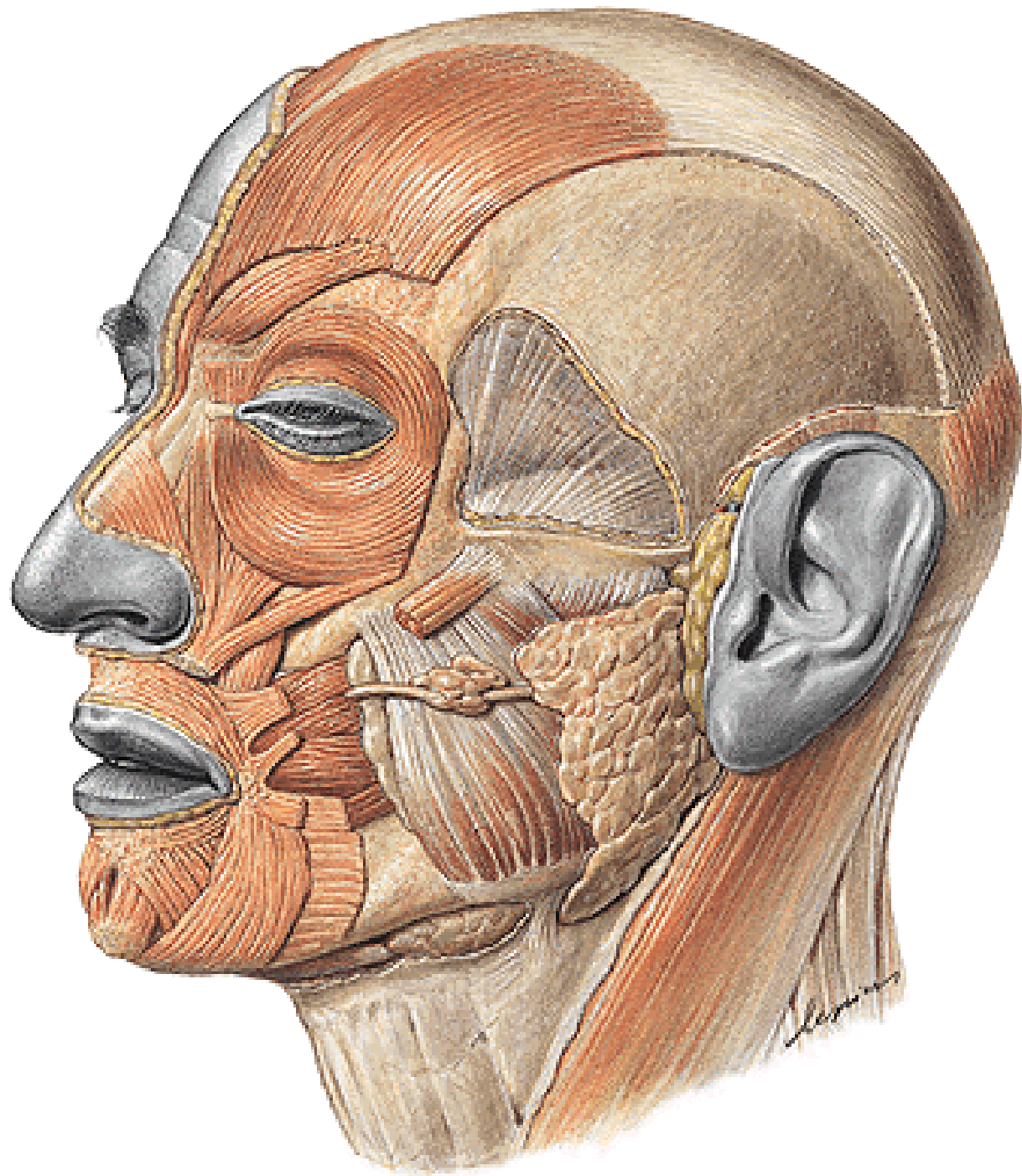




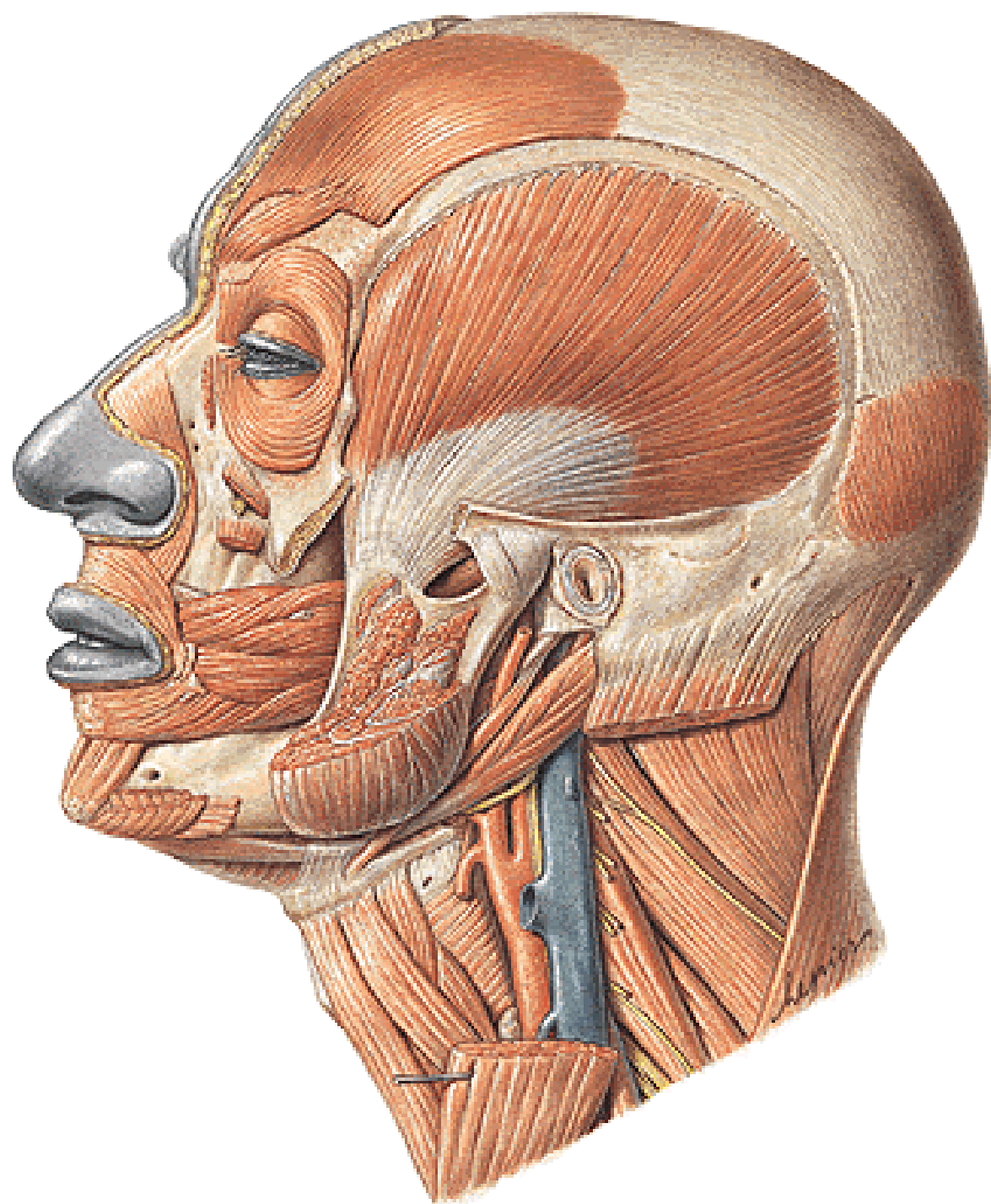


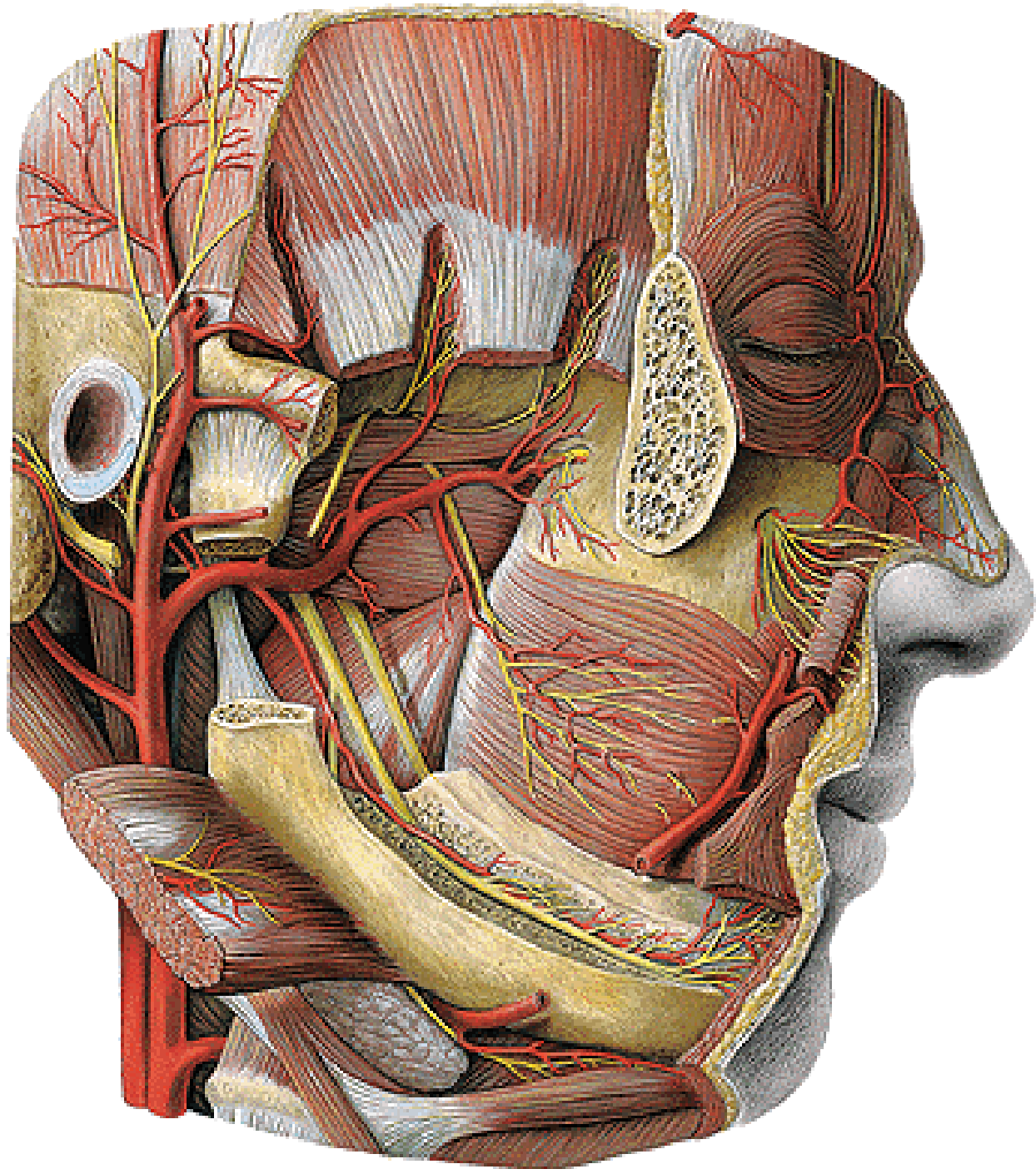


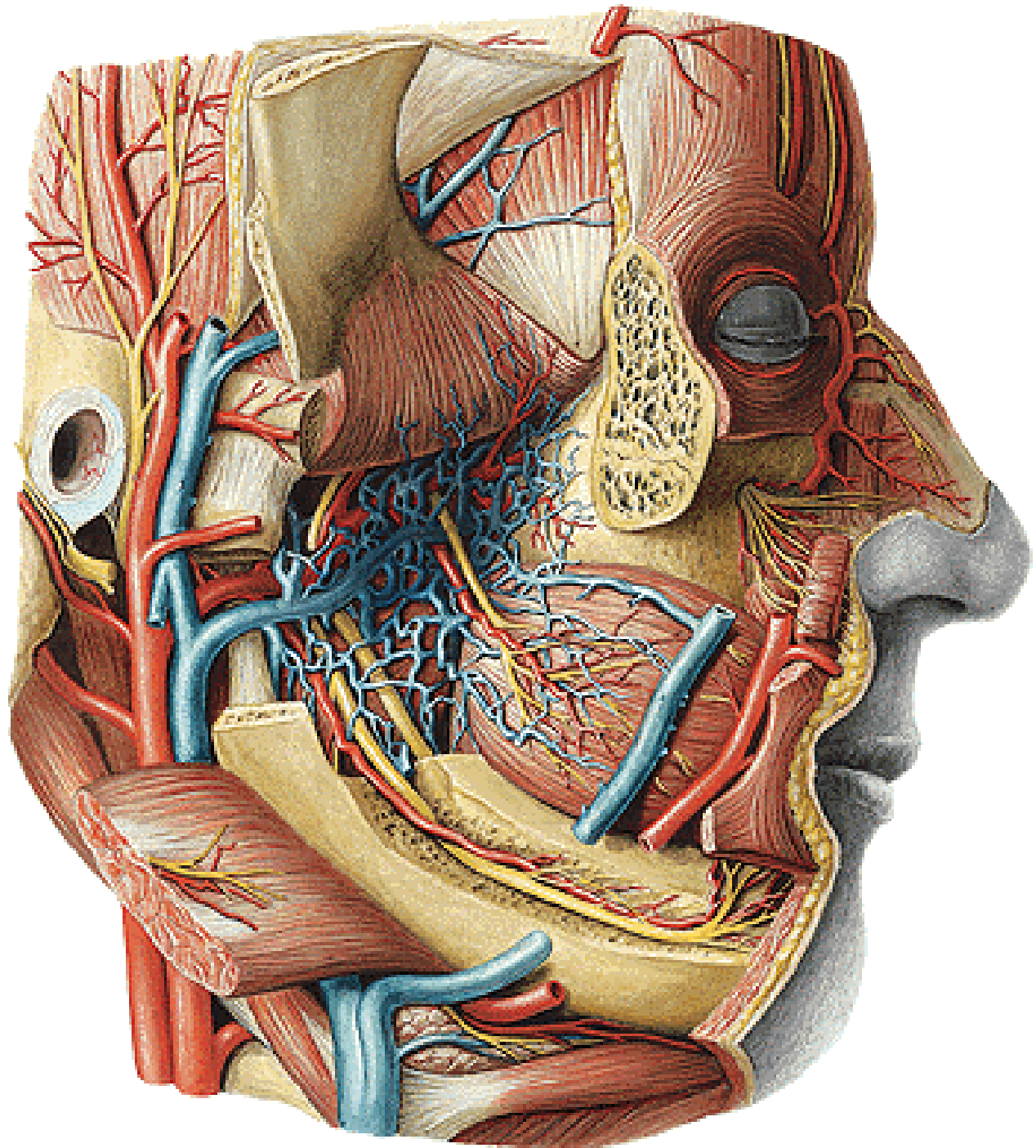












# Projection of a. meningea media (Krönlein)

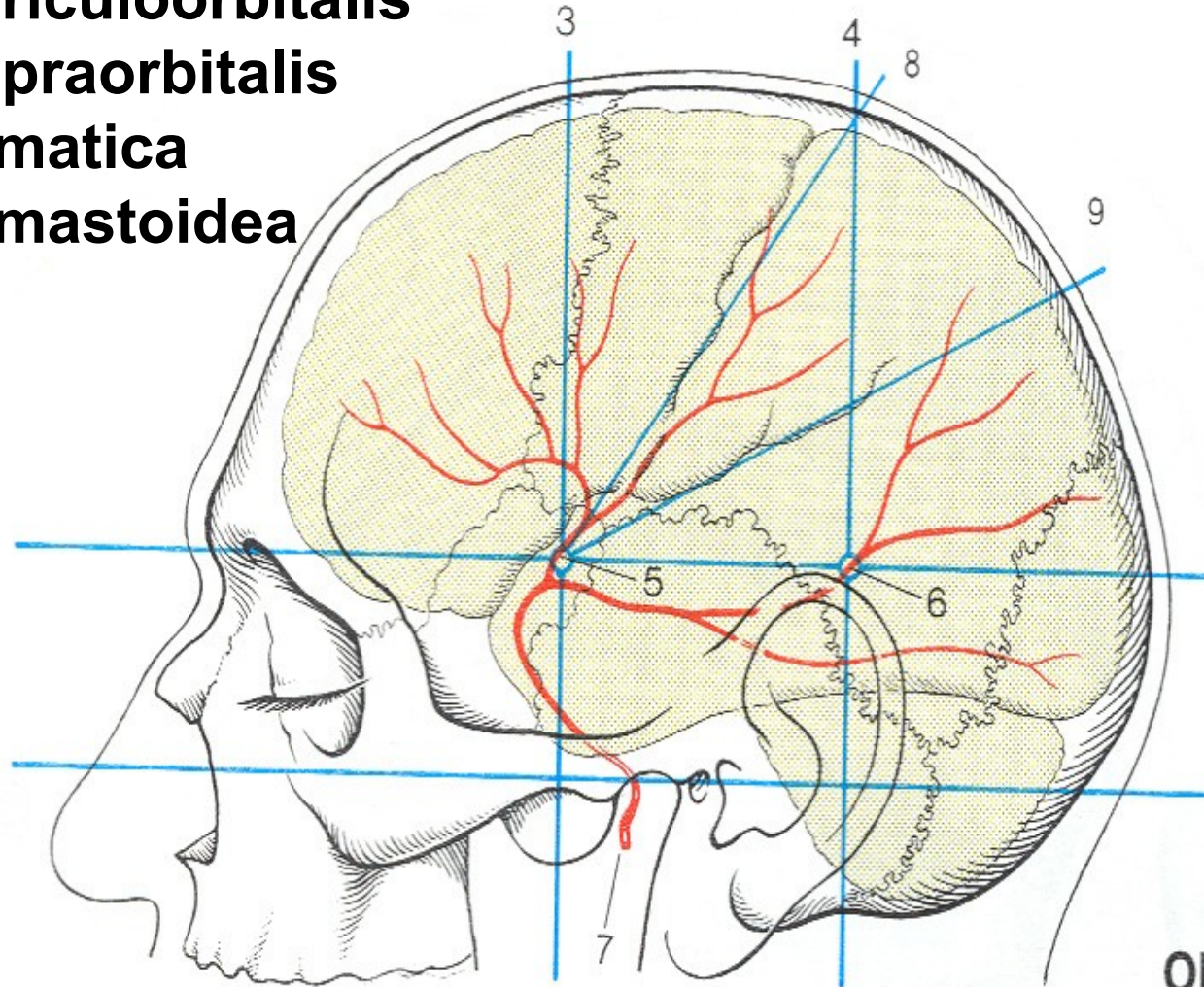
- r. frontalis
- r. parietalis

Linea horizontalis auriculoorbitalis

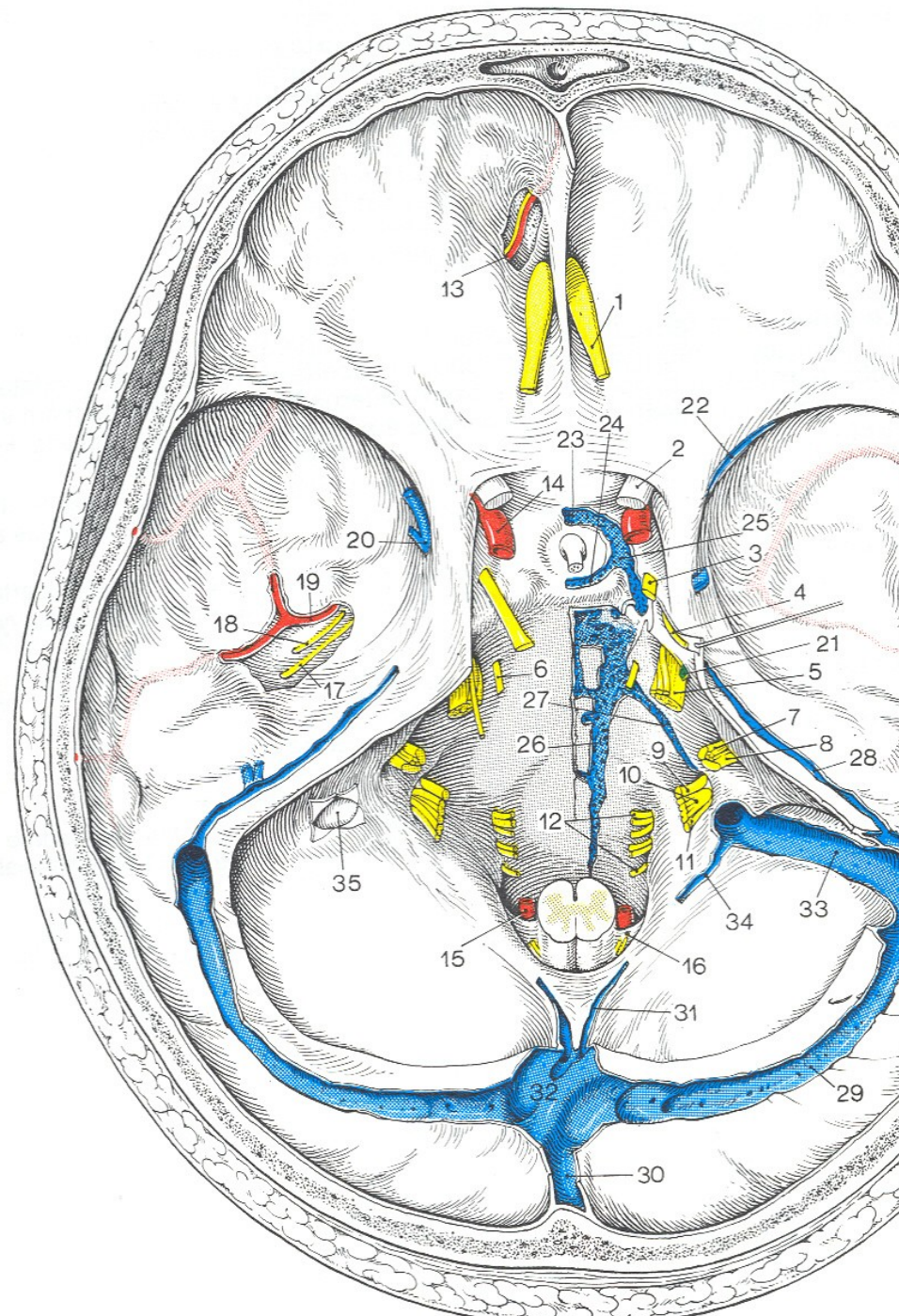
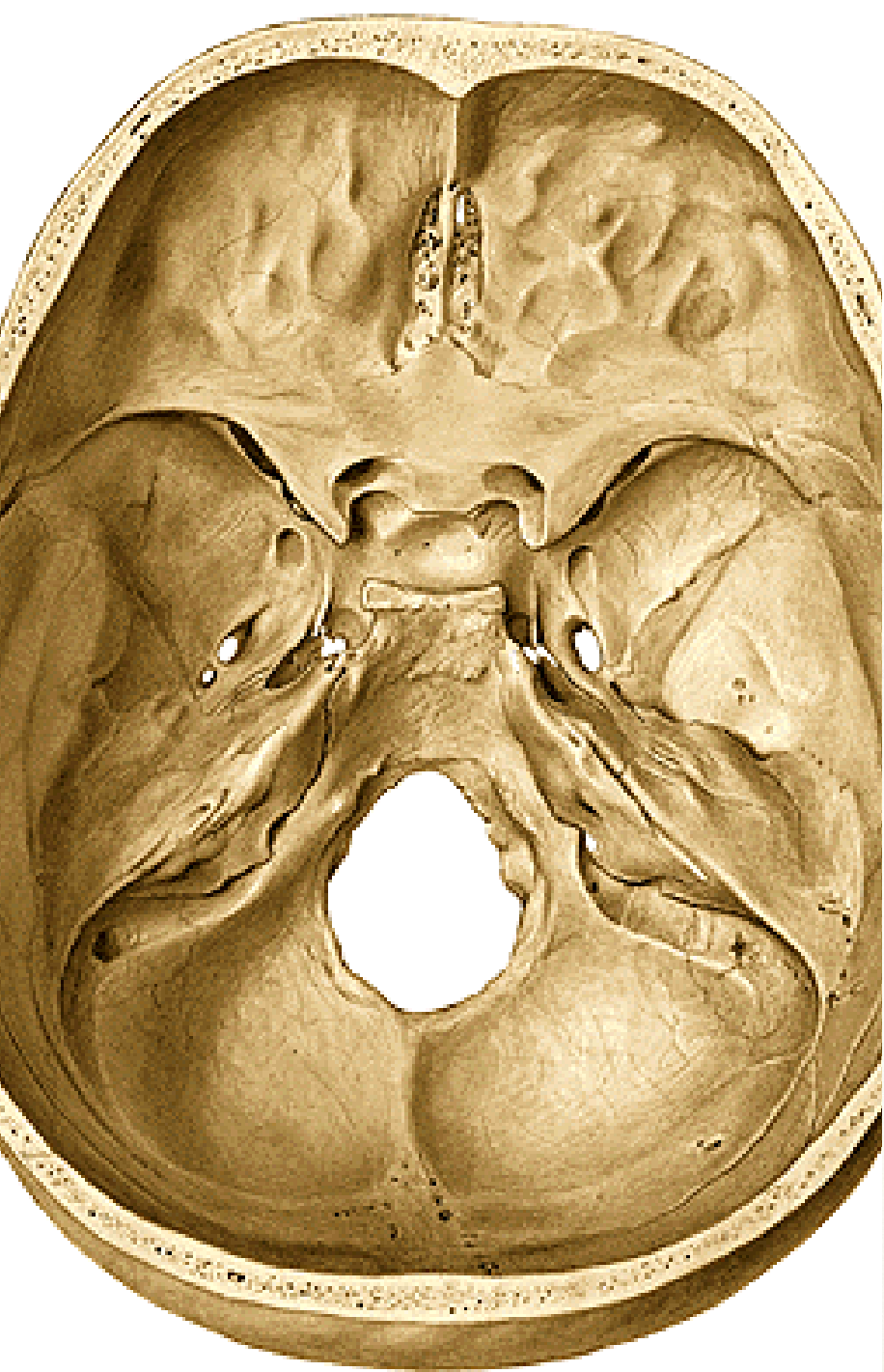
Linea horizontalis supraorbitalis

Linea verticalis zygomatica

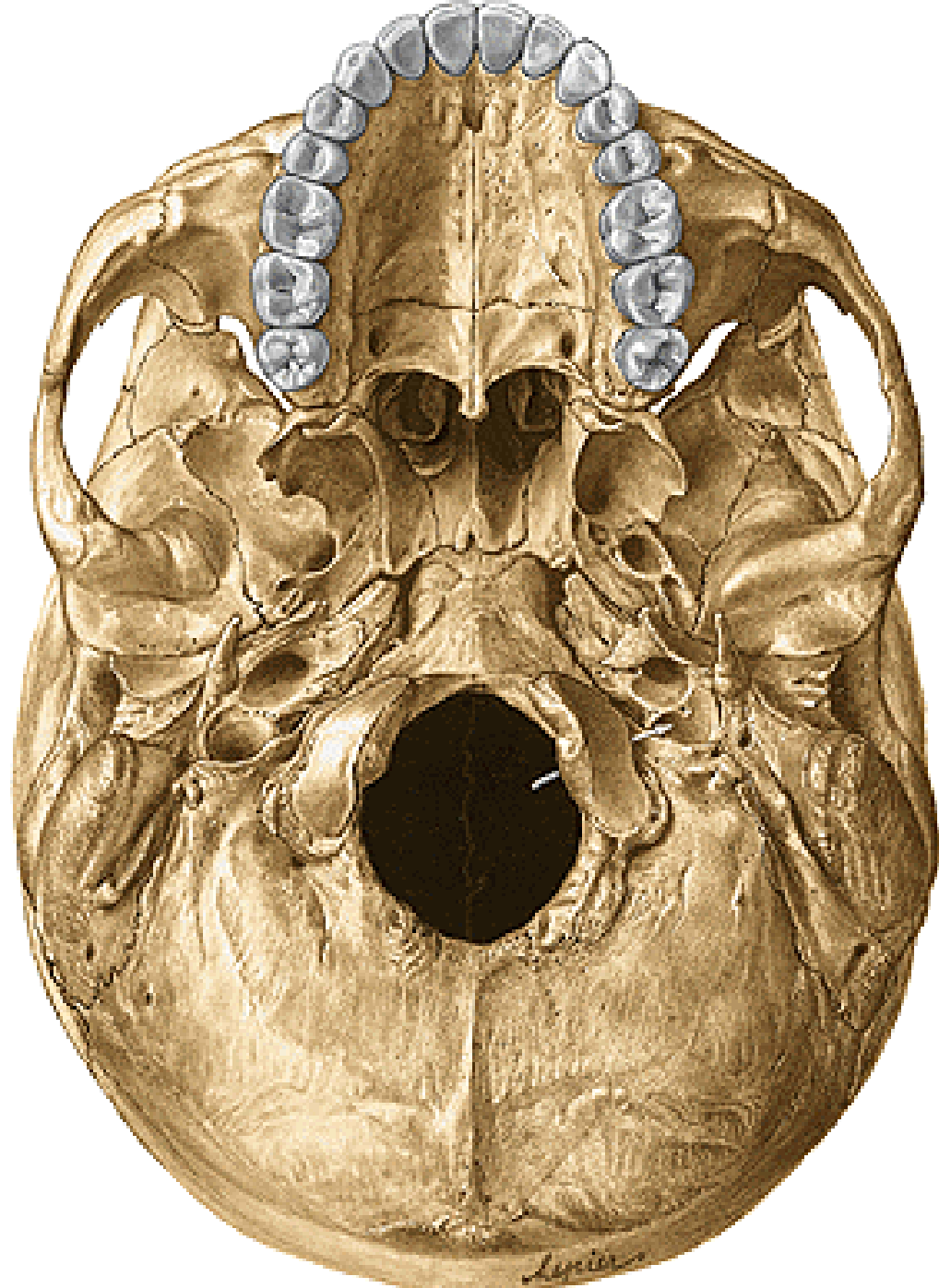Linea verticalis retromastoidea



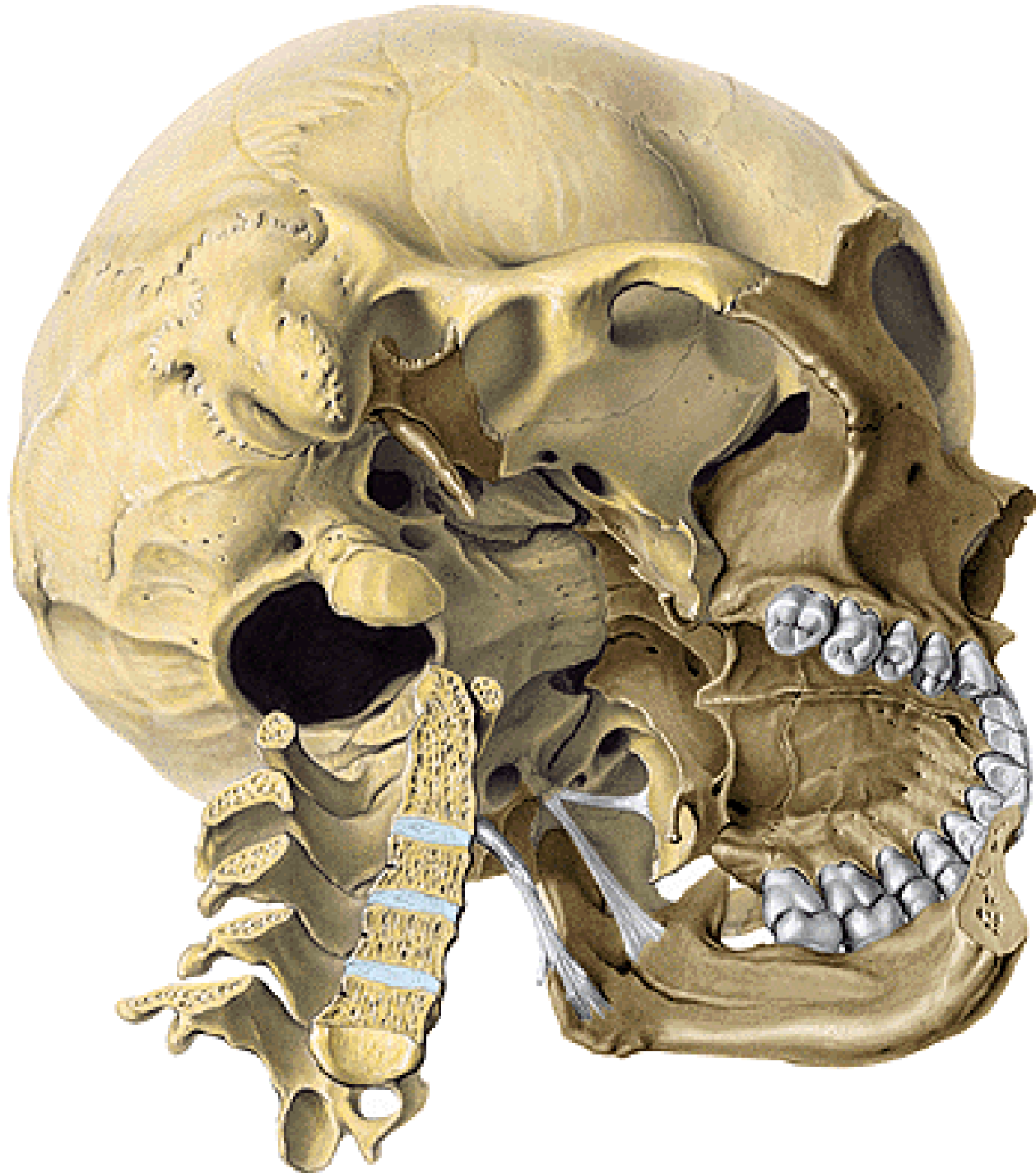**BASIS CRANII INT.**

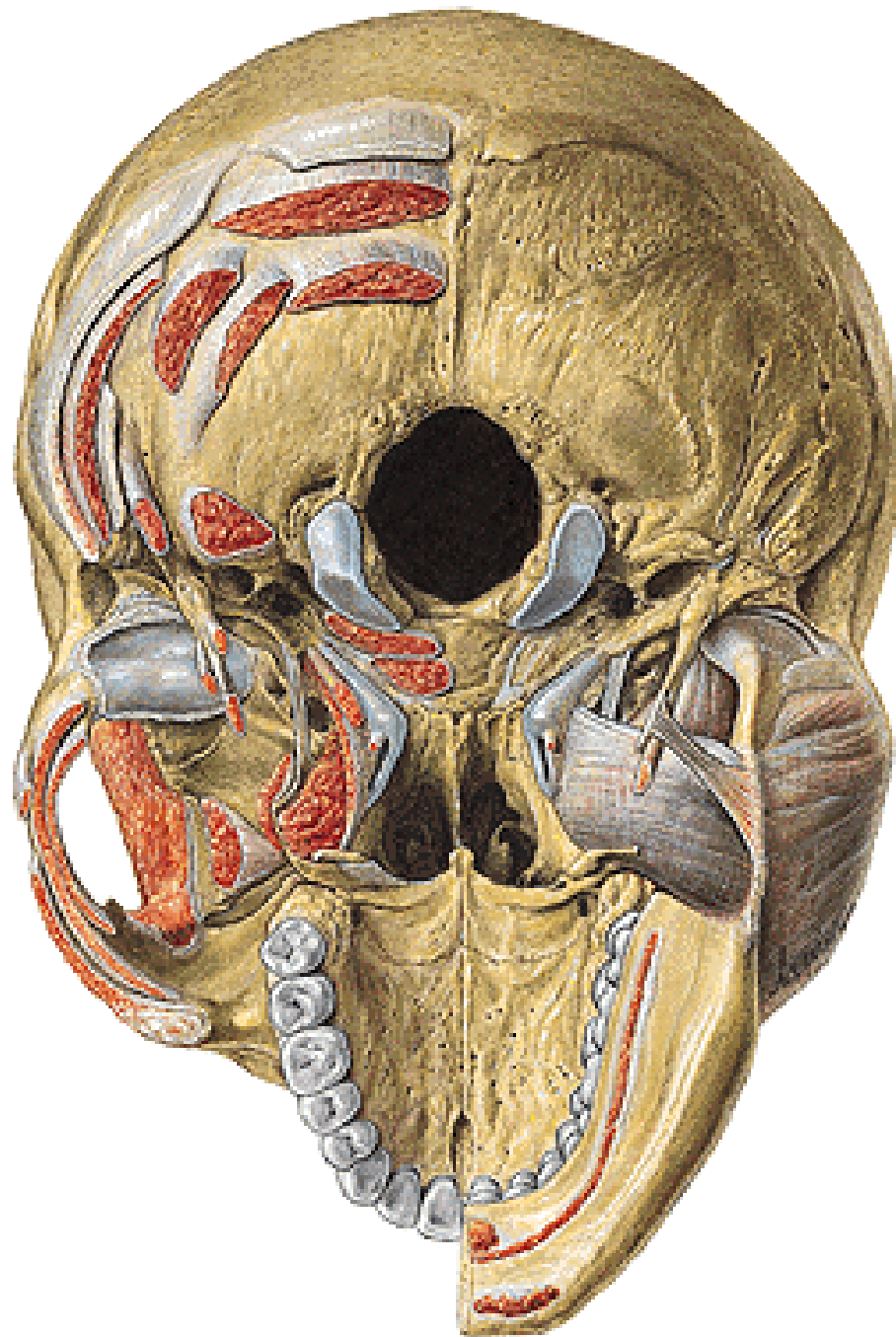


**BASIS CRANII EXT.**



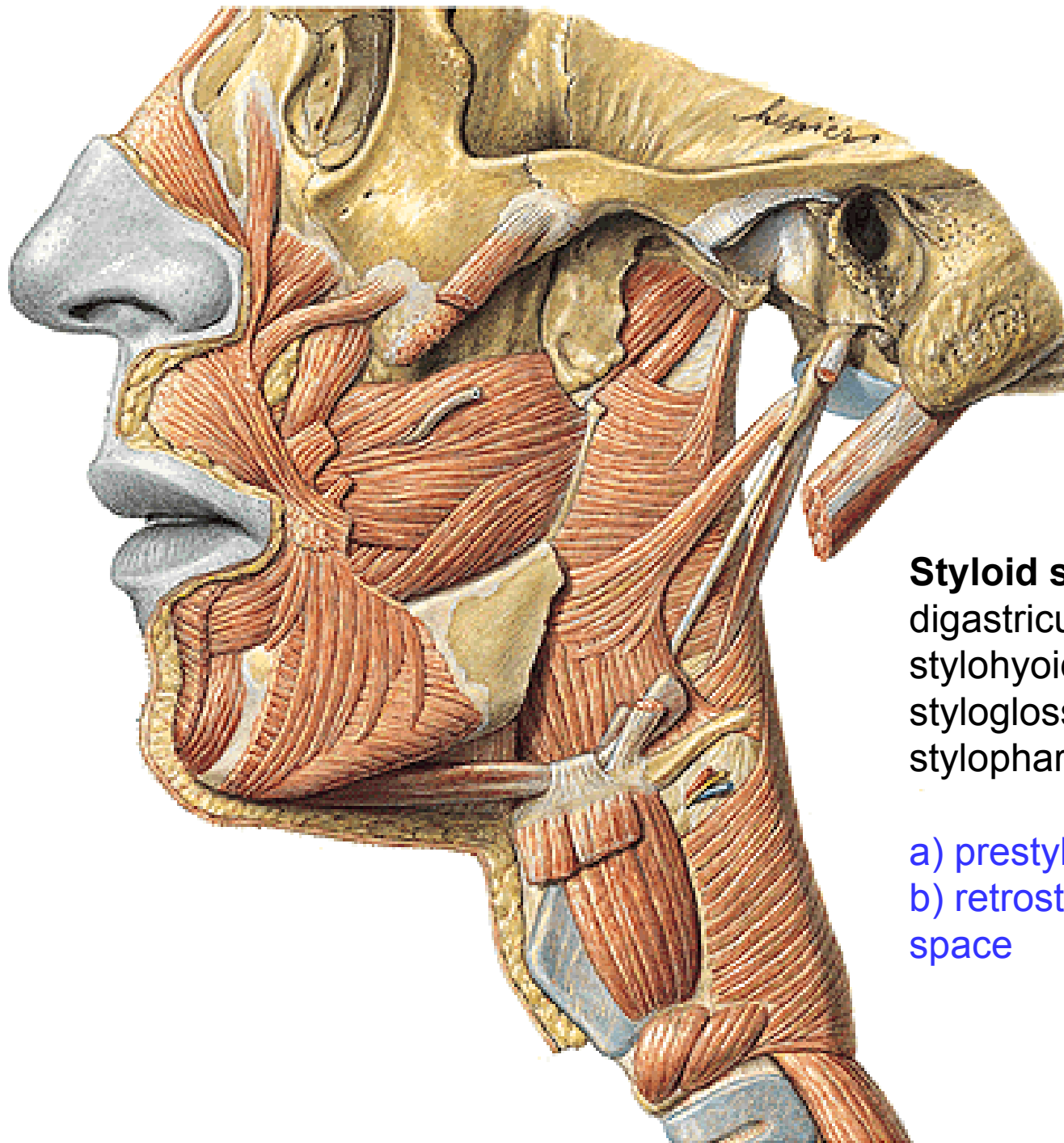






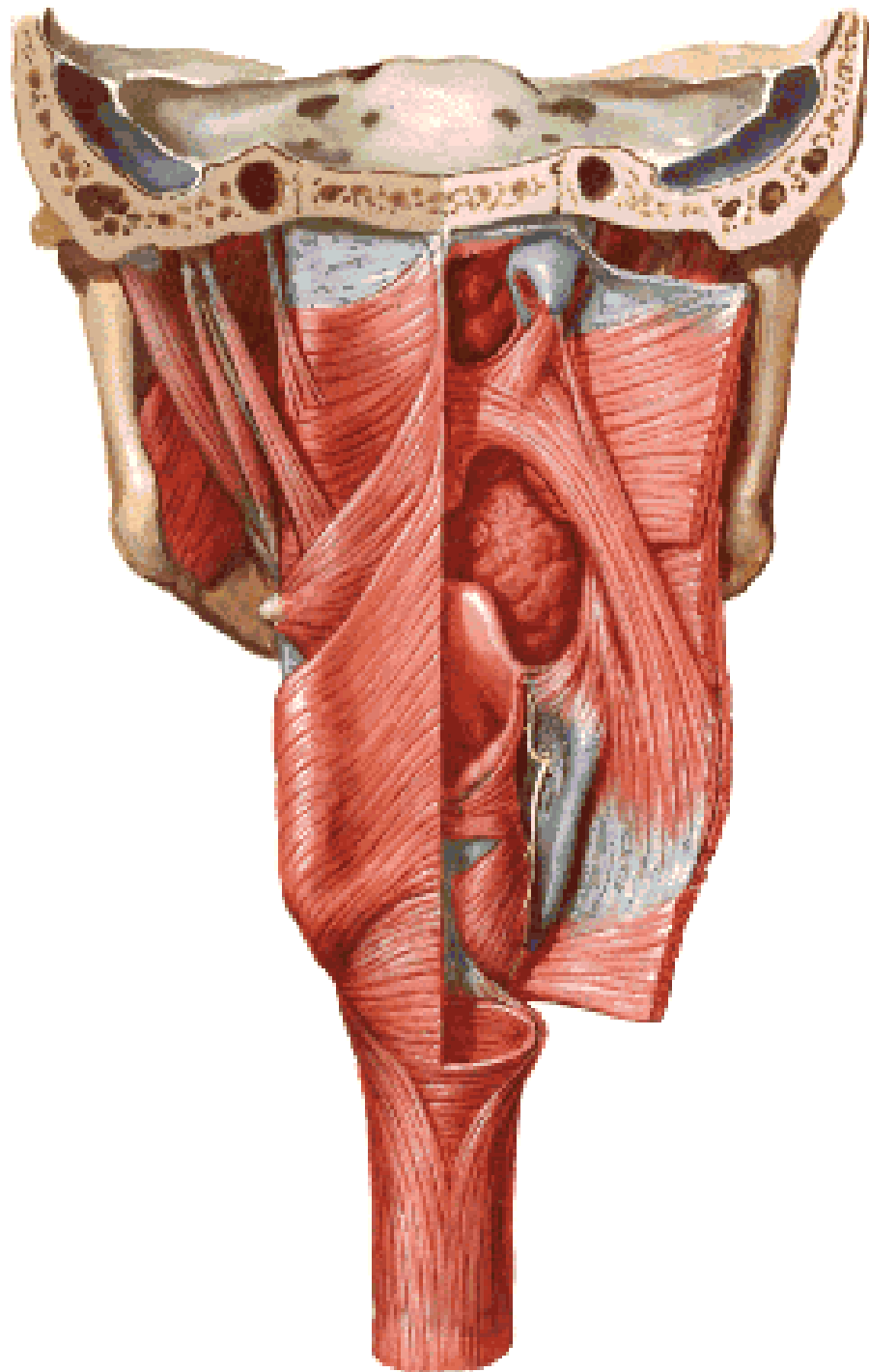
# **Regio infratemporalis**



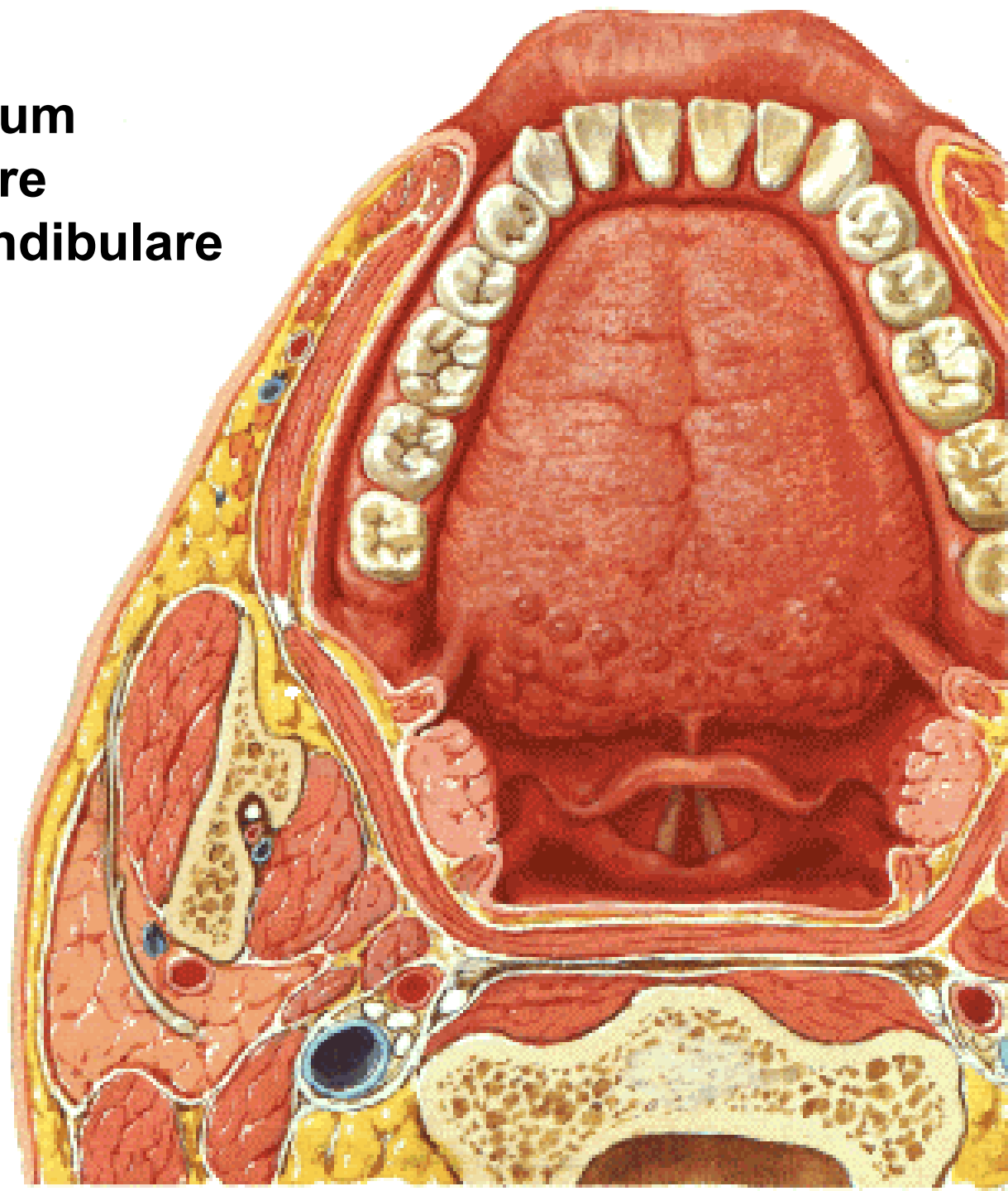


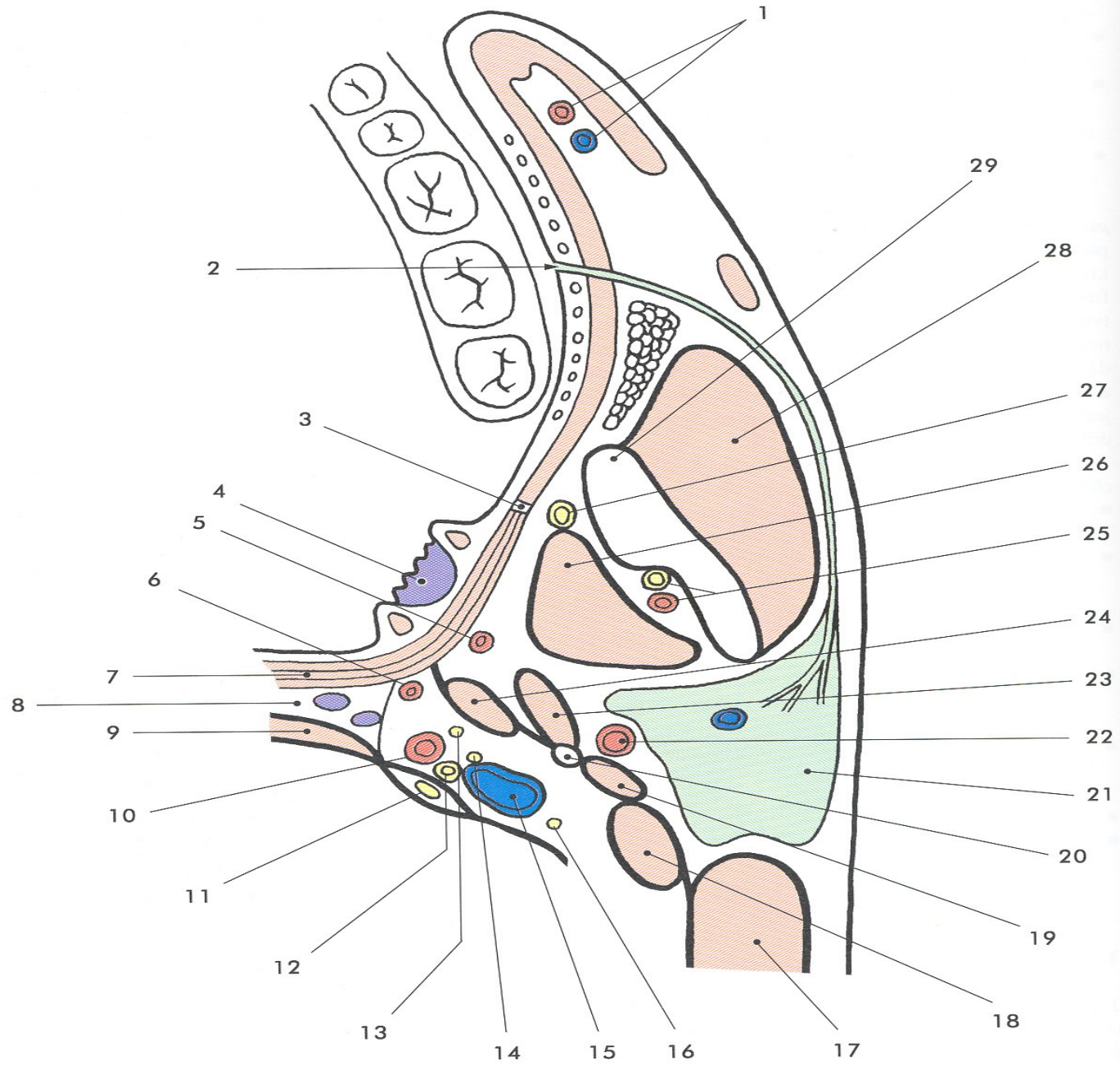
**Styloid septum:**  
digastricus  
stylohyoideus  
styloglossus  
stylopharyngeus

a) prestyloid space  
b) retrostyloid space

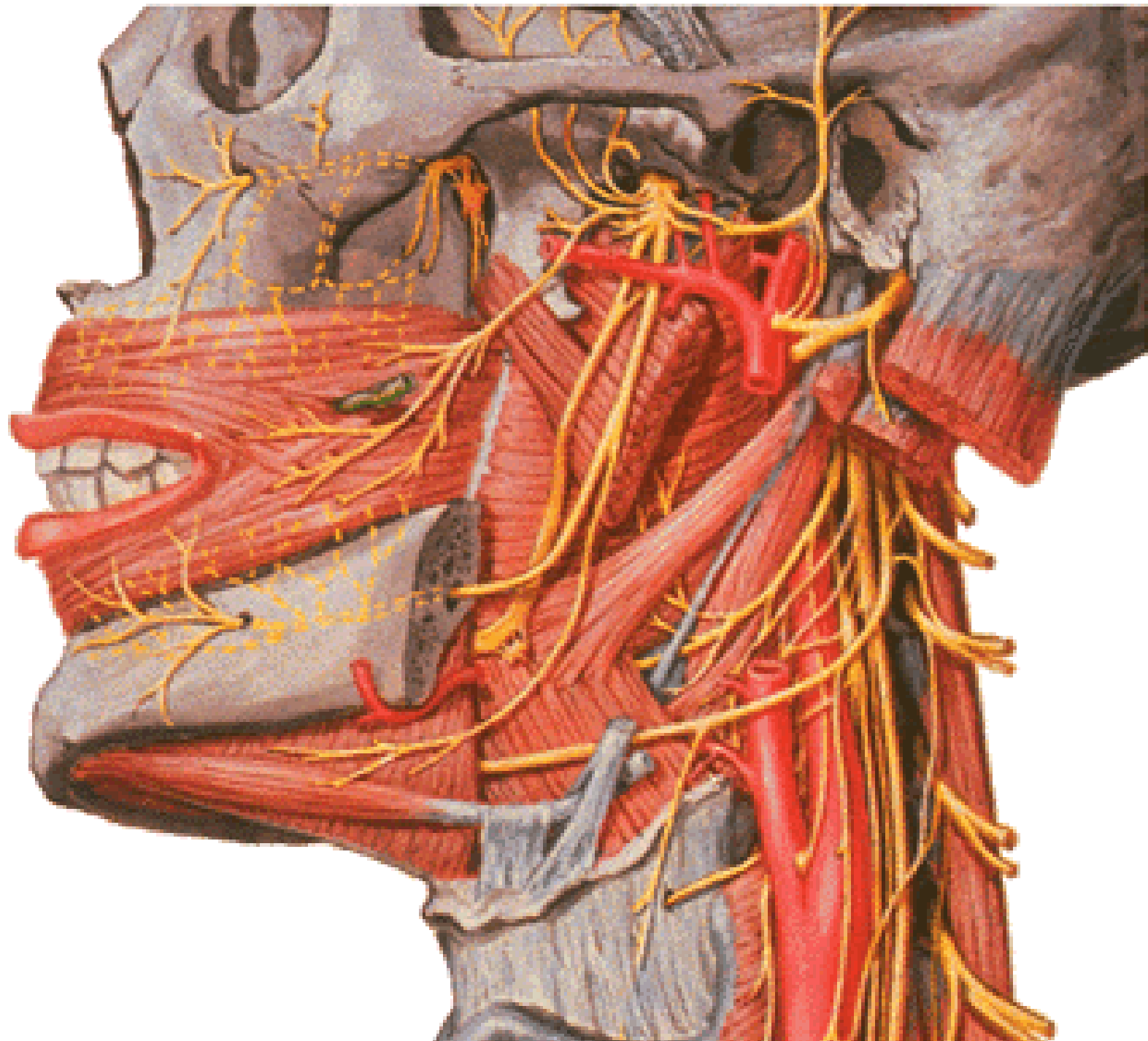


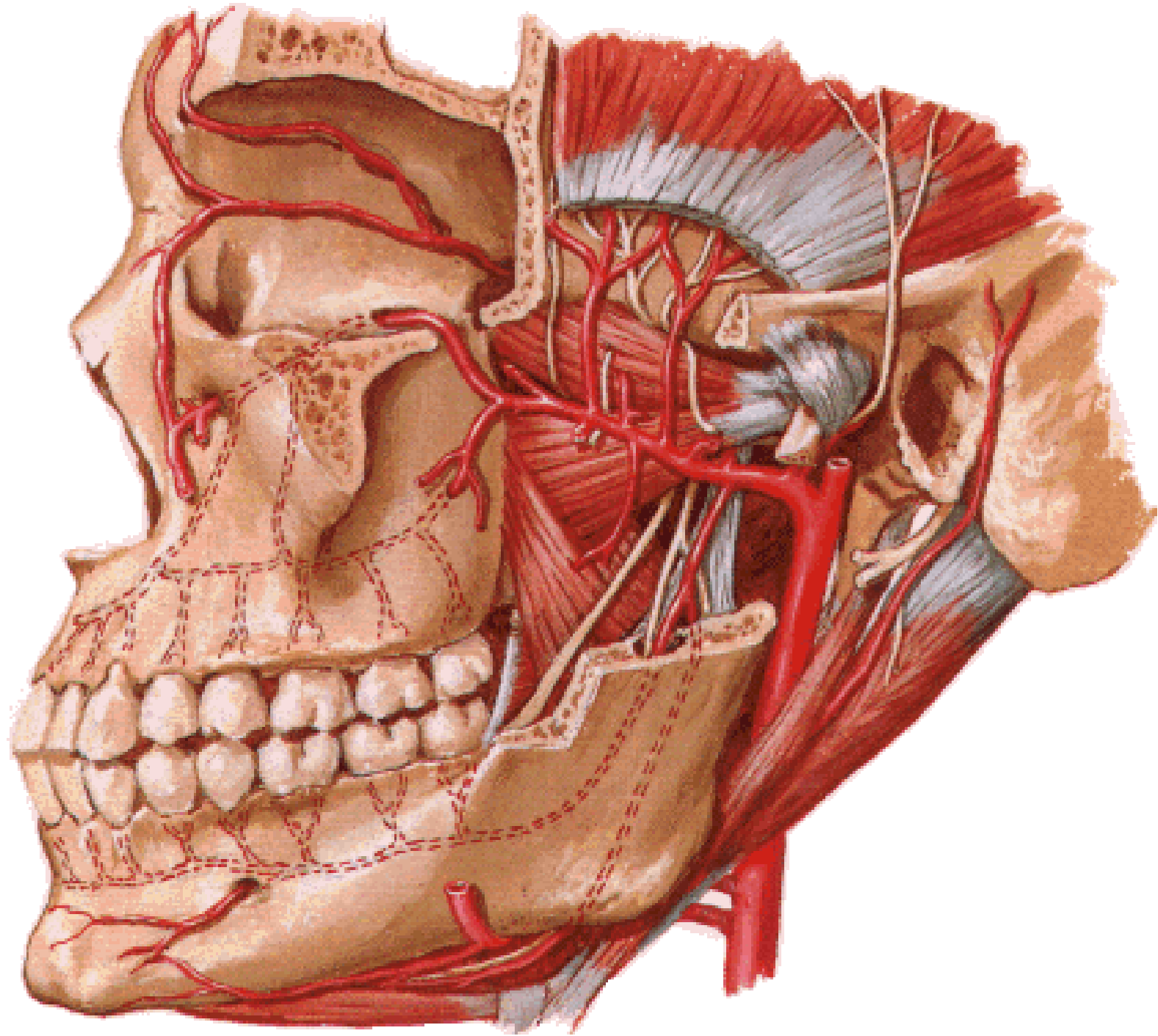
**Spatium prestyloideum**  
**Spatium paratonsilare**  
**Spatium pterygomandibulare**



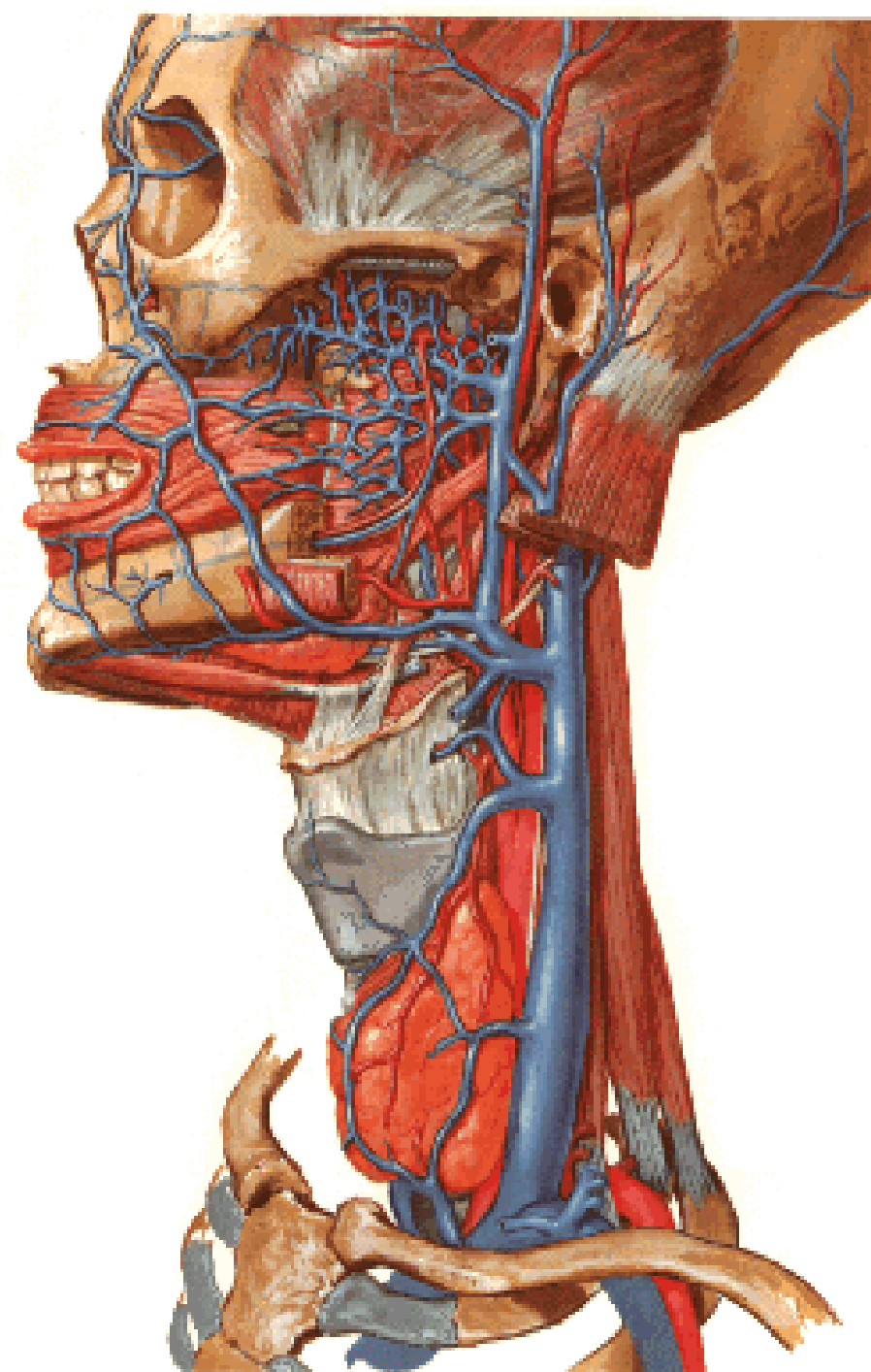


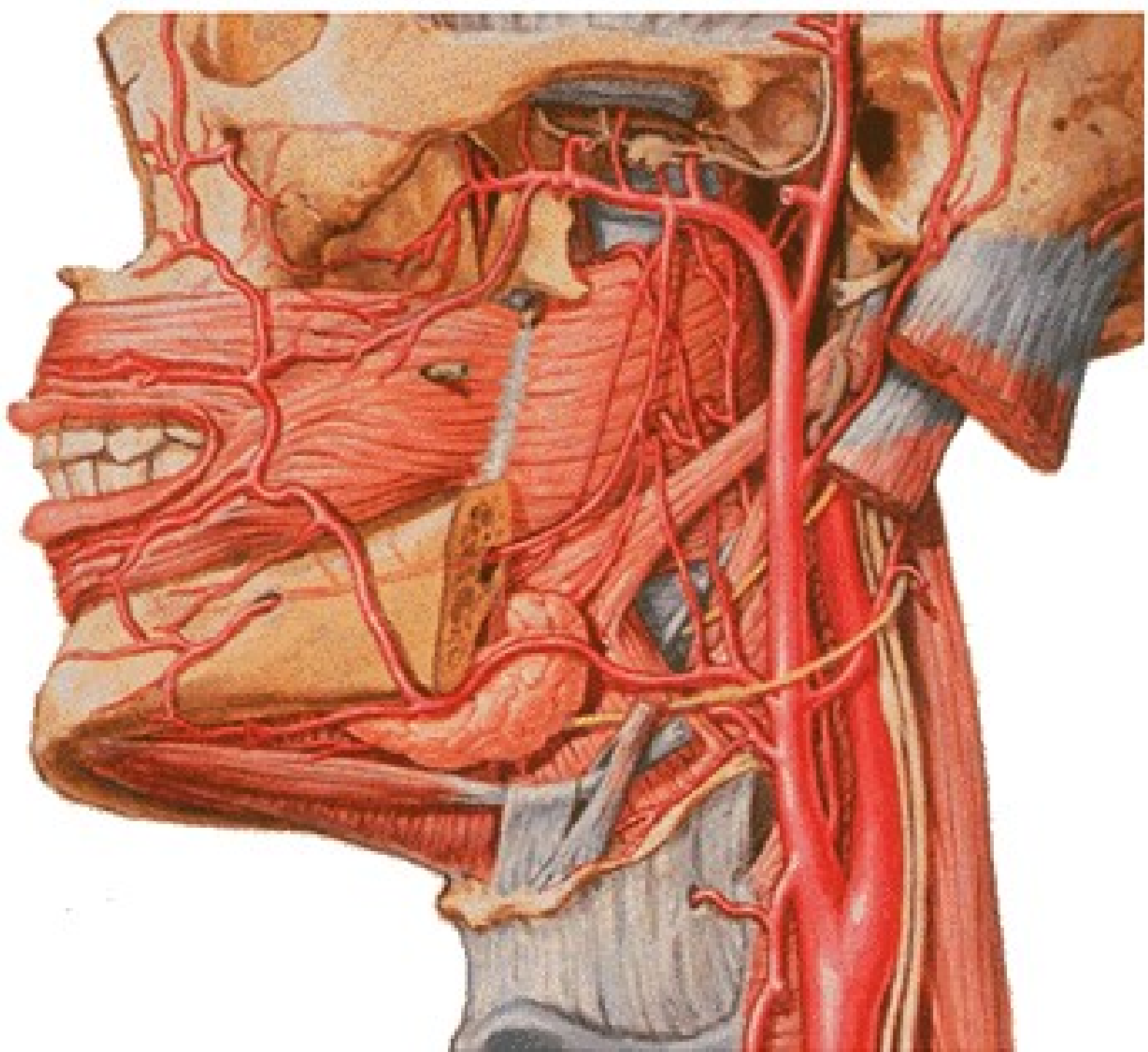


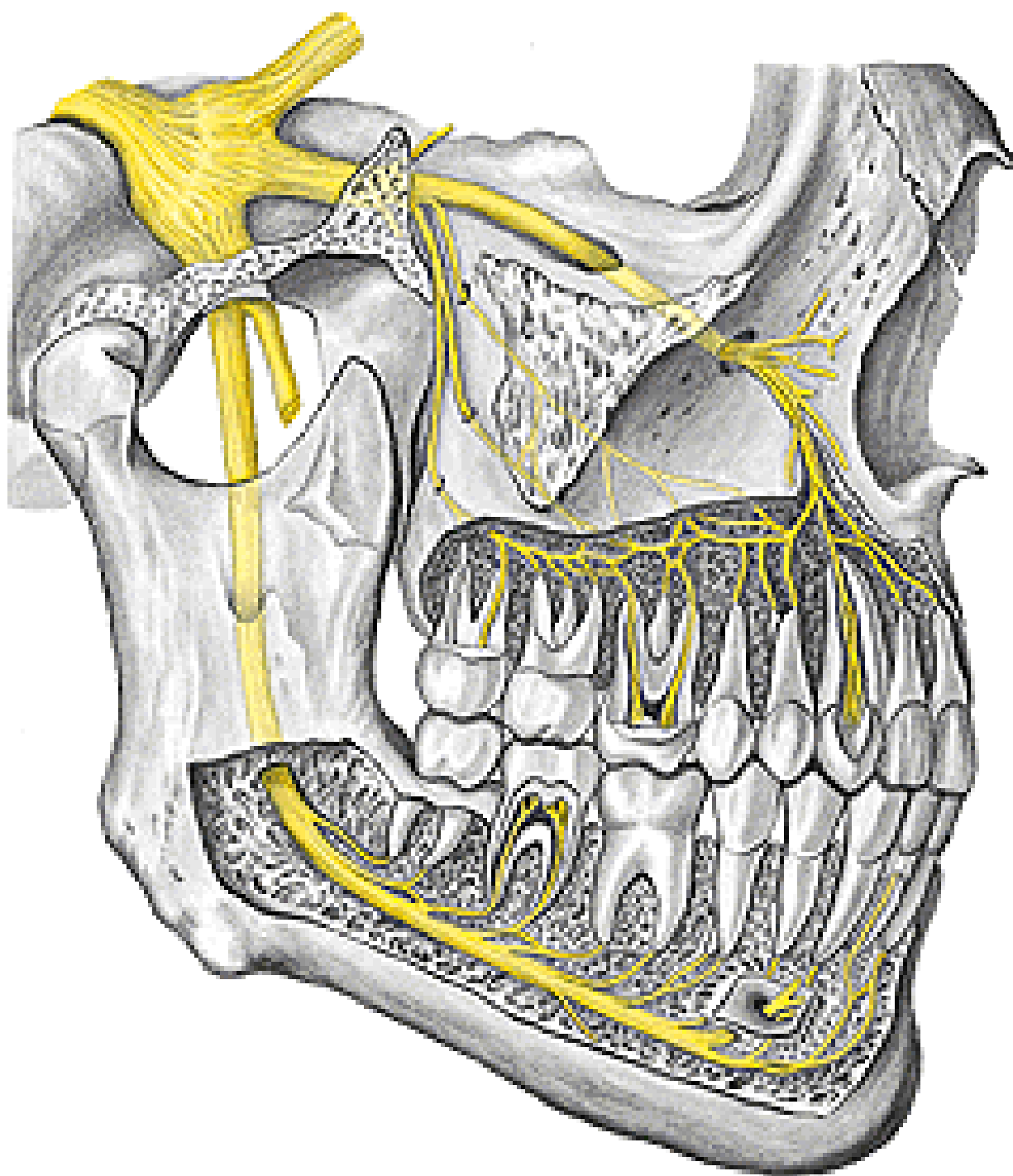


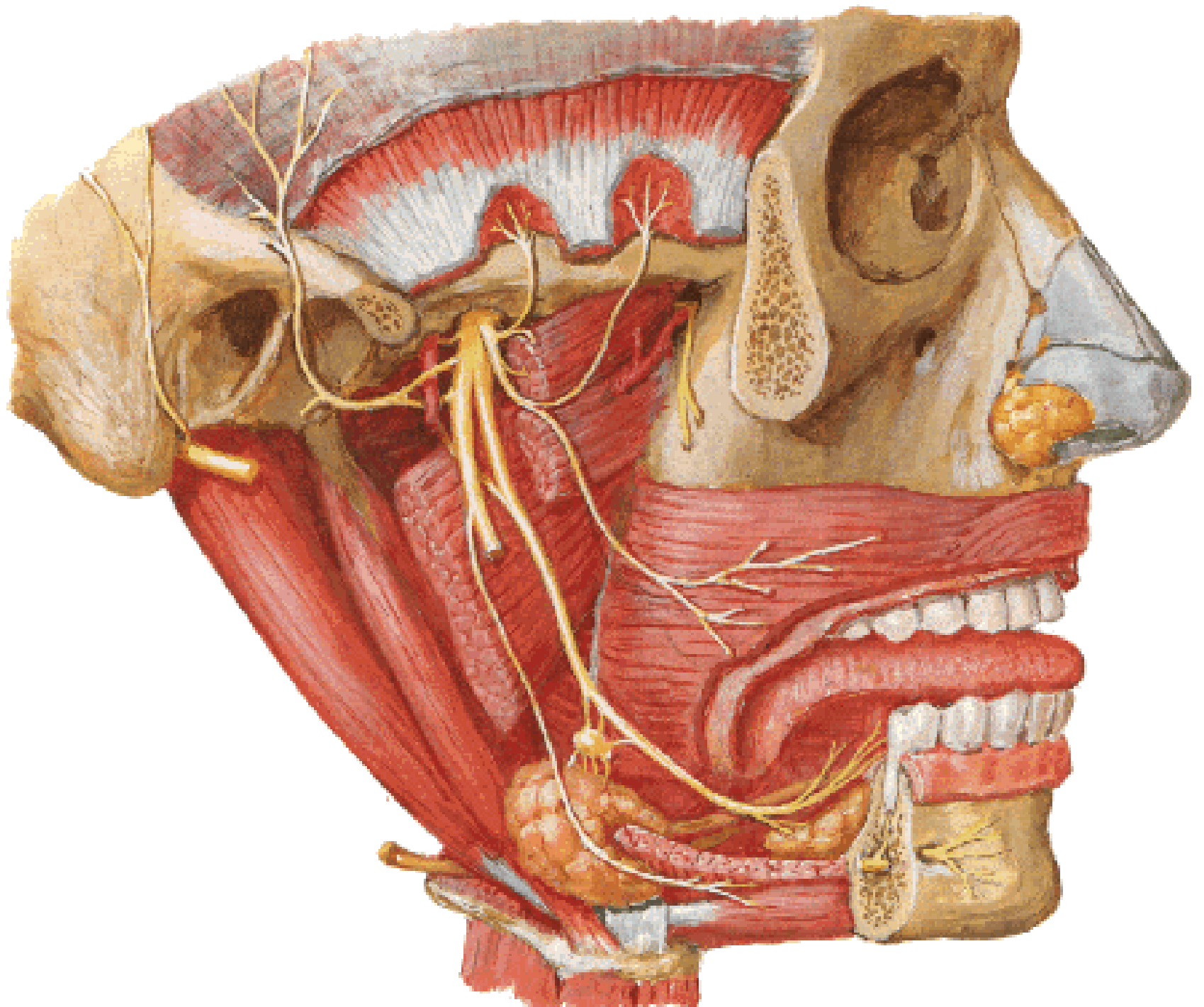


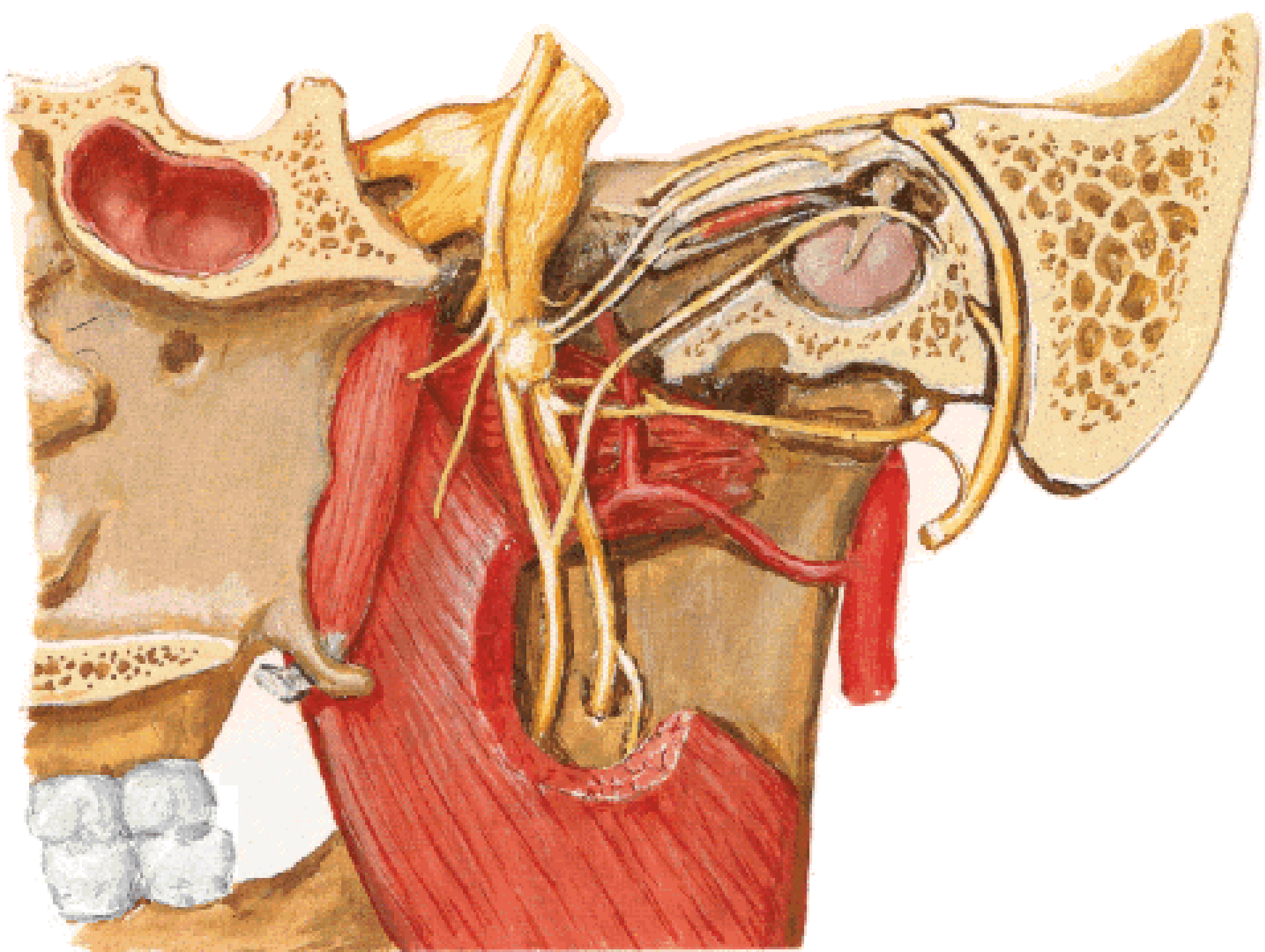
# Plexus pterygoideus

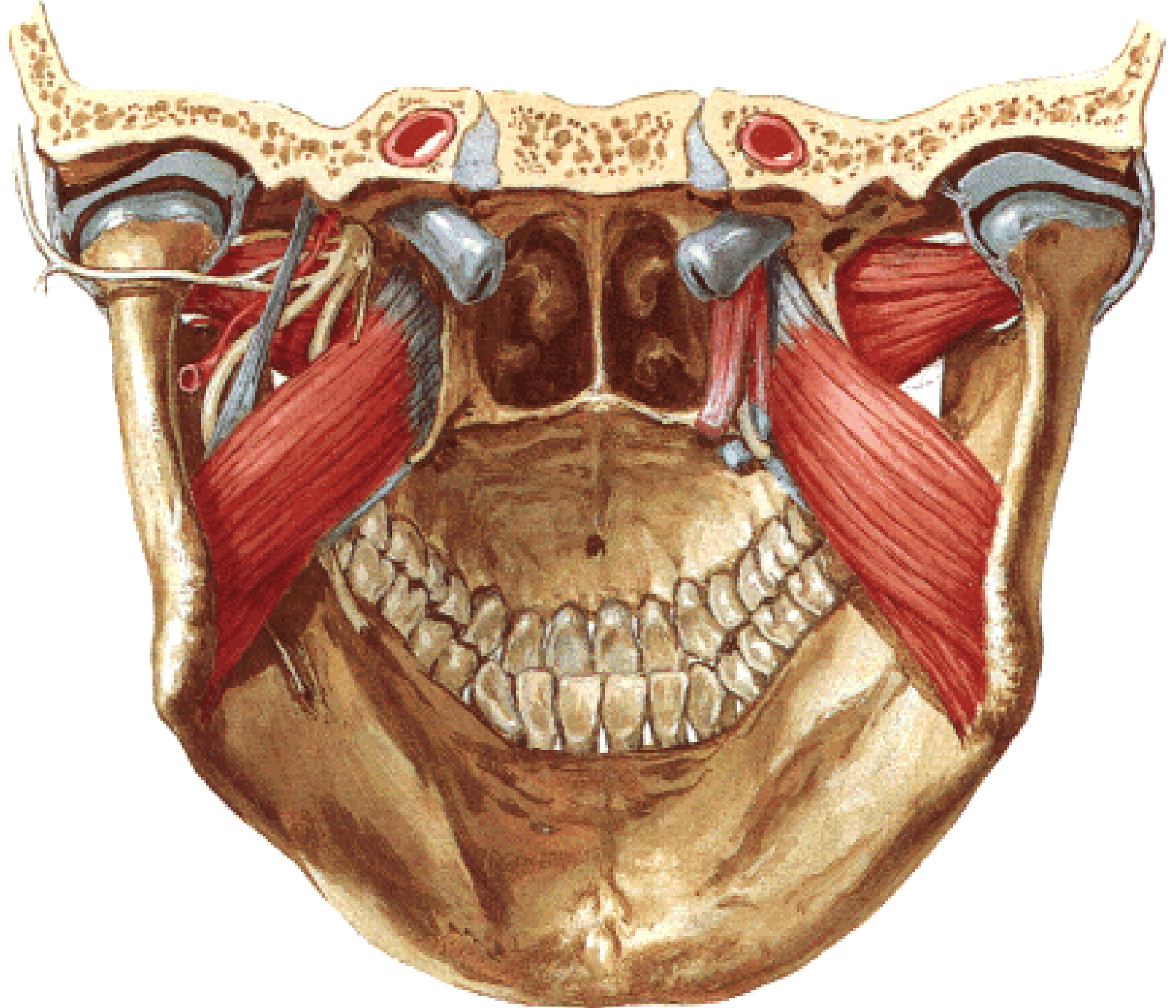




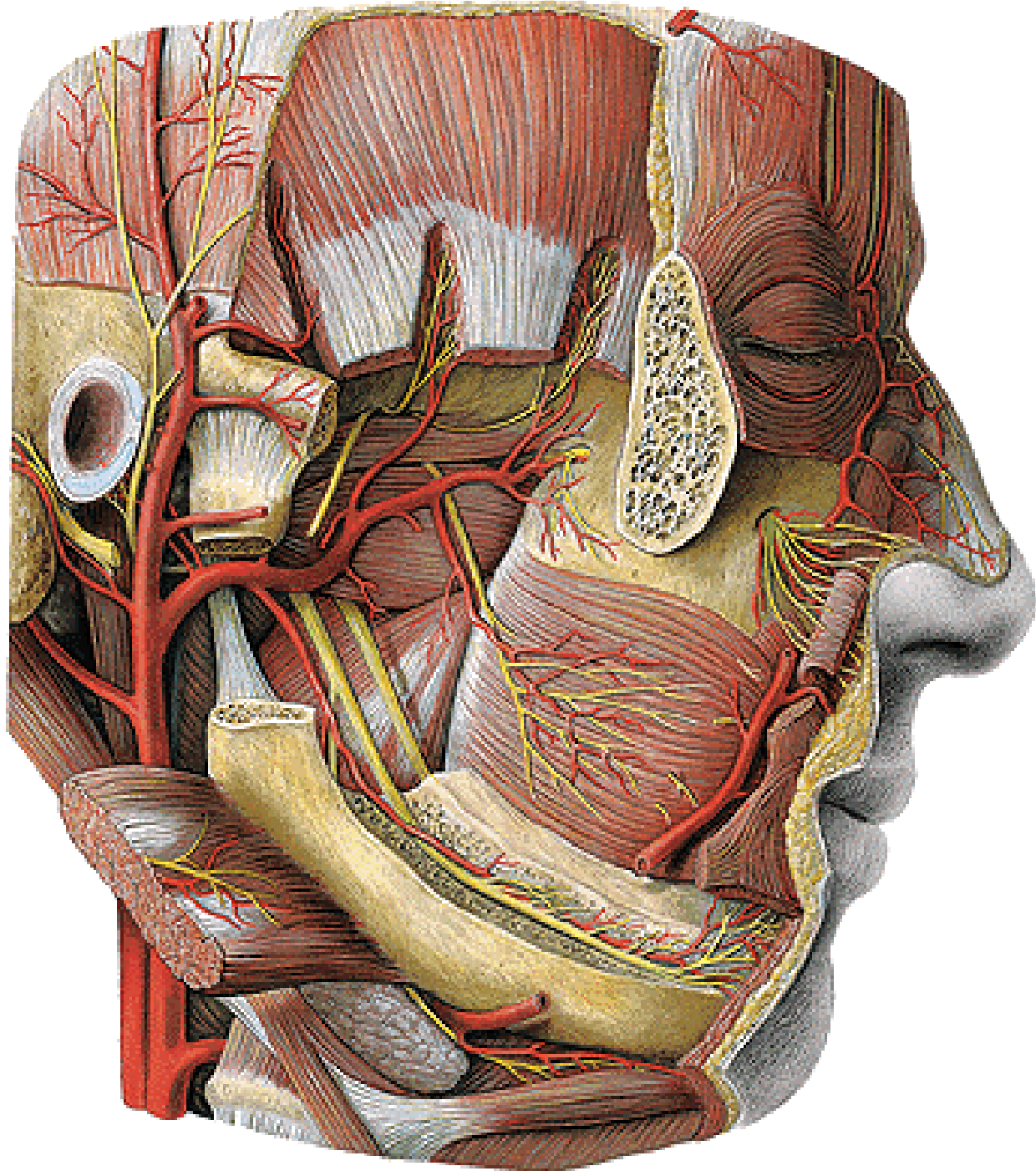


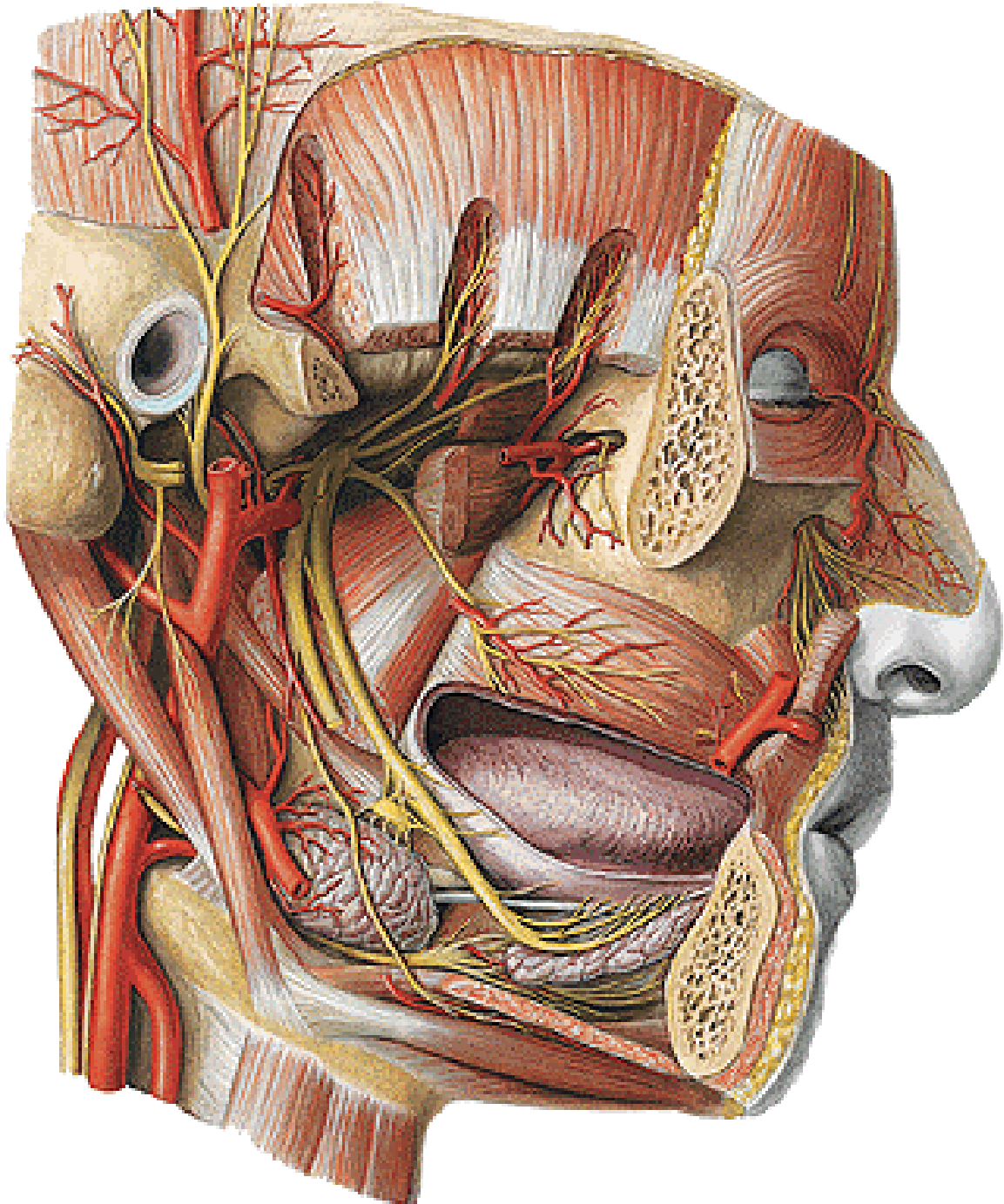




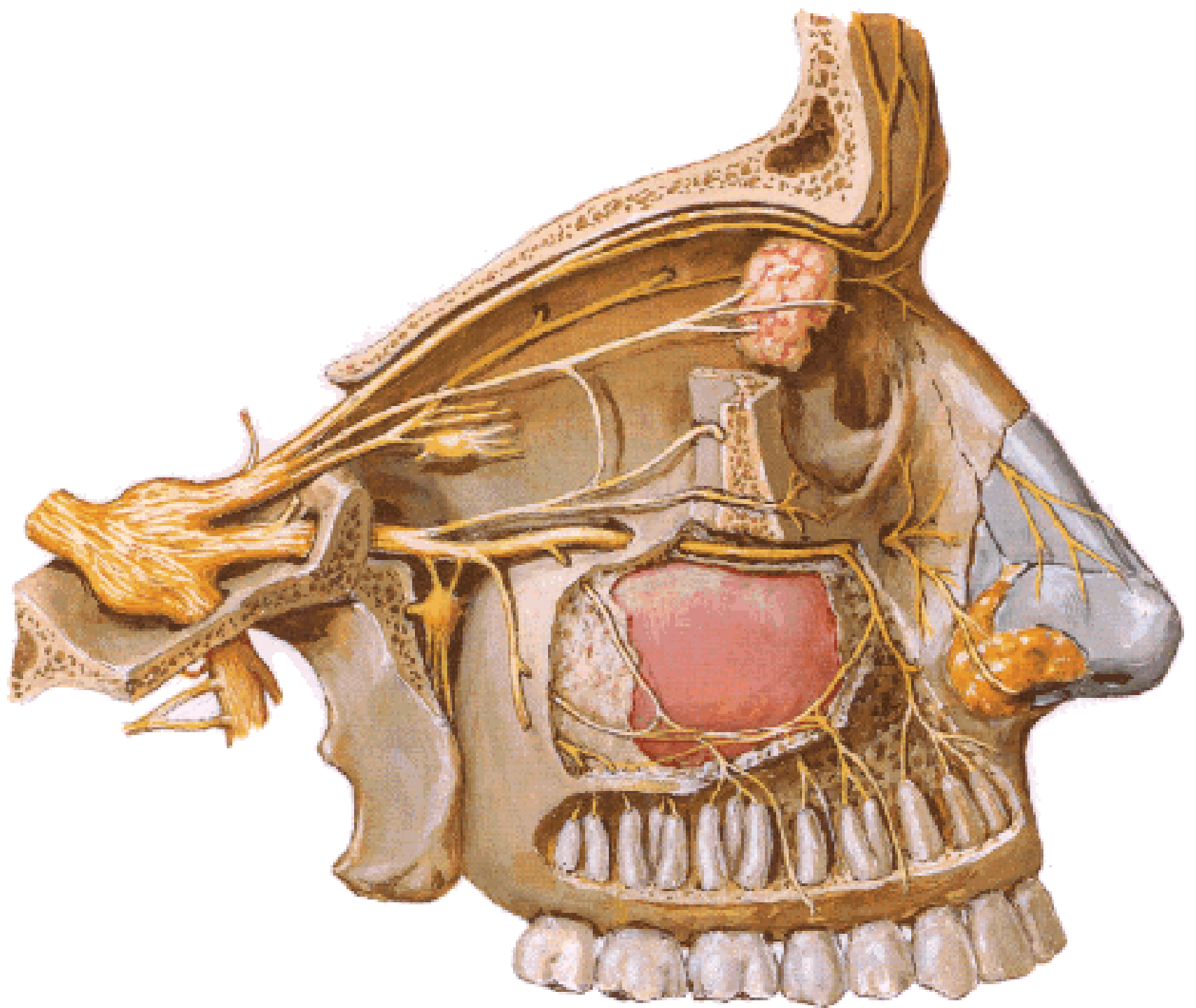


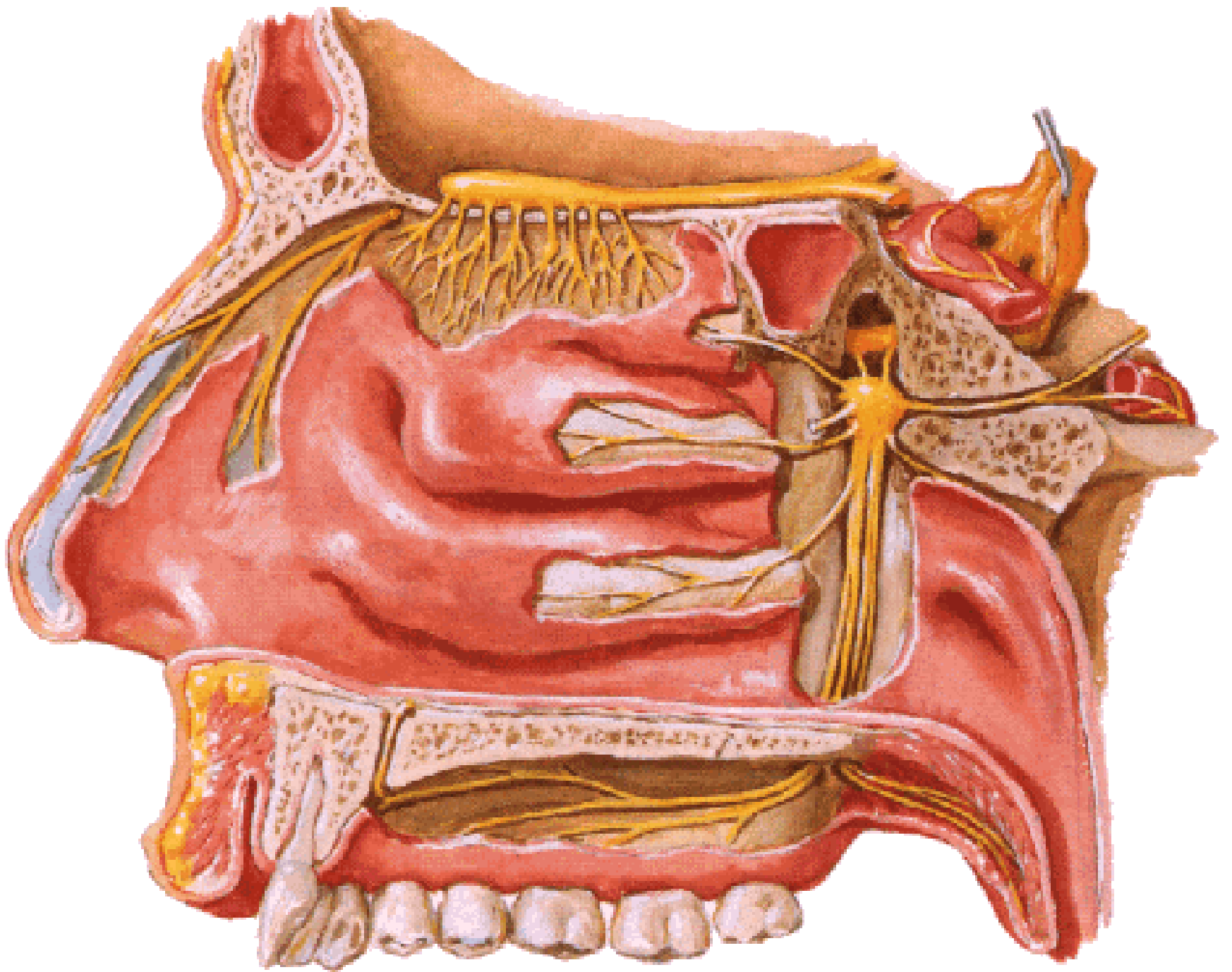


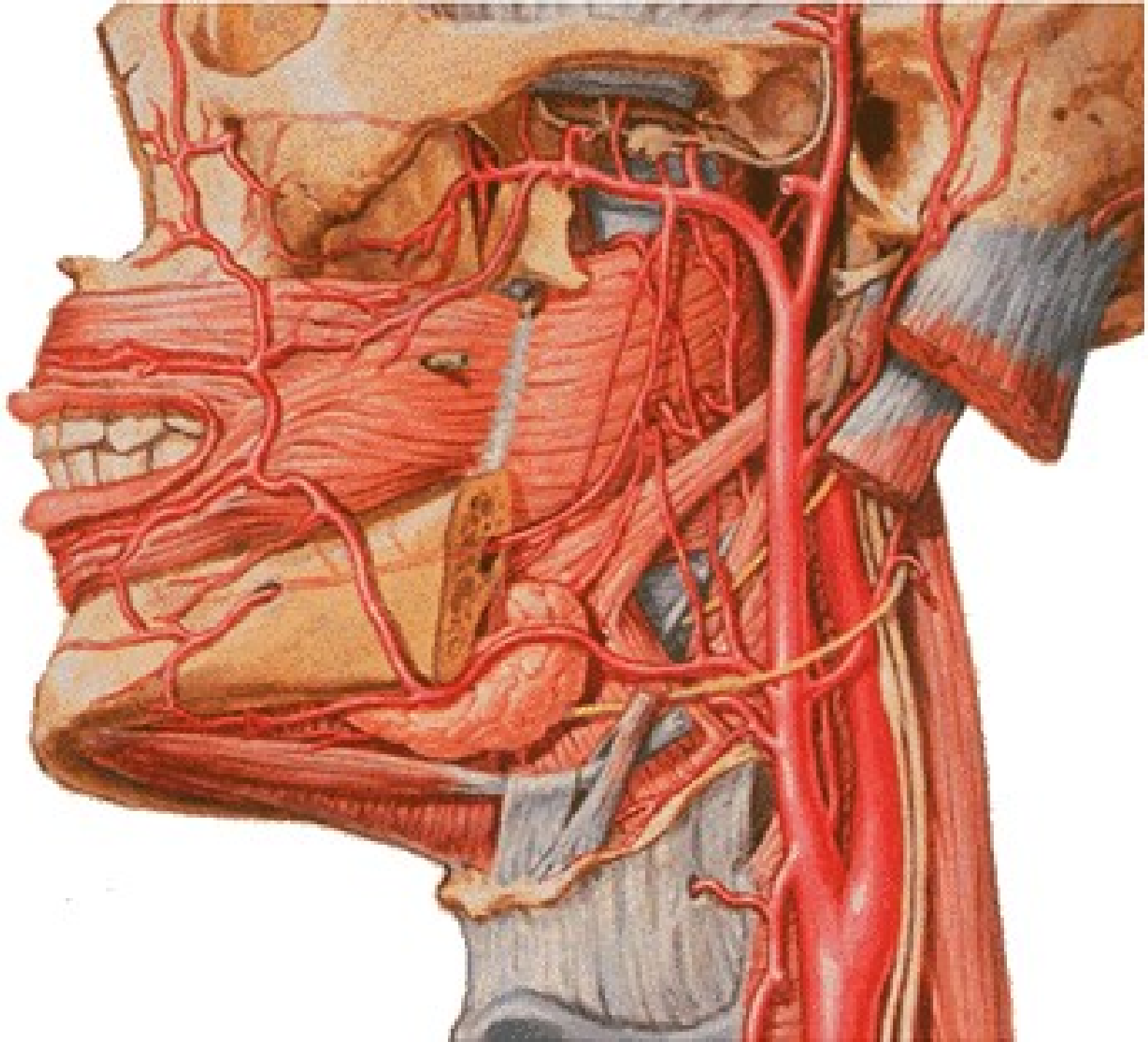




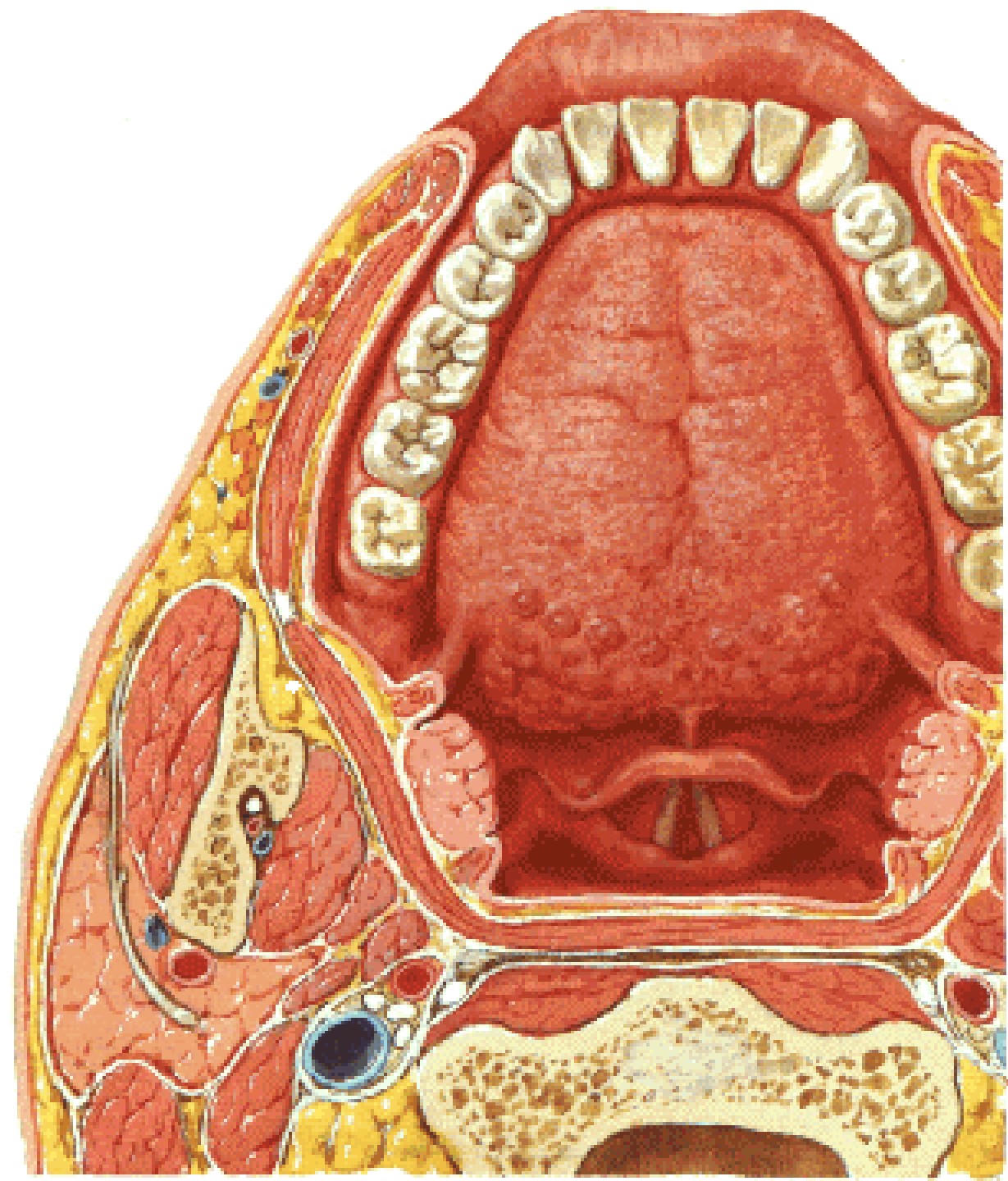
**FOSSA PTERYGOPALATINA**



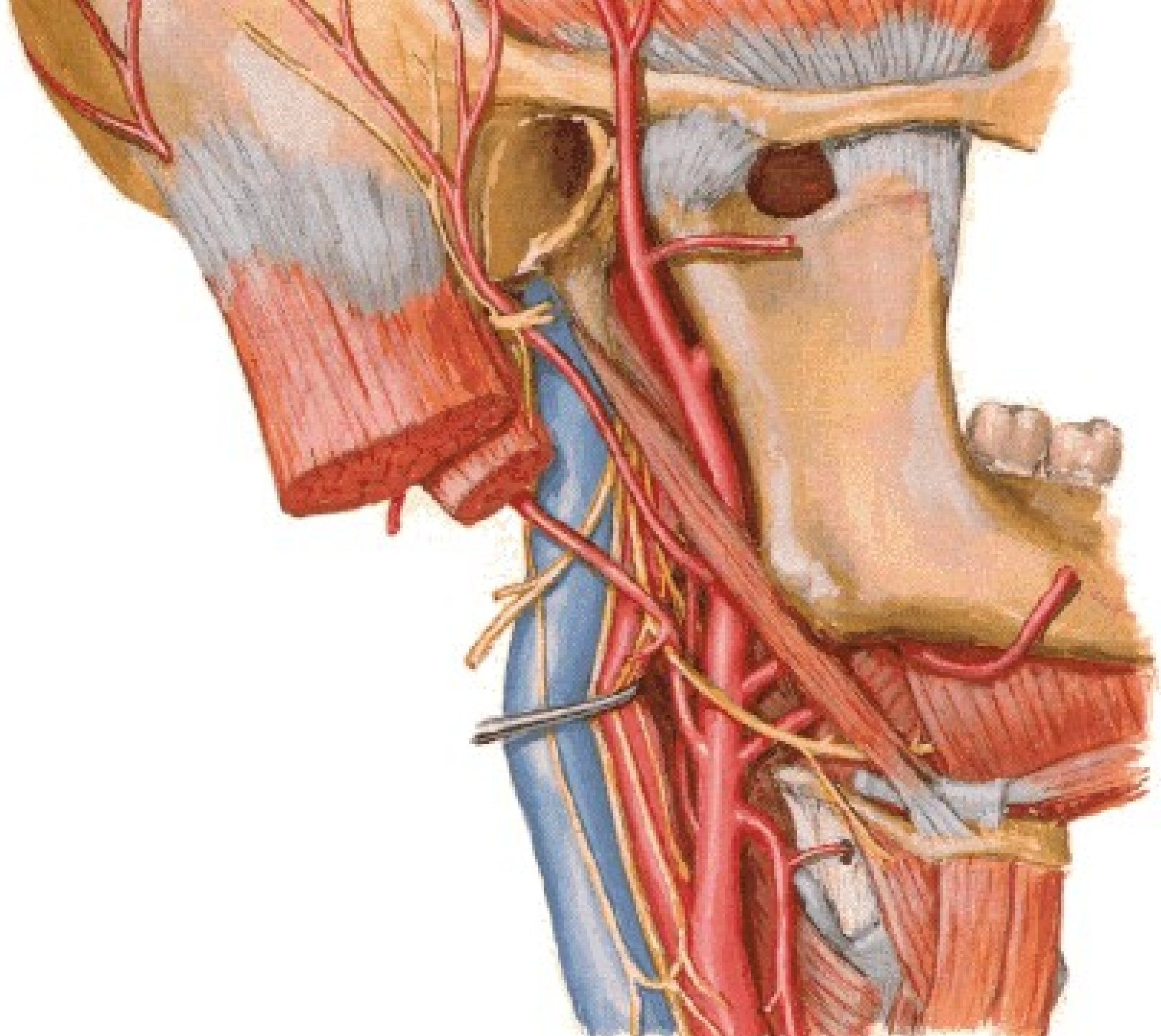




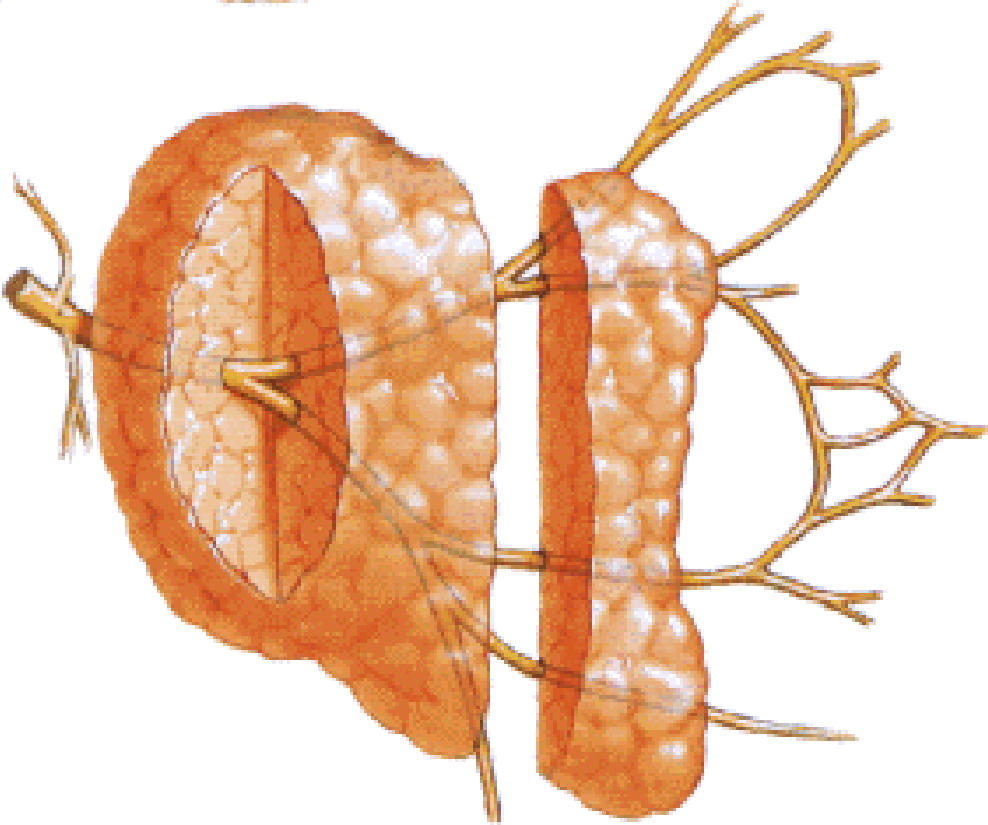
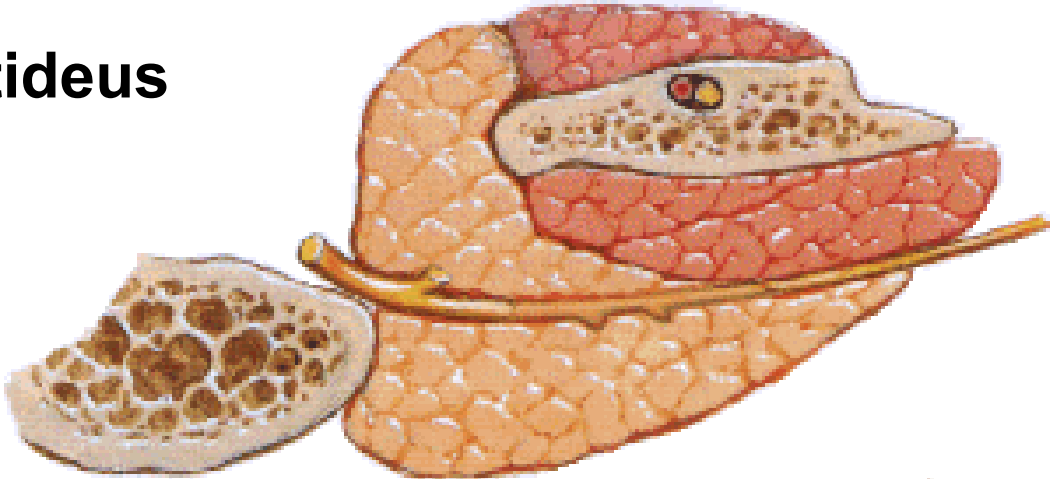
# **Regio parotidea**



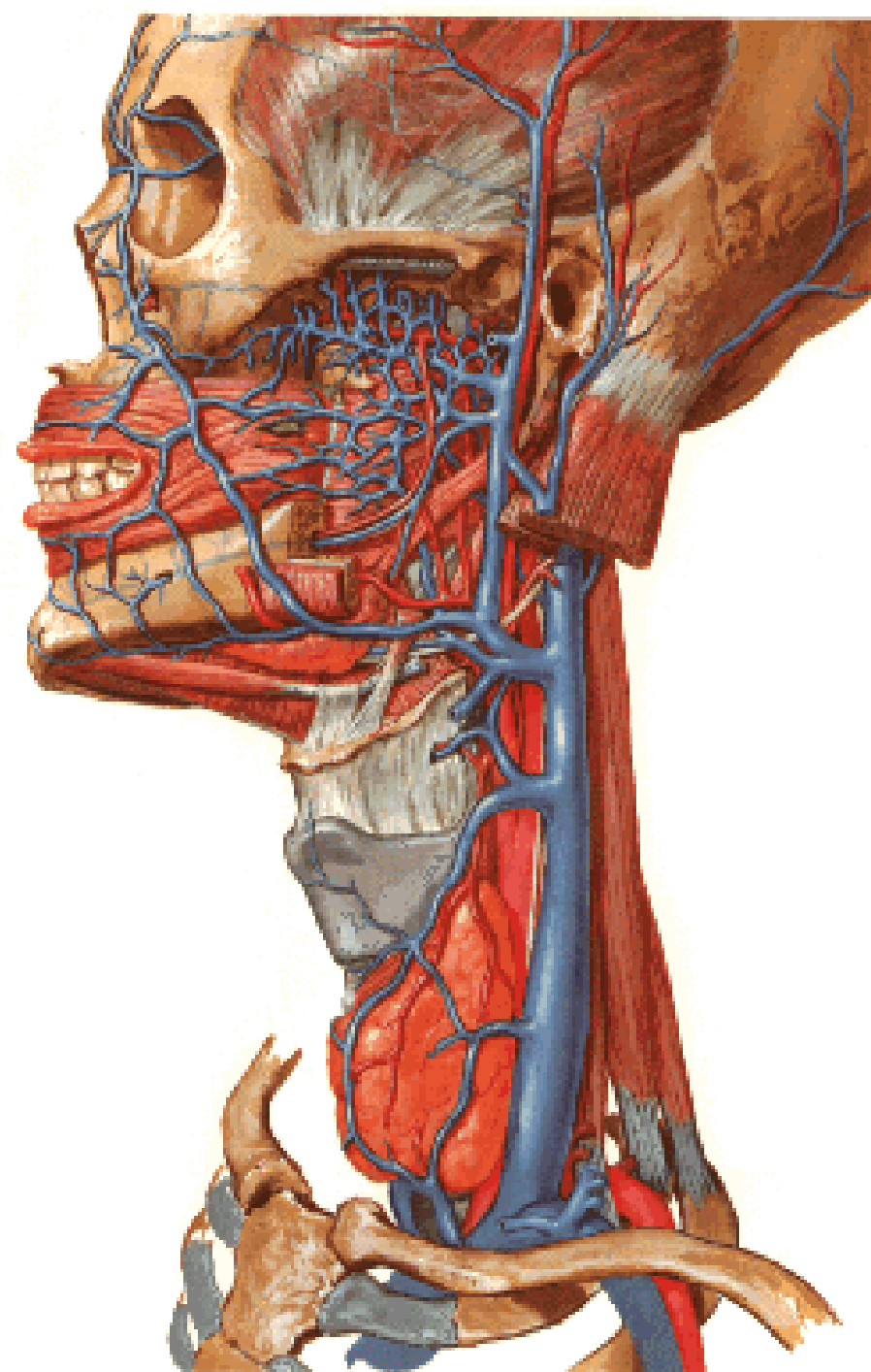


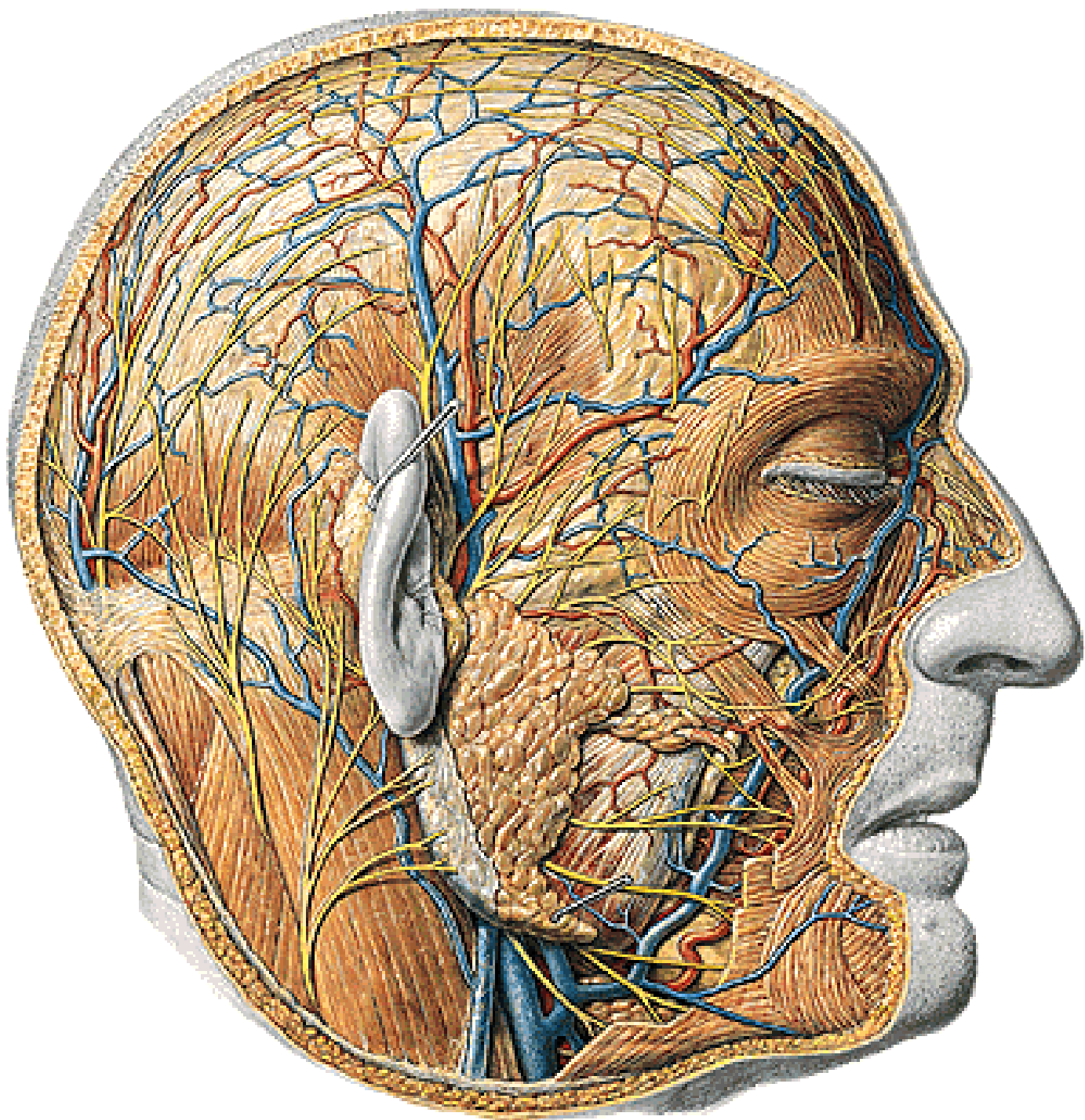


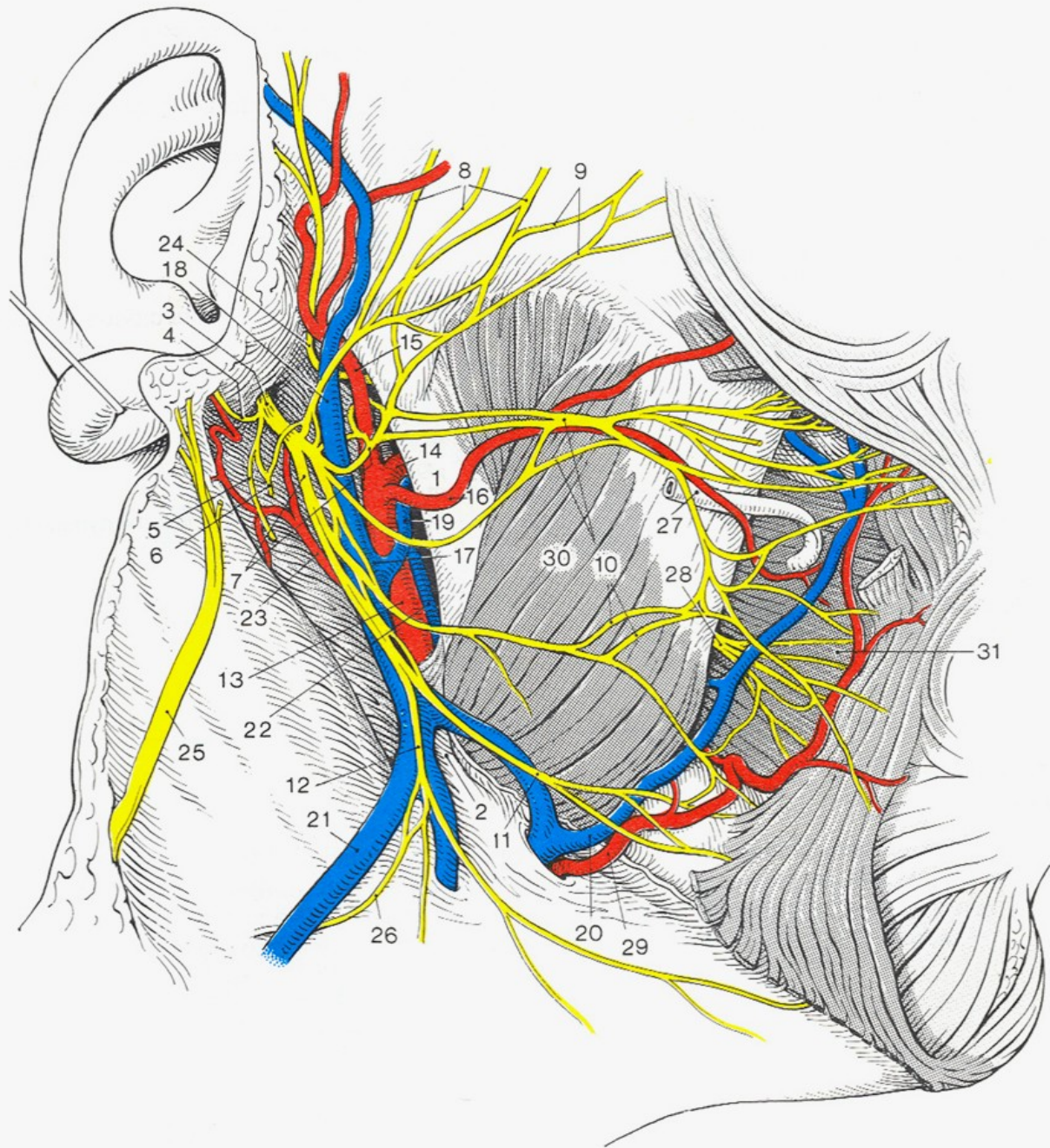
# Plexus parotideus



## V. retromandibularis







Obr. 6

Illustrations were copied from:

**Atlas der Anatomie des Menschen/Sobotta.  
Putz,R., und Pabst,R. 20. Auflage. München:  
Urban & Schwarzenberg, 1993)**

**Čihák R: Anatomie 2 (Splanchnologia).  
Avicenum,  
zdravotnické nakladatelství, Praha, 1988.**