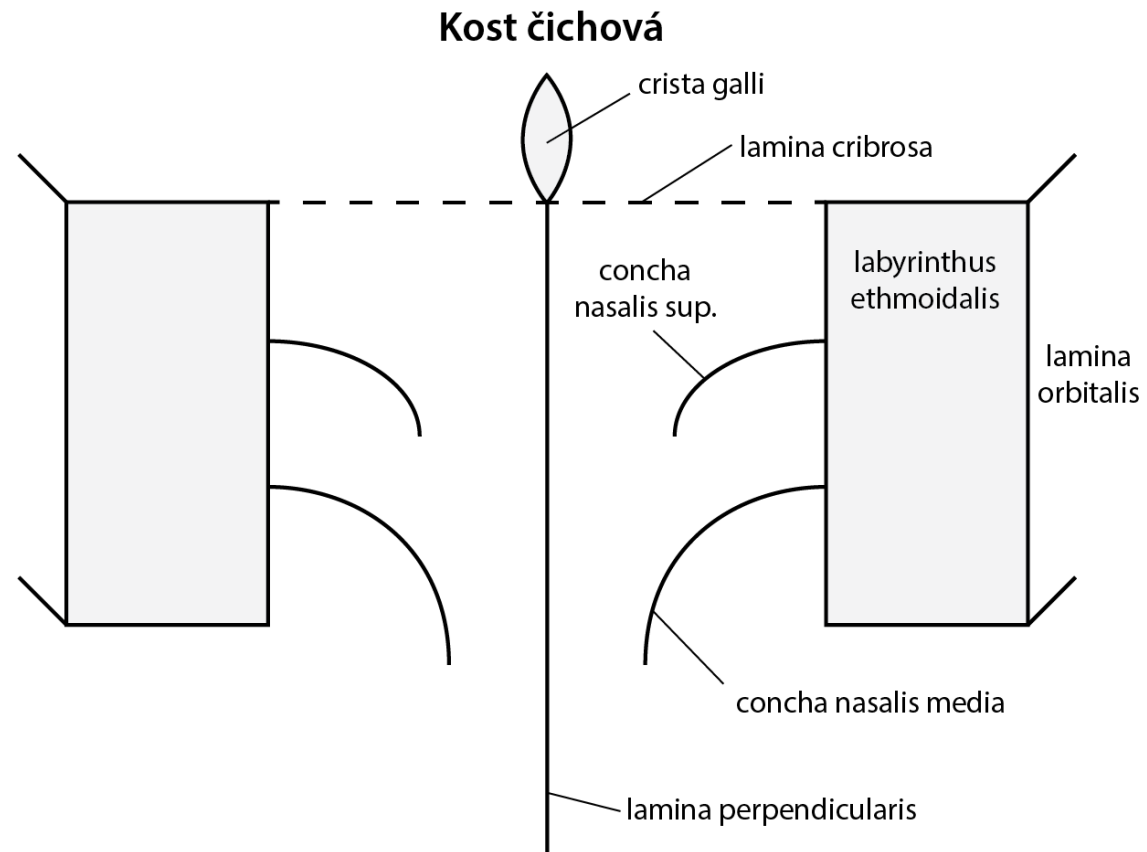
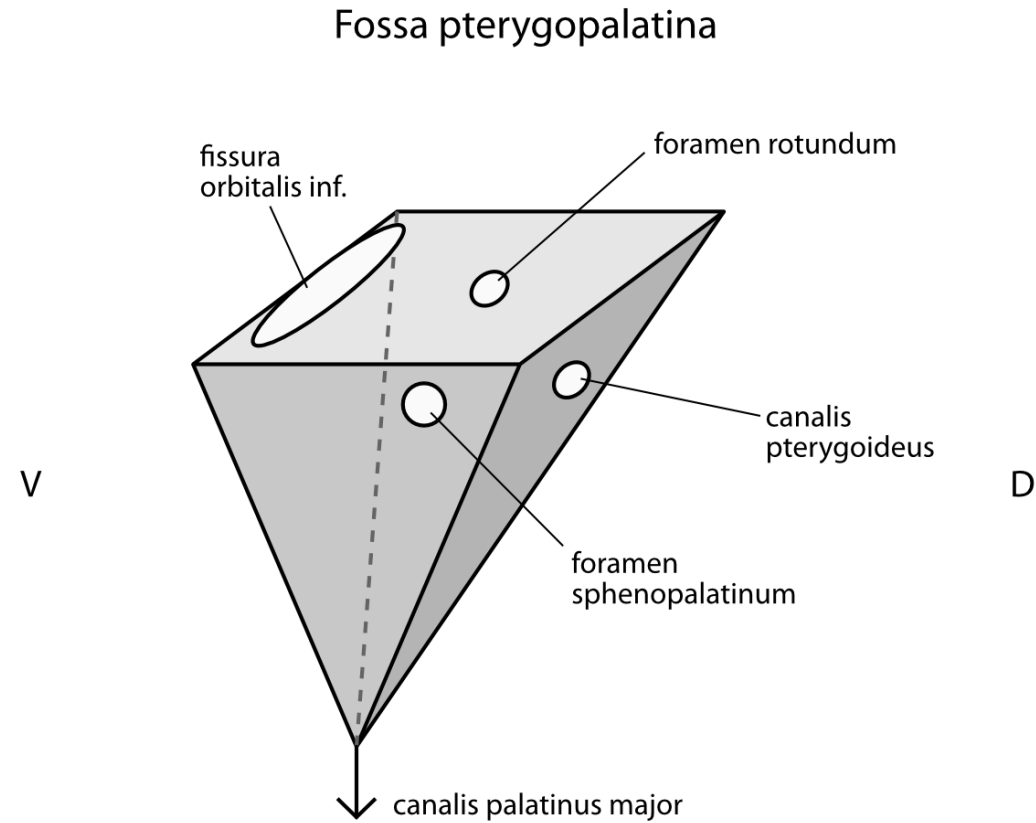


Set of schemas to the topic head and neck

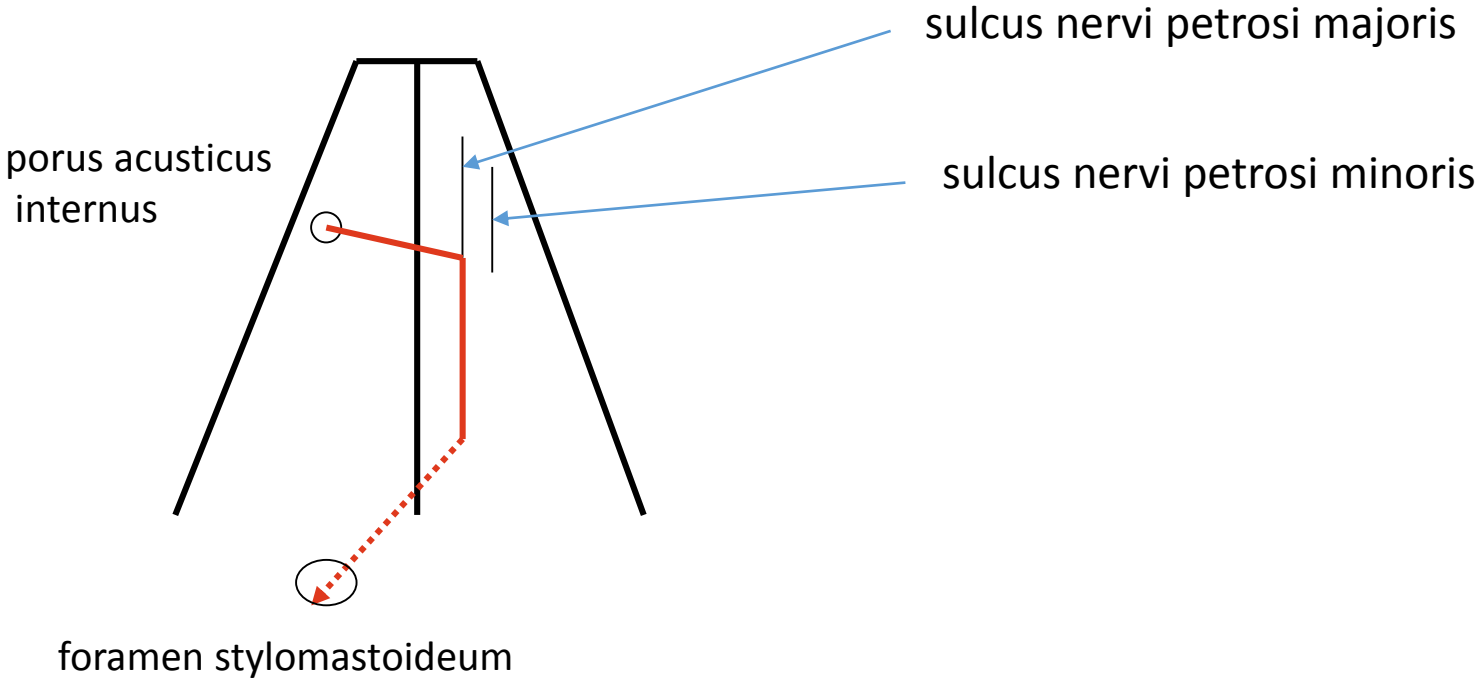
Os ethmoidale



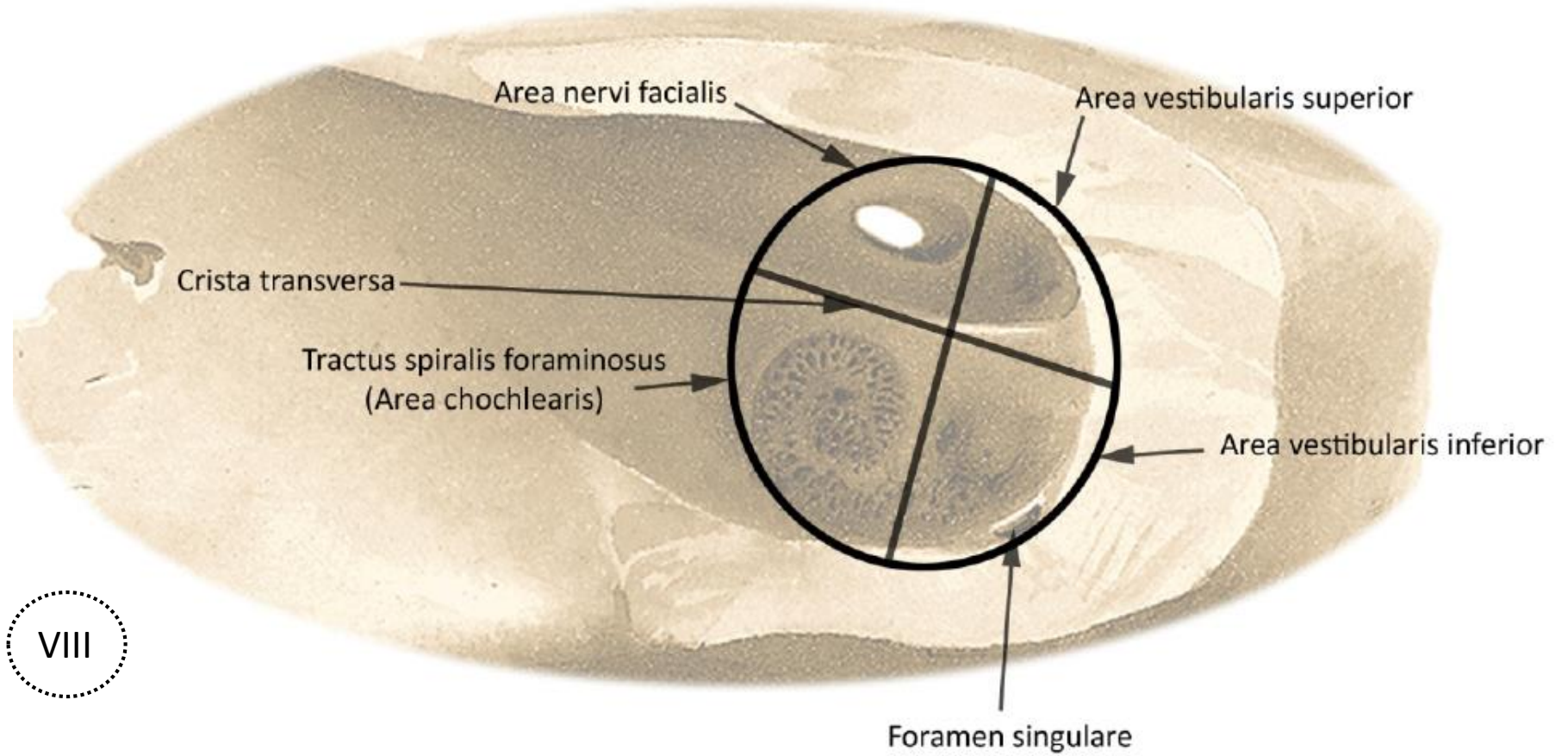
Pterygopalatine fossa – shape, walls



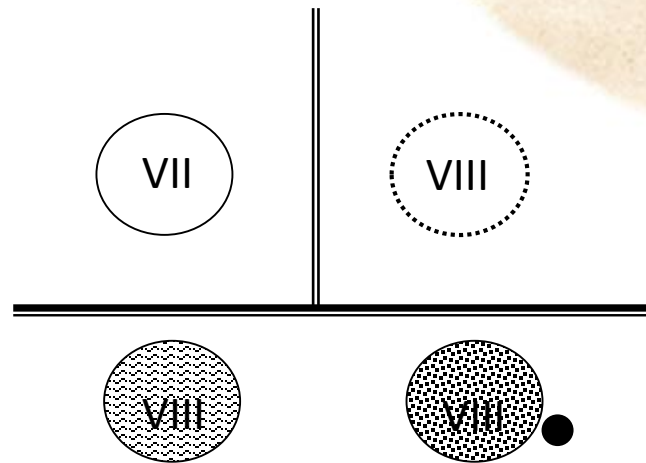
Course of facial canal in the pyramid – superior aspect



Floor of the internal acoustic meatus

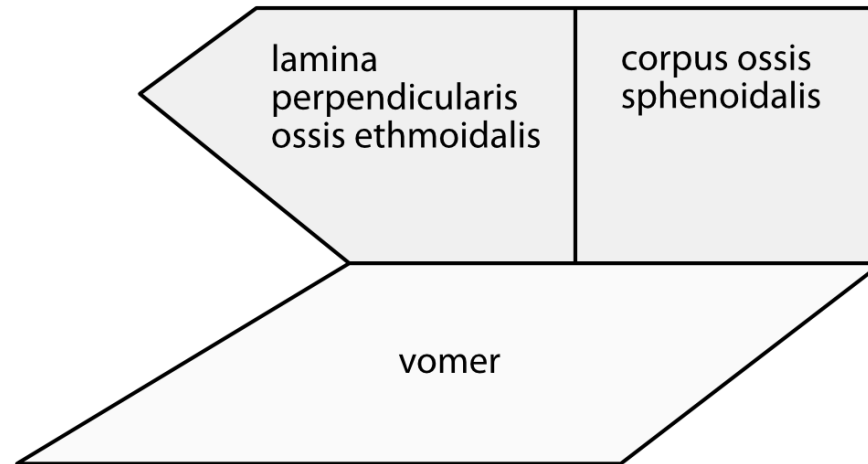


V

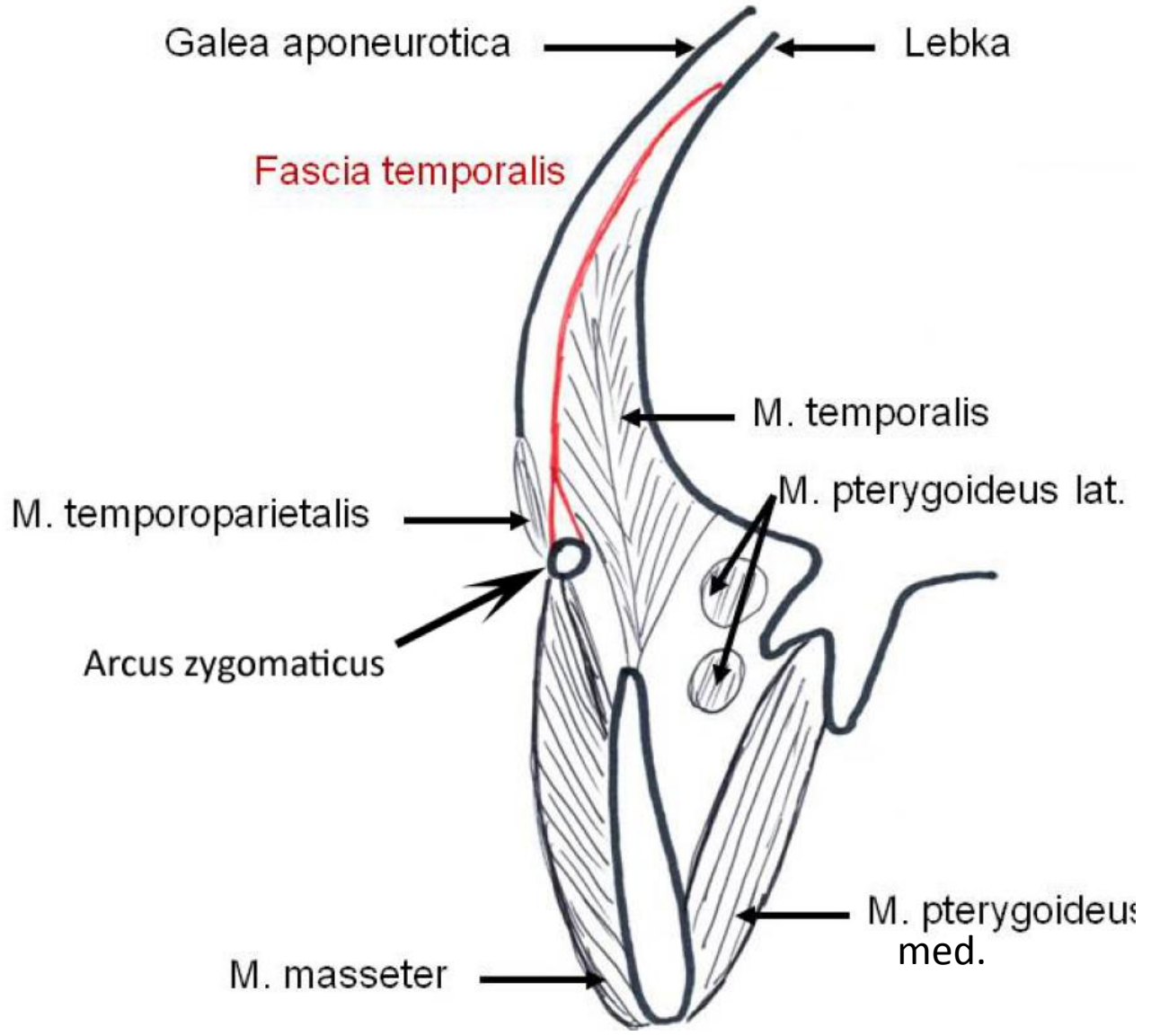


D

Osseous nasal septum (vomer, lamina perpendicularis ossis ethmoidalis)

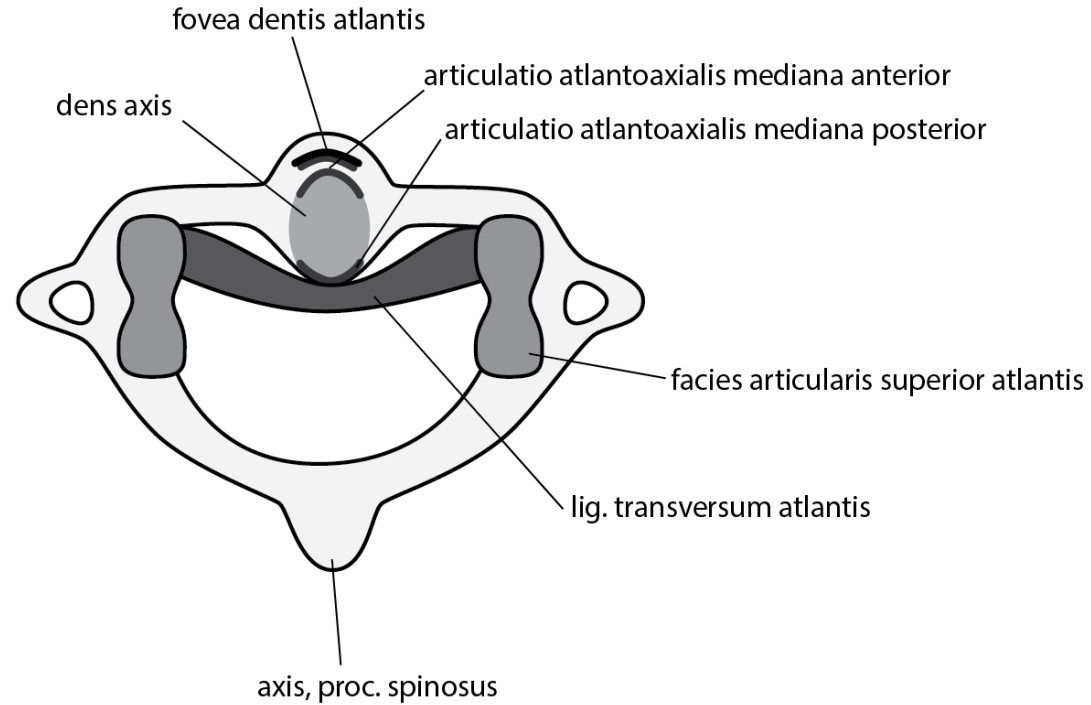


Temporal fossa – frontal section, attachment of the temporal fascia



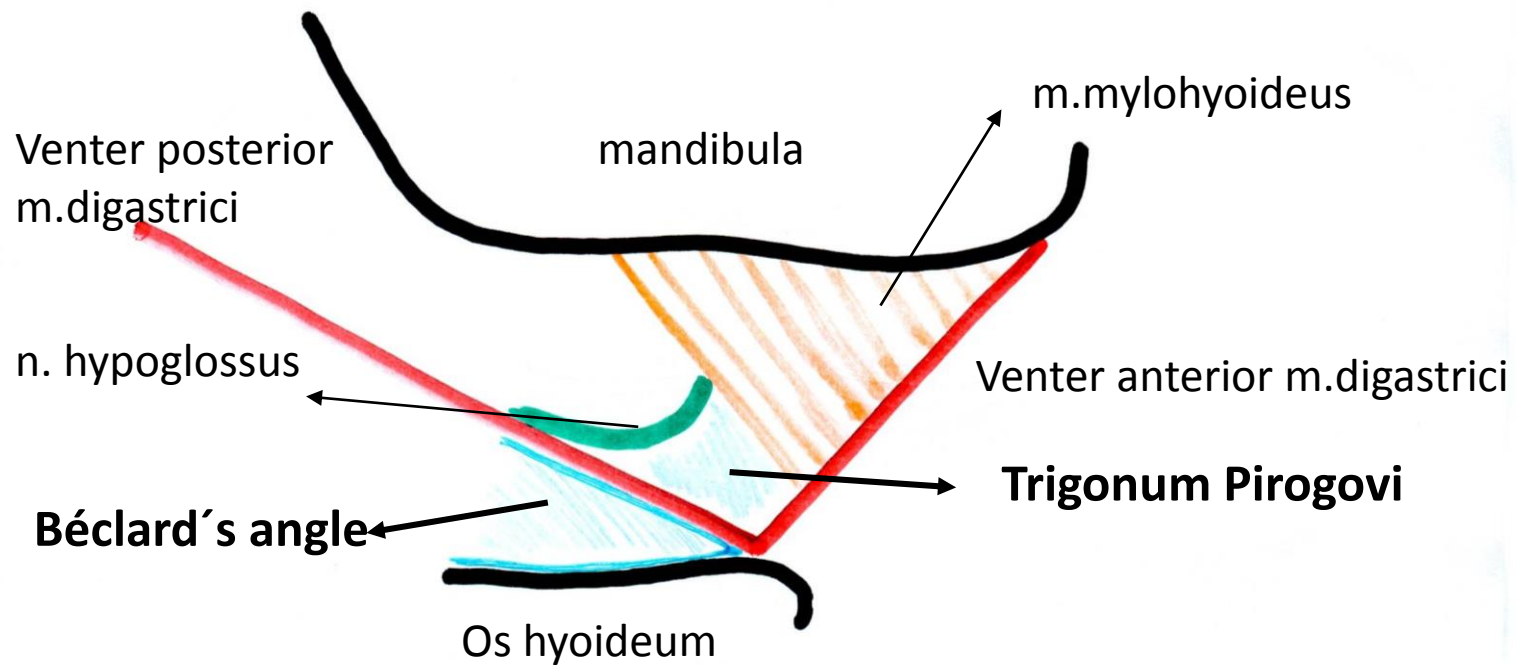
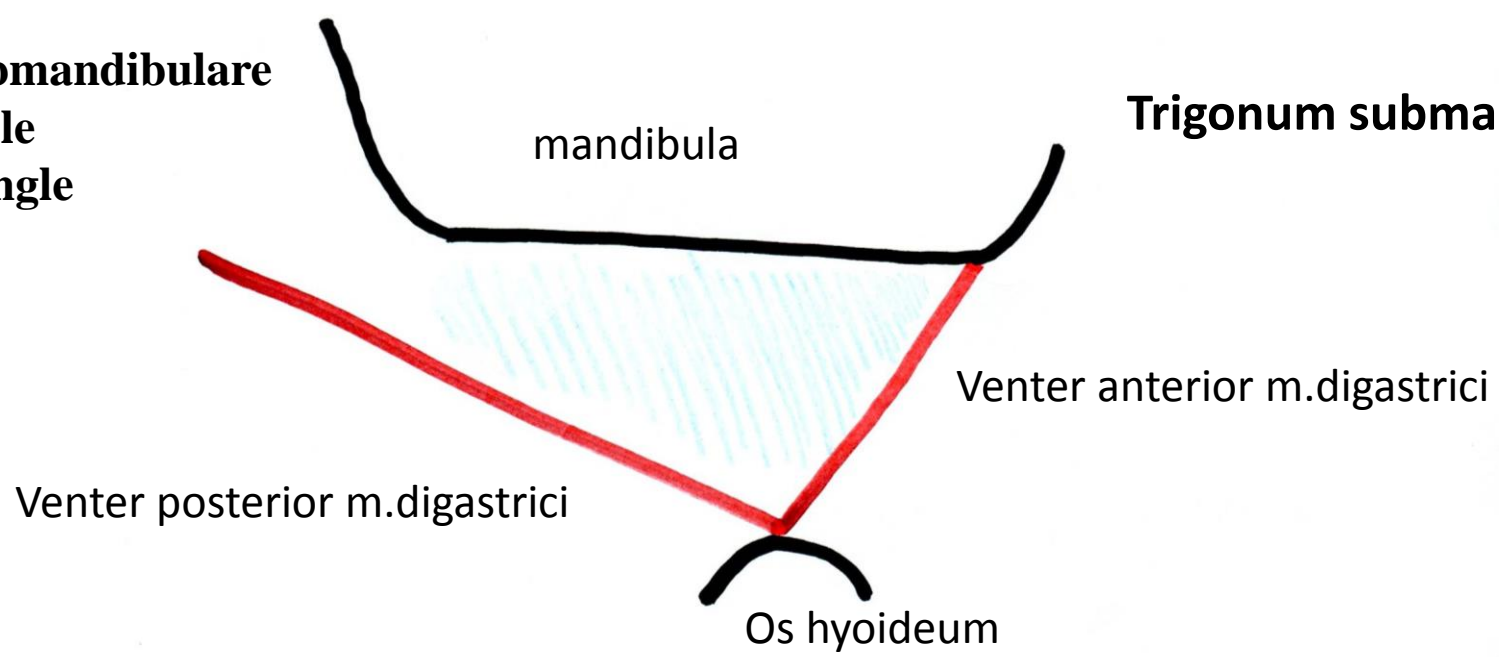
Ligaments of the atlanto-axial joint – superior aspect

Lig. transversum atlantis

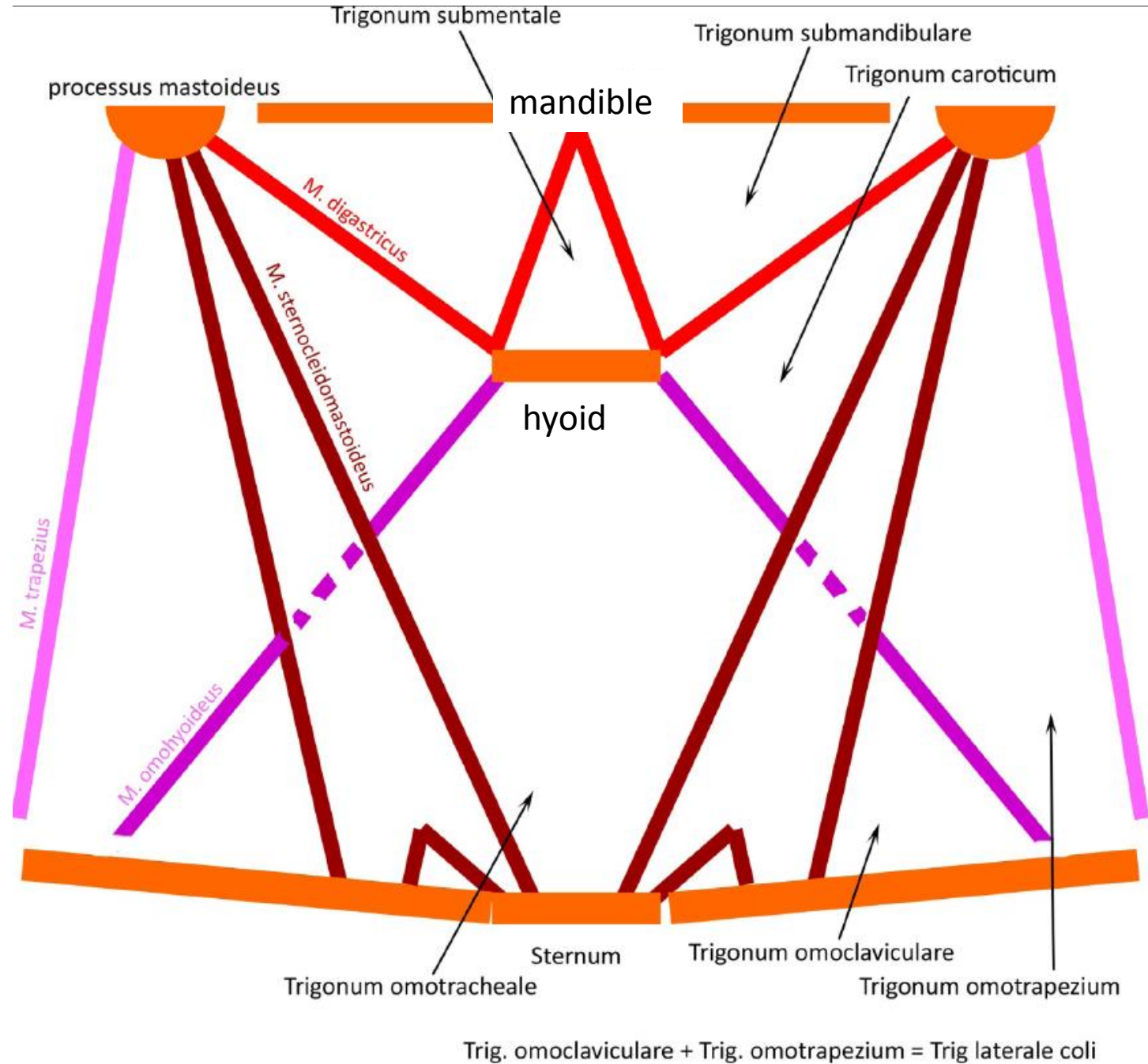


Trigonum submandibulare
Beclard's angle
Pirogow's tringle

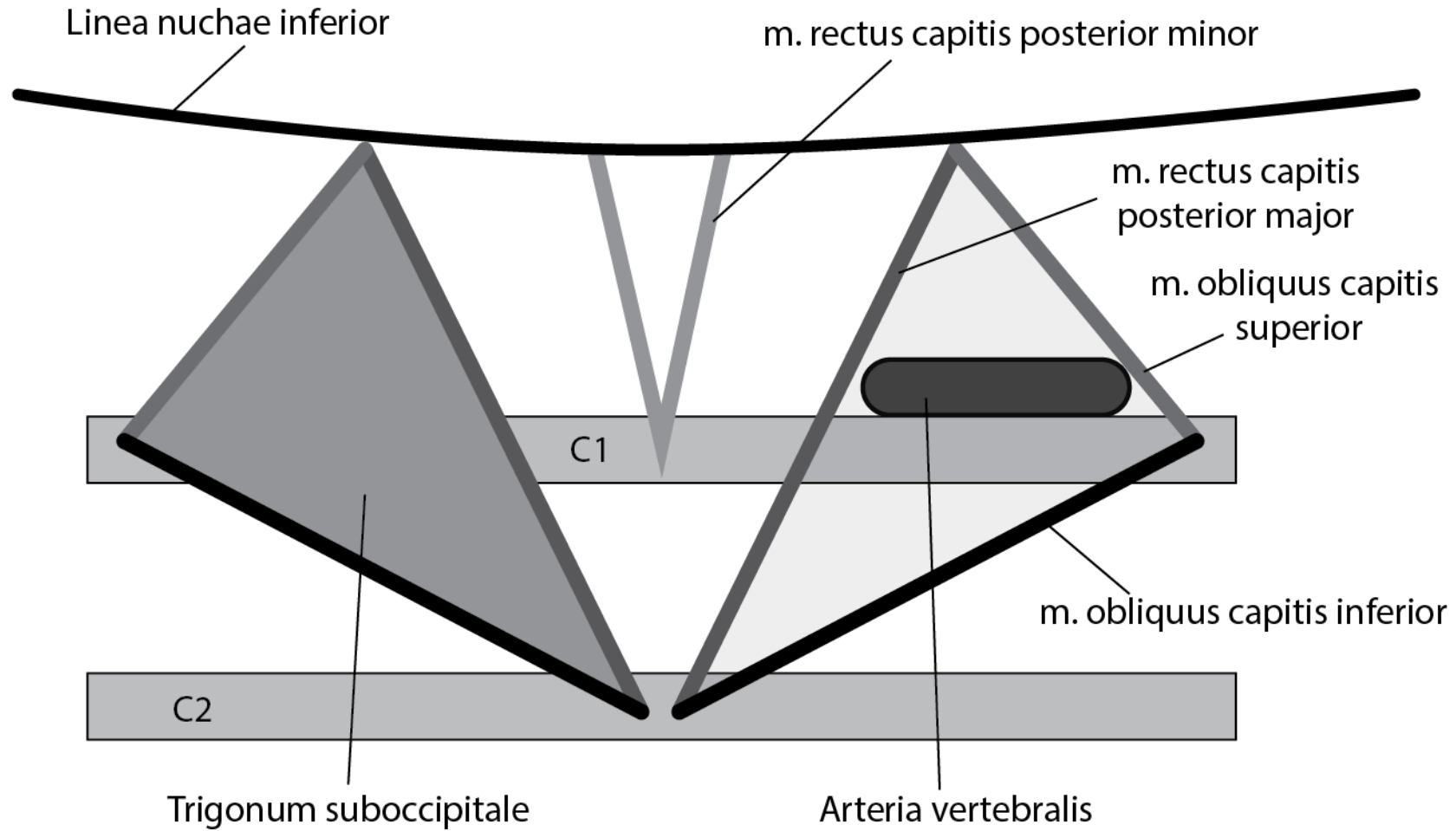
Trigonum submandibulare



Triangles of the neck

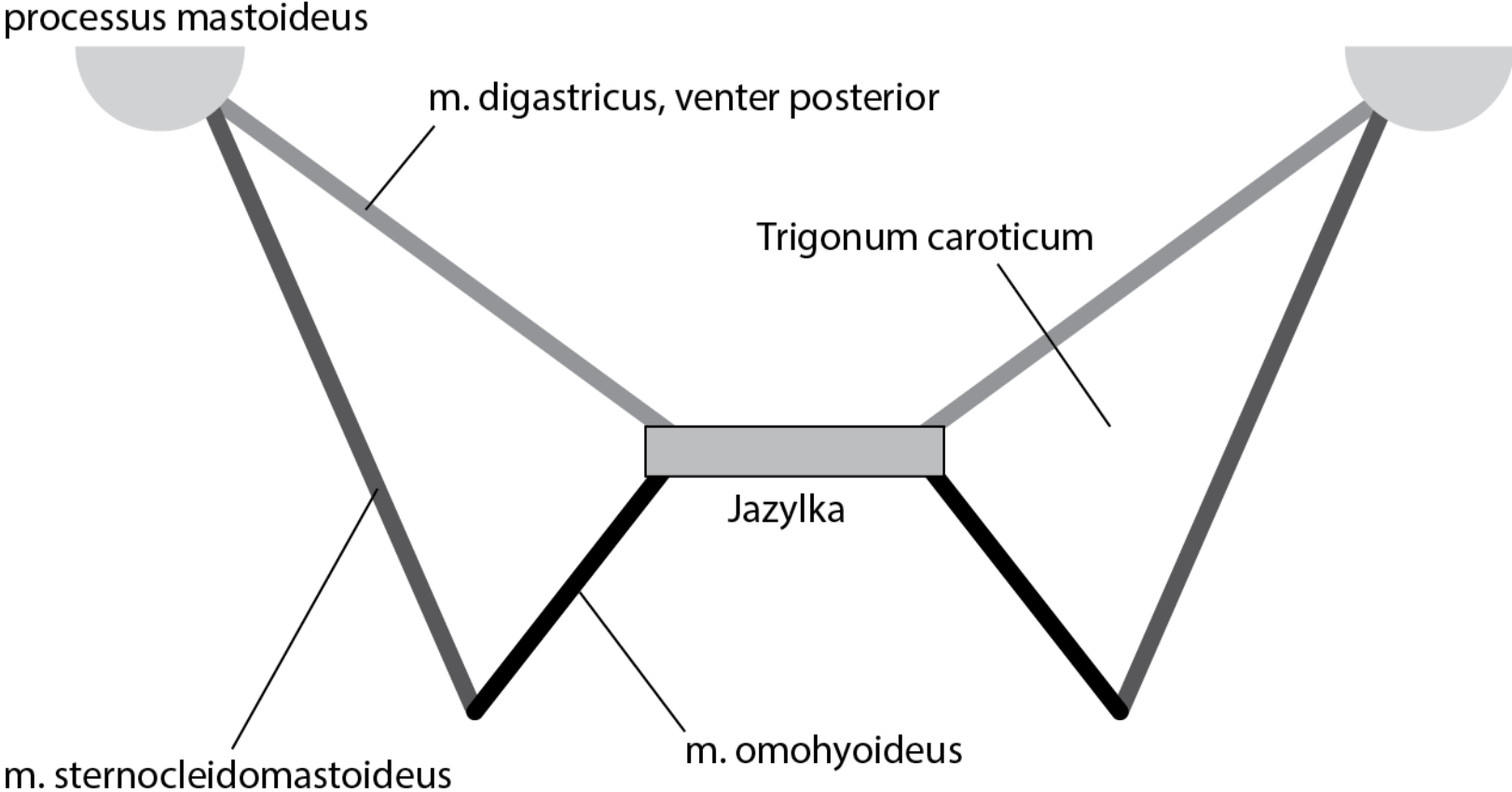


Trigonum suboccipitale

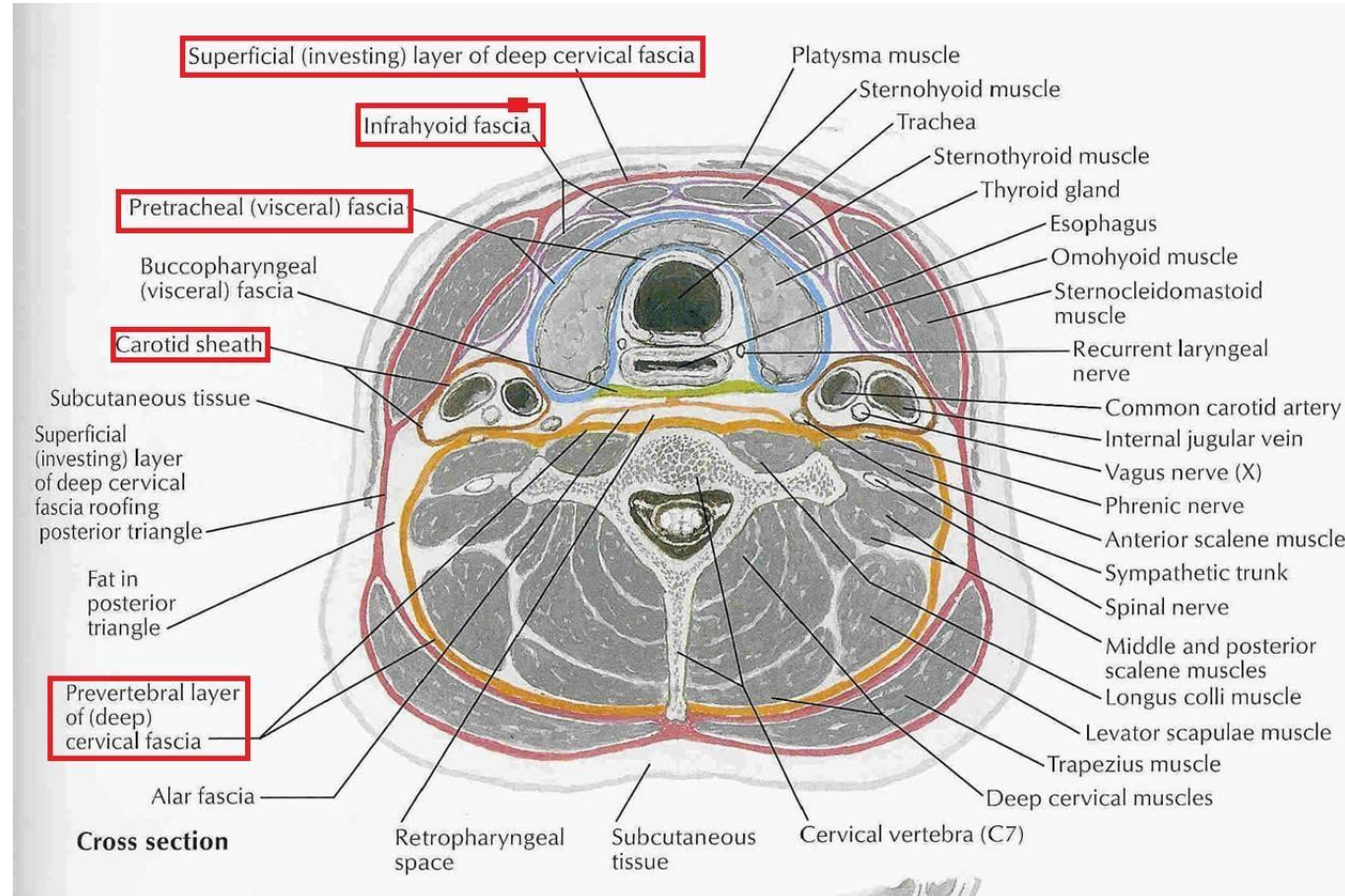


Trigonum caroticum

Trigonum caroticum



Fasciae of the neck (horizontal section)



Fissura scalenorum – position of subclavian artery, trunks of the brachial plexus

