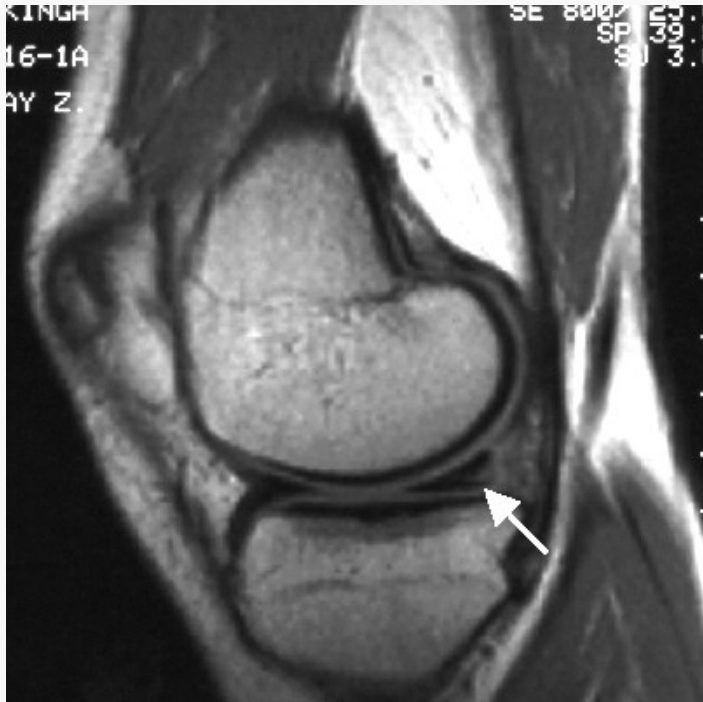

# Injuries



# Laesio

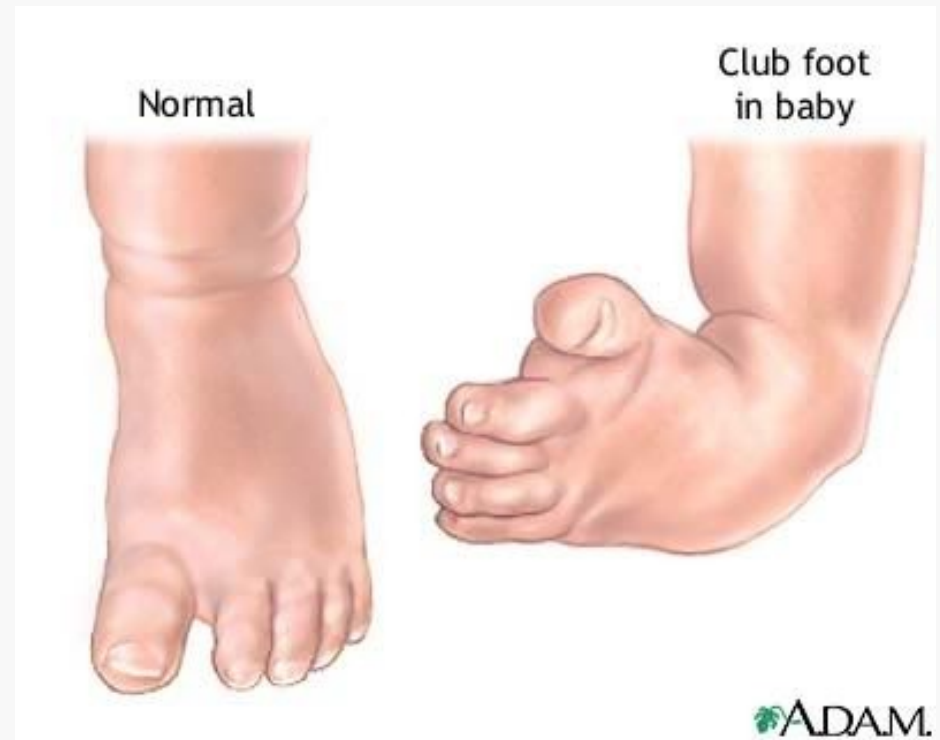- Any damage of an organ or tissue that leads to its damaged function

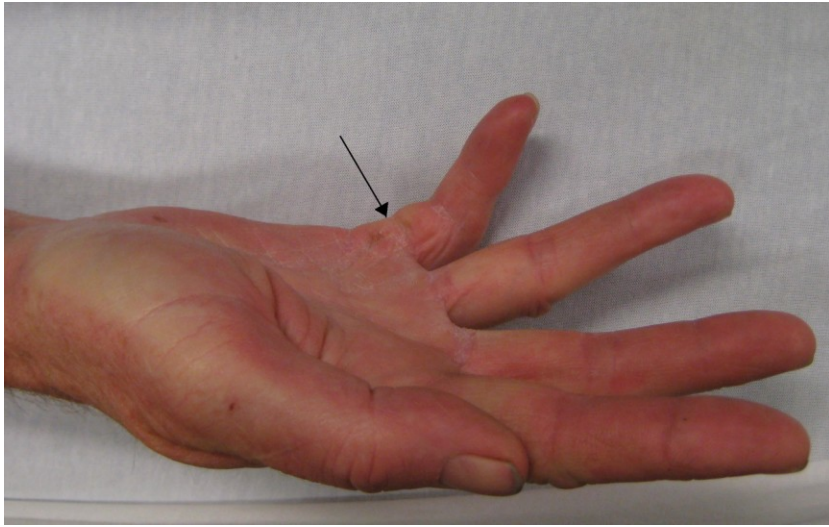


Torn meniscus

# Deformitas

- Permanent bodily malformation of the shape of and organ or part of the body

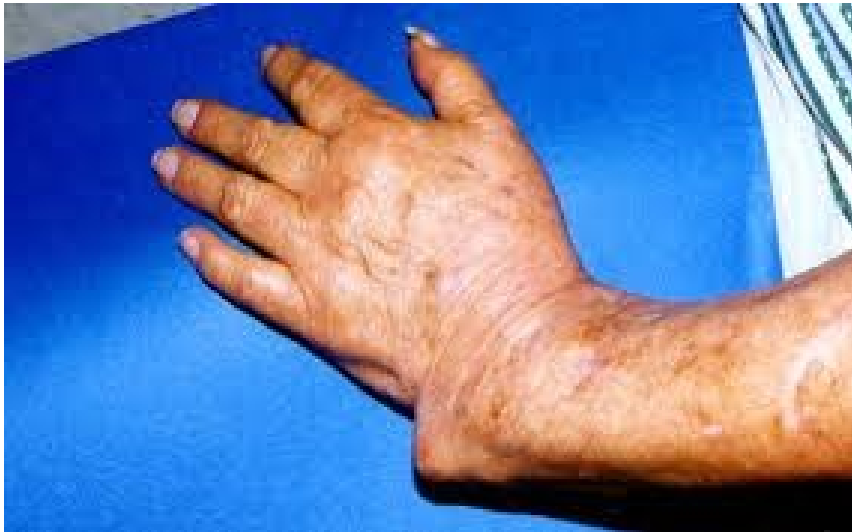



*Laesio – ligamentum –  
musculus – flexor – digitus  
– minimus – manus – lateris  
– sinister*

**ENDINGS?**

**Laesio ligamenti muscoli flexoris digiti minimi manus lateris sinistri**



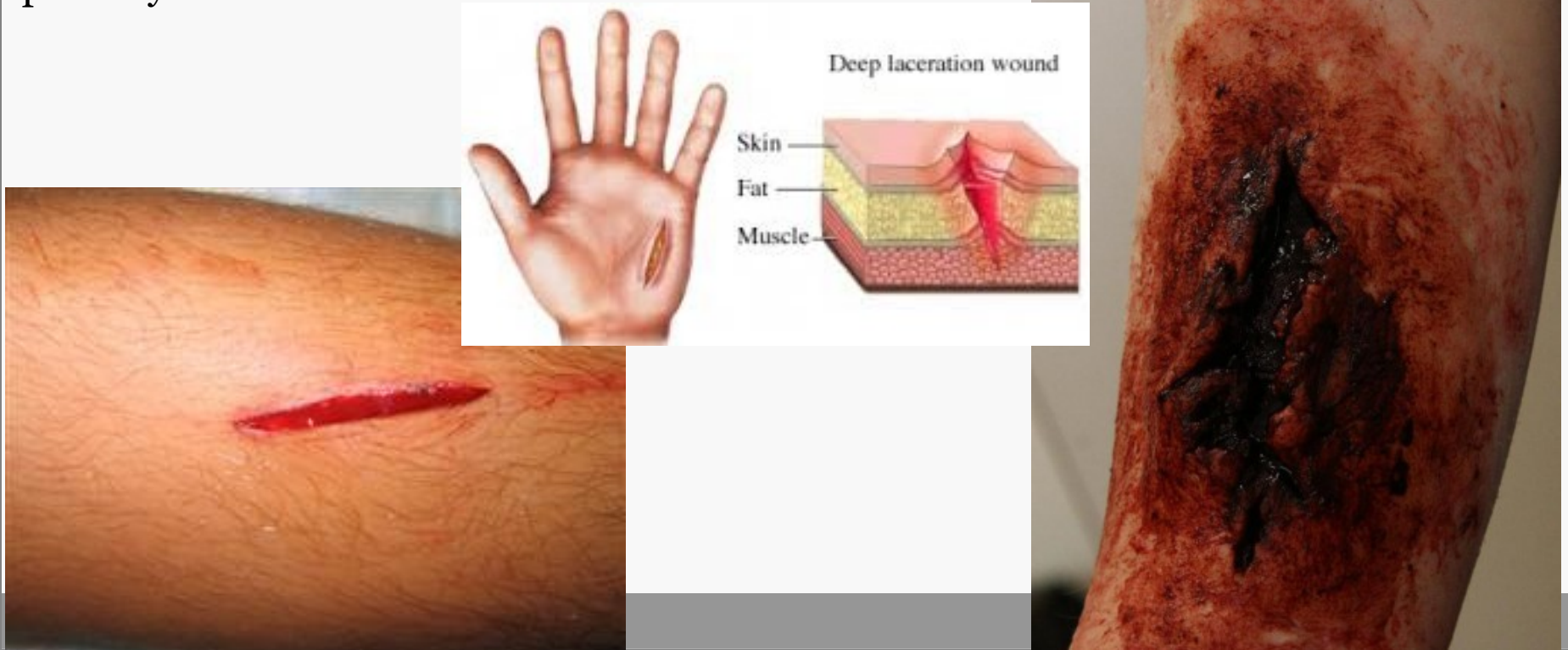*Deformitas antebrachii l.  
dx. grave* → *gravis*

**ANY MISTAKE?**

Laceratio, onis, f. = vulnus lacerum



**A torn ragged wound.** A wound produced by the tearing of body tissue. External lacerations may be small or large and may be caused in many ways, such as a blow from a blunt instrument, a fall against a rough surface, or an accident with machinery. Lacerations within the body occur when an organ is compressed or moved out of place by an external or internal force.



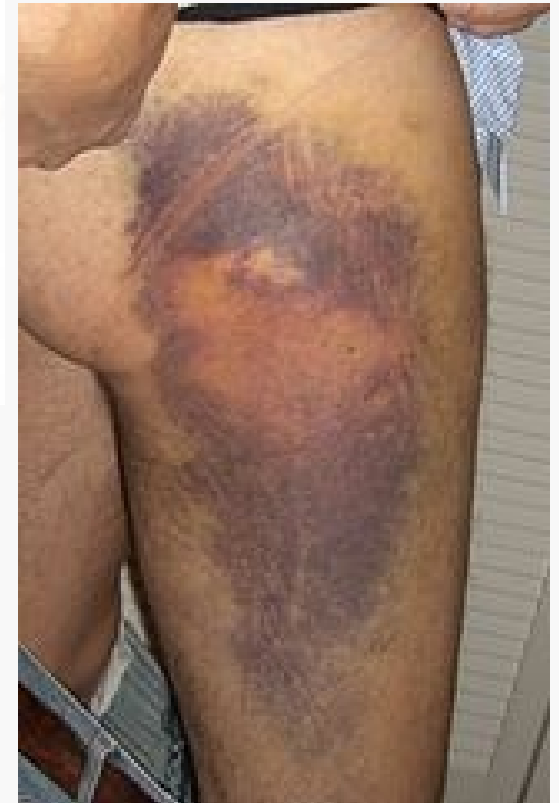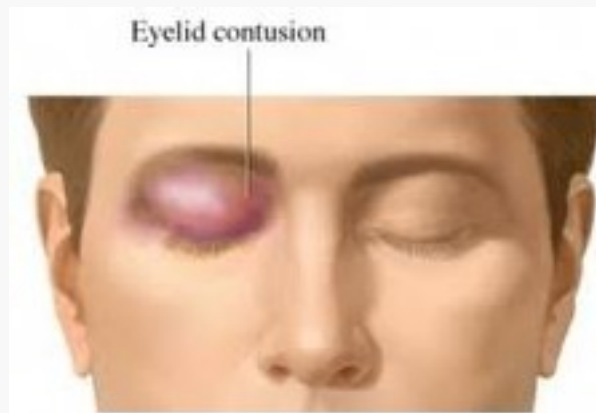Contusio, onis, f. = vulnus contusum



**Bruise wound**, an injury to tissues with skin discoloration and without breakage of skin. Blood from the broken vessels accumulates in surrounding tissues, producing pain, swelling, and tenderness, and the discoloration is the result of blood seepage just under the skin.

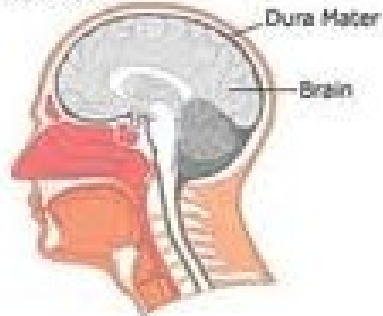
## Haematoma

=Localized swelling filled with blood

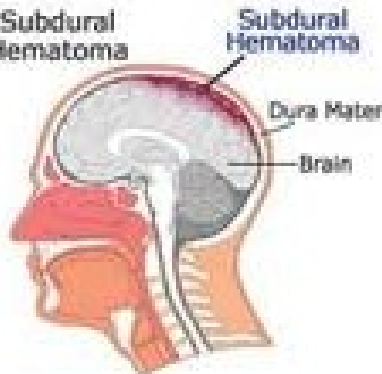


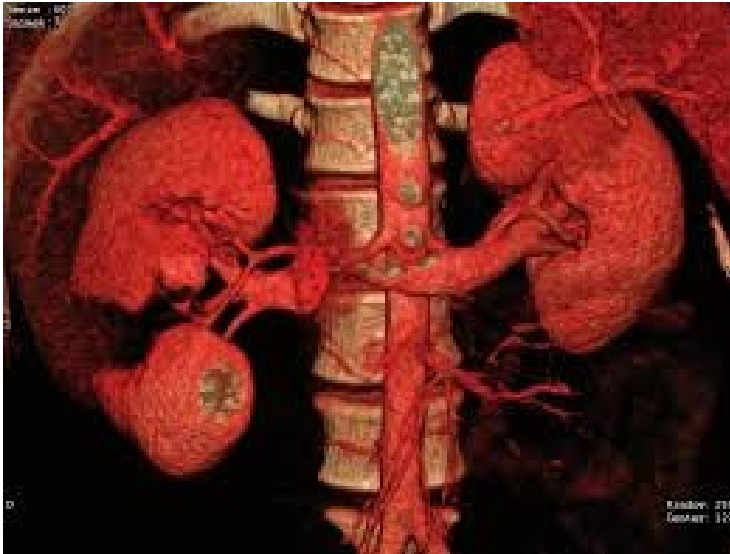## Subdural Hematoma

Normal



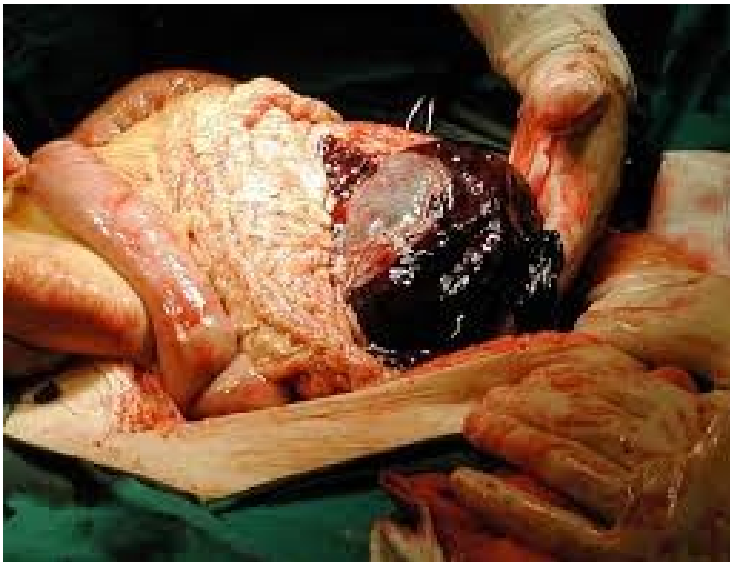Subdural Hematoma





*Laceratio renis sin. gr. IV.*

*ABBREVIATIONS?*

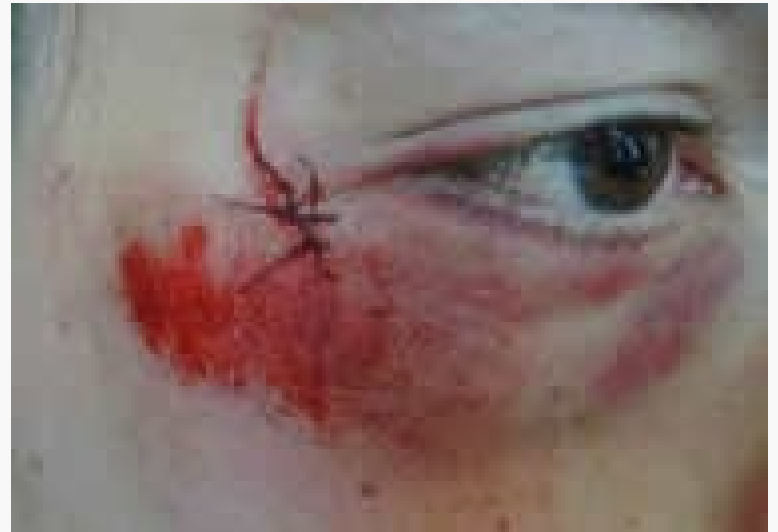
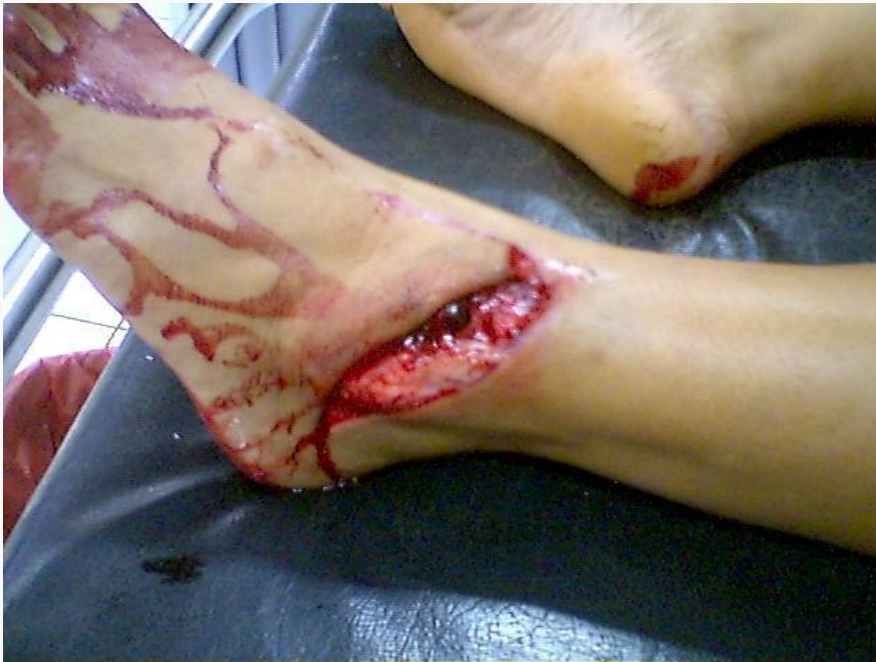
*Contusio lienis gr. III.*

*Exitus ex*

contusione lienis gradus tertii

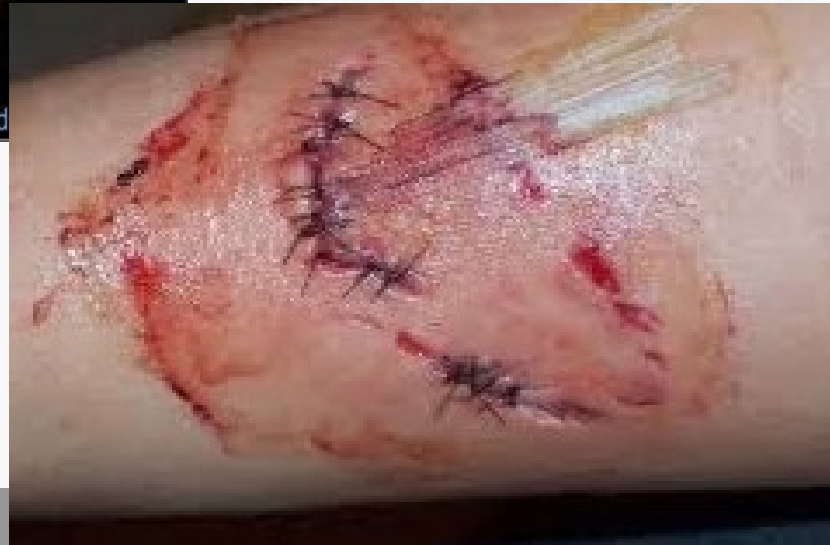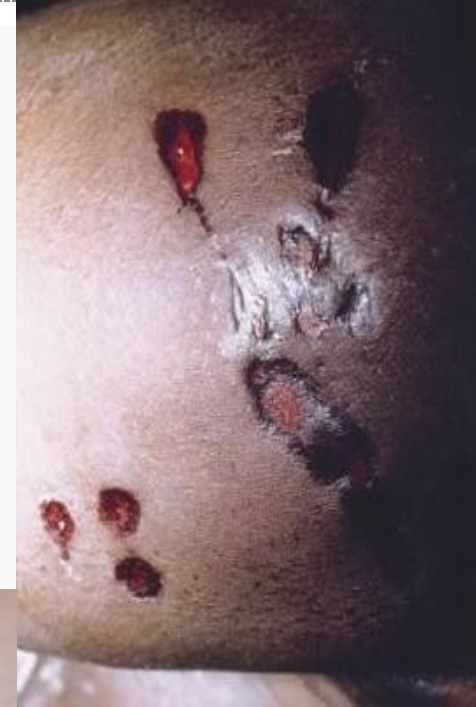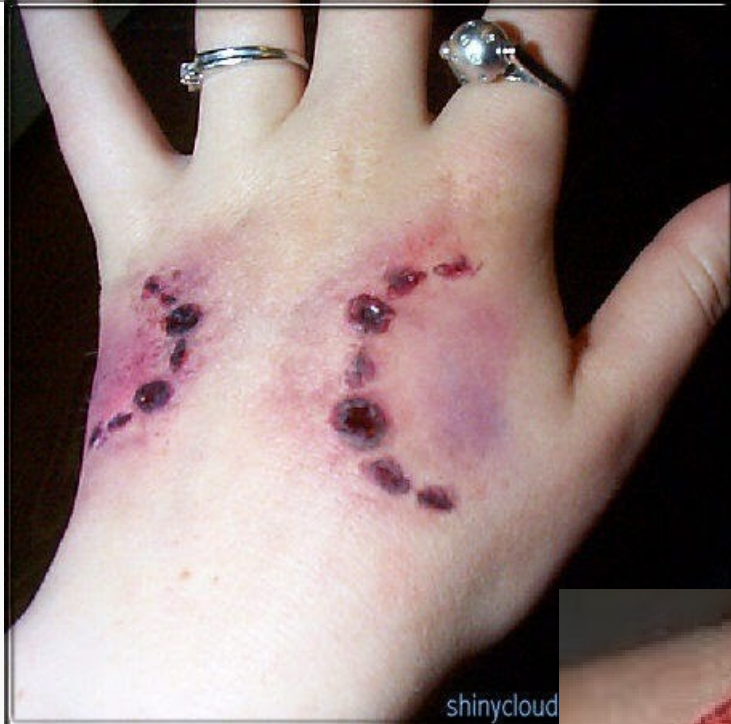# Vulnus contusolacerum



# Vulnus morsum



**Bite wound** – this wound is usually also contusolacerum (torn and bruise)



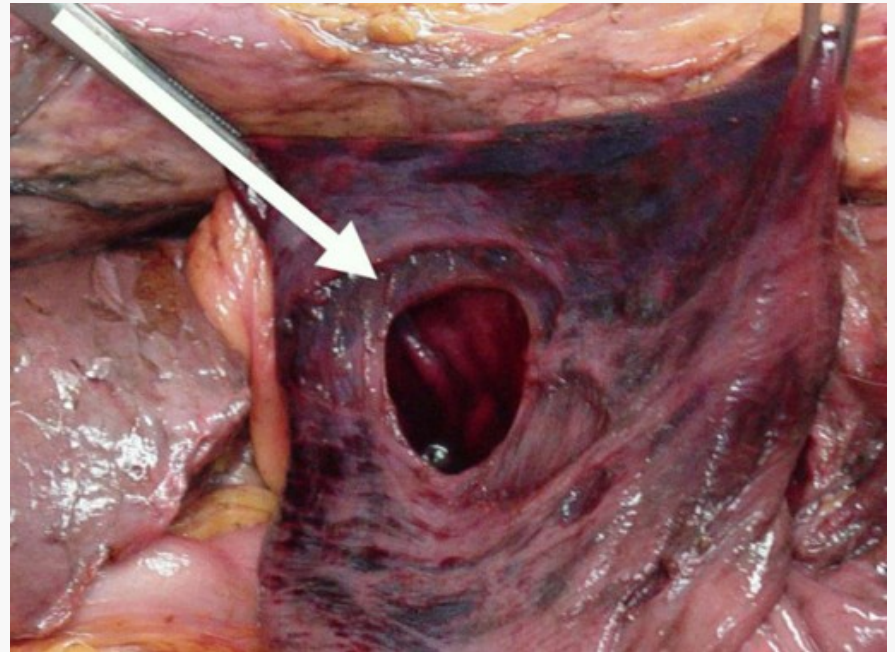
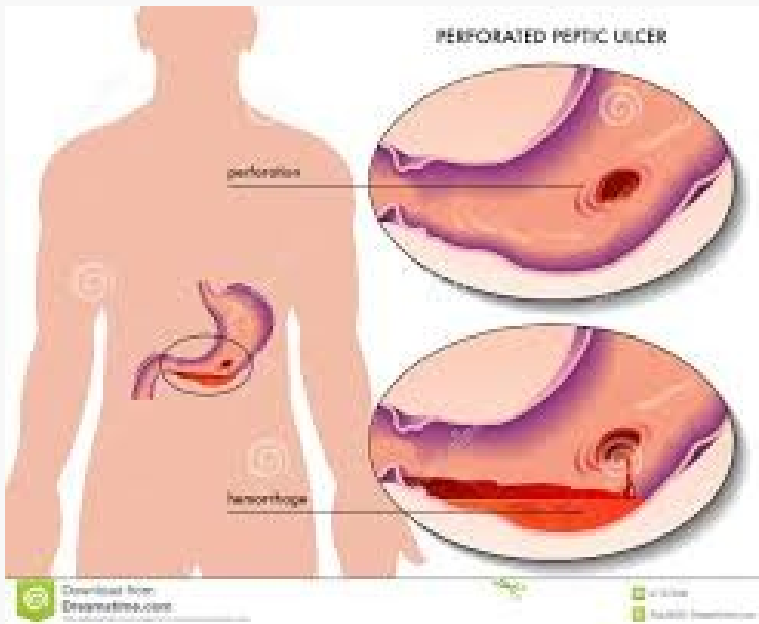


# Perforatio, onis, f.

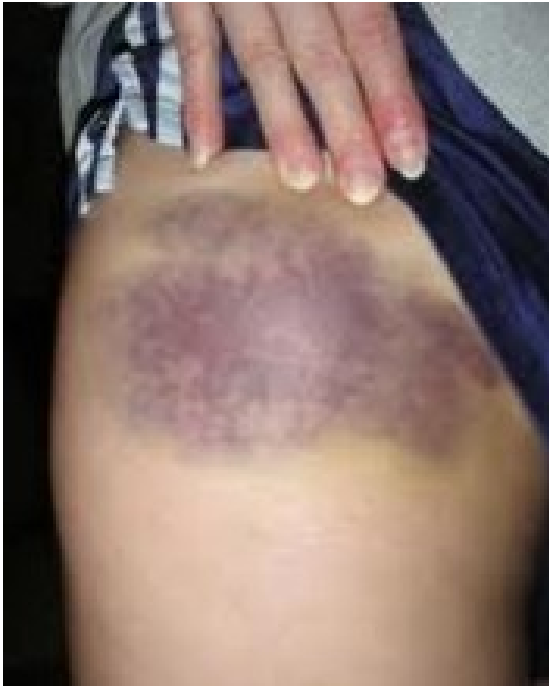

## **Perforation -**

Hole through the whole thickness of a tissue or membrane

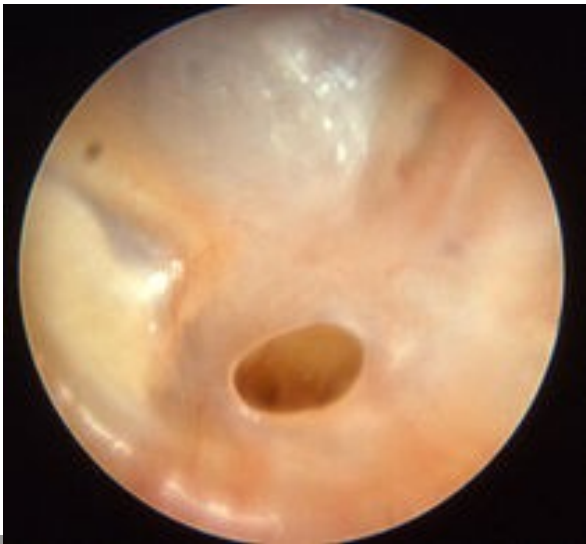

Perforatio fundi gastrici



*Contusio femoris lateris  
sinistri cum haematomate  
musculi quadricipitis femoris  
lateris sinistri*

***FILL IN MISSING ENDINGS***



*Perforatio membranae  
tympani*

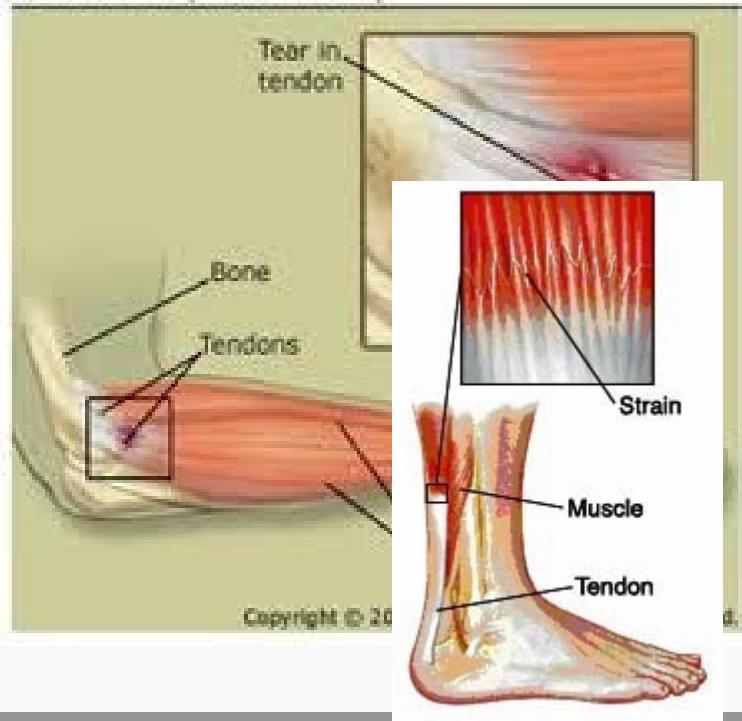*St. p.*  
perforationem membranae tympani

# Distensio, onis, f.

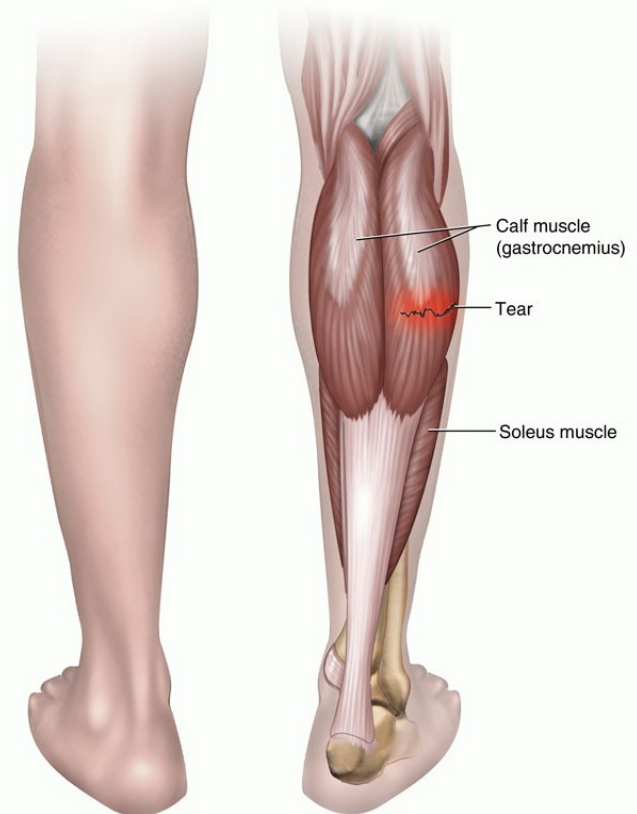


**strain** = an injury to a muscle or tendon in which the muscle fibres tear as a result of overstretching

Tendinitis (Elbow strain)



Calf Muscle Strain

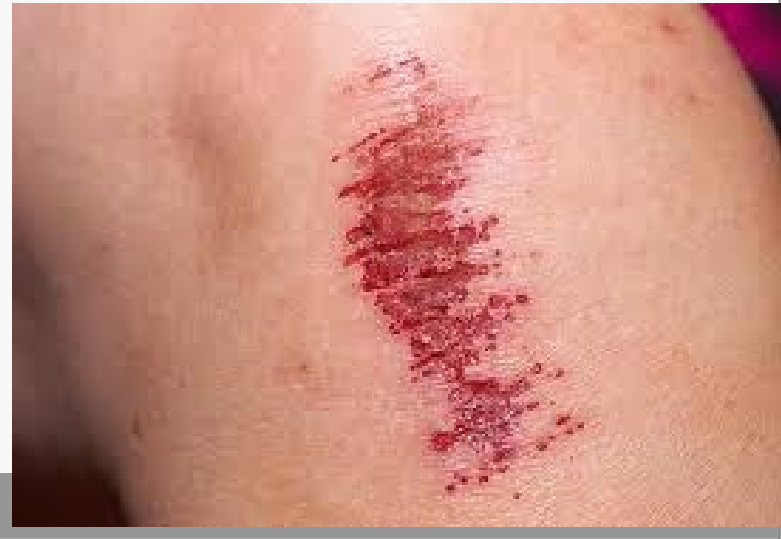
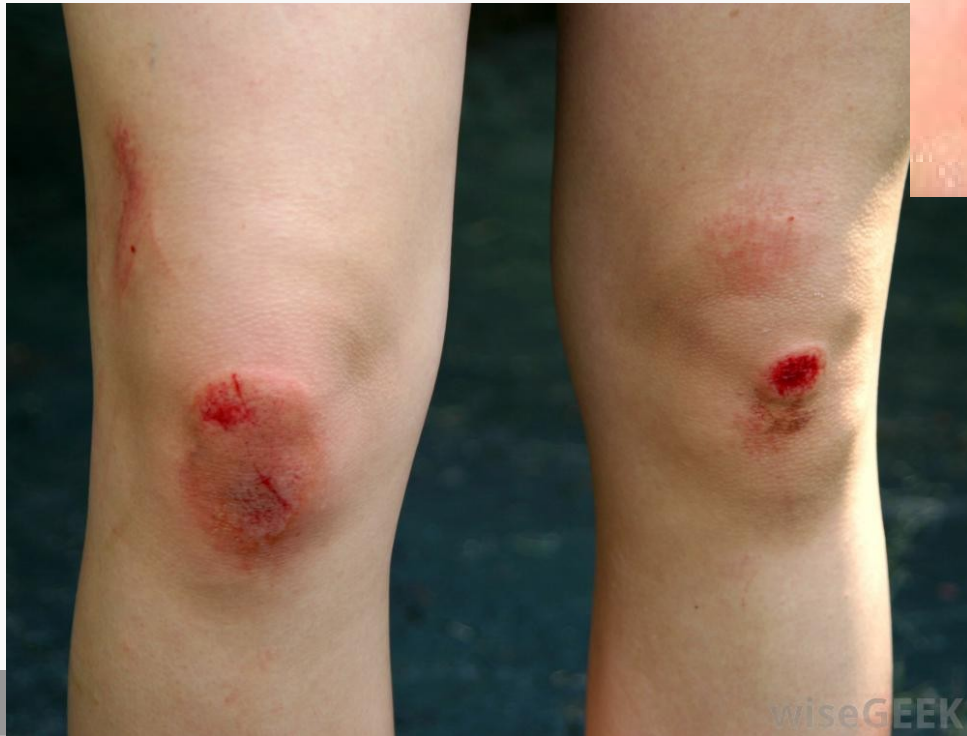
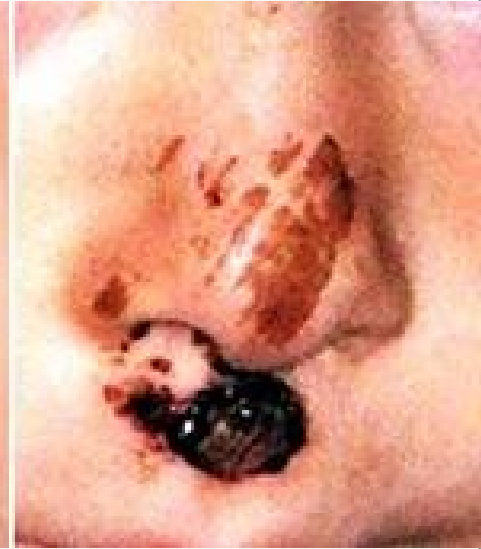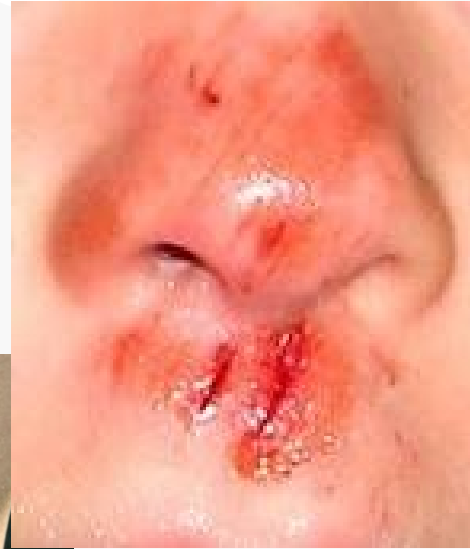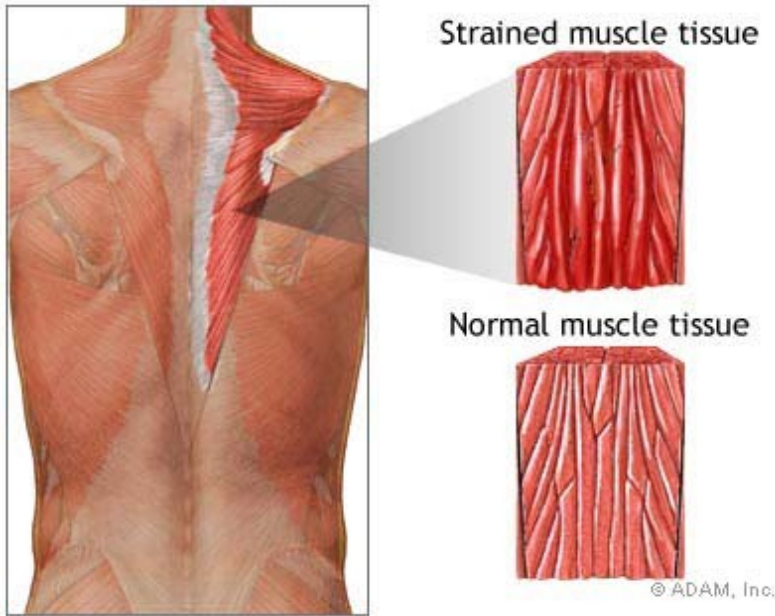
# Excoriatio, onis, f.



**scrape**

= skin surface removed

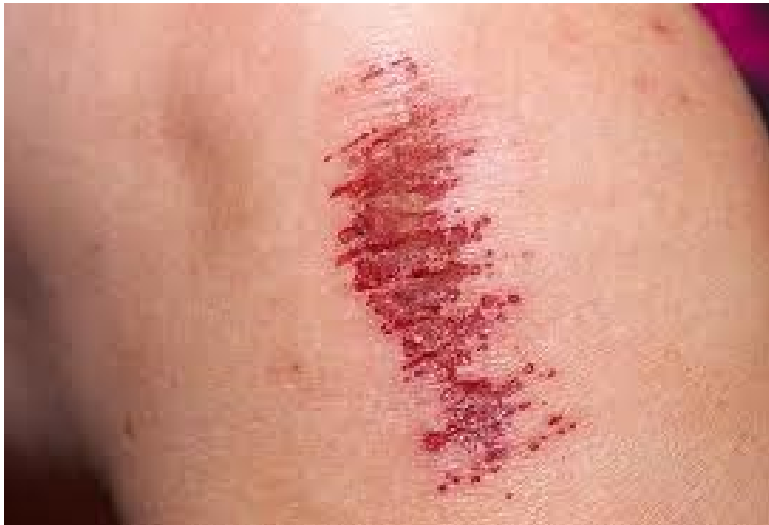



*Musculus trapezius l. dx.*

***Distensio***

musculi trapezii lateris dextri



*Excoriationes* faciei  
*(face)*, manus *(hand)*

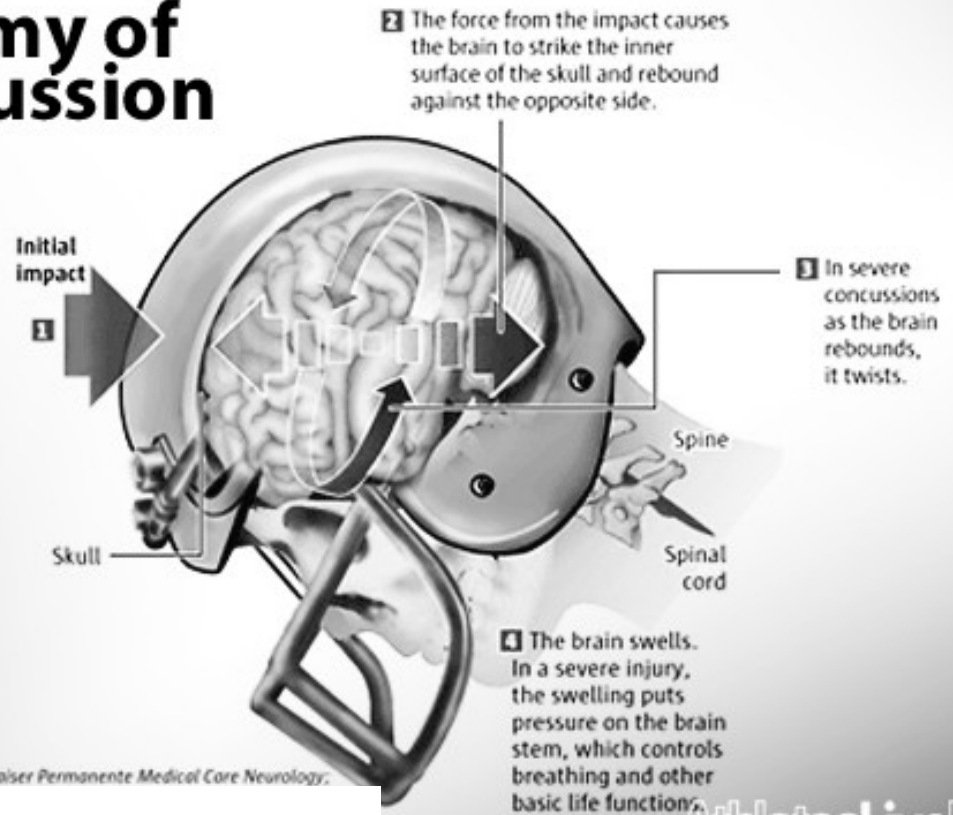
*l. utr. et* genus  
*(knee)*

*l. utr. superficiales*

# Commotio, onis, f.

**concussion** = a violent jarring or shaking that results in a disturbance of brain function

## Anatomy of a concussion



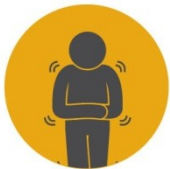Sources: Dr. Jay Rosenberg of Kaiser Permanente Medical Care Neurology.

AthletesLiveHere.com

### Common signs of concussion:



Dizziness



Nausea



Headaches



Light Sensitivity

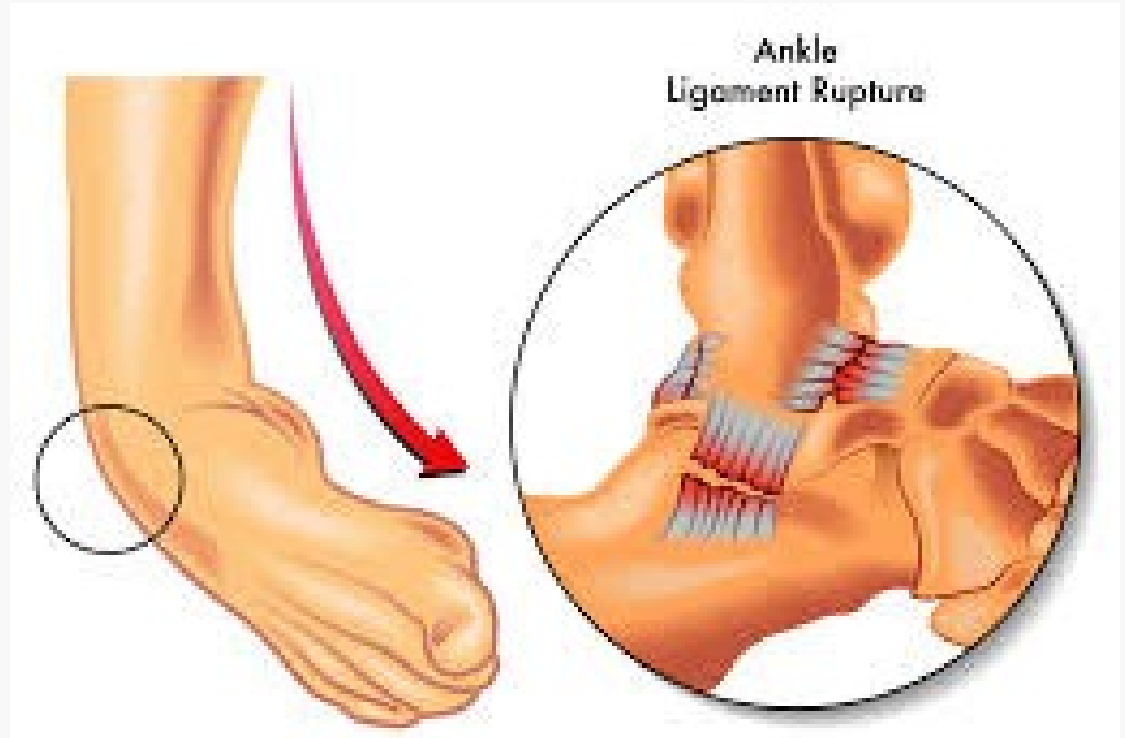
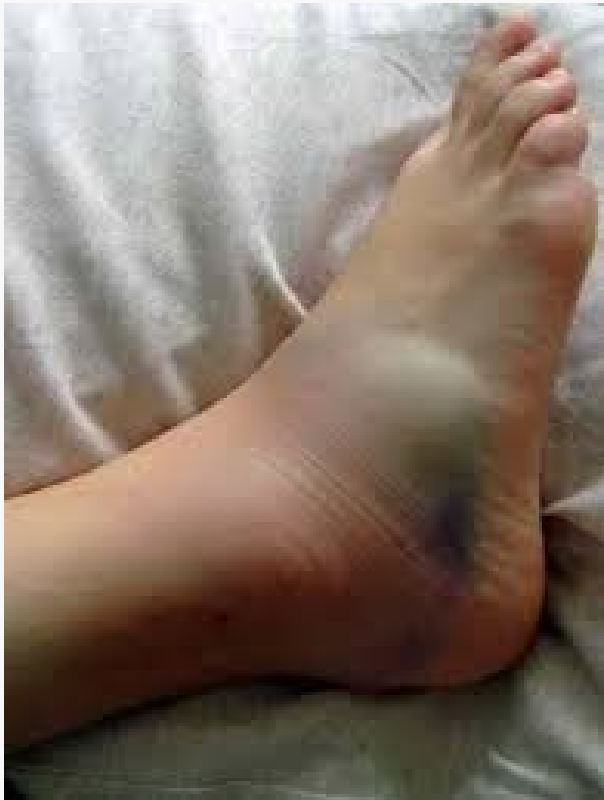
Confusion

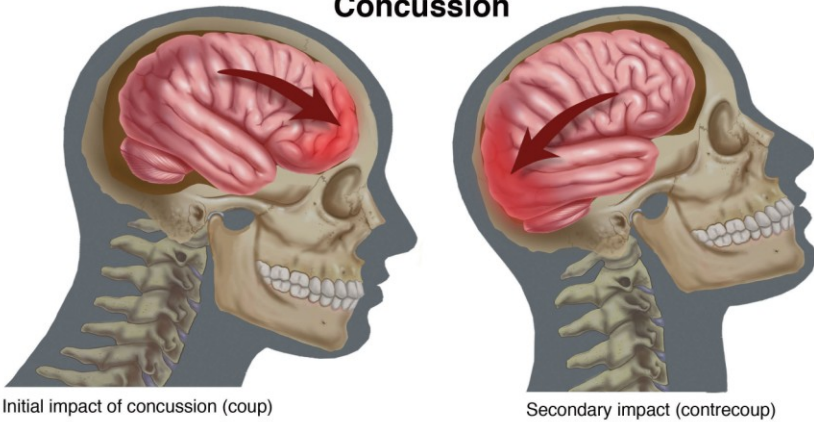
# Distorsio, onis, f.



**sprain, distorsion** = a joint injury in which some of the fibers of a supporting ligament are ruptured but the continuity of the ligament remains intact



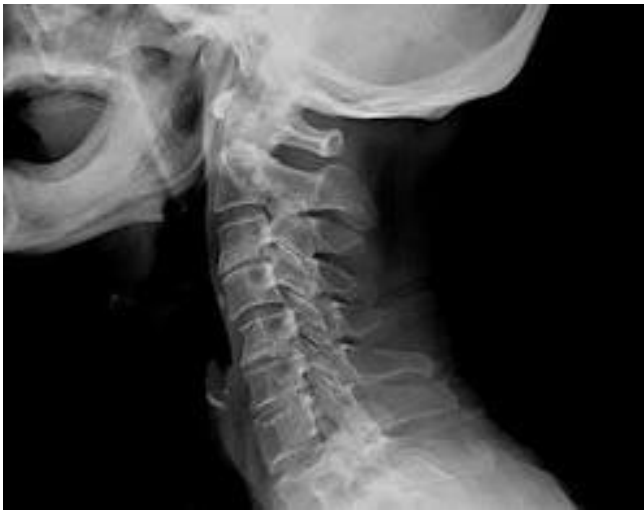Concussion



*sin. | cerebri | commotio | cum  
| l. | ossis | fissura | temporalis*

**PUT IN THE CORRECT  
ORDER**

**commotio cerebri cum fissura ossis temporalis l. sin.**



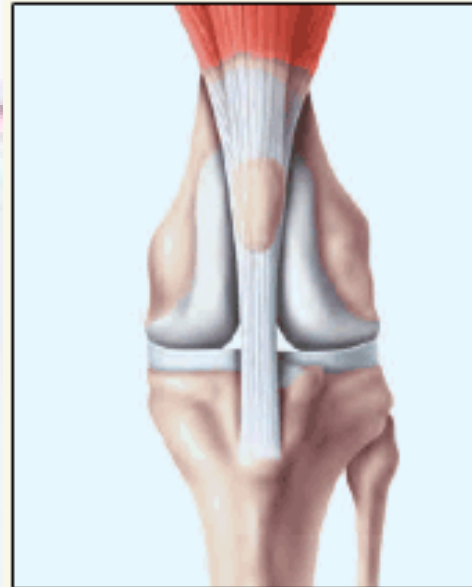
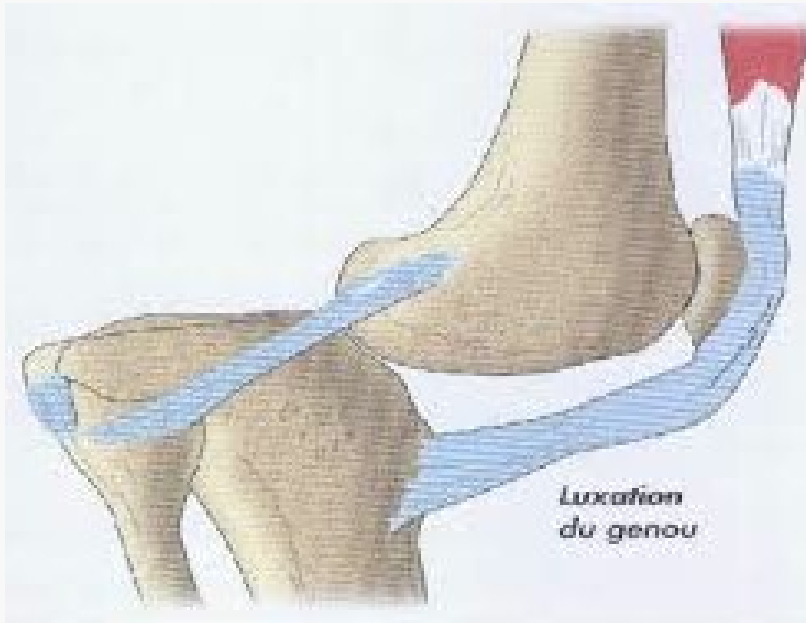
*Susp. distorsionis columnae  
vertebralis partis cervicalis*

**Susp. = suspicio**

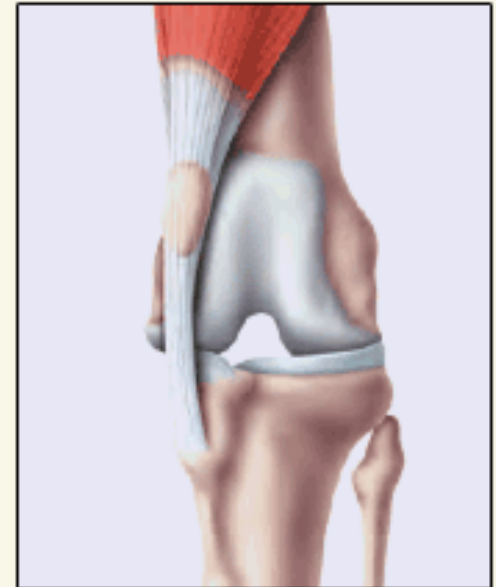

# Luxatio, onis, f.

**Luxation** = displacement of a bone from a joint



*Normal patellar alignment. The patella and quadriceps are in alignment and the patella is seated in the groove.*

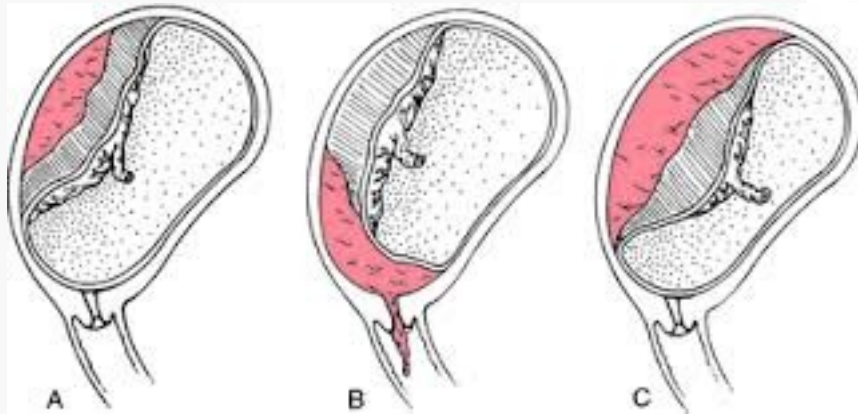


*Medial patellar luxation. The quadriceps and patella are medial to the trochlear groove and the tibia is rotated medially.*

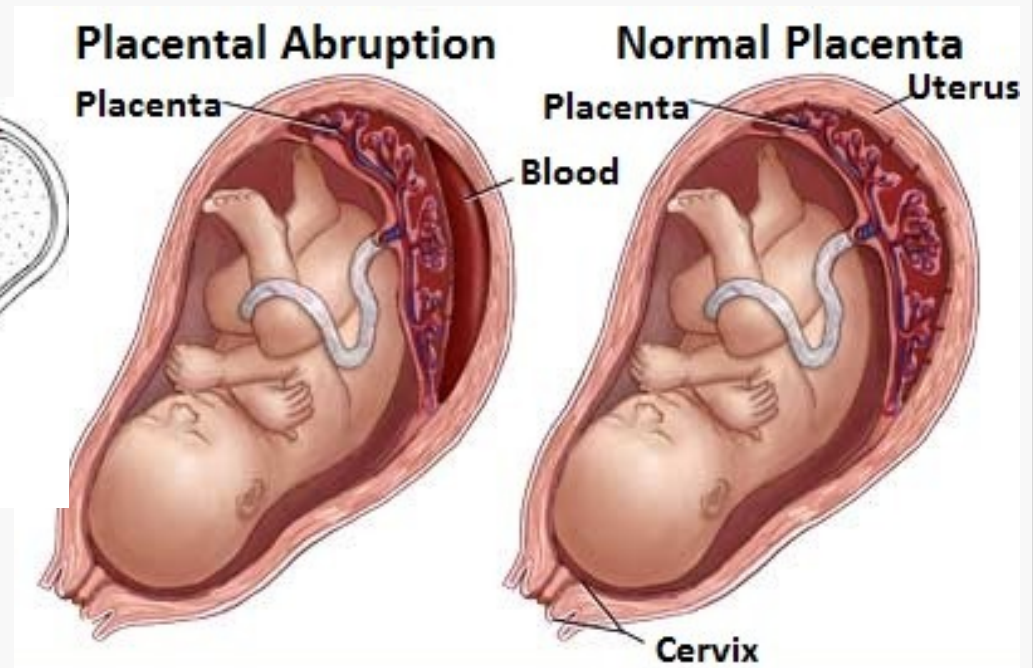
# Abruptio, onis, f.

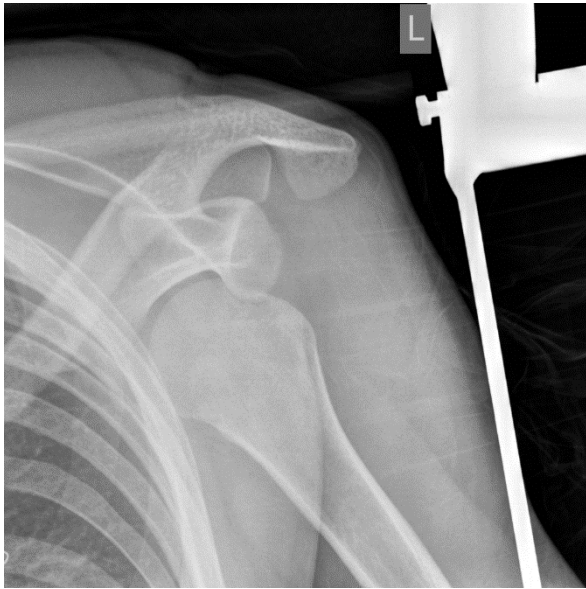

A tearing away, separation, or detachment



Placental abruption

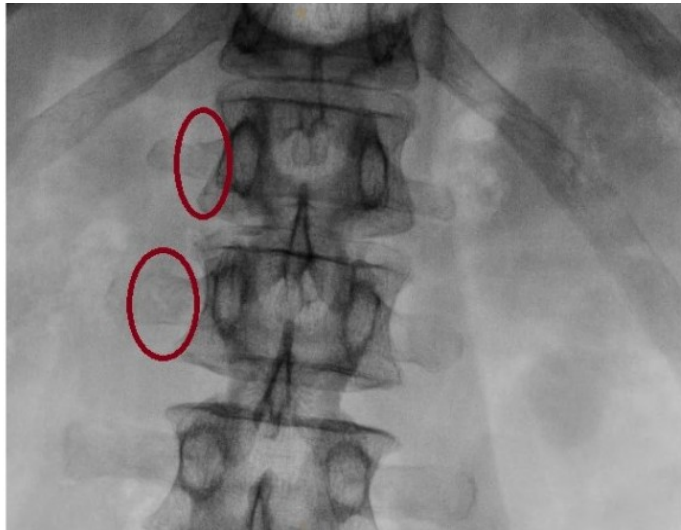




*humeri | fractura | luxatione | cum |  
comminutiva | proximalis | l. | partis |  
sin.*

***PUT IN THE CORRECT ORDER***

*fractura partis proximalis humeri l.  
sin. comminutiva cum luxatione*



*Abruptio partis ventralis  
corporis vertebrae C7 v. s.*

***OF THE 3RD, 4TH AND  
5TH LUMBAR VERTEBRA?***

***v.s. = verisimiliter***

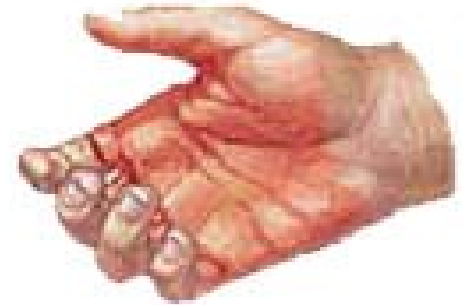# Combustio, onis, f.

## burn wound

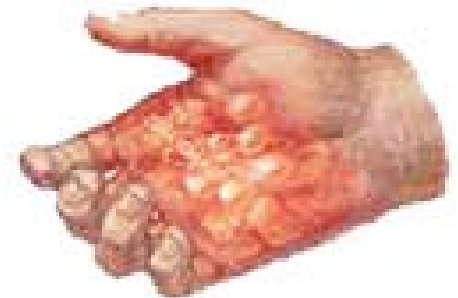Epidermis  
Dermis  
Subcutaneous  
Muscle



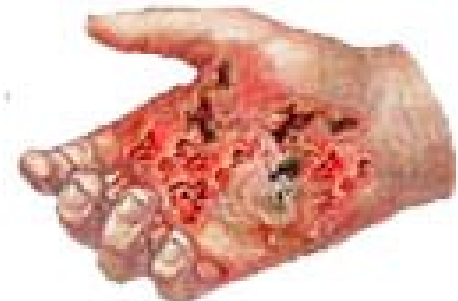Superficial  
(first degree)  
burn



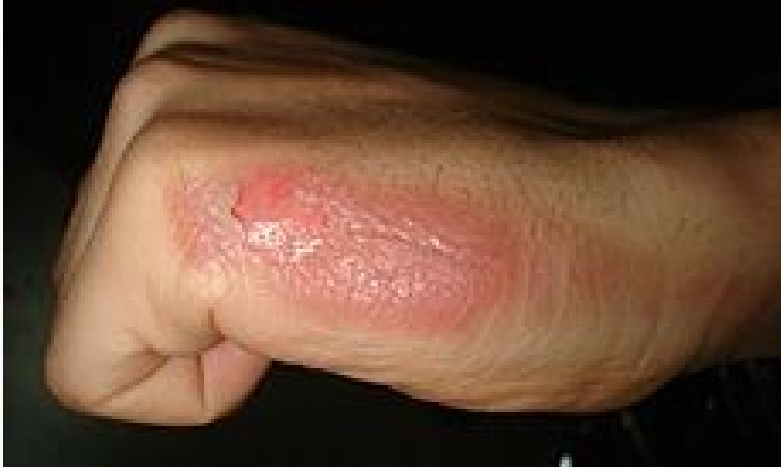Partial thickness  
(second degree)  
burn



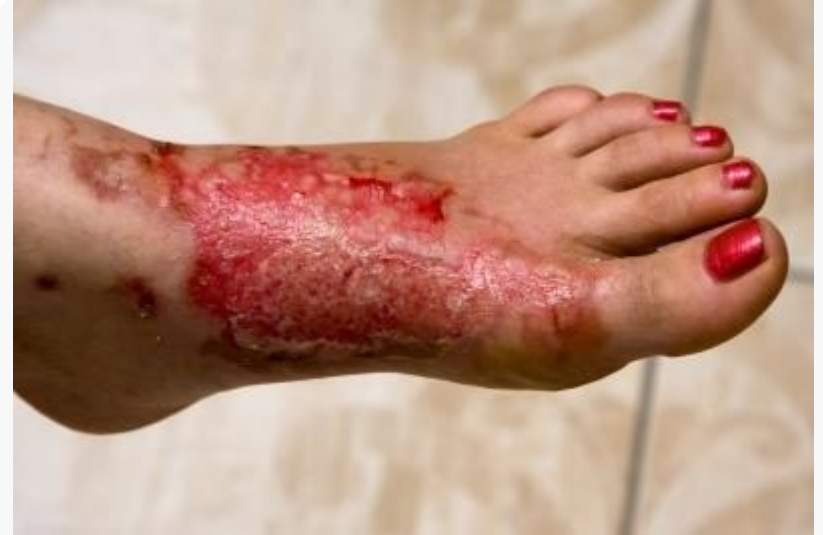Full thickness  
(third degree)  
burn



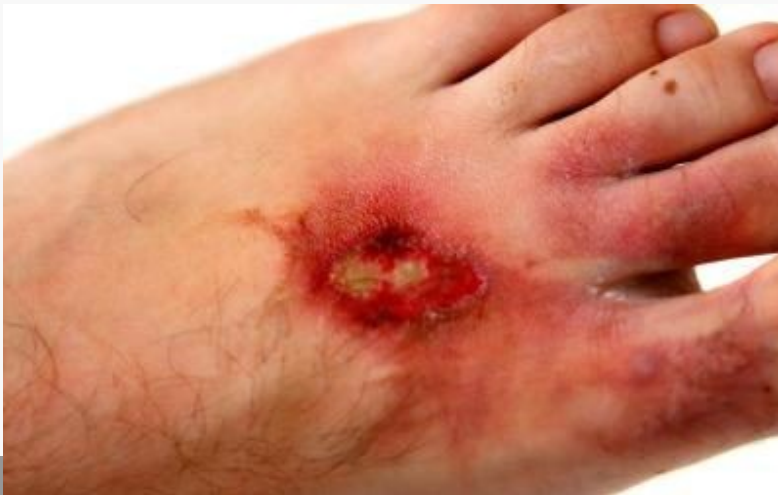# Combustio, onis, f.



2<sup>nd</sup> degree/grade burn



3<sup>rd</sup> degree/grade burn



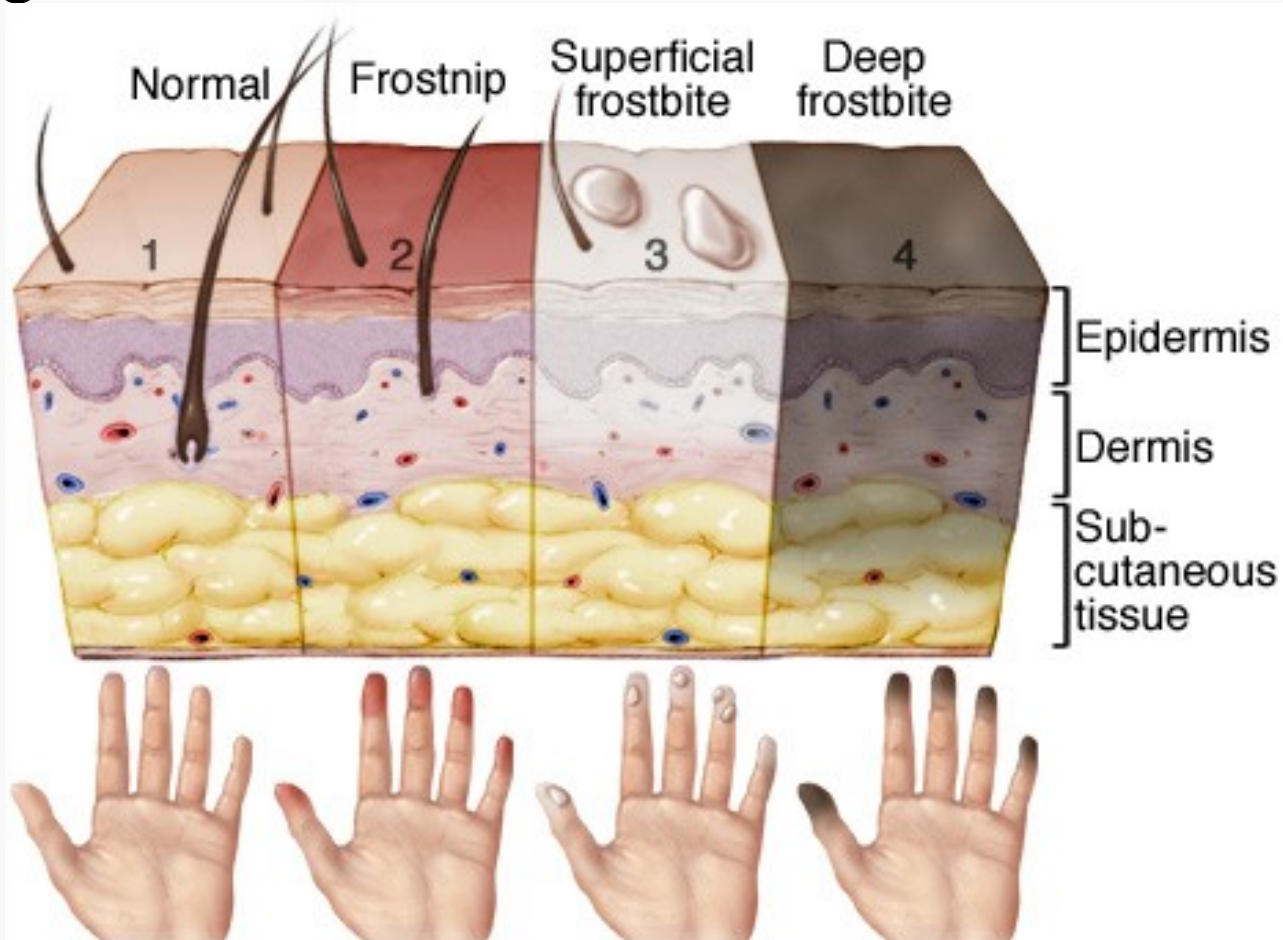
## **infected burn wound**

-change in the color of the skin around the burn, swelling, strange odor, the wound sinks deeper into the skin and gets larger, green or yellow pus develops, a fever

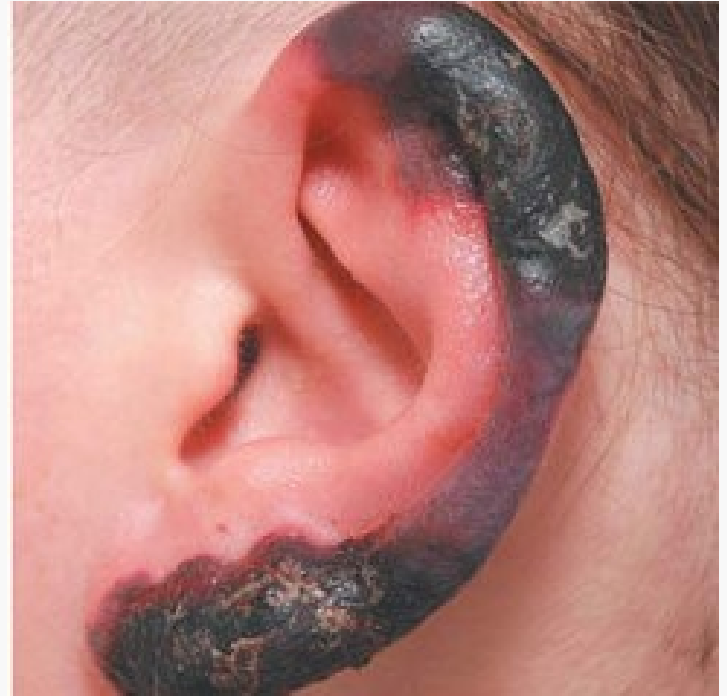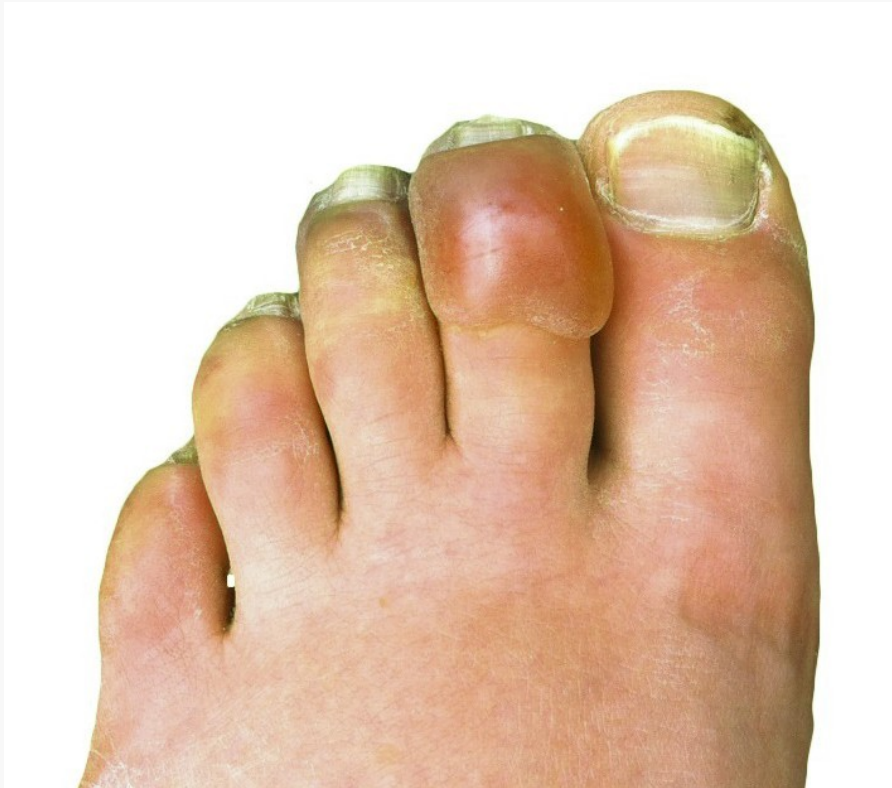# Congelatio, onis, f.

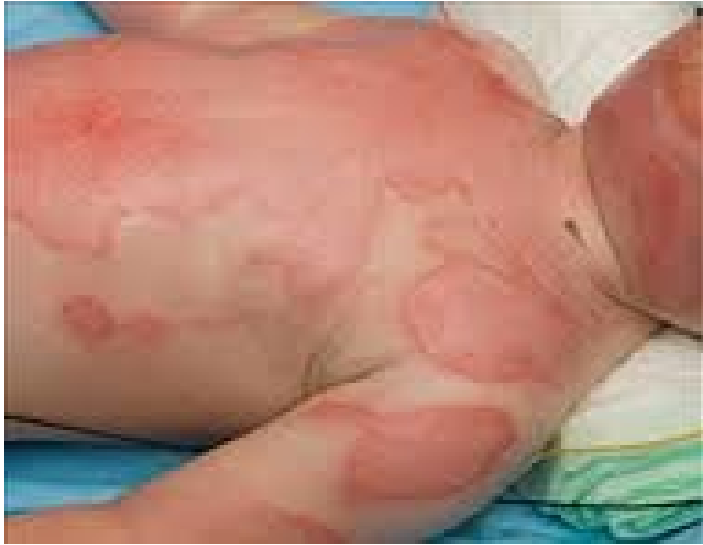

## frostbite



# Congelatio, onis, f.

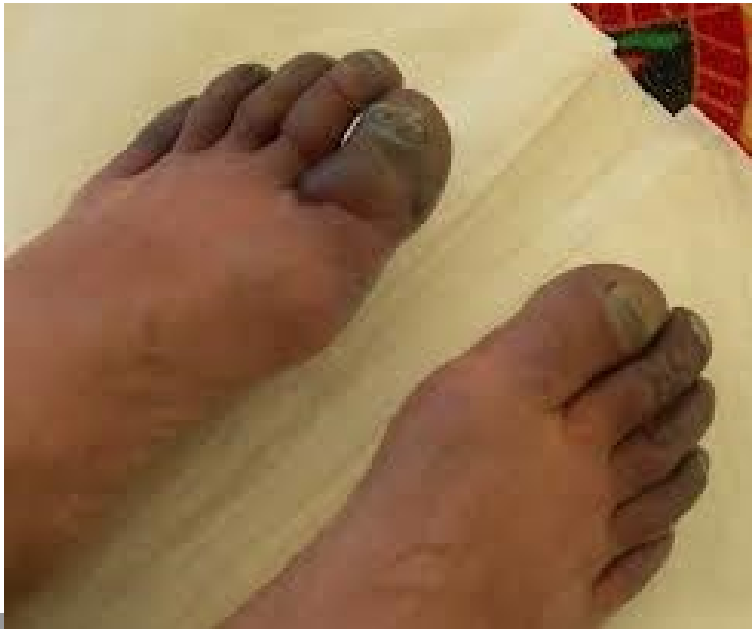



*Combustio thoracis, cervicis  
et faciei gr. II.*

***PLURAL?***

combustiones thoracis, cervicis et  
faciei gradus secundi



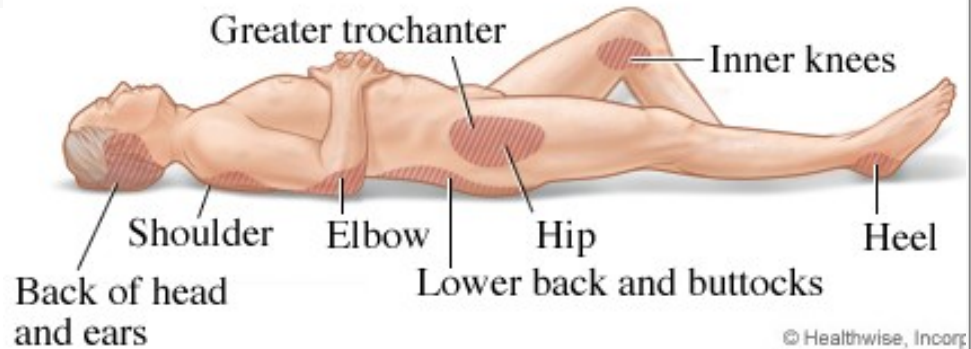
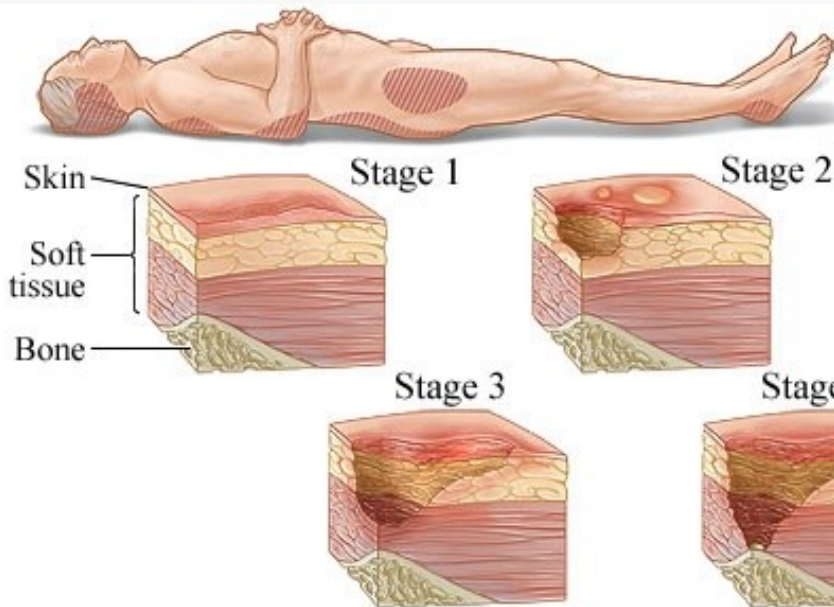
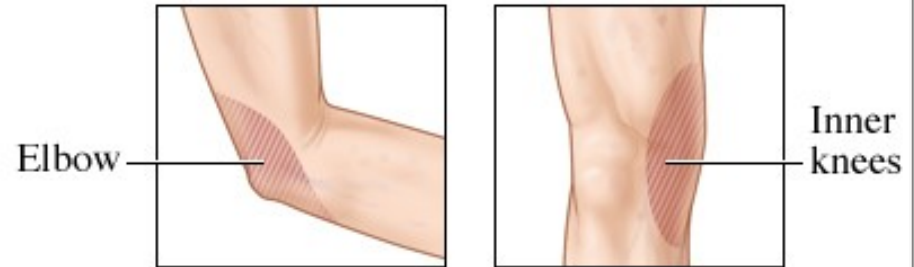
*Congelationes extremitatis  
inferioris l. utr. gr. I.*

***OF THE FOURTH GRADE?***



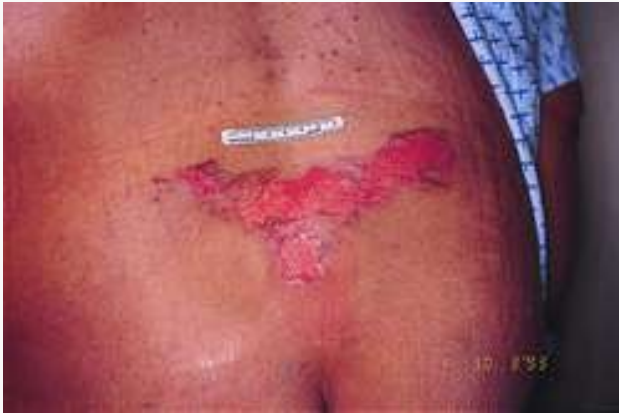# Decubitus, us, m.

**bedsore** – pressure ulcer due to local interference with circulation; persons most at risk are those who are emaciated (nutritionally deficient in protein), obese, immobilized by traction or anything else, diabetic, or suffering from a circulatory disorder.

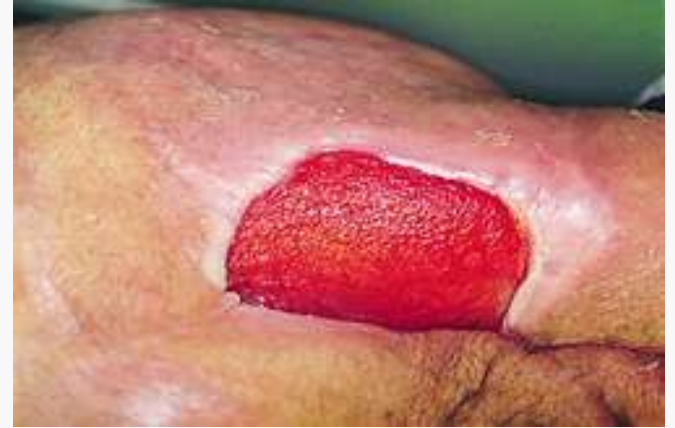

© Healthwise, Incorp

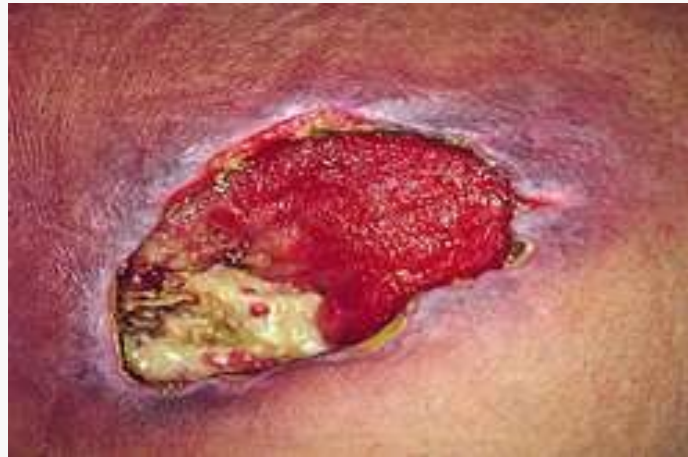# Decubitus, us, m.



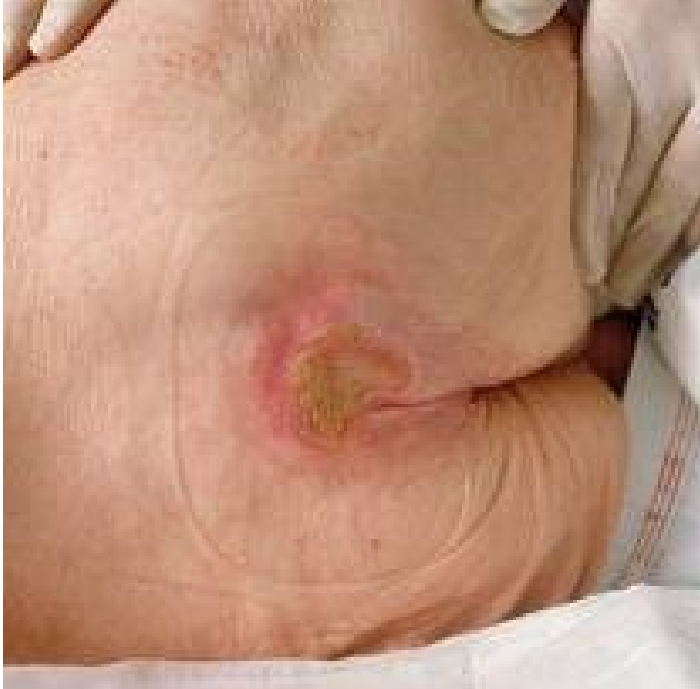stage 1 pressure ulcer



stage 2 pressure ulcer



stage 3 pressure ulcer



*Decubitus regionis*

*calcanei*

*(heel bone) et*

*ossis sacri*

*(sacral bone) gr. II.*