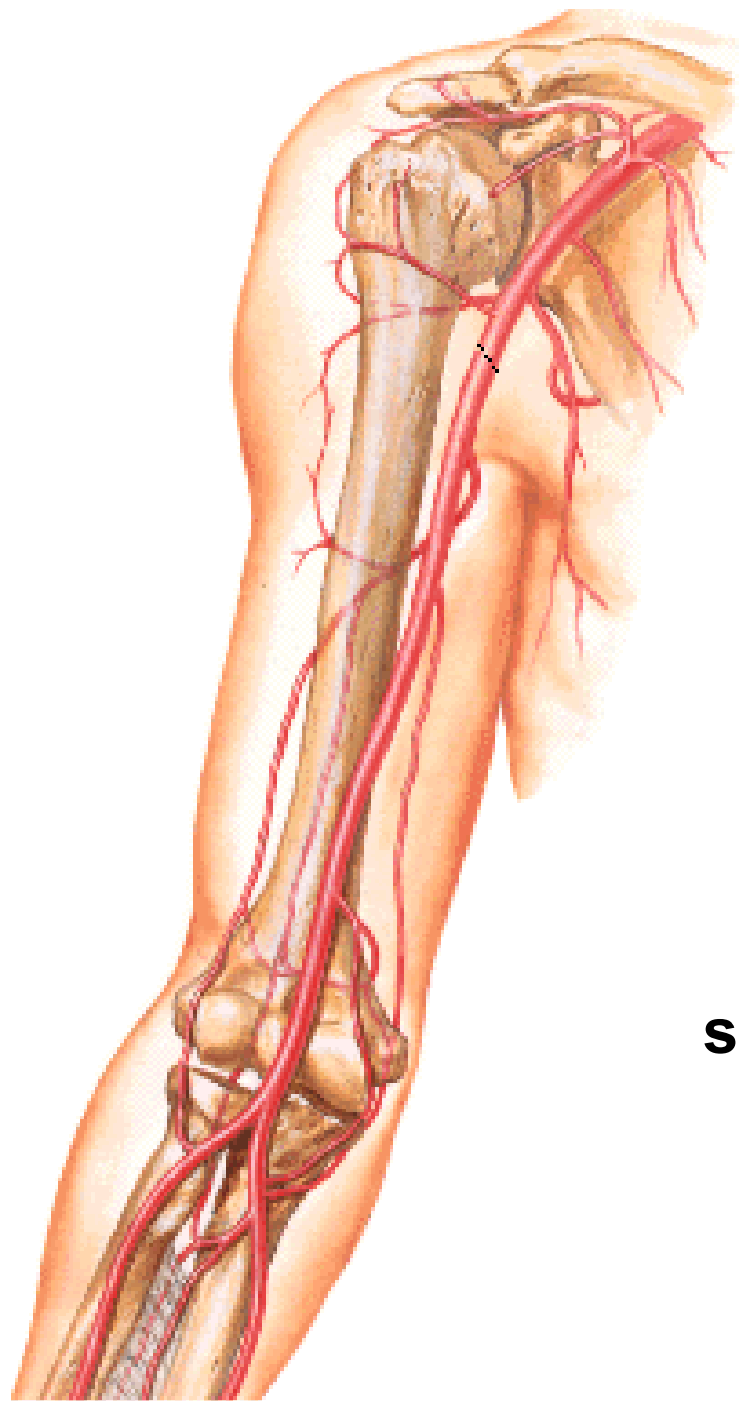


ARTERIES OF THE UPPER LIMB

II.

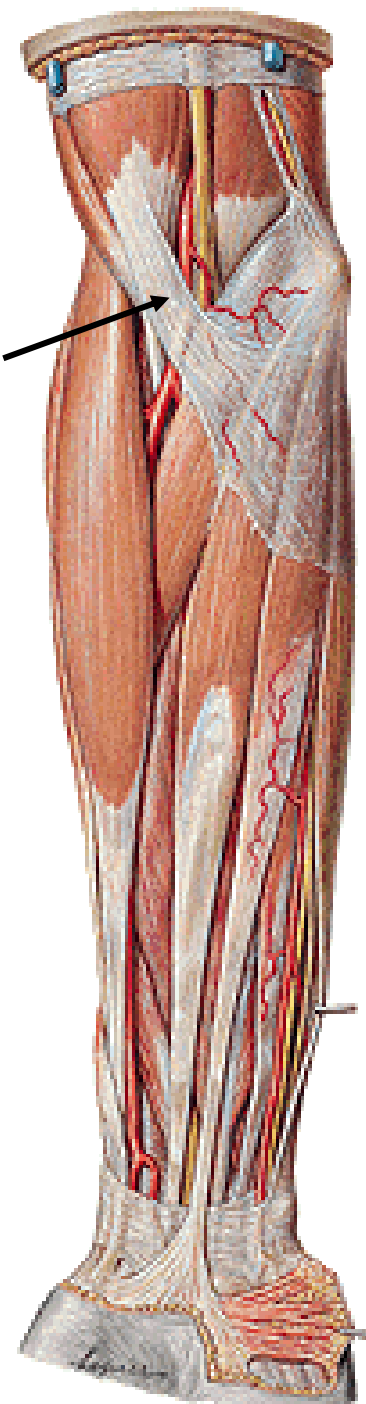

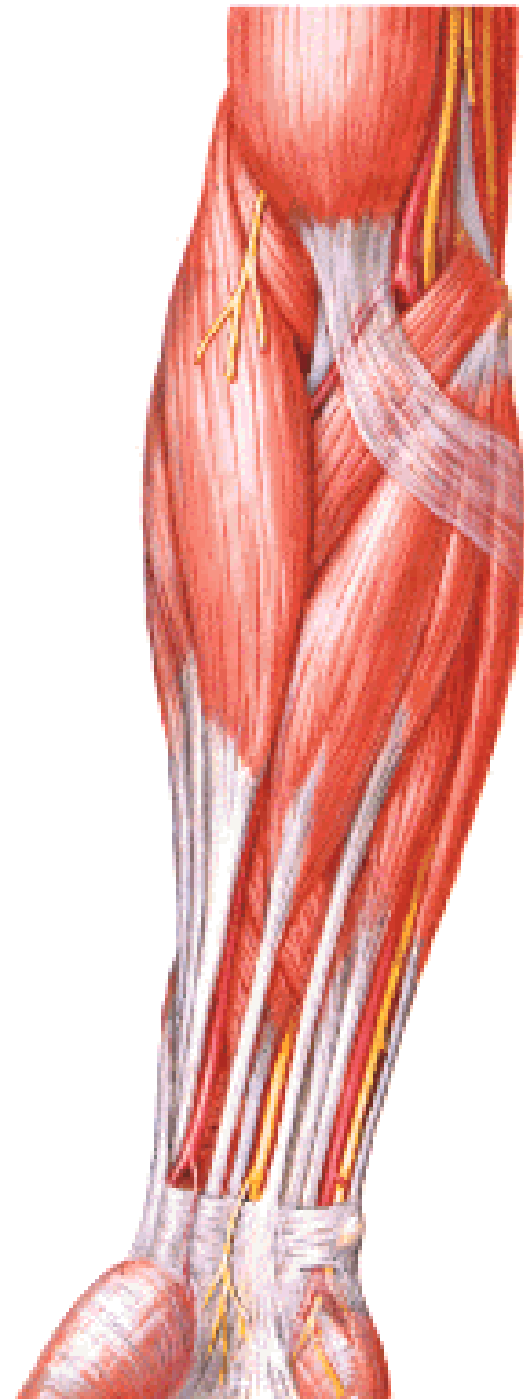
A. BRACHIALIS

aponeurosis m. bicipitis
brachii



sulcus bicipitalis medialis





MUSCULI ANTEBRACHII

Anterior group:

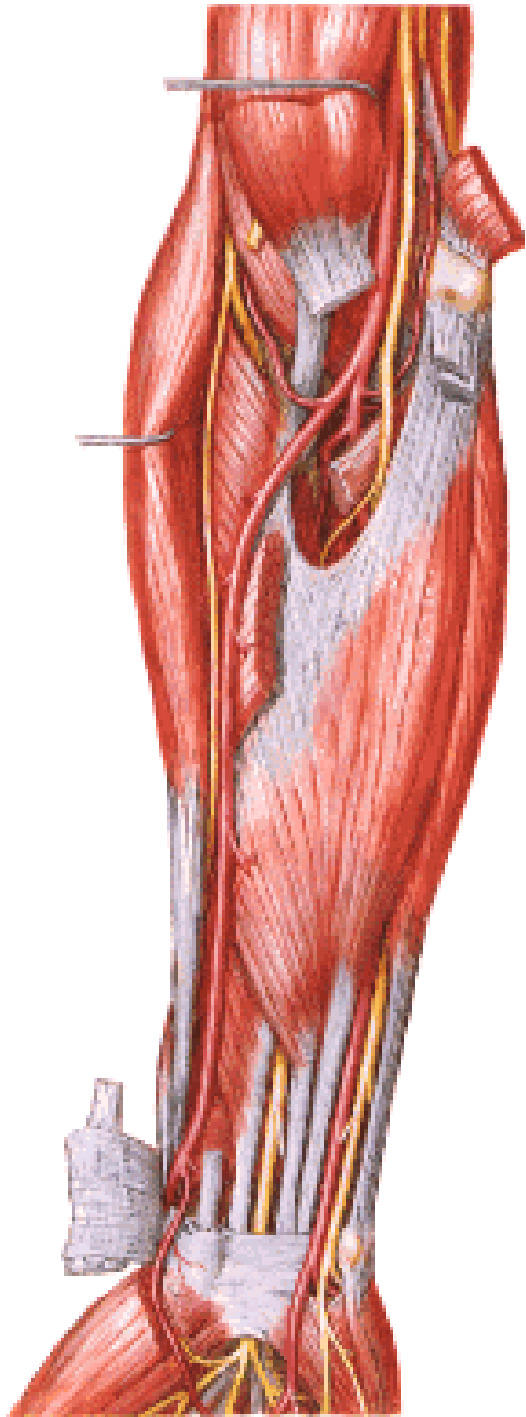
Superficial layer:

M. pronator teres

M. flexor carpi radialis

M. palmaris longus

M. flexor carpi ulnaris

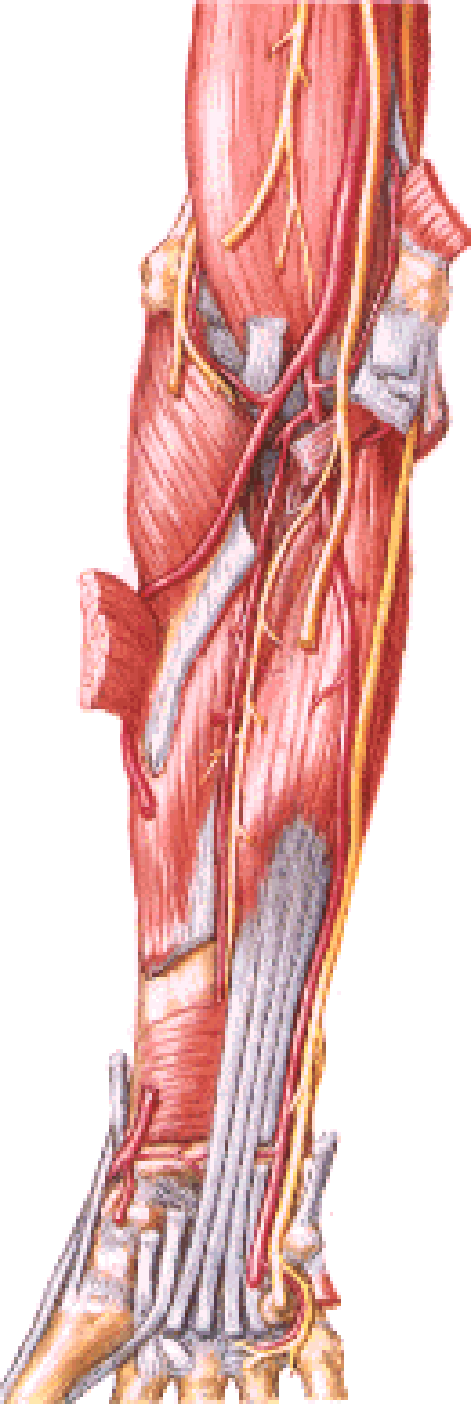


MUSCULI ANTEBRACHII

Anterior group:

Intermediate layer:

M. flexor digitorum superficialis



MUSCULI ANTEBRACHII

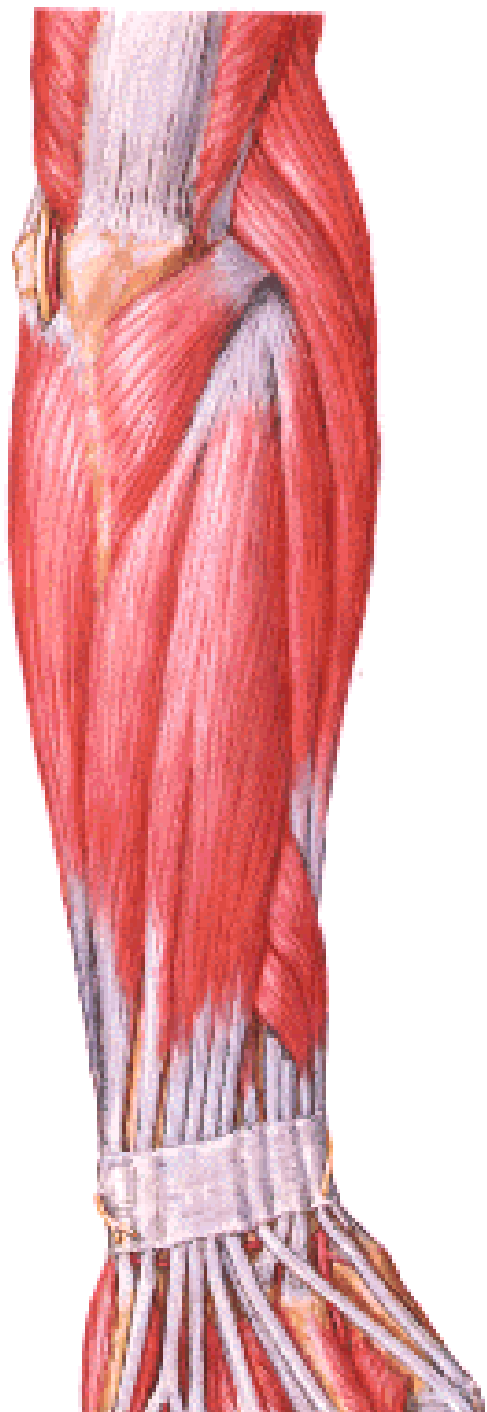Anterior group:

Deep layer:

M. flexor digitorum profundus

M. flexor pollicis longus

M. pronator quadratus



MUSCULI ANTEBRACHII

Posterior group:

Superficial layer:

M. extensor digitorum

M. extensor digiti minimi

M. extensor carpi ulnaris

MUSCULI ANTEBRACHII

Posterior group:

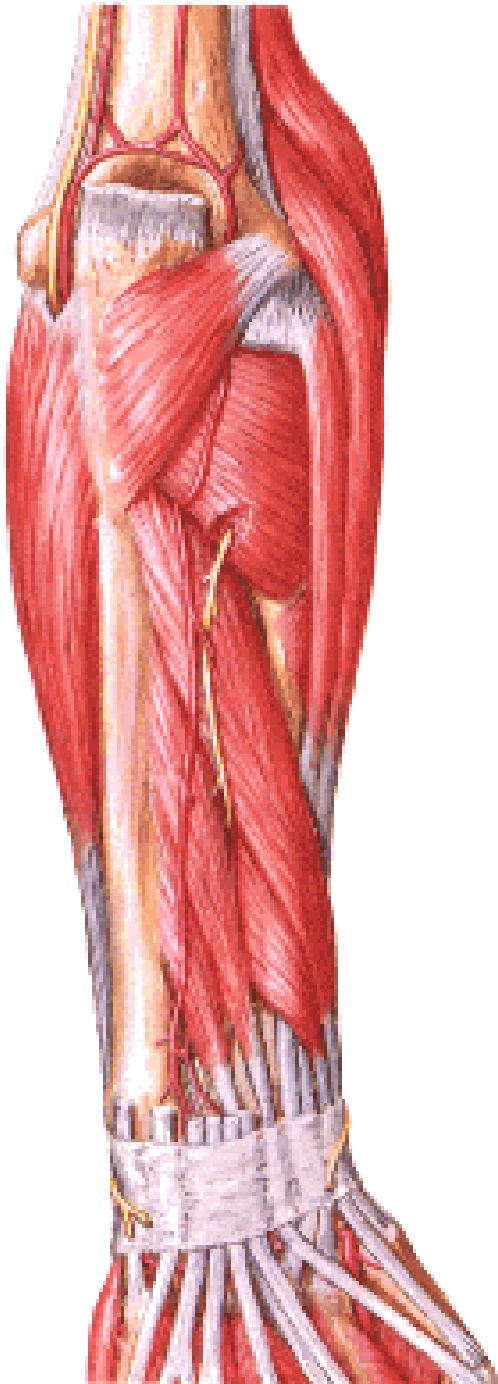
Deep layer:

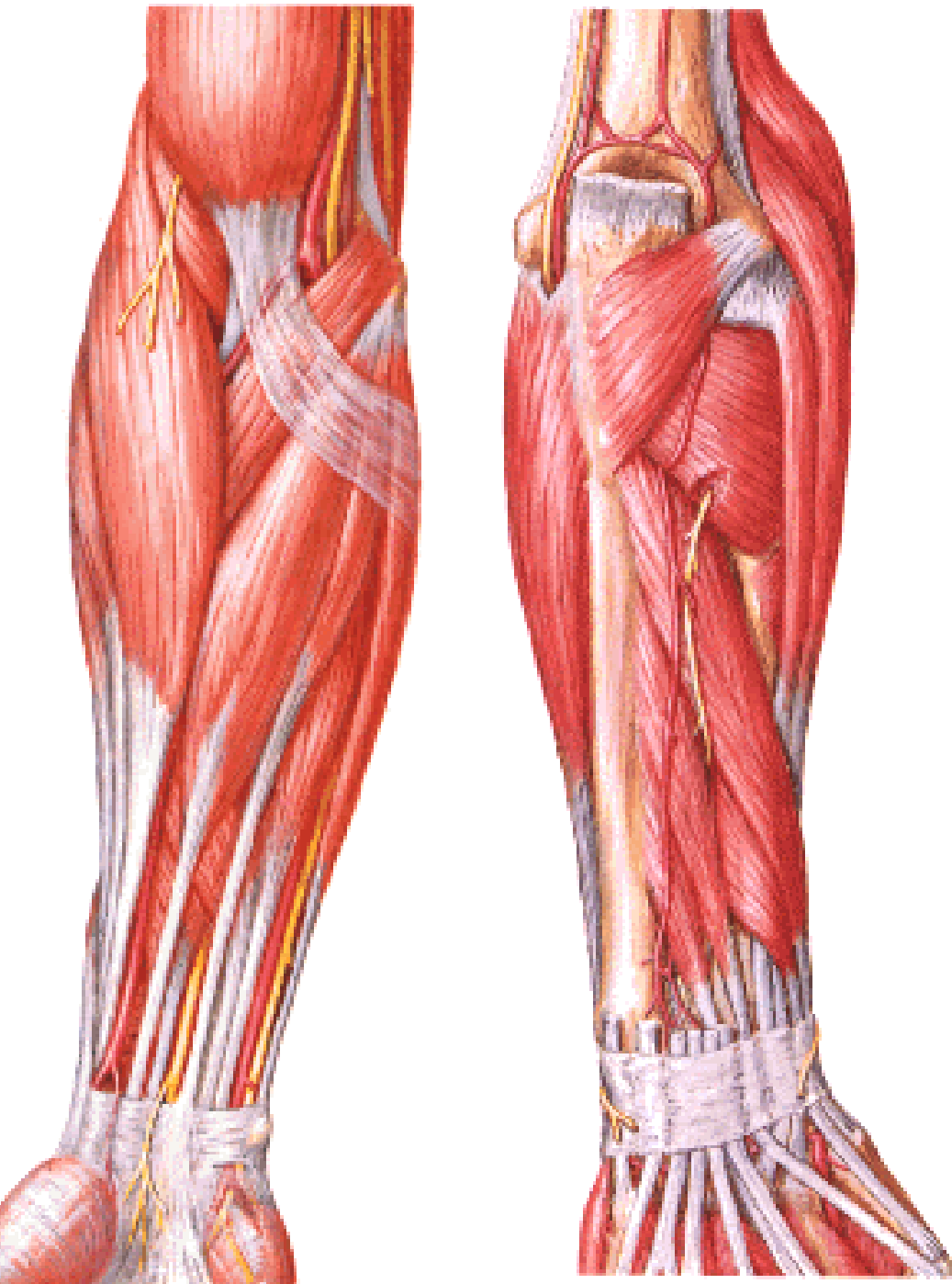
M. abductor pollicis longus

M. extensor pollicis brevis

M. extensor pollicis longus

M. extensor indicis





MUSCULI ANTEBRACHII

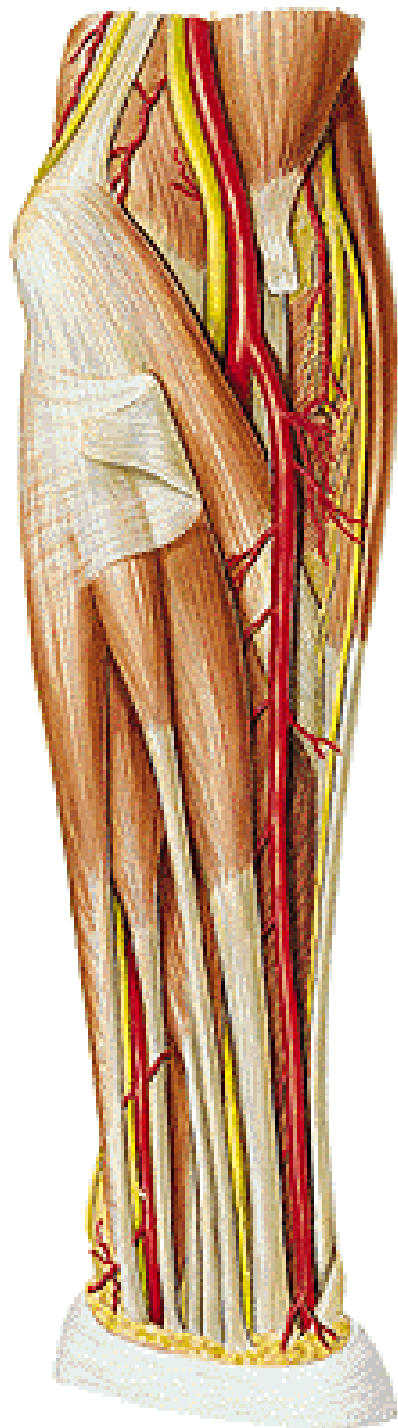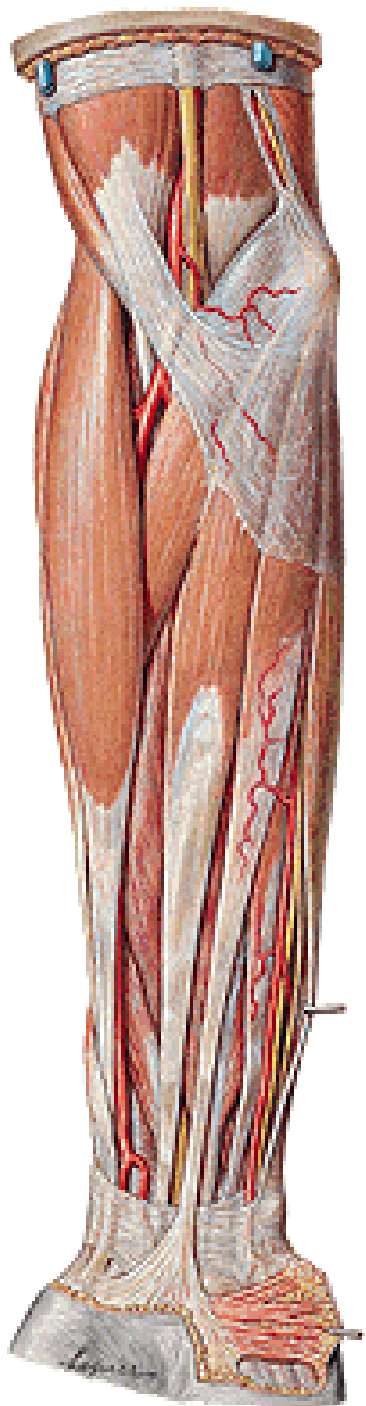
Lateral group:

M. brachioradialis

**M. extensor carpi radialis
longus**

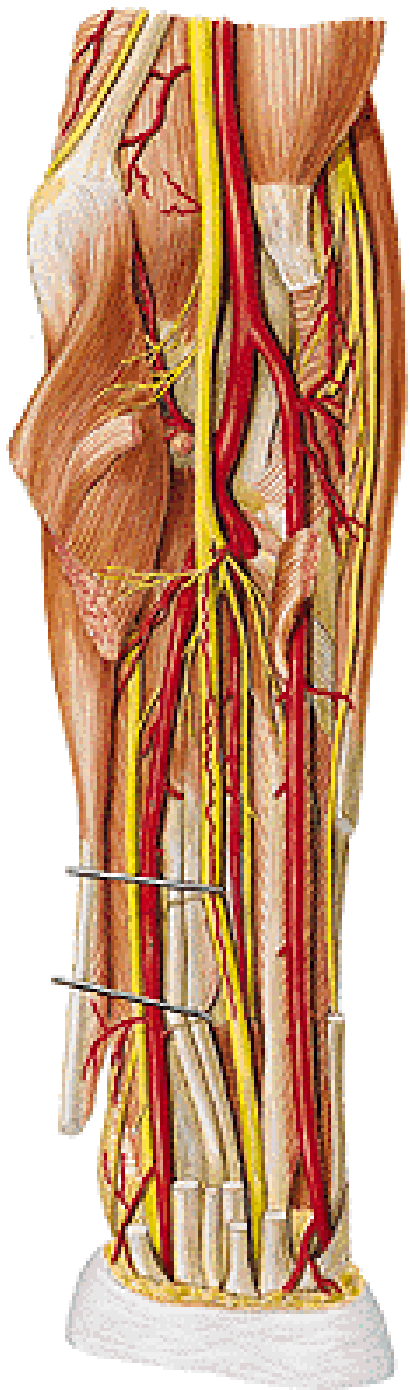
**M. extensor carpi radialis
brevis**

M. supinator



A. RADIALIS

- m. pronator teres**
- m. brachioradialis**
- m. flexor carpi radialis**



Posteriorly:

tendon of biceps

supinator

insertion of pronator teres

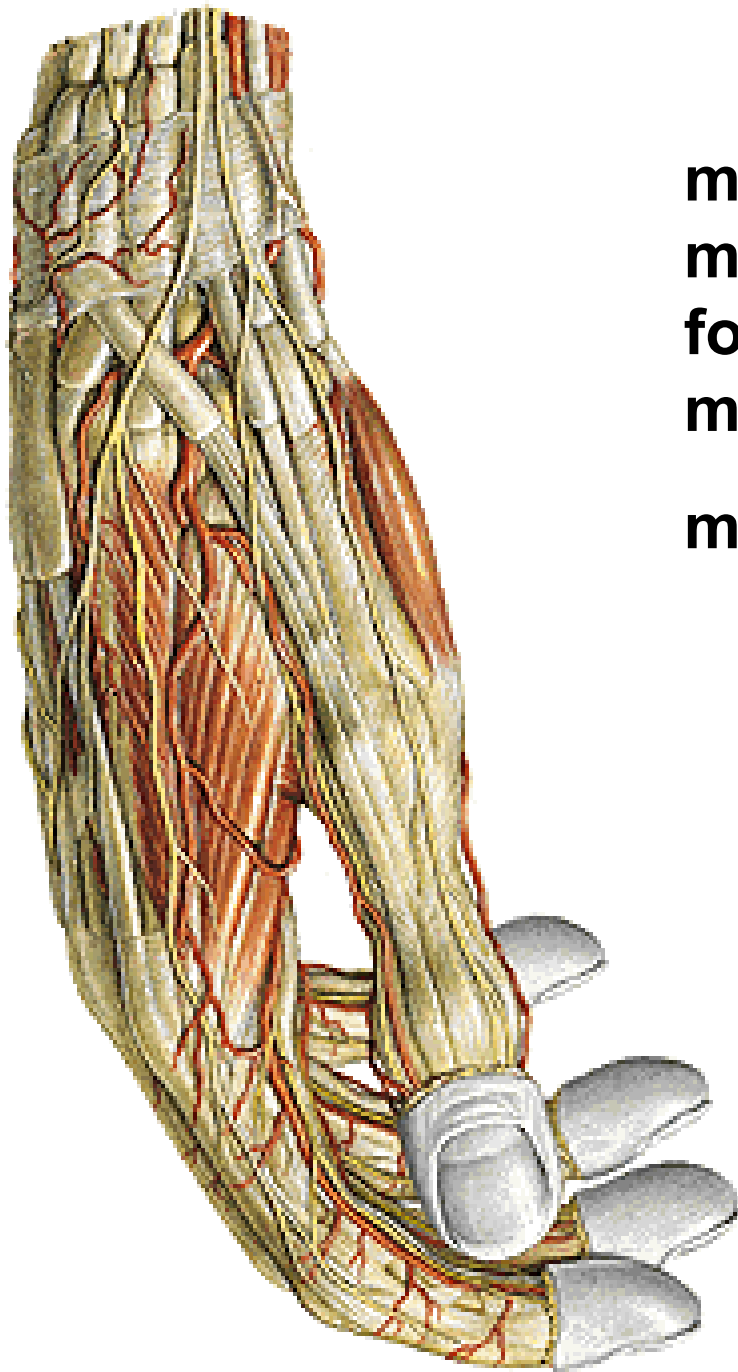
caput radiale m. flexoris digitorum spf.

flexor pollicis longus

pronator quadratus

distal end of the radius

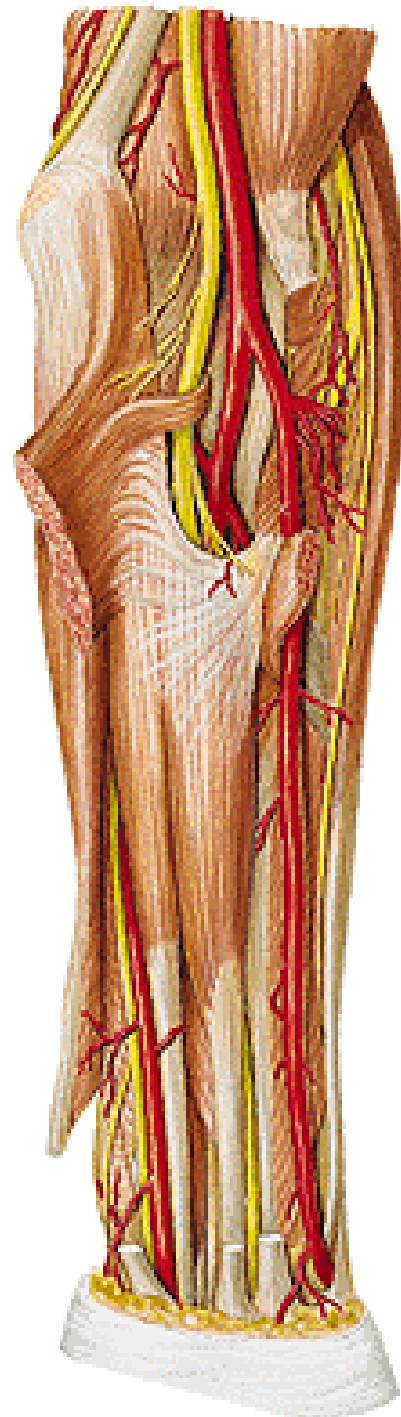
r. superficialis n. radialis



m.abductor pollicis longus
m. extensor pollicis brevis
foveola radialis
m. extensor pollicis longus
m. interosseus dorsalis I.

A. RADIALIS - branches:

- a. recurrens radialis
(rete articulare cubiti)
- rr. musculares



A. ULNARIS

Anteriorly:

m. pronator teres

m. flexor carpi radialis

m. palmaris longus

m. flexor digitorum spf.

m. flexor carpi ulnaris

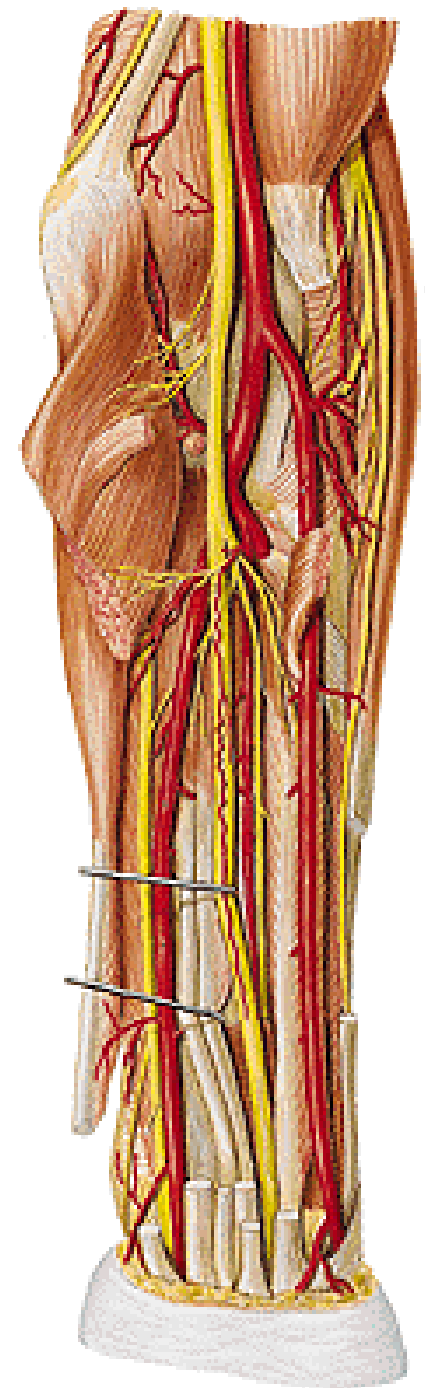
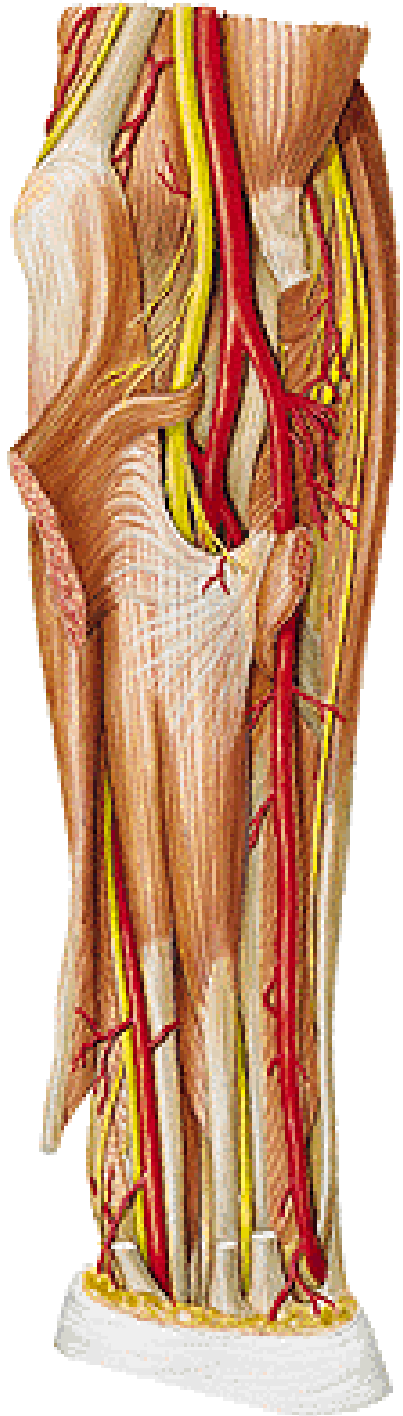
Posteriorly:

m. brachialis

m. flexor digitorum prof.

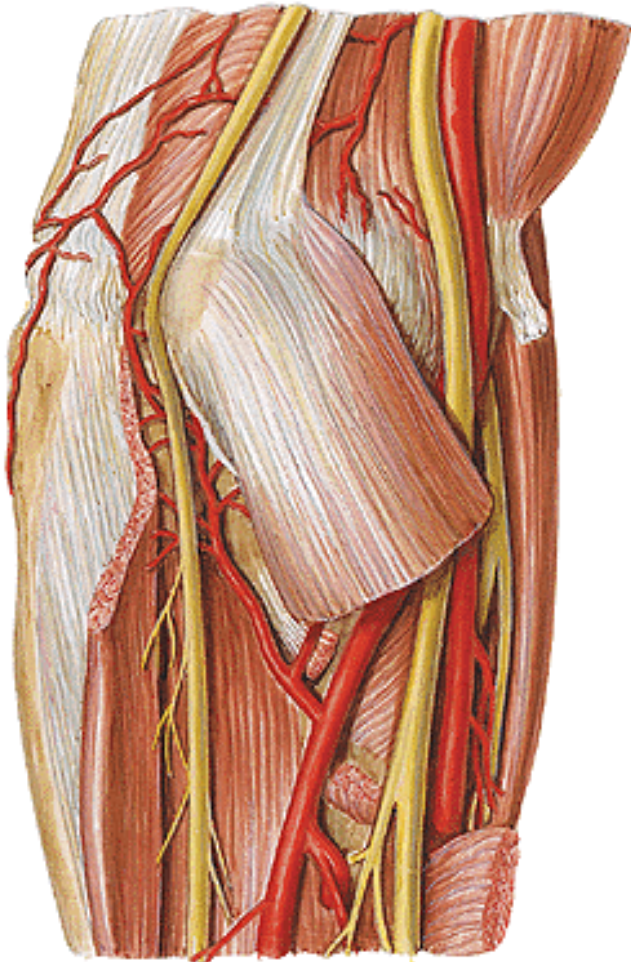
n. ulnaris

n. medianus

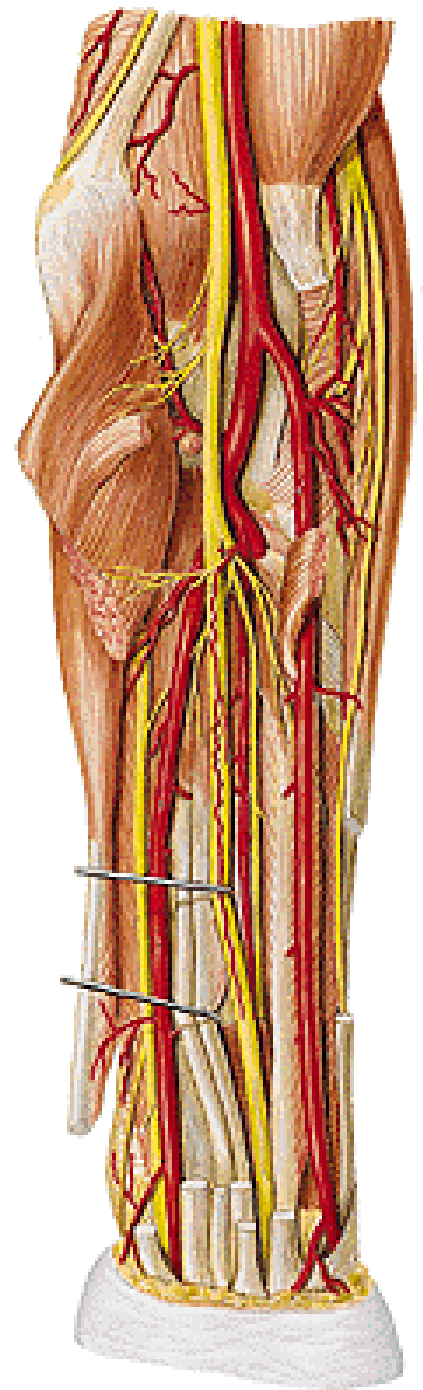


A. ULNARIS – branches:

-a. recurrens ulnaris
(rete articulare cubiti)

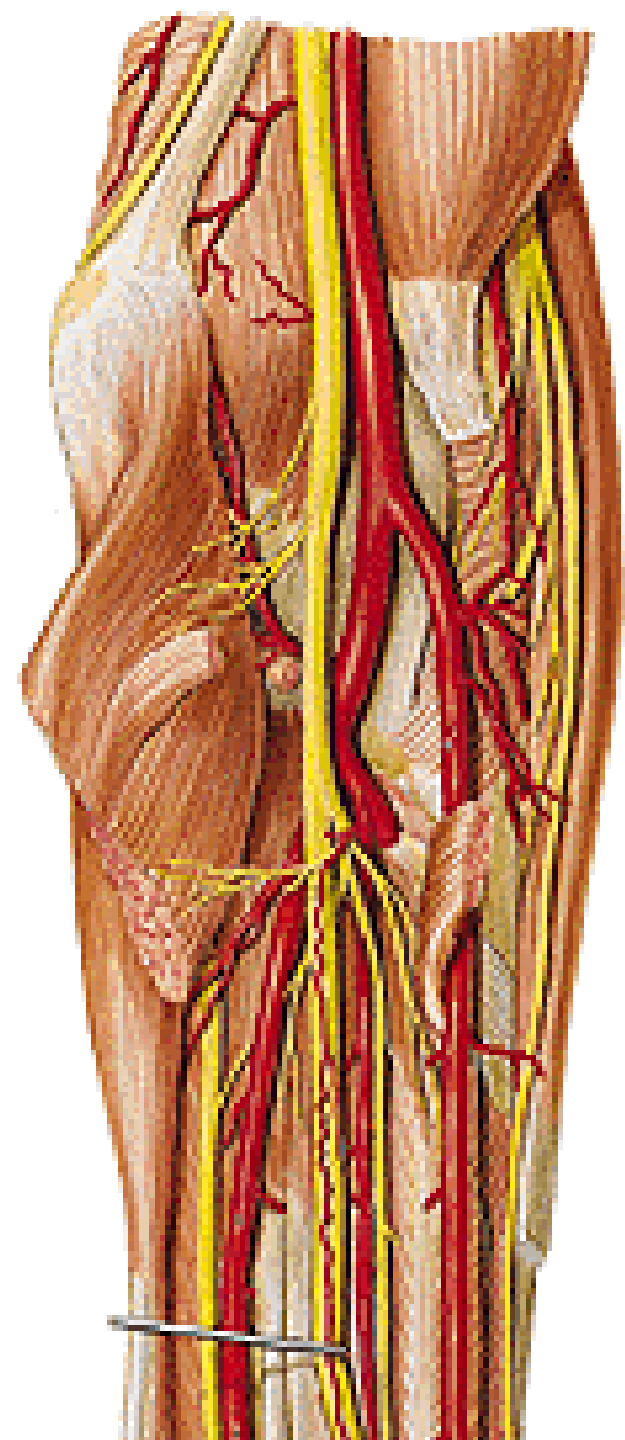


- rr. musculares



A. ULNARIS – branches:

- **a. interossea communis**
 - **a. interossea ant. (n. interosseus anterior)**
 - **a. mediana (n. medianus)**
 - **a. interossea post.**



A. ULNARIS – branches:

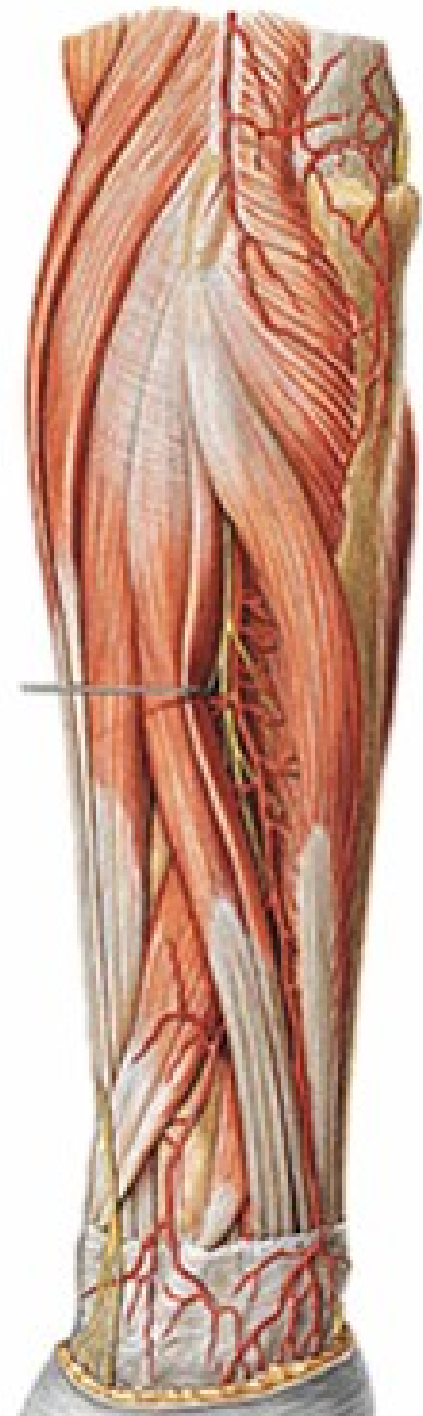
a. interossea post.

- a. recurrens interossea

m. supinator

m. abductor pollicis longus

r. profundus n. radialis

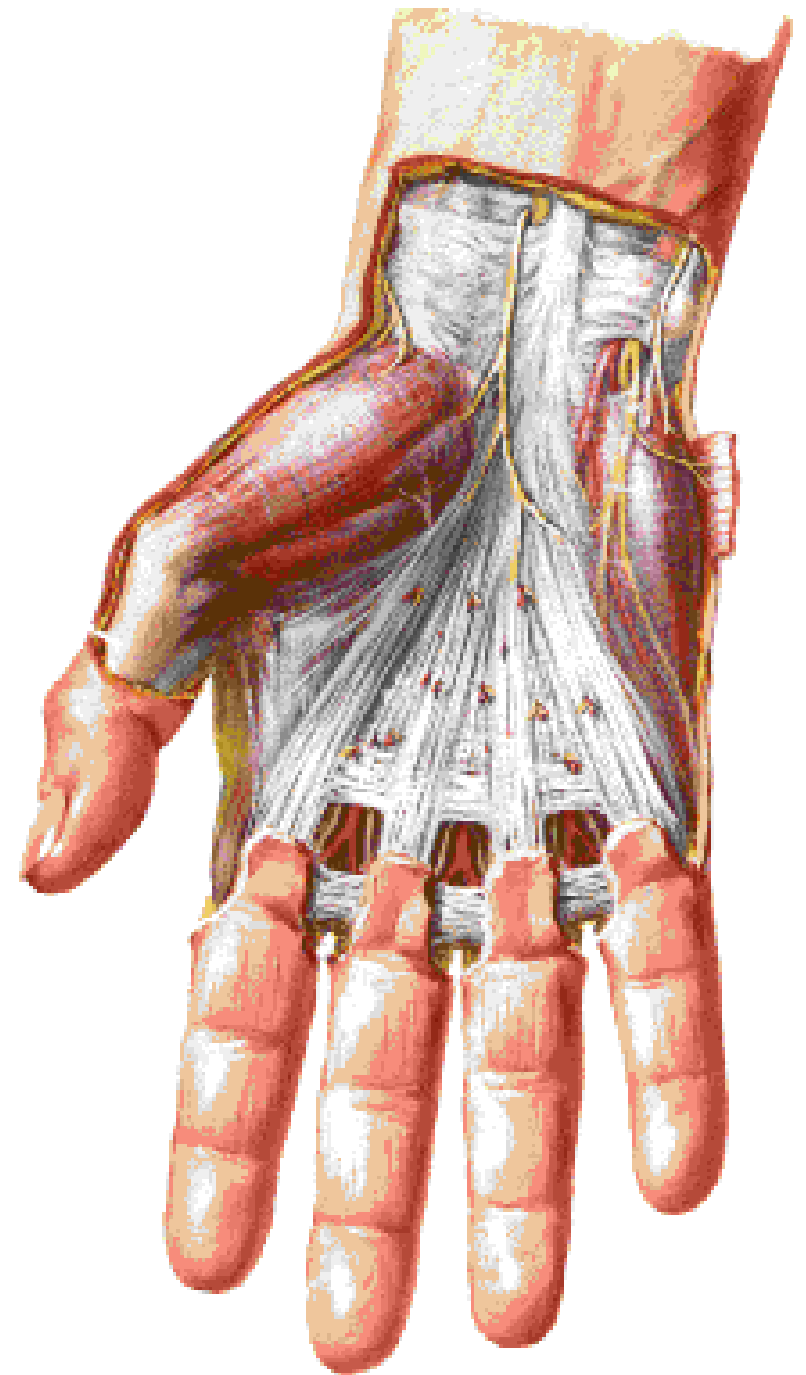


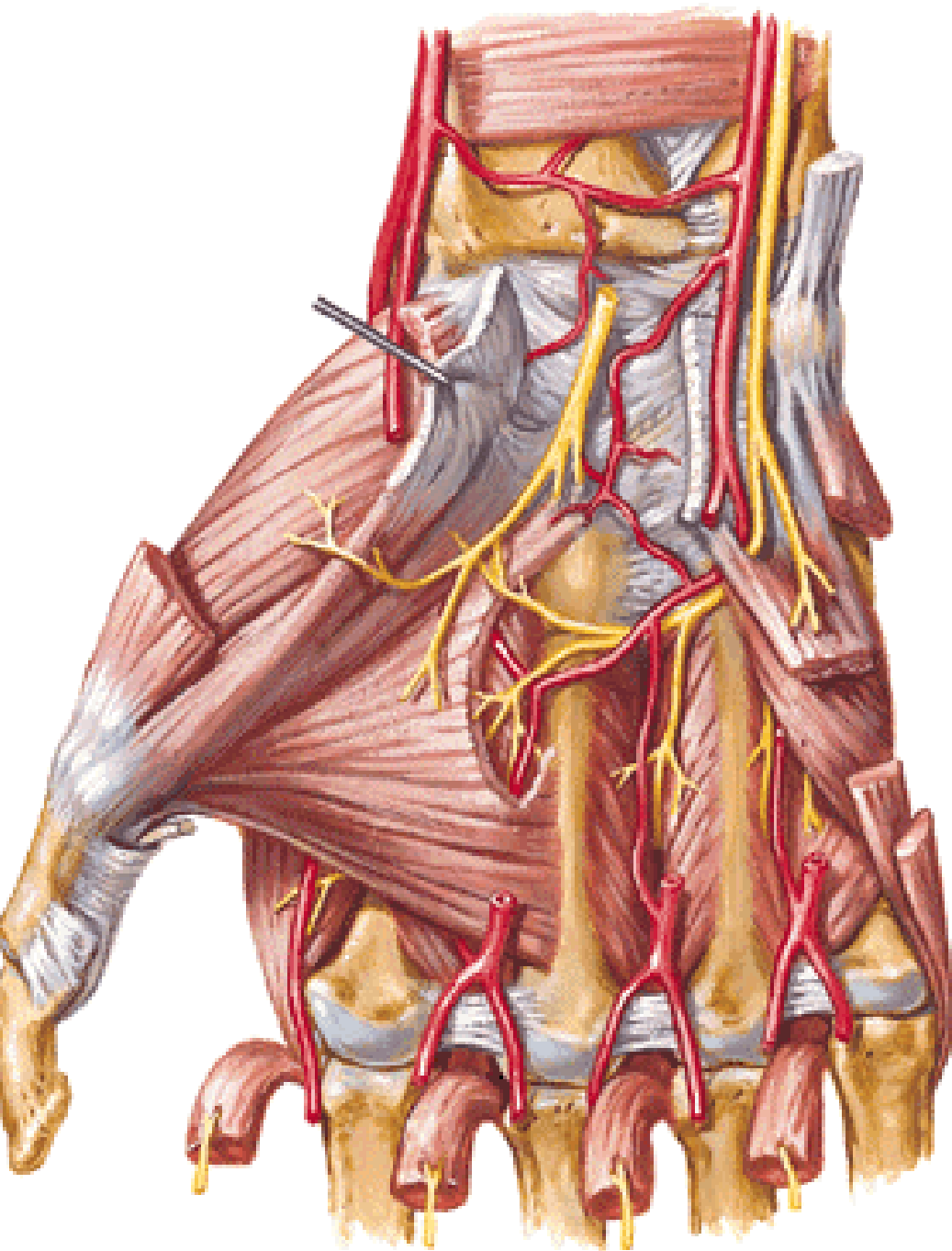
Musculi manus:

Thenarus

Hypothenarus

Aponeurosis palmaris





Thenar:

M. abductor pollicis brevis

M. flexor pollicis brevis

M. opponens pollicis

M. adductor pollicis

Hypothenar:

M. palmaris brevis

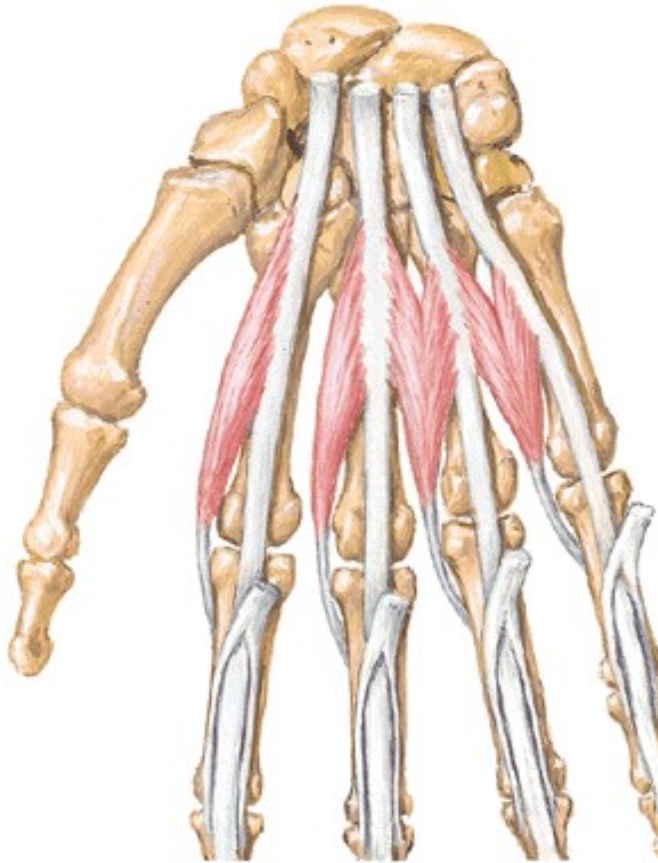
M. abductor digiti minimi

M. flexor digiti minimi brevis

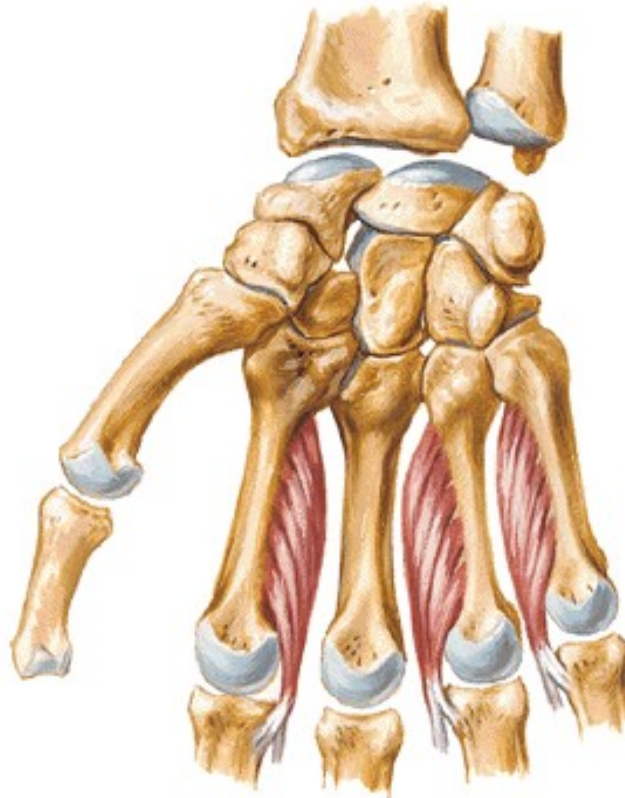
M. opponens digiti minimi

Middle group:

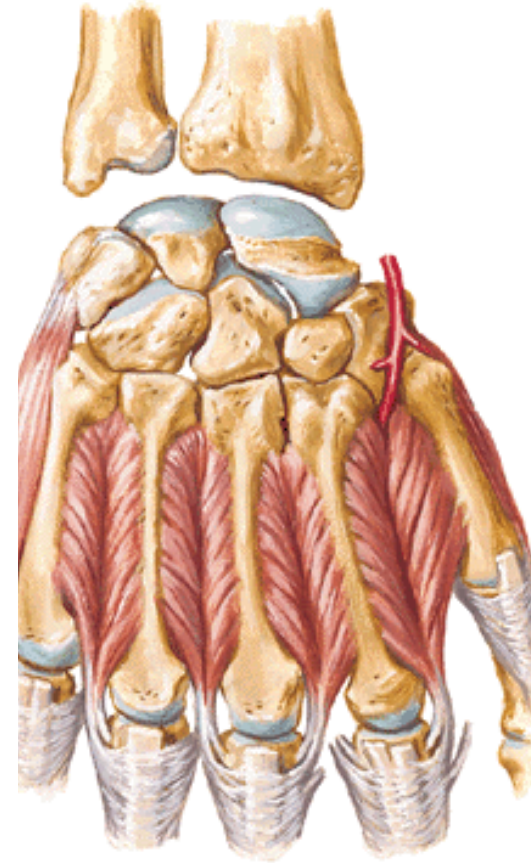
M. lumbricales



M. interossei palmares



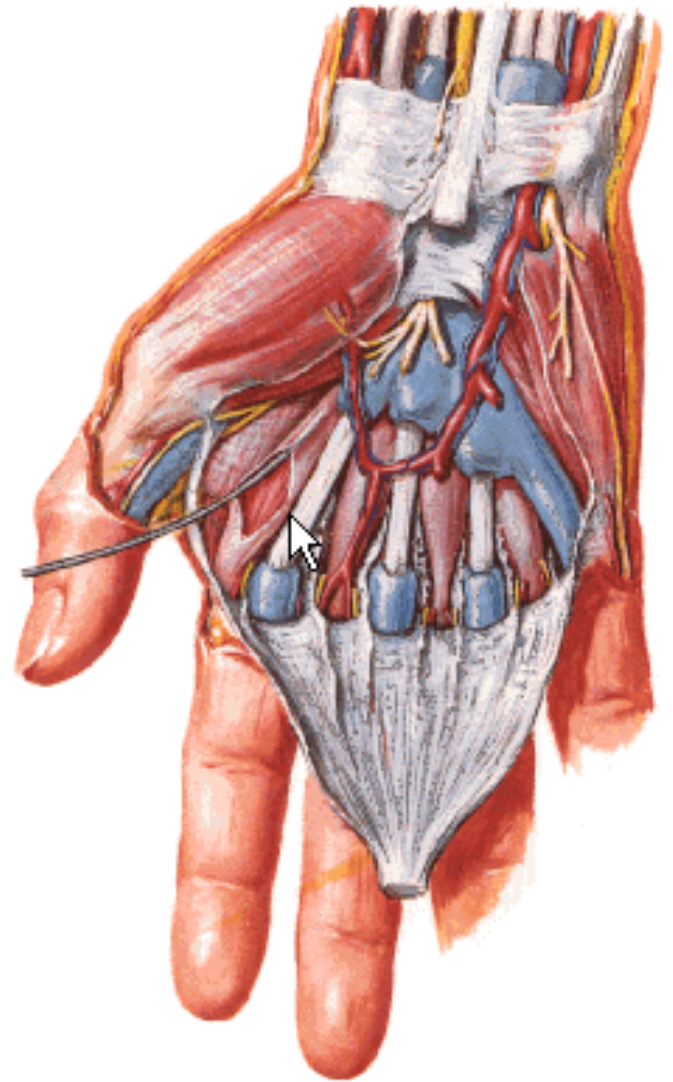
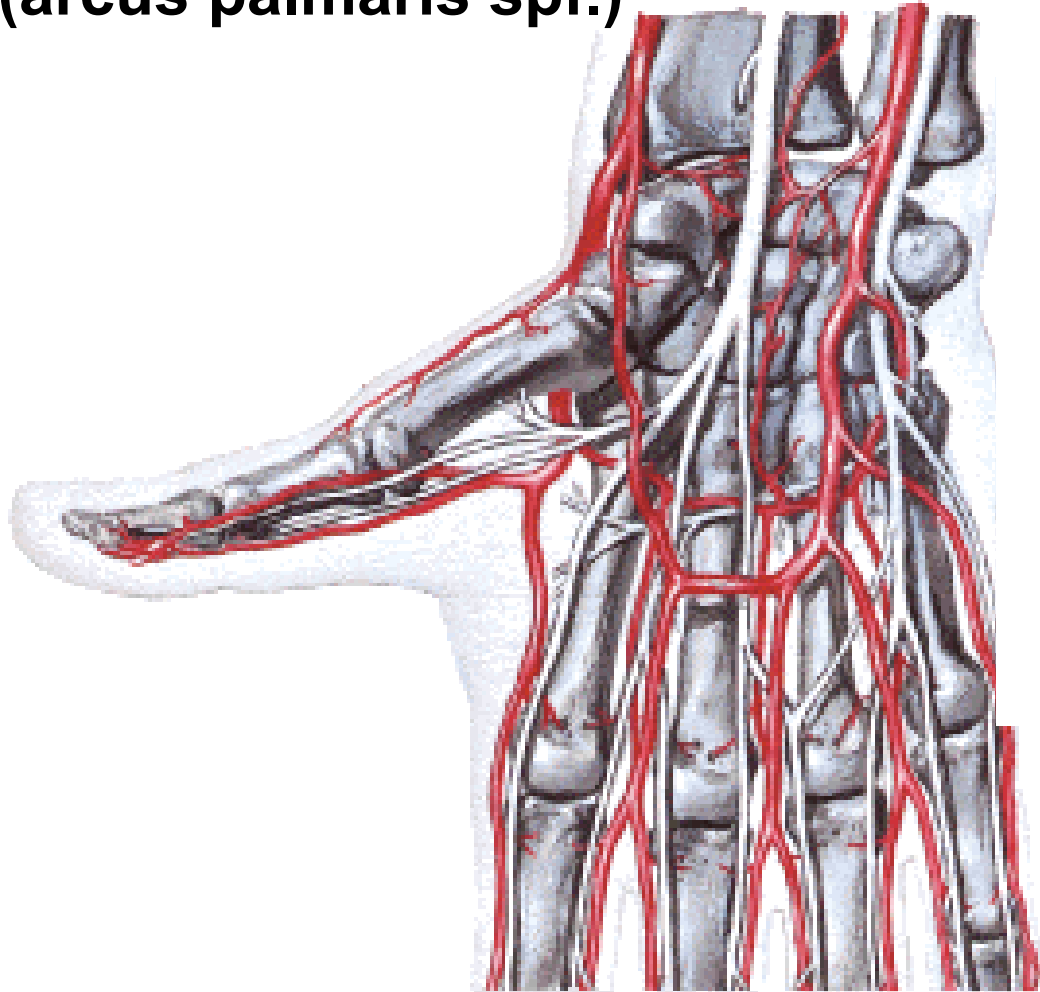
M. interossei dorsales



A. RADIALIS – branches:

-r. carpeus palmaris
(rete carpi palmare)

-r. palmaris spf.
(arcus palmaris spf.)

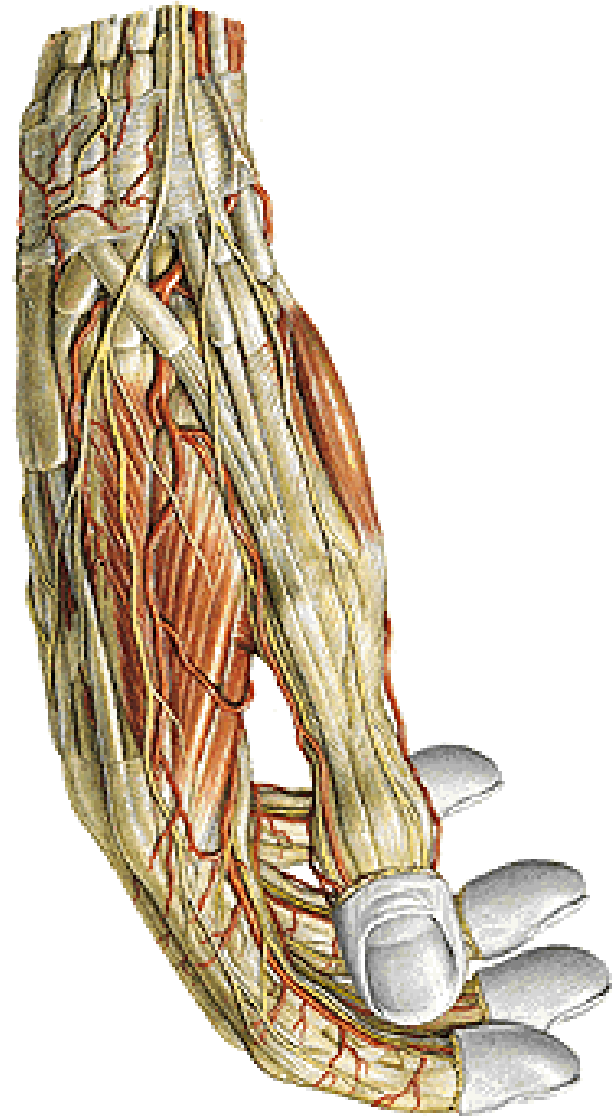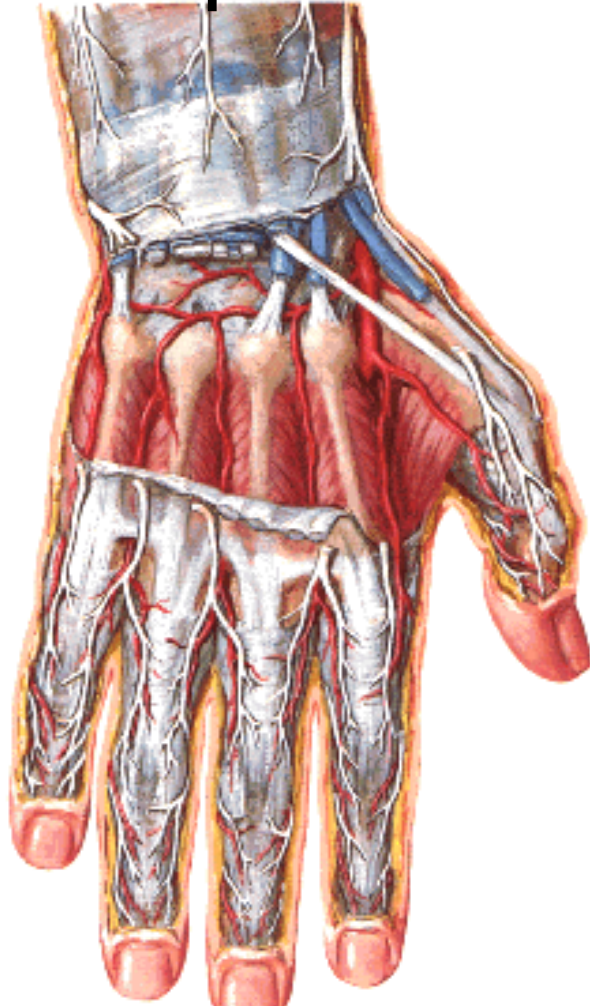


A. RADIALIS – branches:

-r. carpeus dorsalis

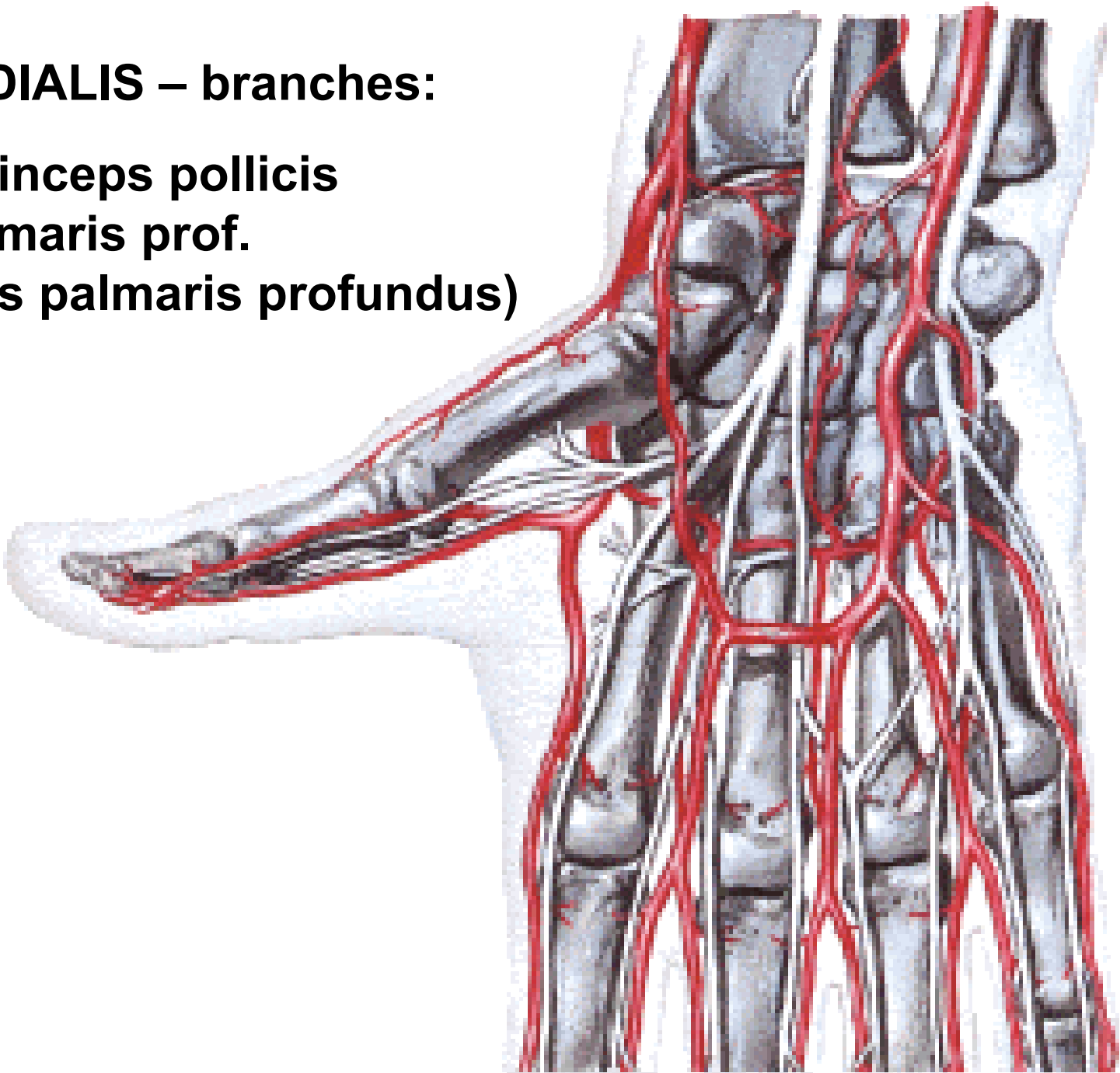
(rete carpi dorsale – 3 aa. metacarpeae dorsales
– aa. digitales dorsales)

- a. metacarpea dorsalis I.



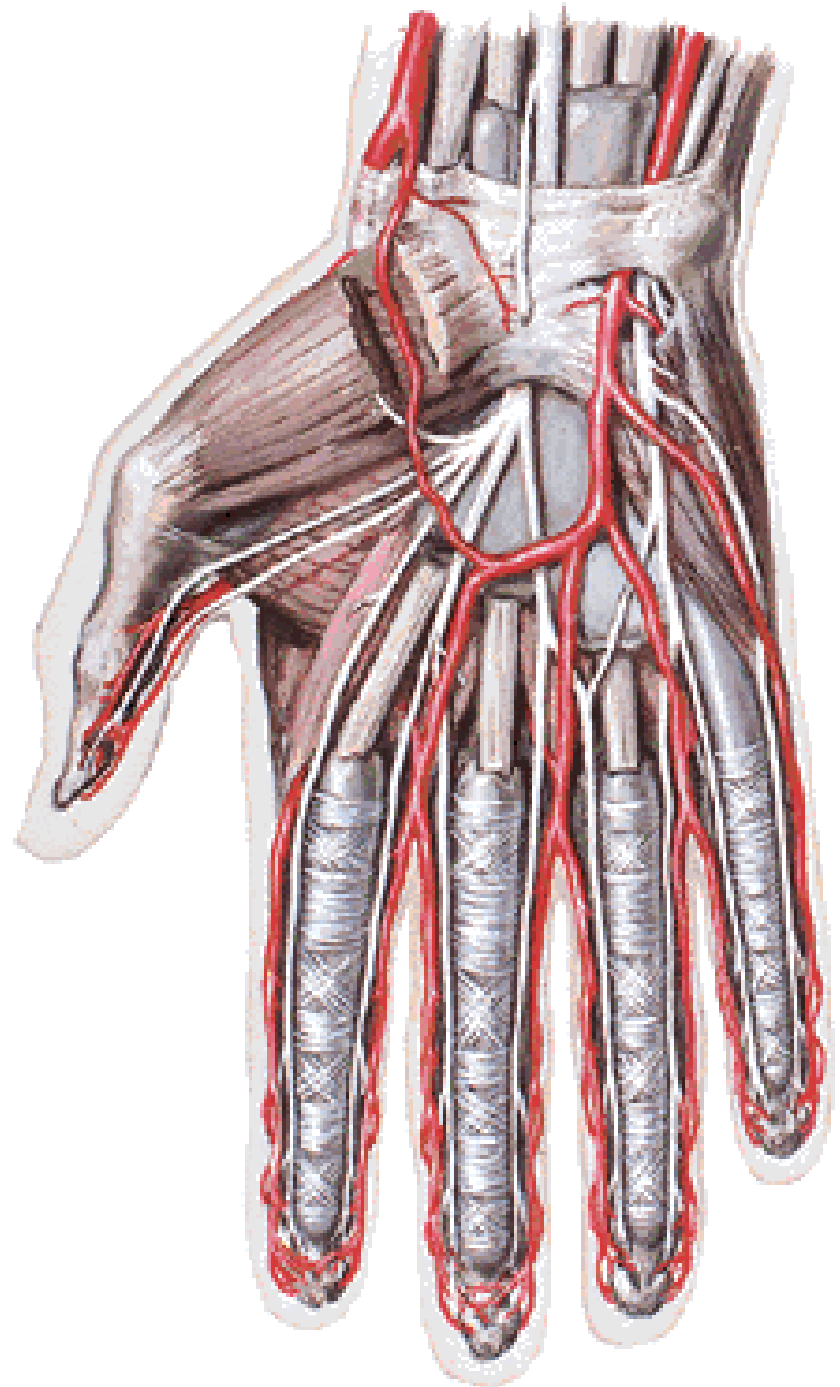
A. RADIALIS – branches:

- a. princeps pollicis
- r. palmaris prof.
(arcus palmaris profundus)



A. ULNARIS

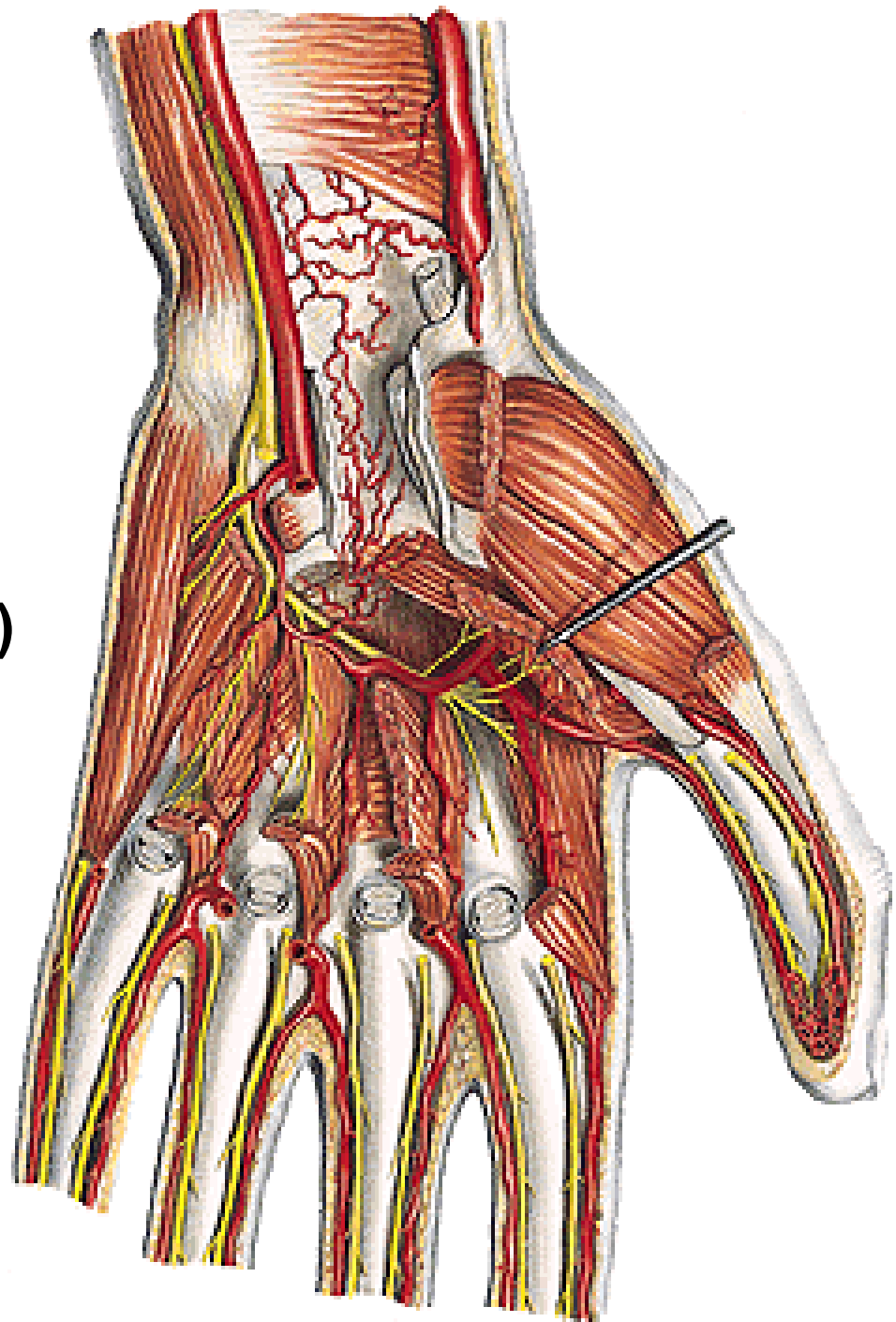
retinaculum flexorum



A. ULNARIS – branches:

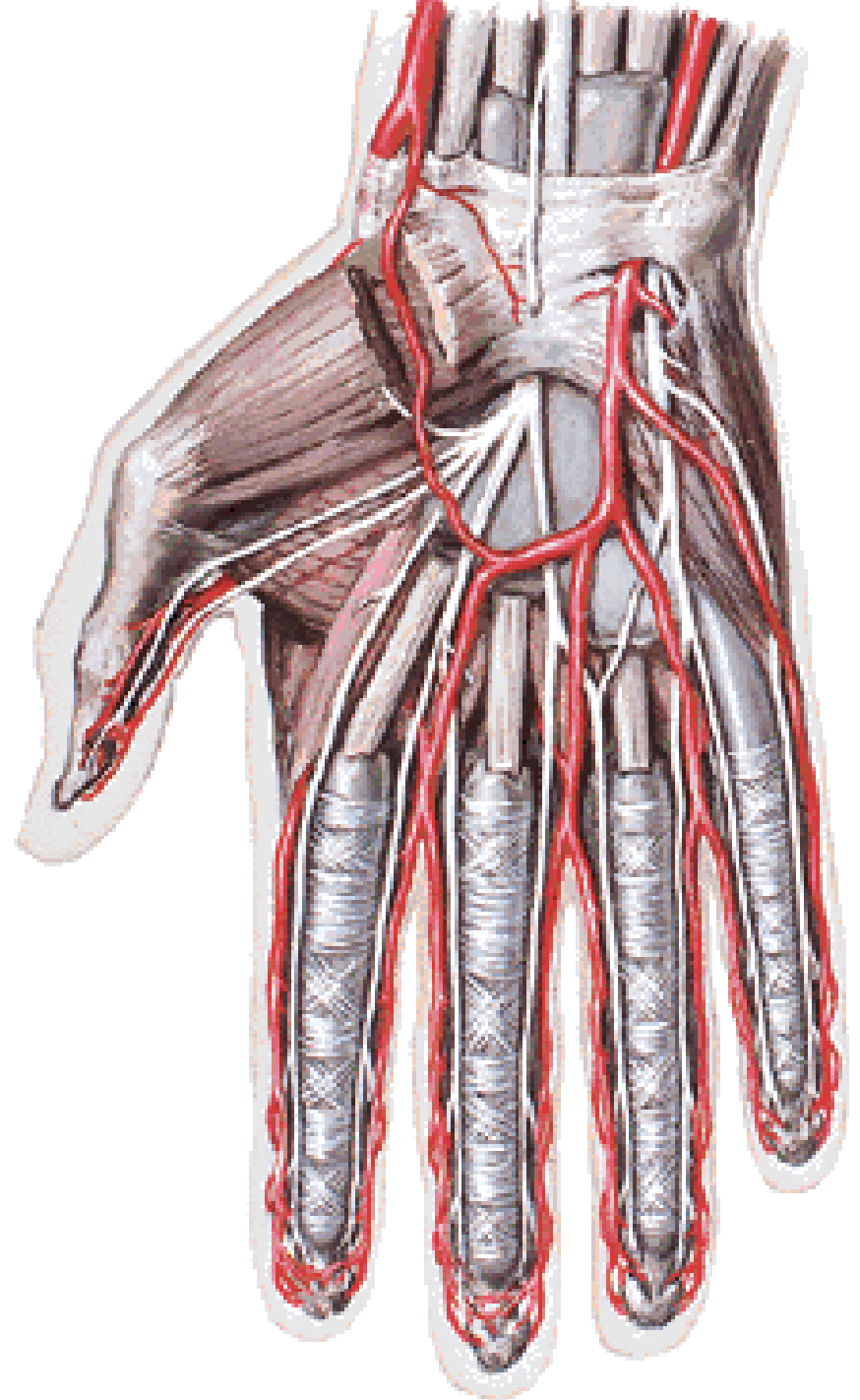
- r. carpeus palmaris
(rete carpi palmare)**
- r. carpeus dorsalis
(rete carpi dorsale)**
- r. palmaris prof.
(arcus palmaris profundus)**

- m. abductor digiti minimi**
- m. flexor digiti minimi**
- m. opponens digiti minimi**



A. ULNARIS – branches:

- r. palmaris spf.
(arcus palmaris spf.)

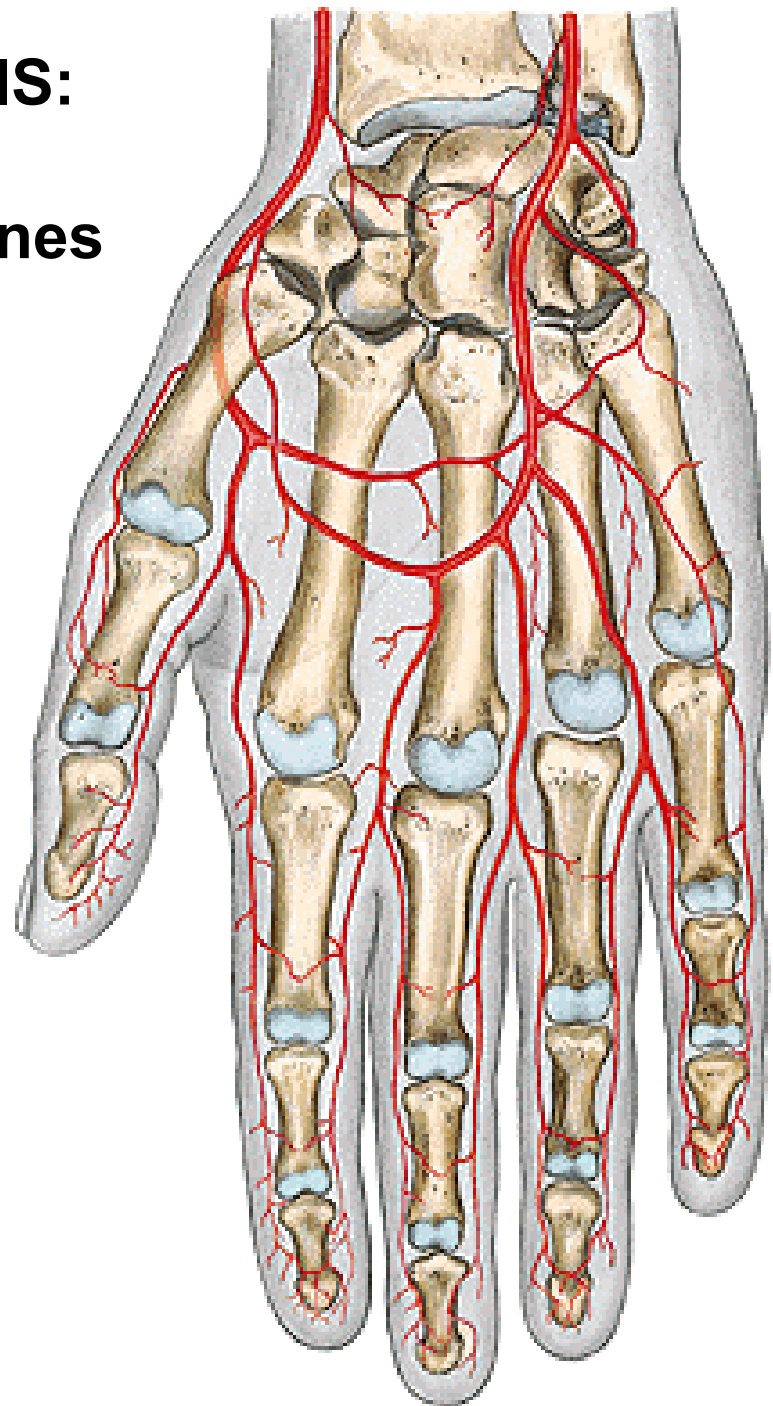


ARCUS PALMARIS SUPERFICIALIS:

- 3 aa. digitales palmares communes
 - 2 aa. dig. palmares propriae
- a. palmaris digiti quinti ulnaris

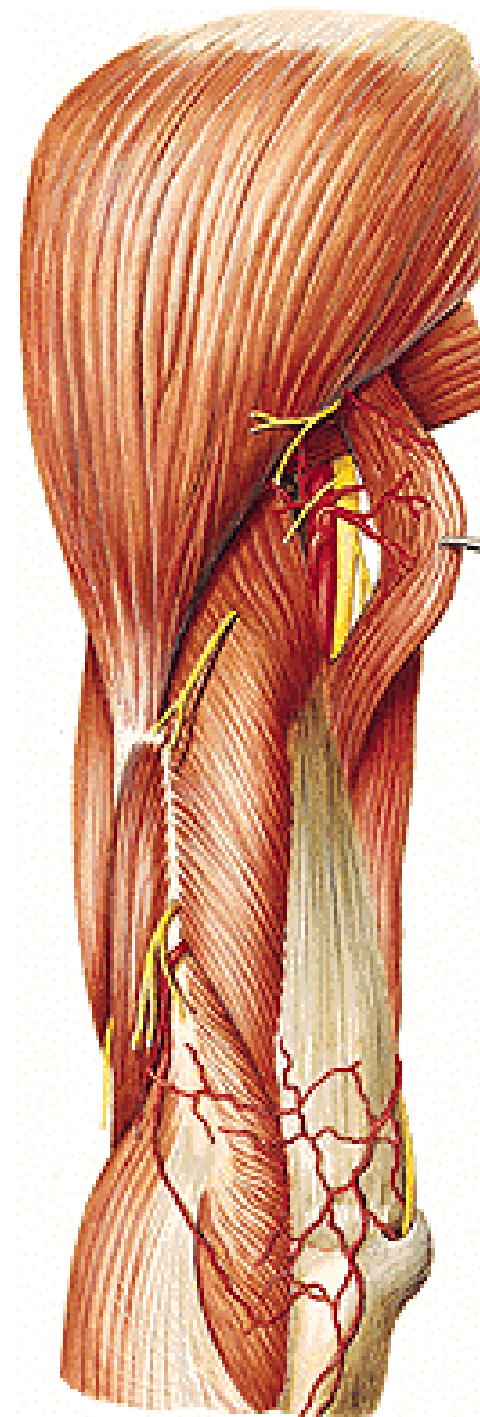
ARCUS PALMARIS PROFUNDUS:

- aa. metacarpeae palmares
 - rr. perforantes



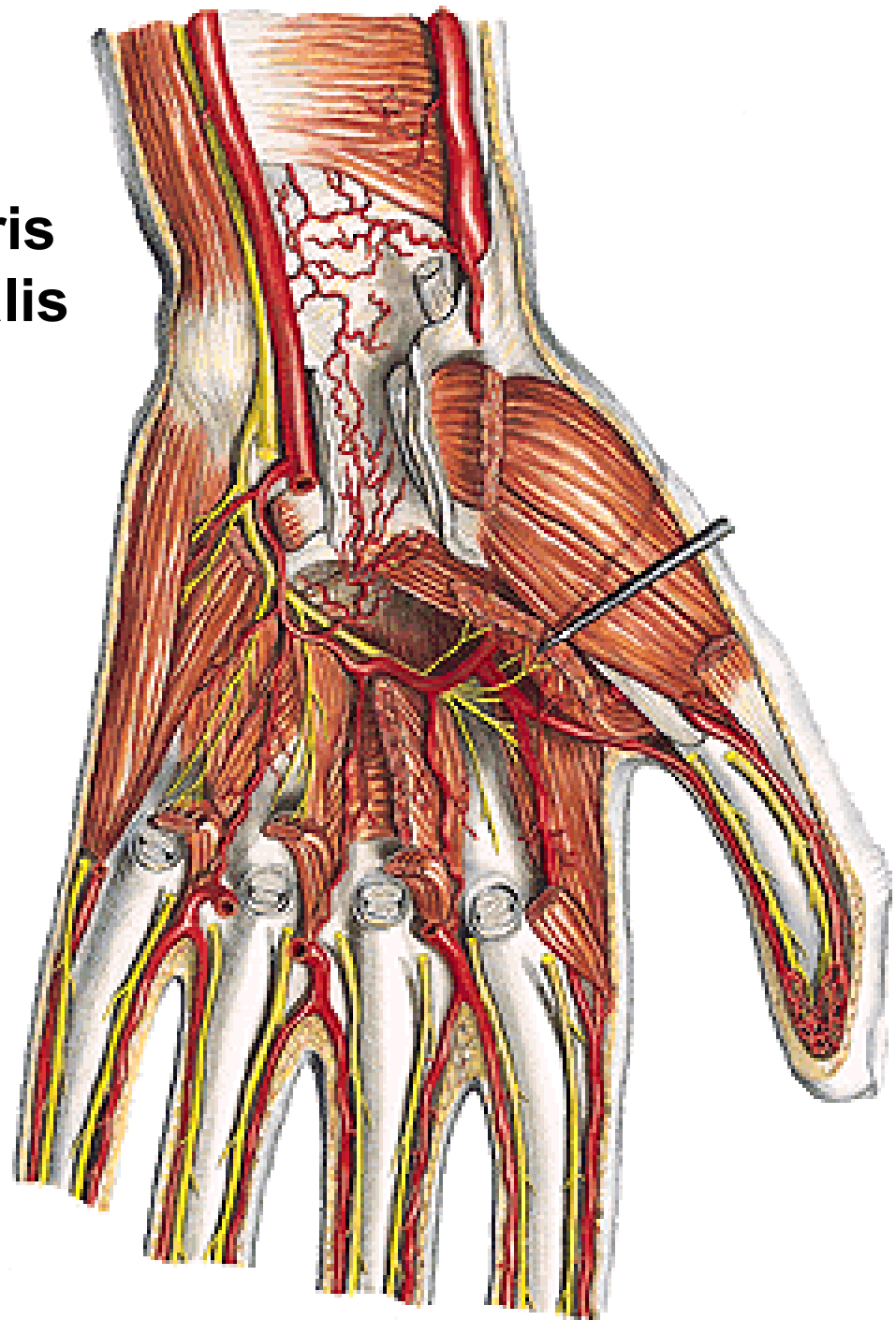
RETE ARTICULARE CUBITI:

- a. collateralis media et rad. (a. prof. brachii)
- a. collateralis ulnaris sup. (a. brachialis)
- a. collateralis ulnaris inf. (a. brachialis)
- a. recurrens radialis (a. radialis)
- a. recurrens interossea (a. interossea post.)
- a. recurrens ulnaris (a. ulnaris)



RETE CARPI PALMARE:

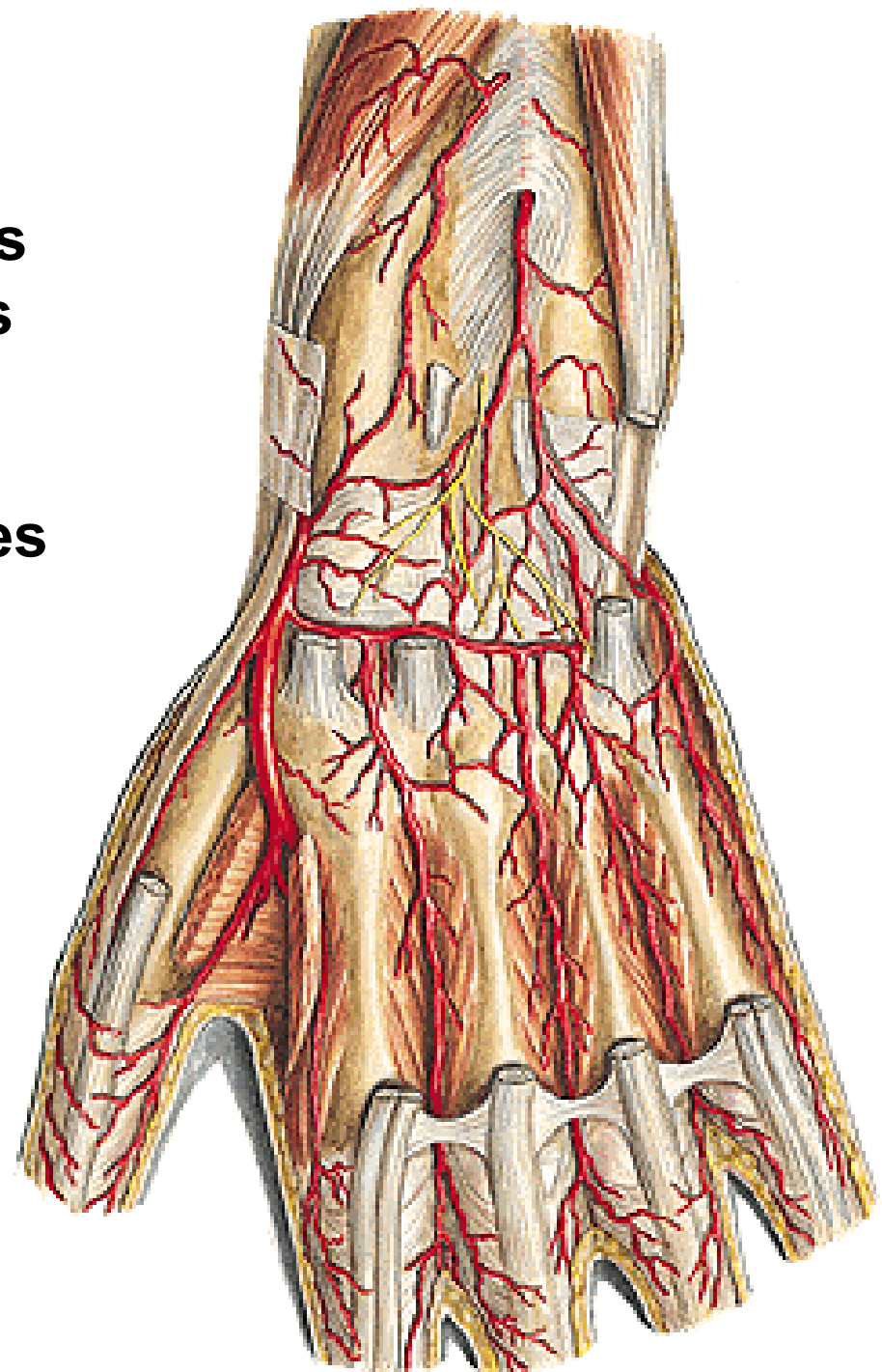
- r. carpeus palmaris a. ulnaris
- r. carpeus palmaris a. radialis
- a. interossea ant.
- arcus palmaris prof.



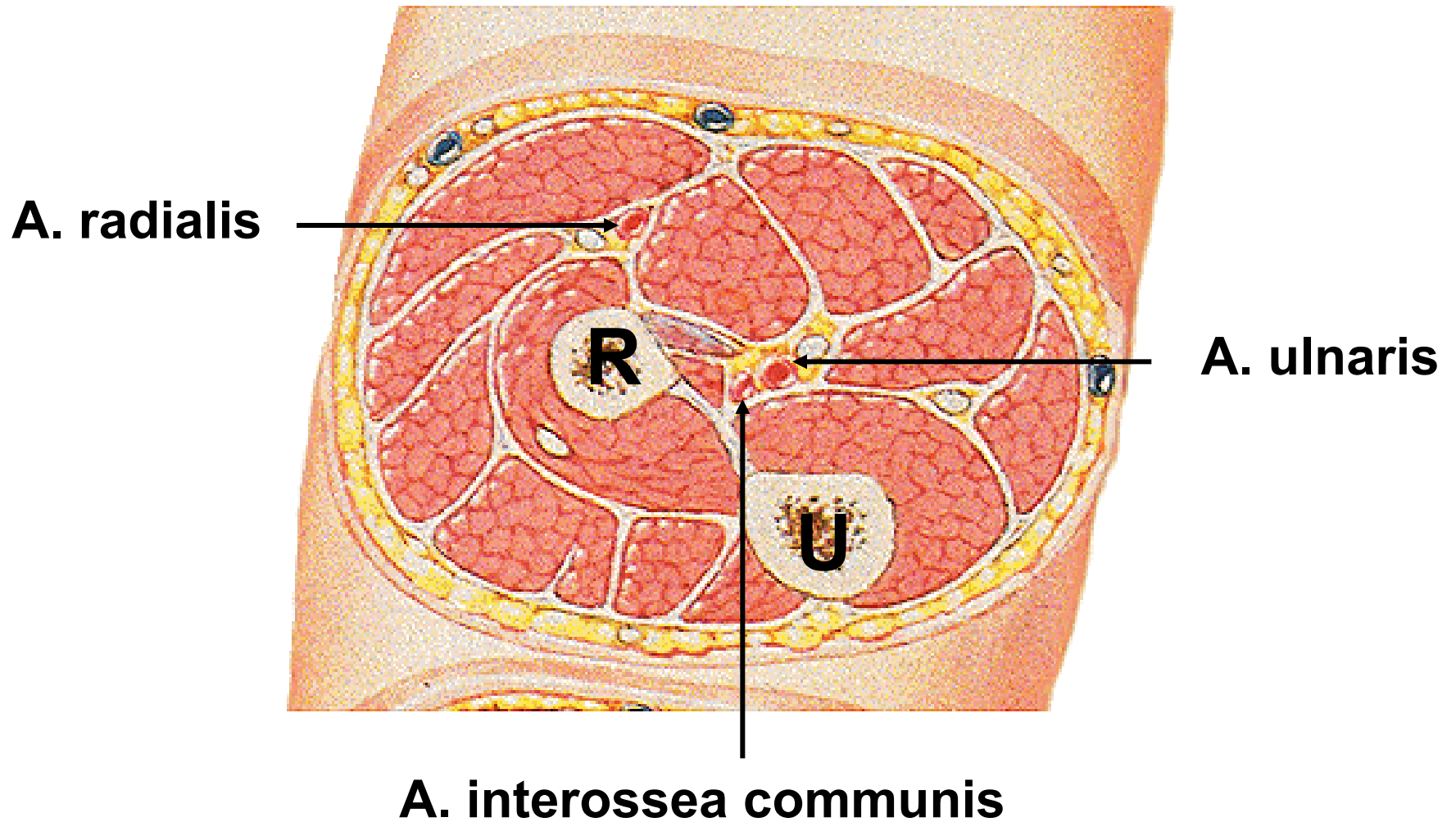
RETE CARPI DORSALE:

- r. carpeus dorsalis a. radialis
- r. carpeus dorsalis a. ulnaris
- a. interossea ant. et post.

→ 3 aa. metacarpeae dorsales
2 aa. digitales dorsales



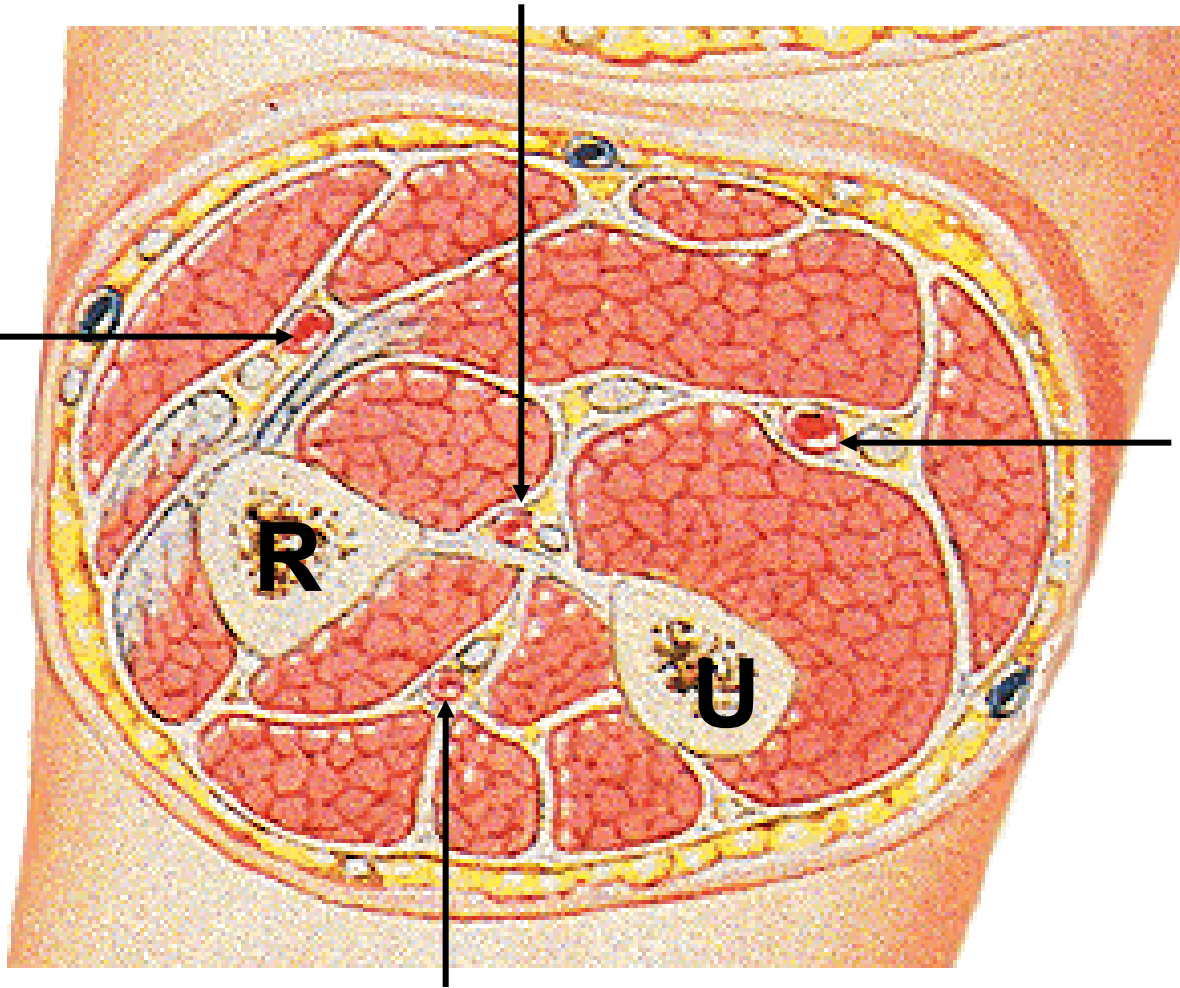
Forearm – proximal cross section



Forearm – middle cross section

A. interossea anterior

A. radialis



A. ulnaris

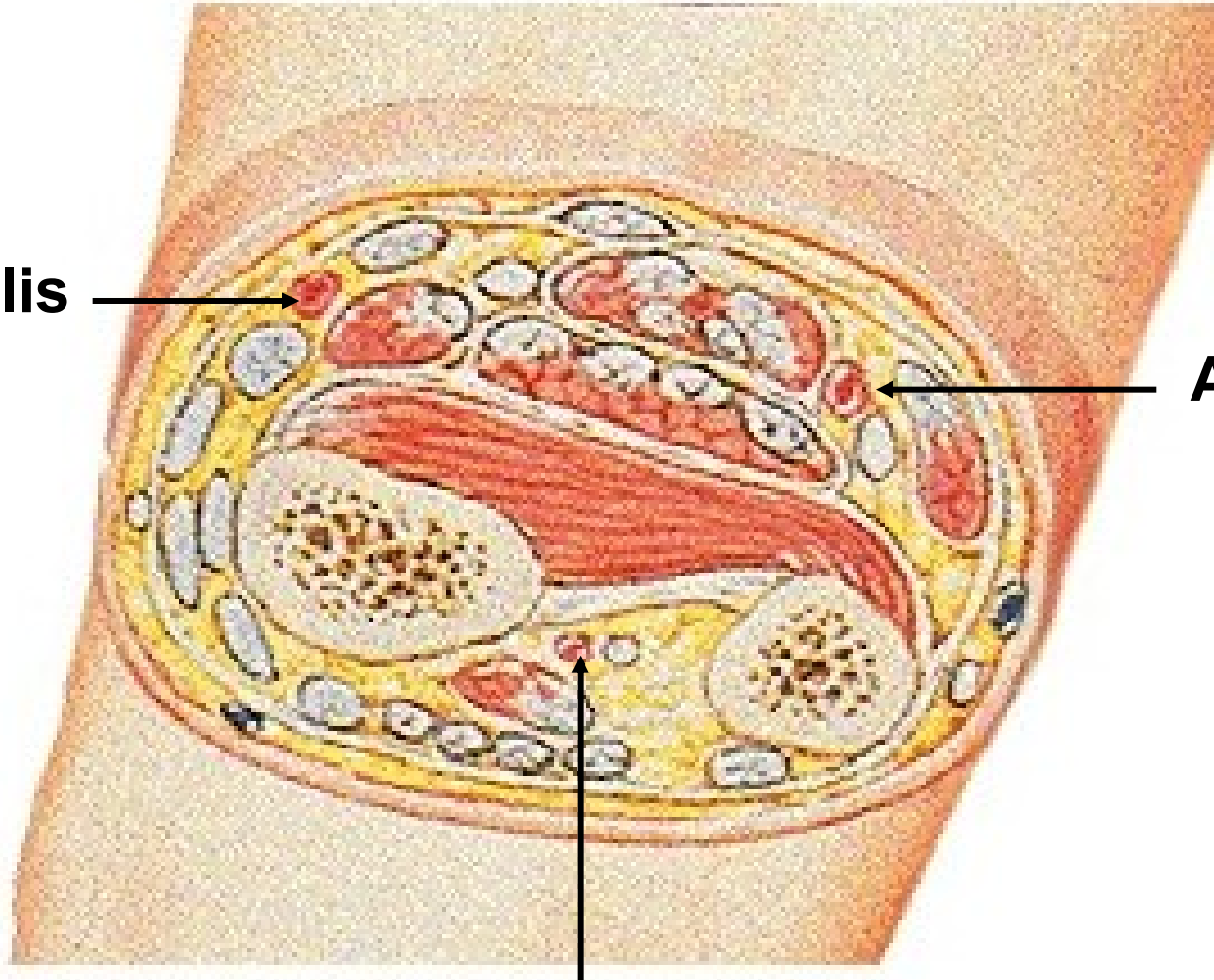
A. interossea posterior

Forearm – distal cross section

A. radialis



A. ulnaris



A. interossea anterior



Illustrations and photographs were copied from:
Atlas der Anatomie des Menschen/Sobotta.
Putz,R., und Pabst,R. 20. Auflage. München:
Urban & Schwarzenberg, 1993