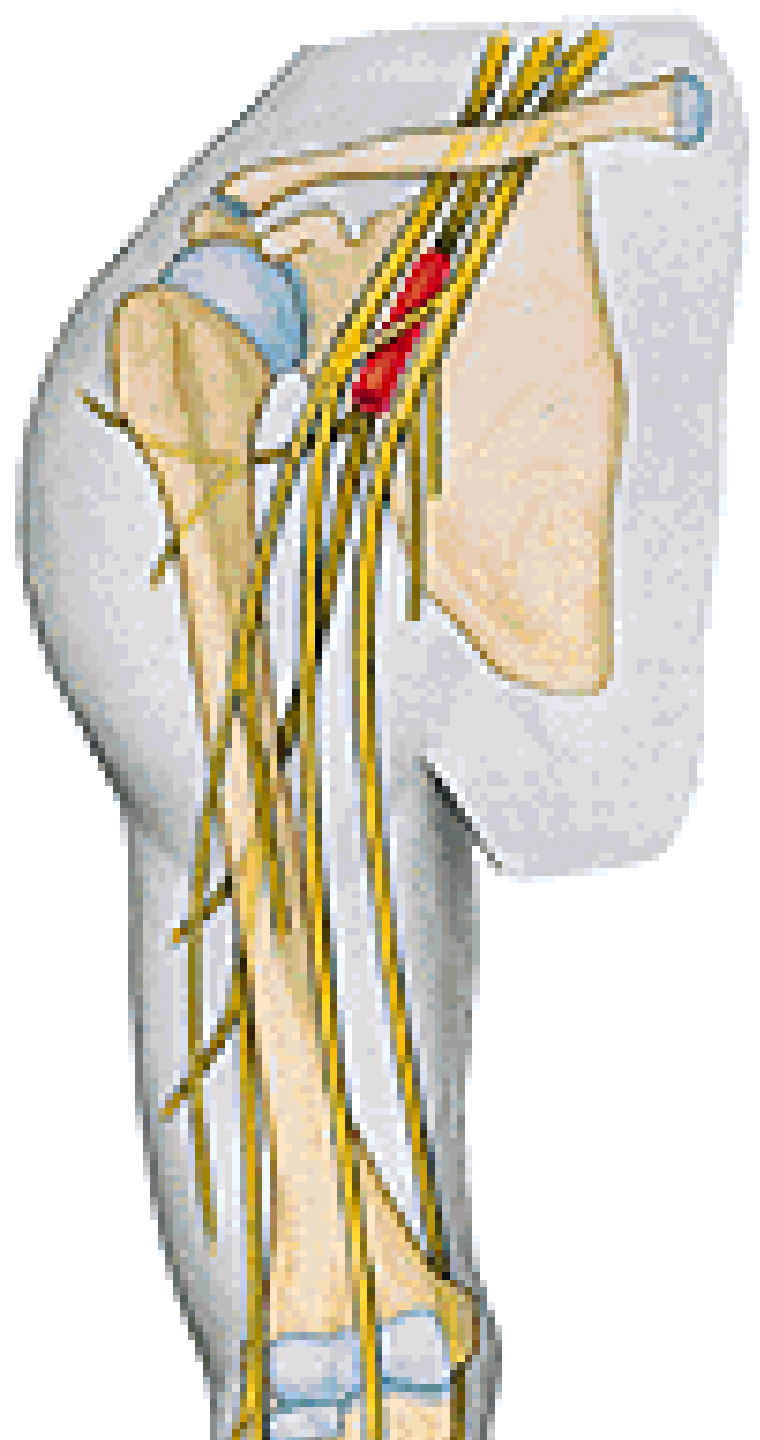
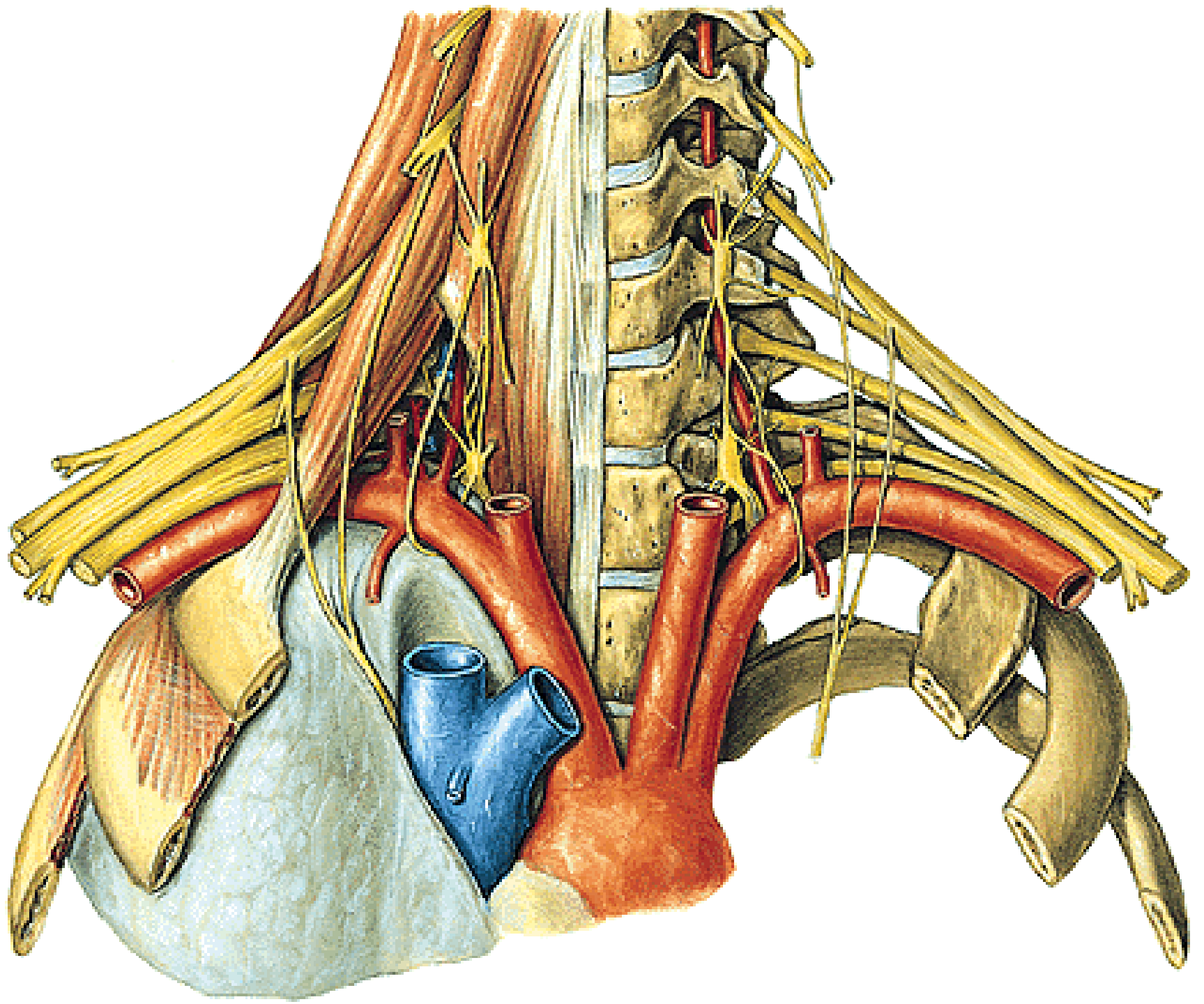


PLEXUS BRACHIALIS

PARS SUPRACLAVICULARIS

PARS INFRACLAVICULARIS



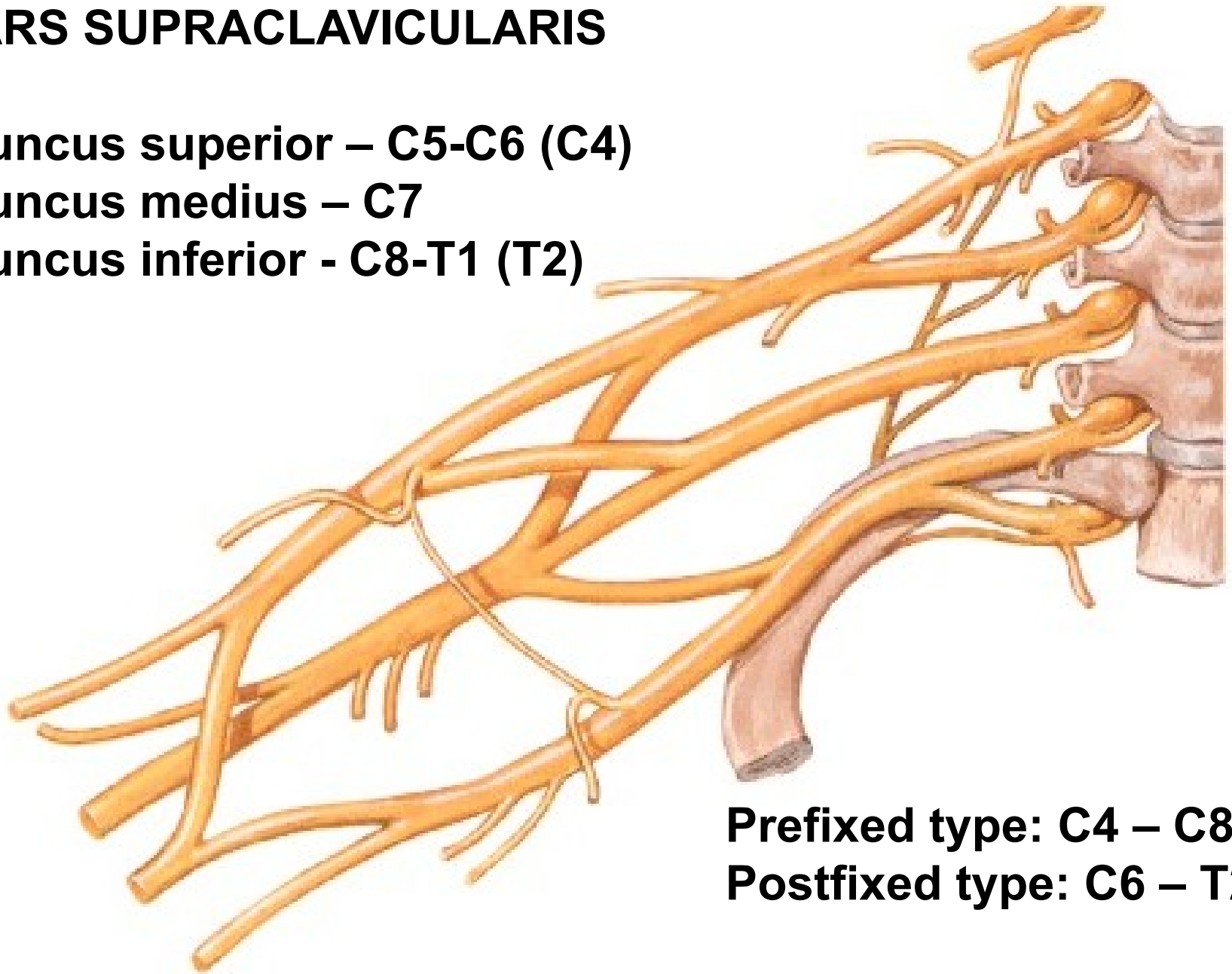


PARS SUPRACLAVICULARIS

Truncus superior – C5-C6 (C4)

Truncus medius – C7

Truncus inferior - C8-T1 (T2)



Prefixed type: C4 – C8

Postfixed type: C6 – T2

PARS SUPRACLAVICULARIS

N. dorsalis scapulae (C4, C5)

- mm. rhomboidei
- m. levator scapulae

N. thoracicus longus (C5, C6, C7)

- m. serratus ant.

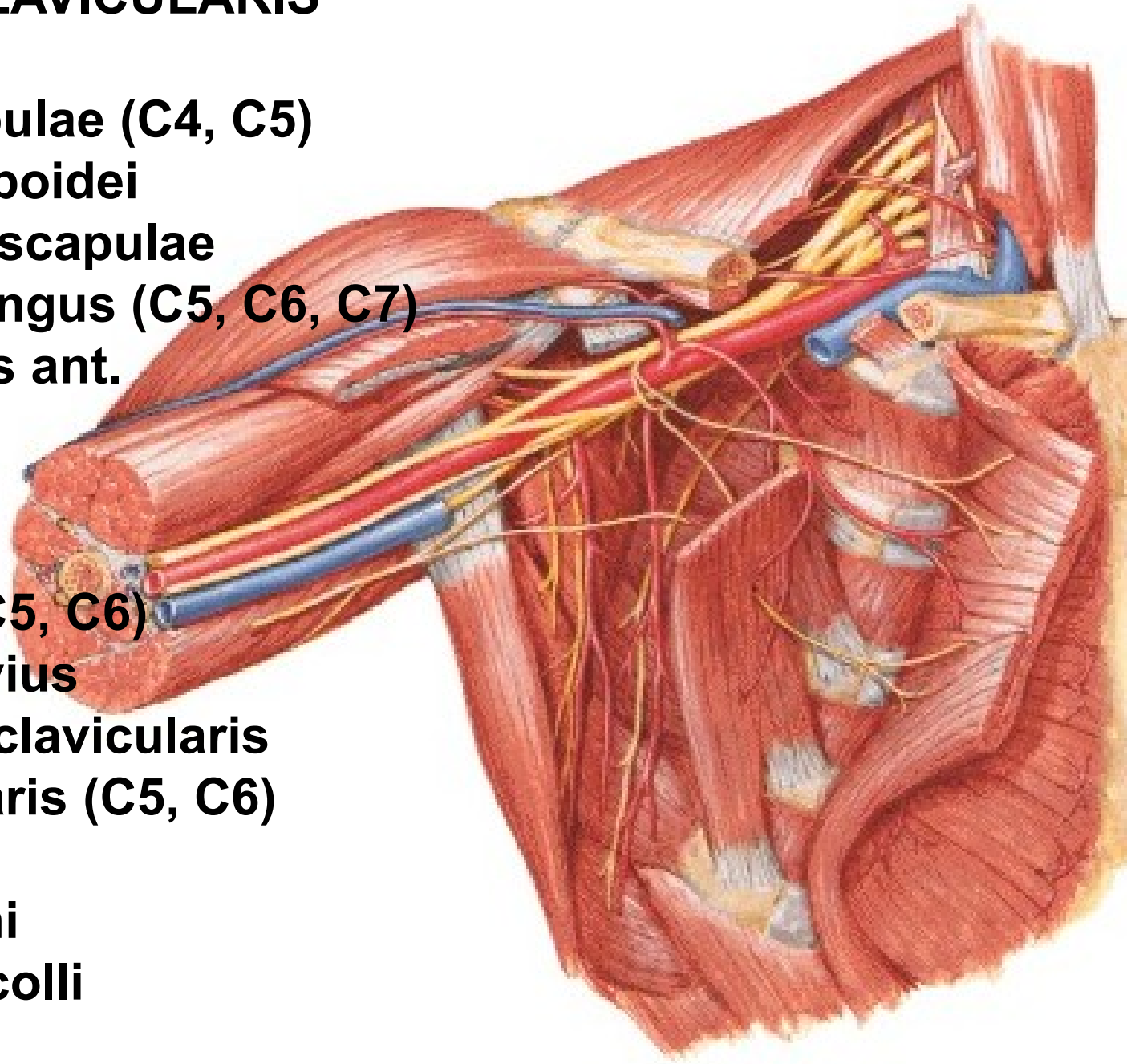
N. subclavius (C5, C6)

- m. subclavius
- art. sternoclavicularis

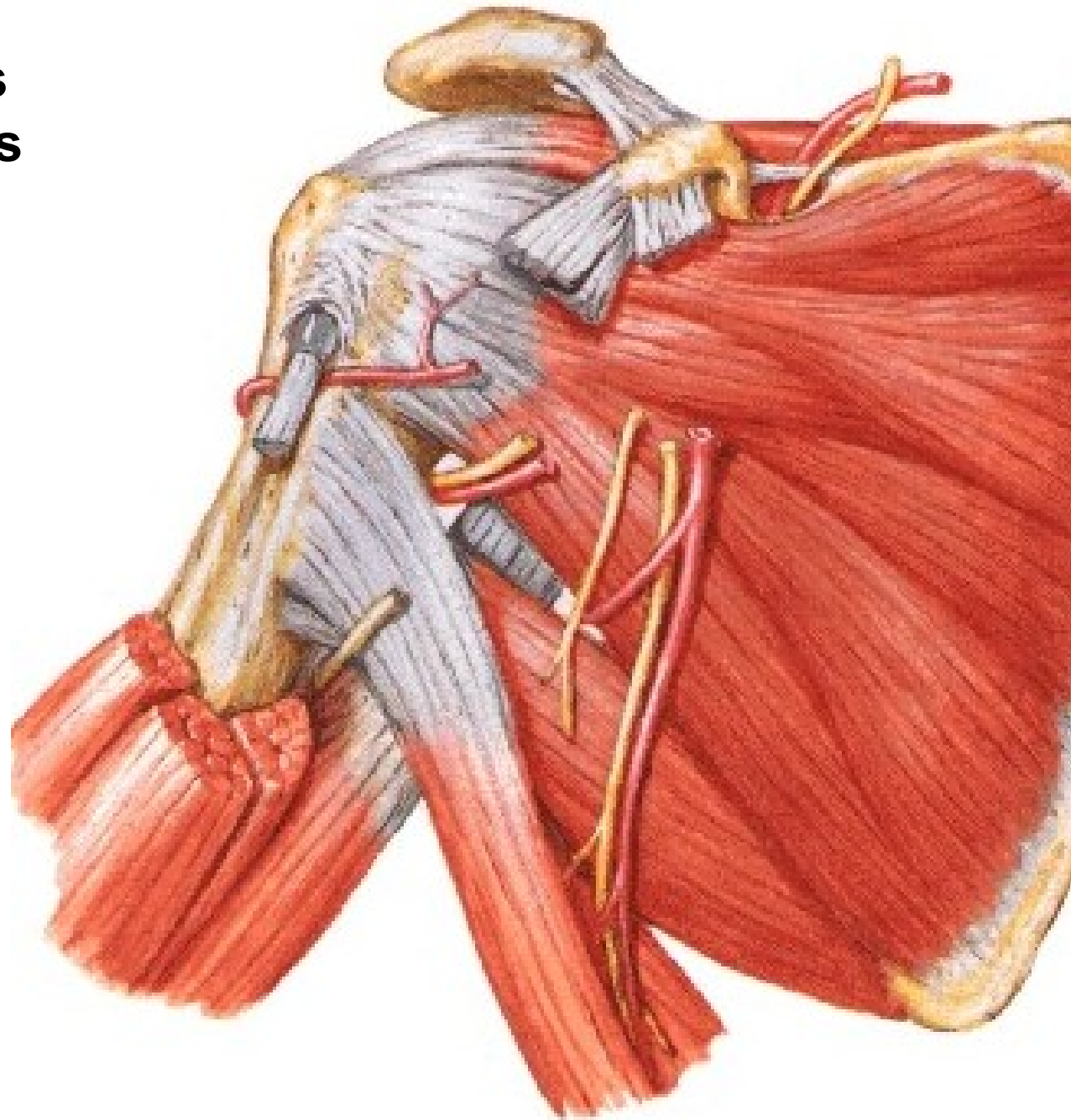
N. suprascapularis (C5, C6)

Rr. musculares

- mm. scaleni
- m. longus colli

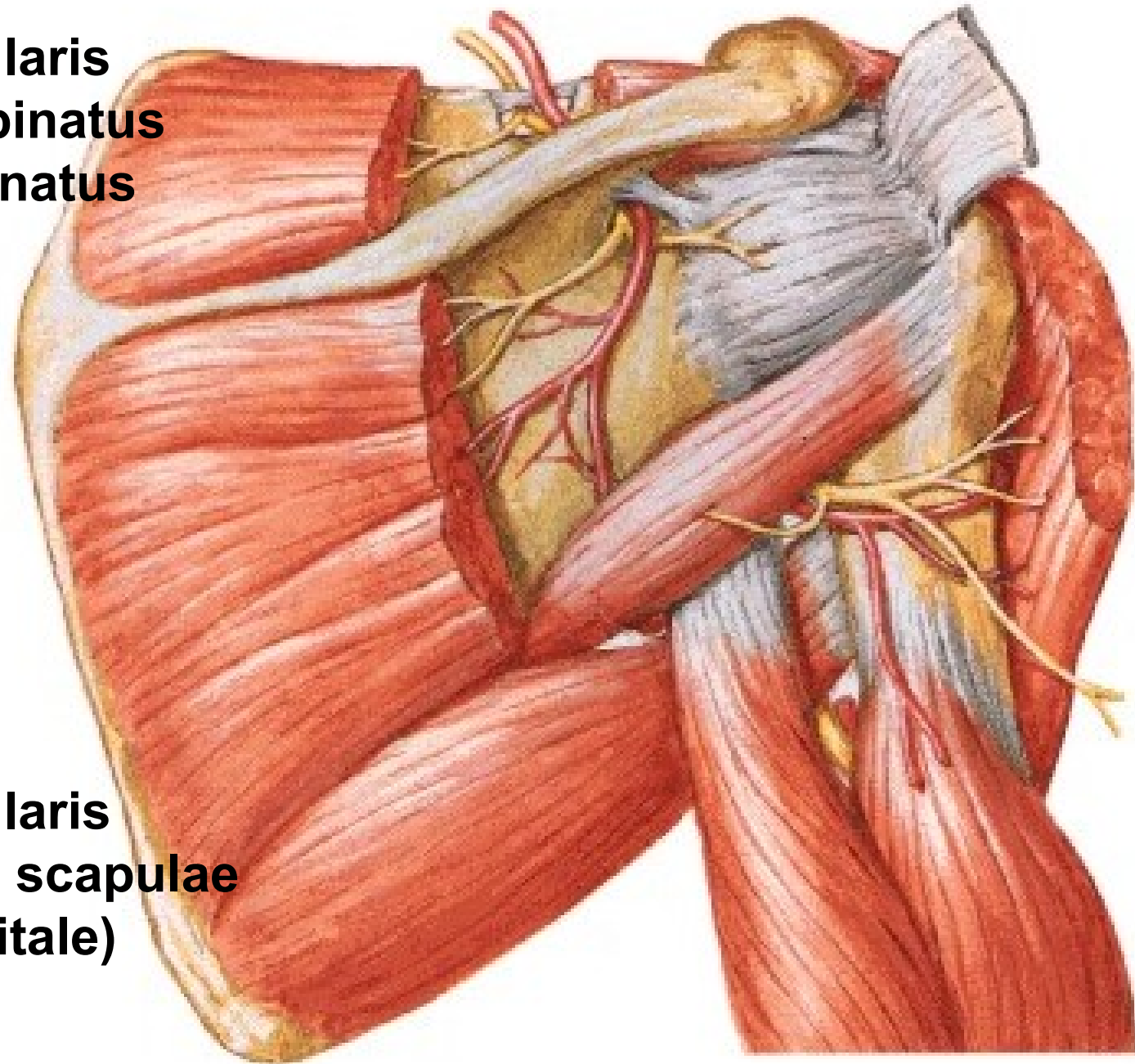


N suprascapularis
A. suprascapularis



N. suprascapularis

- m. supraspinatus
- m. infraspinatus
- art. humeri



A. suprascapularis

A. circumflexa scapulae
(for. omotricipitale)

N. pectoralis lateralis (C5, C6, C7)

- mm. pectorales

N. pectoralis medialis (C8, T1)

- mm. pectorales

N. subscapularis sup. (C5)

- m. subscapularis

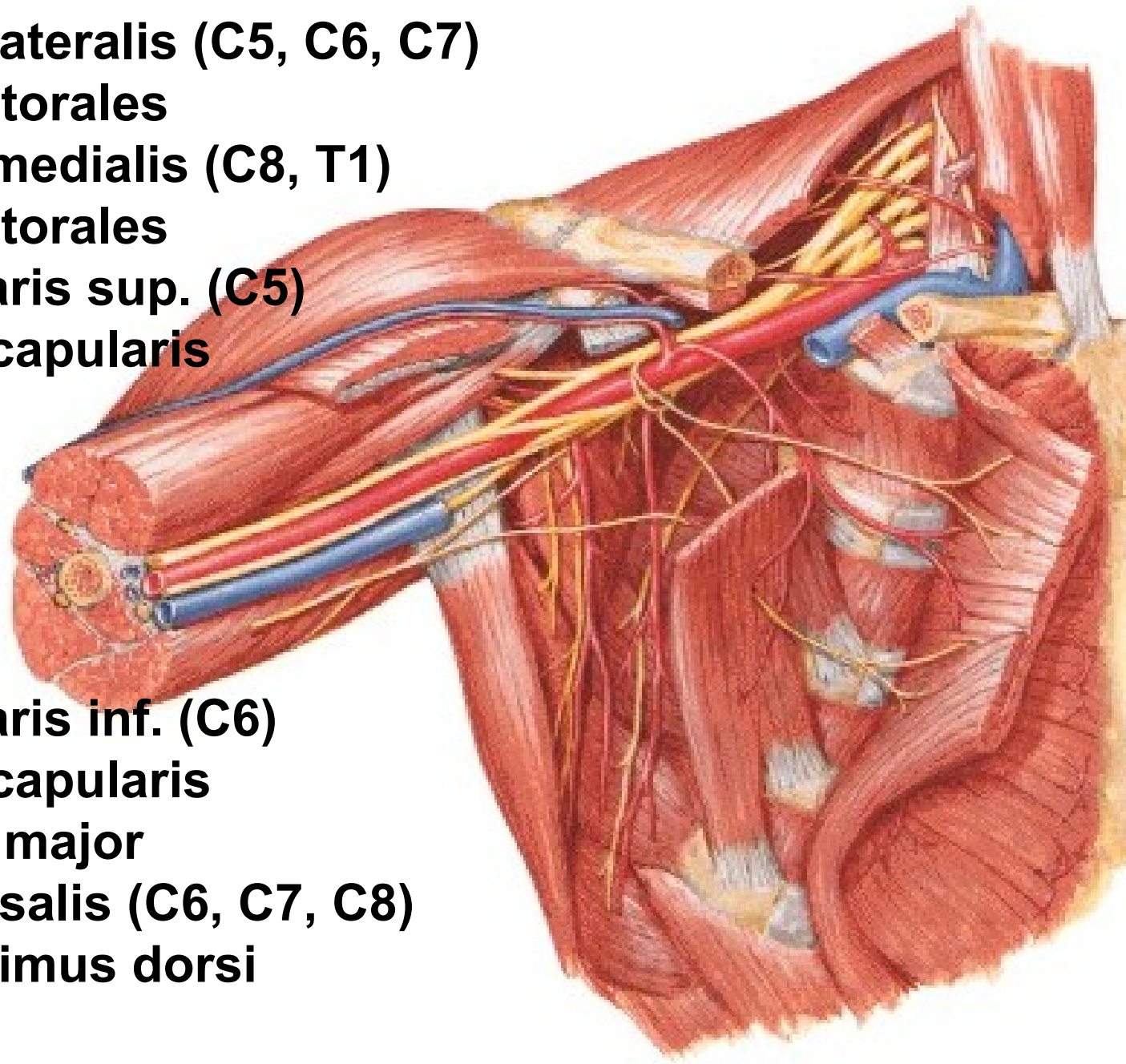
N. subscapularis inf. (C6)

- m. subscapularis

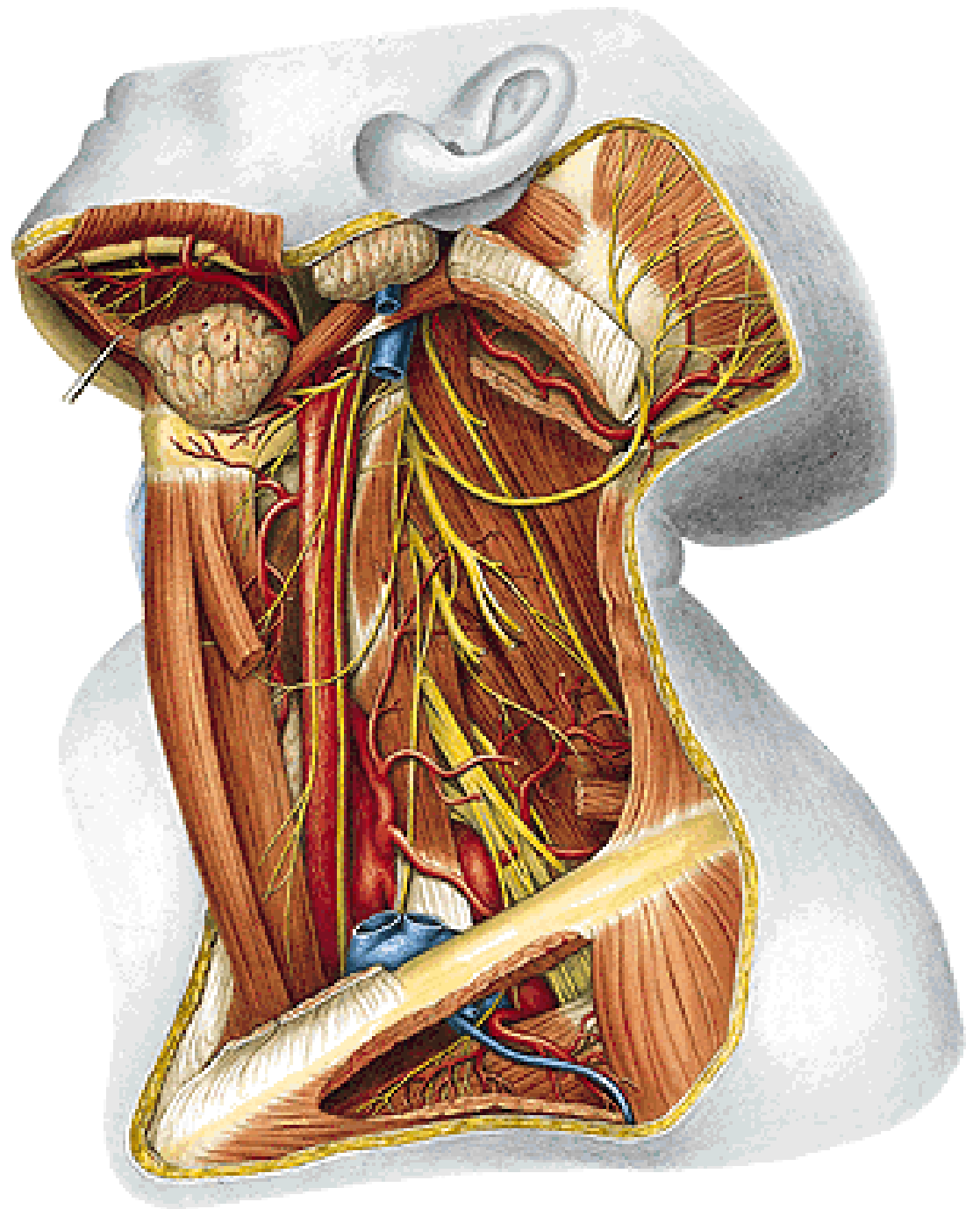
- m. teres major

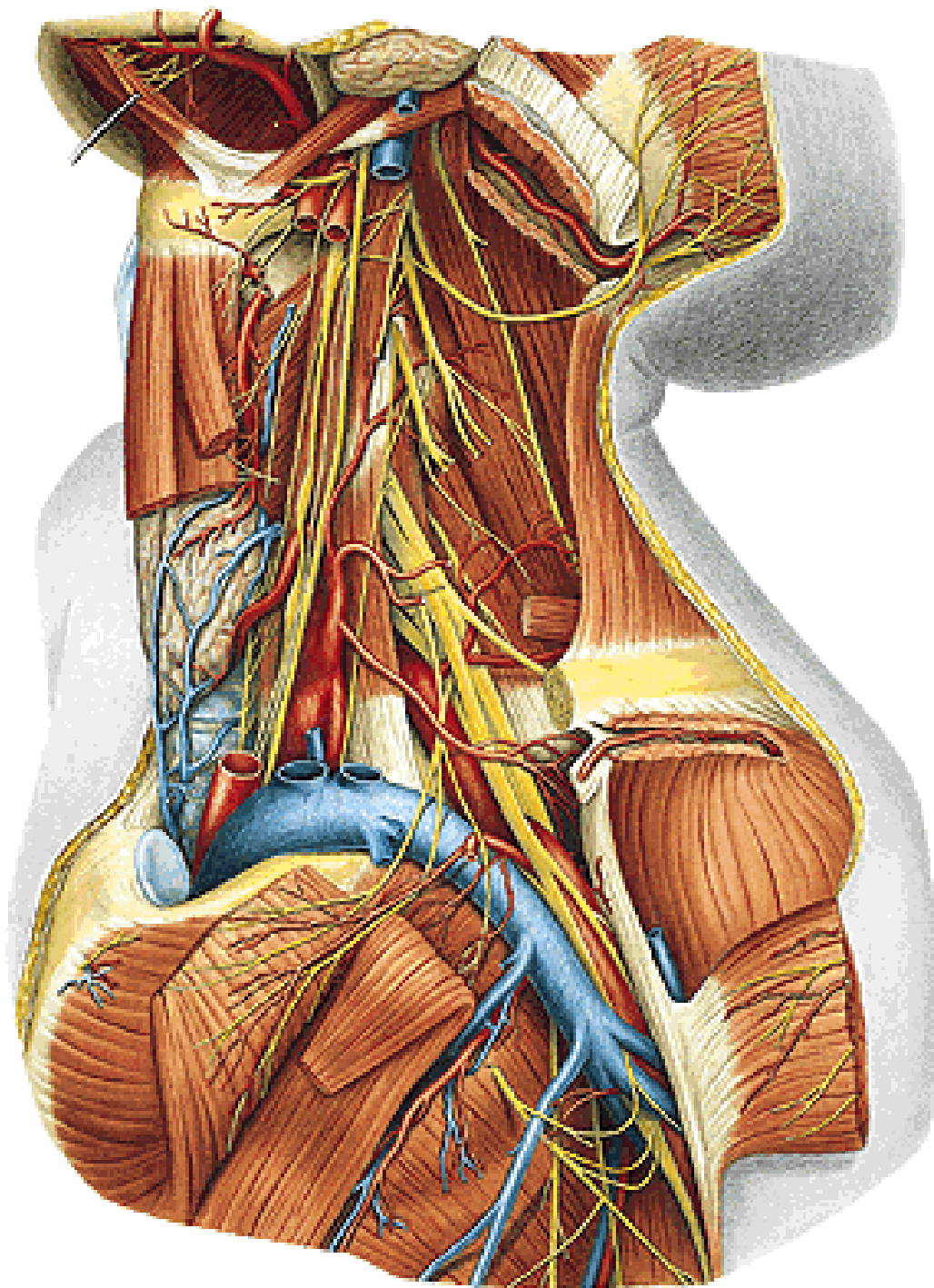
N. thoracodorsalis (C6, C7, C8)

- m. latissimus dorsi



N. phrenicus





PARS INFRACLAVICULARIS
(terminal branches)

Fasciculus lateralis

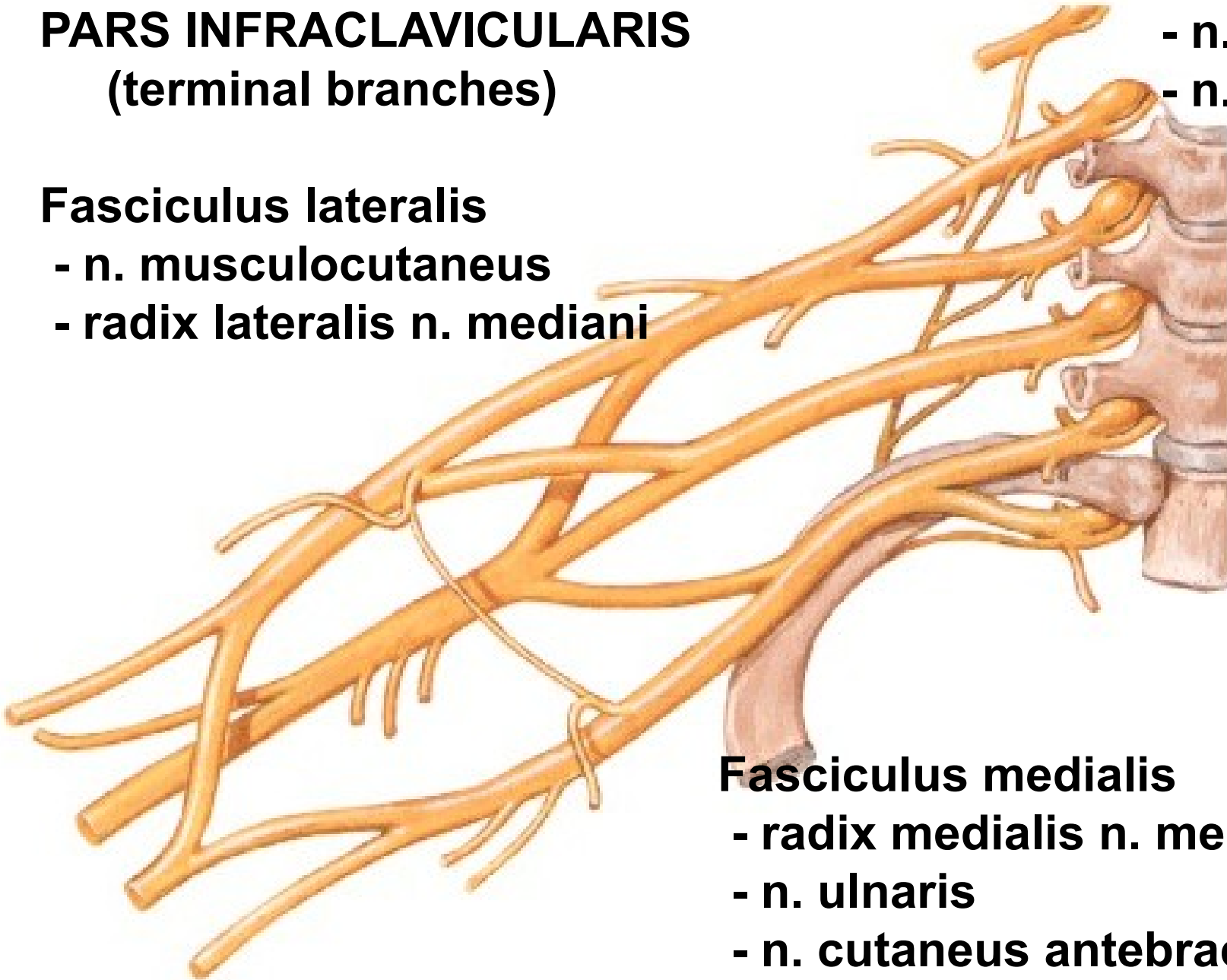
- n. musculocutaneus
- radix lateralis n. mediani

Fasciculus posterior

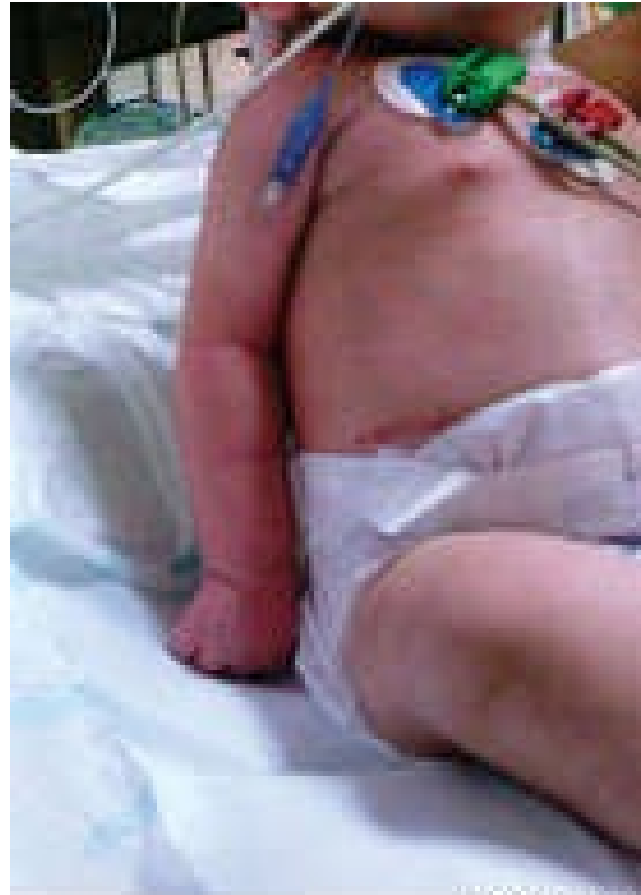- n. axillaris
- n. radialis

Fasciculus medialis

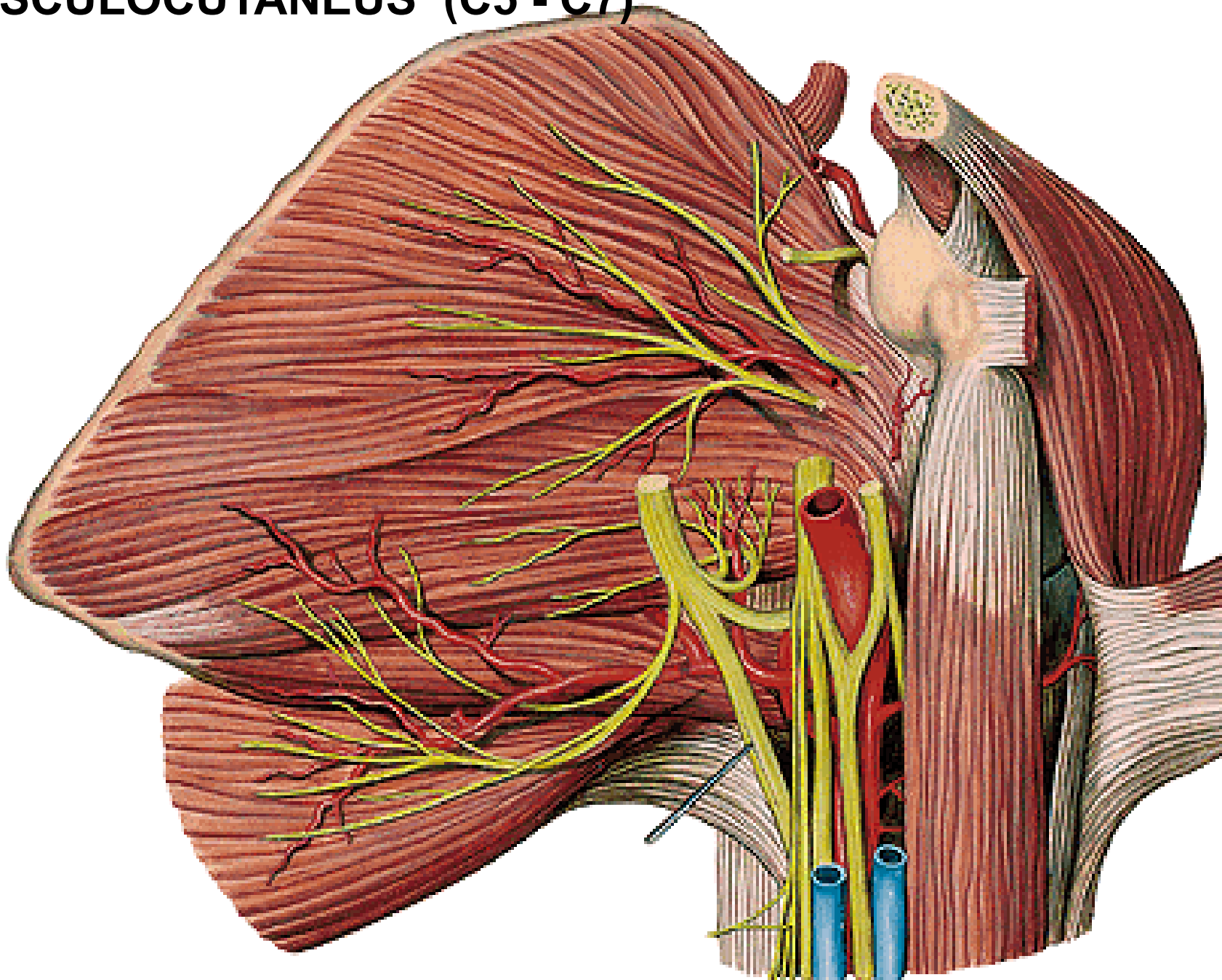
- radix medialis n. mediani
- n. ulnaris
- n. cutaneus antebrachii med.
- n. cutaneus brachii medialis



**Waiter's tip position
(Erb's palsy):
shoulder adduction with internal rotation
elbow extension
forearm pronation
wrist flexion
finger flexion**

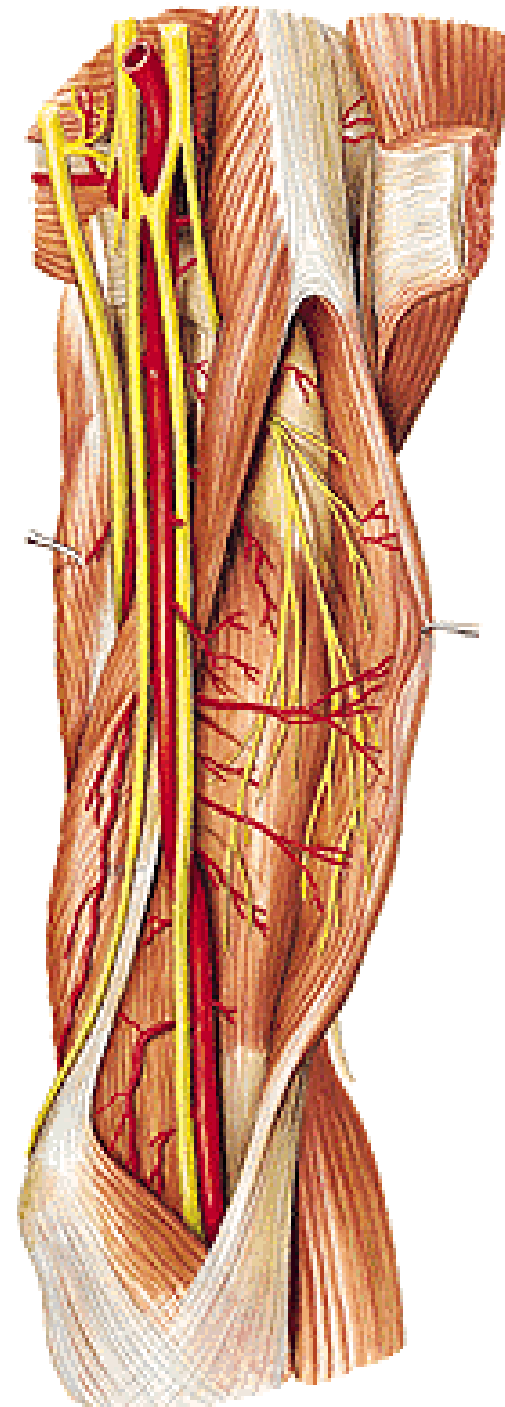
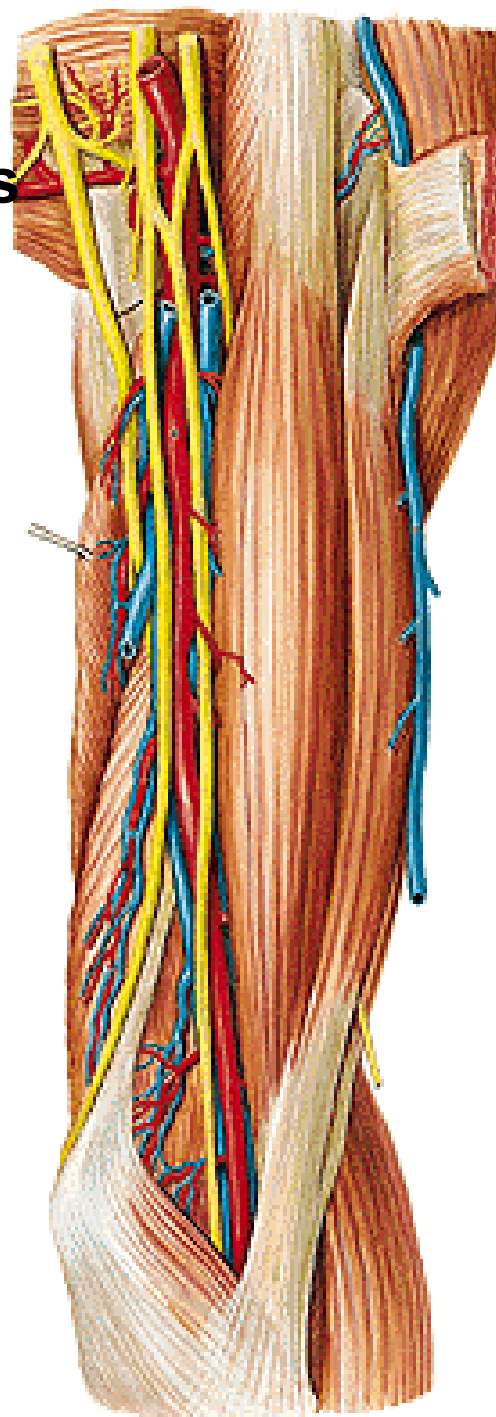


N. MUSCULOCUTANEUS (C5 - C7)

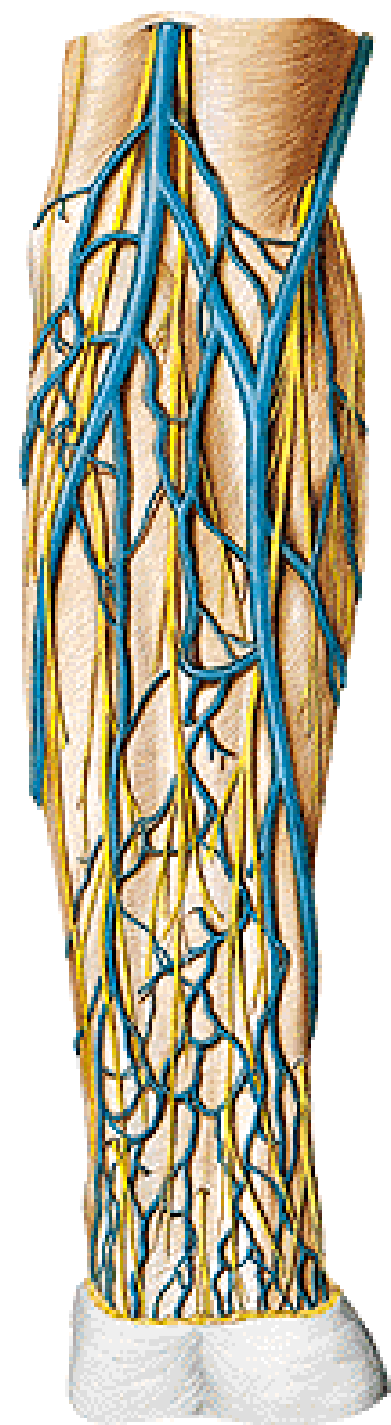


N. musculocutaneus

- **m. coracobrachialis**
- **m. biceps brachii**
- **m. brachialis**

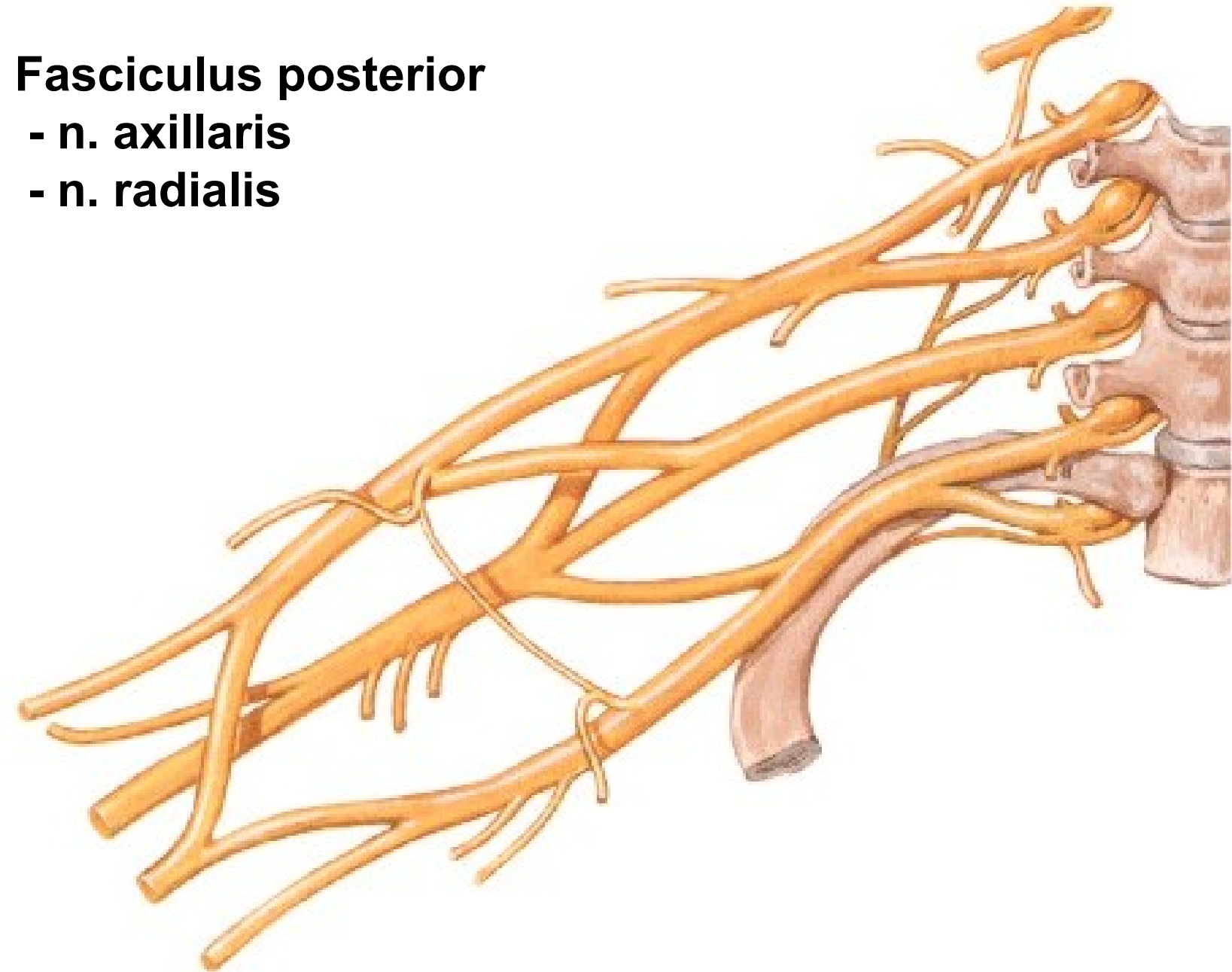


N. cutaneus antebrachii lat.

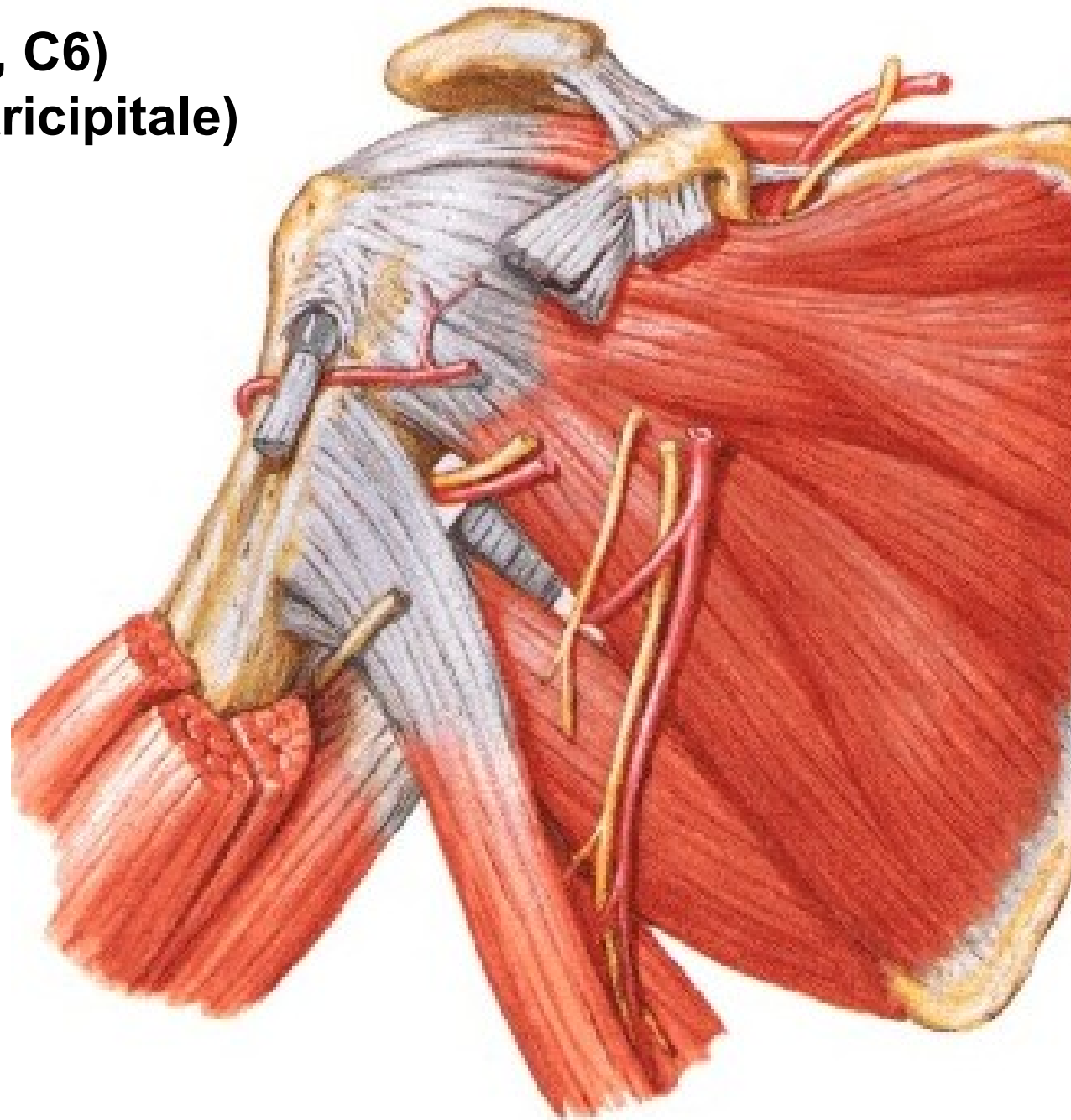


Fasciculus posterior

- n. axillaris**
- n. radialis**



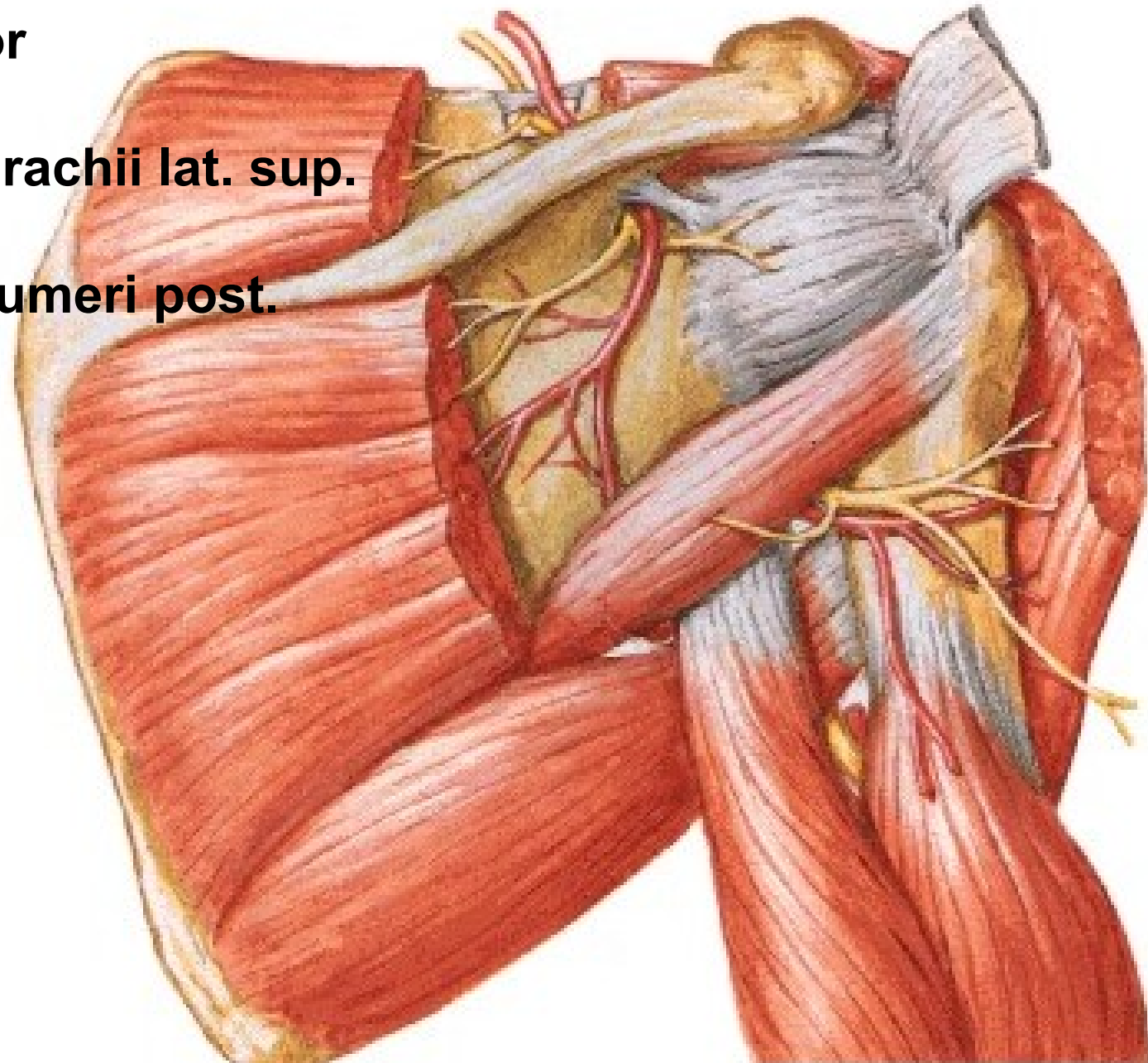
N. AXILLARIS (C5, C6)
(foramen humerotricipitale)



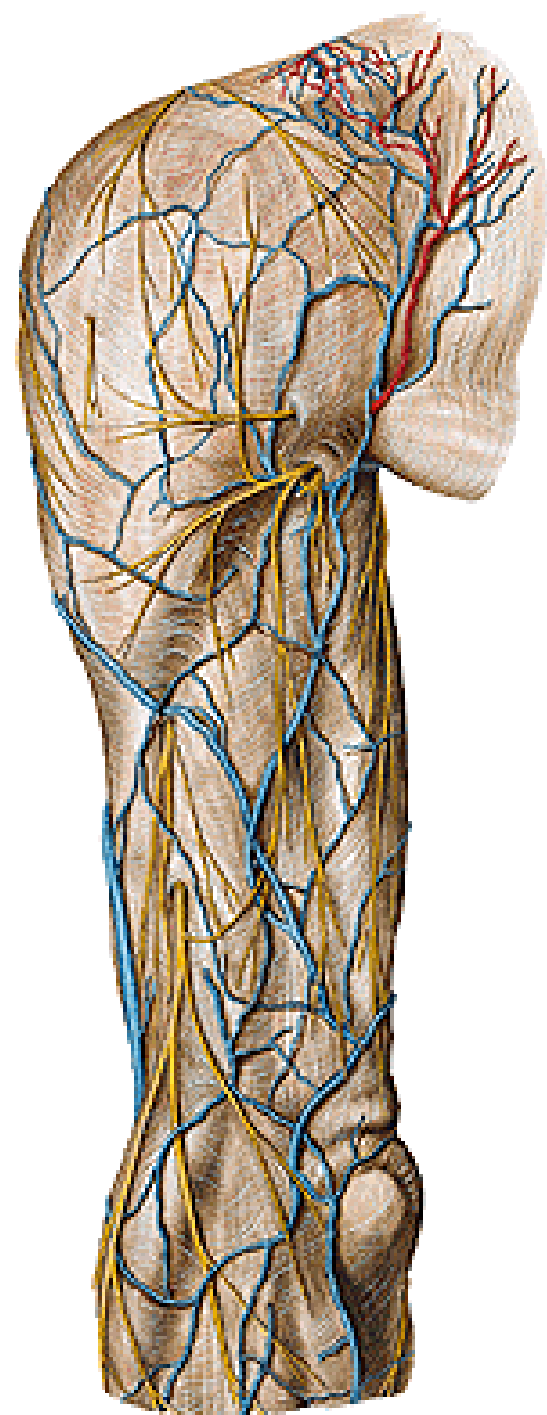
N. axillaris

- m. deltoideus
- m. teres minor
- art. humeri
- n. cutaneus brachii lat. sup.

A. circumflexa humeri post.



N. cutaneus brachii lat. sup.

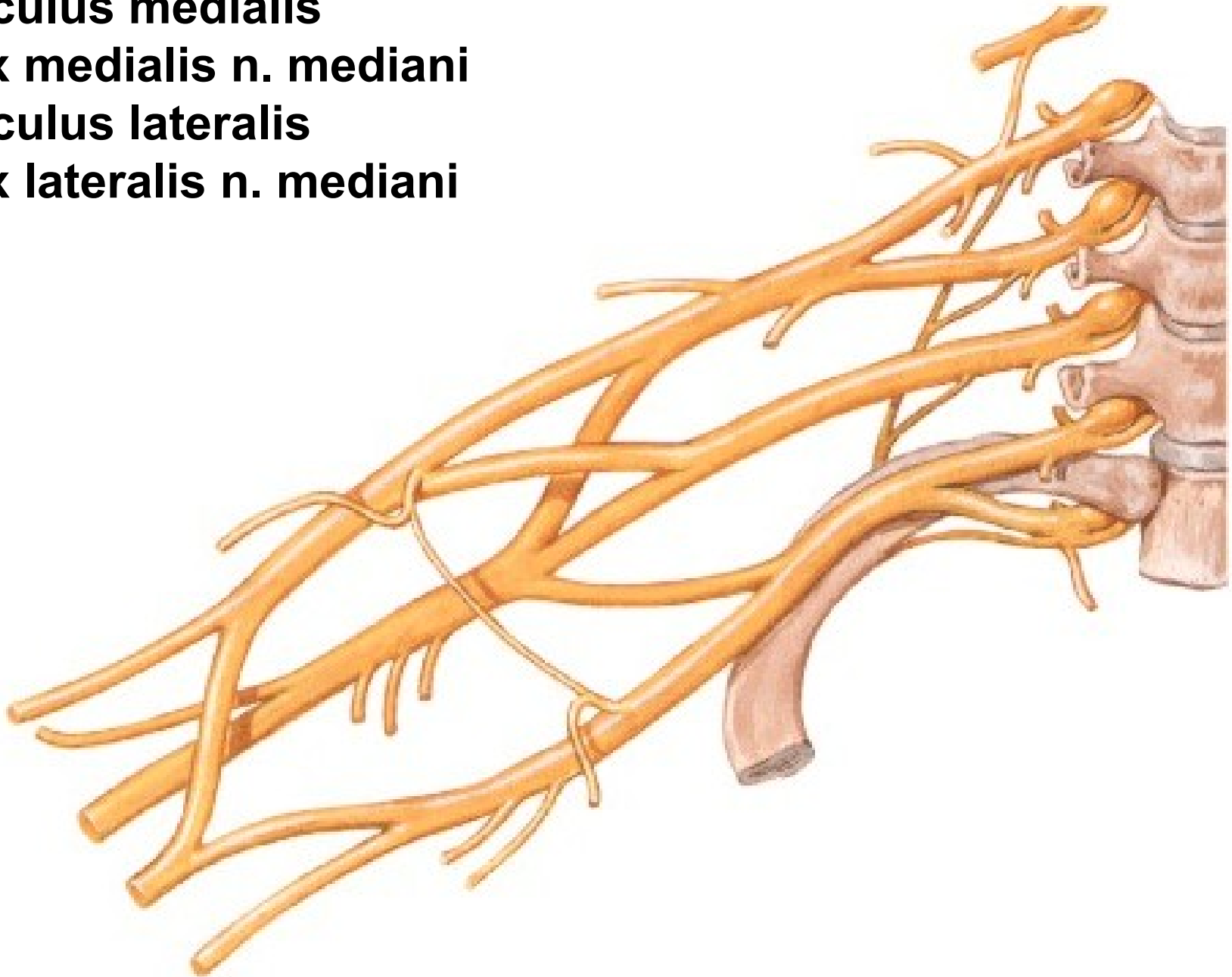


Fasciculus medialis

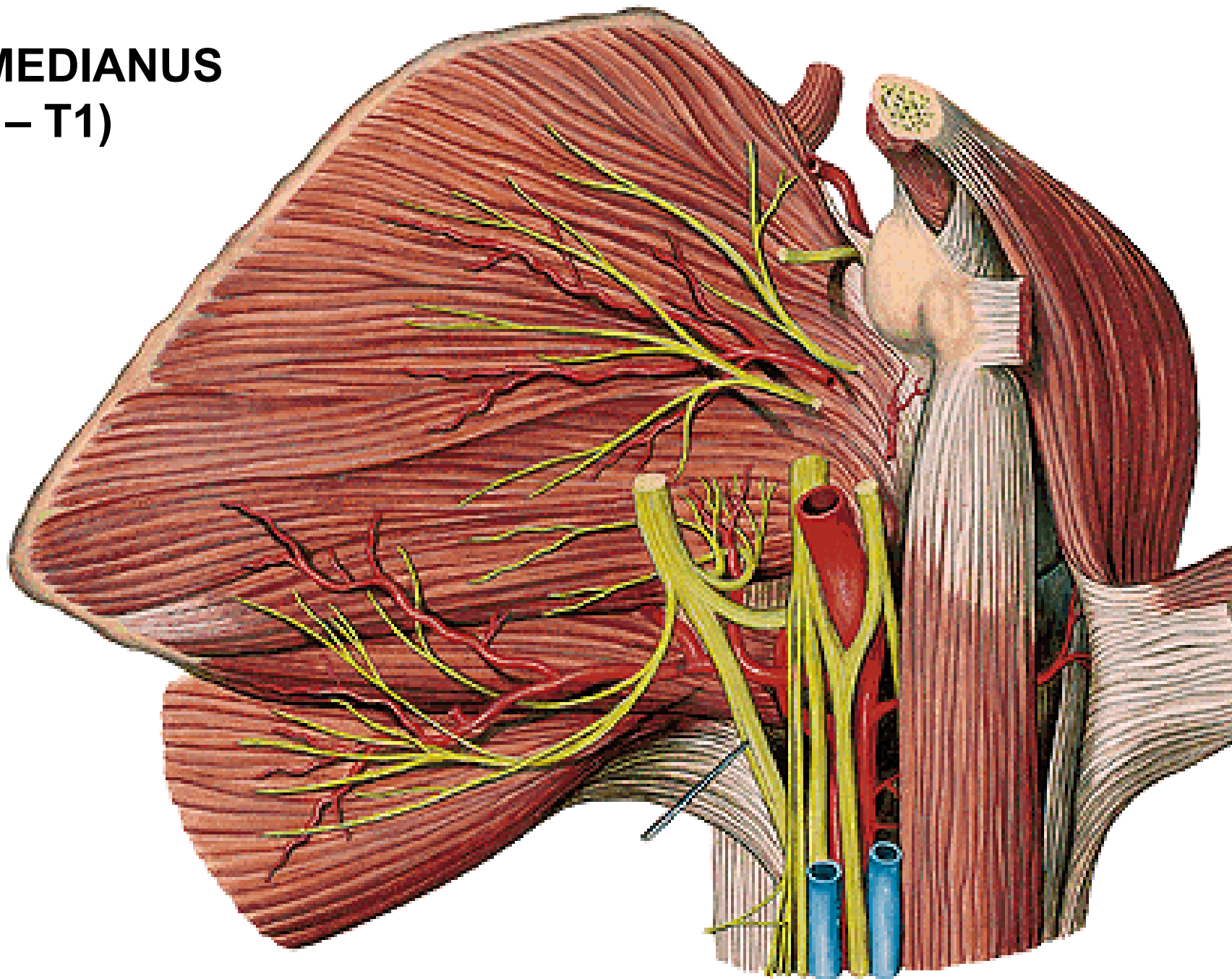
- radix medialis n. mediani

Fasciculus lateralis

- radix lateralis n. mediani

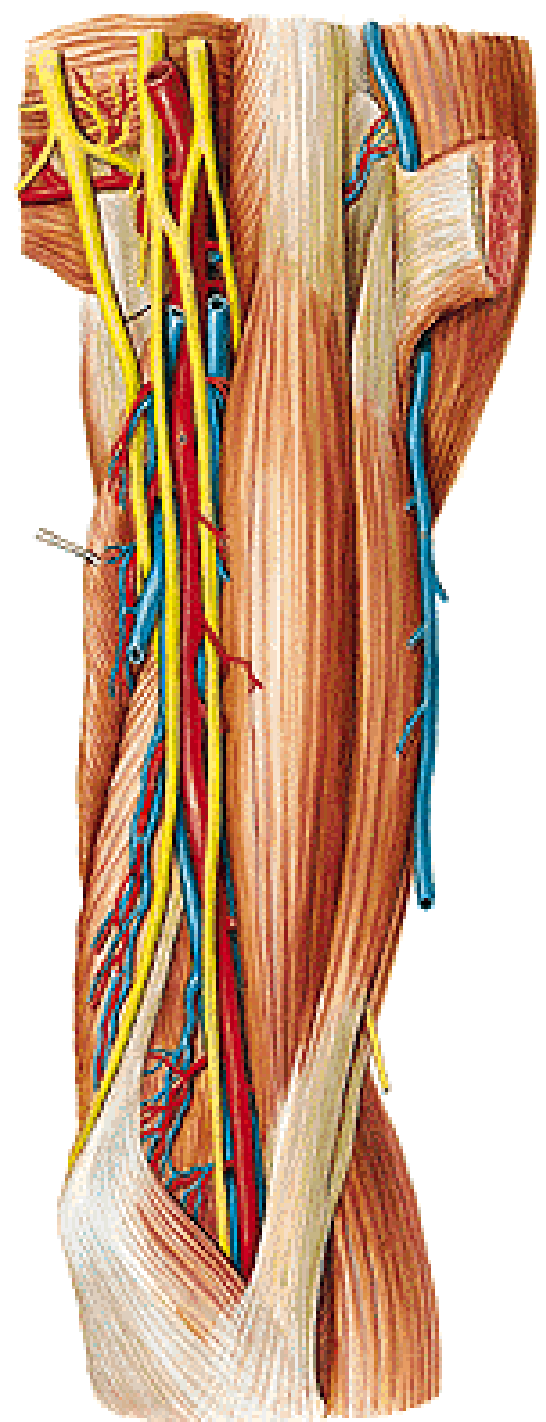


**N. MEDIANUS
(C5 – T1)**

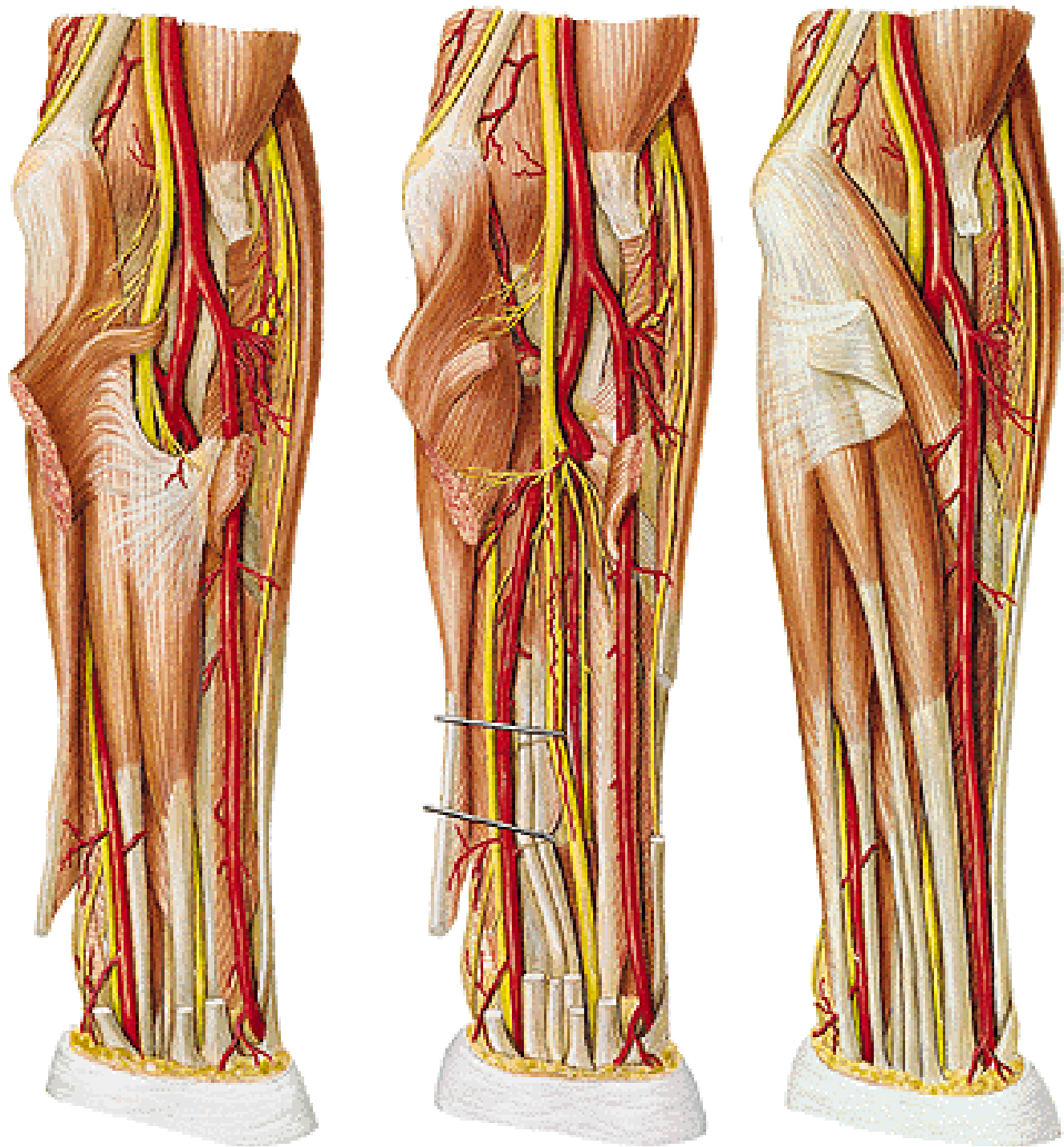


N. medianus

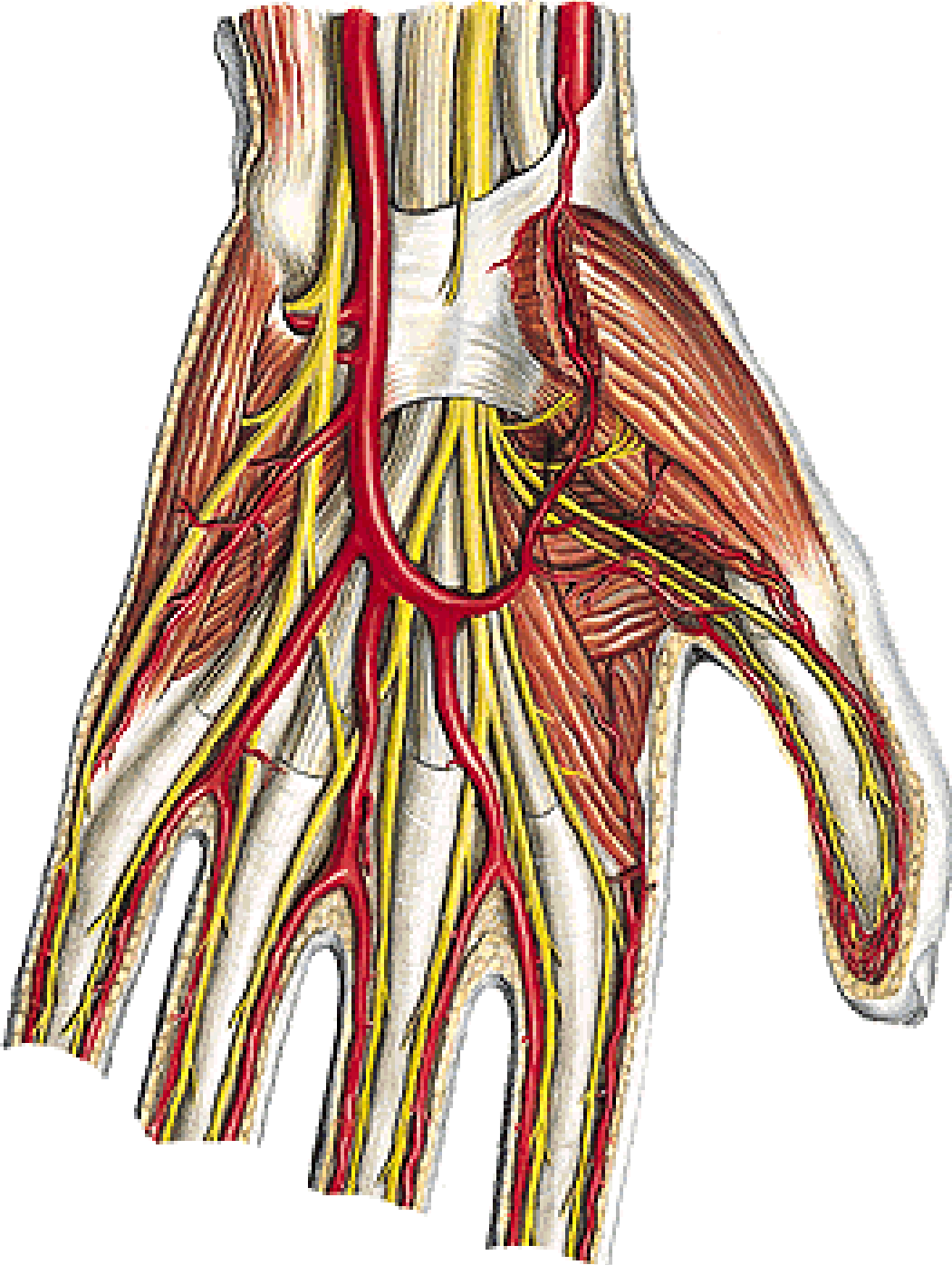
(Sulcus bicipitalis medialis)



N. medianus



N. medianus



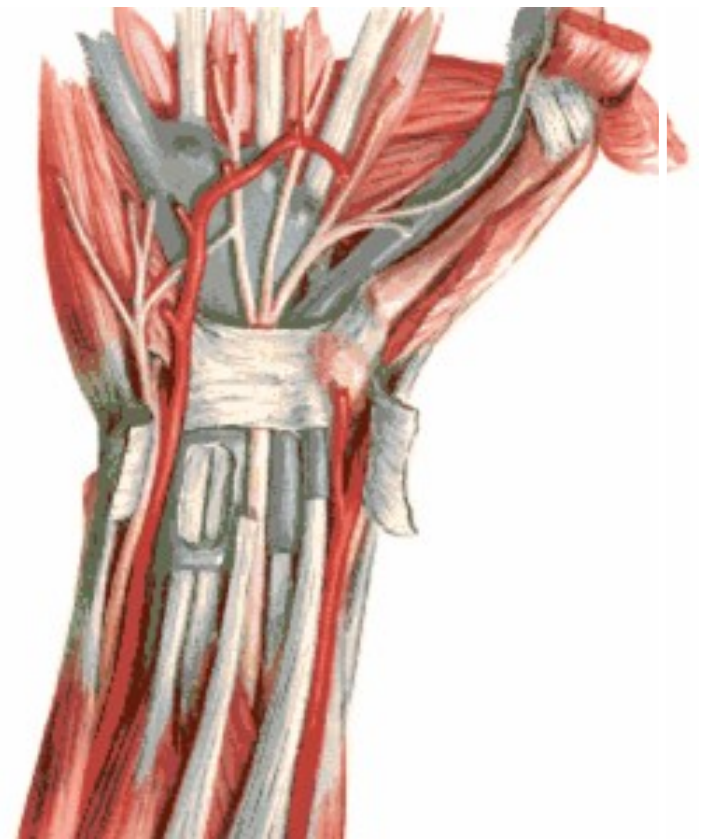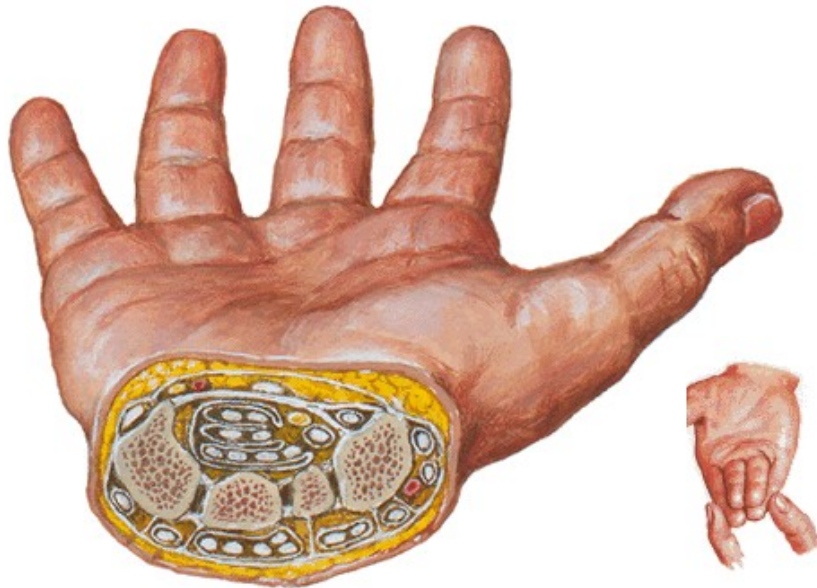Canalis carpi: n. medianus

**m. flexor digitorum spf. (3,4
2,5)**

m. flexor digitorum prof.

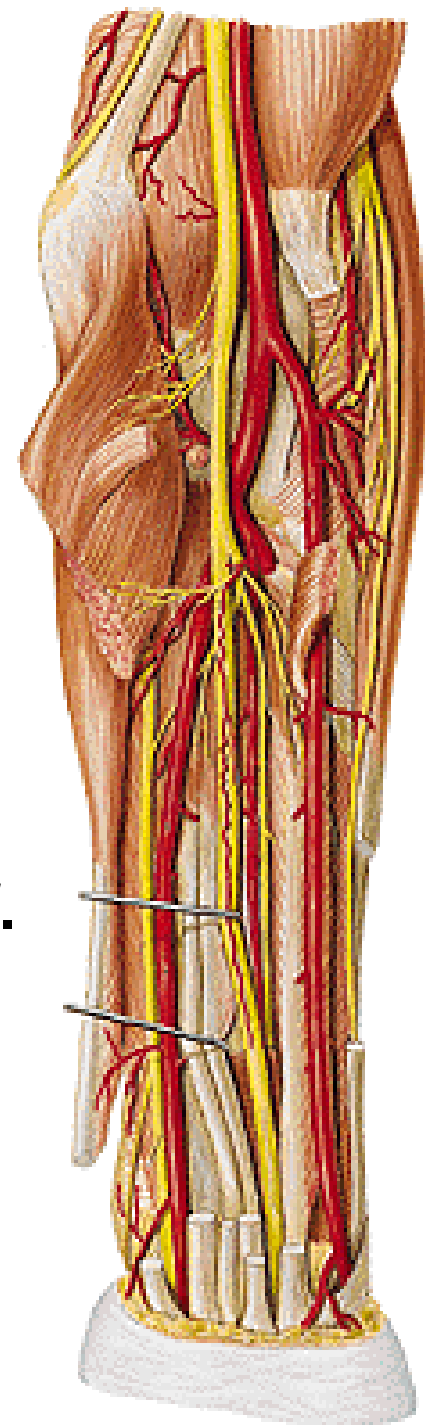
m. flexor pollicis longus

m. flexor carpi ulnaris



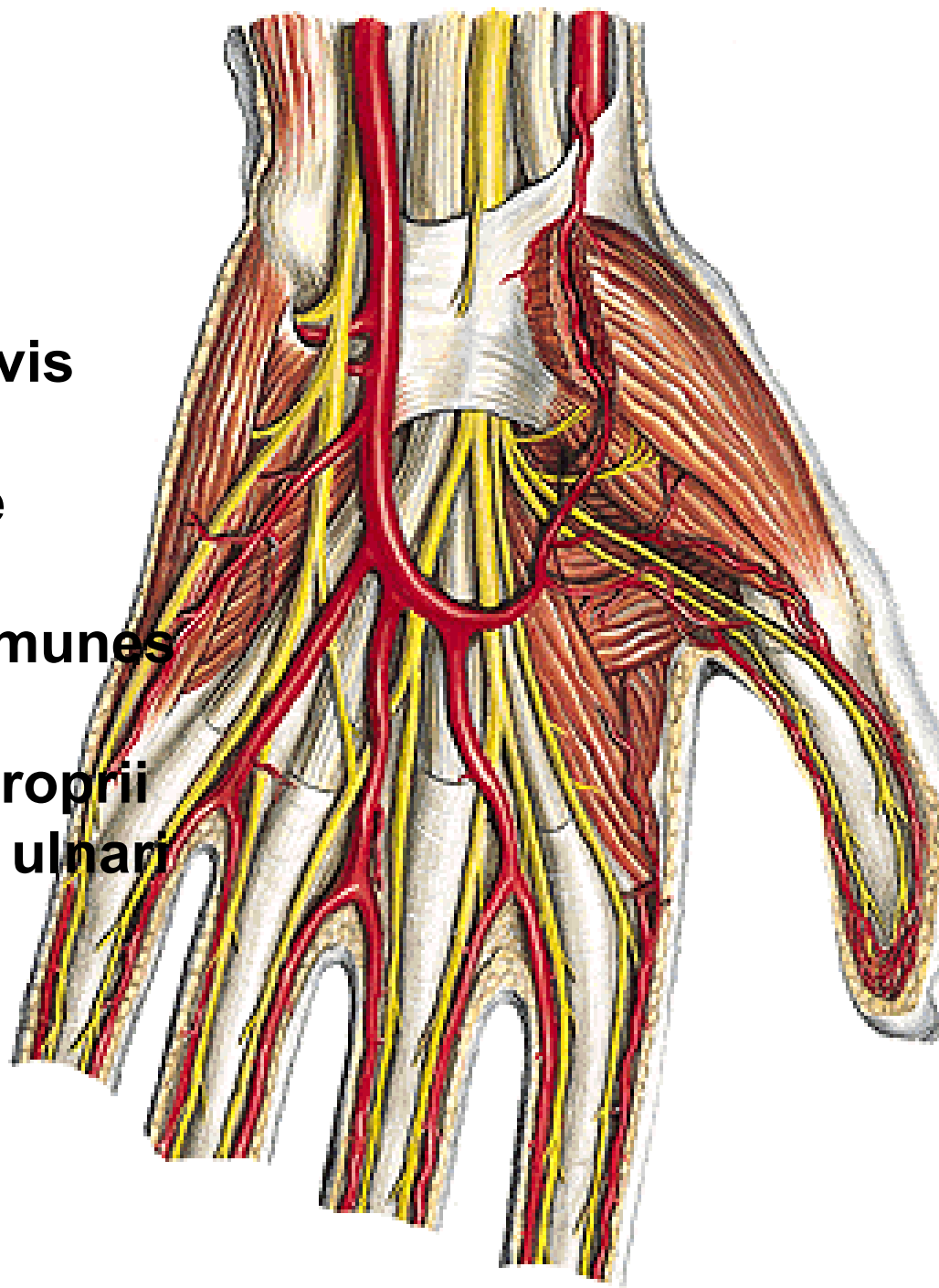
N. medianus

- **rr. articulares**
- **rr. musculares**
 - **m. pronator teres**
 - **m. flexor carpi radialis**
 - **m. palmaris longus**
 - **m. flexor digitorum spf.**
- **n. interosseus antebrachii ant.**
 - **m. flexor pollicis longus**
 - **radial half of m. flexor dig. prof.**
 - **m. pronator quadratus**
- **r. palmaris**



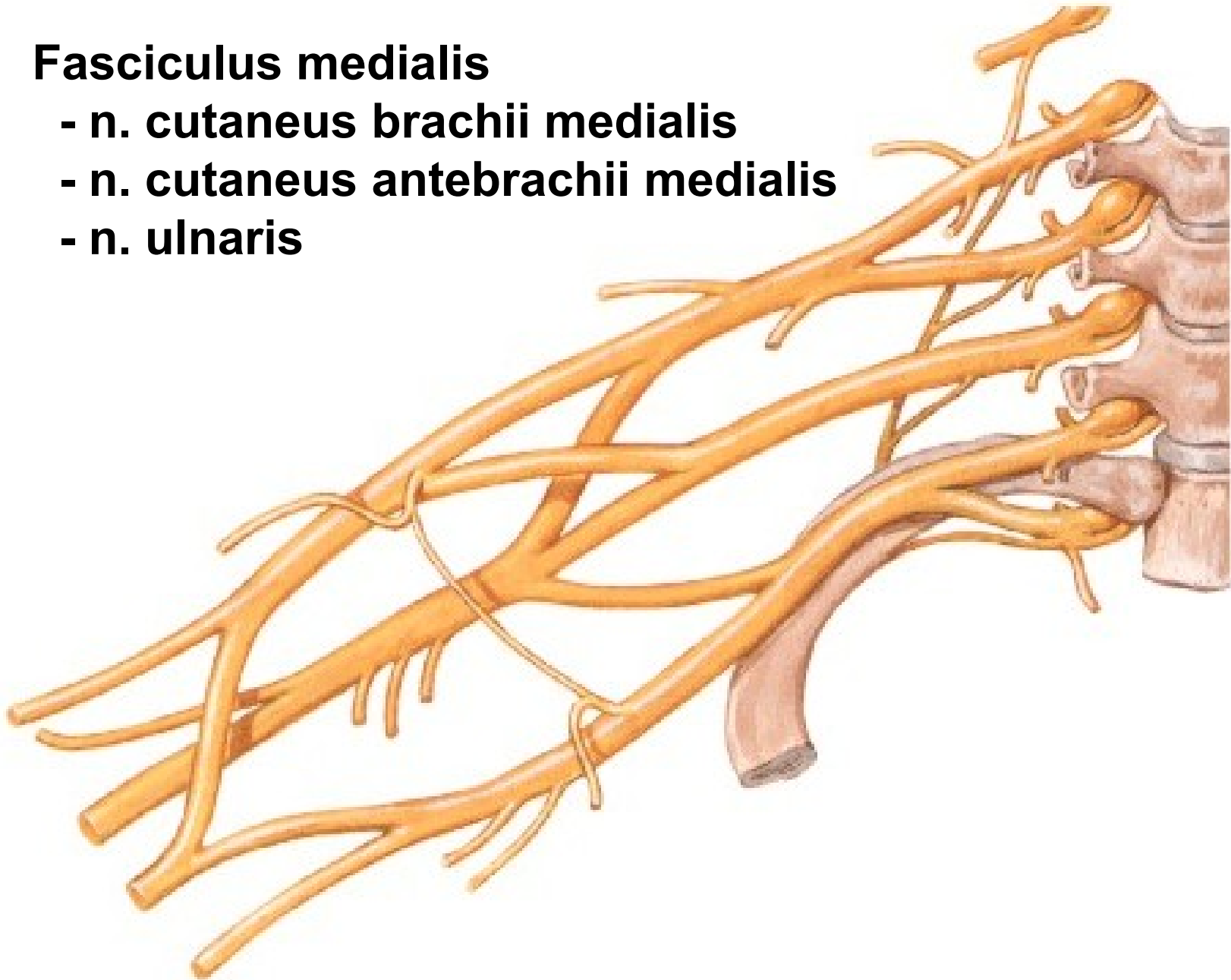
N. medianus

- r. thenaris
 - m. abductor pollicis brevis
 - m. flexor pollicis brevis
 - caput superficiale
 - m. opponens pollicis
- nn. digitales palmares communes
 - mm. lumbricales (I, II)
 - nn. digitales palmares proprii
- r. communicans cum nervo ulnari



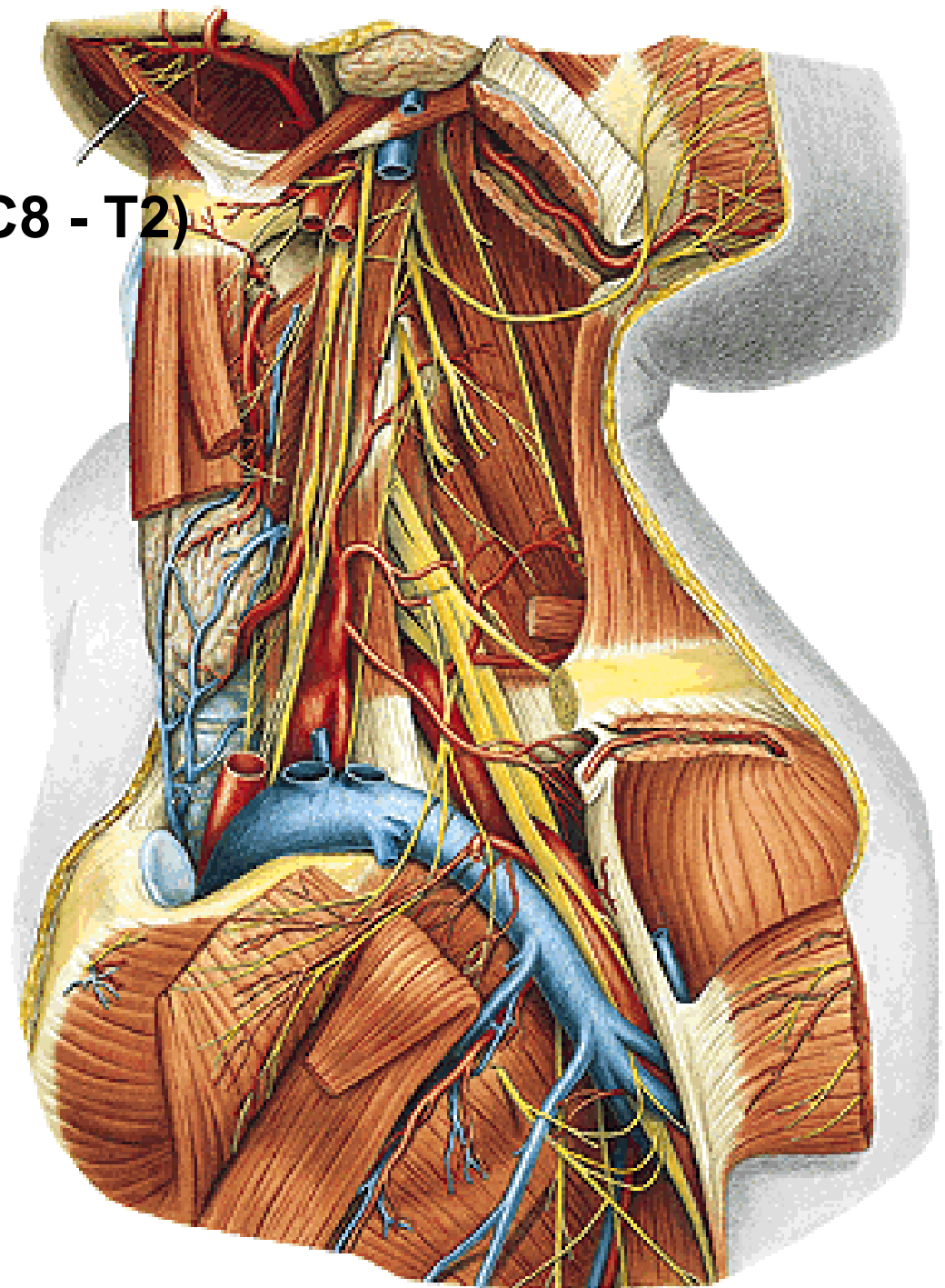
Fasciculus medialis

- **n. cutaneus brachii medialis**
- **n. cutaneus antebrachii medialis**
- **n. ulnaris**

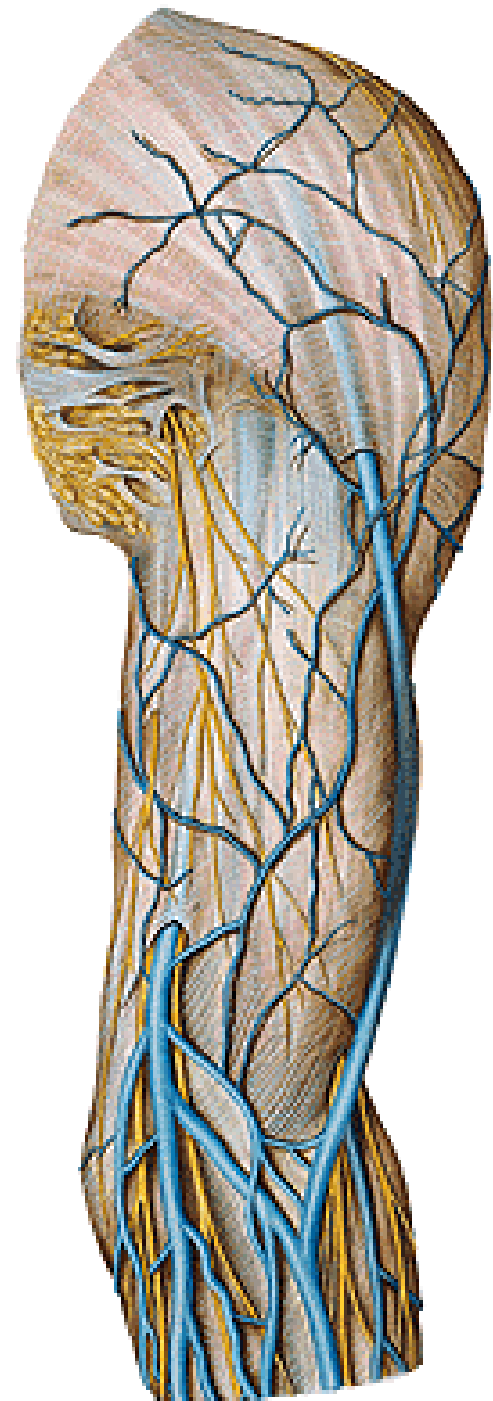


N. cutaneus brachii med. (C8 - T2)

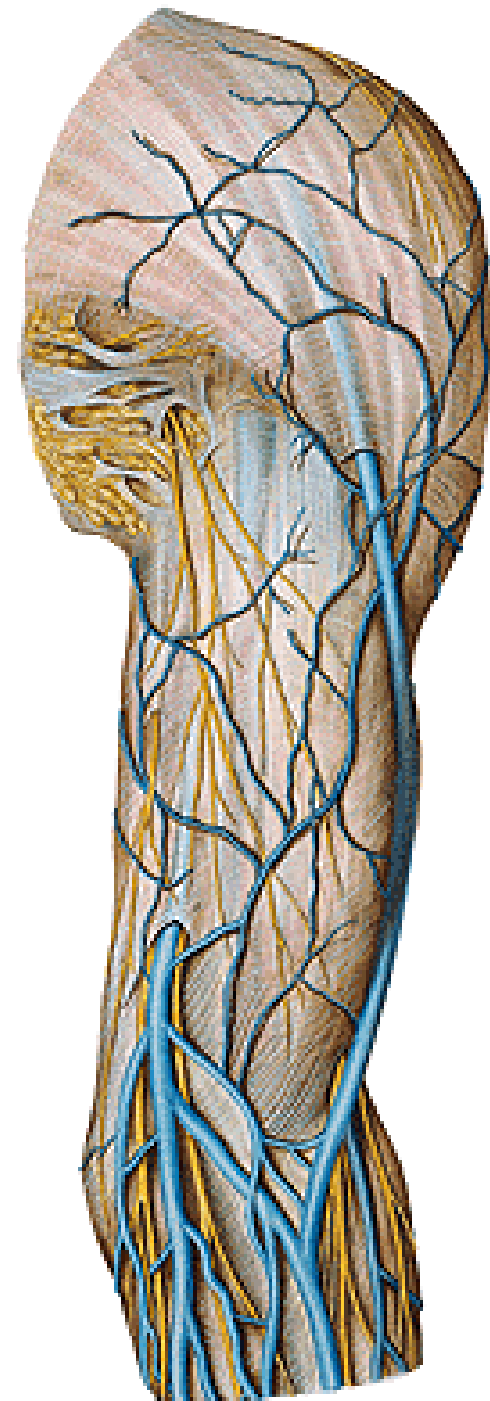
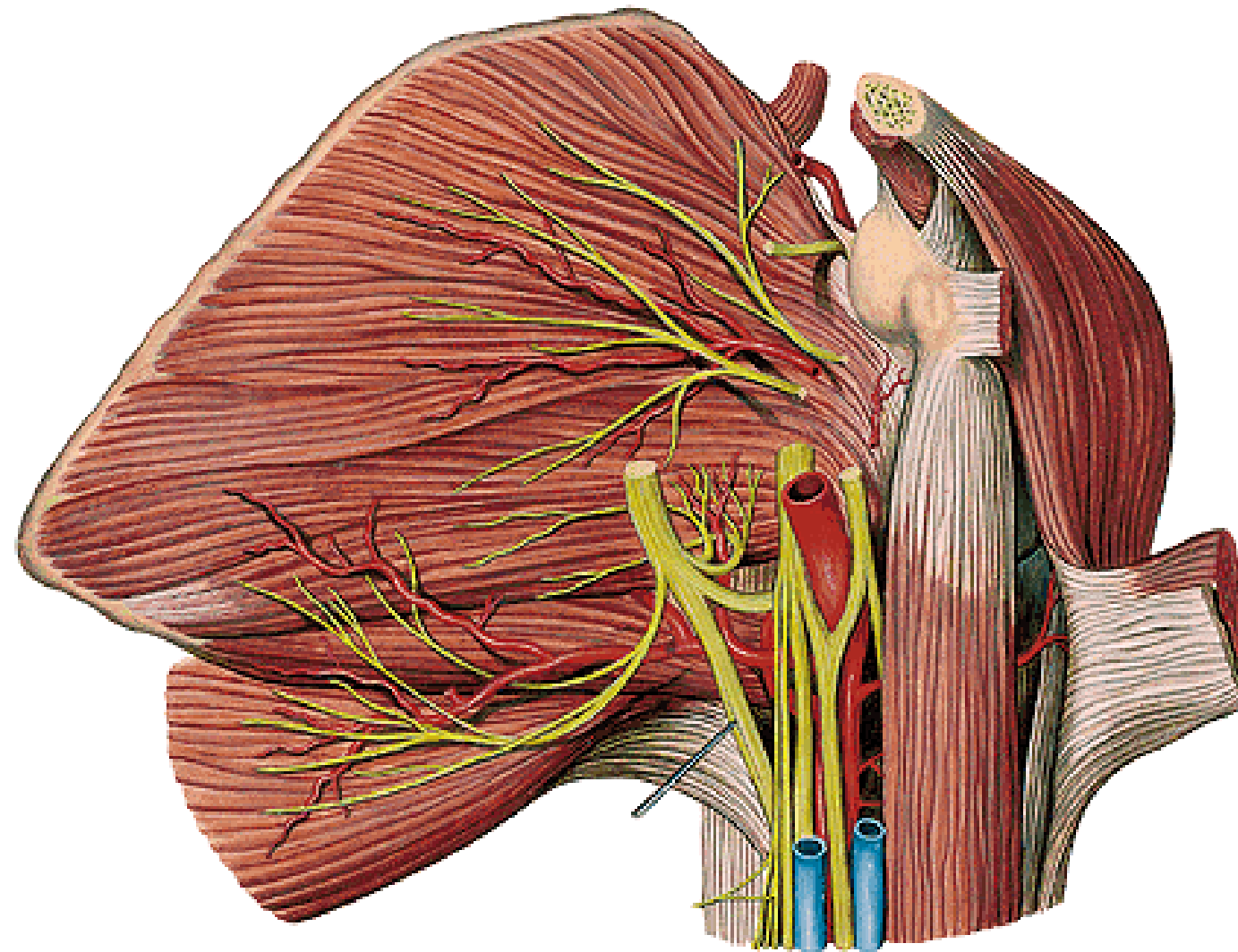
(nn. intercostobrachiales)



N. cutaneus brachii med.




N. cutaneus antebrachii med. (C8, T1)



N. cutaneus antebrachii med.

- r. anterior**
- r. posterior (ulnaris)**

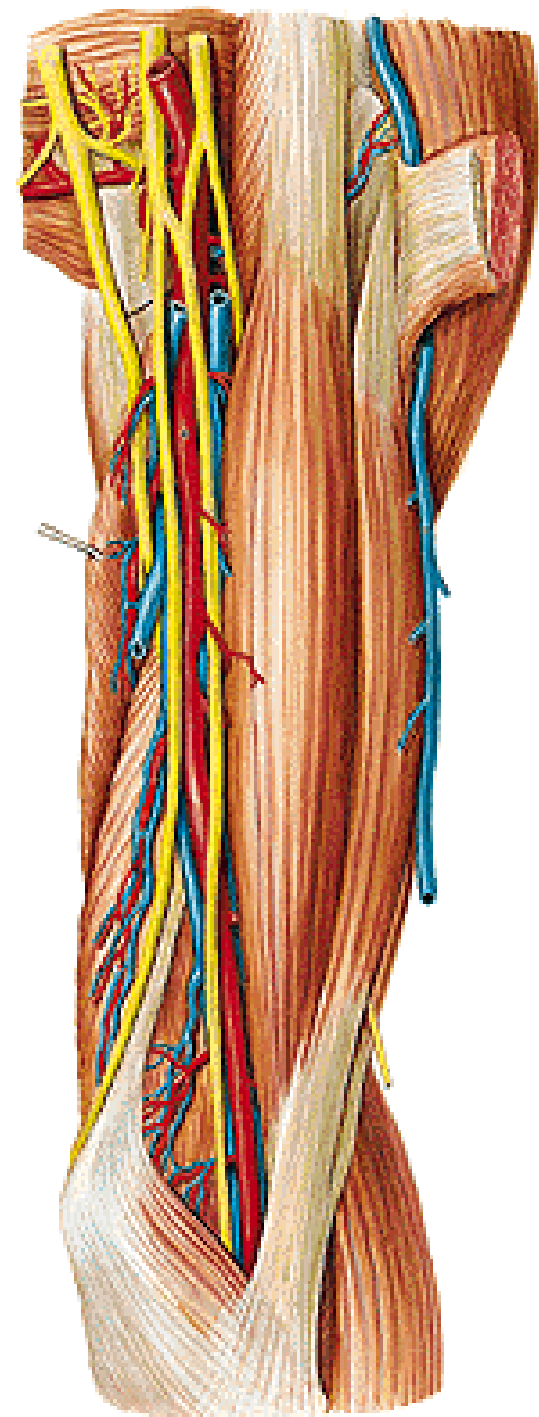
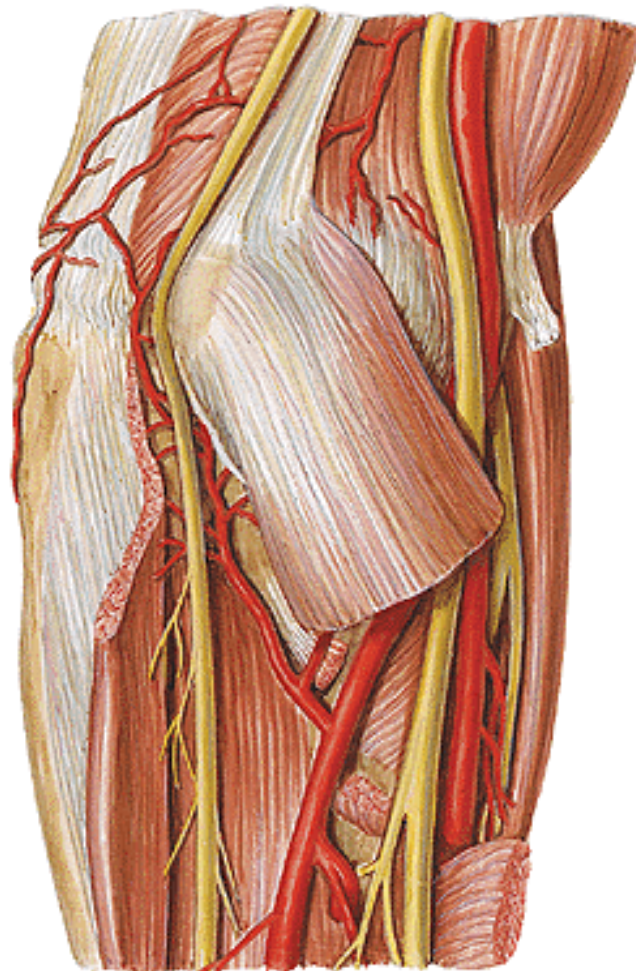


N. ulnaris (C7 - T1)

sulcus bicipitalis medialis

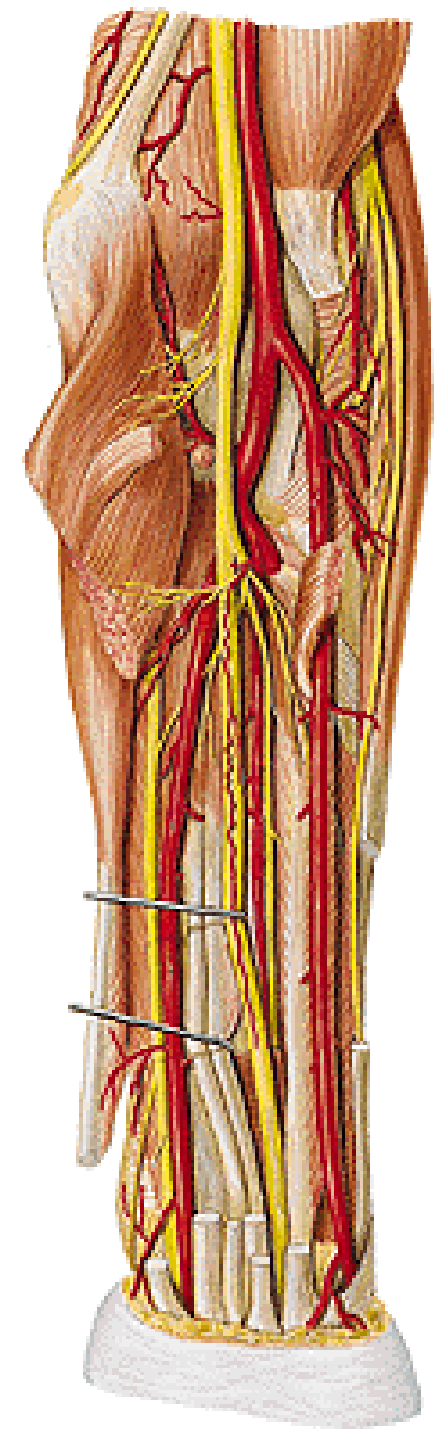
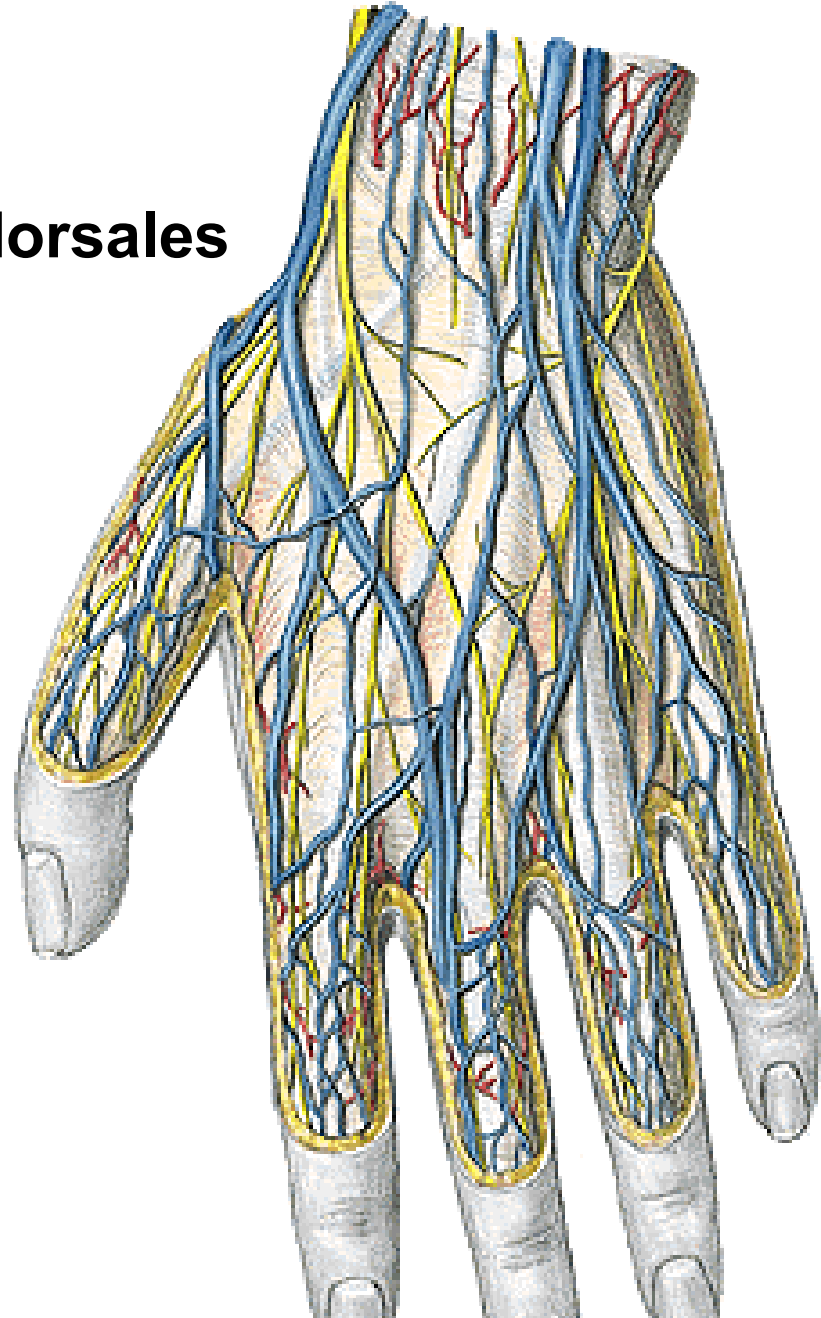
septum intermusculare brachii mediale

sulcus n. ulnaris



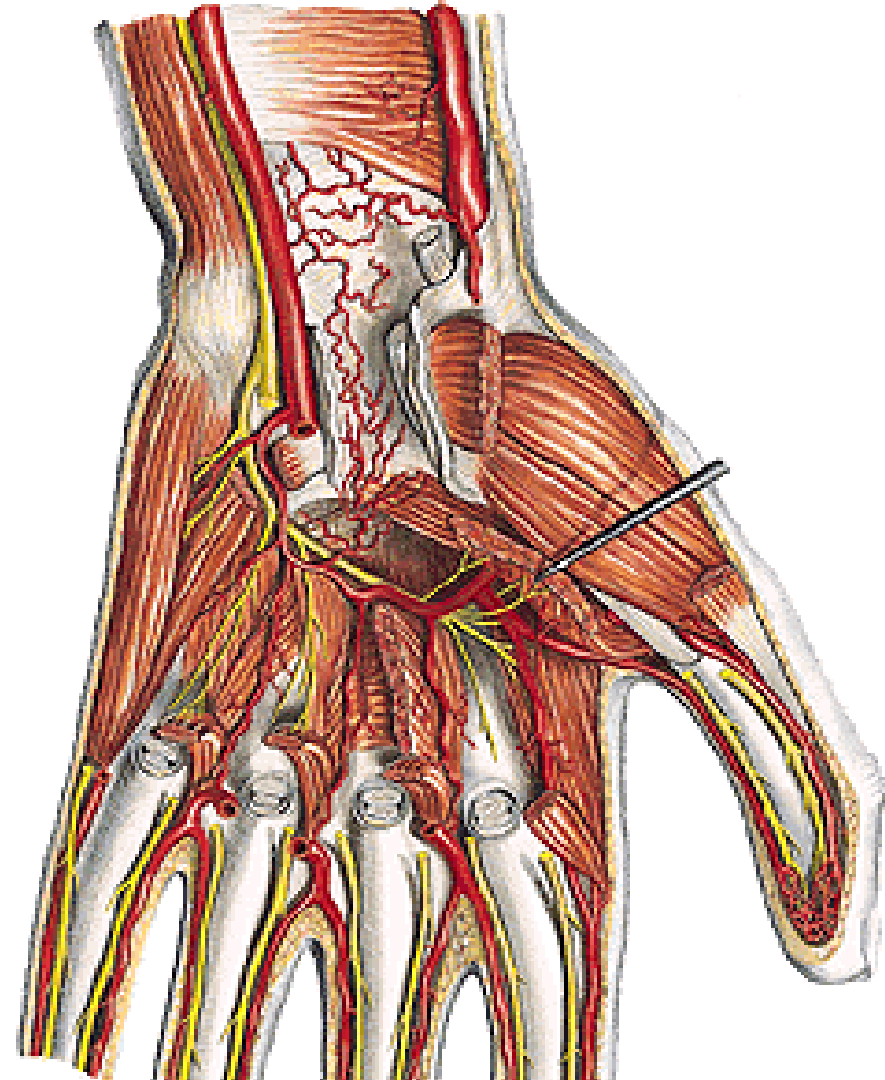
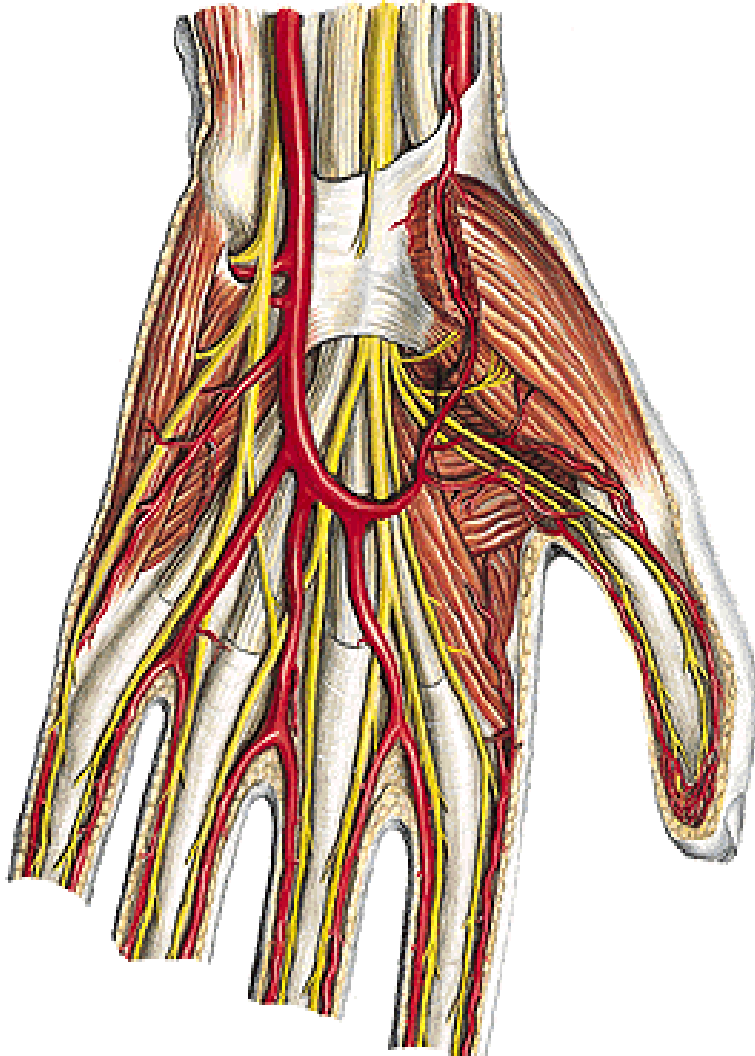
N. ulnaris

- rr. articulares
- rr. musculares
- r. dorsalis
- nn. digitales dorsales

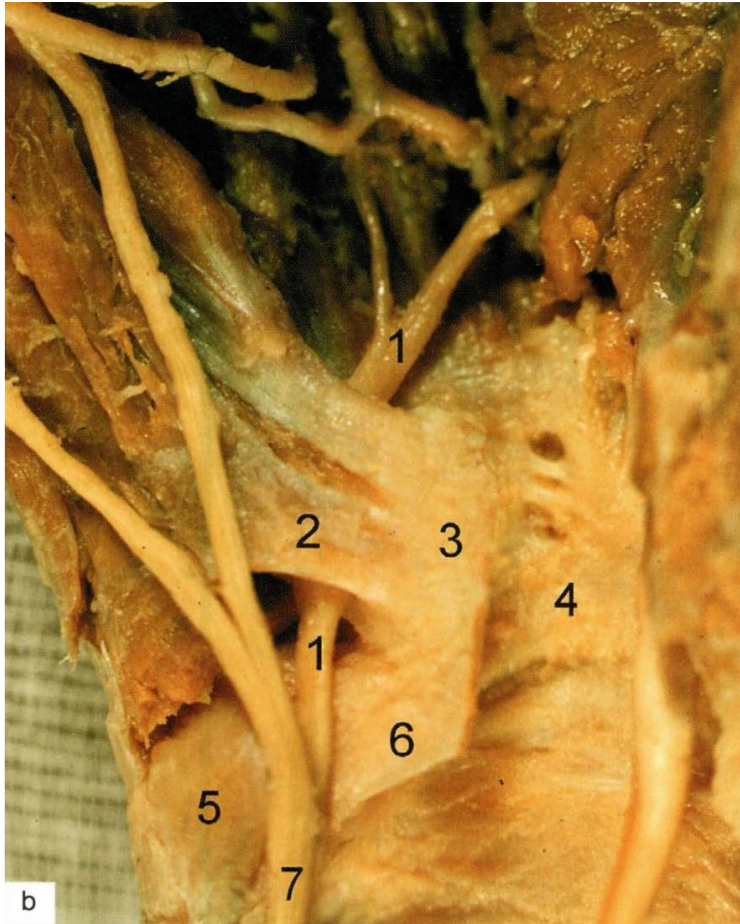


N. ULNARIS

- r. palmaris
- r. superficialis - nn. dig. palmares comm. et proprii
- r. profundus - rr. musculares



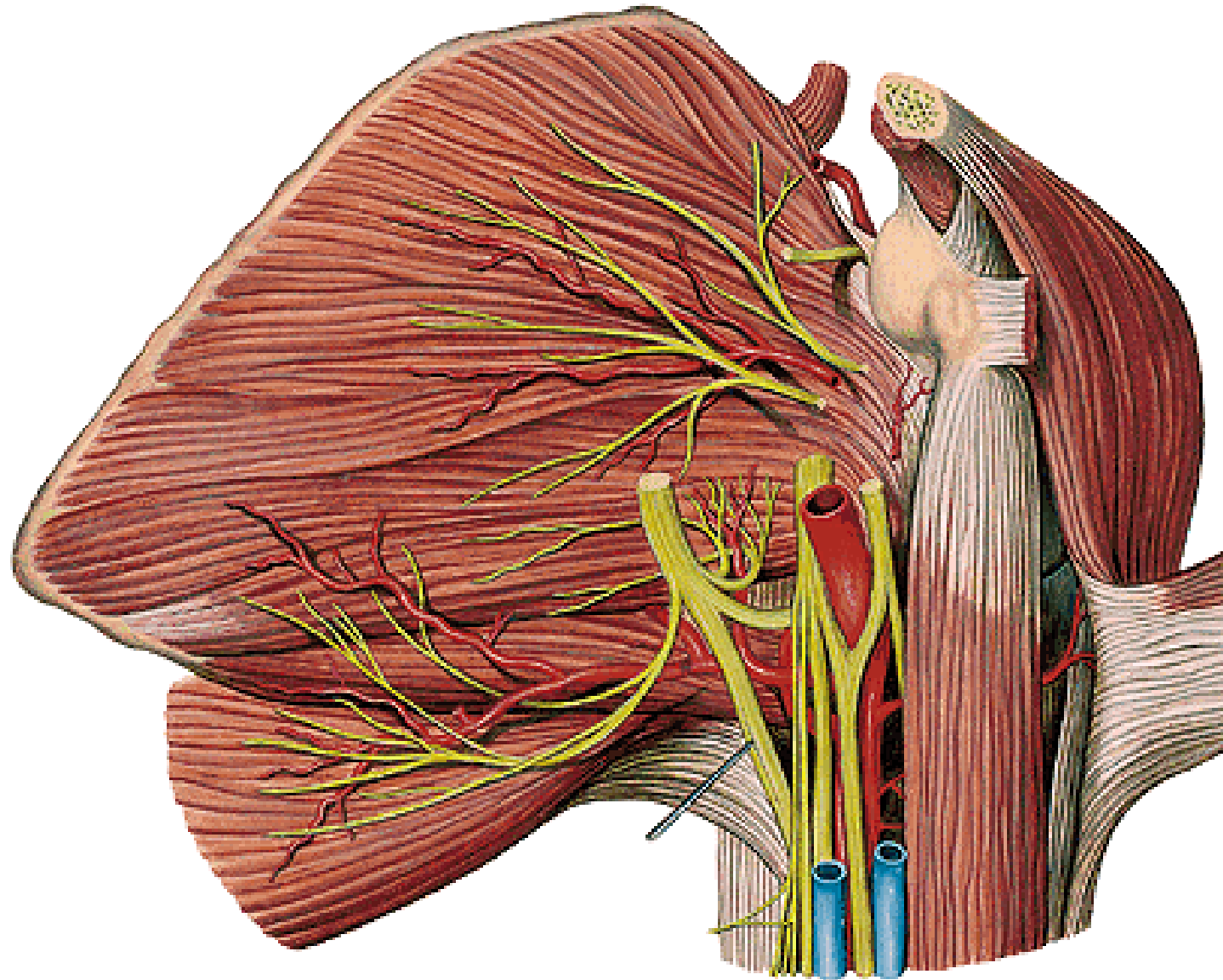
Ulnar (Guyon) canal



1. Ramus prof. n. ulnaris
2. Hiatus distalis (pisohamate canal)
3. Hamulus ossis hamati
4. Carpal tunnel
5. Os pisiforme
6. Lig. pisohamatum
7. N. ulnaris

Ulnar nerve entrapment - Claw hand

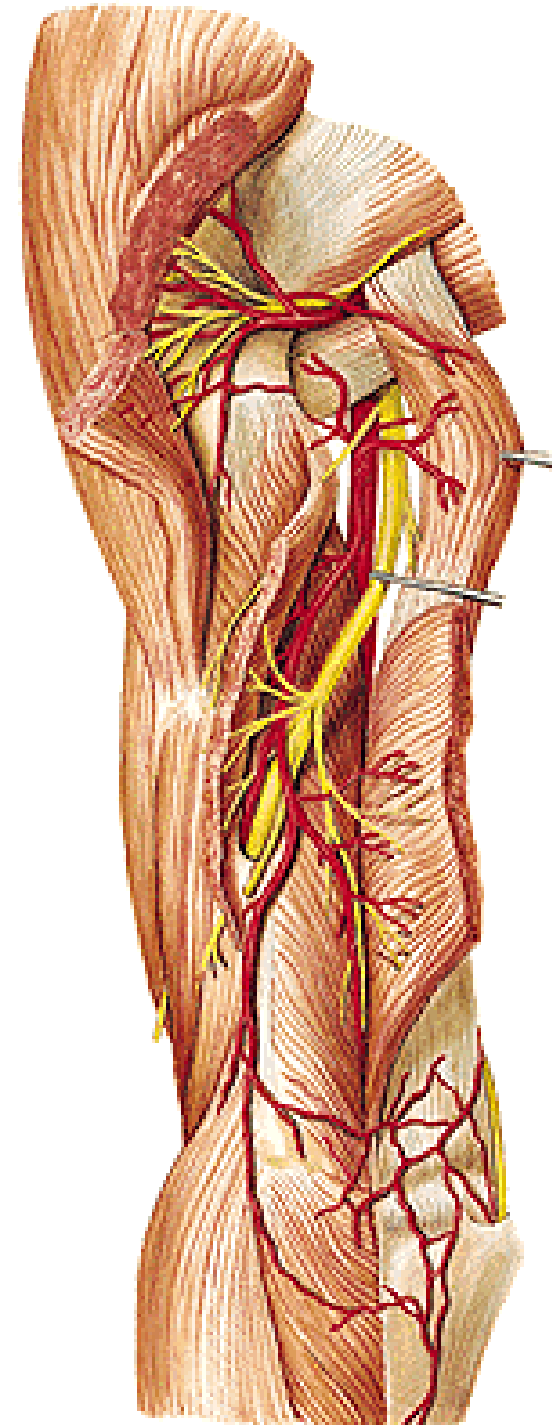
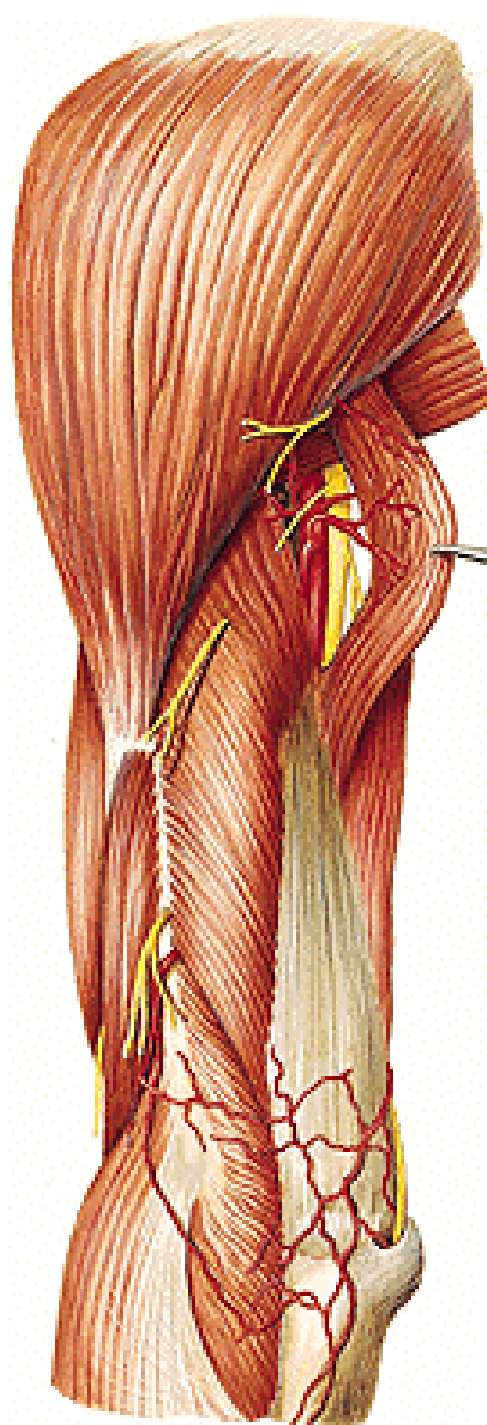
N. radialis (C5 – T1)



N. radialis

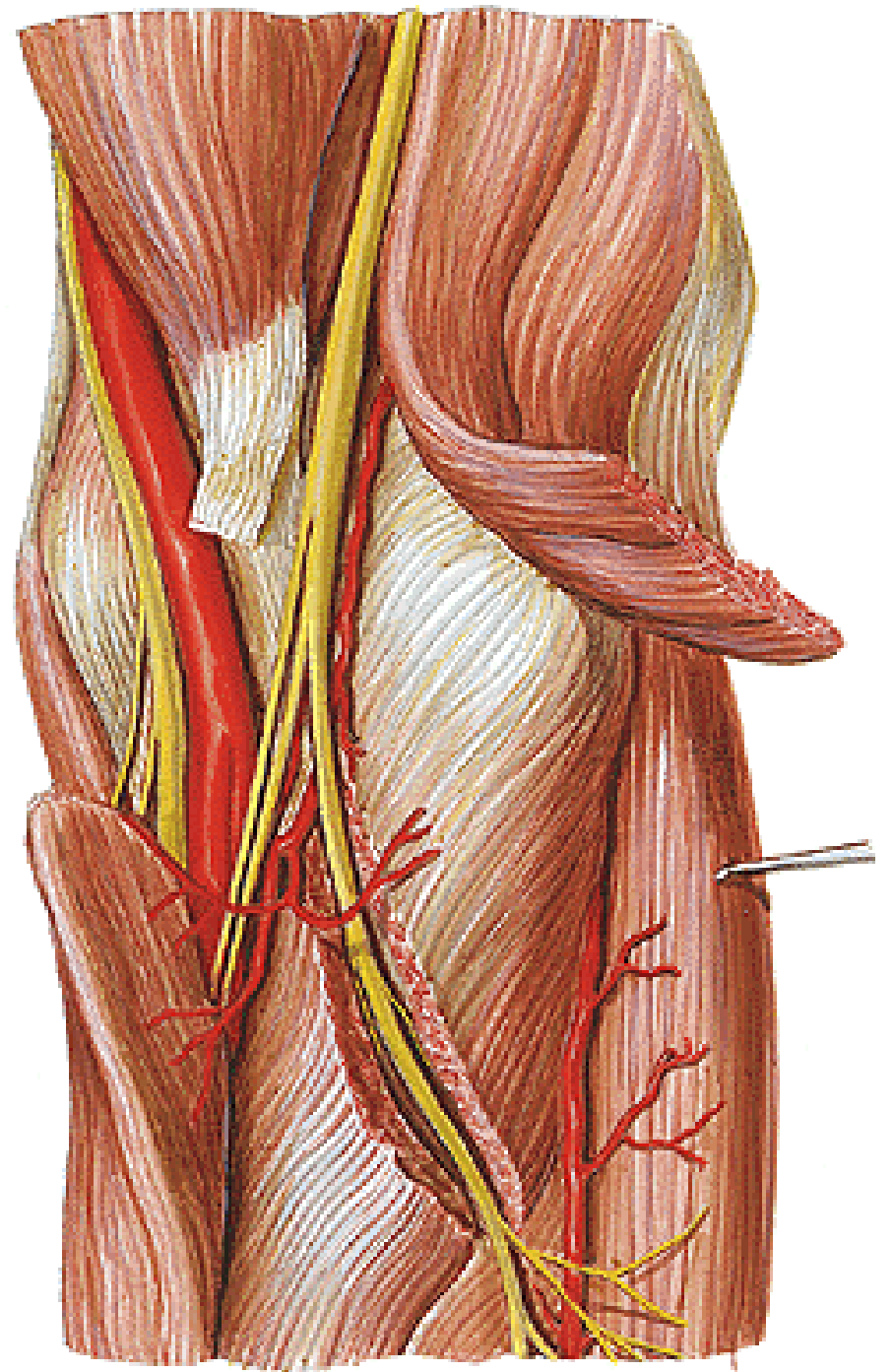
sulcus n. radialis

(a. profunda brachii)



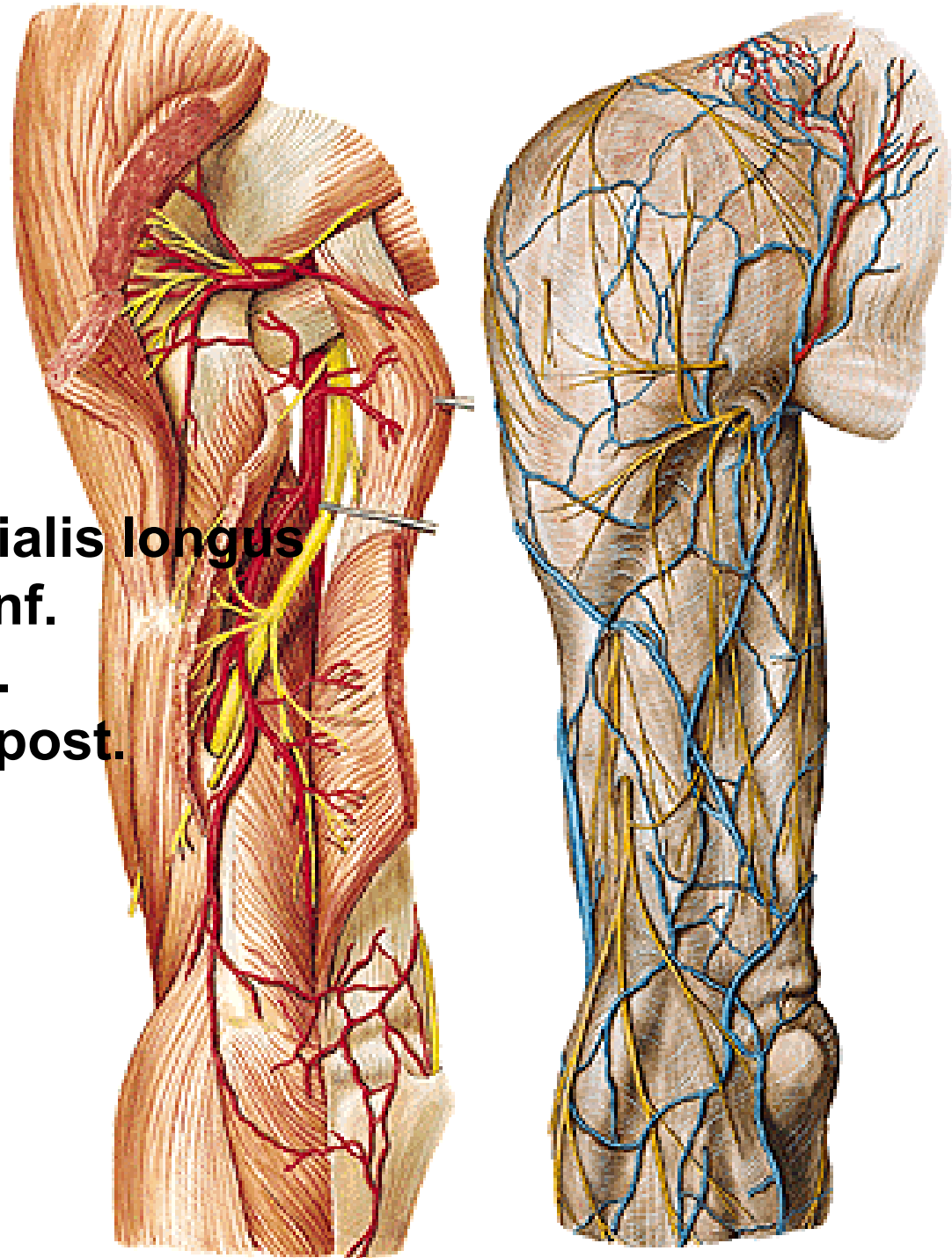
N. radialis

- **r. superficialis**
- **r. profundus**



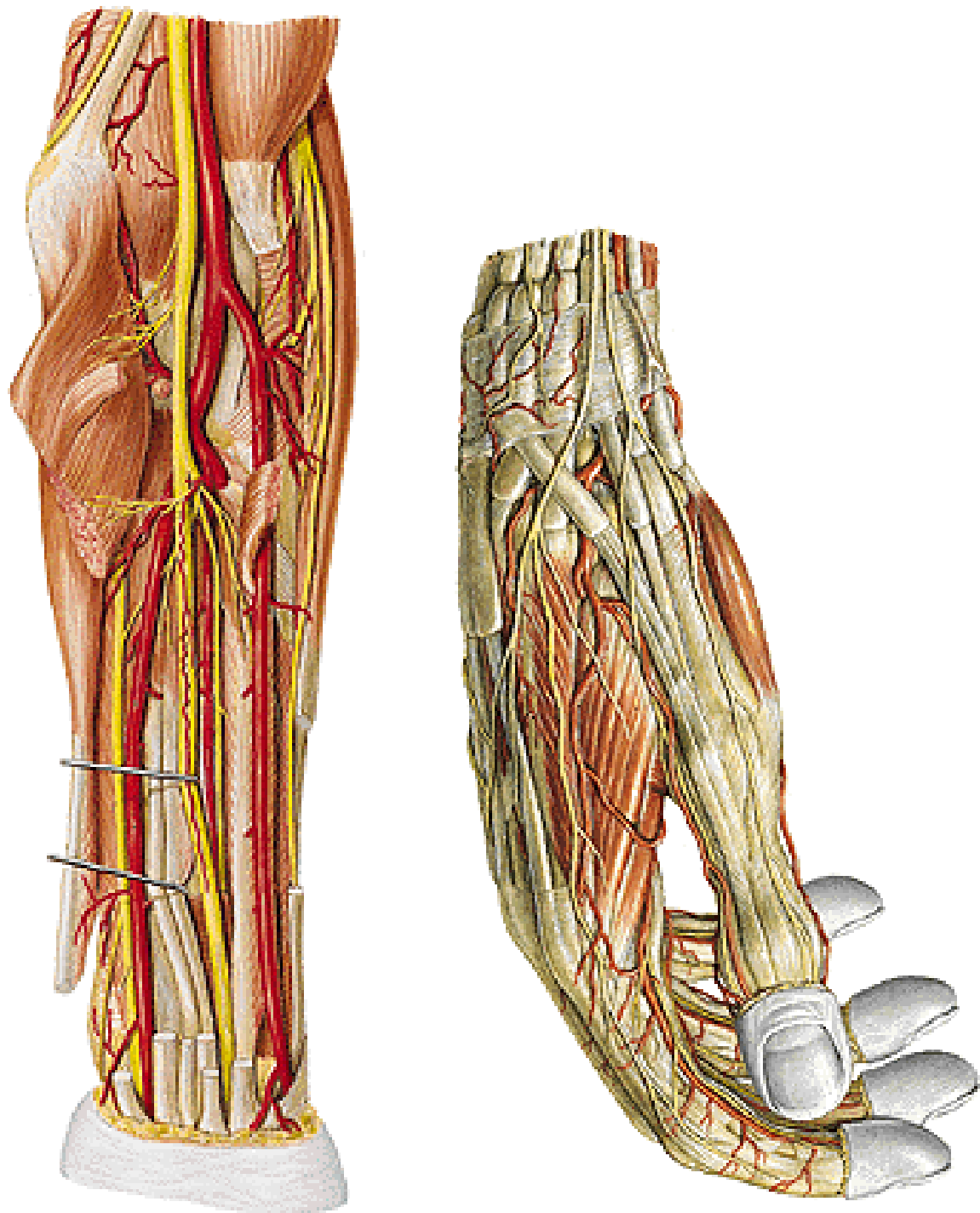
N. radialis

- rr. musculares
 - m. triceps brachii
 - m. anconeus
 - m. brachioradialis
 - m. extensor carpi radialis longus
- n. cutaneus brachii lat. inf.
- n. cutaneus brachii post.
- n. cutaneus antebrachii post.



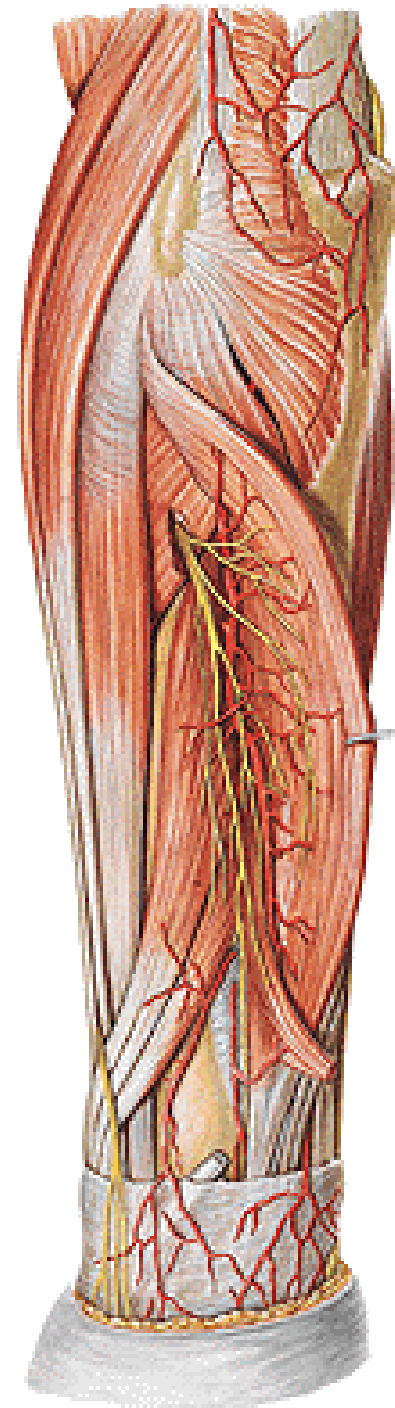
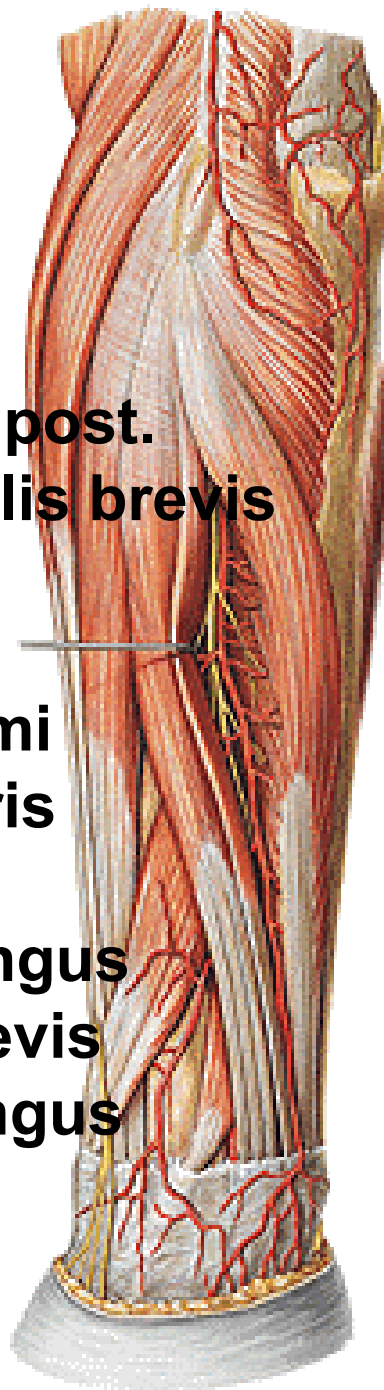
N. RADIALIS

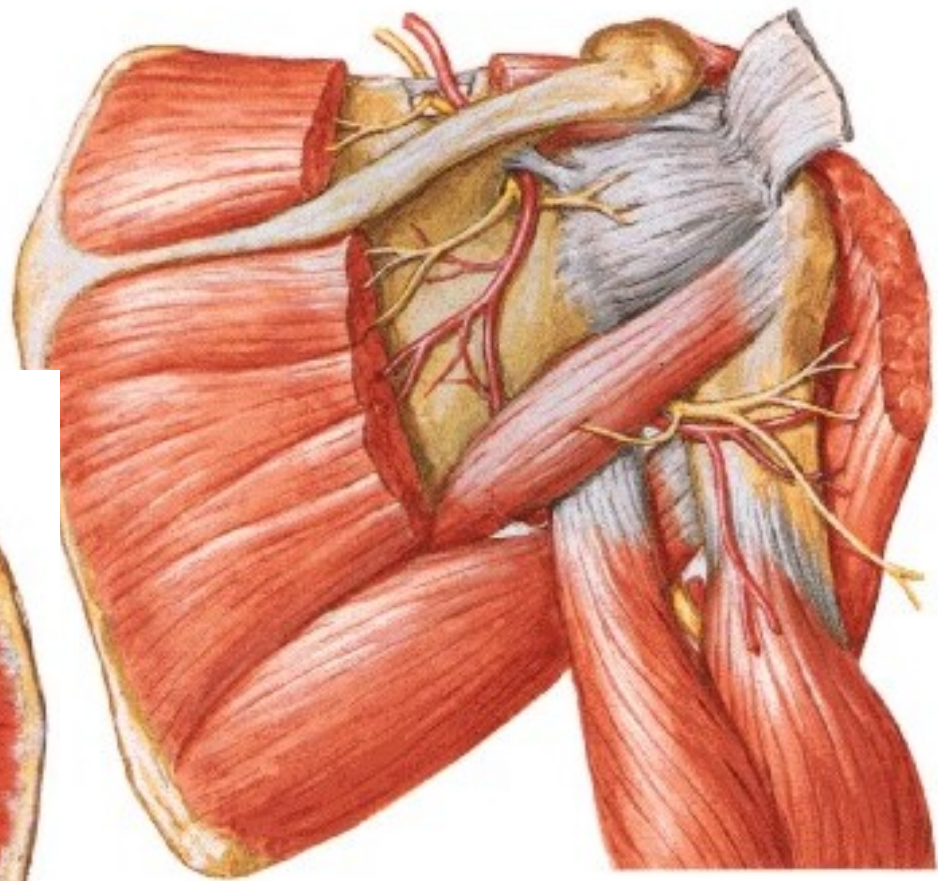
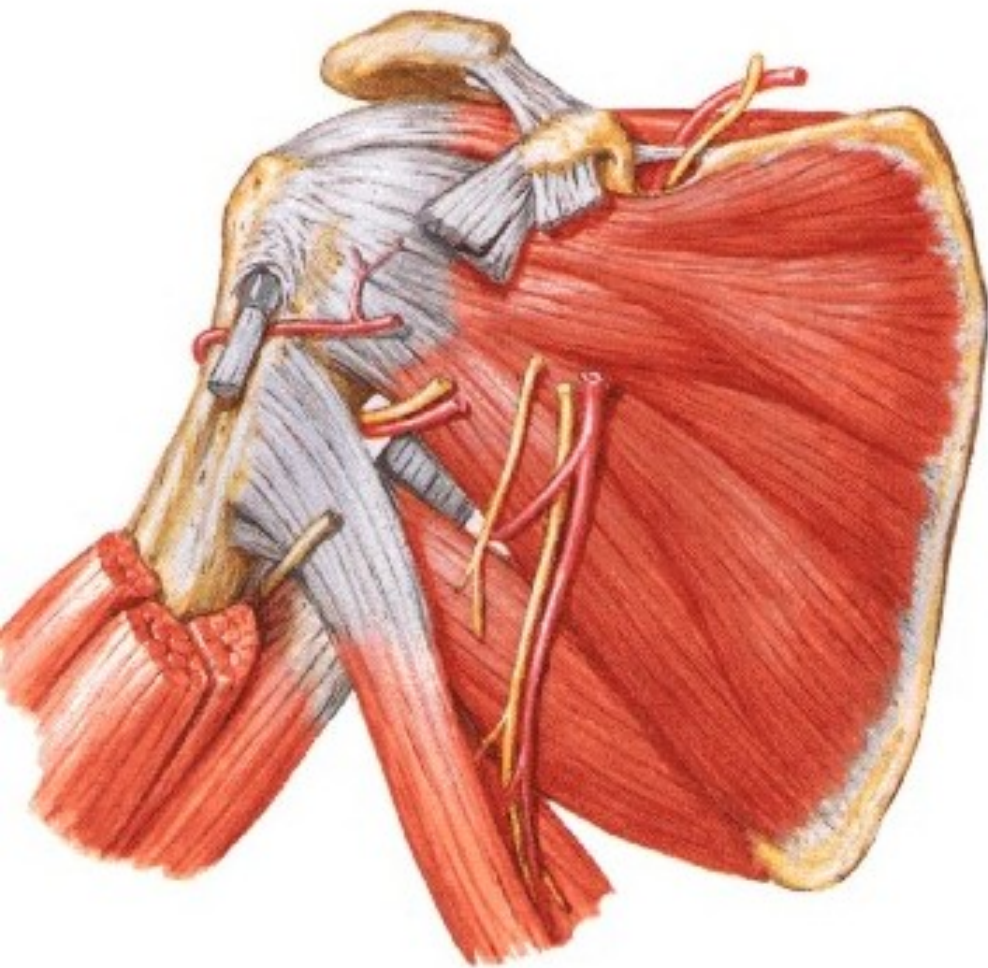
- r. superficialis
- nn. digitales dorsales

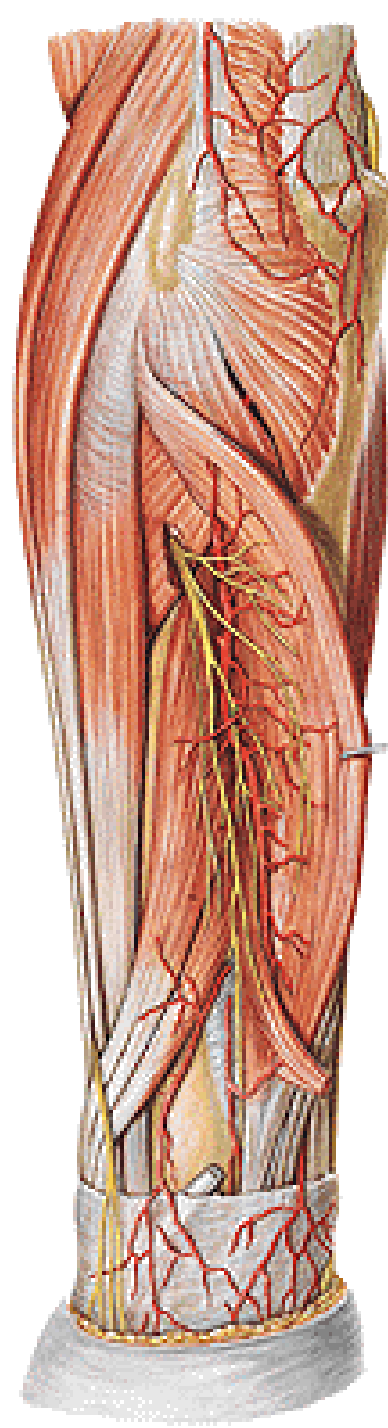
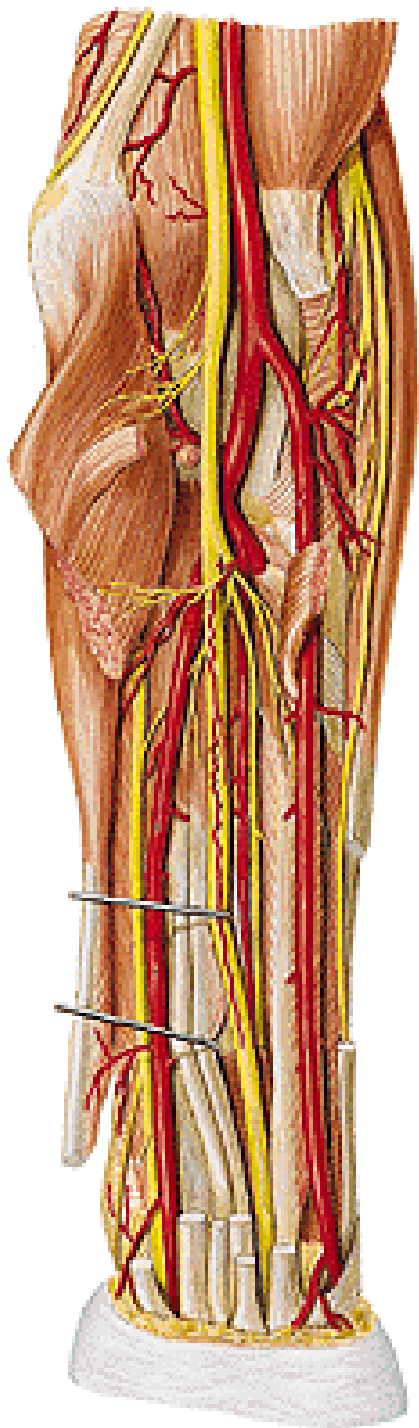


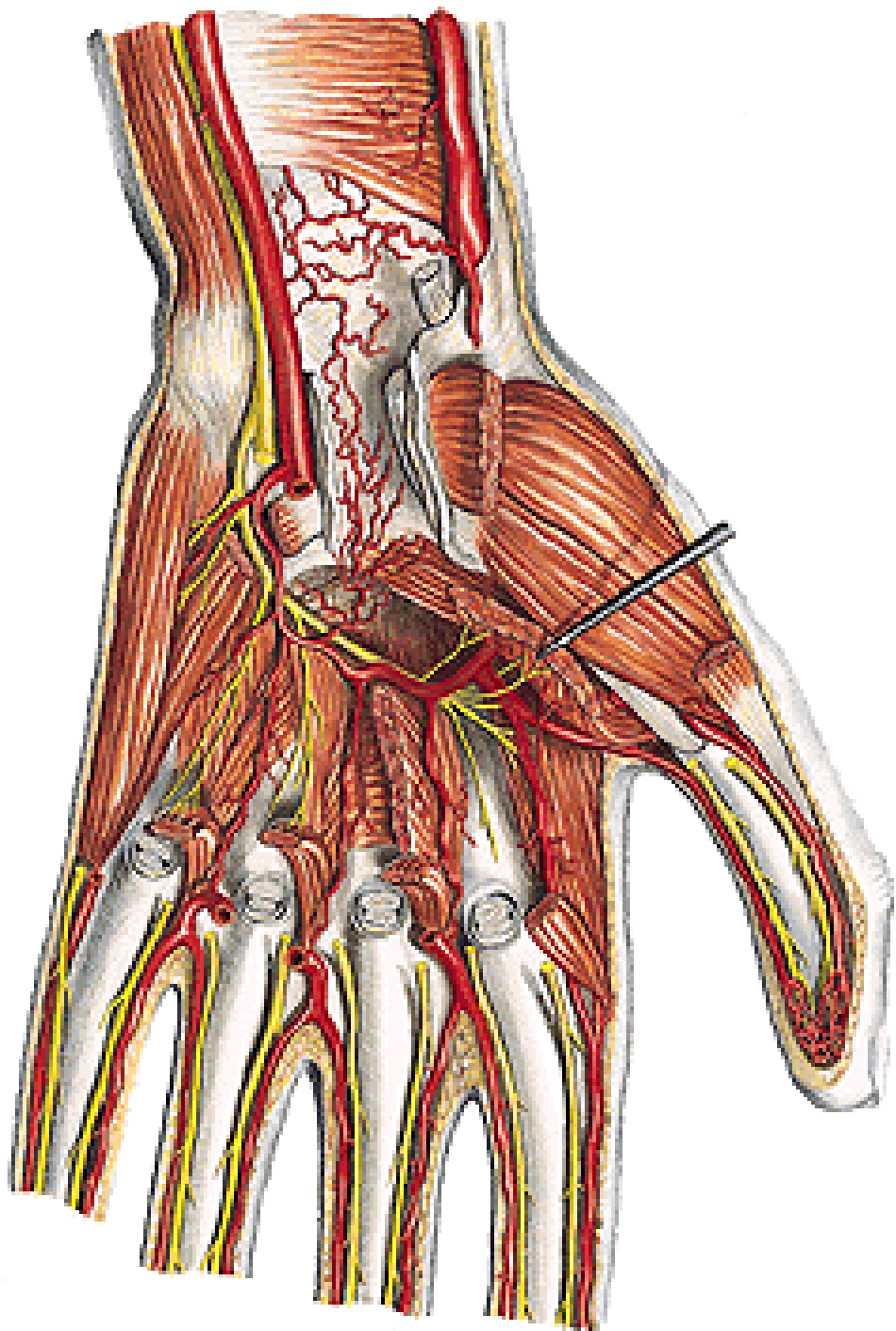
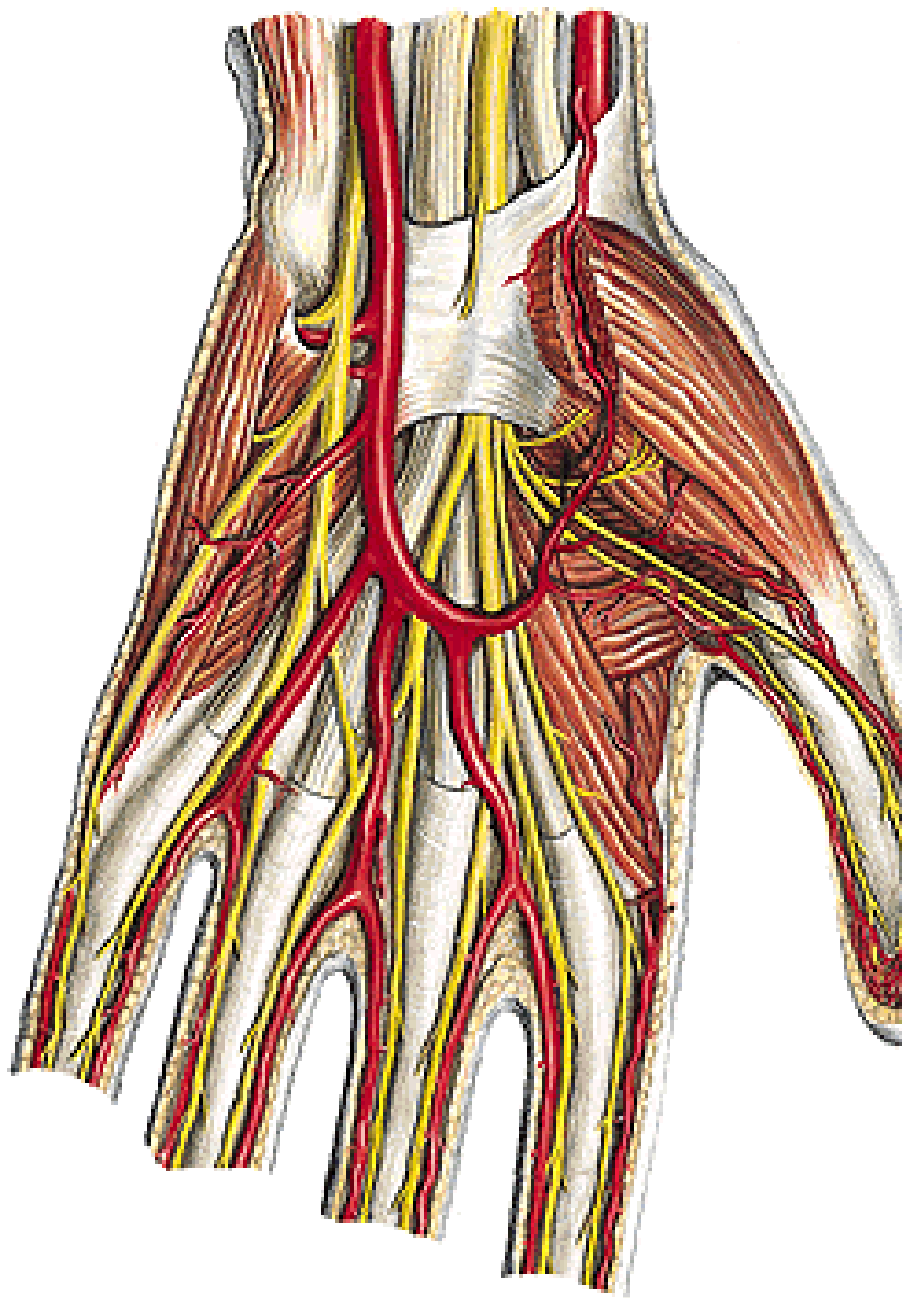
N. RADIALIS

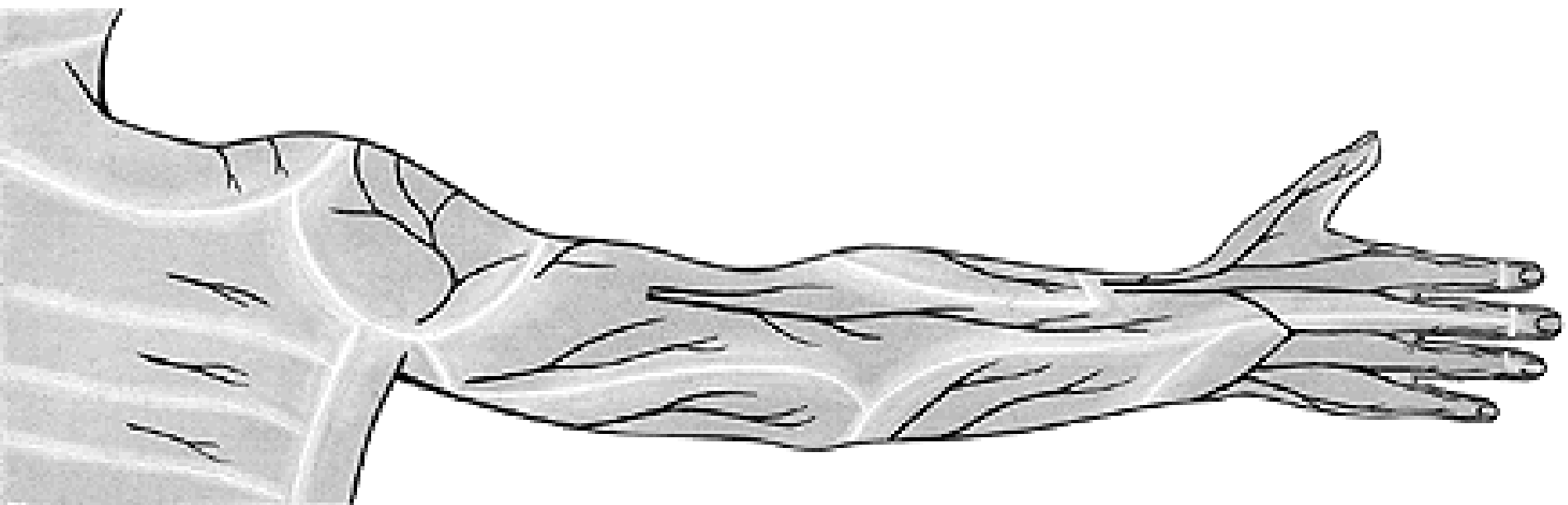
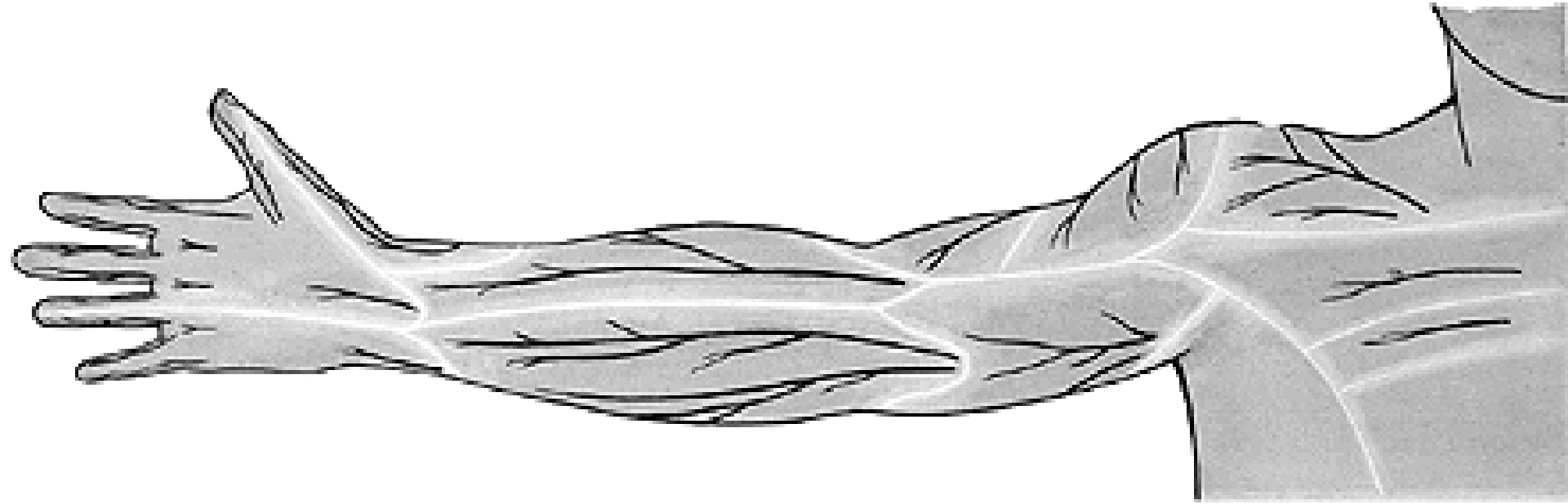
- r. profundus
- rr. musculares
- n. interosseus antebrachii post.
 - m. extensor carpi radialis brevis
 - m. supinator
 - m. extensor digitorum
 - m. extensor digiti minimi
 - m. extensor carpi ulnaris
 - m. extensor indicis
 - m. abductor pollicis longus
 - m. extensor pollicis brevis
 - m. extensor pollicis longus

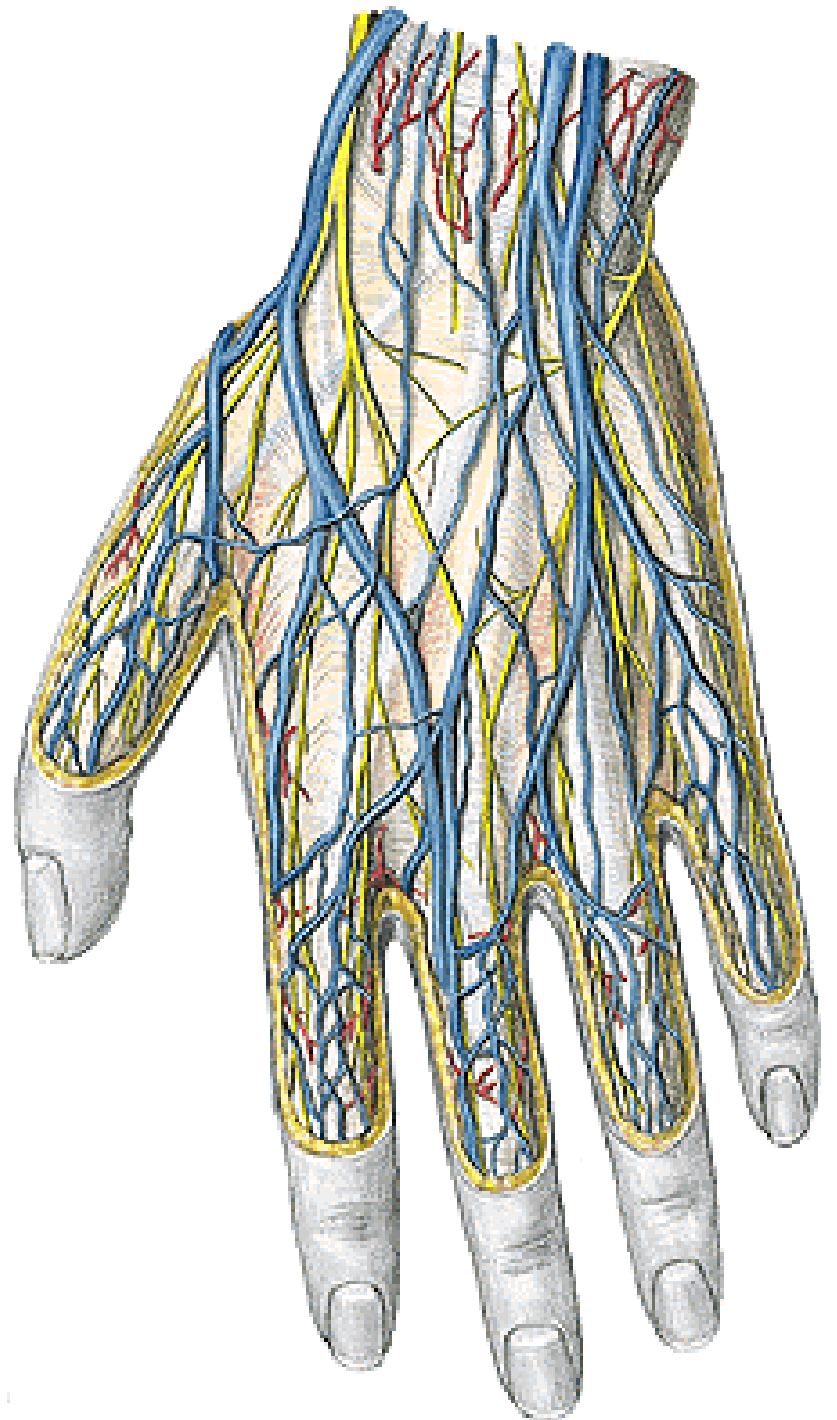
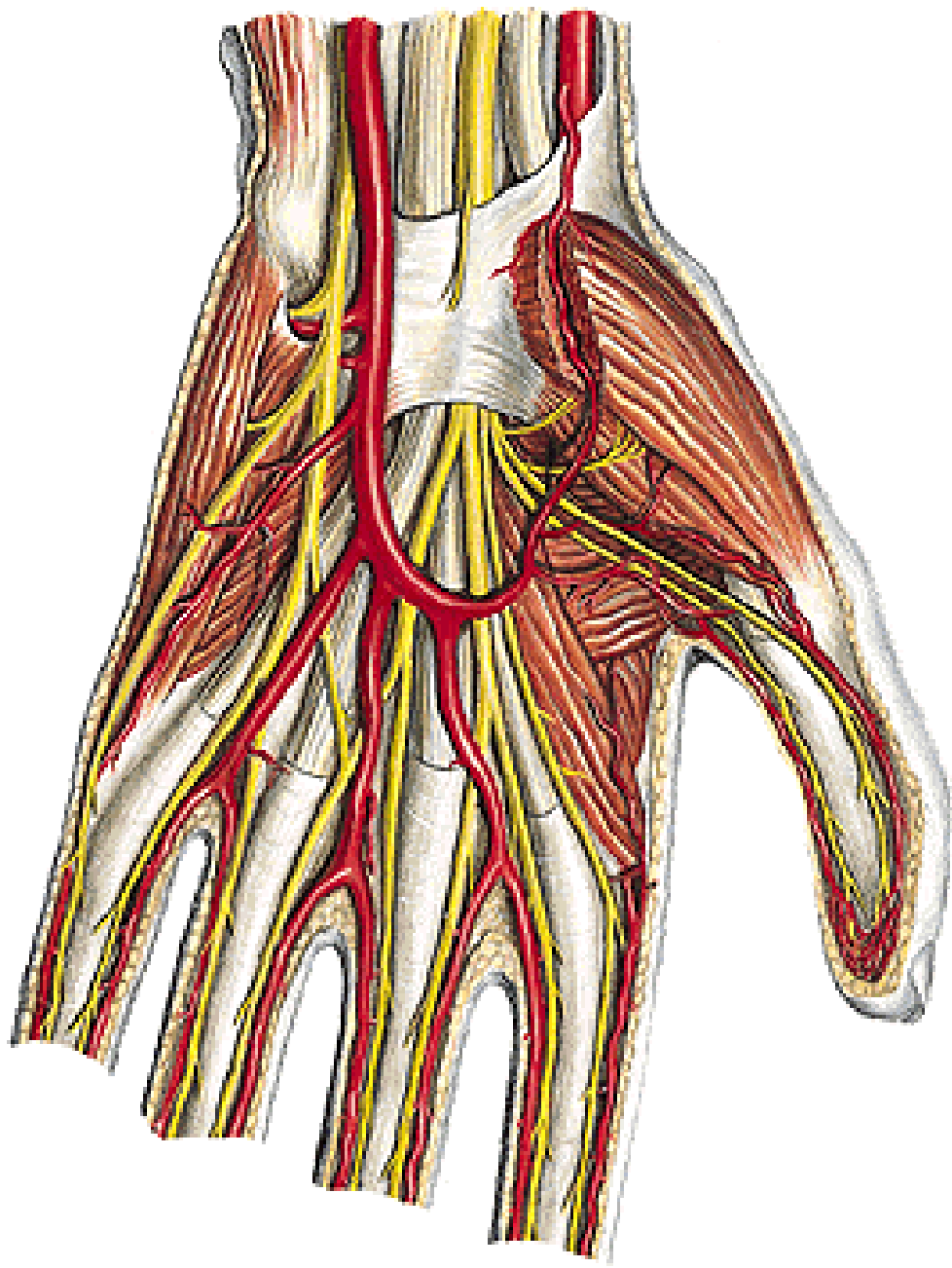












CROSS SECTION THROUGH THE ARM

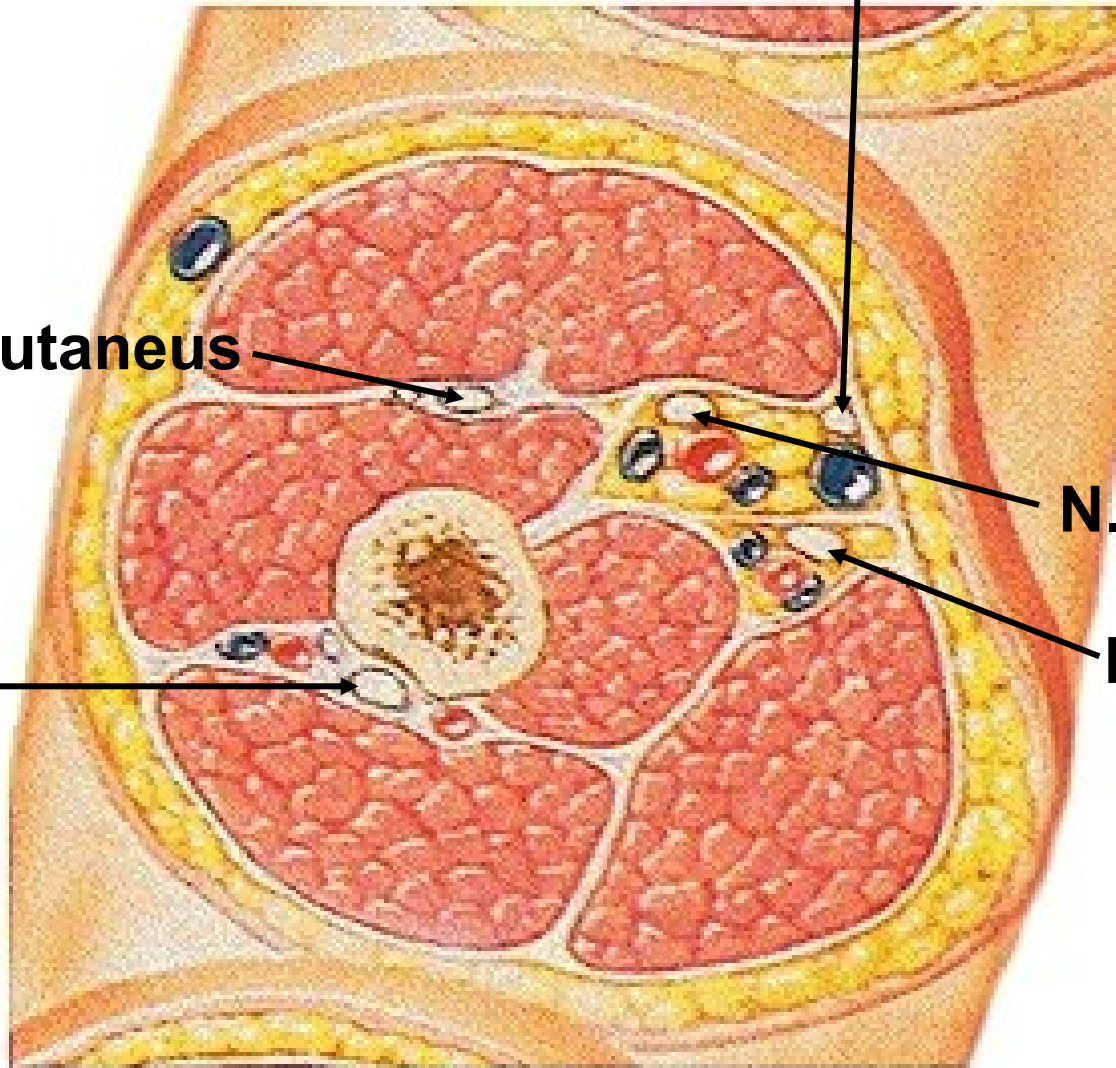
N. cutaneus antebrachii med.

N. musculocutaneus

N. medianus

N. ulnaris

N. radialis

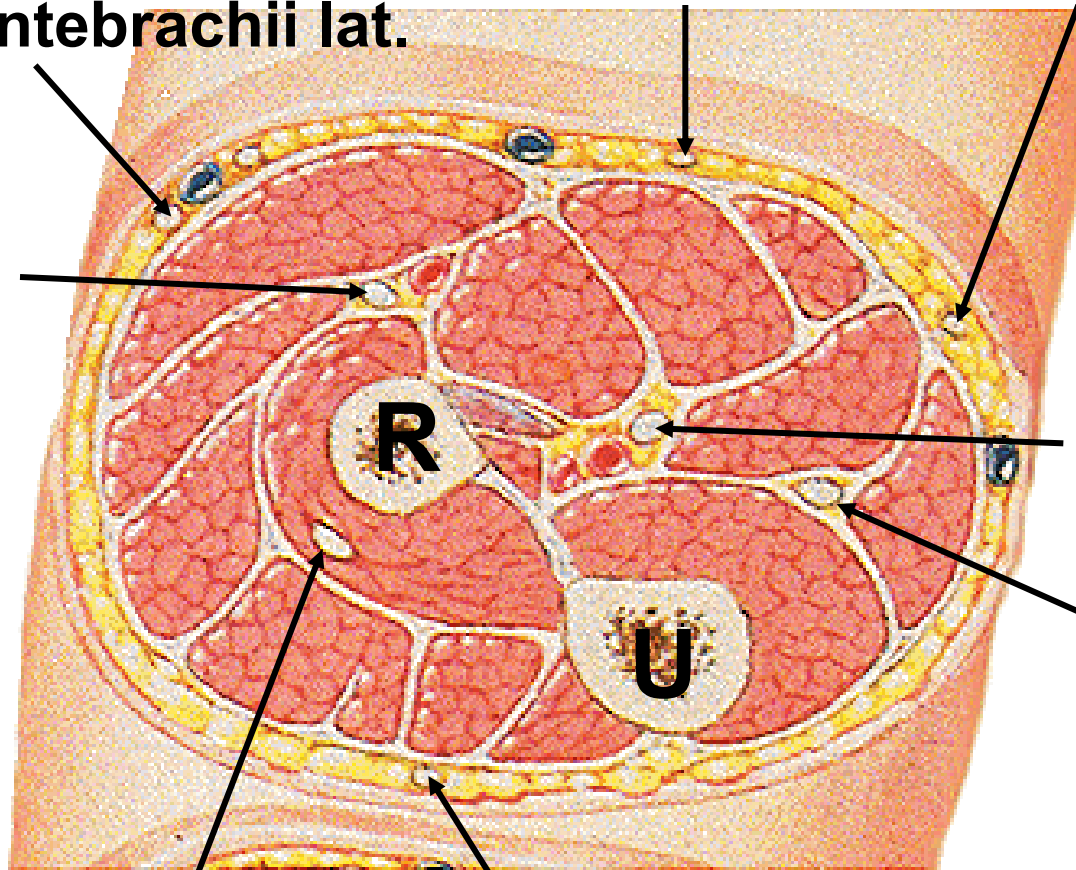


FOREARM – PROXIMAL CROSS SECTION

N. cutaneus antebrachii med.
- r. ant. - r. post.

N. cutaneus antebrachii lat.

N. radialis
- r. spf.



N. medianus

N. ulnaris

N. cutaneus antebrachii post.

N. radialis – r. prof.

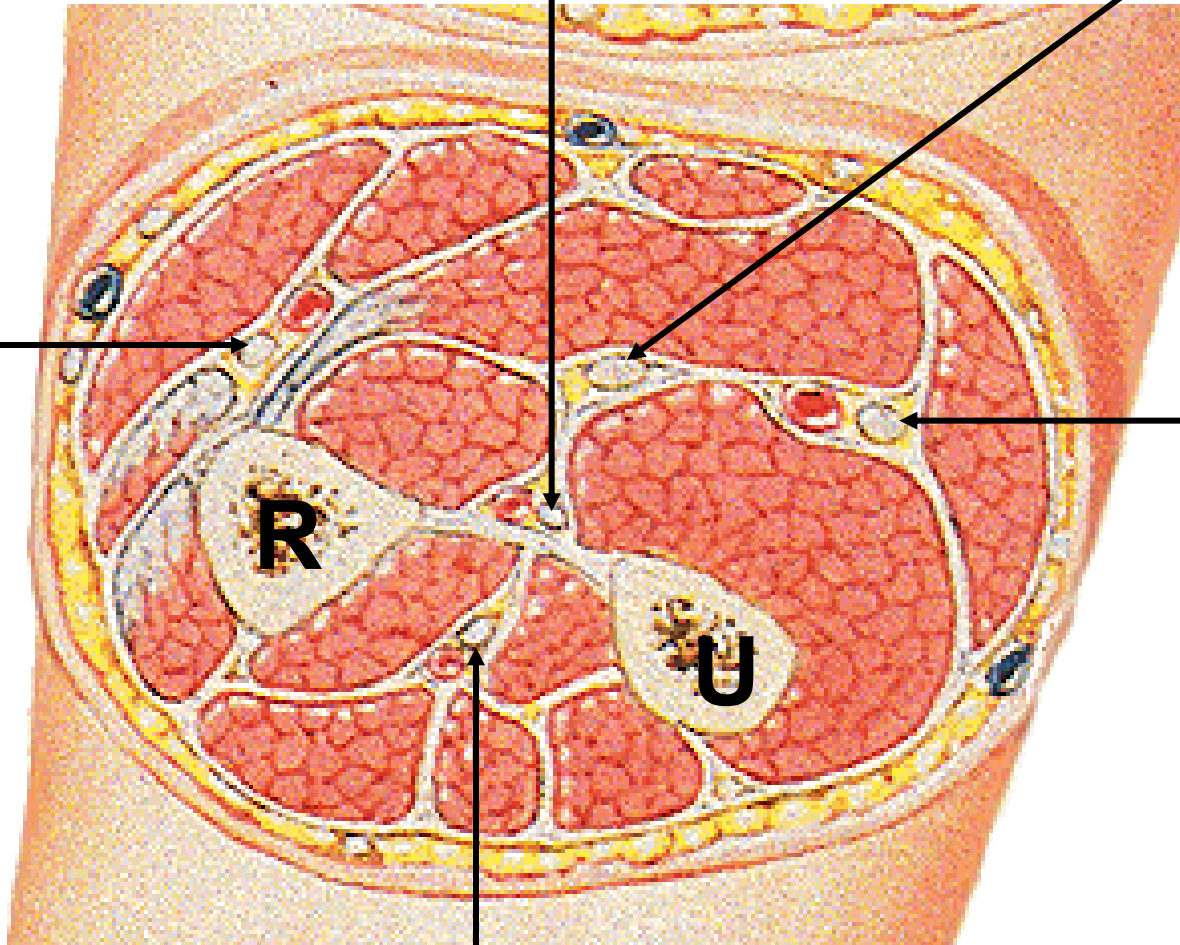
FOREARM – MIDDLE CROSS SECTION

N. interosseus anterior

N. medianus

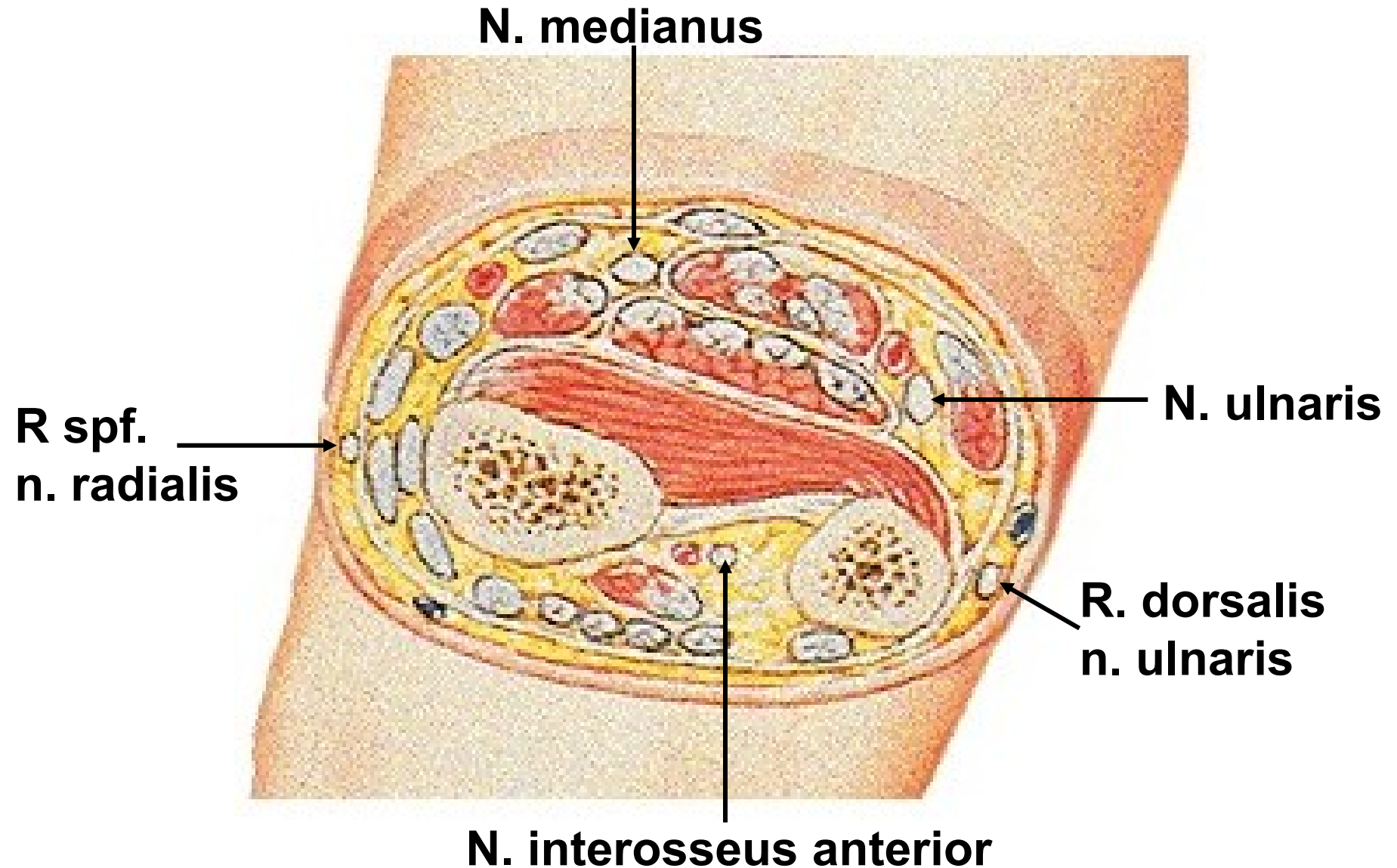
**R. spf.
n. radialis**

N. ulnaris



N. interosseus posterior

FOREARM – DISTAL CROSS SECTION



Illustrations and photographs were copied from:
Atlas der Anatomie des Menschen/Sobotta.
Putz,R., und Pabst,R. 20. Auflage. München:
Urban & Schwarzenberg, 1993
Netter: Interactive Atlas of Human Anatomy.
Windows Version 2.0