


Epiphyseal disorders

Z. Rozkydal

Epiphyseal disorders

Idiopathic avascular
necrosis of epiphysis
of long bones

Etiology unknown



Epiphysis

Metaphysis

Diaphysis

Metaphysis

Epiphysis

Obr. 1

Perthes disease

It is a complication of the necrosis of proximal epiphysis of the femur

4 -12 years

10 % bilateral

More often in boys

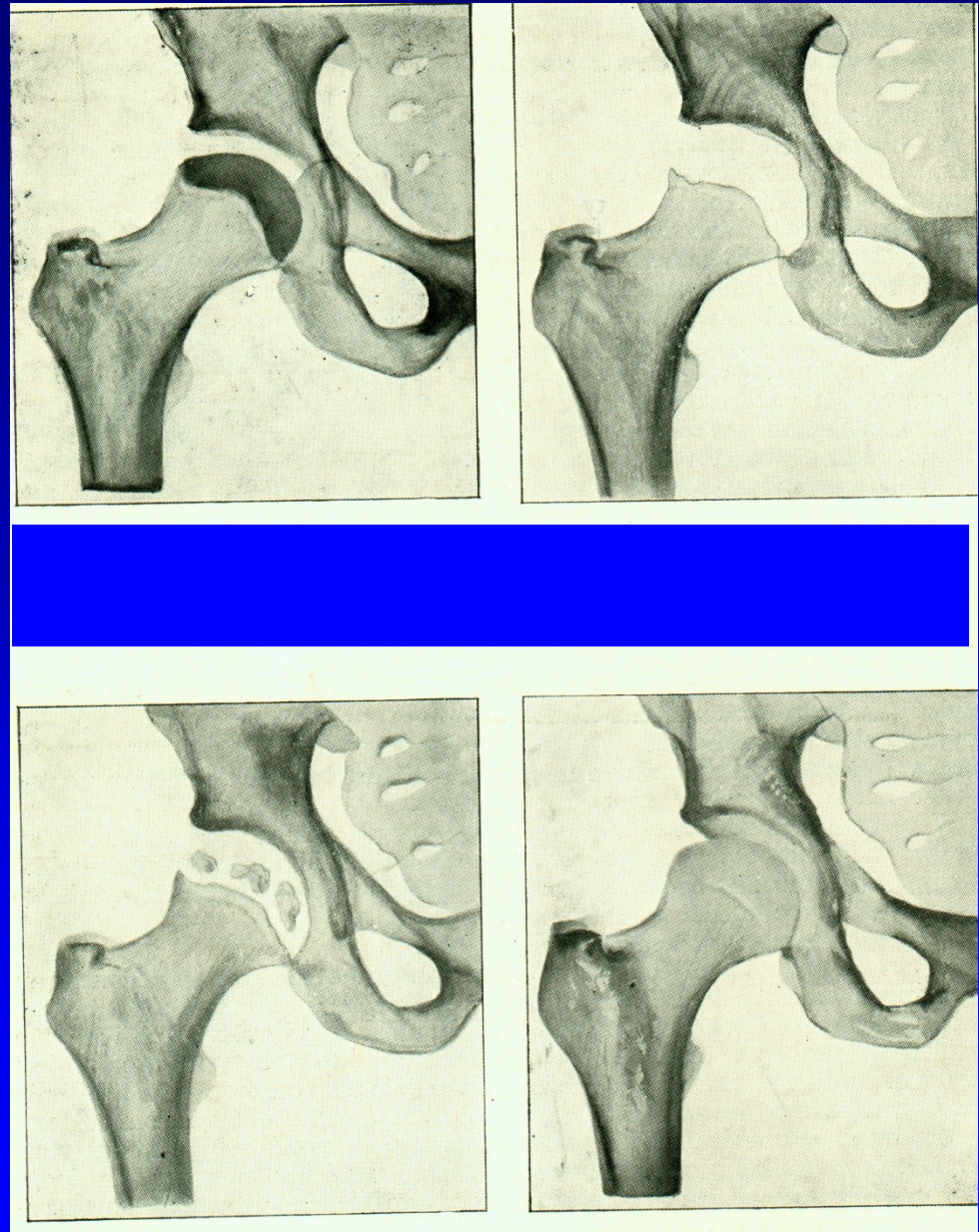
Symptoms: limping, pain
limited ROM (rotation, abduction)



Obr. 2

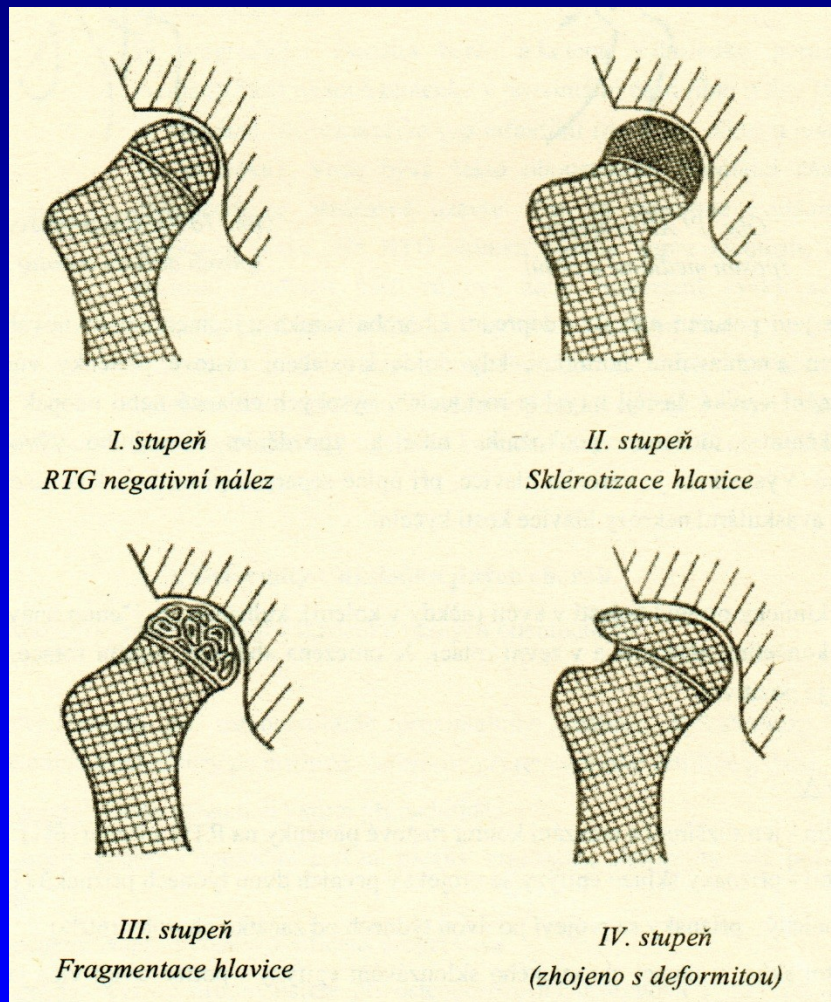
Frejka classification

1. st. latency 6 - 18 months
2. st. necrosis
3. st. decalcination
4. st. recovery
5. st. consequences

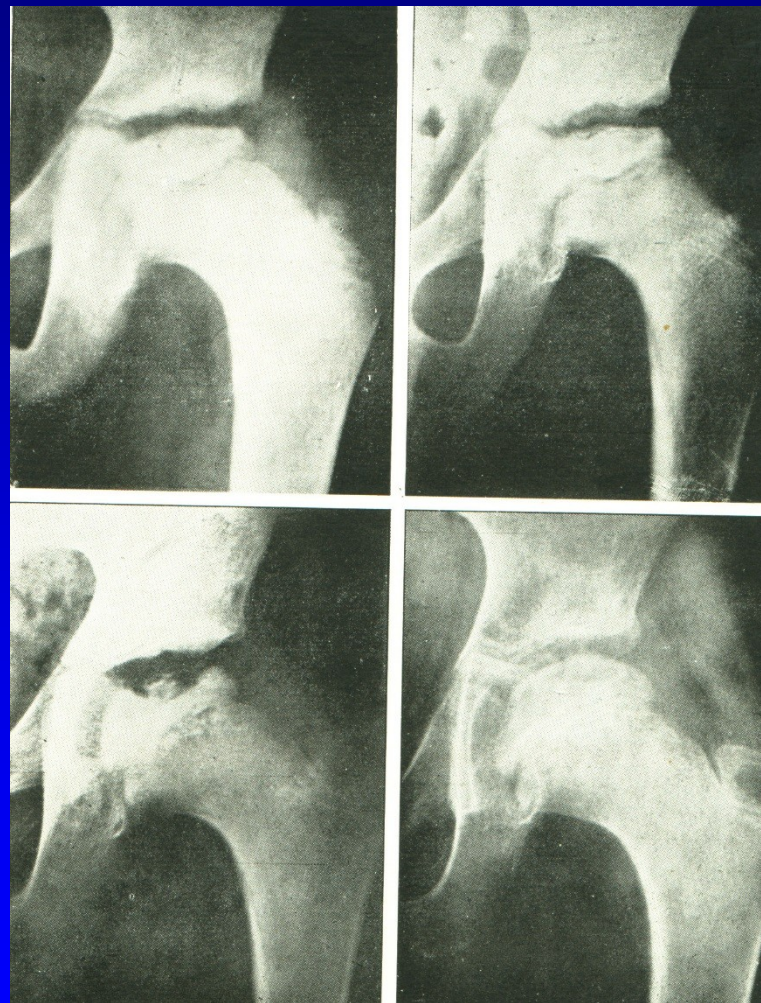


Obr. 3

Perthes disease- stages



Obr. 4



Obr. 5

Perthes disease

Ischemia of the whole epiphysis

Articular cartilage continues to grow

Bone is resorbed and replaced by woven bone

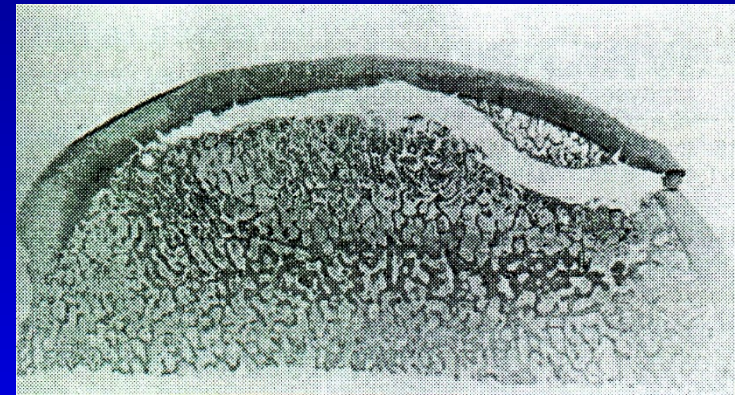
The bone is soft and vulnerable

Subchondral fracture

- shows the extent of damage

New bone is gradually revascularised

New bone is plastic-
can be deformed



Obr. 6

Subchondral fracture
of femoral epiphysis

M. Perthes

1. Ischemic stage: avascular necrosis
growth arrest of epiphysis
revascularisation from periphery
ossification
2. Ischemic stage: trauma, subchondral fracture
resorption under the fracture
replacement by plastic woven bone
subluxation, deformity

Catterall classification

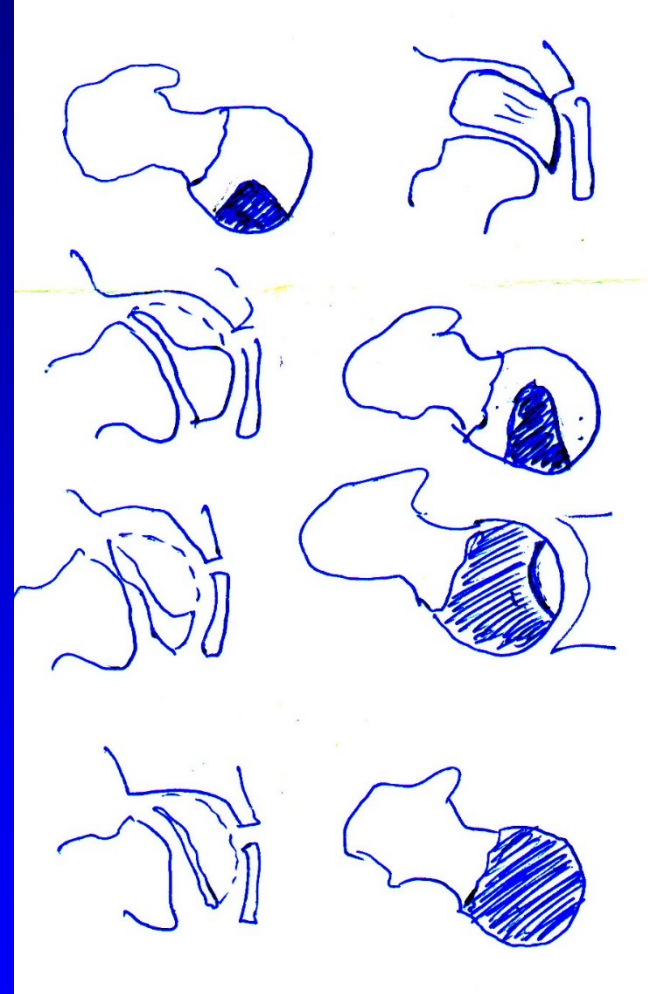
I. 25 %

II. 50 %

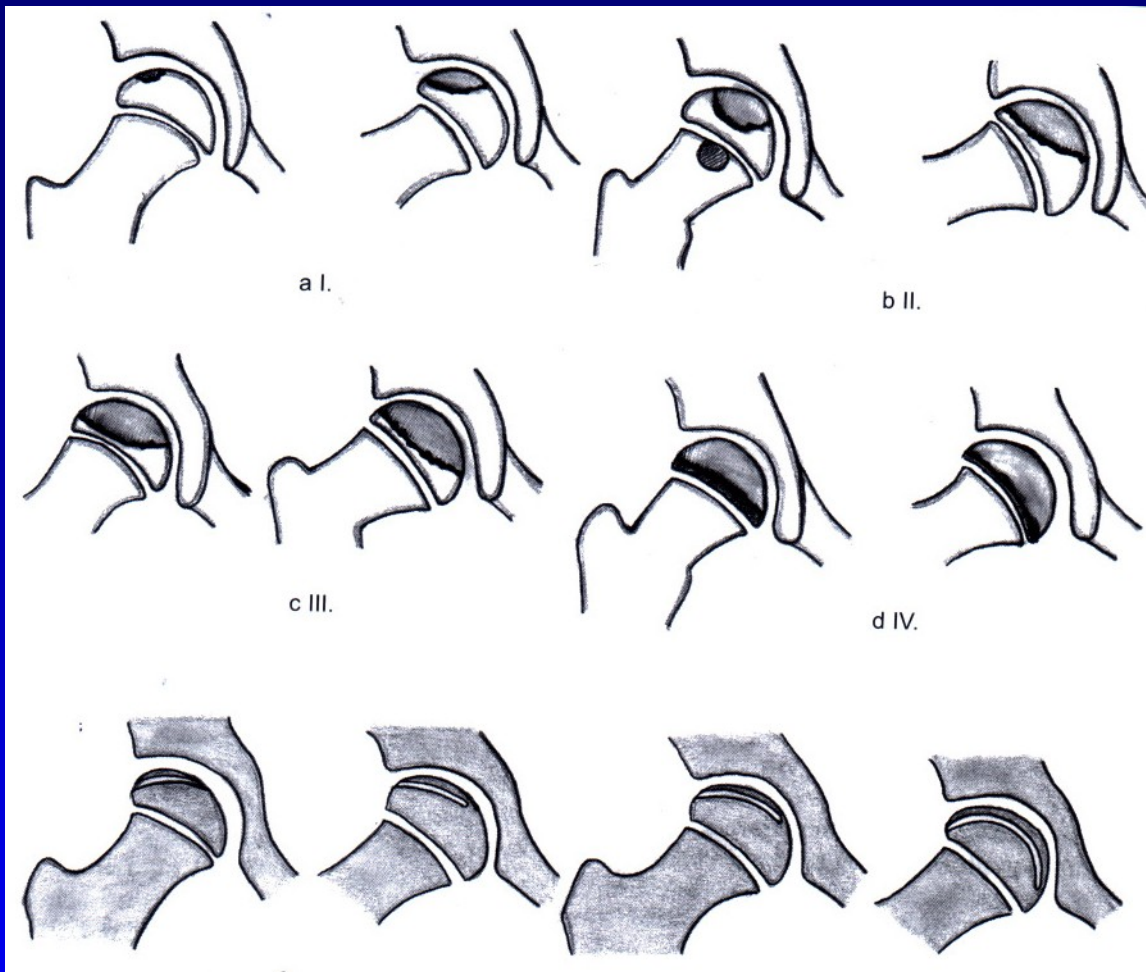
med.- lateral column

III. 75 %

IV. 100 %

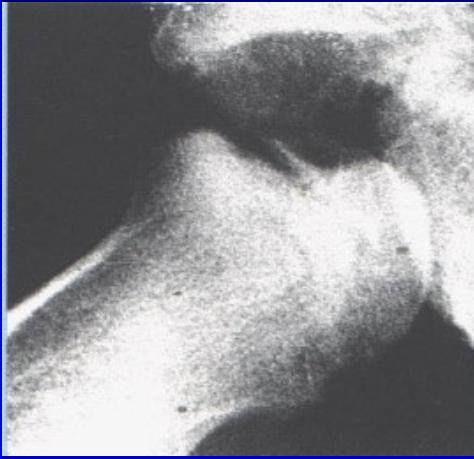
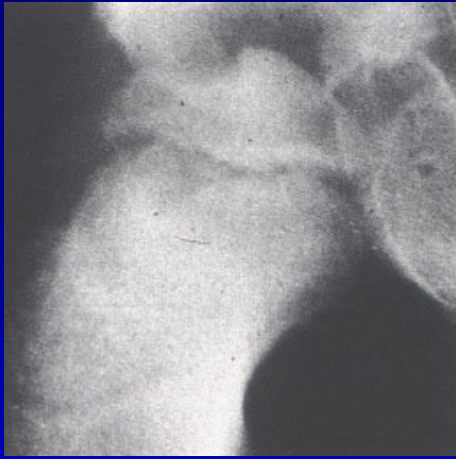

Obr. 7



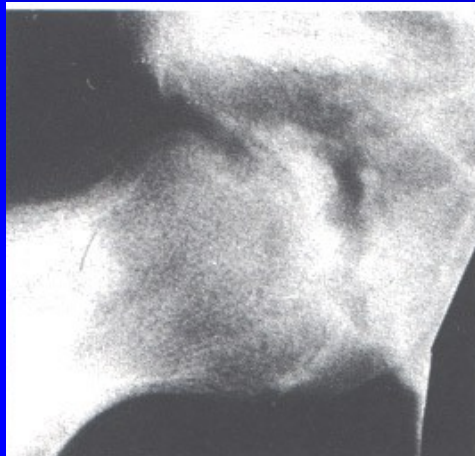
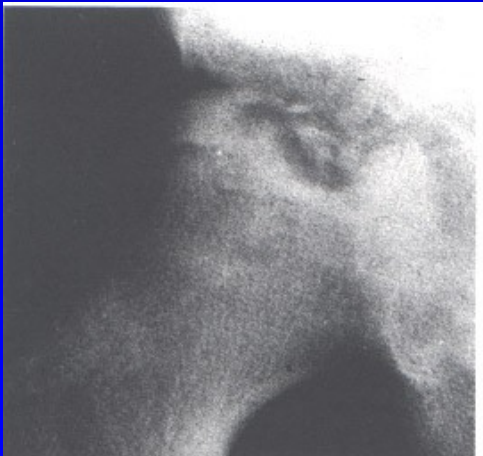Subchondral fx
less than one half

Subchondral fx
more than one half



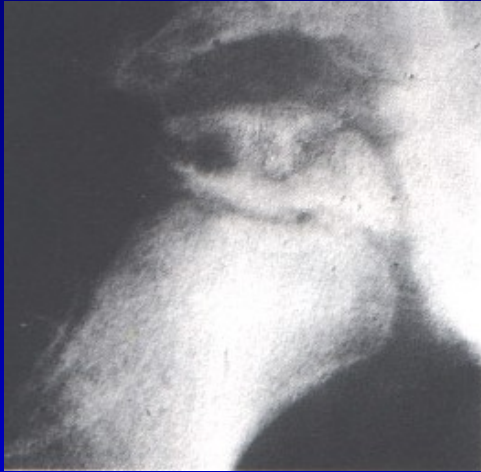Obr. 8

Catterall I

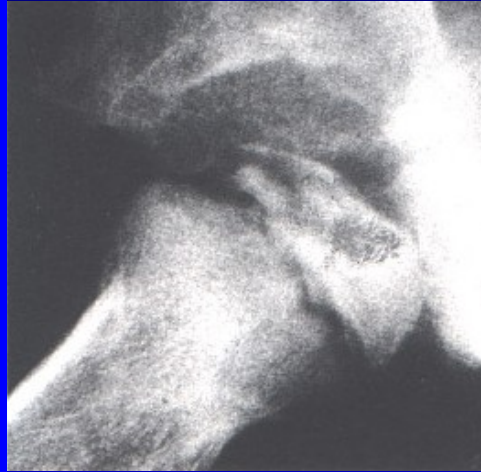

Obr. 9

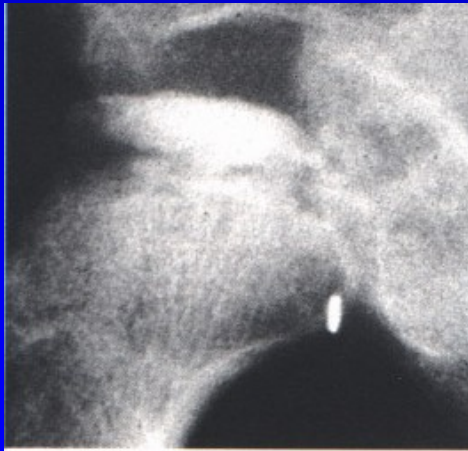
Catterall II



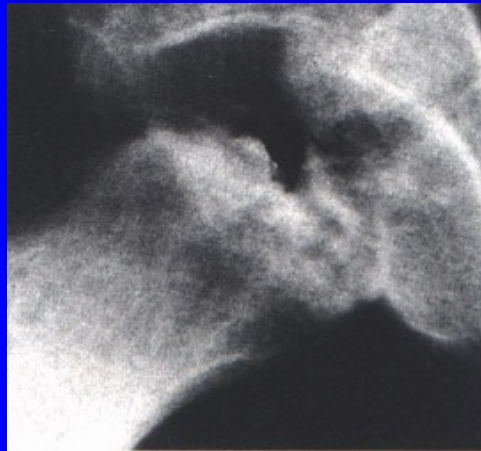
Obr. 10



Catterall III



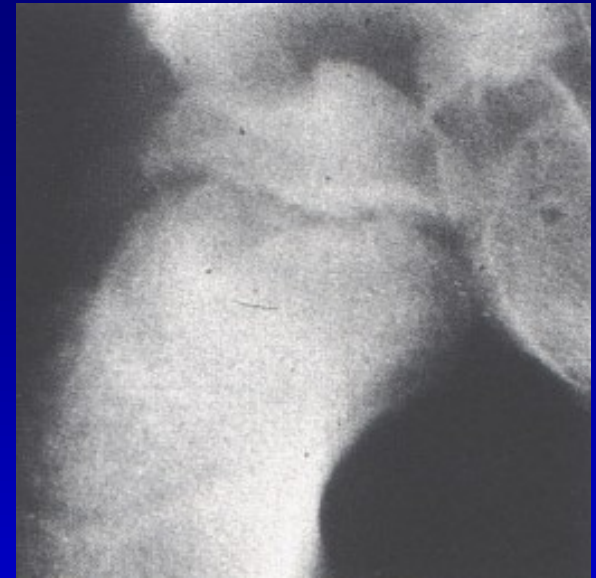
Obr. 11



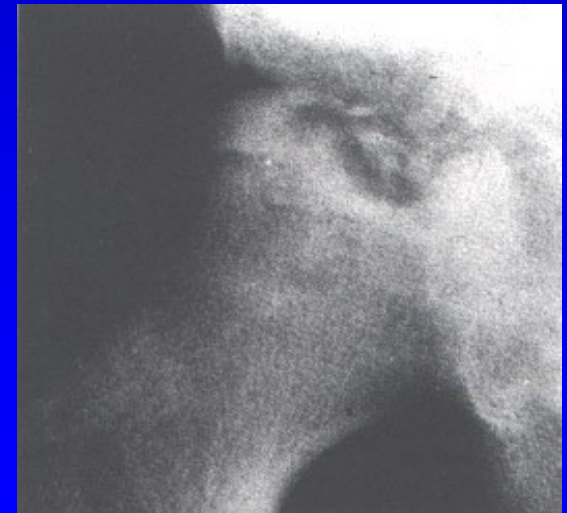
Catterall IV

Salter classification

- A Catterall I. a II.
less than one half of the epiphysis
short subchondral fracture
lateral column intact
conservative treatment



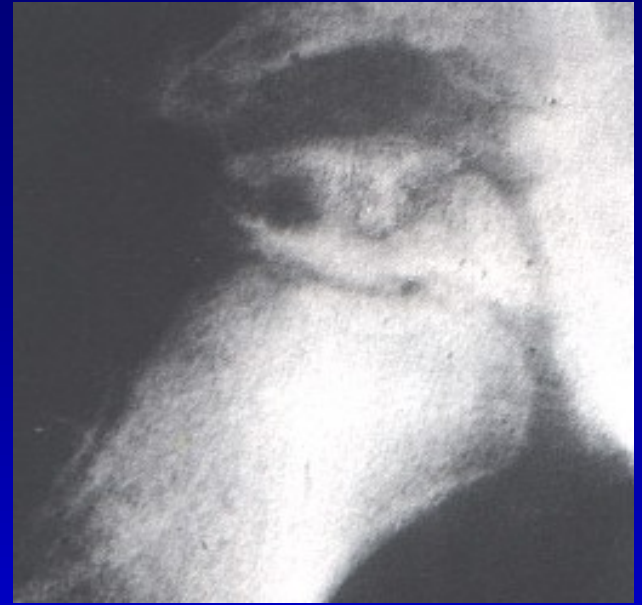Obr. 12



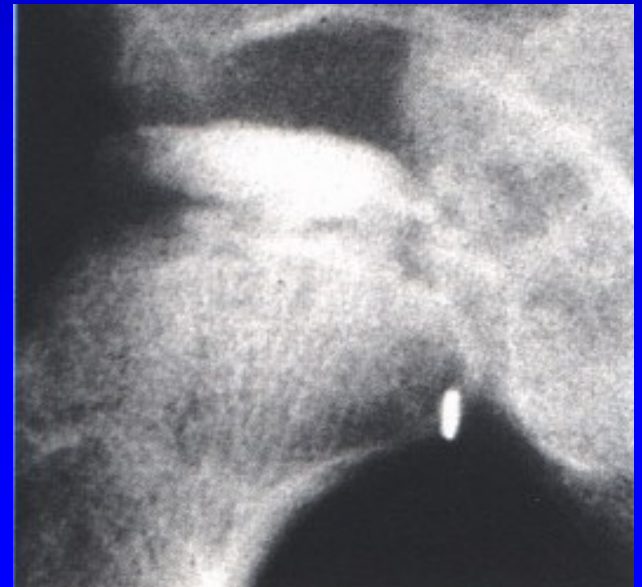
Obr. 13

Salter classification

B Cateral III. a IV.
more then one half of the epiphysis
long subchondral fracture
lateral column is absent
operative treatment



Obr. 14



Obr. 15

Examination

X-ray

Arthrography

CT - 3 D reconstruction

MRI

Scintigraphy

Ultrasonography

Prognosis

I. a II. stage	good prognosis
III. a IV. stage	wrong prognosis

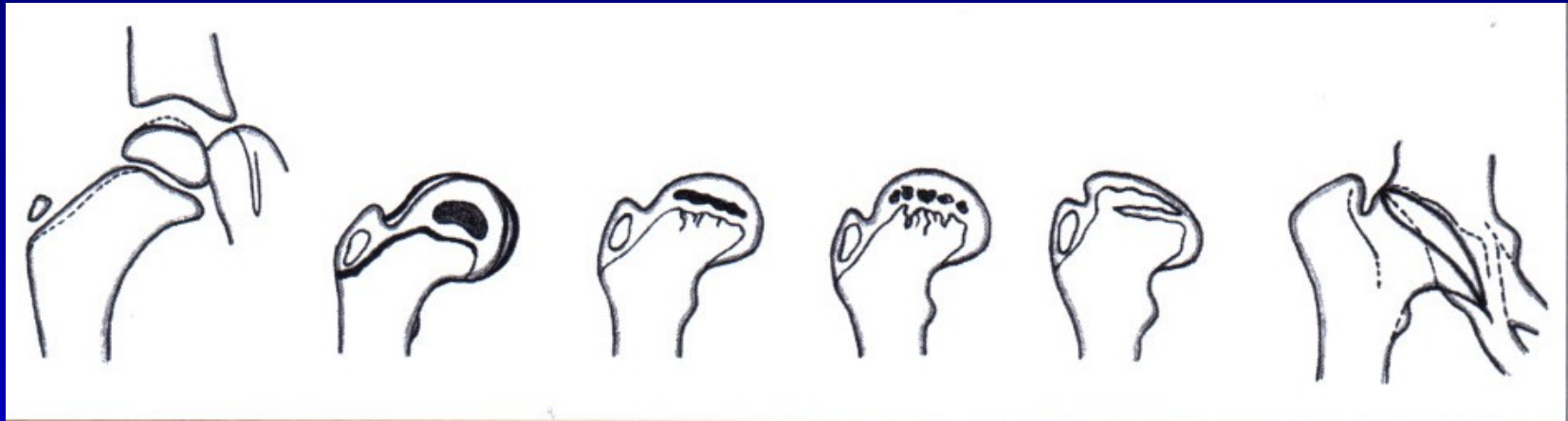
Risk factors:

Older age

Loss of containment, subluxation

Large extent

Limited movements



Types of deformity in Perthes disease

Management

- containment of the head in the acetabulum
- good range of motion

Conservative methods

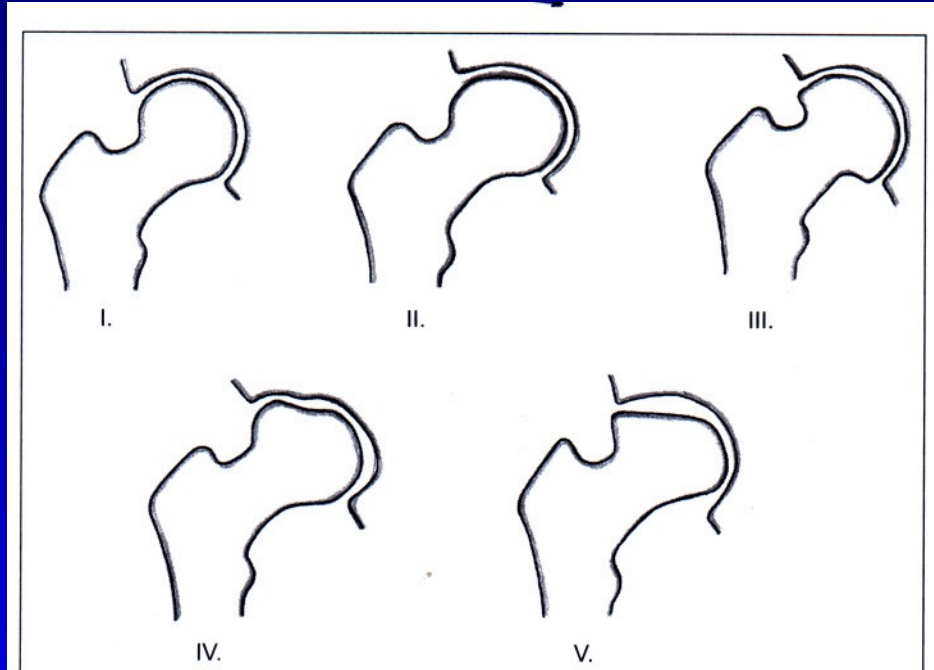
- Atlanta orthosis

Operative methods

Osteotomy of the pelvis (Salter, Steel, Sutherland, Dungal)

Shelf plasty

Osteotomy of the femur



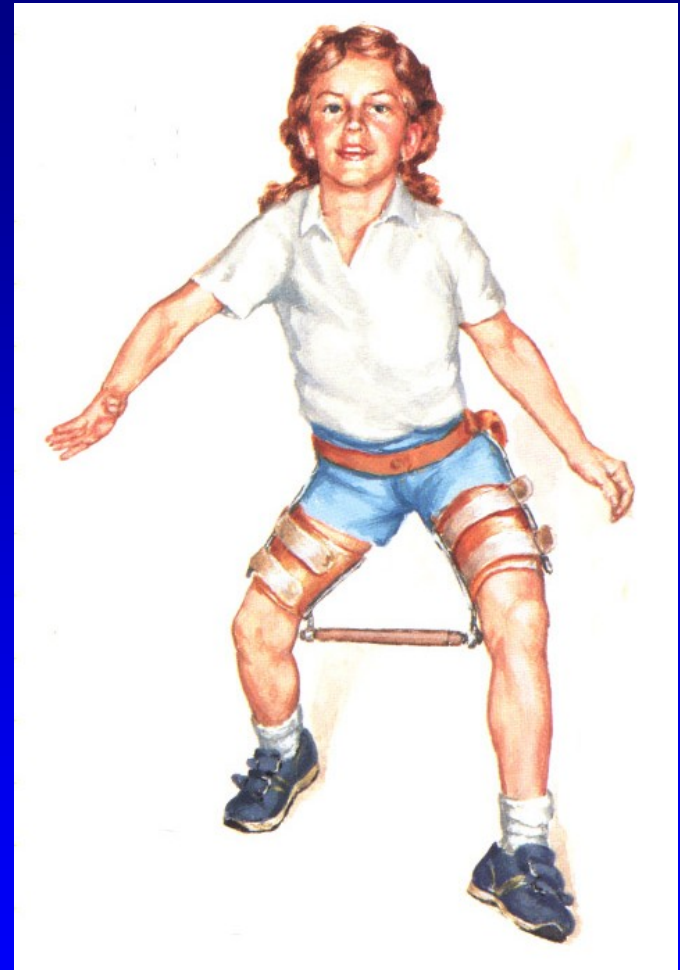Stulberg classification of deformity
of the femoral head in Perthes disease

Conservative methods

Rest in bed

Crutches

Atlanta orthosis



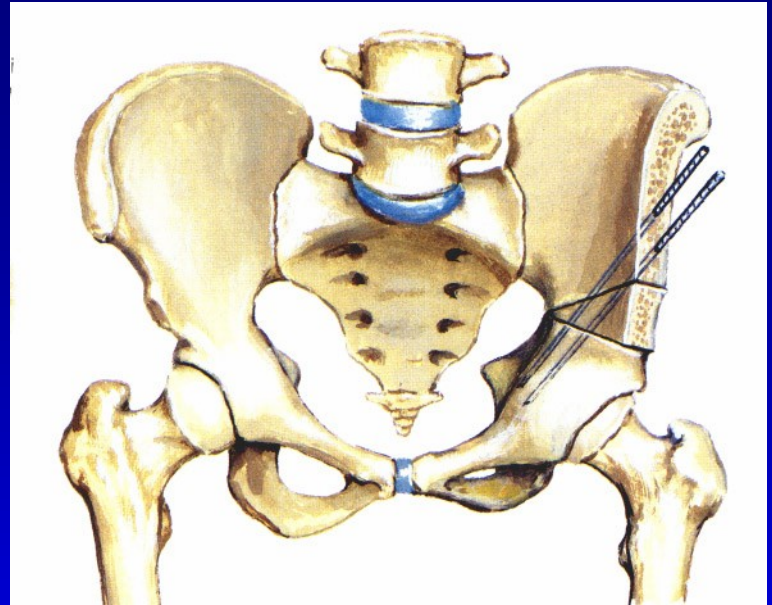
Obr. 16

Atlanta orthosis

Operative methods

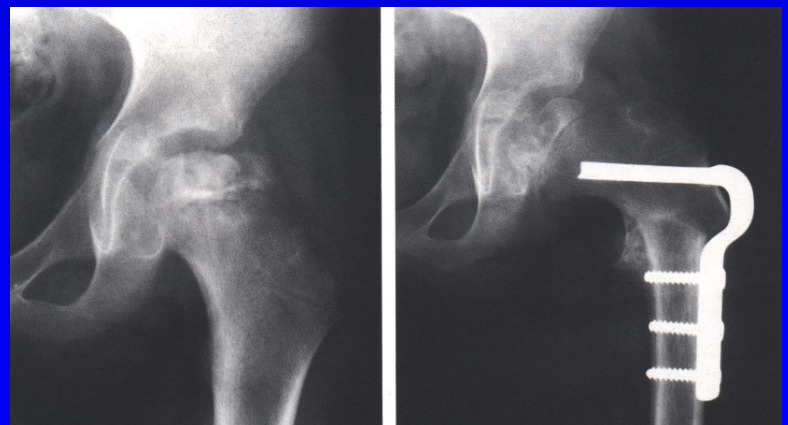
Salter pelvic osteotomy

Obr. 17

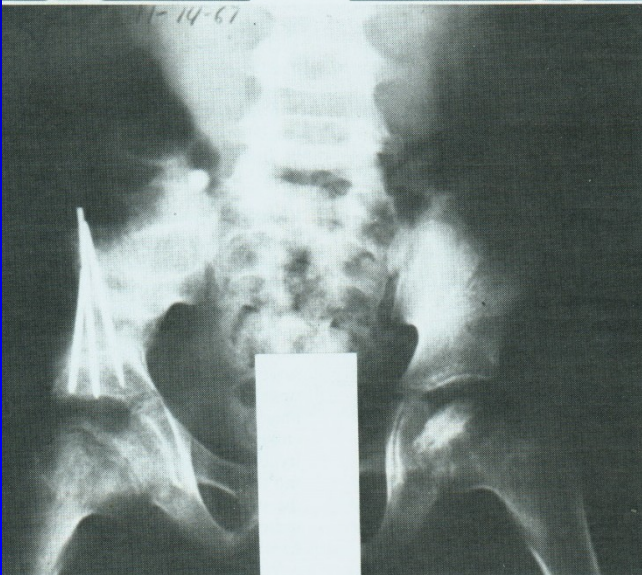
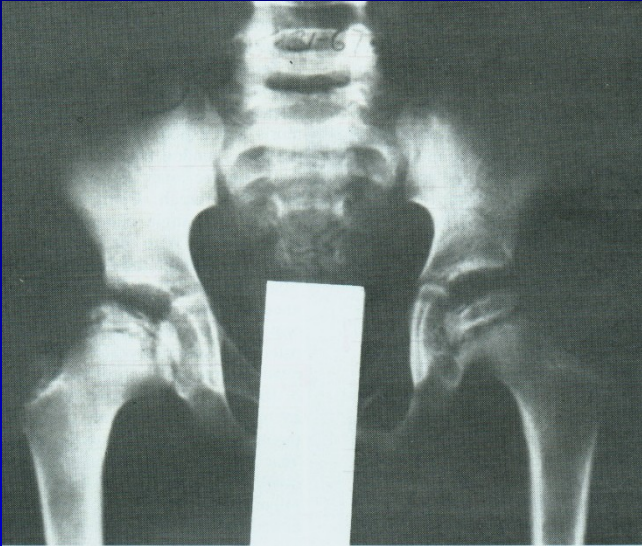


Varus osteotomy of the femur

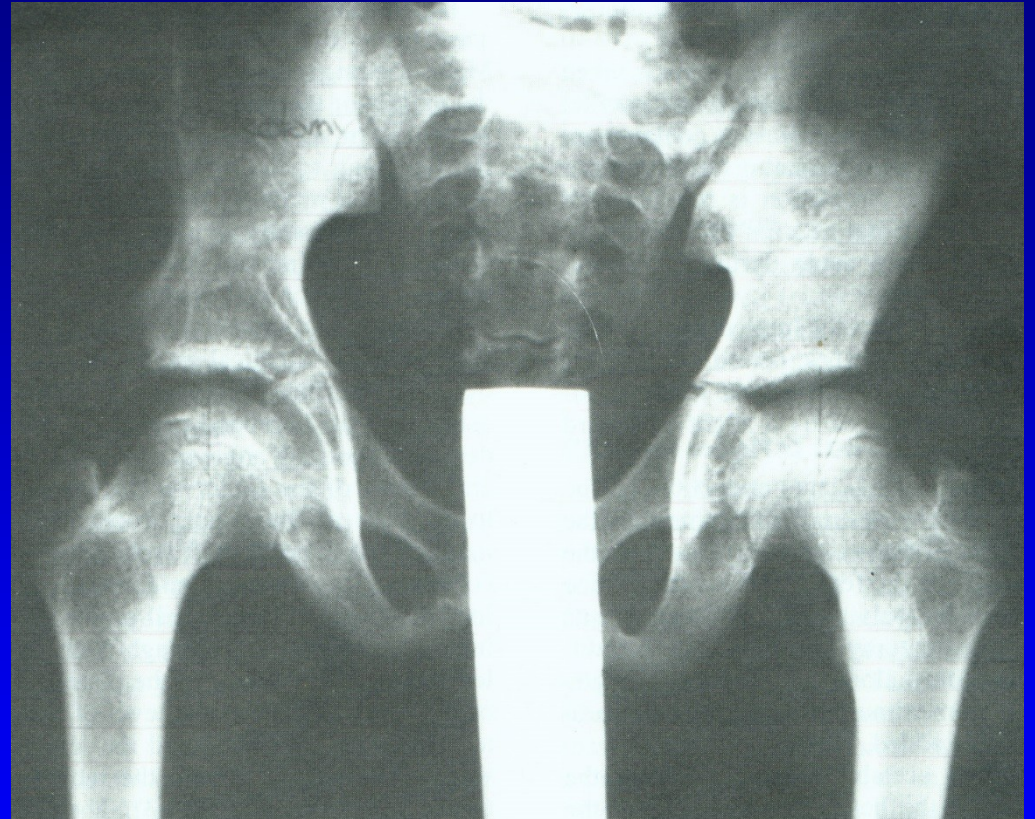
Obr. 18



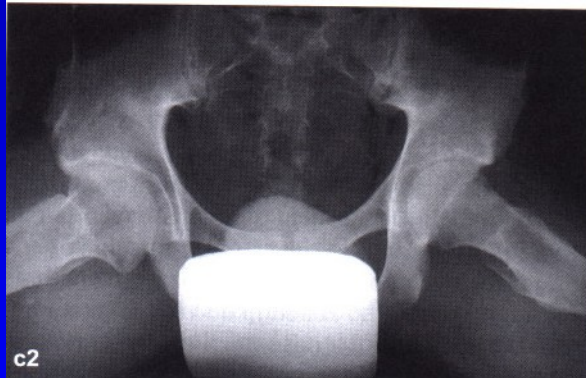
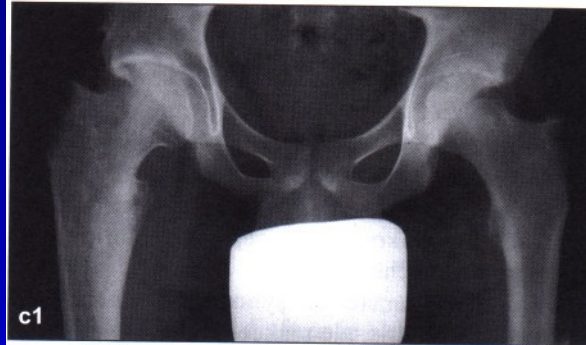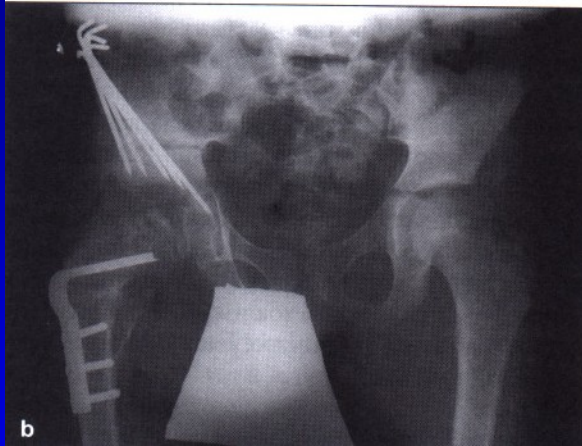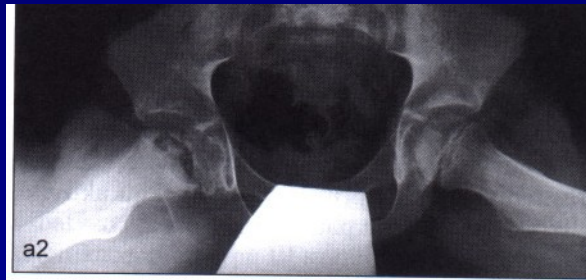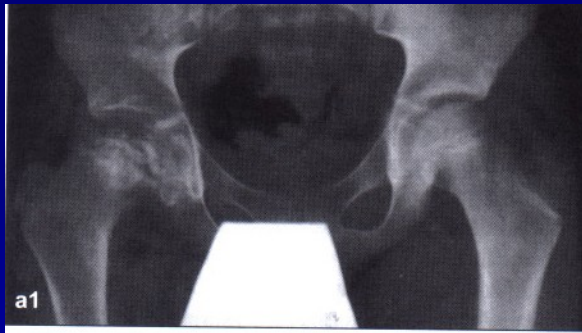Salter osteotomy



Obr. 19



Obr. 20



Perthes disease on the right hip
after Salter osteotomy
Almost normal hip in 18 years of age

Consequences of Perthes disease

Coxa plana

Shortening of the leg

Limited movements

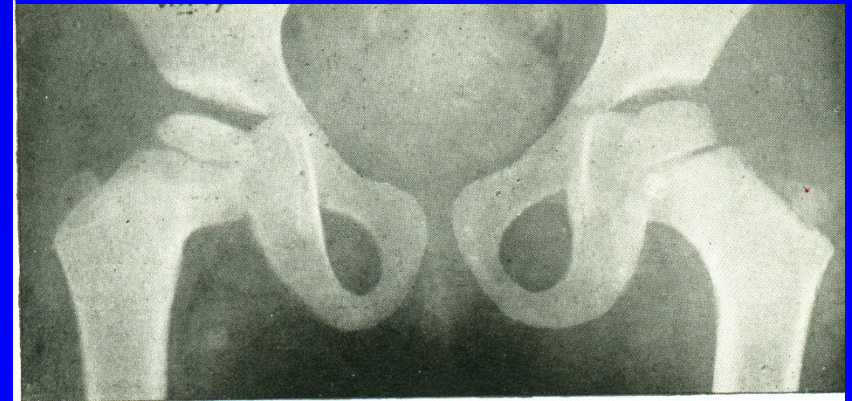
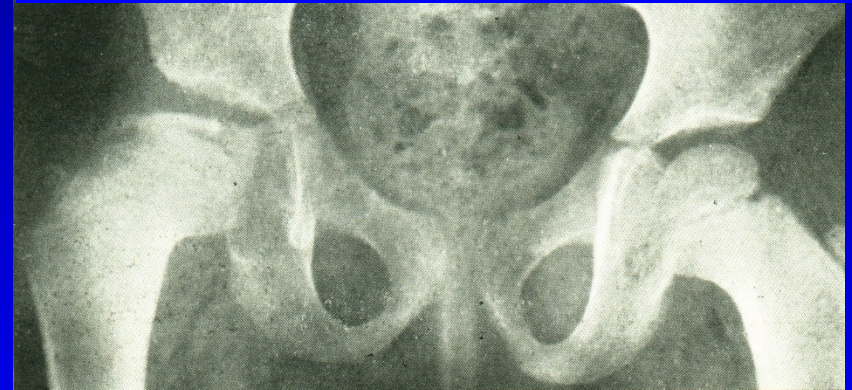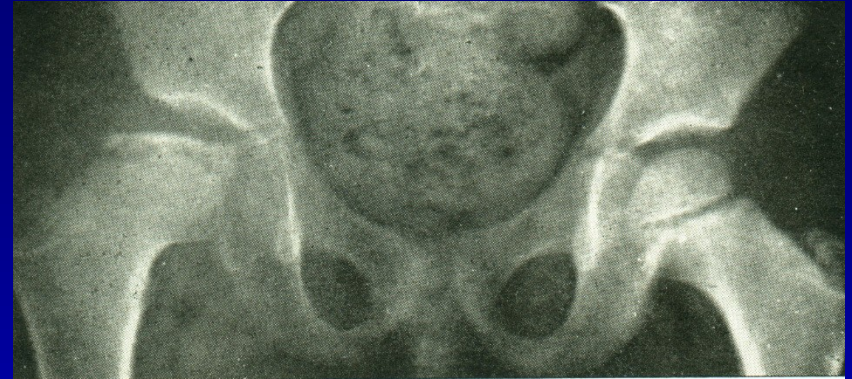
Early osteoarthritis

Better prognosis

Younger age

Less extent of damage

No subluxation



Tibia vara Blount

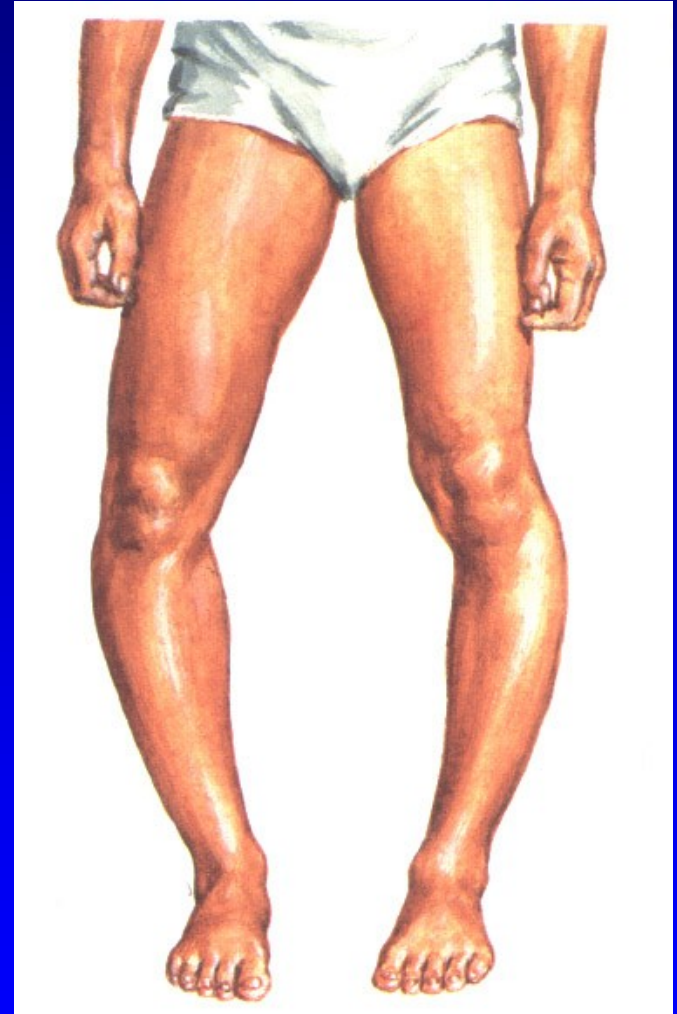
Disorder of proximal epiphysis
of the tibia

Early arrest of growth plate on medial
side with smaller epiphysis

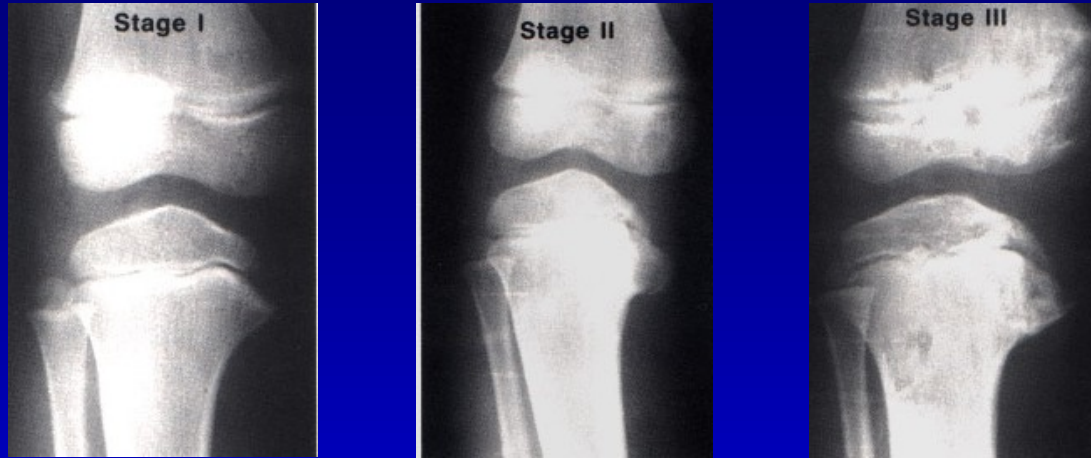Infantile – up to 3 years

Juvenile - up to 10 years

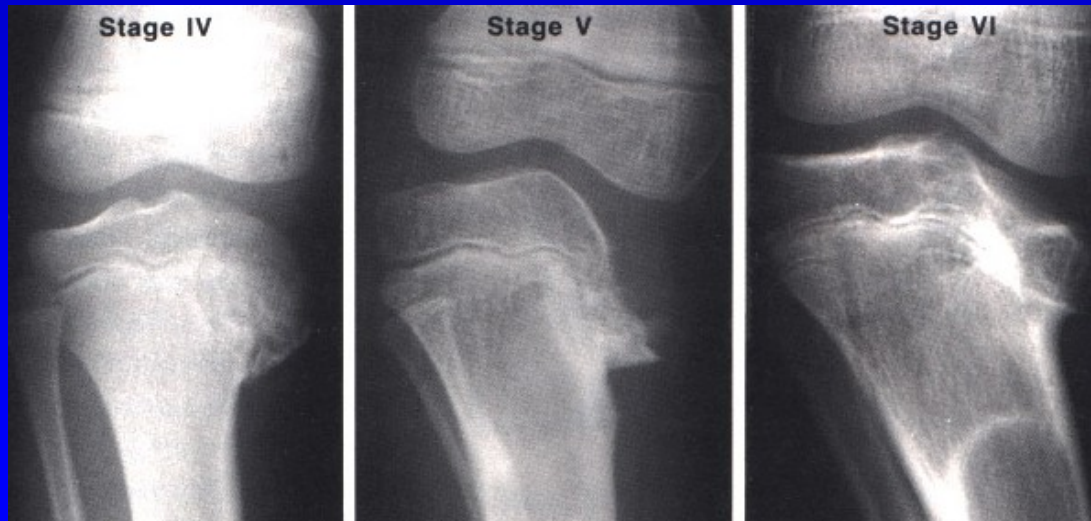
Th: orthosis, osteotomy



Tibia vara Blount



Obr. 24



Obr. 25

Slipped upper femoral epiphysis

Growth plate of proximal epiphysis

of the femur is weak and soft

Imbalance of growth hormon and
sexual hormones

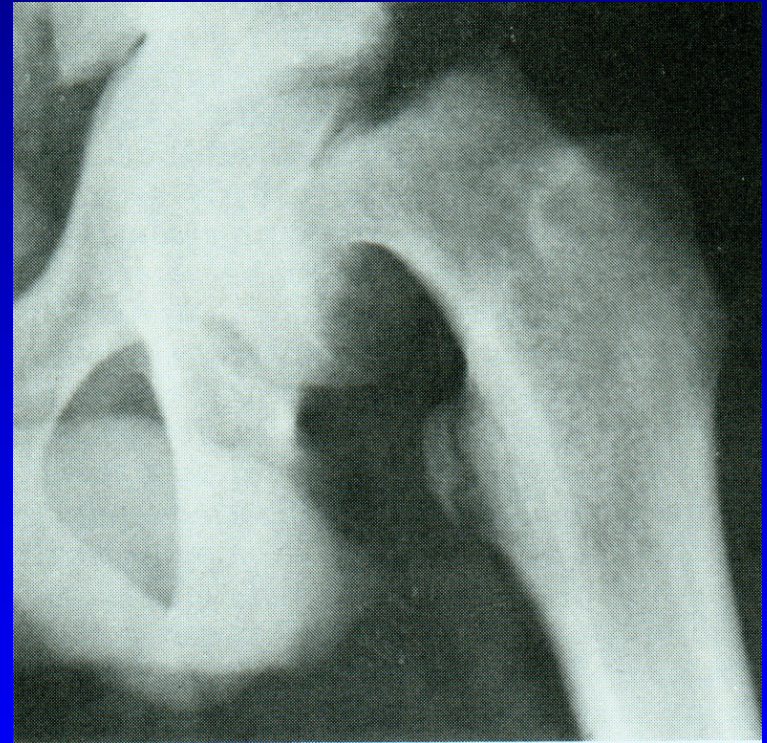
Obese patients

Fröhlich syndrom

Adiposogenital syndrom

9-15 years

Bilateral in one third

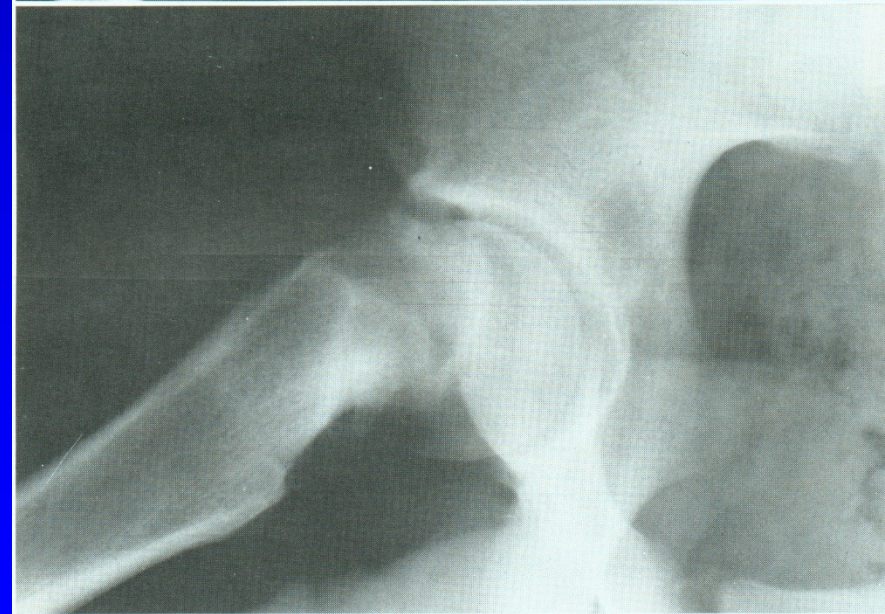
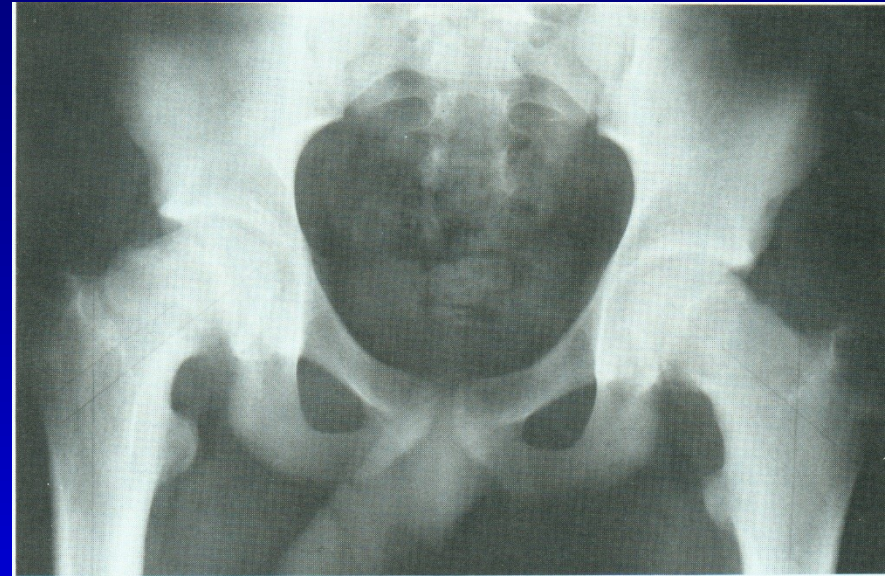


Obr. 26

Slipped upper femoral epiphysis

Slipping of epiphysis
down and backwards
to varus and to retroversion

Metaphysis goes proximally
and to external rotation



Symptoms

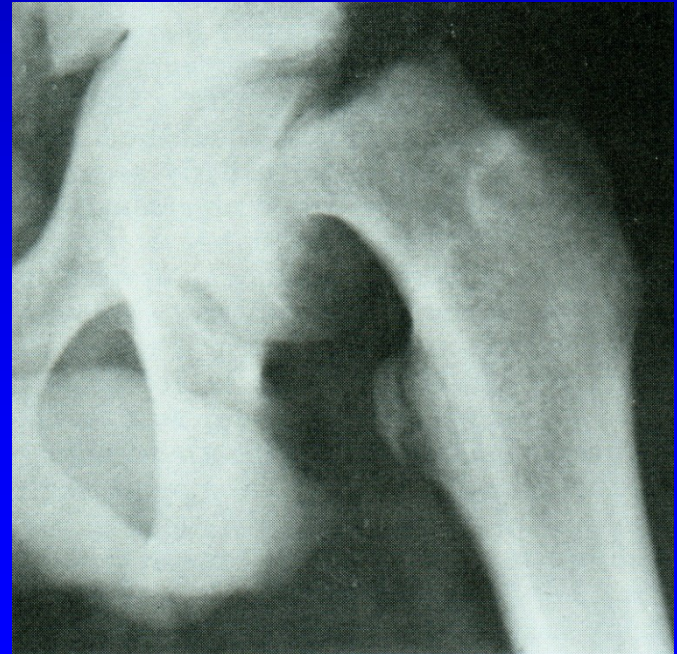
Pain in groin and in the thigh

Limping

Shortening of the leg

Limited abduction and external rotation

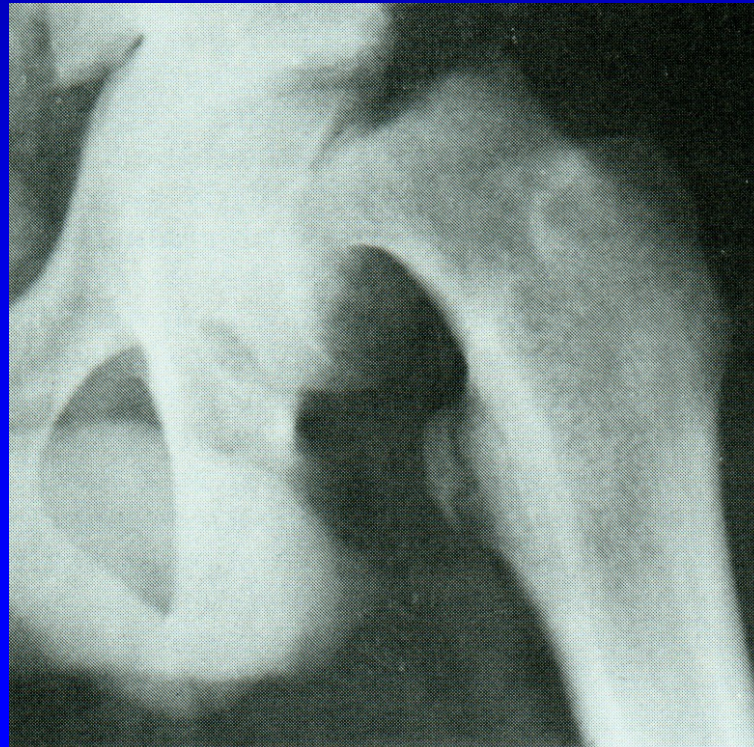
Positive Trendelenburg sign



Obr. 28

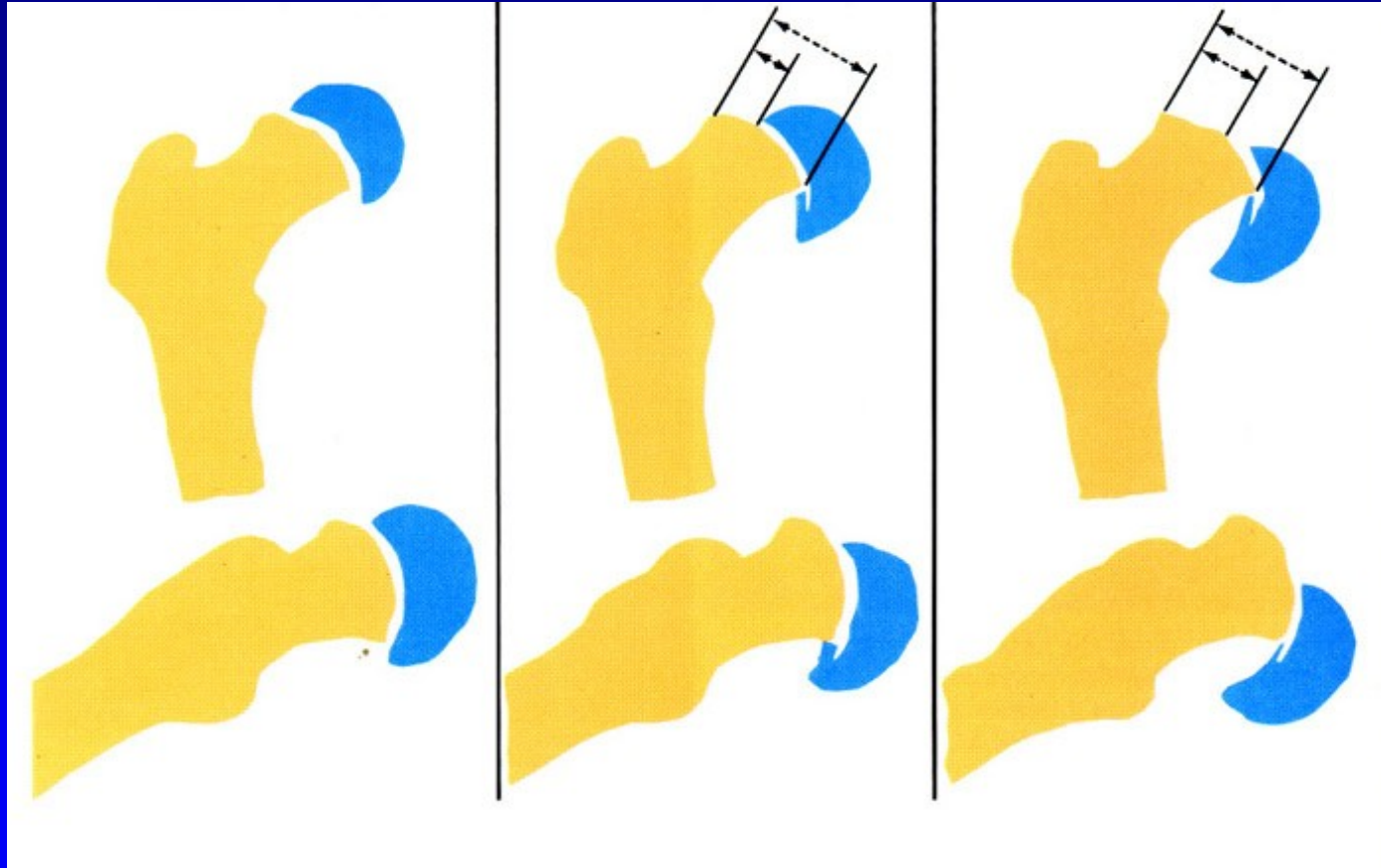
Types

1. Preslip (6%)
2. Acute slip (11%)
3. Chronic slip (after two weeks, 60 %)
4. Acute slip on chronic slipping (23%)



Obr. 29

Stages



1.

2.

3.

Obr. 30

Stages

1. Slight: slip up to 30%
2. Moderate : slip 30-60 %
3. Severe: slip above 60 %

Management

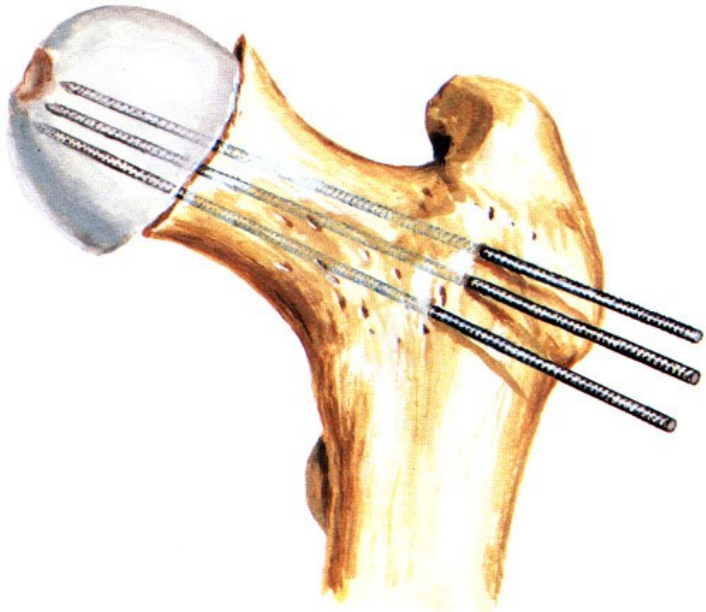
Fixation in situ (K wires, Knowles pins)

Closed reduction and K wires

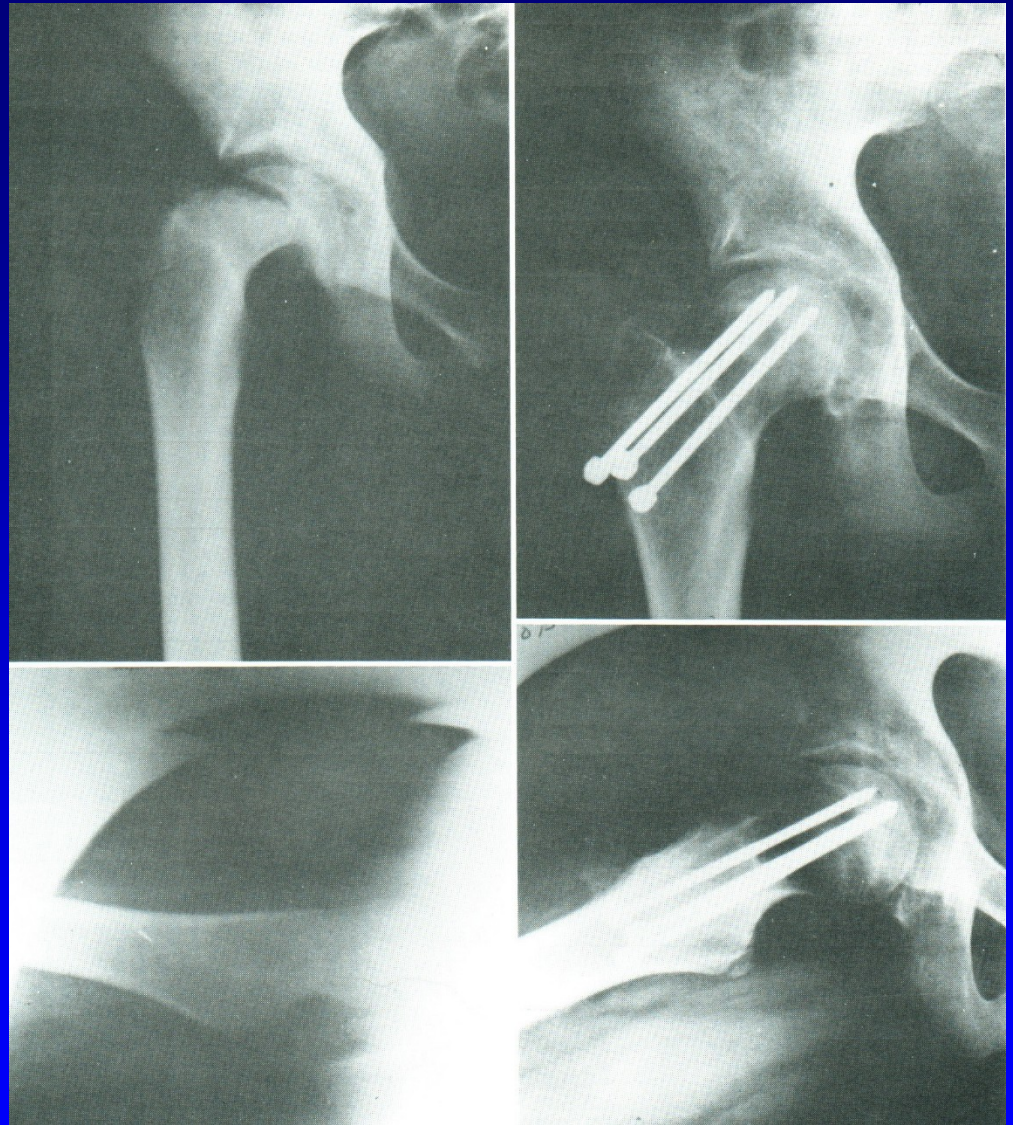
Open reduction

Osteotomy of proximal femur -
Southwick, Imhäuser-Weber

Fixation in situ

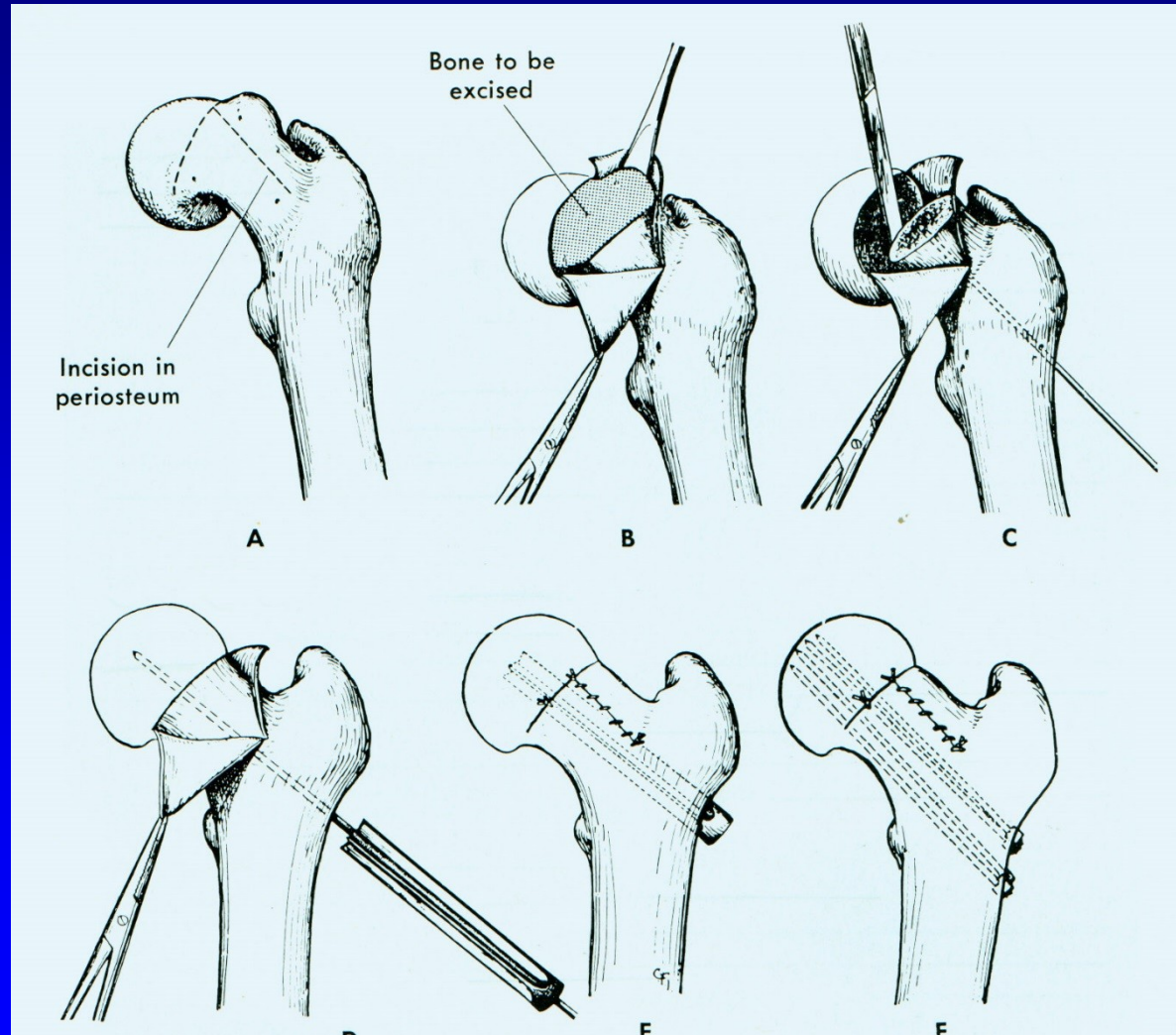


Obr. 31



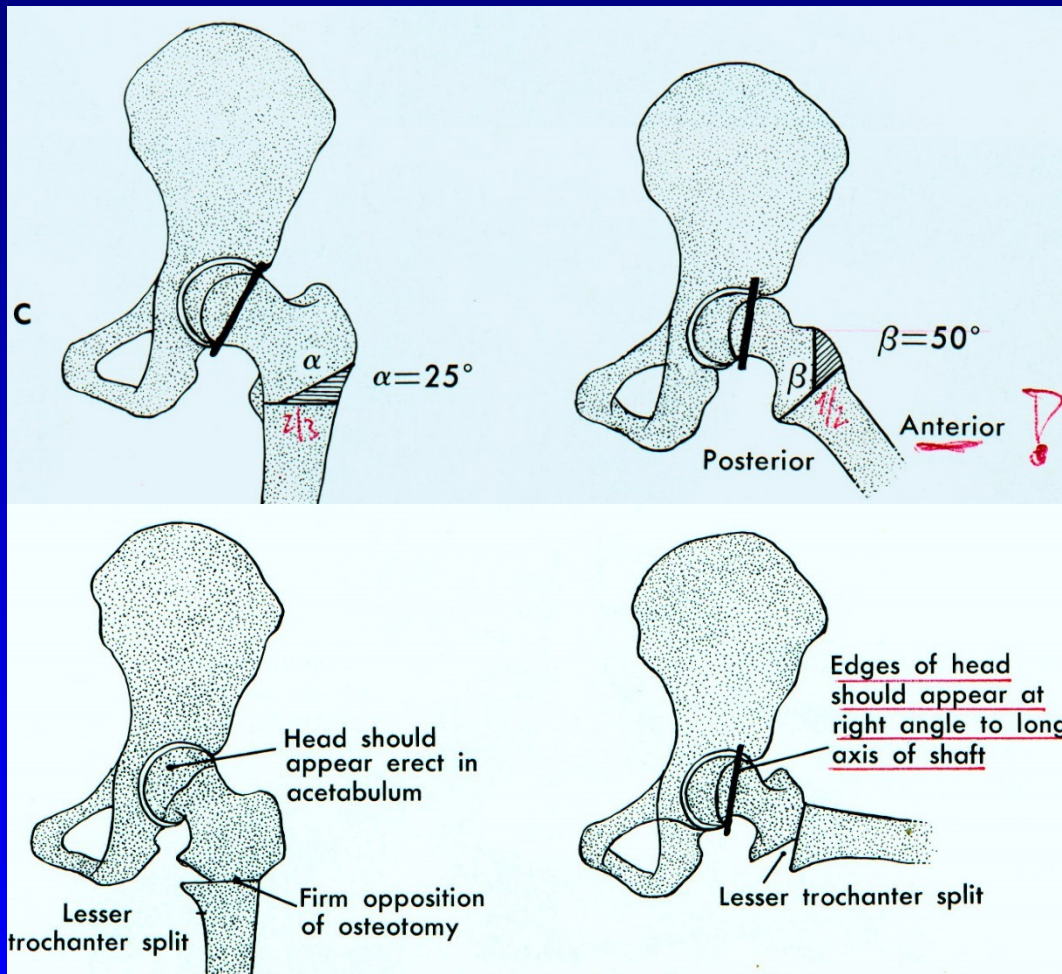
Obr. 32

Open reduction

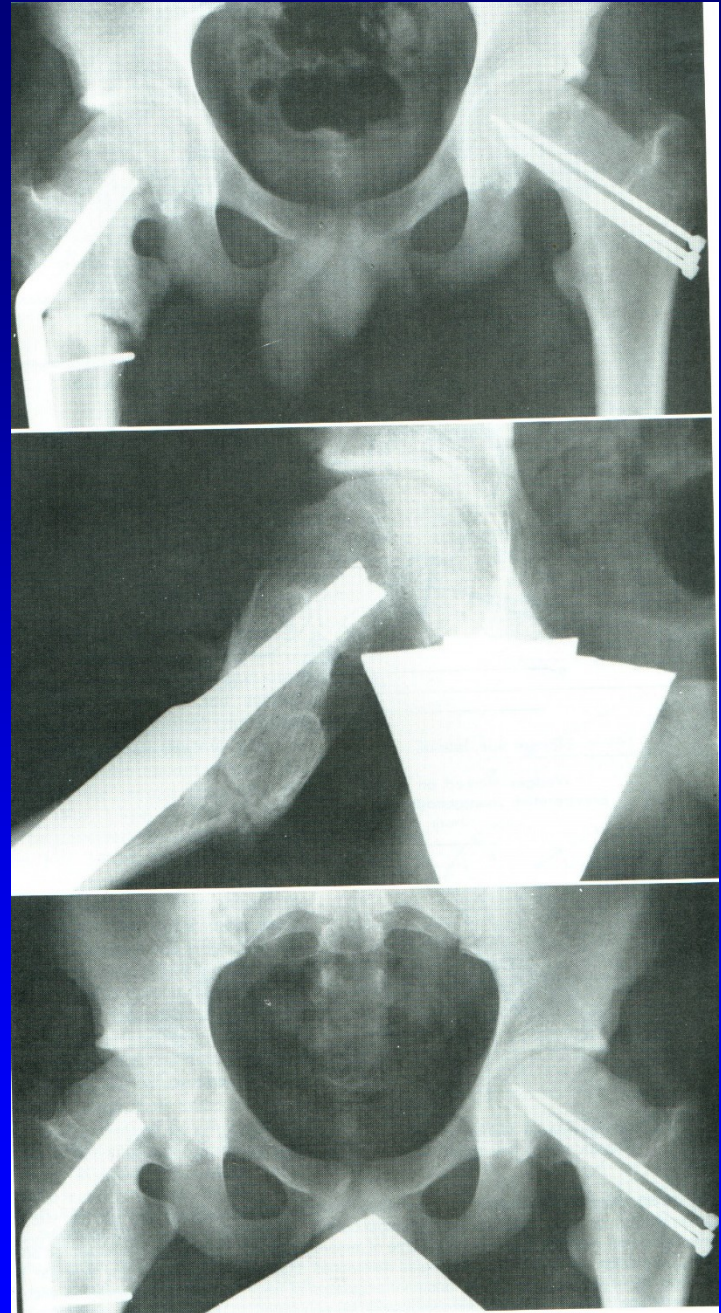

Obr. 33

Southwick osteotomy



Pertrochanteric osteotomy



Obr. 35

Complication of slipped upper femoral epiphysis

Avascular necrosis of the femoral head

Chondrolysis of the femoral head

Osteoarthritis of the hip

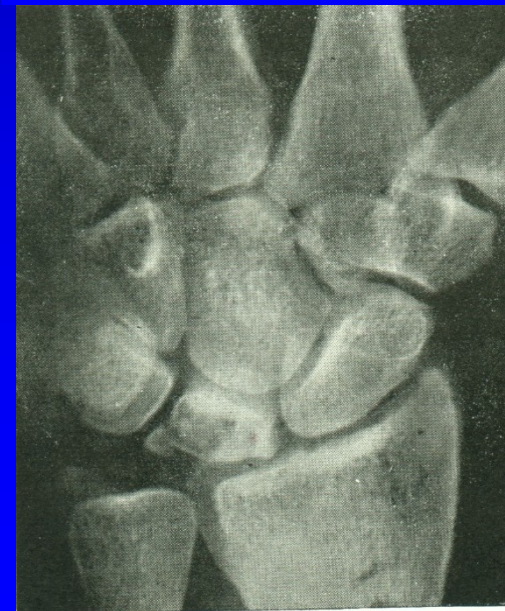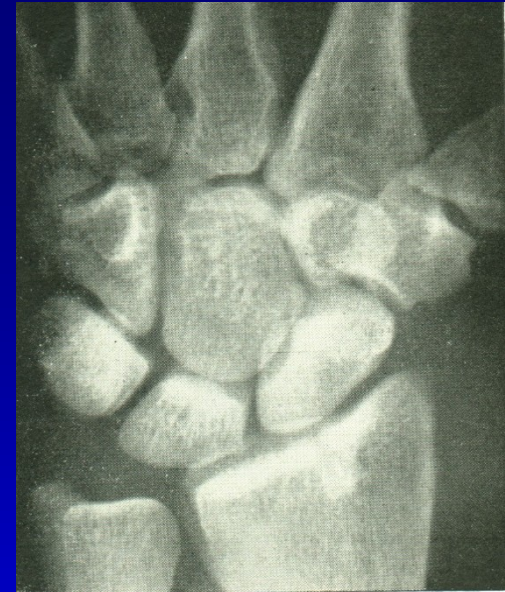Necrosis of os lunatum m. Kienböck

Therapy

Rest

Immobilisation

Removal and replacement
by tendon, by os pisiforme
or by artificial material



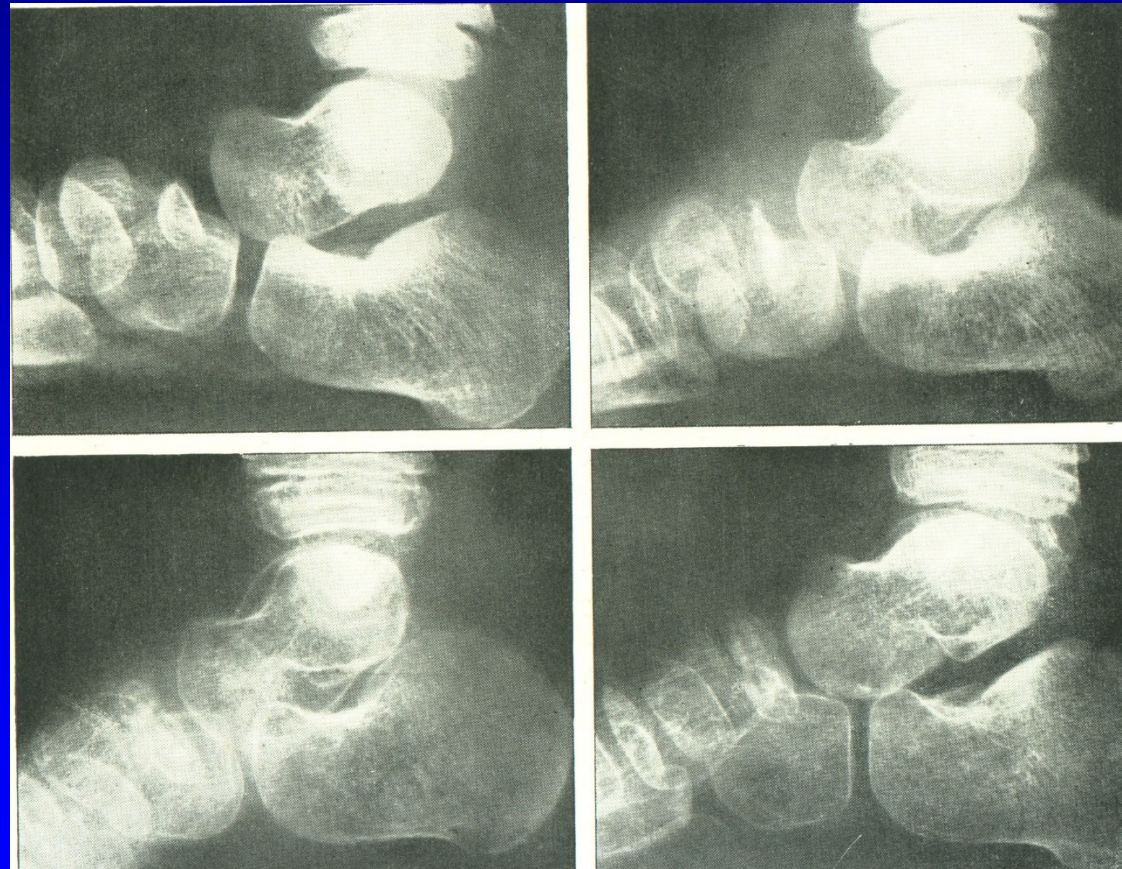
M. Köhler I. - necrosis of navicular bone

Therapy

Rest

Immobilisation

Arthrodesis



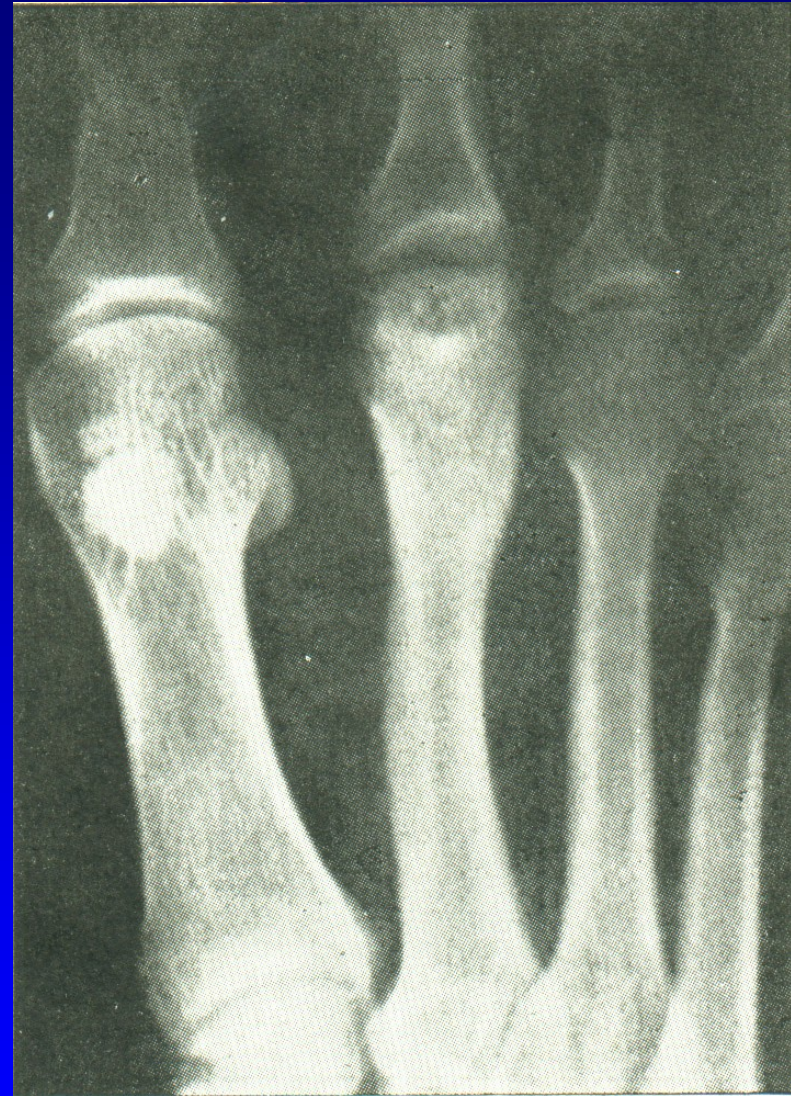Obr. 37

M. Köhler II.
M. Freiberg-Köhler
Necrosis of metatarsal head

Therapy

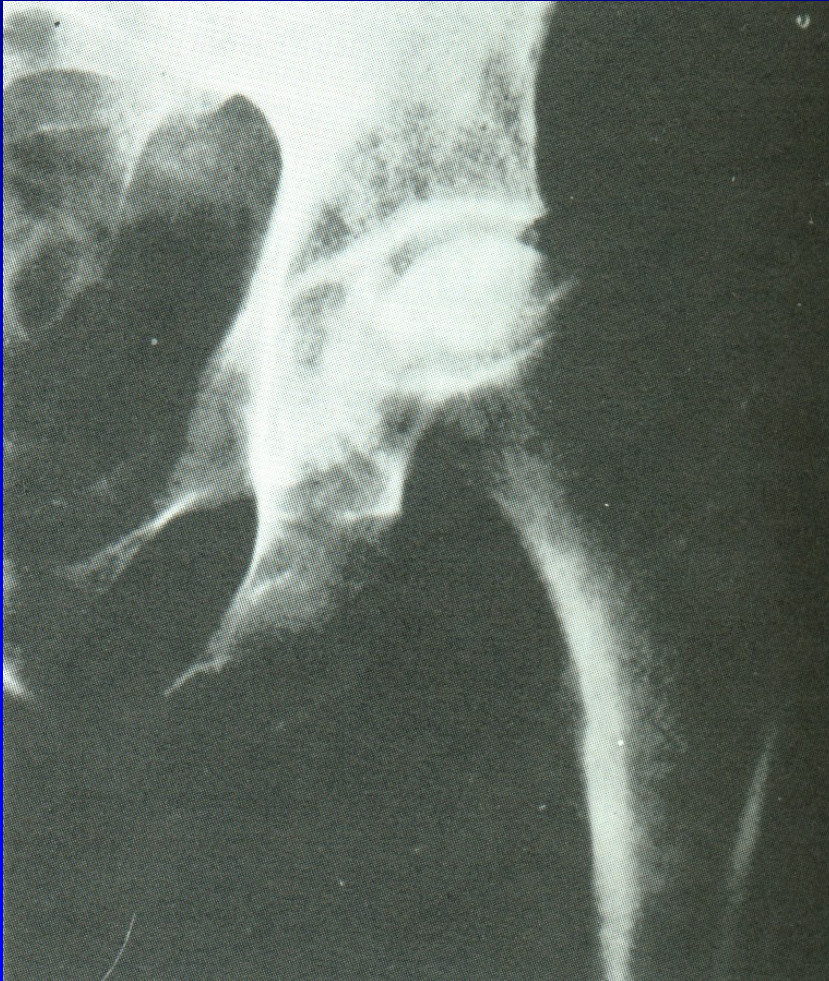Rest, padding

Surgery:
Removal of necrotic part
Osteotomy



Obr. 38

Avascular necrosis of femoral head in adults



Etiology unknown

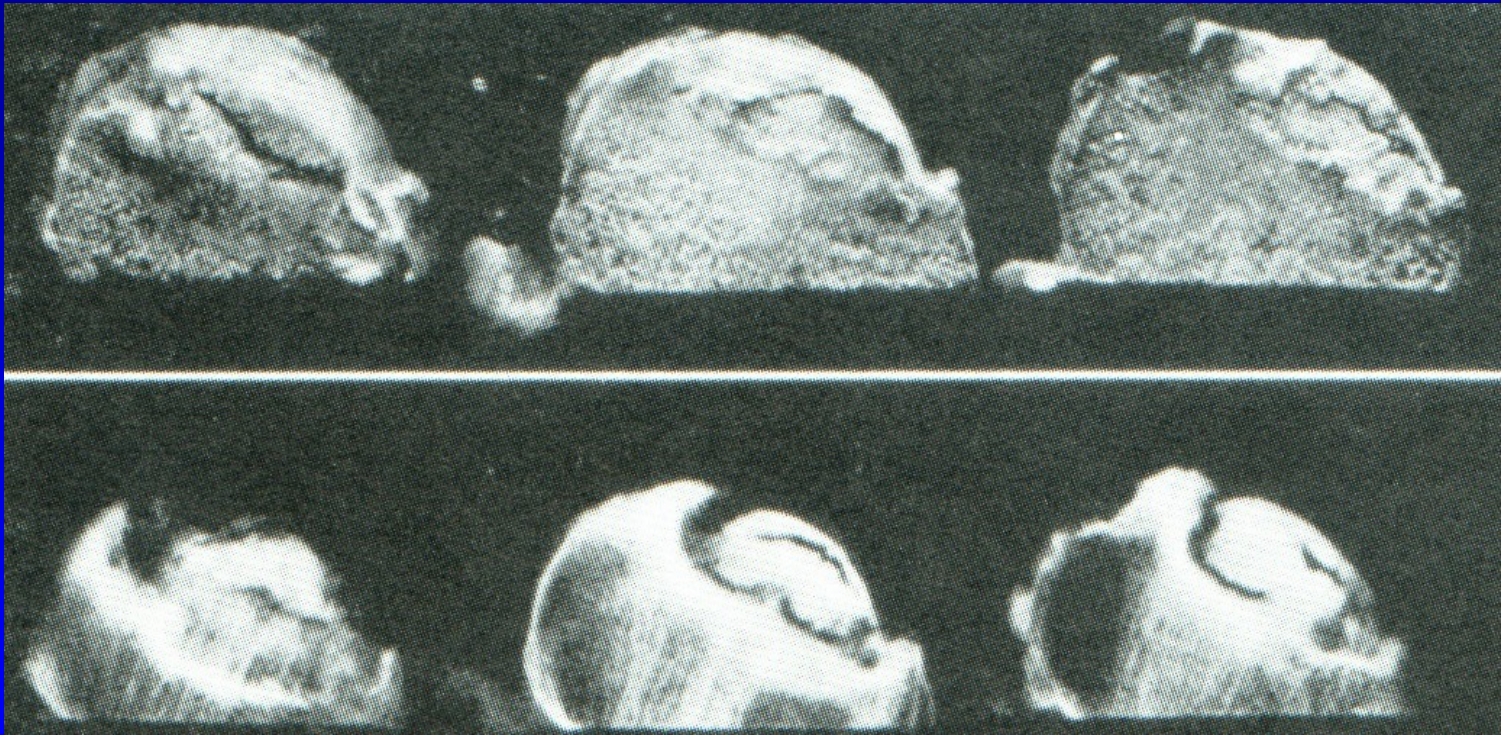
Pain

Limited movements

Limping

Obr. 39

Avascular necrosis of femoral head



Obr. 40

Management

Crutches

Forrage, bone grafting

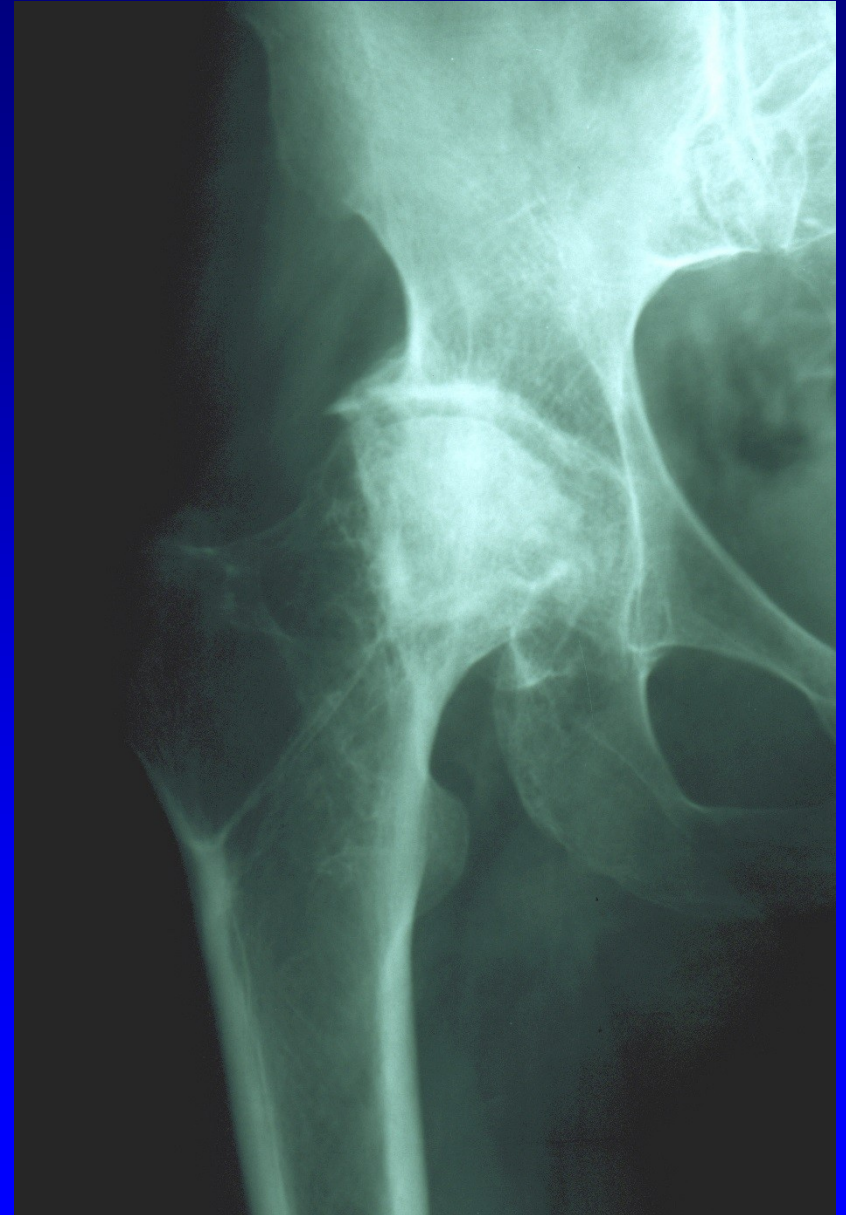Osteotomy-varus, valgus, derotation

Arthrodesis

Total hip replacement

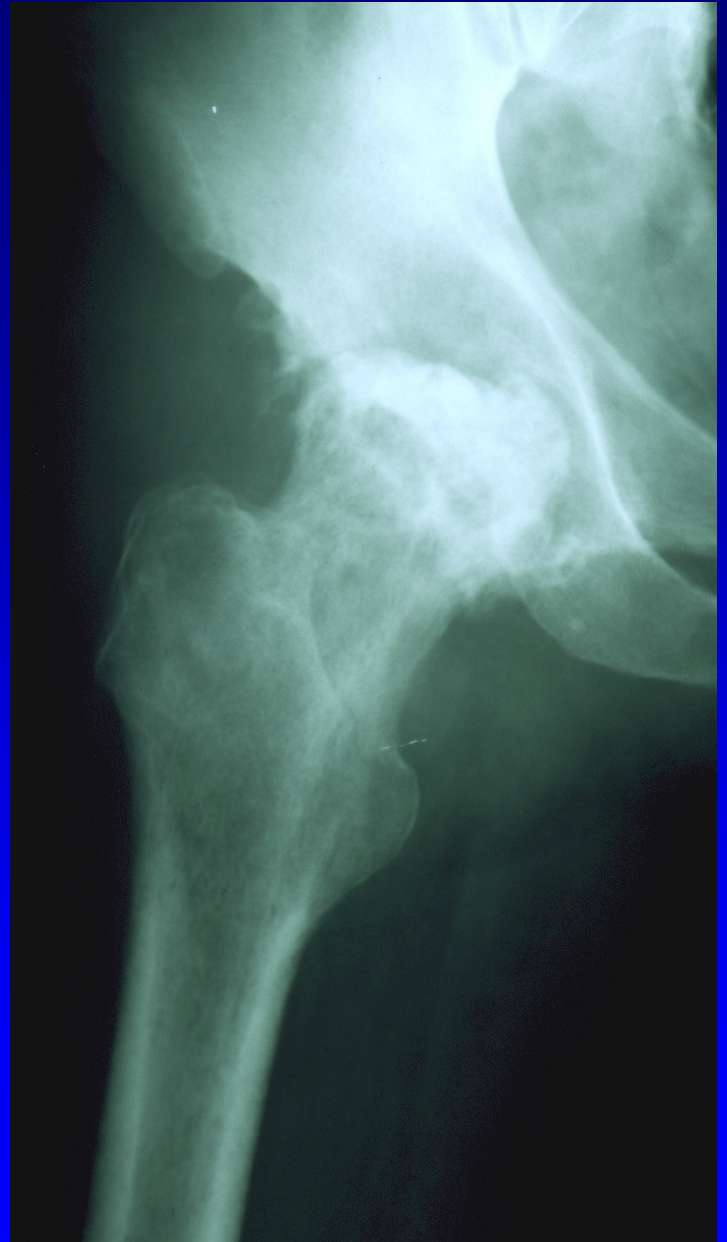Necrosis after fracture
of the neck of the femur

Obr. 41



Necrosis of the femoral head
after coxitis

Obr. 42



M. Ahlbäck – necrosis of medial condyle of the femur

m. Osgood- Schlatter – proximal apophysis
of the tibia

Necrosis of sesamoid bone

M. Panner – osteonecrosis of humeral head

Vertebra plana Calvé

Necrosis of apophysis of calcaneus

Literature

Janíček, P.: Ortopedie. Lékařská fakulta MU v Brně,
2001.

Spoluautoři: Dufek, P., Chaloupka, R., Krbec, M.,
Poul, J., Procházka, P., Rozkydal, Z.

Figures

Edmonson A.S., Crenshaw, A.H. : Campbell's Operative Orthopaedics. Sixth Edition, The C.V. Mosby Company, 1980.
Obr. 19,20,27,33,34,35.

Netter, F.: The CIBA collection of medical illustrations Vol. 8, part. I, II., Ciba- Geigy Corporation, 1990.
Obr. 5,8,9,10,11,12,13,14,15,16,17,18,22,24,25,30,31,32.

Bartoníček, J., Heřt, J.: Základy klinické anatomie Pohybového aparátu. Maxdorf, Jesenius, 2004.
Obr. 2

Figures

Turek, S.: Orthopaedics. J.B. Lippincott Company,
Third Edition, 1977
Obr. 6,38,40.

Frejka, B.: Základy ortopedické chirurgie. Avicenum
Praha, 1970
Obr. 3,21,26,28,29,36,37.

Janíček, P.: Ortopedie. Masarykova univerzita, 2001.
Obr. 4.