

Metabolic disorders

Z. Rozkydal

Metabolic disorders- osteopathy

- Osteoporosis
- Osteomalatia
- Primary hyperparathyreoidisms
- Secondary hyperparathyreoidisms:
 - renal osteodystrophy
 - gastrointestinal osteodystrophy

Composition of bone

50 % anorganic material (hydroxyapatit crystals)

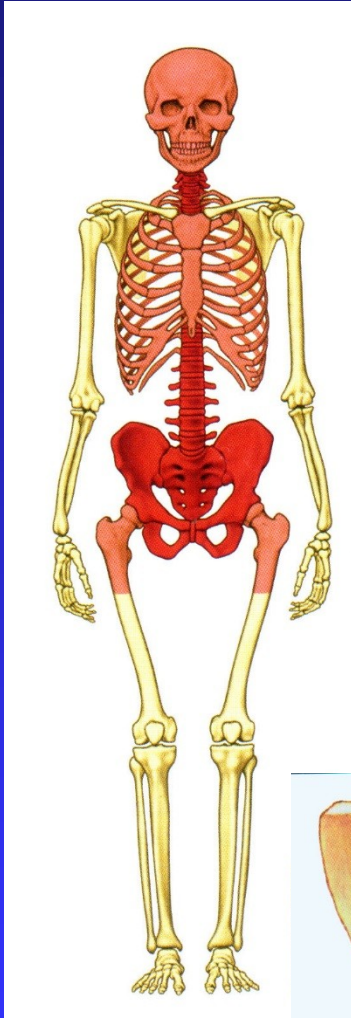
25 % organic bone matrix (osteoid):

90 % collagen type I

10 % other proteins (osteocalcin,
osteonectin, proteoglycans, enzymes)

25 % water binding on collagen and proteoglycans

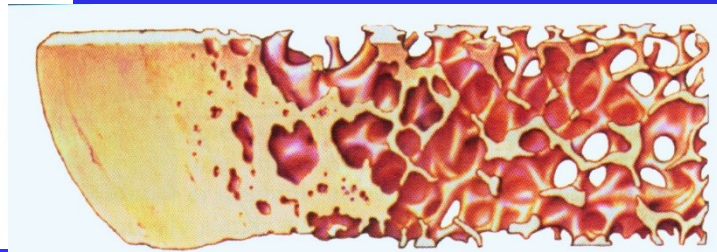
Skeleton



Weight 5 kg

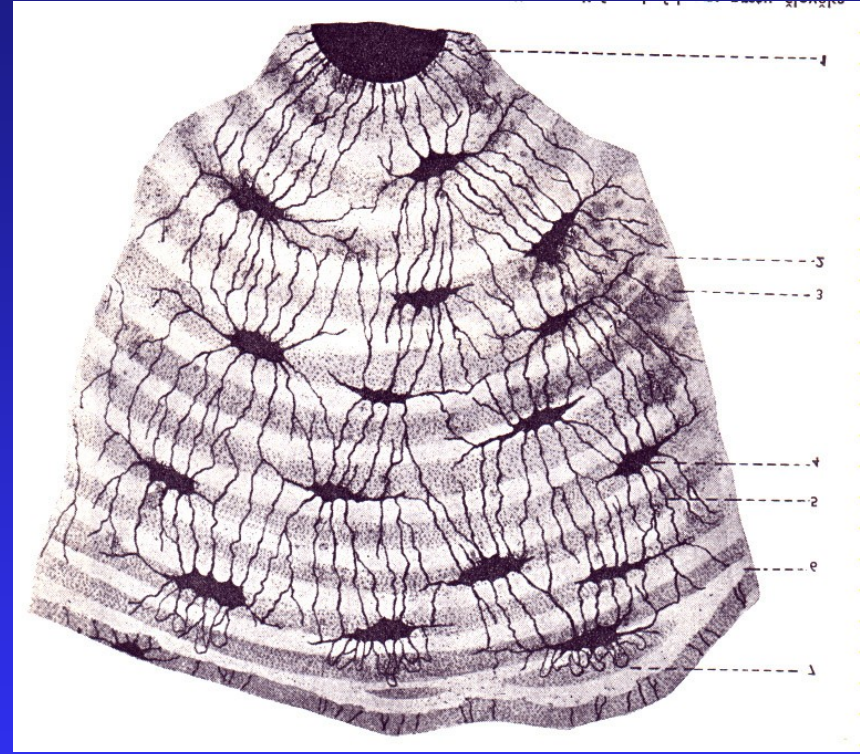
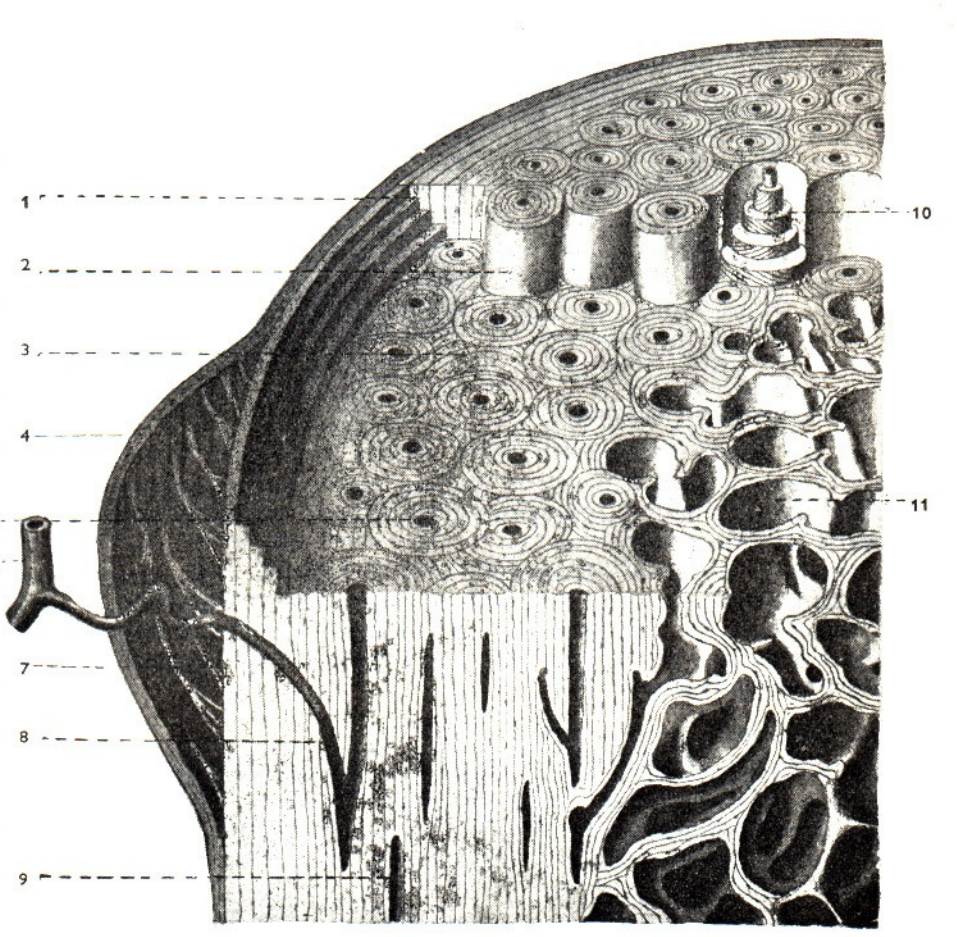
Cortical bone 4 kg

Trabecular bone 1 kg


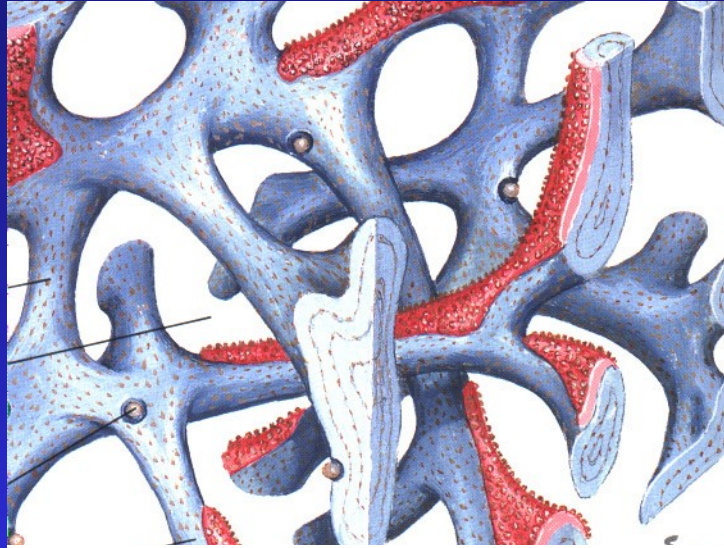


Cortical bone Trabecular bone

Cortical bone- Haversian system



Trabecular bone

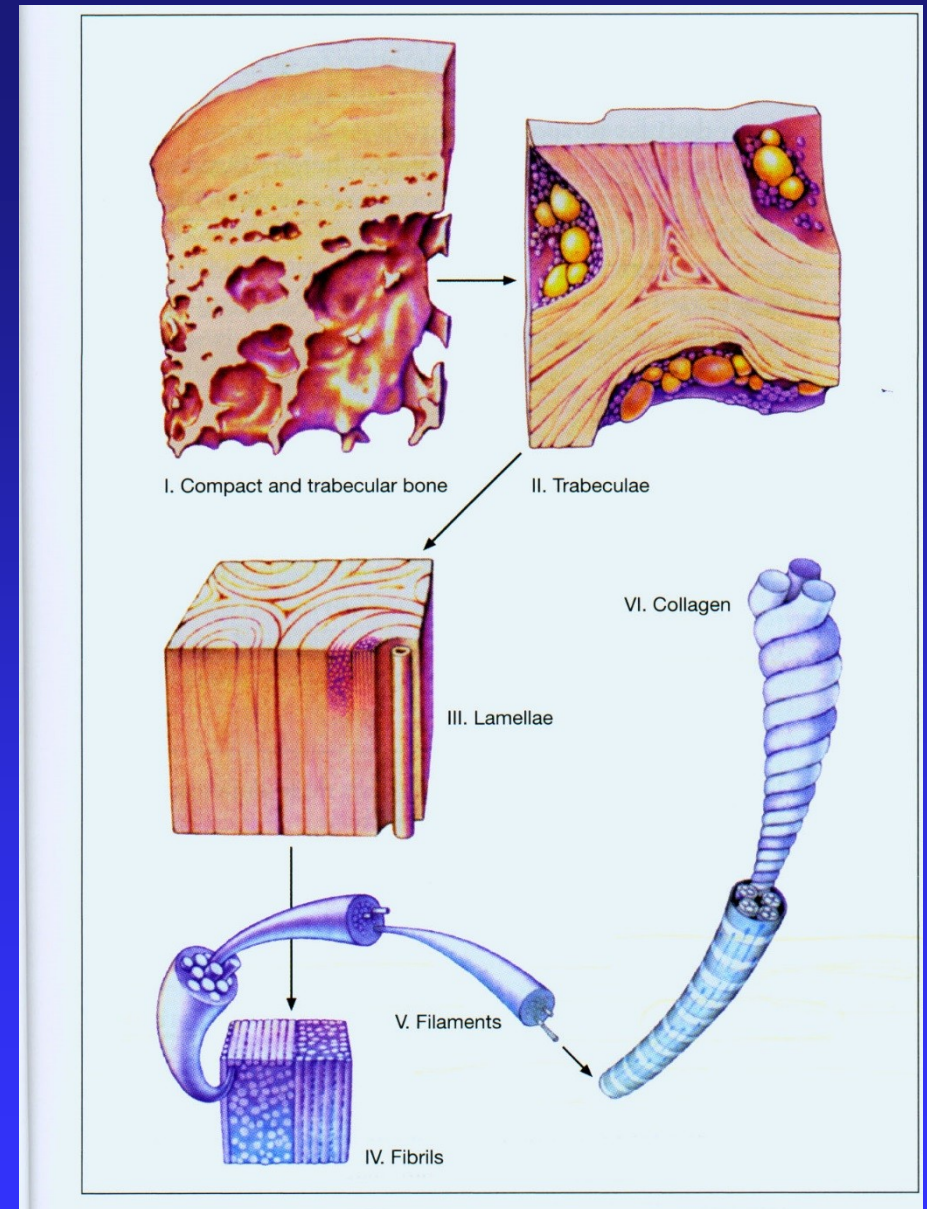


Trabecular bone:

- 20% of the skeleton
- 80% of remodelling

Cortical bone:

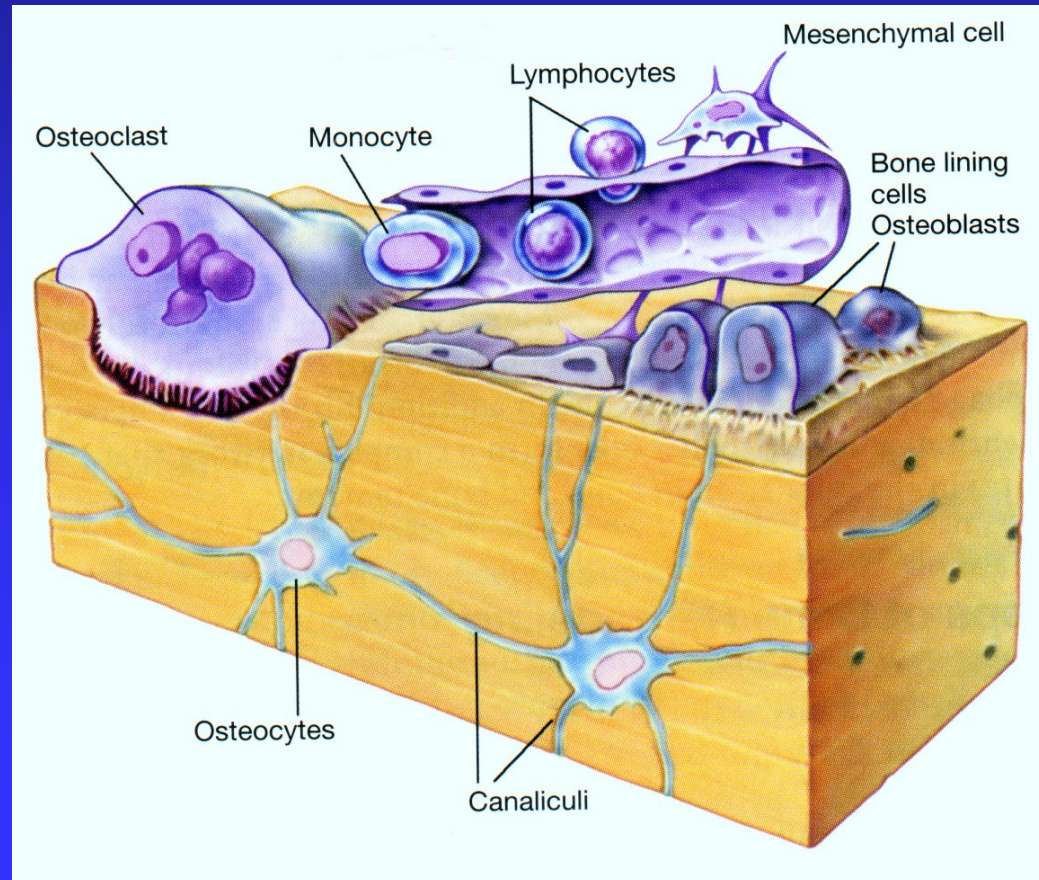
- 80% of the skeleton
- 20% of remodelling



Collagen type I.

Osteoblasts:

- They produce osteoid- organic part of matrix
- They provide mineralisation of bone
- They produce alkaline phosphatase
– indicator of the synthesis of proteins



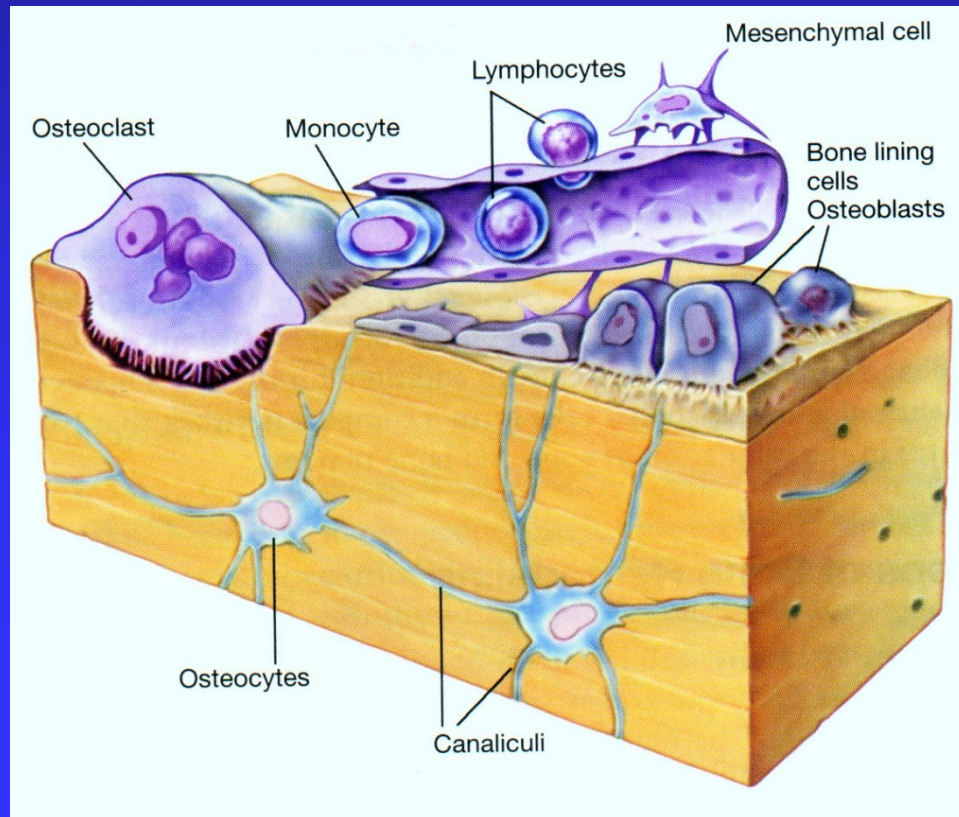
Osteoclasts:

Large multinuclear cells

They are localised in Howship lacunae on the surface of bone

They produce acid phosphatase and lytic enzymes

They dissolve hydroxyapatite crystals and bone matrix

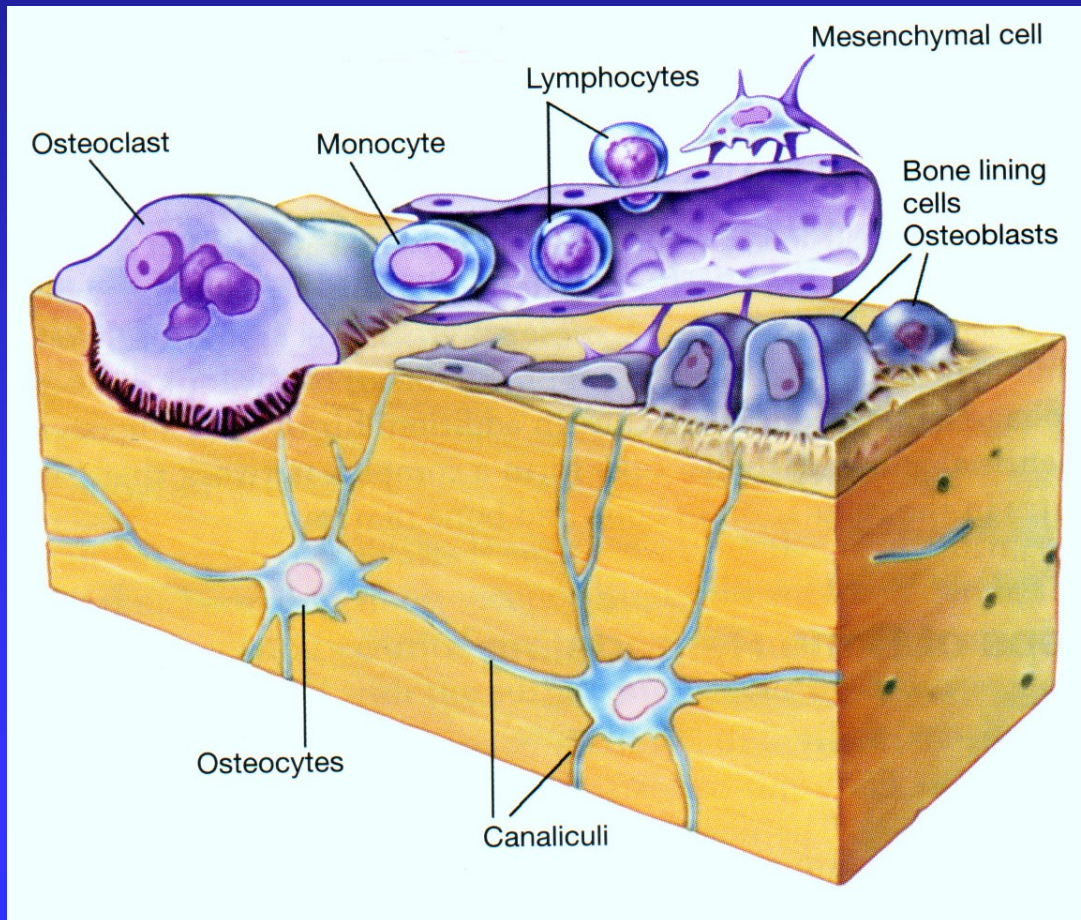


Osteocytes

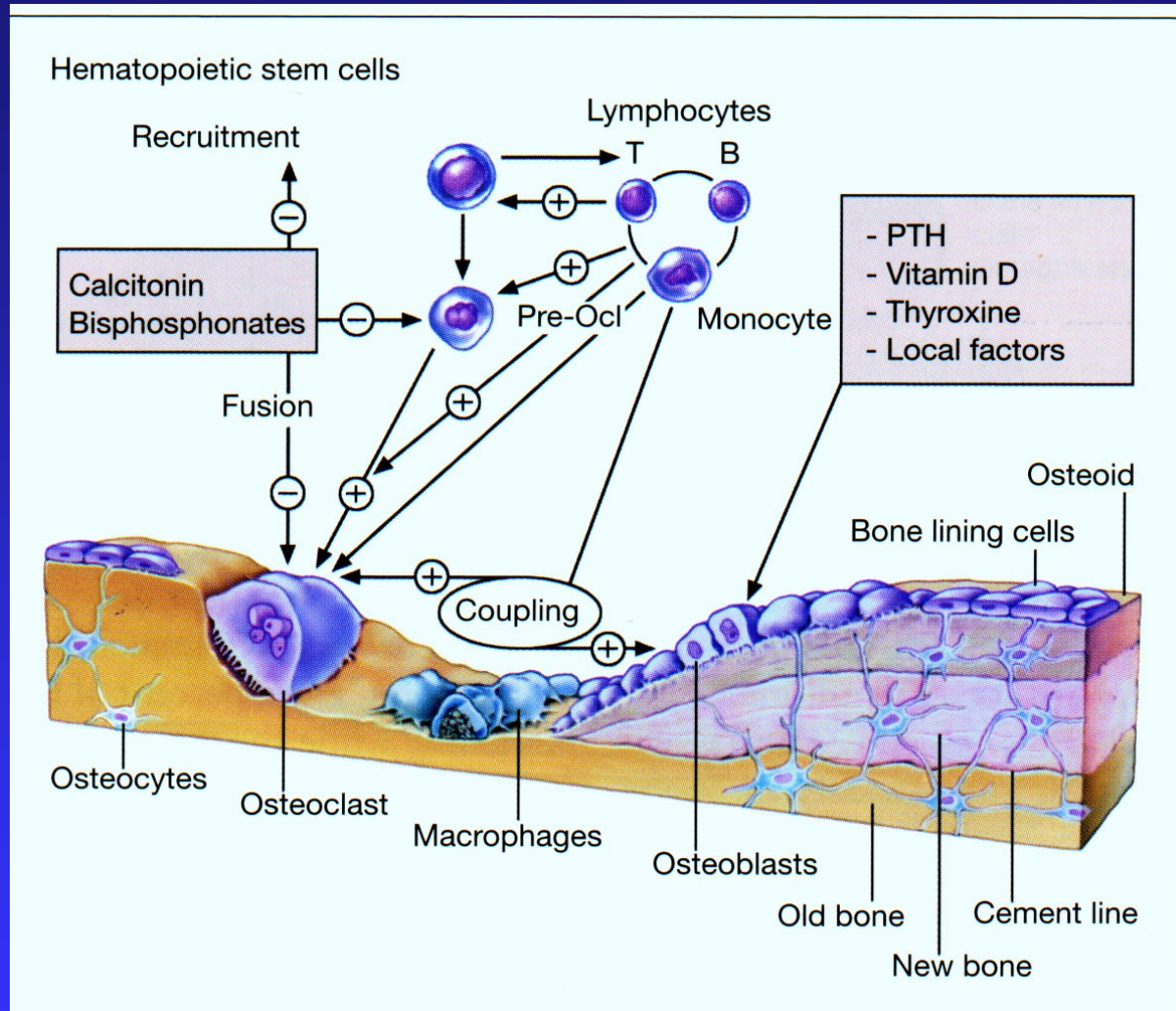
They lie in lacunae of corticals and trabecular bone

They are connected with canaliculi

They maintain metabolism of bone



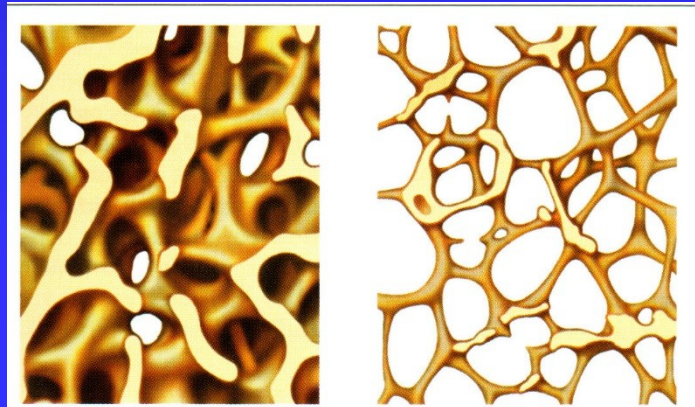
Remodelling of bone



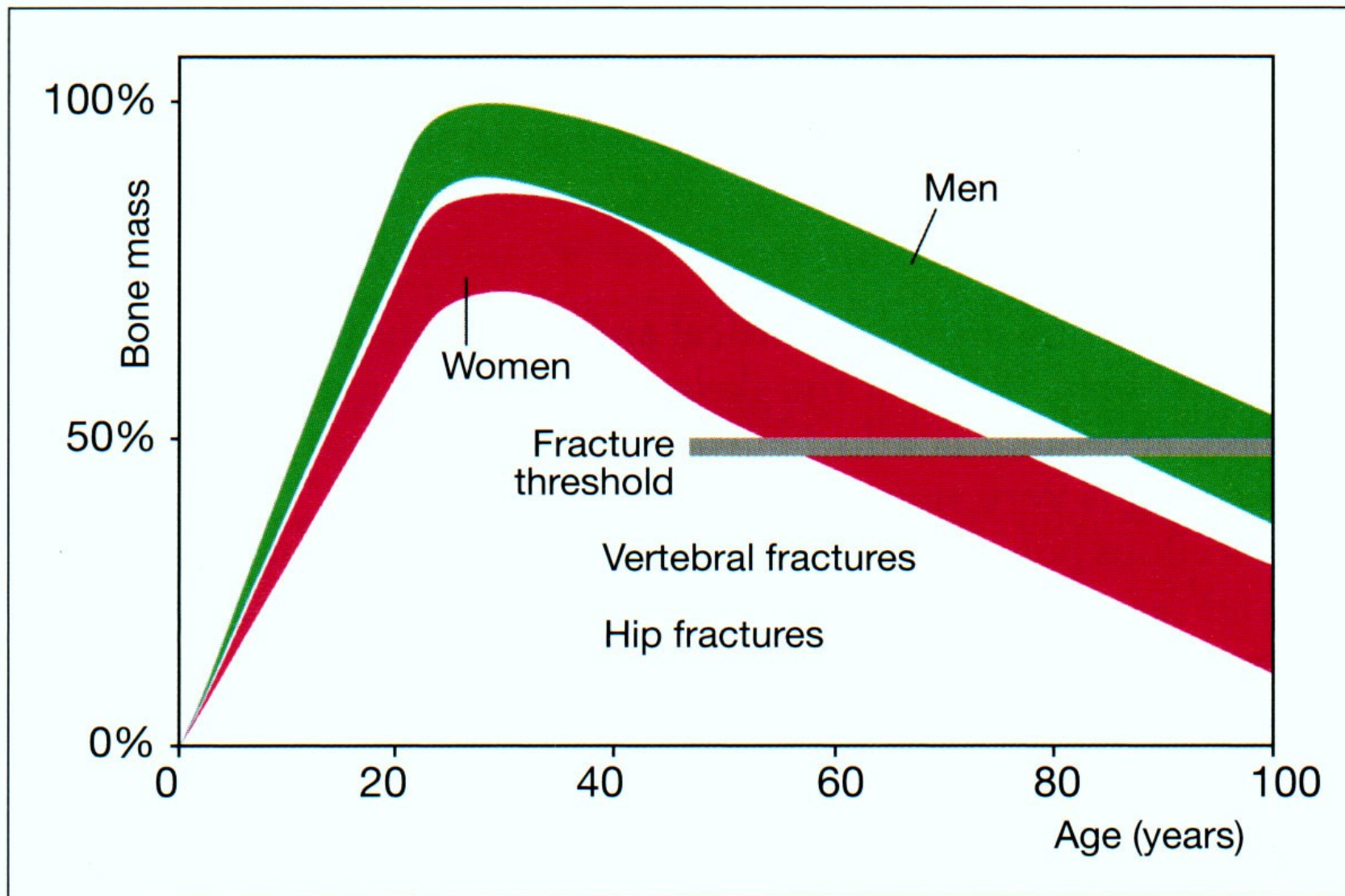
Resorption is finished in 2 weeks
Mineralisation up to six months

Osteoporosis is a systemic disorder of the skeleton

- Diminished strength of bone
- Low bone density
- Impaired microarchitecture
- Tendency to fractures
- Loss of organic and anorganic bone



Peak bone mass - in 25-30 years of age



Bone loss

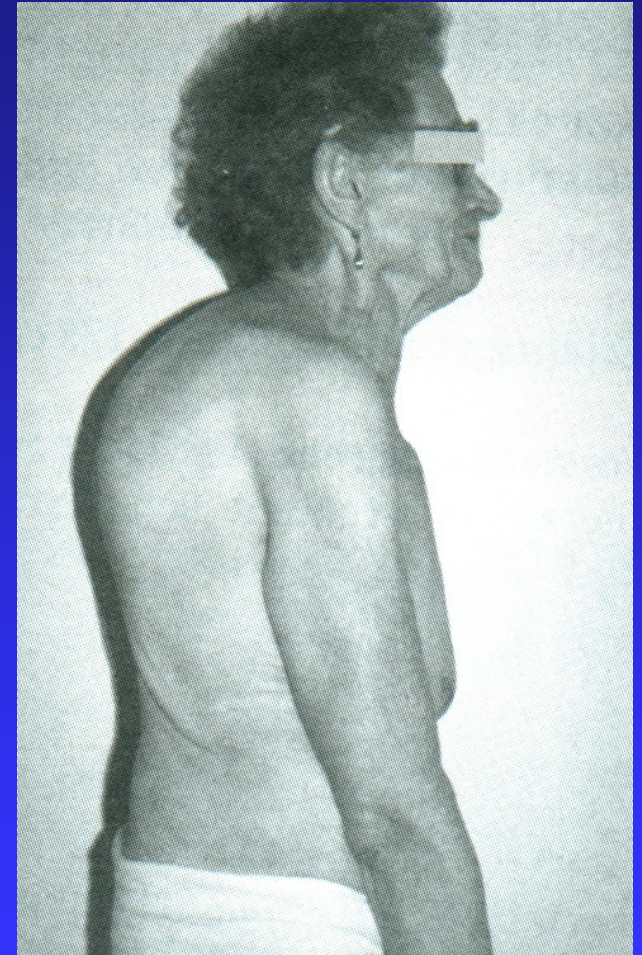- Before menopause 0,3 % / year
- After menopause 3 % / year

Osteoporosis

- primary:
 - idiopathic
 - postmenopausal - type I.
 - involutional (senile) - type II.
- secondary - type III.

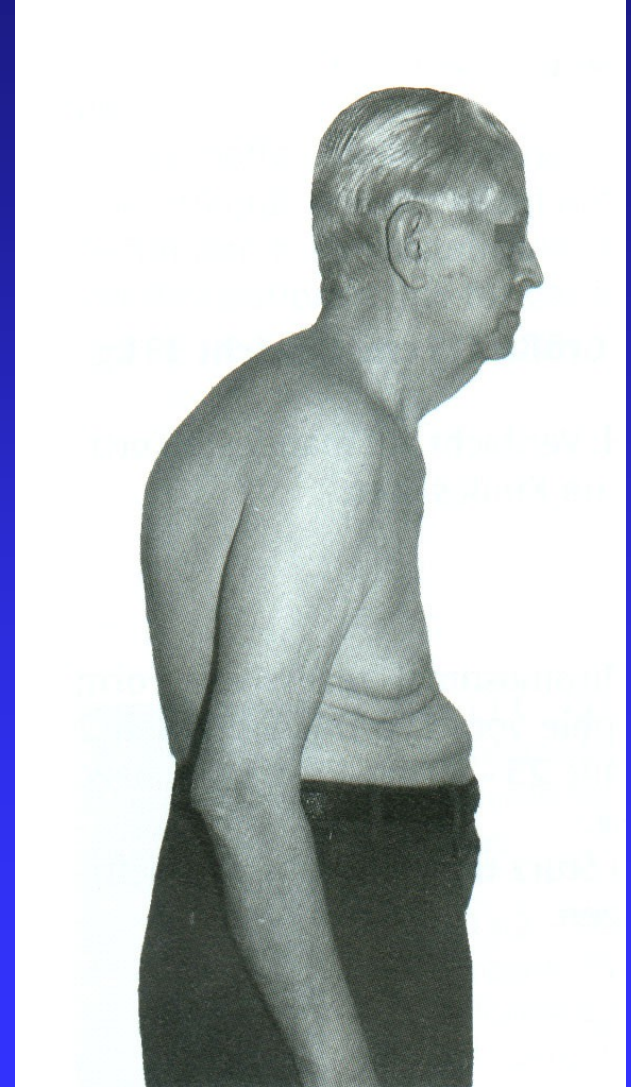
Clinical symptoms

- Back ache
- Diminished ability to work
- Problems with walking and standing
- Problems with lifting heavy objects
- Sharp pain- in a case of fracture

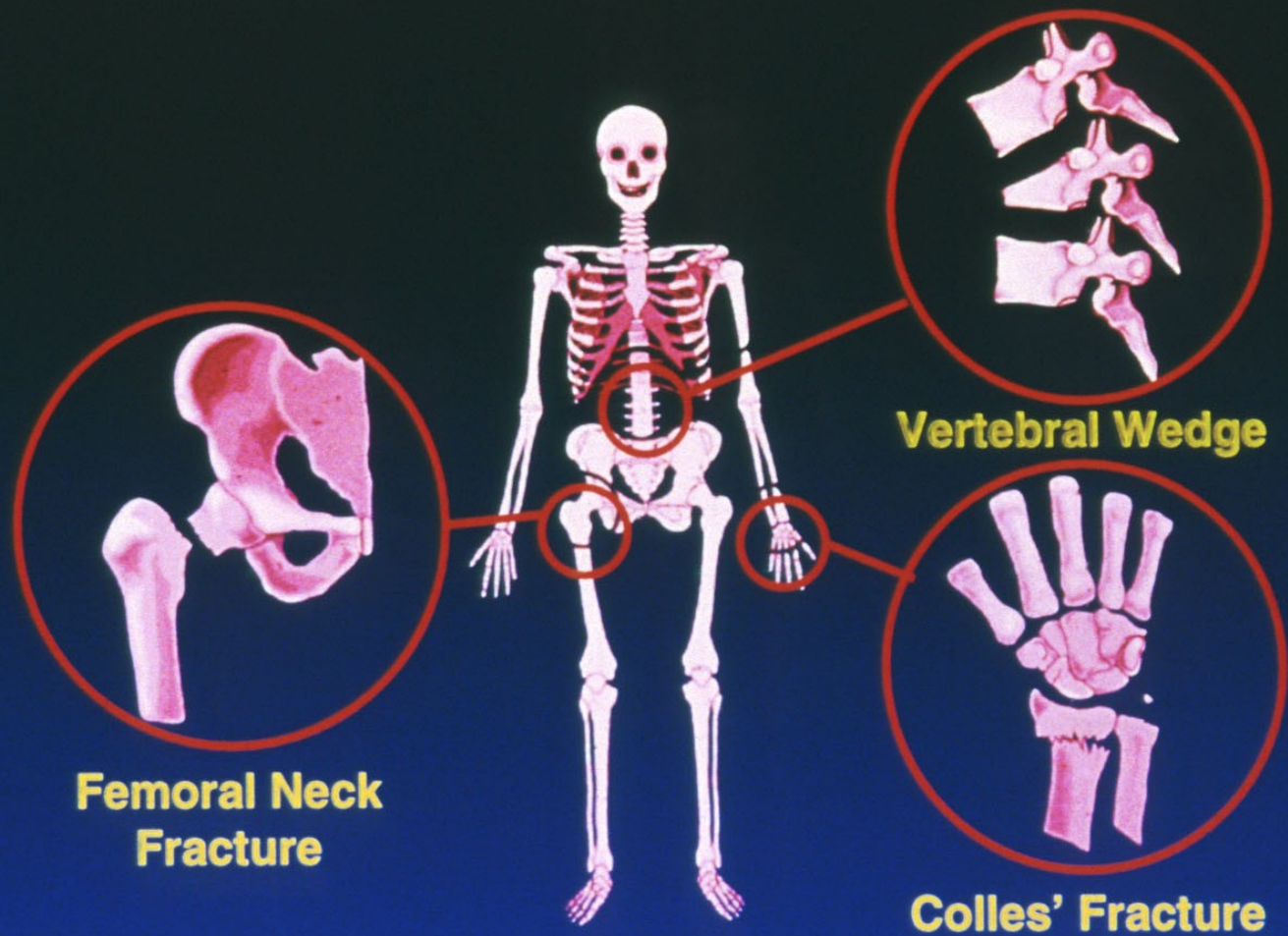


Examination

- Tenderness on spinous process
- Limited movements of the spine
- Paravertebral spasm
- Thoracic kyphosis
- Widow's hump
- Lower length of the stature



THE COMMON FRACTURES OF OSTEOPOROSIS



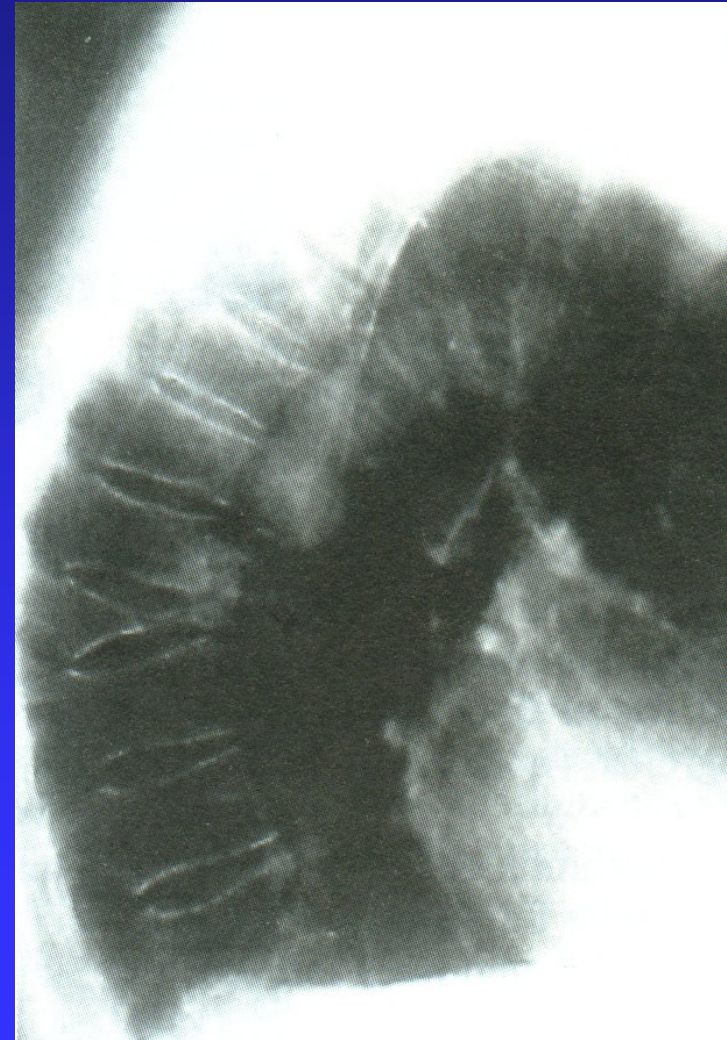
**Femoral Neck
Fracture**

Vertebral Wedge

Colles' Fracture

Imaging techniques

- X- ray shows bone loss of 30 % or more
- DEXA
- QCT
- Ultrasonography



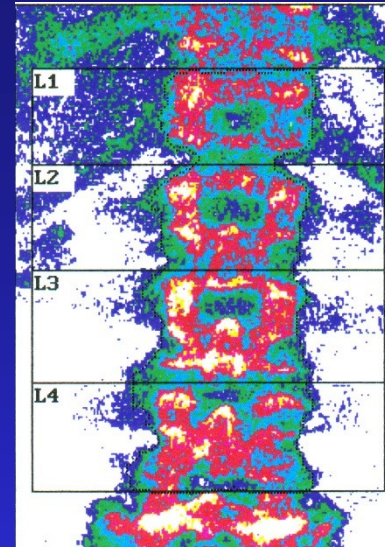
DEXA – Dual Energy Absorptiometry

BMD in g/cm^2

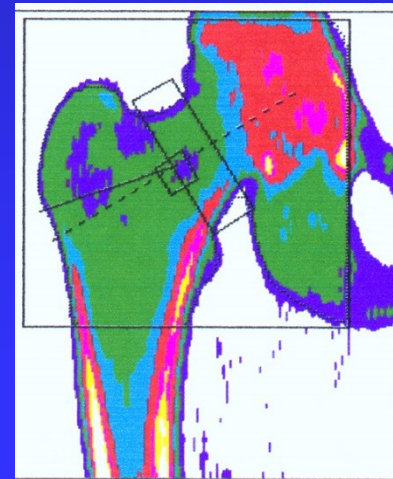
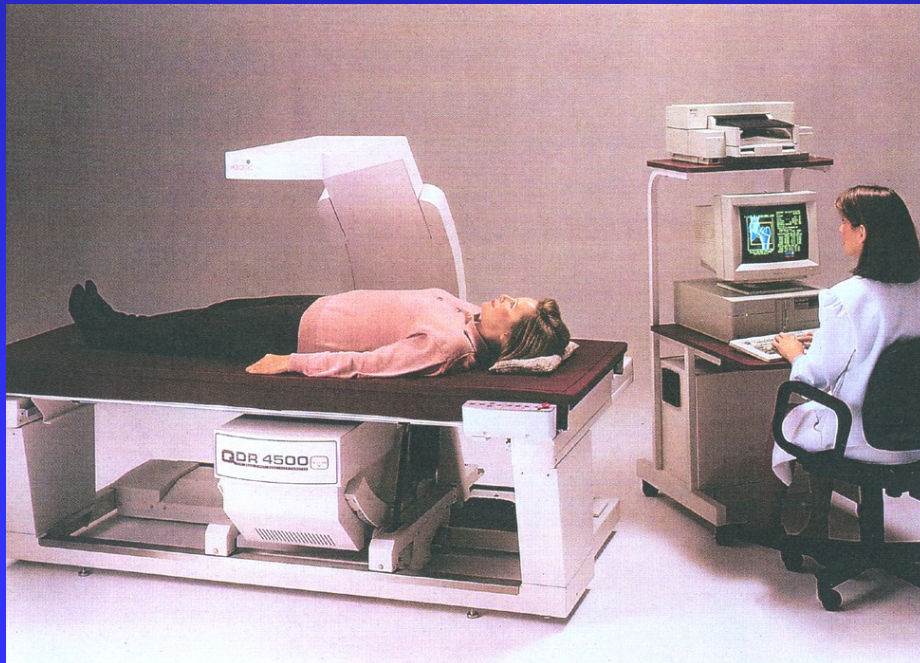
T score

Z score

Change



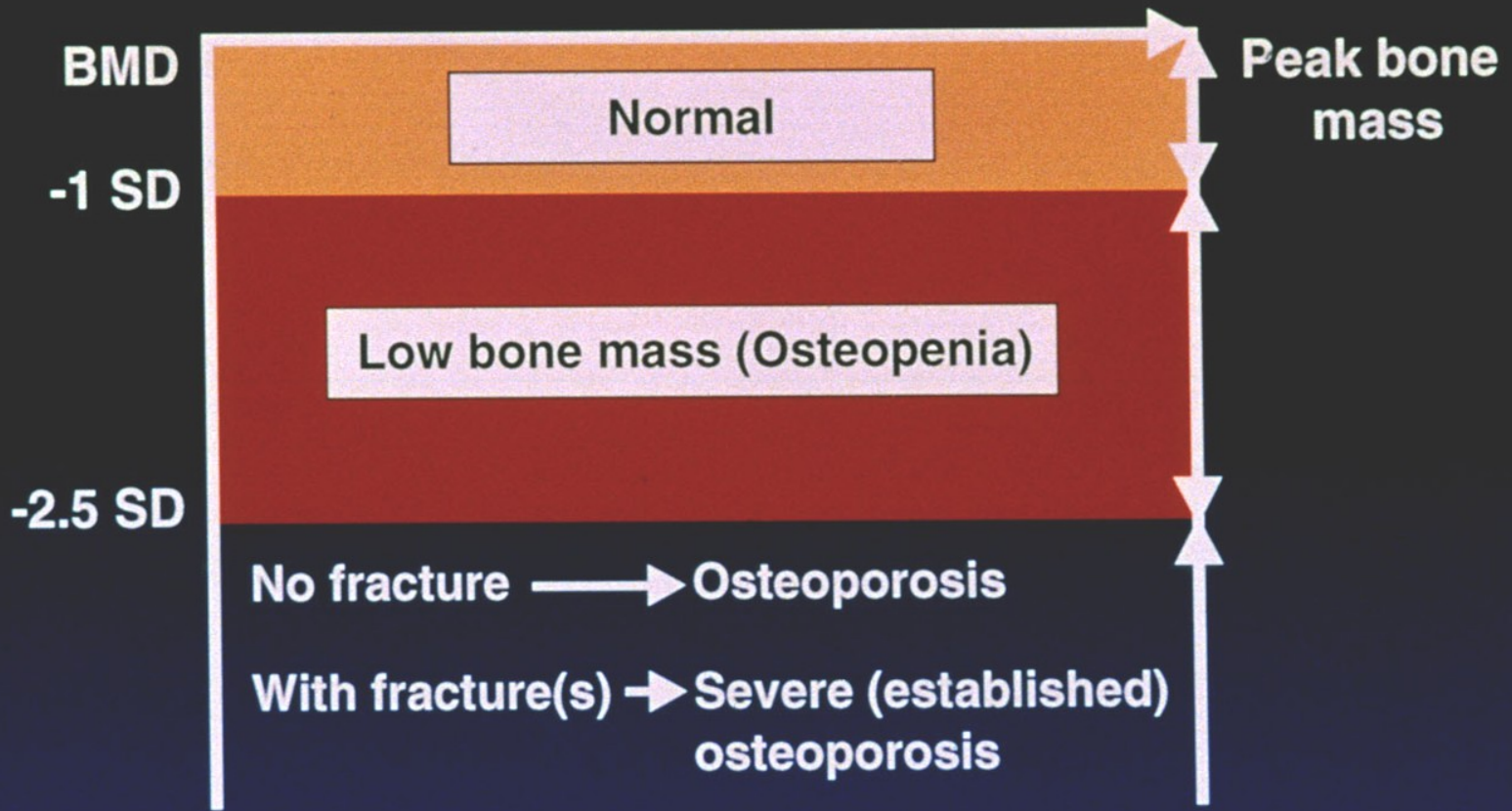
L1-L4



Hip Total

Hip neck

WHO DEFINITION OF OSTEOPOROSIS



Postmenopausal osteoporosis

- 80% of all cases
- 25 % of female are involved
- Between 50- 65 years
- Loss of estrogens- high activity of osteoclasts
- Trabecular bone most often affected

Senile osteoporosis

Over 70 years, ratio female: male = 2 : 1

The cause: no production of osteoblasts in bone marrow

Cortical and trabecular bone



Secondary osteoporosis

- Corticosteroids
- Hyperthyreosis
- Malabsorption
- Alcoholisms
- After trnsplantations

Osteoporosis in men

- Primary
- Hypogonadism

Risk factors

- Low stature
- White and yellow ethnics
- Low physical activity
- Low nutrition with calcium

Risk factors

- Higher age
- Low BMI
- Occurrence in family

Hypogonadal conditions

- premature amenorrhoea
- surgery of ovaria
- oligomenorrhoea, amenorrhoea
- nullipara
- low endogen estrogen
- mental anorexia

Risk factors- drugs

- corticosteroids
- anticonvulsives
- diuretics
- heparin

Risk factors

- malabsorption
- chronic disorders of liver
- chronic disorders of kidney
- alcohol

Prevention of osteoporosis

- Maximal peak bone mass
- Management of disorders in children
- Removal of risk factors
- Management of gastrointestinal disorders
- Nutrition with calcium and vitamin D
- Physical activity

Management

Analgetics

Physiotherapy

Nutrition (proteins, calcium)

Calcium - 1300 mg/day

Vitamin D - 800 I.U./day

Drugs

Orthesis

Surgery



Nutrition

BMI 23-25

Proteins 1,0 g/kg/day

+ 30g of proteins /day

IGF-1 – insulin like growth factor

Calcium

1,5 g / day

Application in the evening

Calcium

- Calcium eff. Pharmavit 500, 1000 mg
- Calcium Sandoz forte 500 mg eff.
- Calcium Slovakofarma eff.
- Maxi-Kalz eff tbl, 100, 500 mg.
- Vitacalcin pulvis, tablety
- Biomin H plv.- Ca, Mg + IGF-1.



Calcium

- Kombi-Kalz pulv, 1000Ca+ 880 IU vit D.
- Osteocare tbl.
- Caltrate plus tbl
- Calcium 500 + vit D3 eff.
- Calcium D forte cps
- Calcicew



Vitamin D

7-dihydrocholesterol

In the skin -UV beams -cholecalciferol

In liver conversion to 25-OH vit. D3

In kidneys conversion to 1,25 dihydroxy-vit. D3

Active agent is calcitriol 1,25 (OH) D3.

80-90% of daily use is covered by sun radiation

Vitamin D

60 % of seniors have hypovitaminosis of vitamin D

Optimal level in blood is 80 nmol/l

Hypovitaminosis - below 20 nmol/l

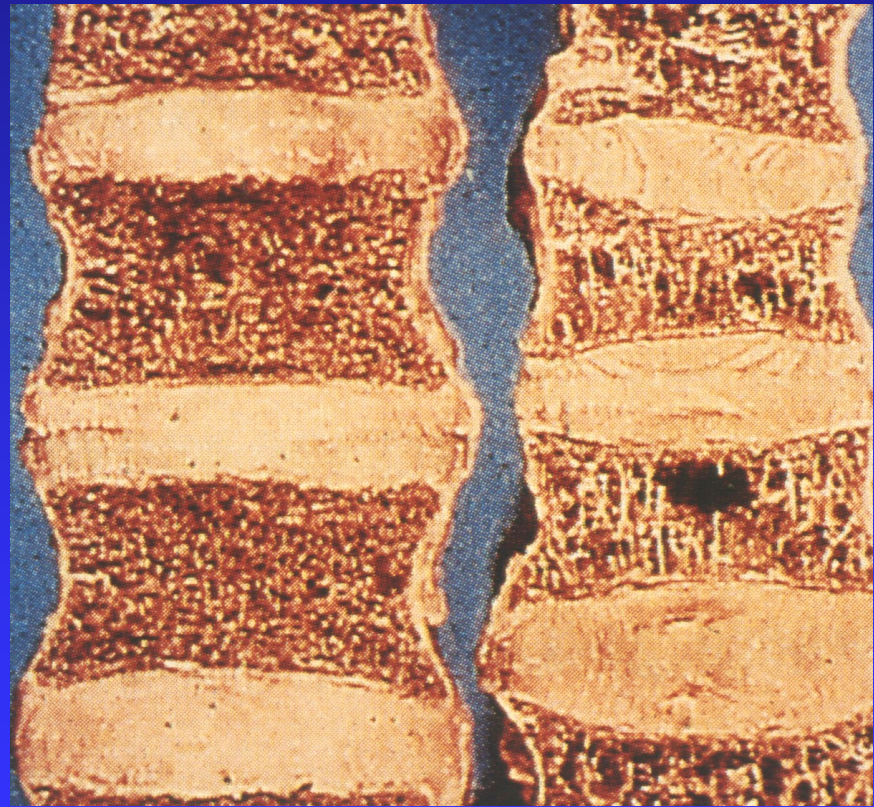
Dosage: 800 IU/day

Vitamin D

- Infadin gtt, vit D cps., Vigantol oel, gtt
- Rocaltrol cps, Vitamín D Slovakofarma cps
- Calciferol inj.
- 1 alfa (OH) D3 – alfakalcidol - Alpha D3
- 1 alfa (OH) D2 – doxercalciferol (Hectorol)
- 22 oxakalcitriol (OCT)
- 19 nor 1,25 (OH)₂ D2 – parikalcitriol (Zemplar)

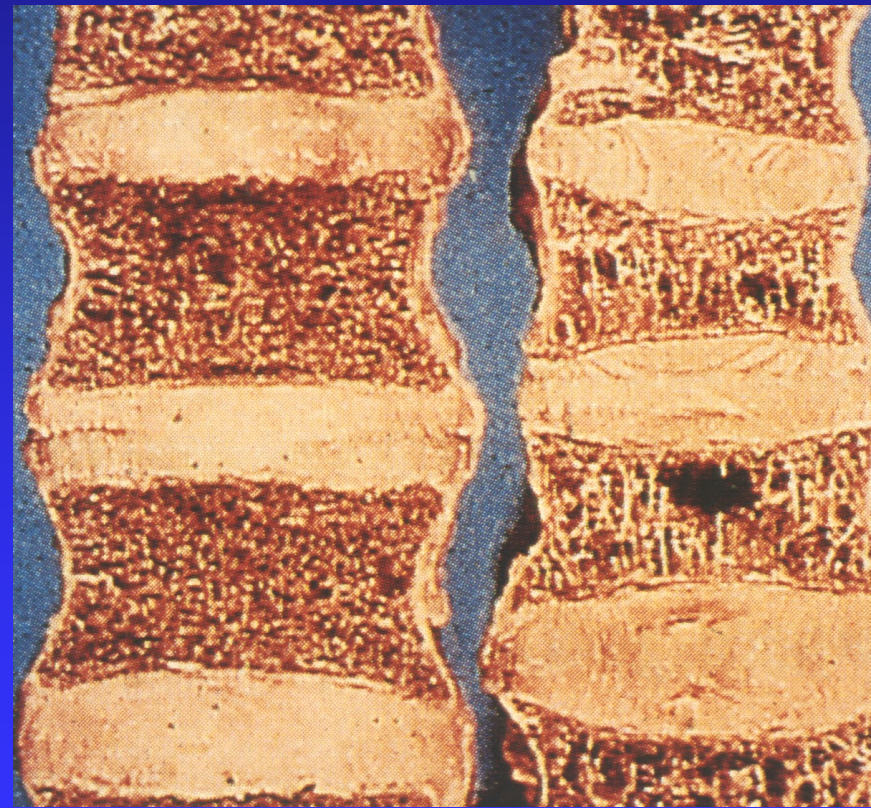
Inhibition of bone resorption

- Bisphosphonates
- SERM
- Stroncium ranelate
- Calcium



Stimulation of bone formation

- Vitamin D
- Anabolics
- Teriparatid
- Stroncium ranelate



HRT

no evidence of effect

Livial®

tibolone

**The tissue-specific therapy with
an estrogenic effect on bone¹**

enhances mood and
libido^{5, 6}

treats climacteric
symptoms⁷

no proliferation of
breast cells (*in vitro*)⁸

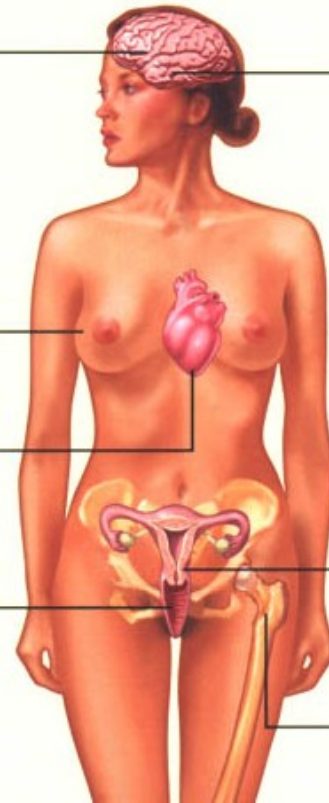
low incidence of
side effects
(eg breast tension)⁹

beneficial effects on the
cardiovascular system¹⁰

treats vaginal atrophy¹²

no endometrial
stimulation¹¹

prevents postmenopausal
bone loss⁴




Bisphosphonates

Incorporation in HA
crystals and matrix

Inhibition of formation,
agregation and
dissolution of crystals

Inhibition of bone
resorption



Fosamax

Bisphosphonates

- Reduction of activity of osteoclasts
- Induction of apoptosis of osteoclasts

Bisphosphonates - indications

Osteoporotic fractures

All forms of osteoporosis

Paget 's disease of bone

Hypercalcemia in carcinomas od myeloma

Bisphosphonates

Pamidronate - Aredia inj.

Clodronate – Bonefos inj, cps., Lodronat inj, cps.

Ibandronate – Bonviva tbl., Bondronate inj.

Alendronate – Fosamax 70 mg tbl., Alendros tbl.

Risedronate - Actonel tbl.

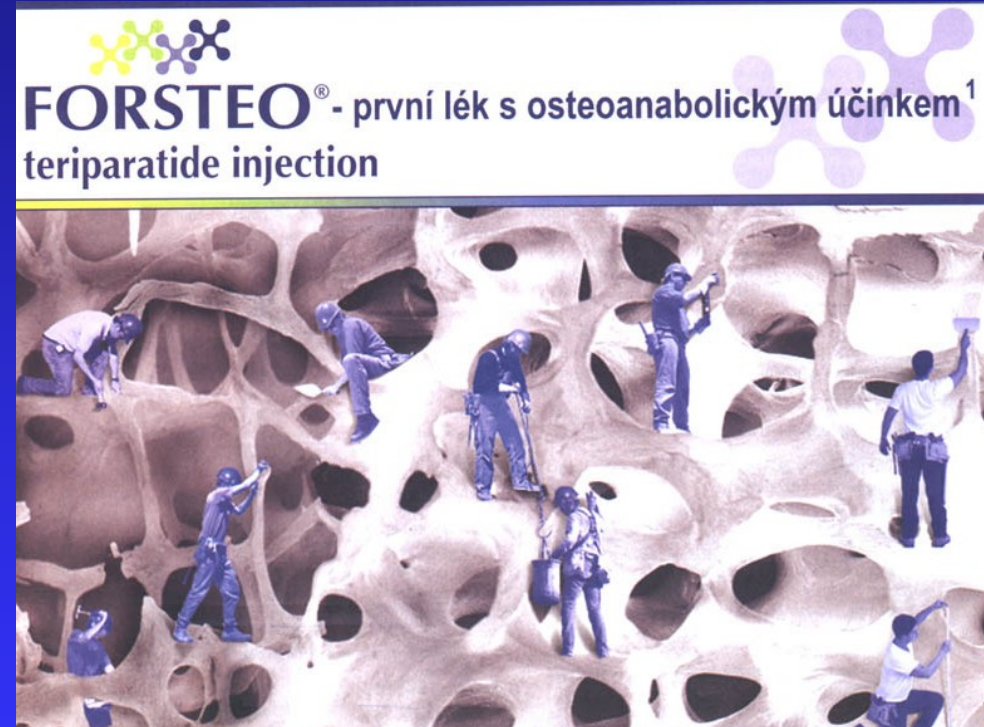
Zoledronate – Aclasta inj.

SERM - selective modulators of estrogen receptors

- Raloxifen (Evista)
- Agonists on bone and cardiovascular apparatus
- Antagonists on endometrium and breast
- They bind on the same place as estrogens (receptors α , β)

Teriparatid – synthetic parathormon 1- 34 fragment

Stimulates bone formation
Stimulates osteoblasts
and remodeling
Improves the strength
of trabecular and cortical
bone



Differential diagnosis

Osteoporosis with corticosteroids

Condition after transplantations

Cushing syndrom

Hyperthyreosis

Rheumatoid arthritis

Osteogenesis imperfecta

Fibrous osseous dysplasia

Osteomyelitis

Myeloma, tumors, osteolytic metastasis

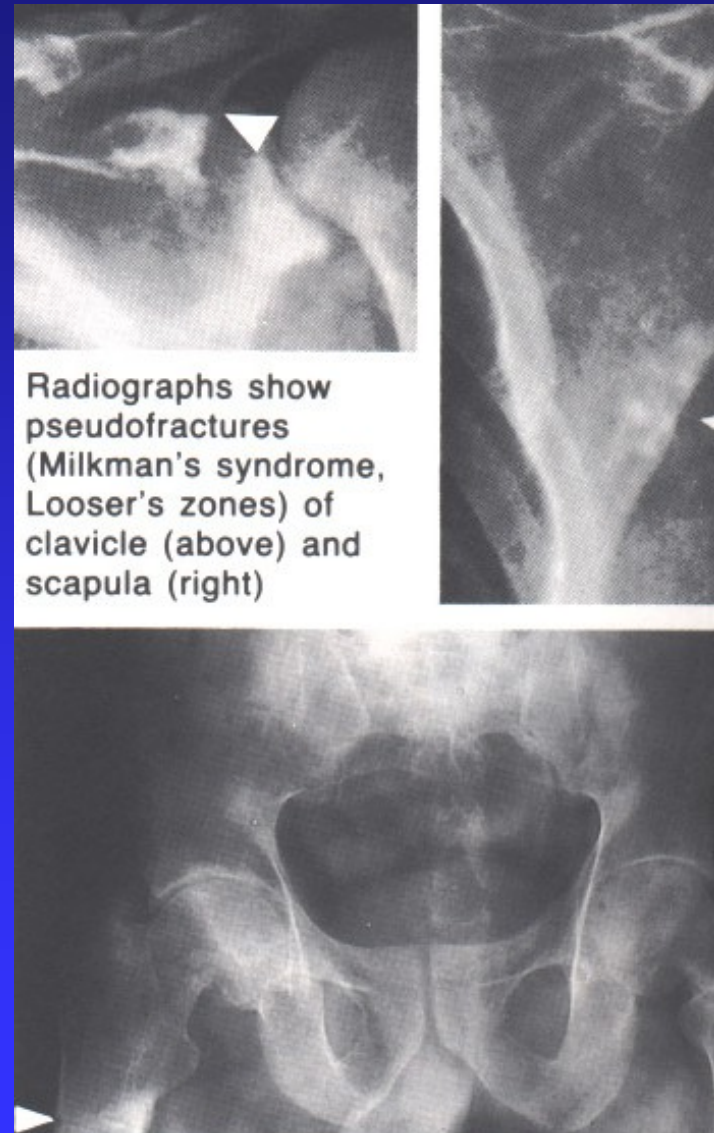
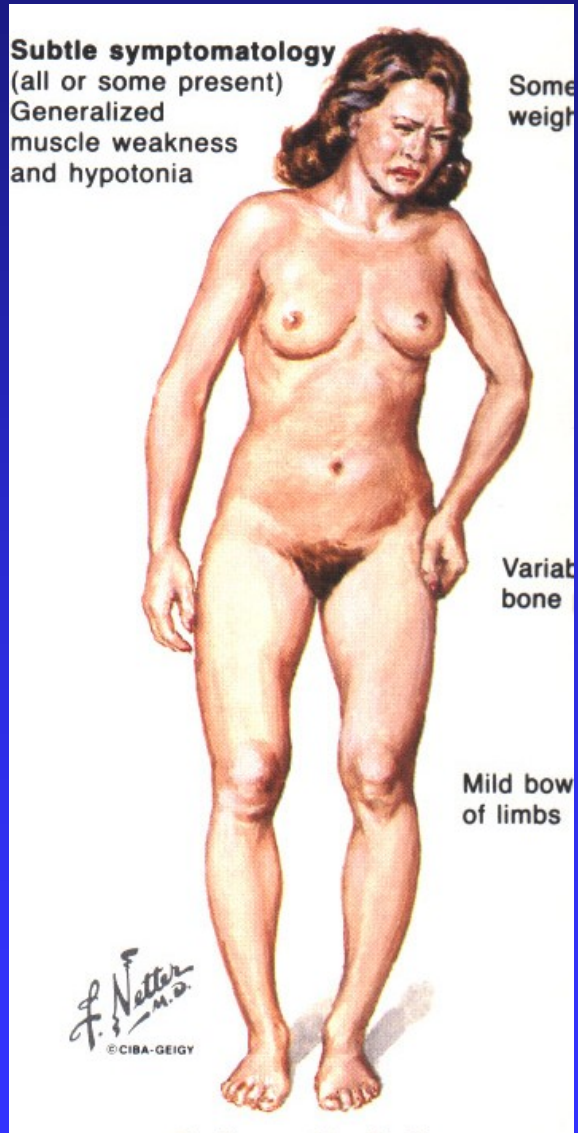
Malnutrition

Algoneurodystrophy

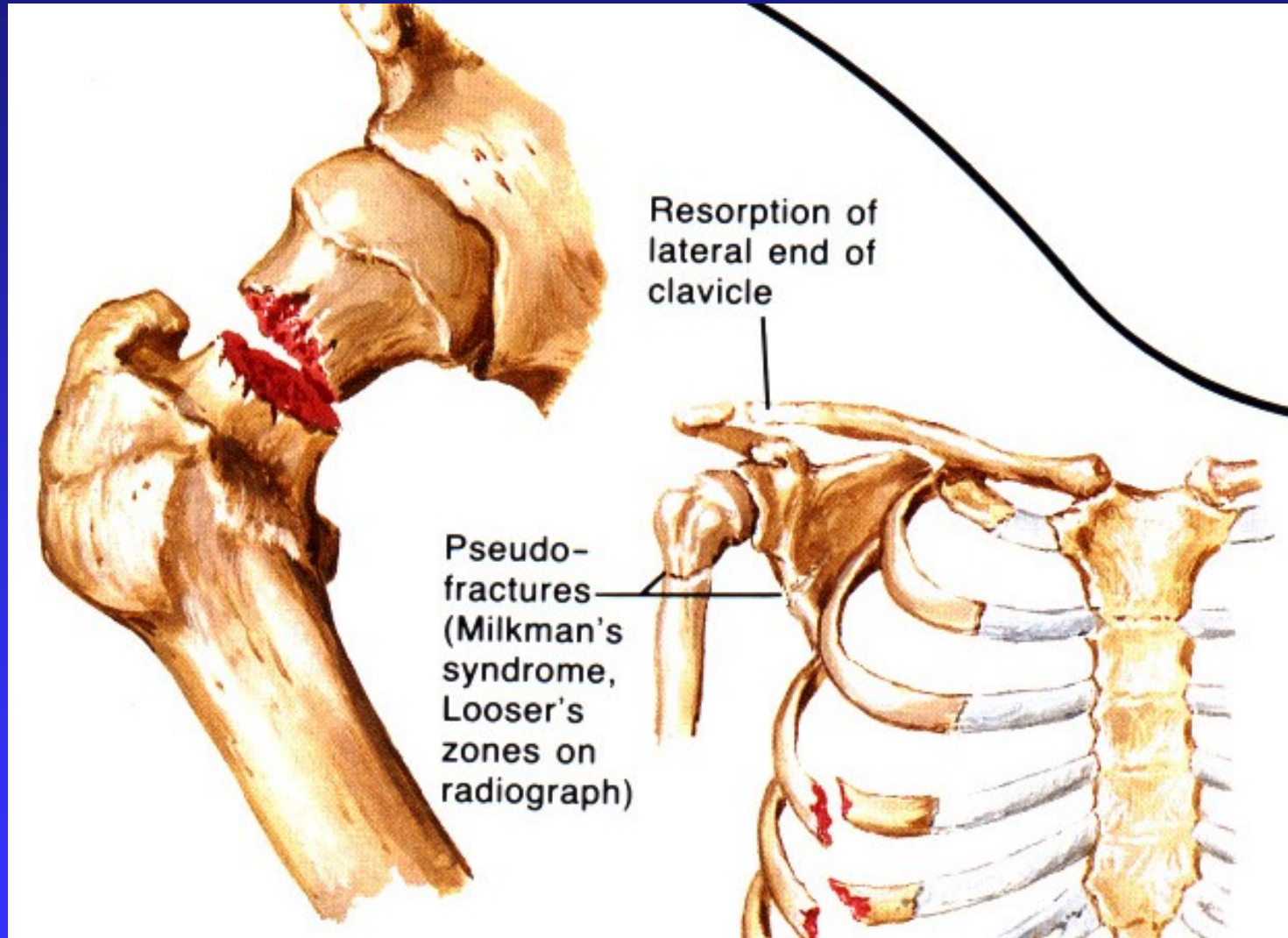
Osteomalatia

- Systemic disorders in adults
- Bone is in a form of nonmineralised osteoid
- Calcium is not layed in HA crystals
- Bone is soft
- The cause: lack of vitamin D

Osteomalatia



Osteomalatia



Symptoms

- Diffuse pain in skeleton
- Muscle weakness
- Tenderness of bones
- Deformities of bones
- Thoracic kyphosis

Laboratory tests

- High level of alkaline phosphatase
- High level of bone isoenzyme of ALP
- Low level of calcium
- Normal level of phosphorus

Radiological finding

Rarefaction of skeleton

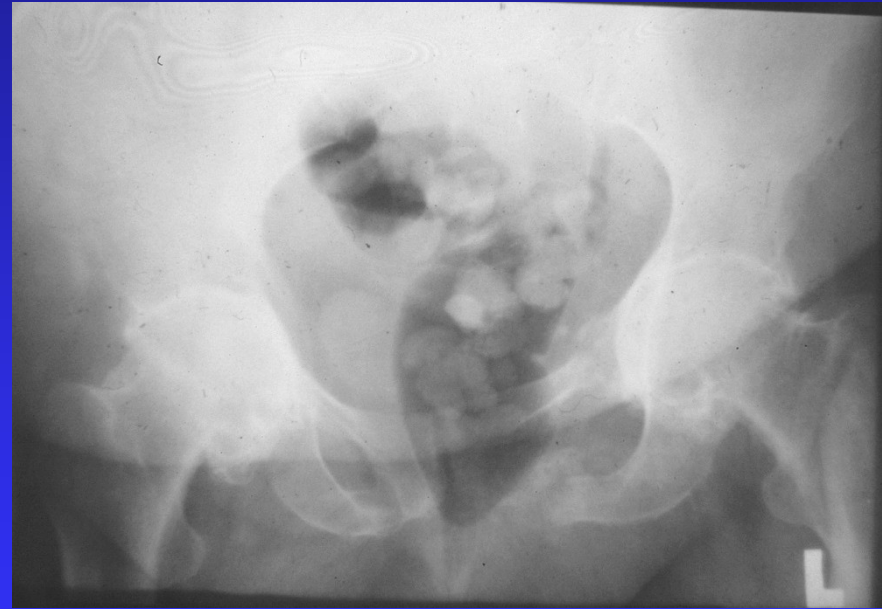Narrow cortical bone

Looser's zone of remodelling
- non mineralised osteoid

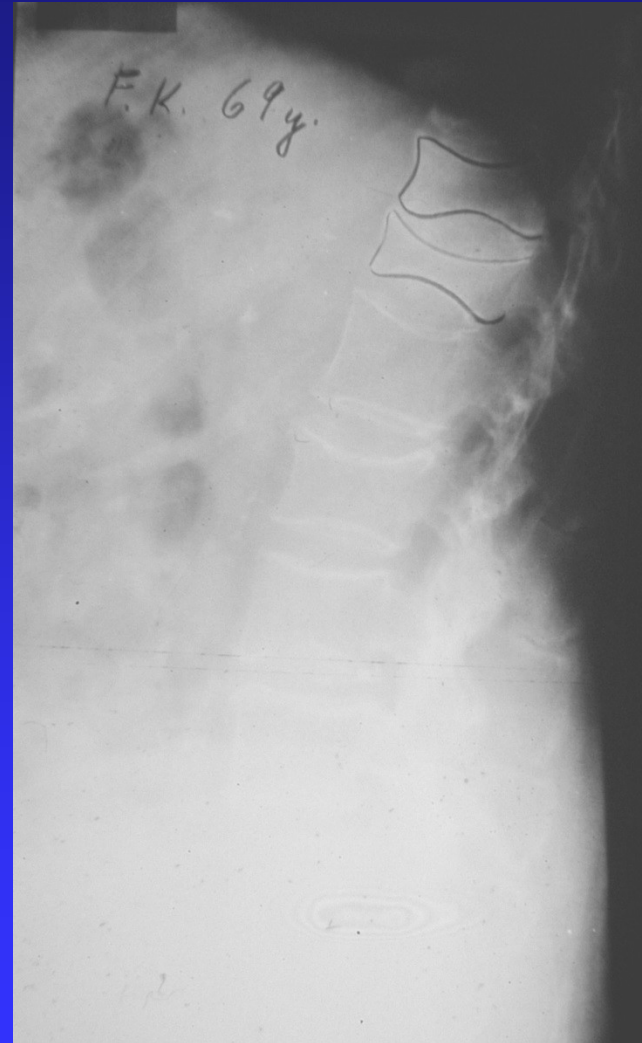
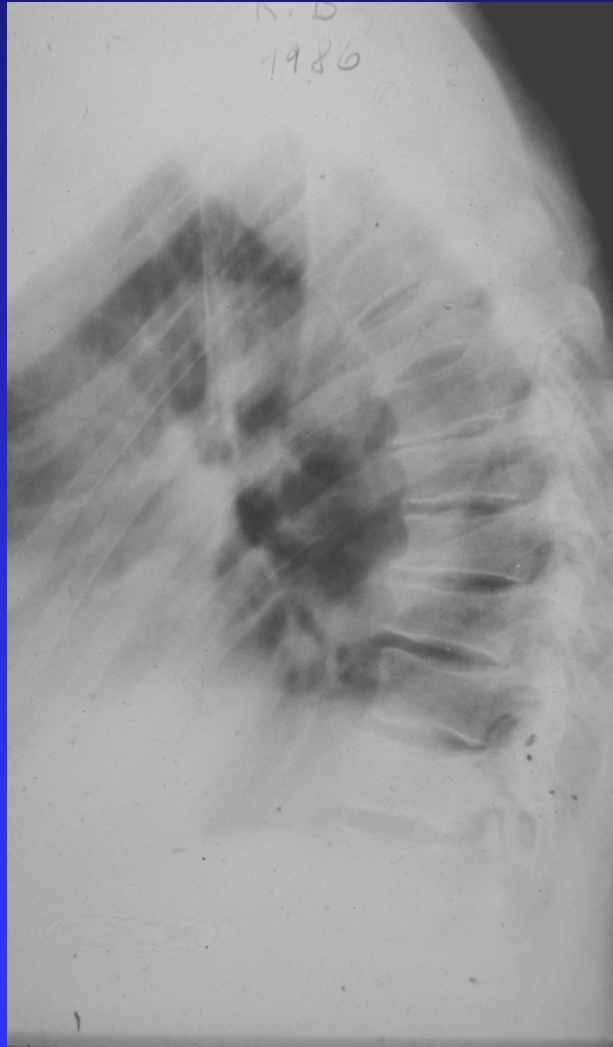
Biconcave shape of vertebrae
coxa vara

Protrusion of acetabulum

Thoracic hyperkyphosis



Osteomalatia



Prevention

- Vitamin D - sun radiation and in food
- Application of vitamin D in renal and liver disorders

Therapy

- Vit. D 10 000 IU per day i.m.
- Calciferol inj.
- Vit. D p.os 2000 IU daily
- Calcium 1000 - 2000 IU daily
- Food with milk, sea fish

Rickets

1. Lack of vitamin D
2. Lack of phosphates

Inability to calcify of matrix

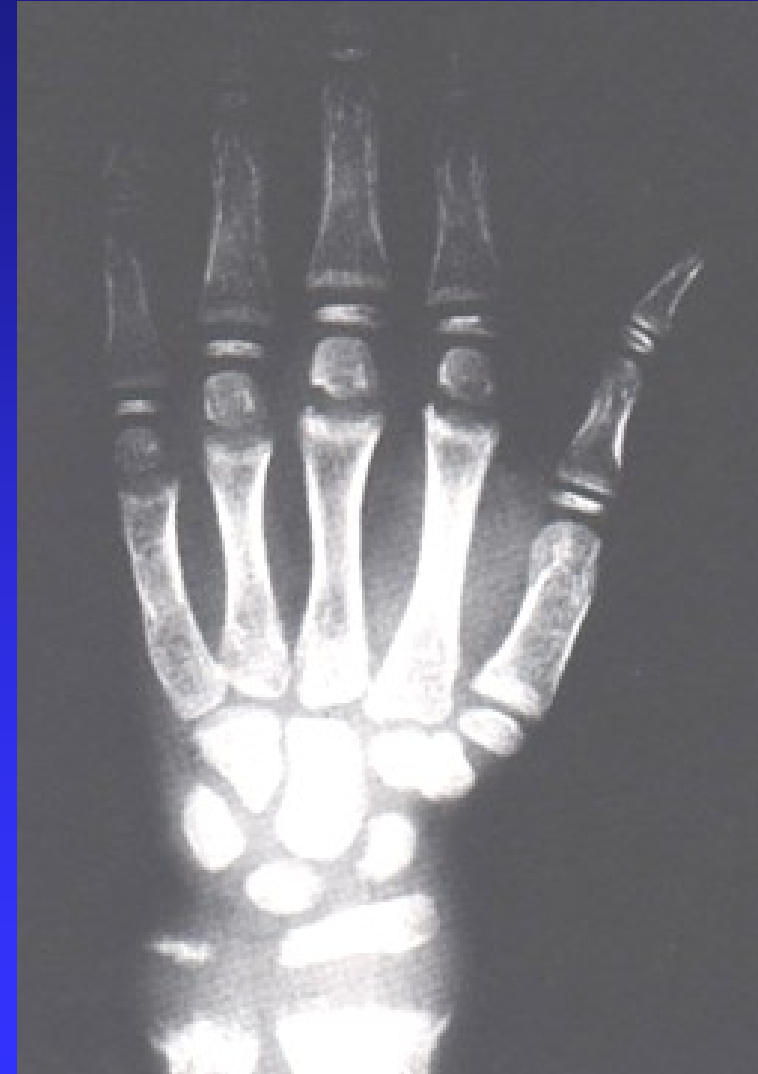Bone is soft

Bending of bone

Wide growth plates

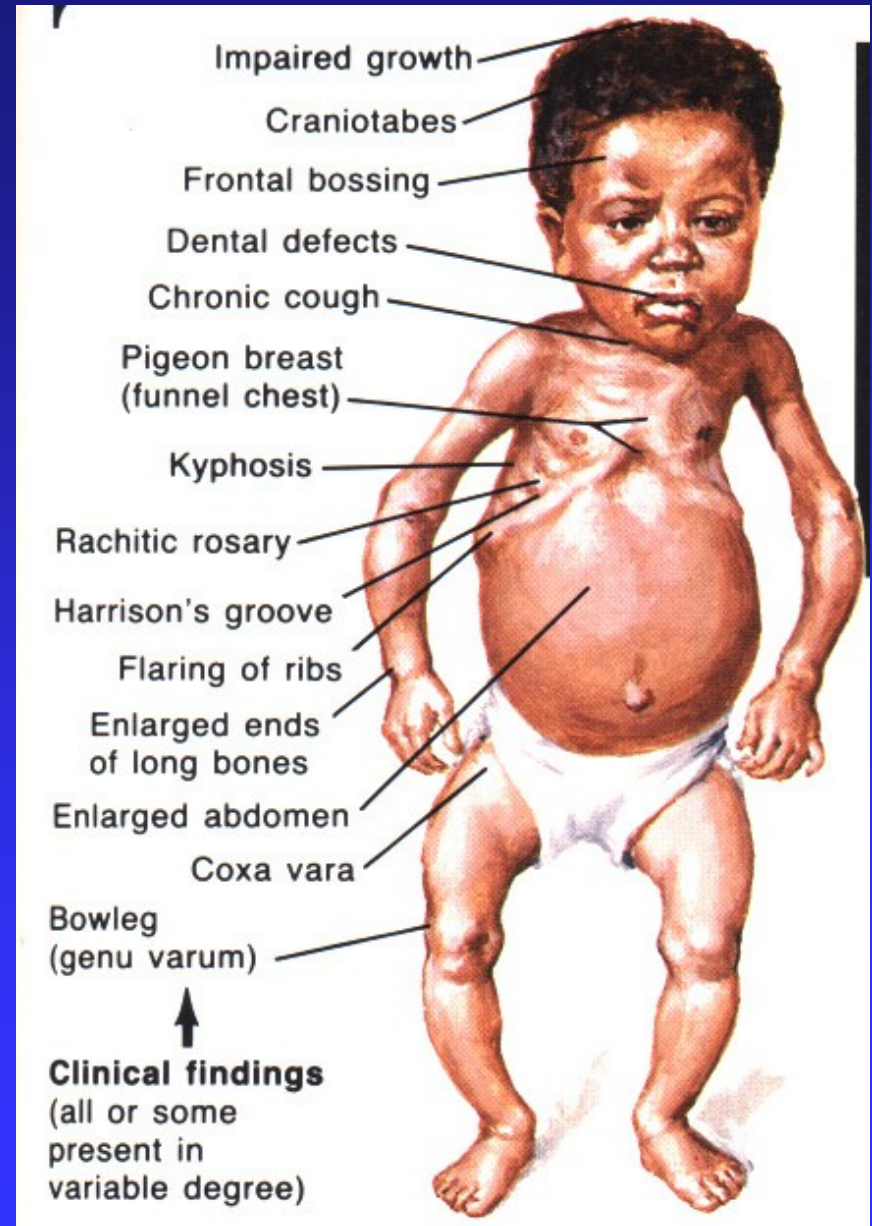
Metaphysis is wide

Deformities of bones



Rickets

- Fatigue
- Enlargement of abdomen
- Walking ability - worsened
- Craniotabes
- Large fontanels
- Dentic disturbances
- Caput quadratum
- Harrison's groove
- Rachitic rosary
- Pectus carinatum
- Crura et coxa vara
- Pedes plani



Management

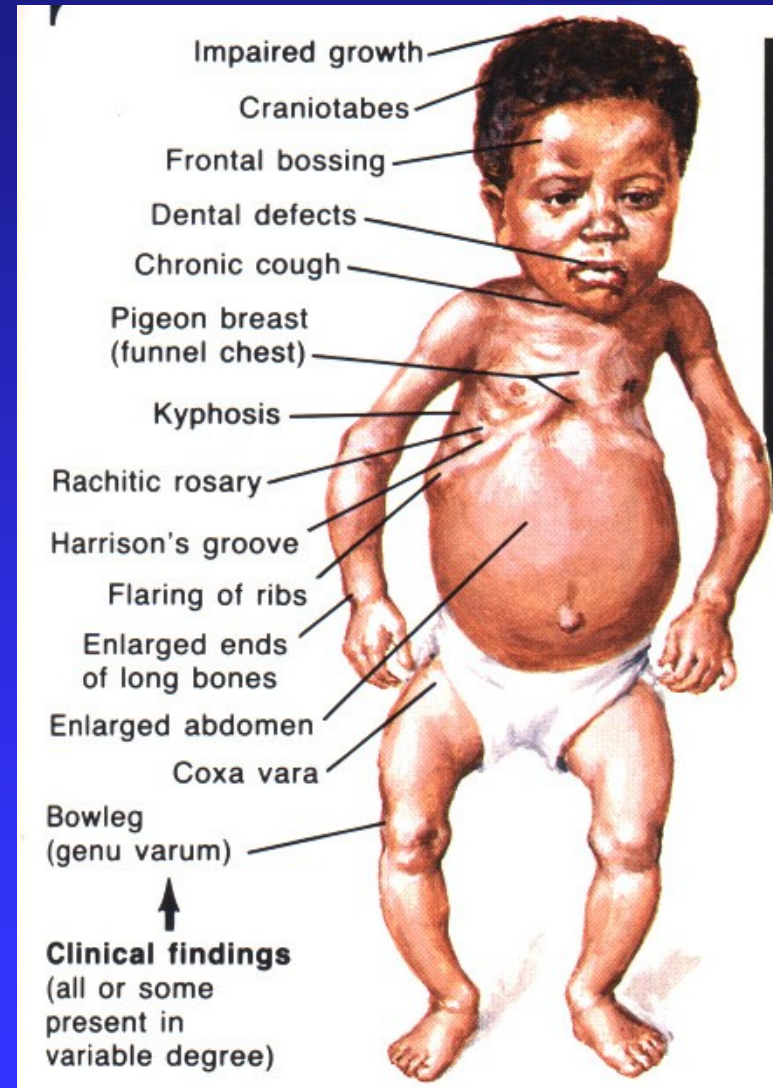
Vitamin D 500- 1000 IU/day 10 weeks

Sun radiation

Milk products with vitamin D

Orthosis

Osteotomies

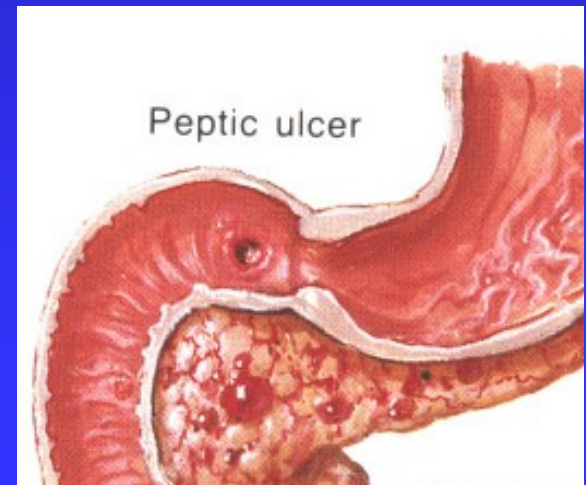
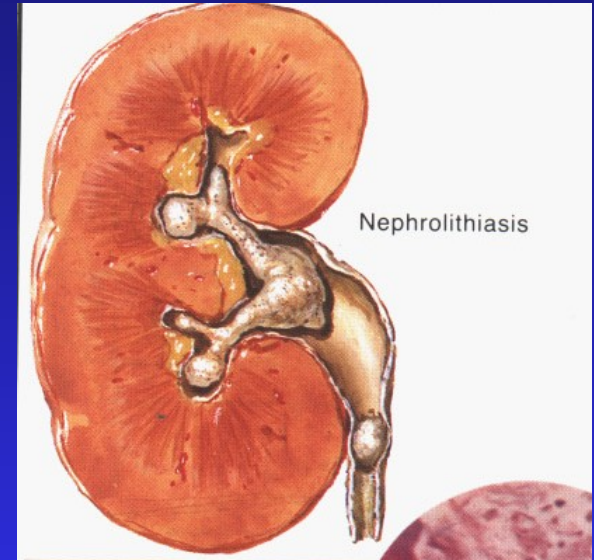


Hyperparathyreoidisms - HPT

- Adenoma of parathyroid glands
- Hyperplasia of parathyroid glands
- Carcinoma of parathyroid glands

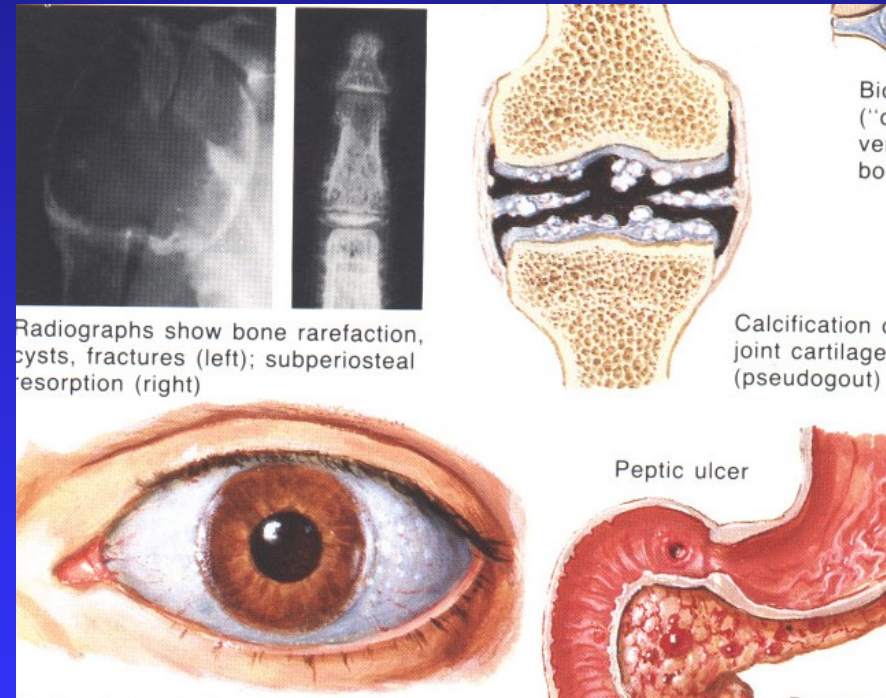
Primary HPT

- Nephrolithiasis, polyuria, polydypsia
- Osteodystrofia fibrosa cystica generalisata
- Gastrointestinal problems
- Acute pancreatitis, cholelithiasis
- Muscle weakness, fatigue, bone pain
- Chondrocalcosis, calcifications



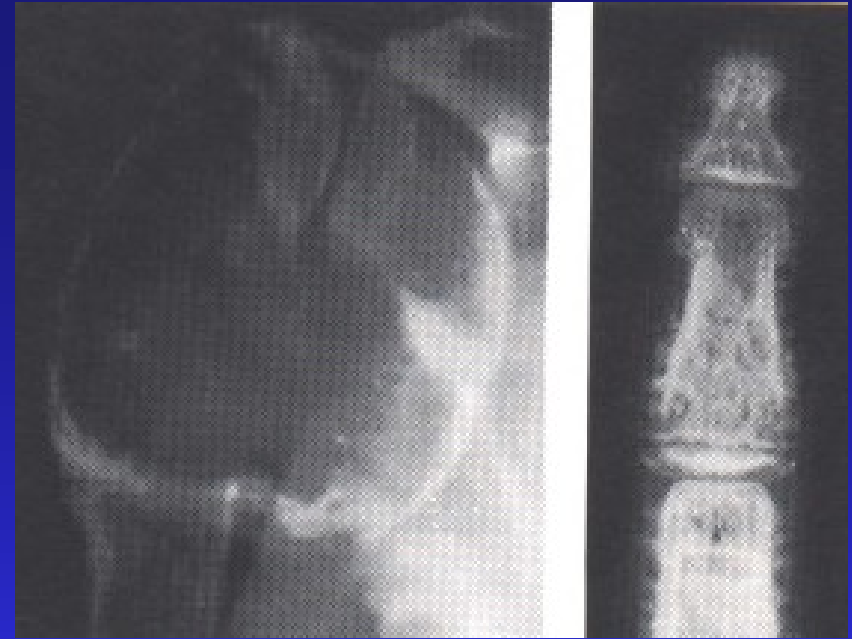
Primary HPT

- High level of calcium
- Hypofosfatemia
- Hyperfosfaturia
- High level of ALP
- High level of parathormon

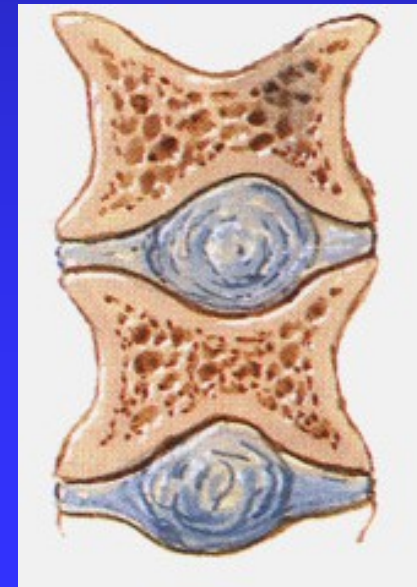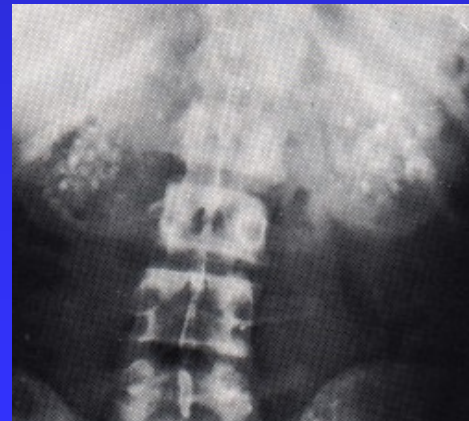


Radiological finding

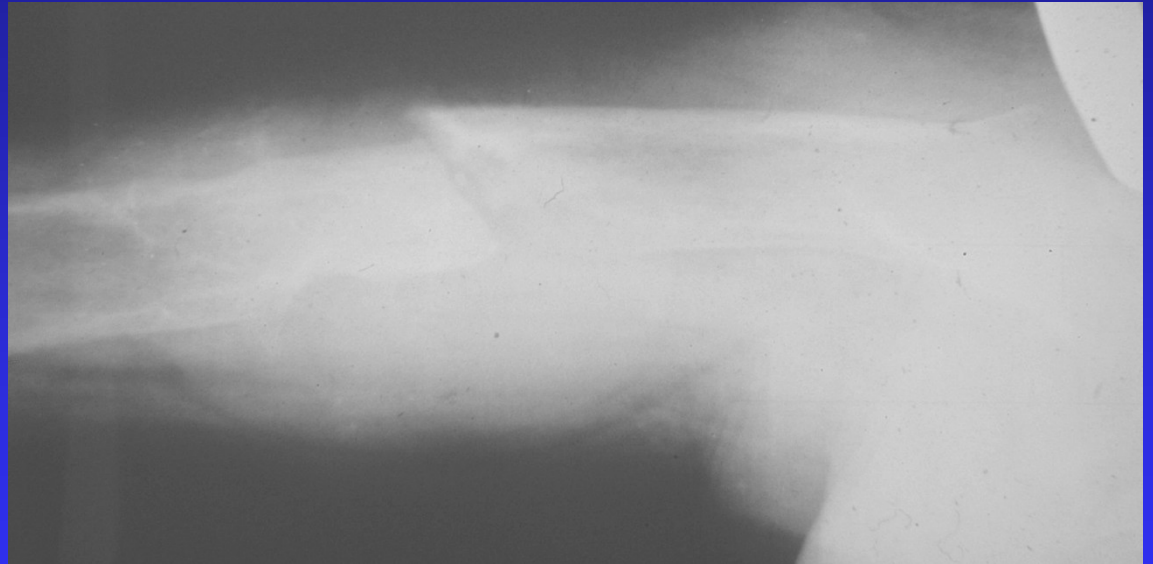
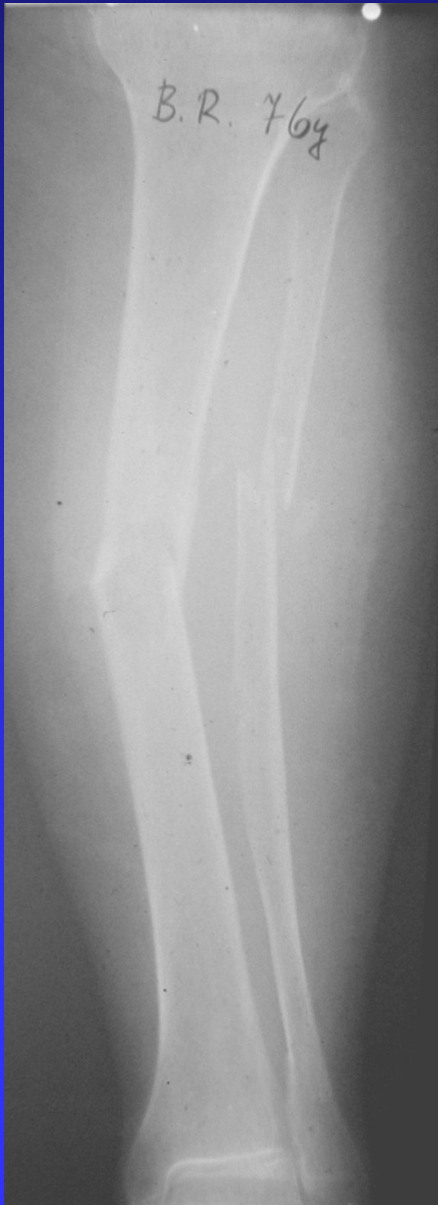- Rarefaction in skeleton
- Narrow corticalis bone
- Resorption in phalangs
- Large cysts as bone tumors



- Kyphosis
- Coxa vara
- Fisures and complete fractures



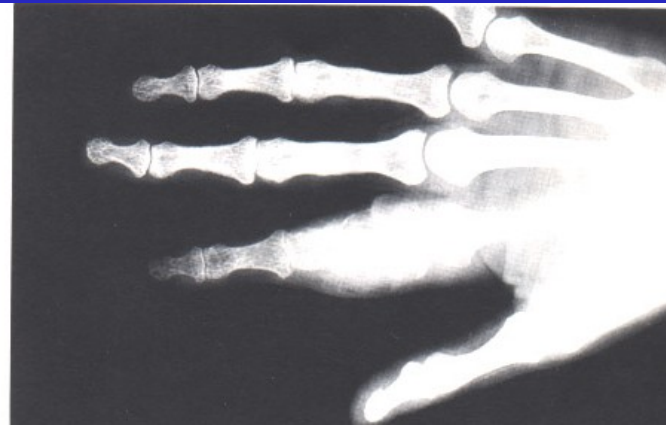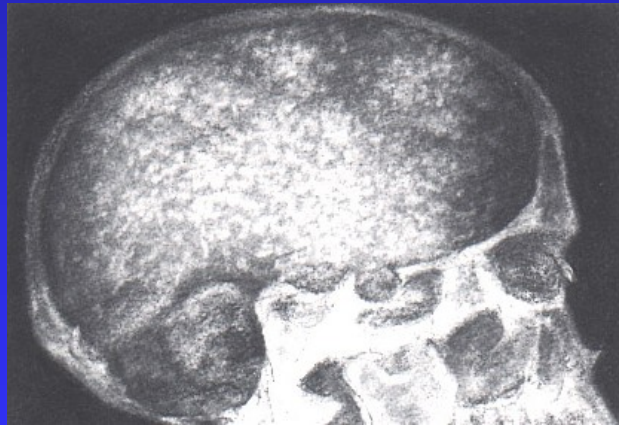
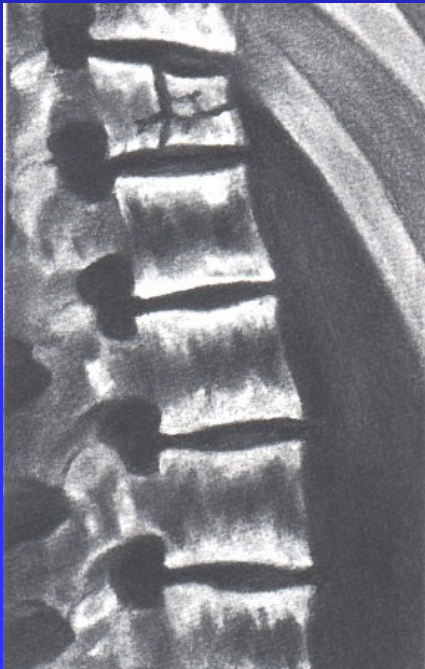Primary HPT



Renal osteodystrophy

- secondary HPT in renal disorders

Secondary hyperplasia of parathyroid glands



Renal osteodystrophy

Fatigue, bone pain

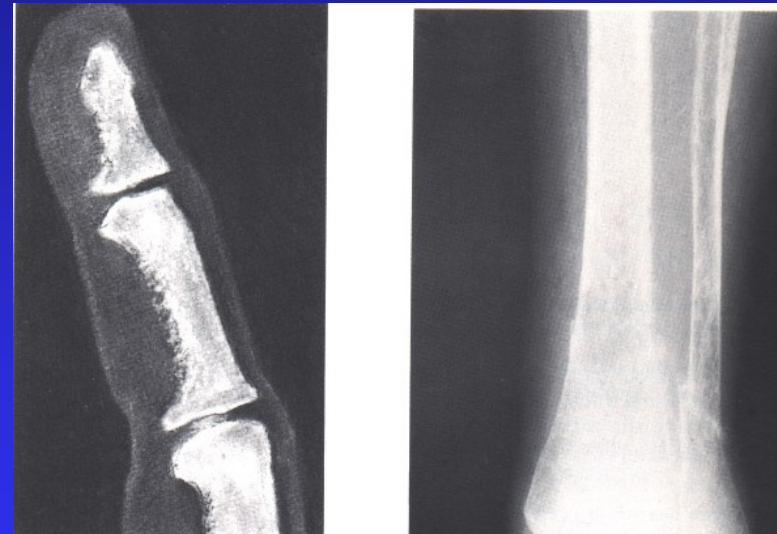
Muscle weakness

Fractures

Th: Treatment of renal disorders

vitamin D3

calcium



Secondary HPT

- Malabsorption of vitamin D

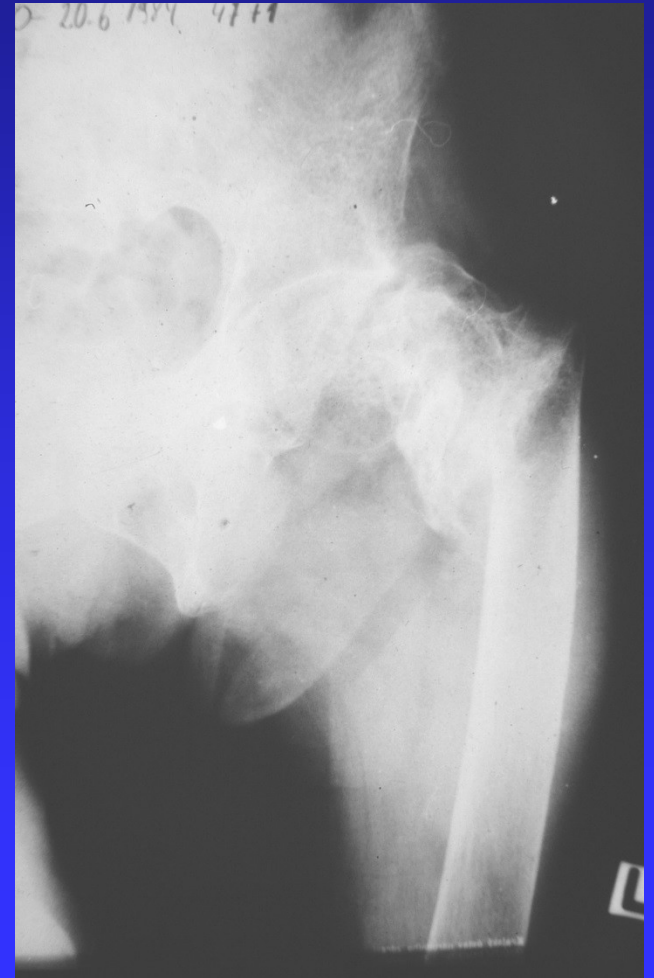
Resection of the stomach or intestine,
gall bladder problems, coeliakia,
pancreatitis

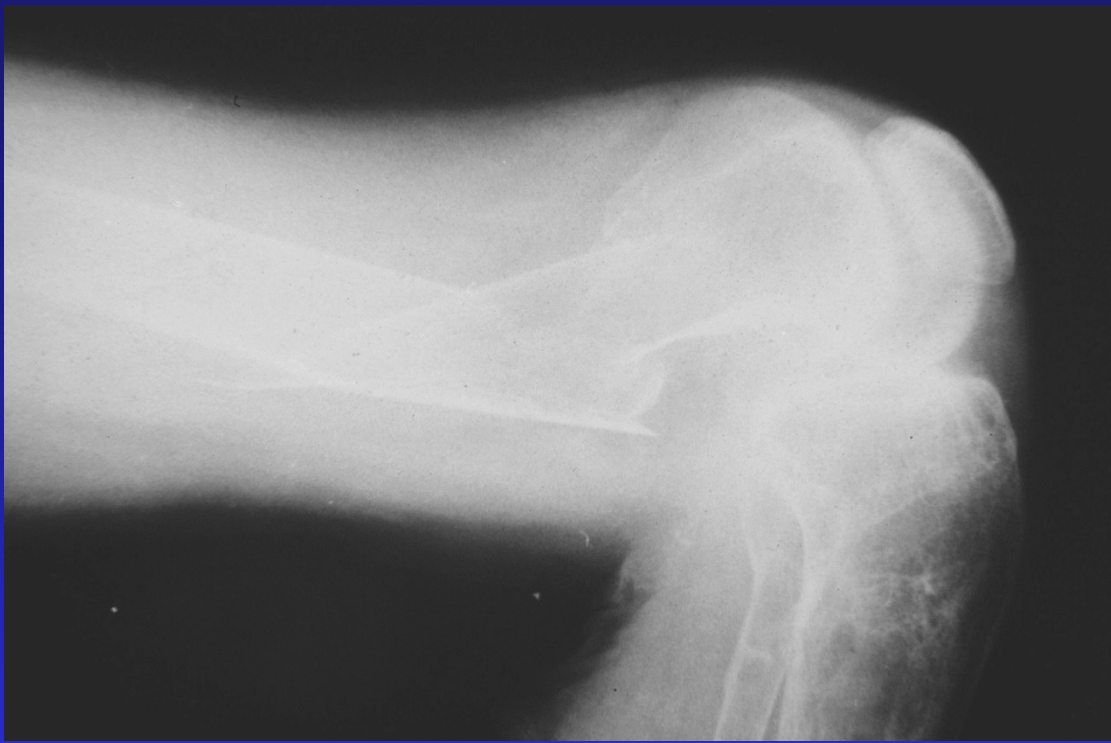
Pain in bones

Muscle weakness

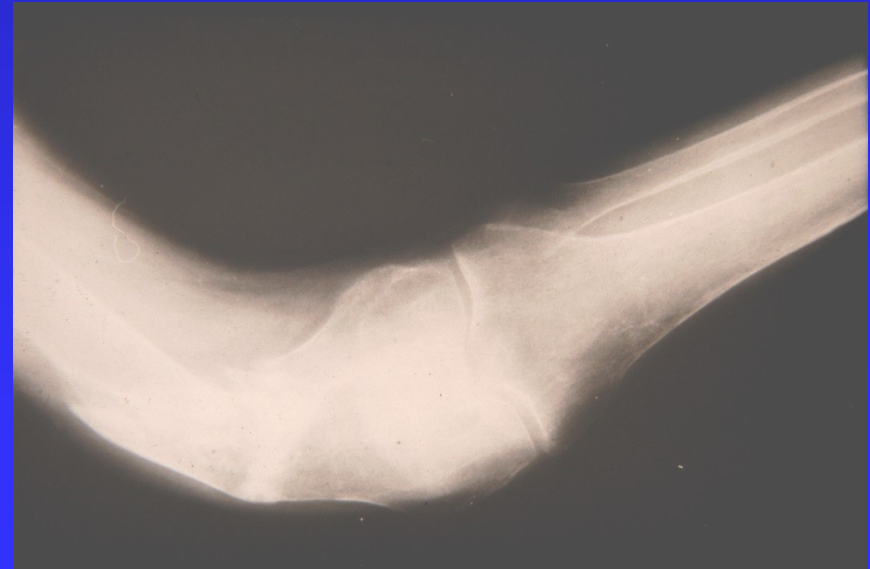
Pseudofractures

Deformities of bone





Secondary HPT
- malabsorption of vitamin D



Paget 's disease of bone

- Sir James Paget in 1876
- Chronic disease
- Slow viral infection (distemper virus from group of paramyxoviruses)
- GB, USA, Australia, New Zealand, France
Germany, Malta.

Morbus Paget

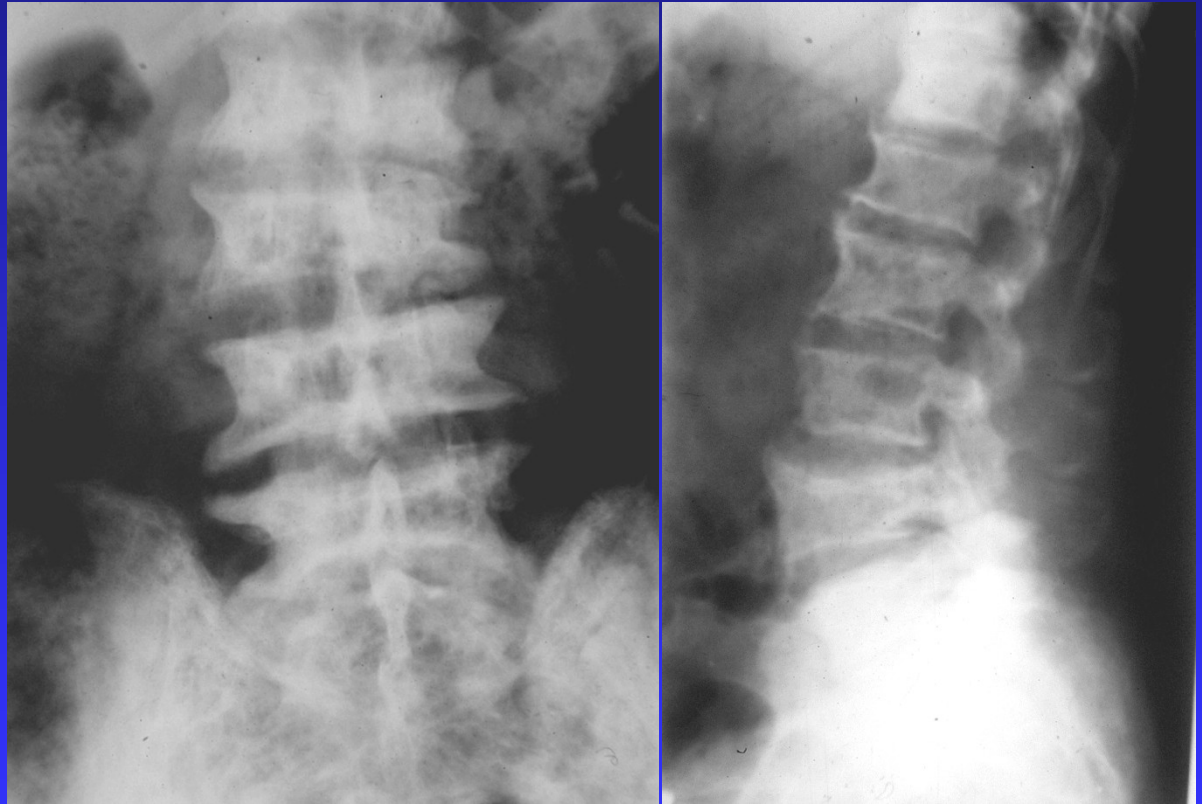
- 1. Osteolytic phase
- 2. Mixed phase
- 3. Osteoblastic phase

Morbus Paget

- Monoostotic form - 20 %
- Polyostotic form
- 95 % are asymptomatic
- 5% symptomatic

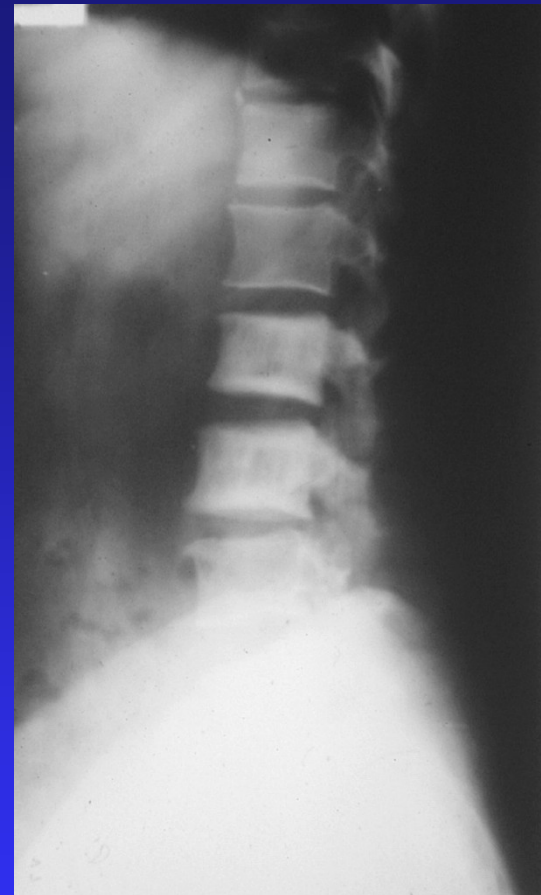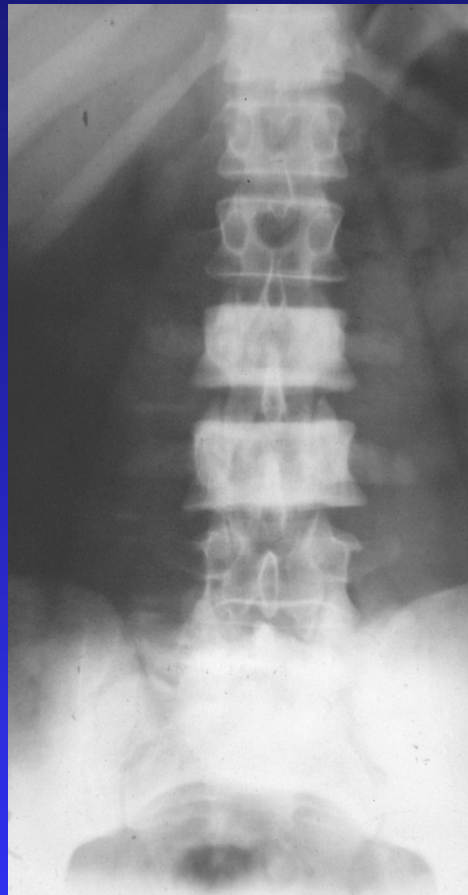
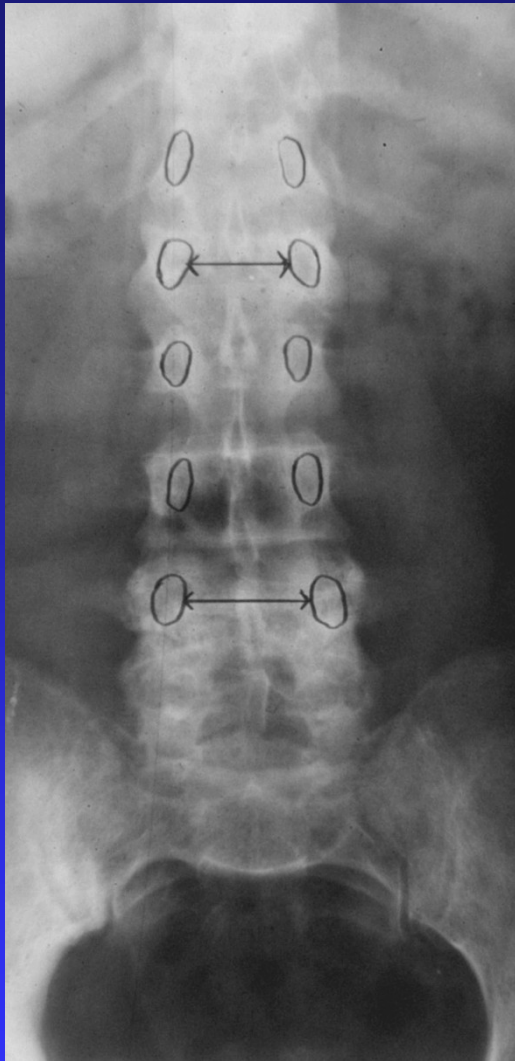
Symptoms

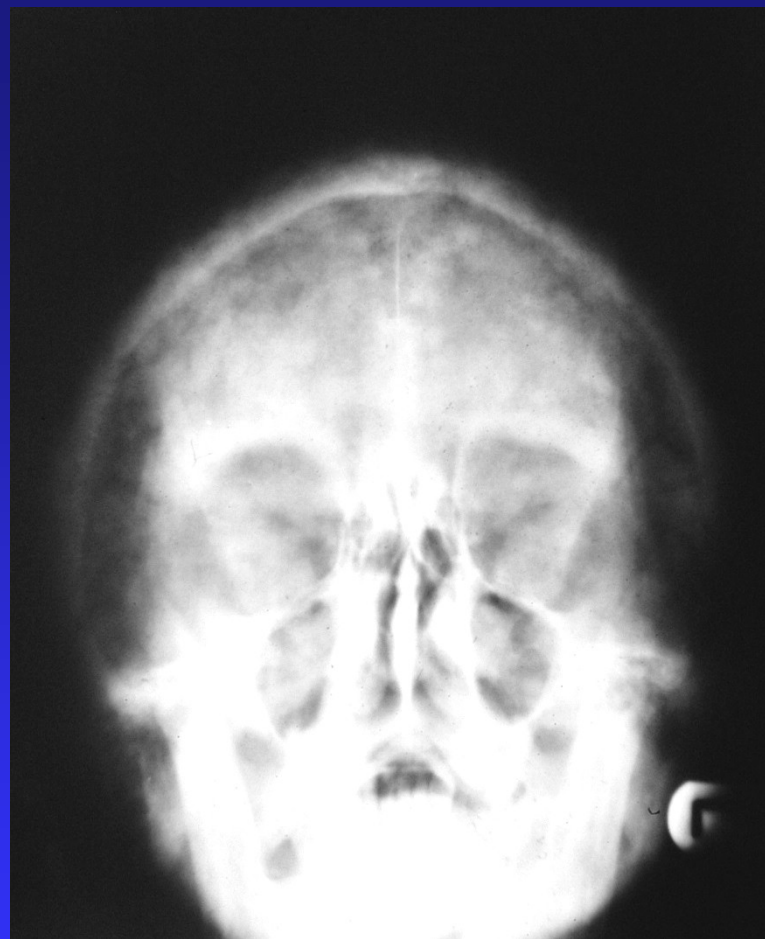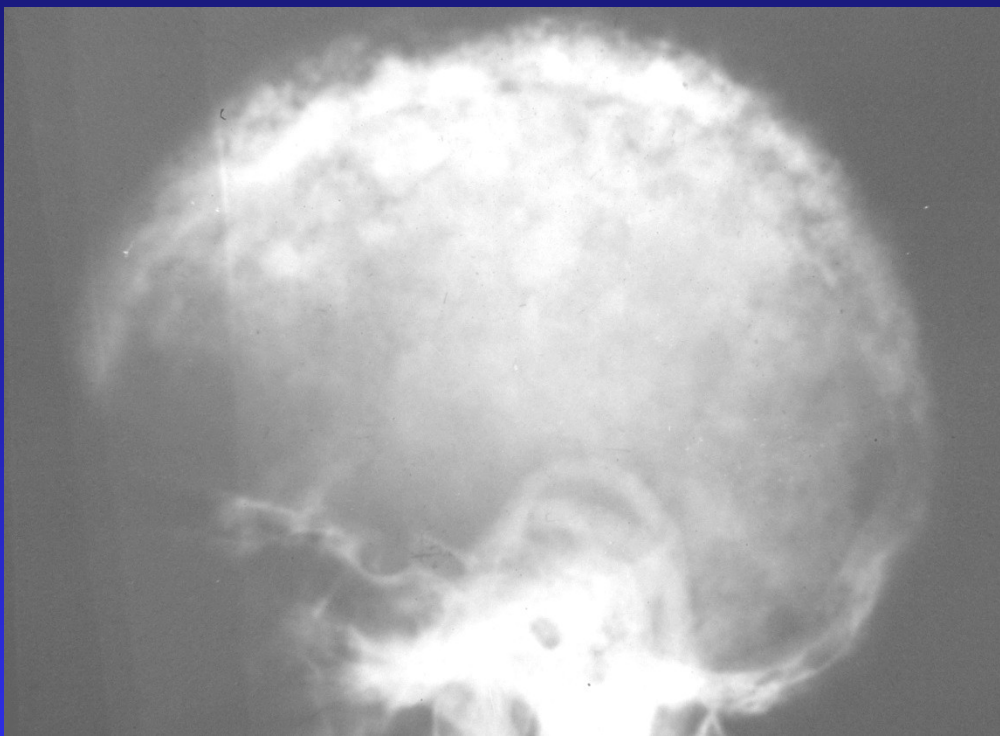
- Pain
- Fatigue
- Deformities
- Complications

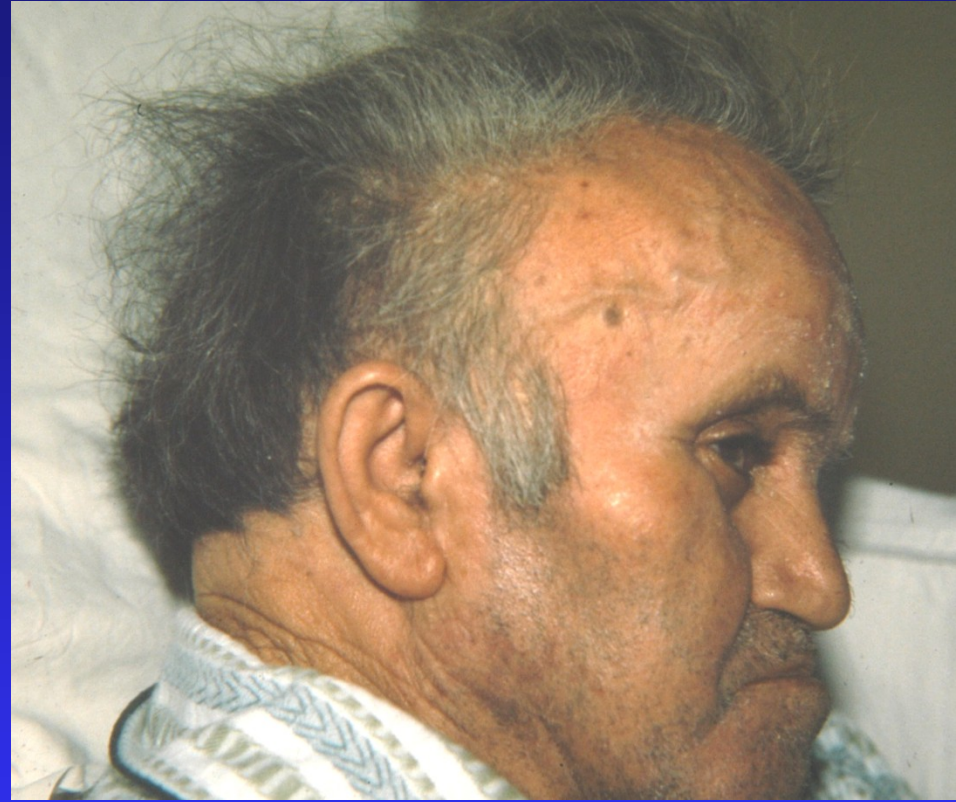
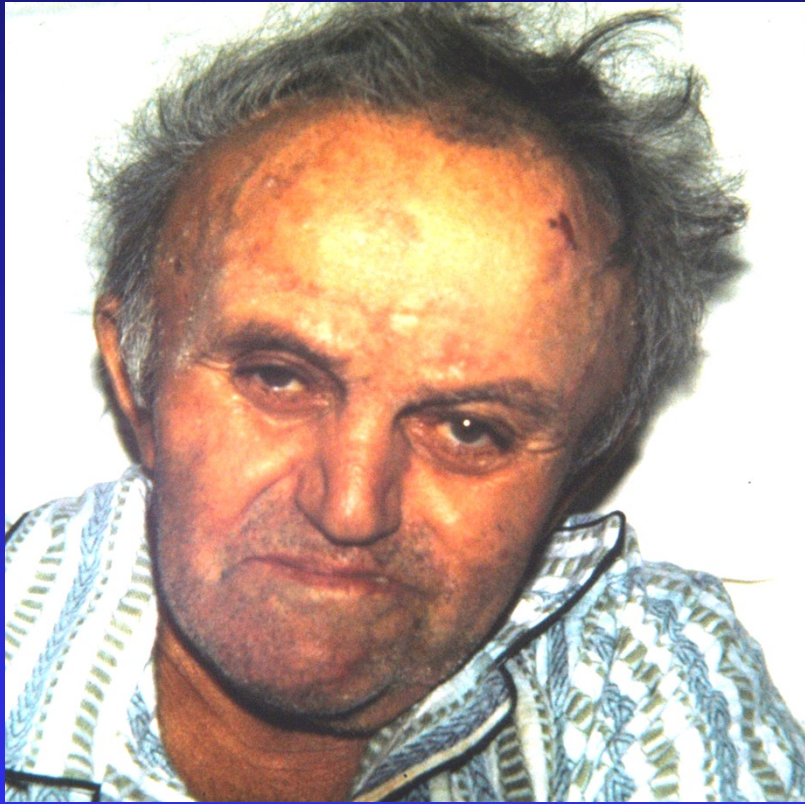
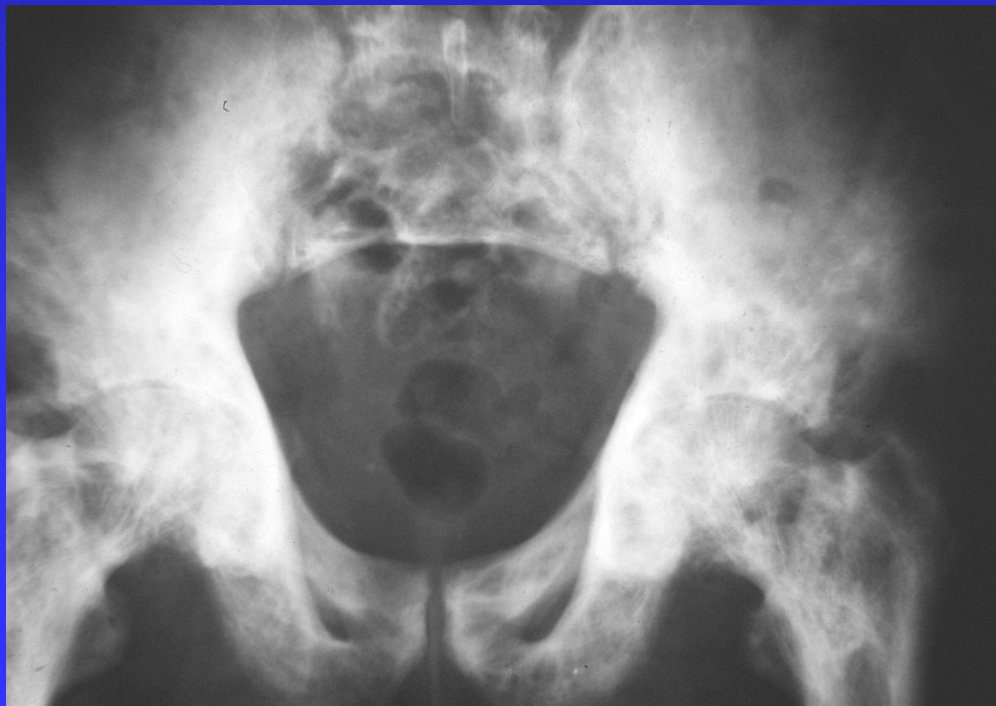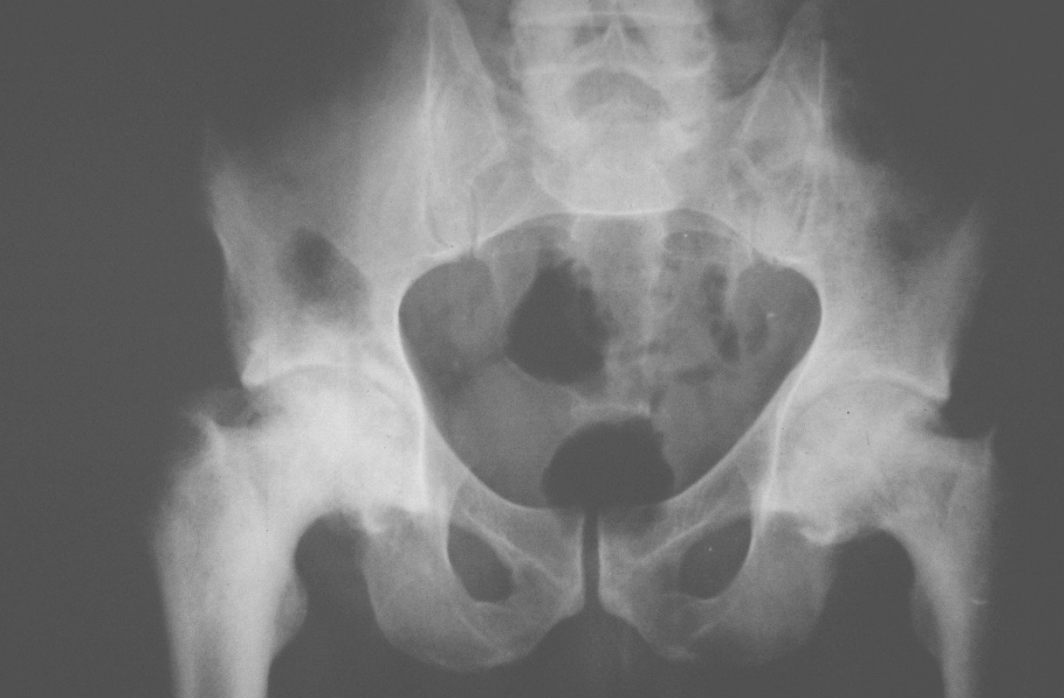
Clinical symptoms

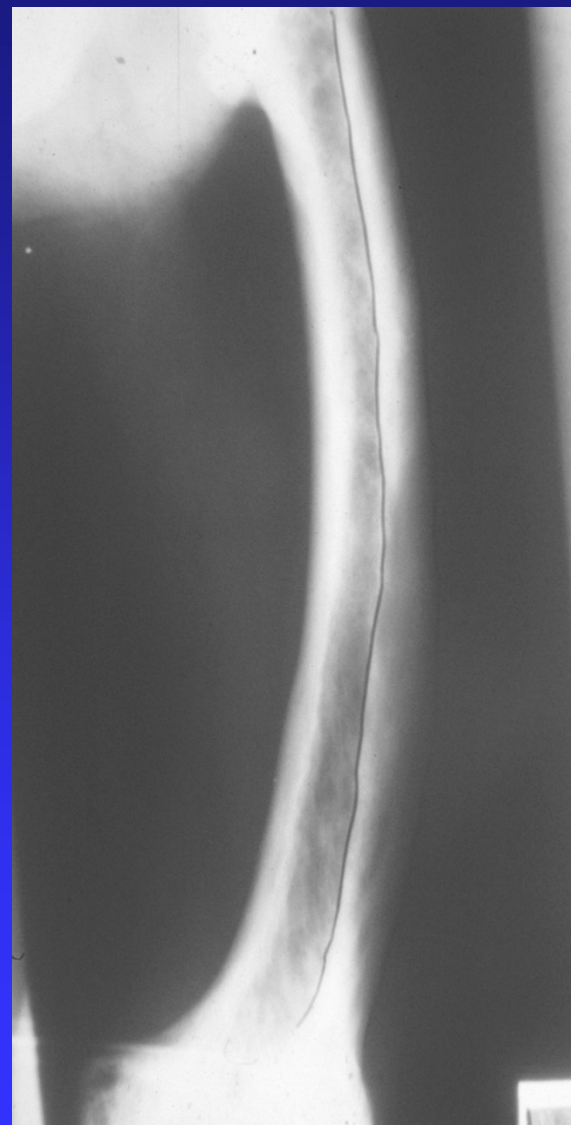
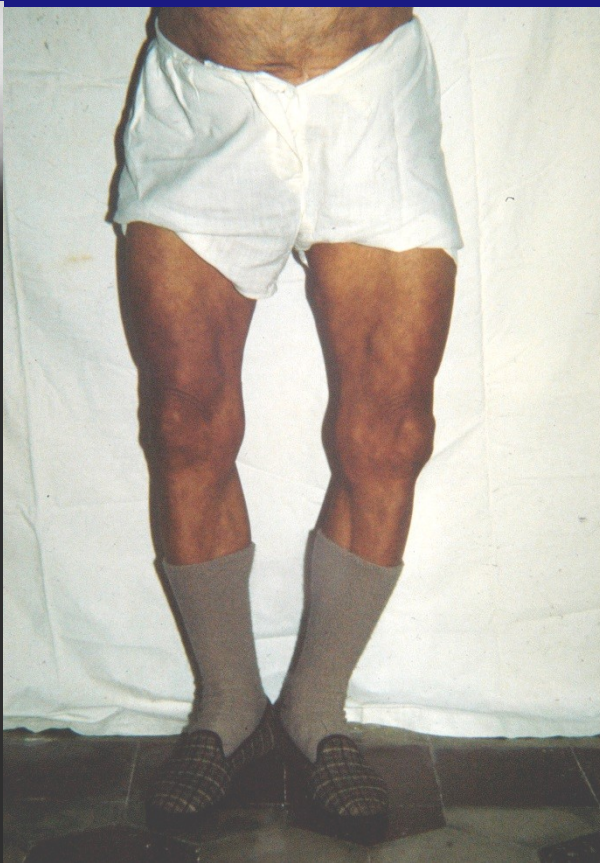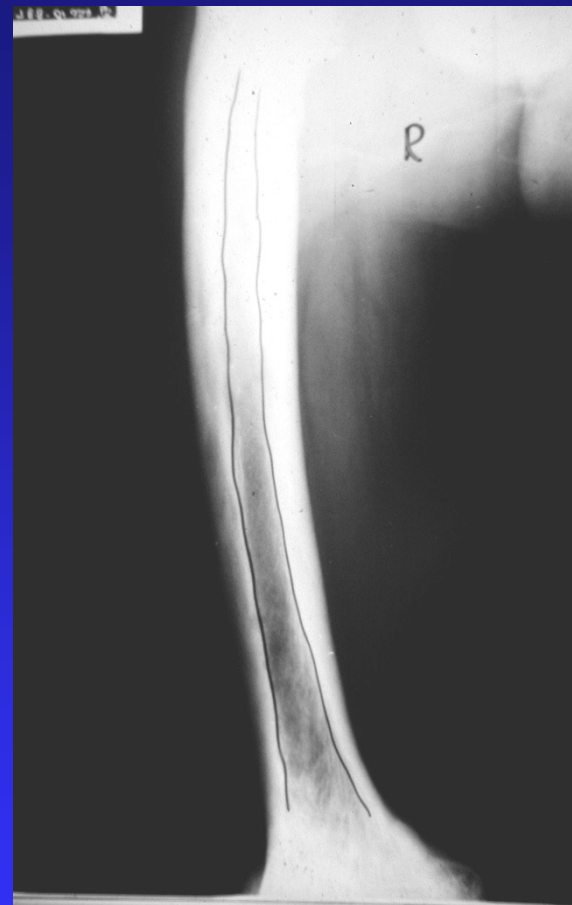
- Mild
- Moderate
- Severe

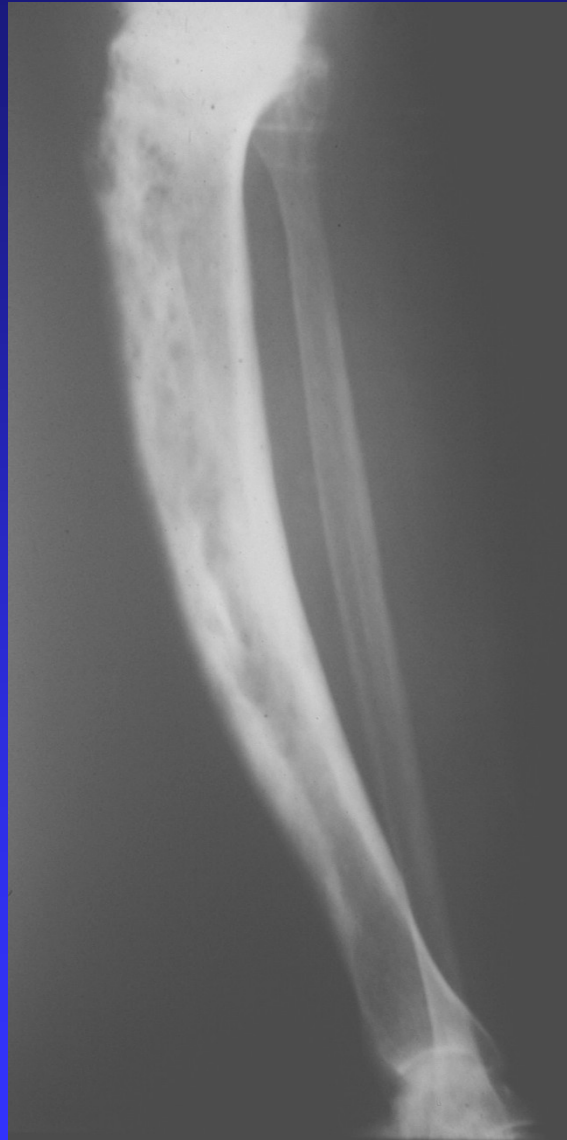
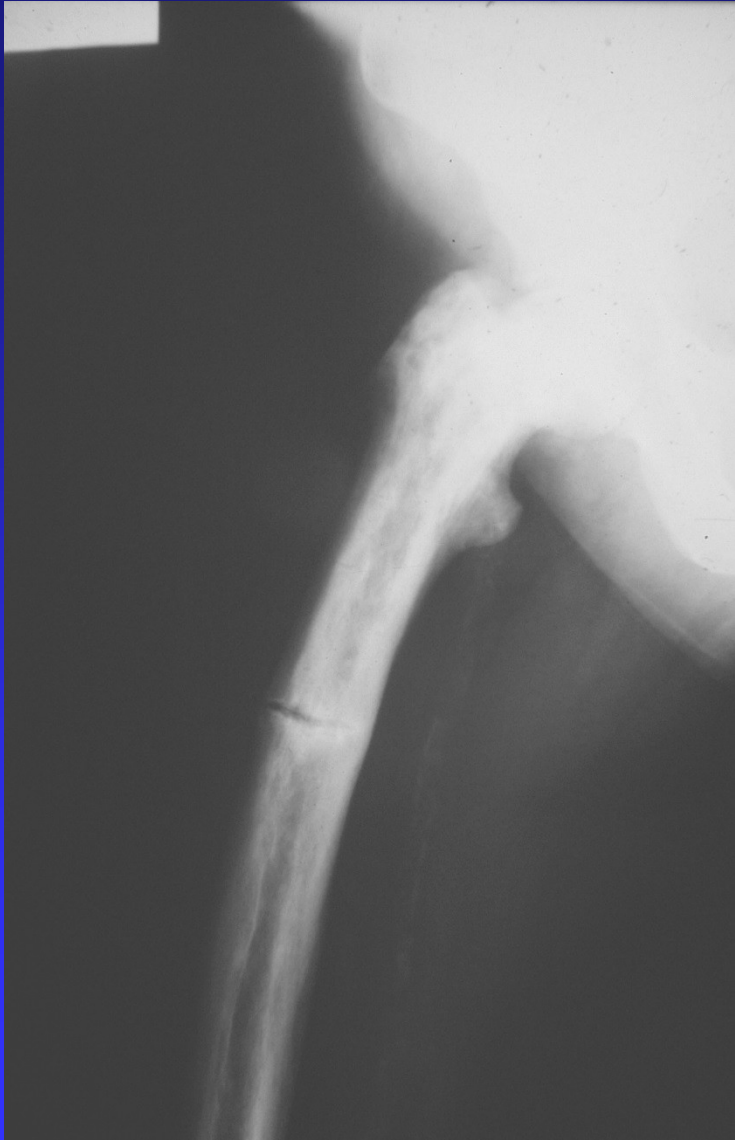


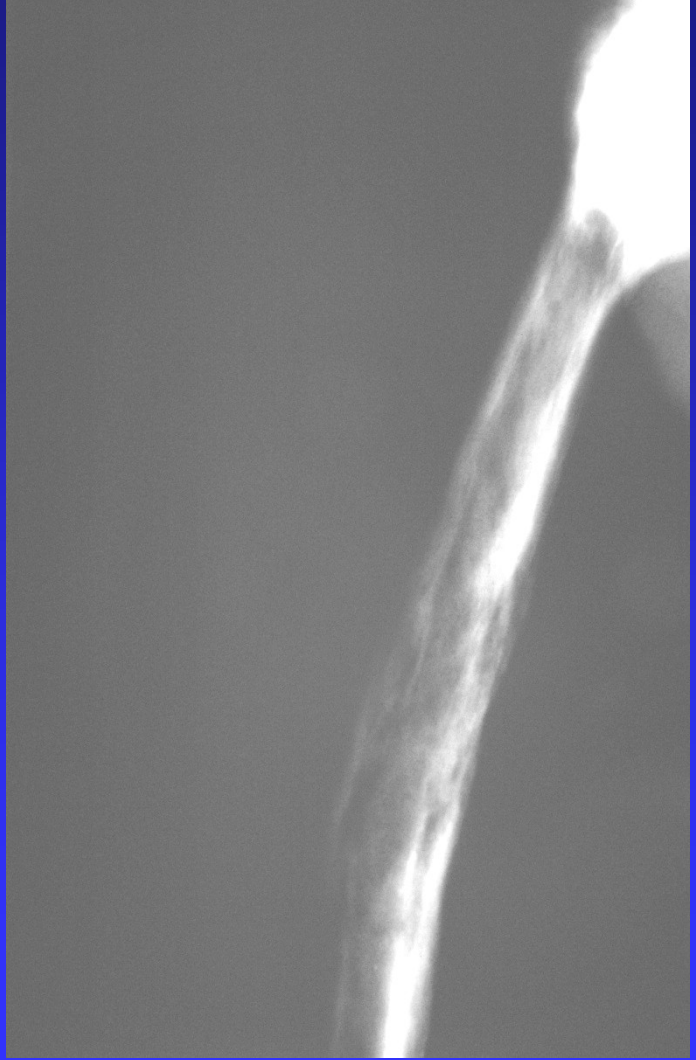
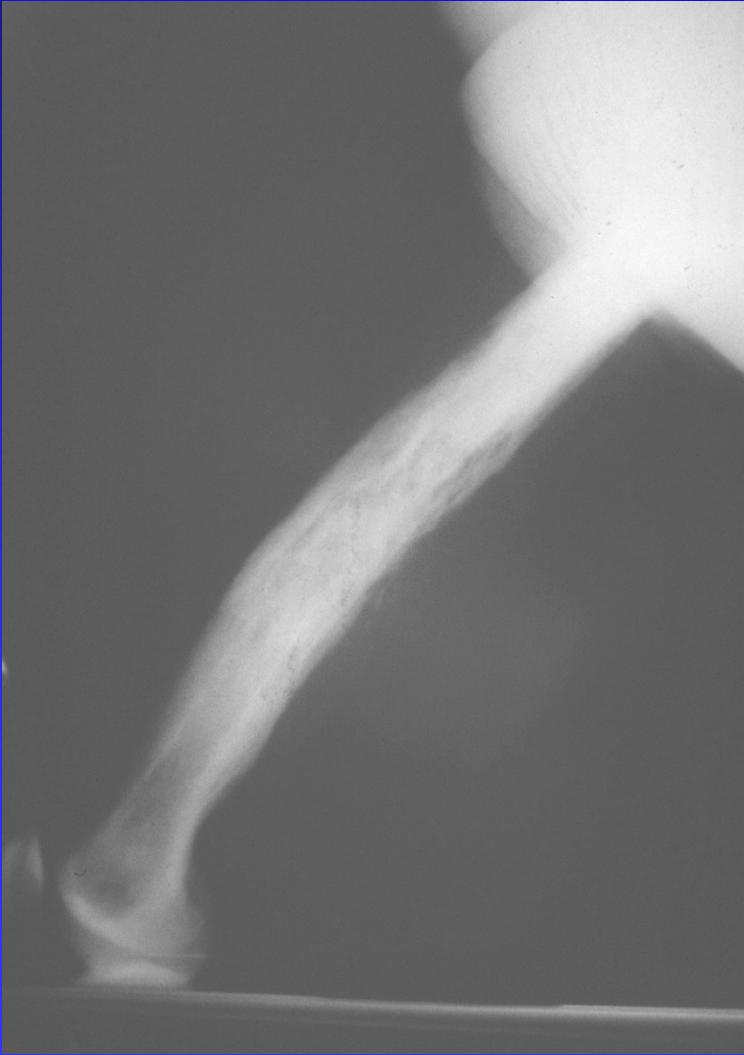


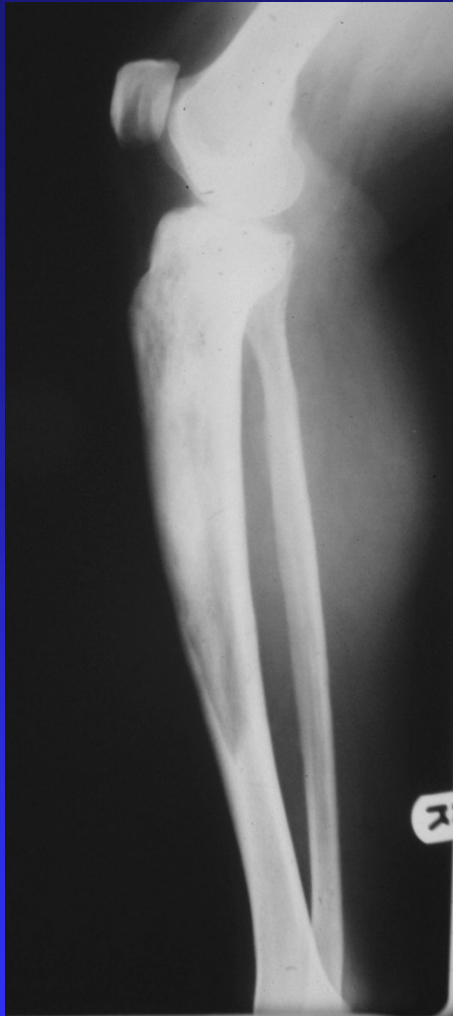




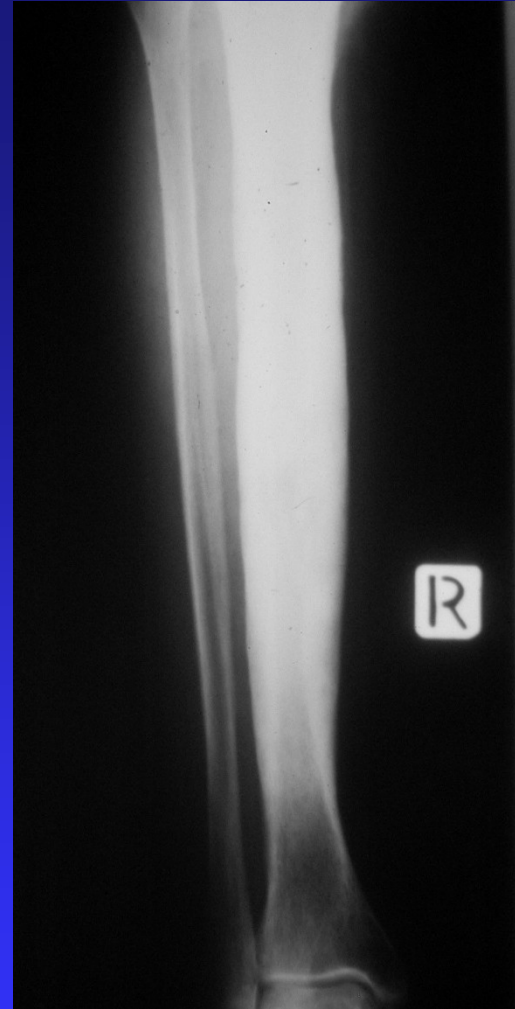


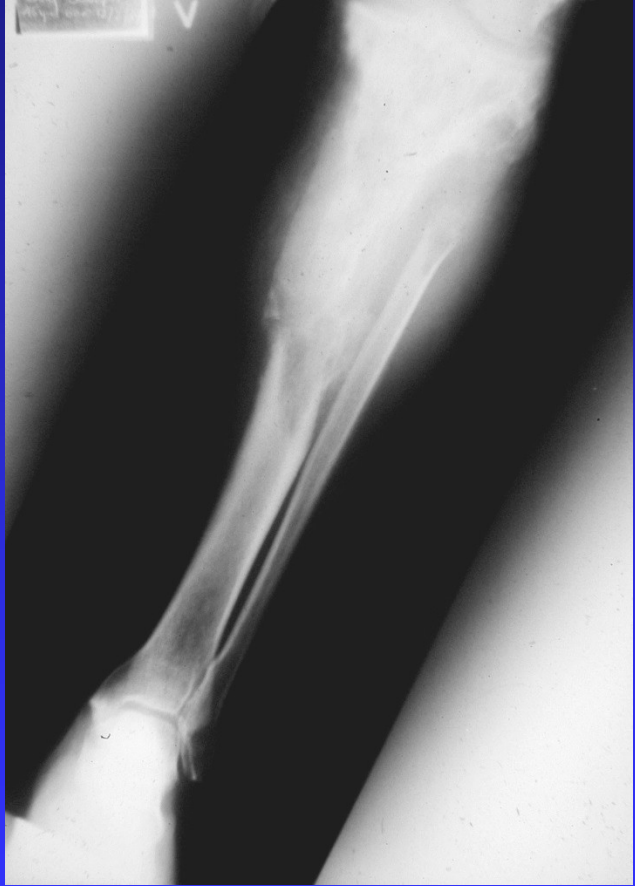
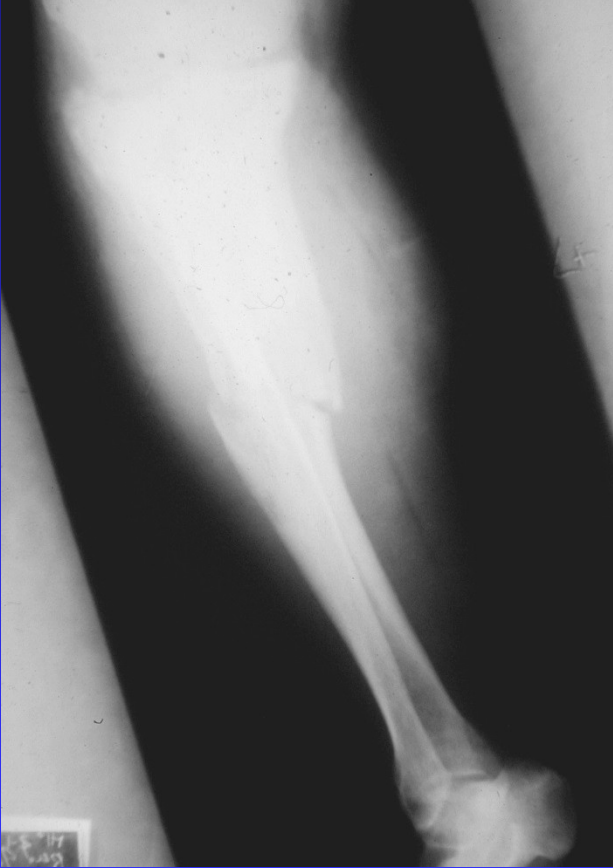


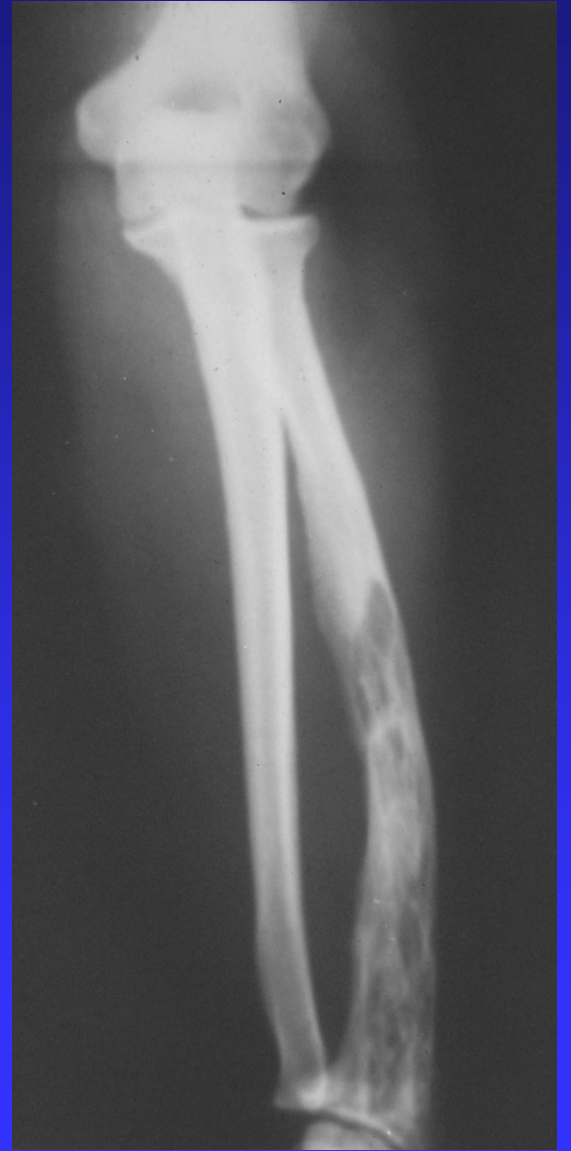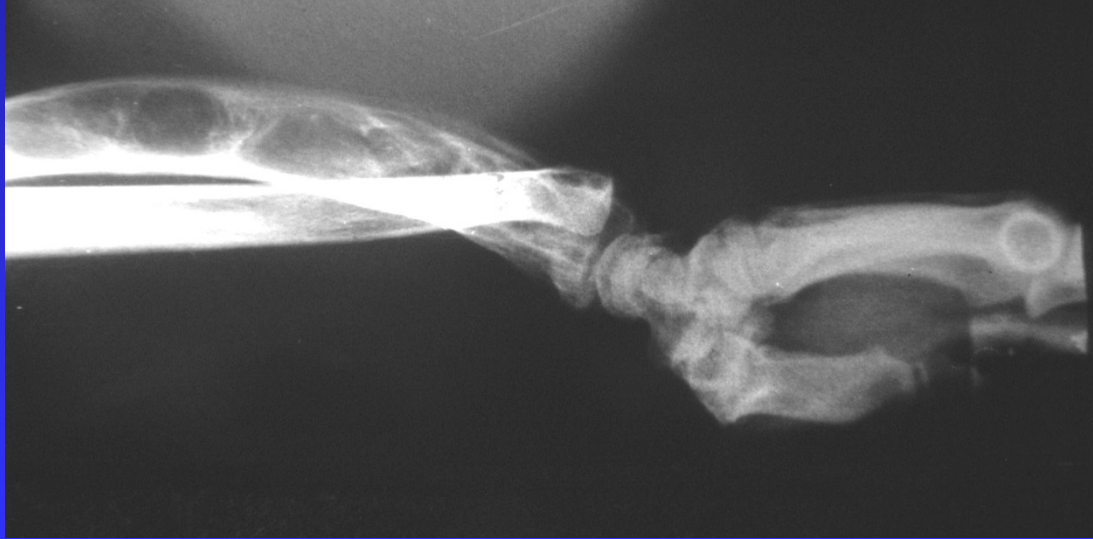Gothic arch







Complications

Fissures

Fractures

Osteoarthritis

Deafness

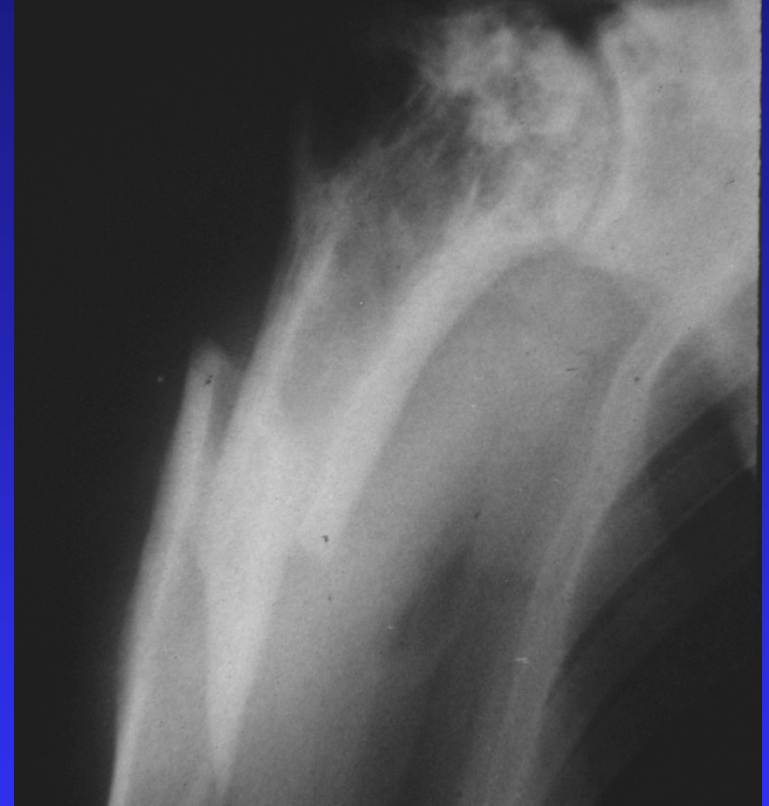
Neuralgia n. trigeminus

Basilar invagination

Vertebrobasilar insufficiency

Paraparesis, sciatica

Dental problems



Complications

Hypertension

Ischemic heart disease

Cardiomegaly

Neoplastic degeneration

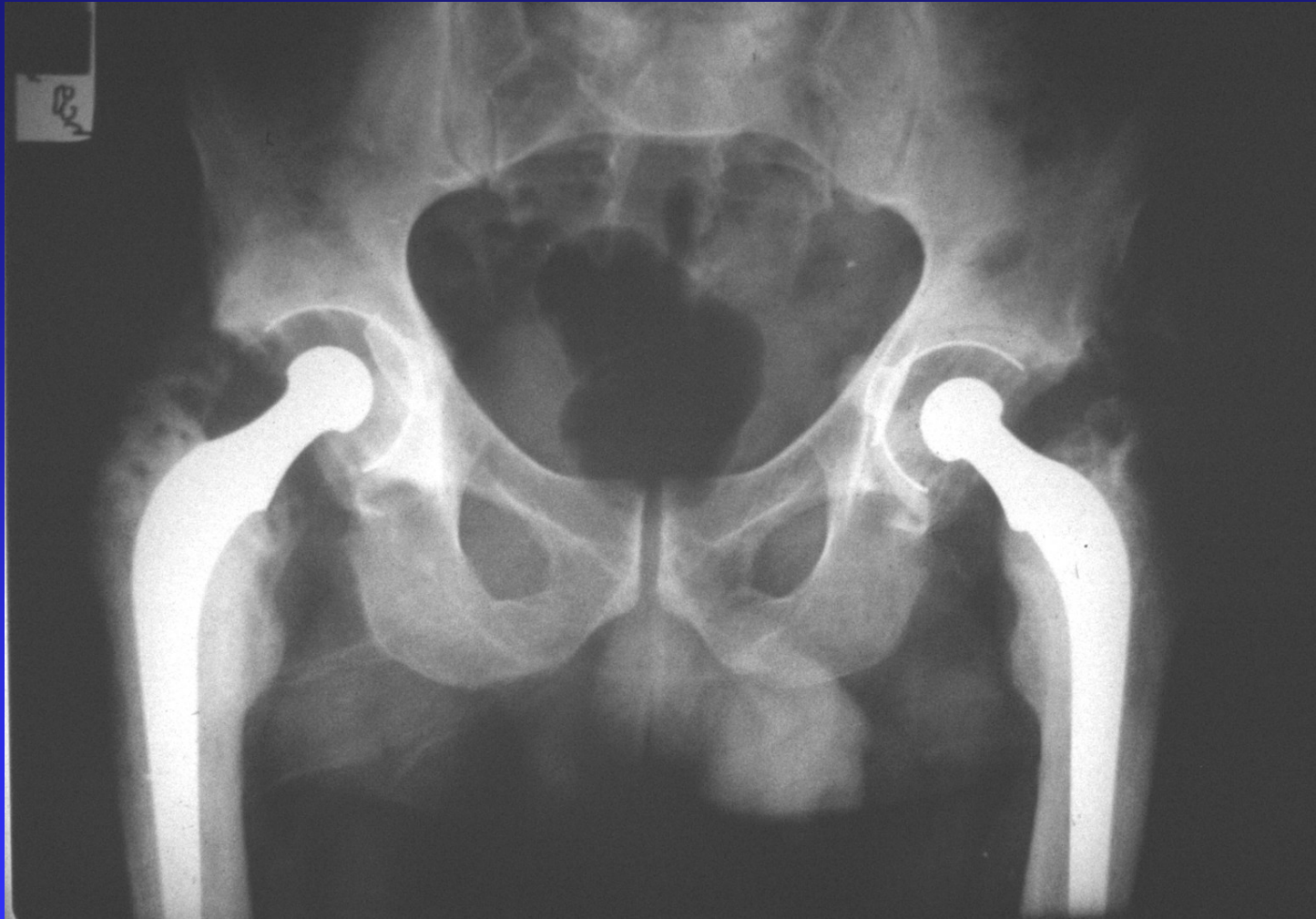
sarcoma

Nephrolithiasis

Calcifications

Management

- Bisphosphonates (Fosamax 40 mg daily three months, Pamidronate, Zoledronate)
- Calcitonin nasal spray, s.c.
- Calcium
- Therapy of complications
- Osteosynthesis of fx
- Total knee and hip replacement



Charnley total hip arthroplasty