

SPINE TRAUMATOLOGY

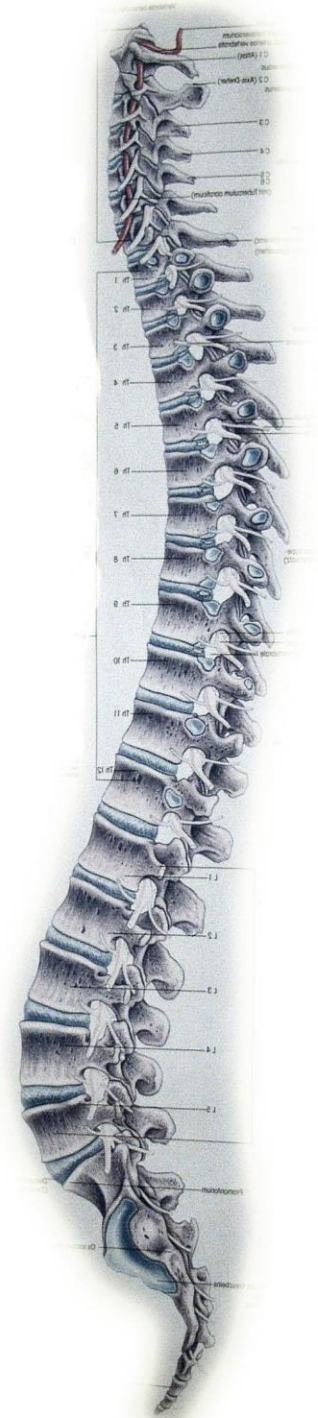
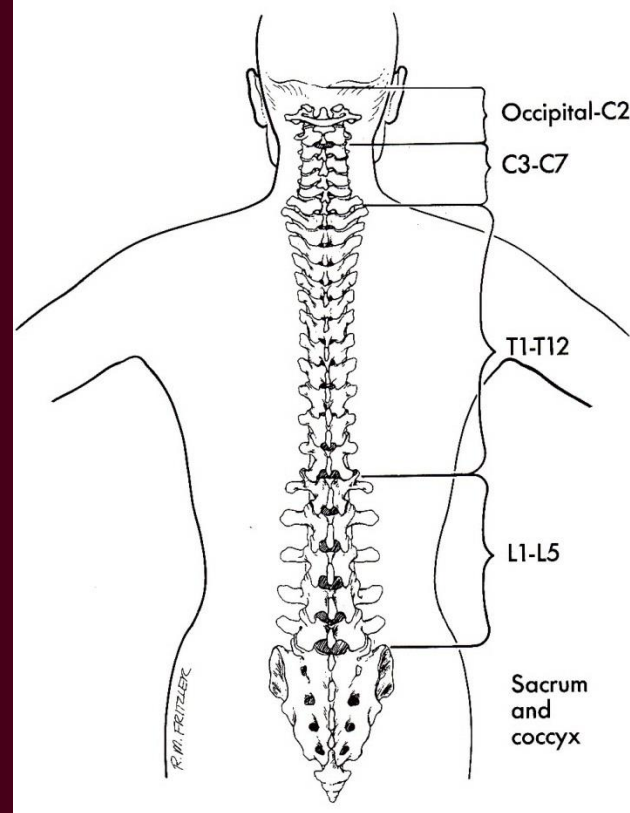
M. Krbec, M. Repko, M. Rouchal,
L. Ryba, R. Chaloupka



*Ortopaedic Univ. Dept.
FN Brno-Bohunice*

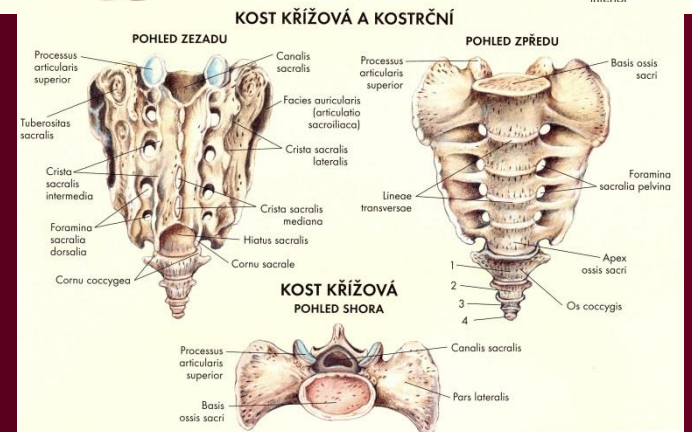
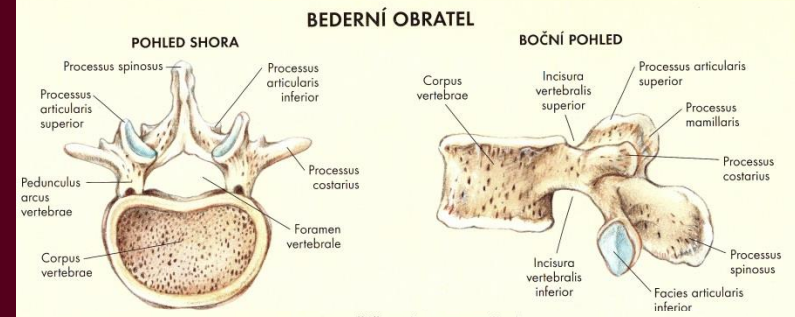
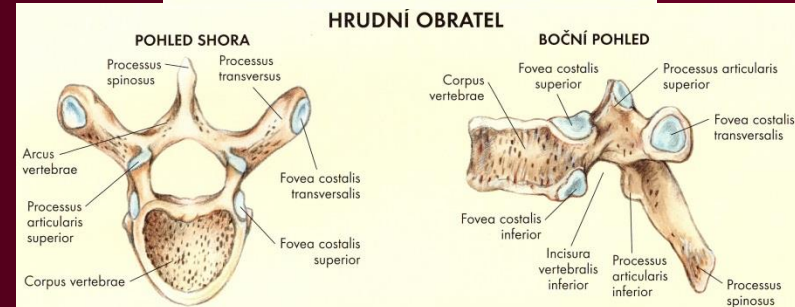
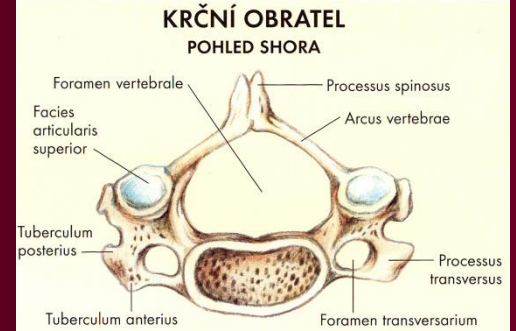
SPINE

- cervical C
 - thoracic T
 - lumbar L
 - sacrum
 - coccyx
-
- body support
 - spinal cord / dura protection



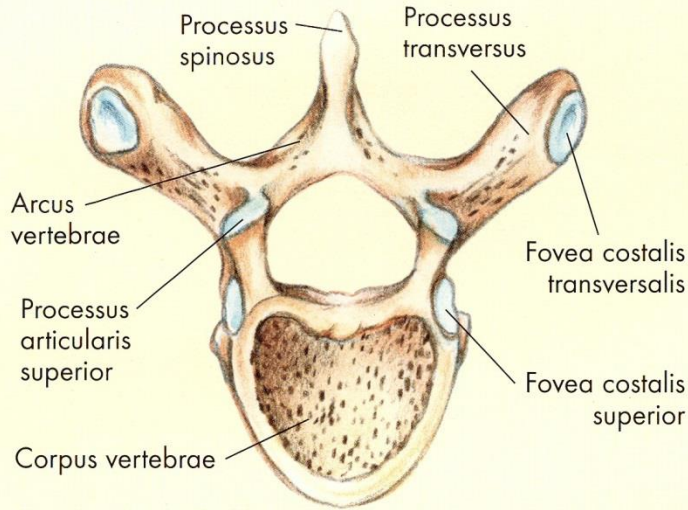
Anatomy of vertebra

- Vertebral body
- Pedicles
- Arch
- Articular processes
 - superior
 - inferior
- Transverse processes
- Spinous process

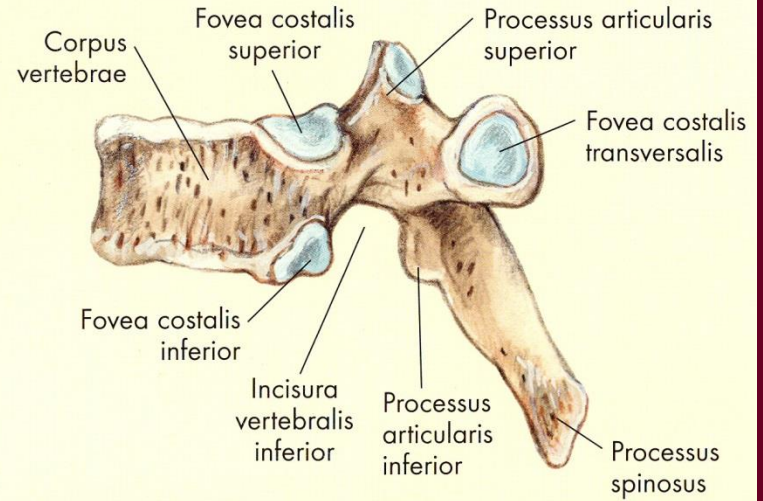


HRUDNÍ OBRATEL

POHLED SHORA

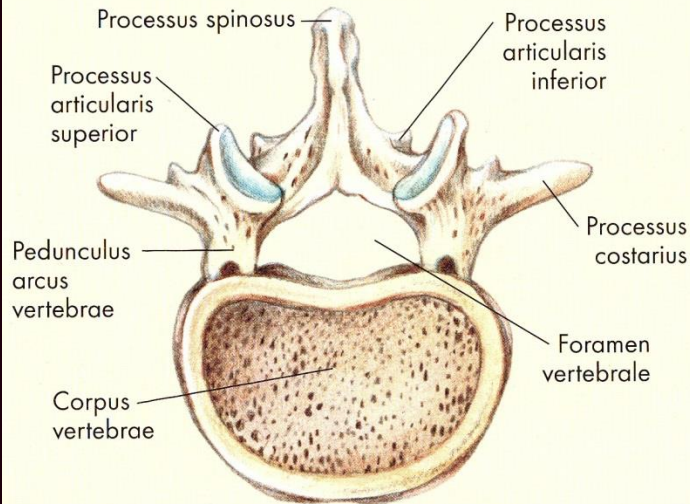


BOČNÍ POHLED

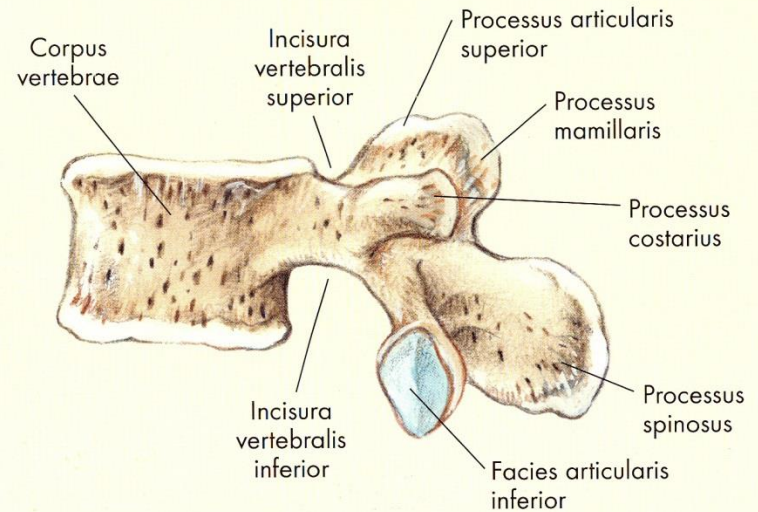


BEDERNÍ OBRATEL

POHLED SHORA

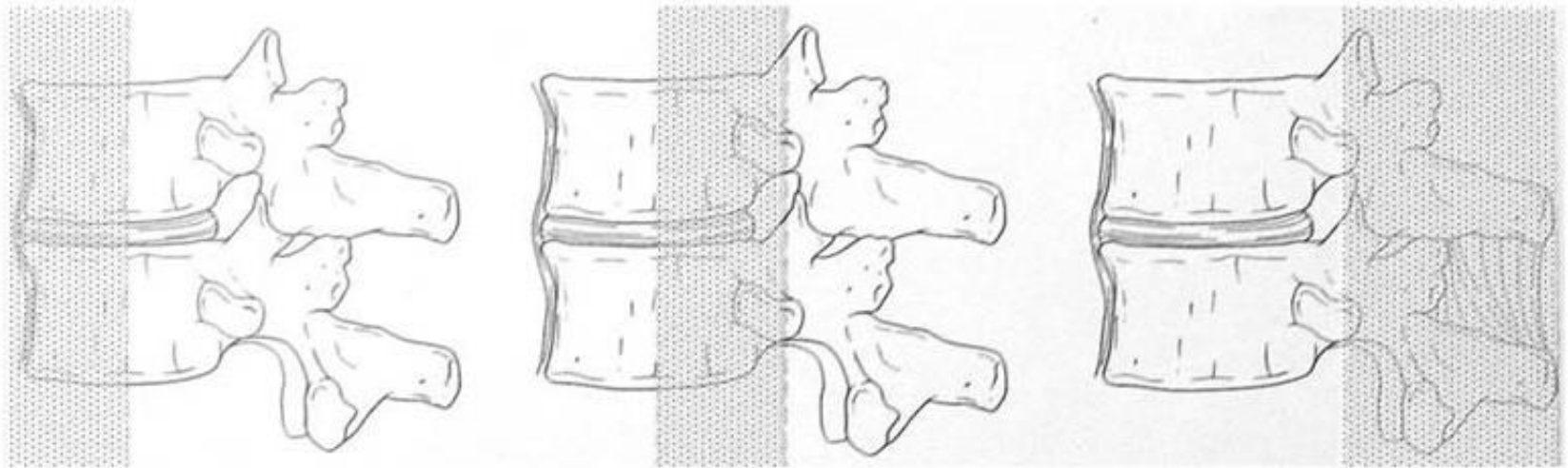


BOČNÍ POHLED



Denis 3-column theory

Denis 3-column theory



Anterior column

Middle column

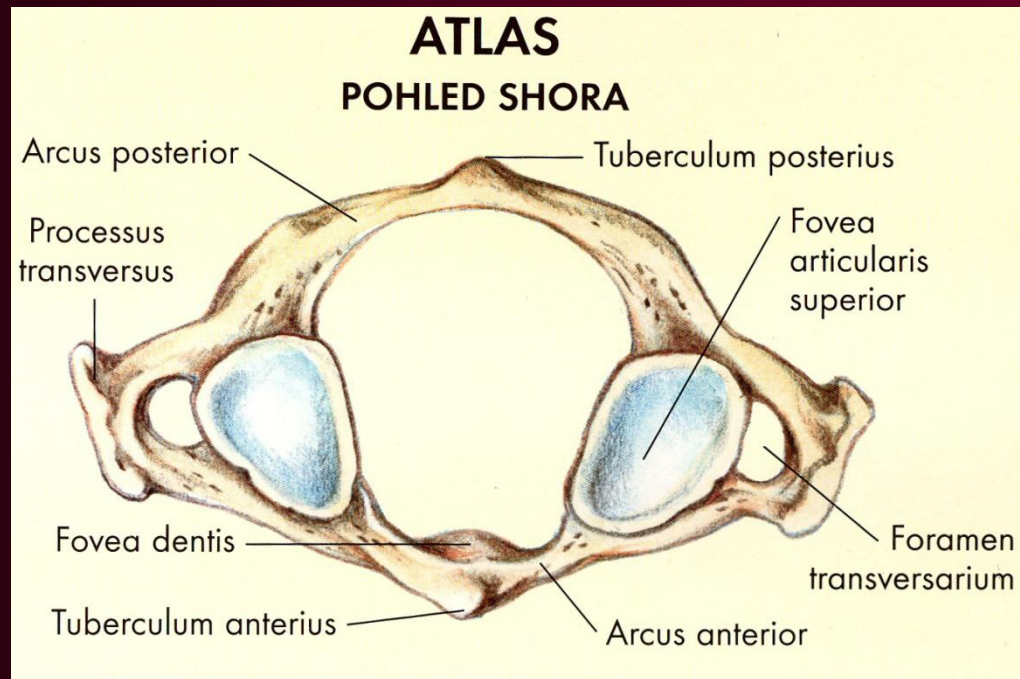
Posterior column

Now 2-column theory(Magerl)

C1

C1 = atlas

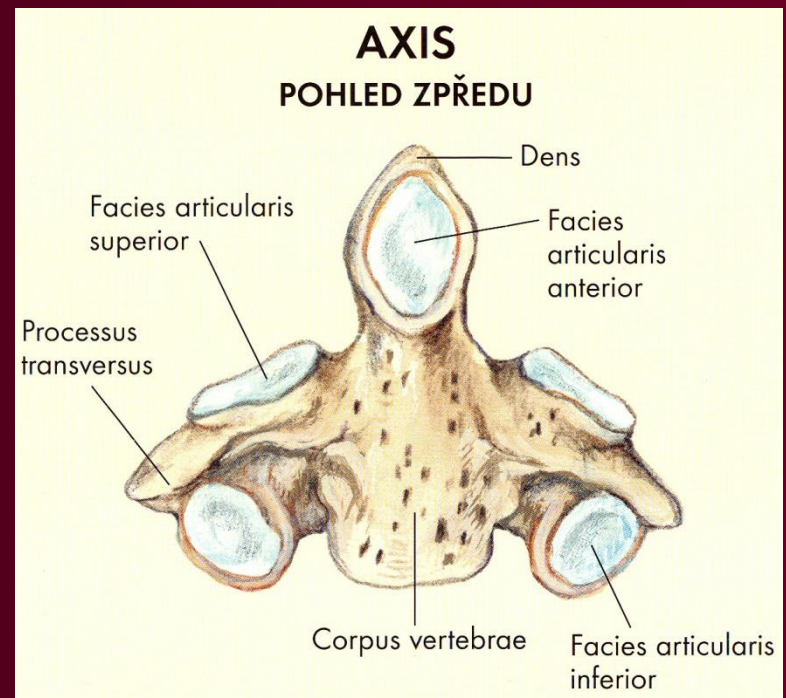
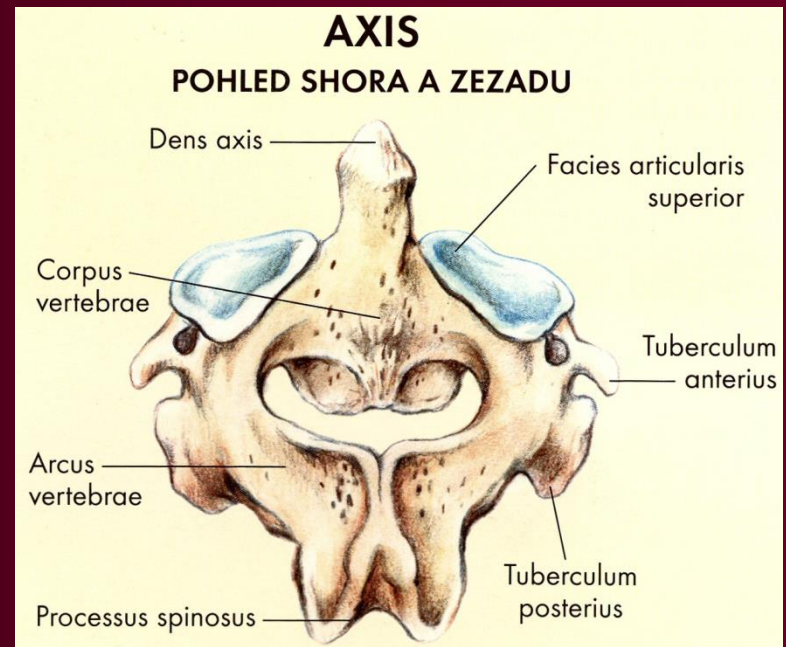
Arches + articular processes



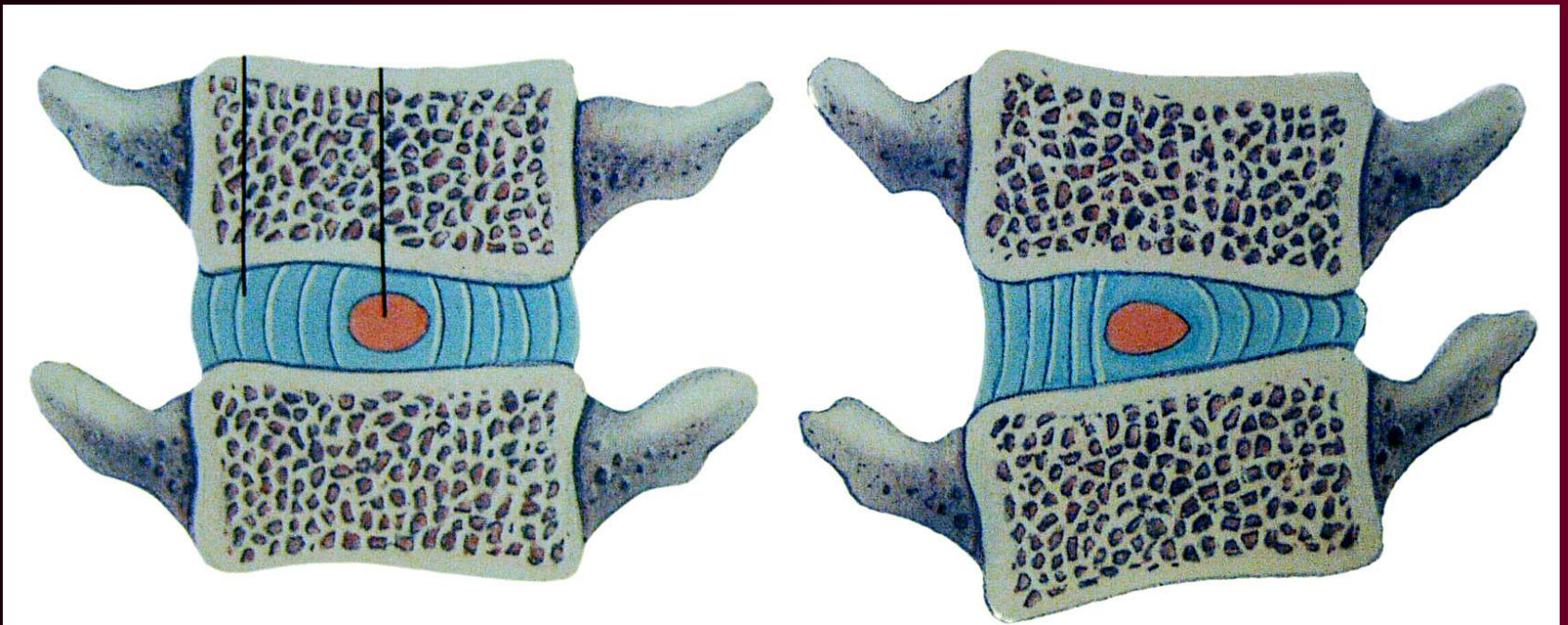
C2

axis

- **Body**
- **Dens**
- **Articular processes**



Discus intervertebralis



EXAMINATION

- **Case history**
- **Clinical examination**
- **X-ray**
- **Neurological**
- **CT**
- **MRI**

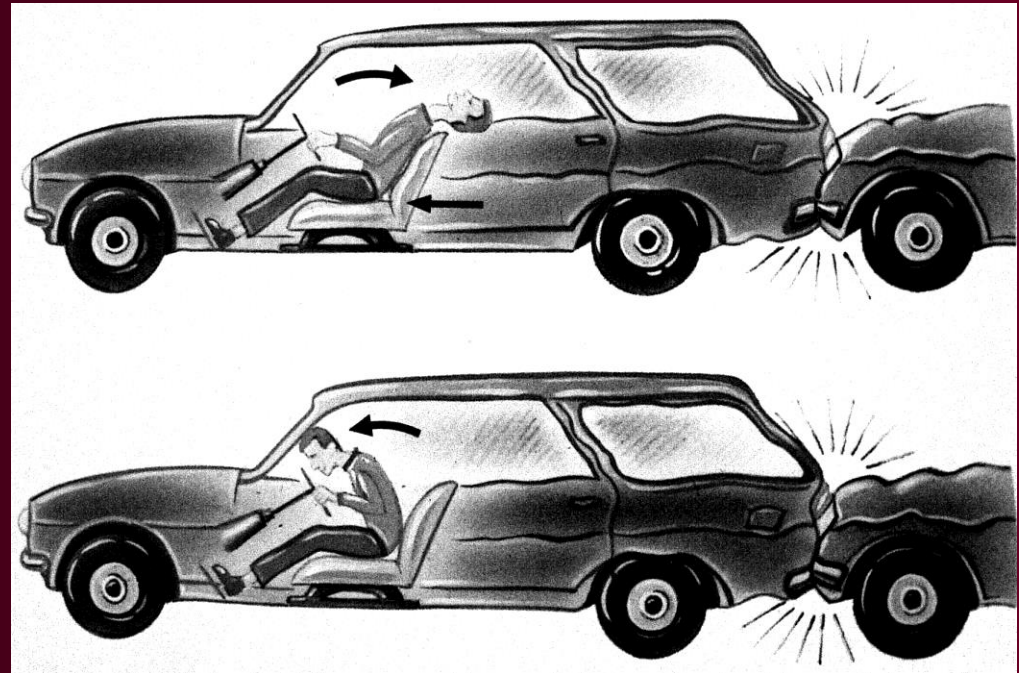

TYPES OF INJURY

Forces, directions

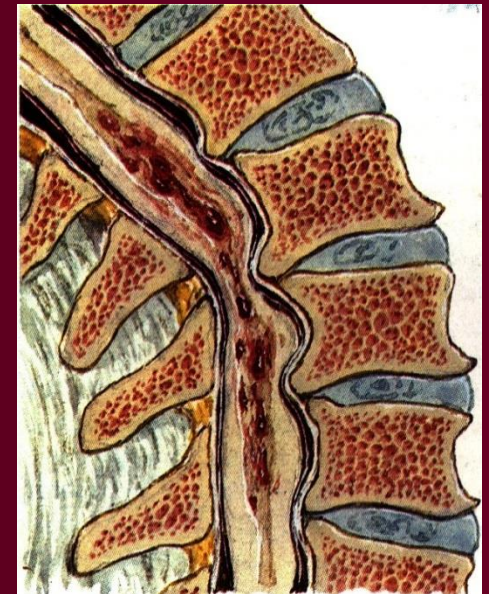

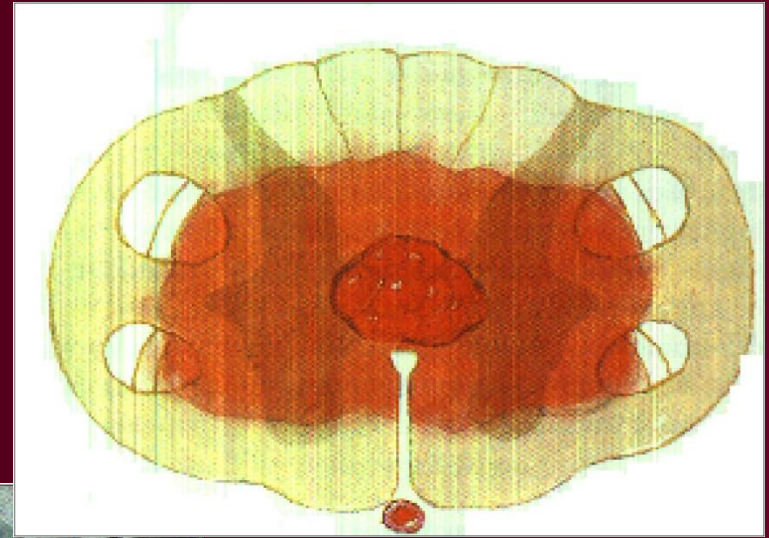
- **Axial pressure**
- **Bending pressure**
- **Rotation**
- **Combination**

MECHANISM OF INJURY

- Falls
- Traffic accidents
- Sport



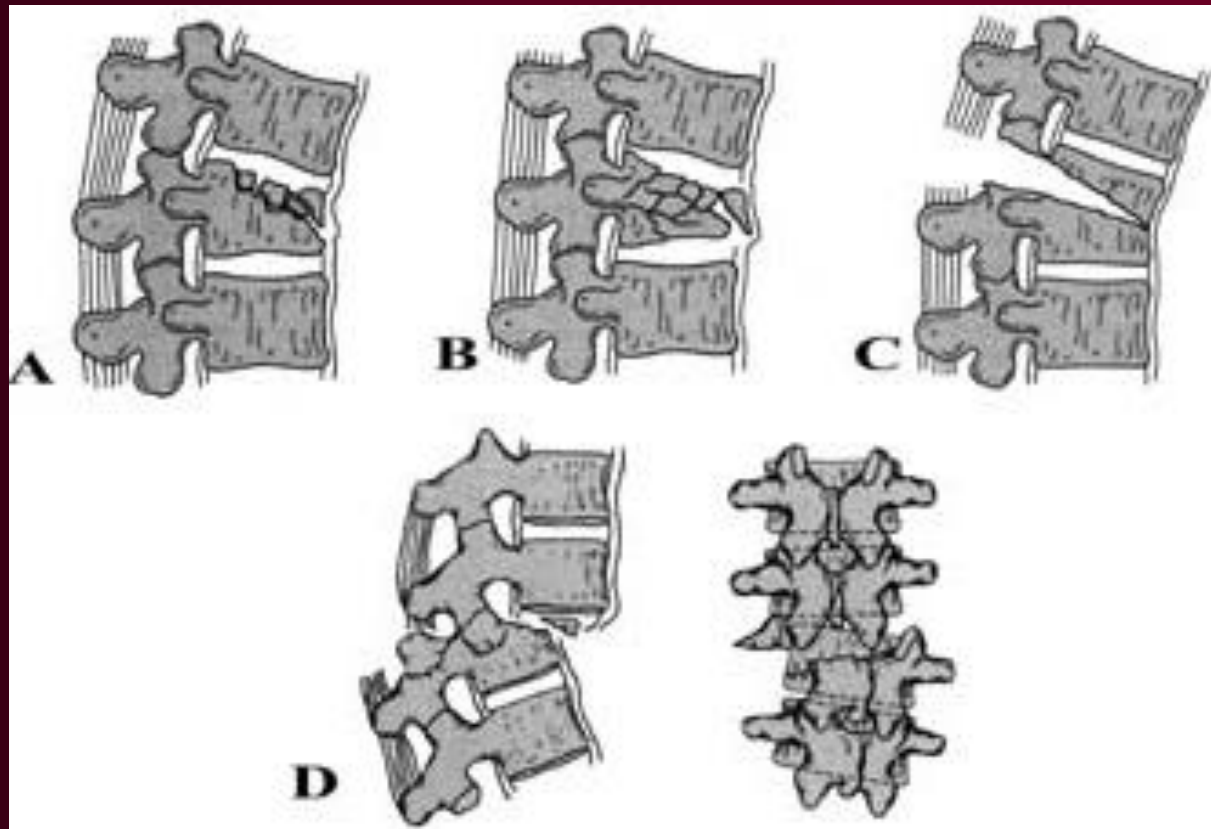
Hematomyelia - Central cord sy



Denis' classification

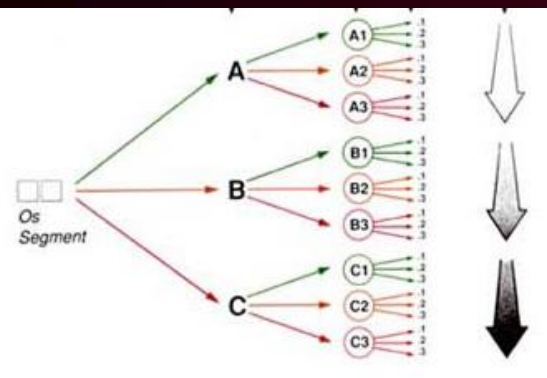
3 three-column concept

- A compressive**
- B burst**
- C flexion-distraction**
- D rotational forces
(shear, translation)**



AO classification

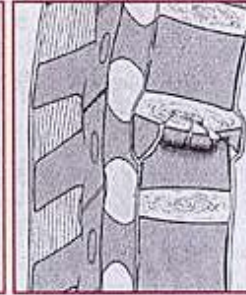
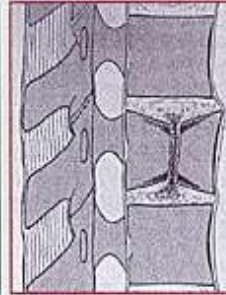
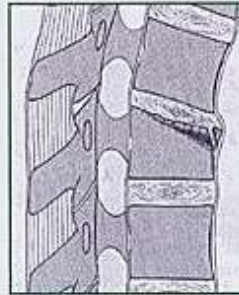
Magerl et al.
2-column



A1

A2

A3

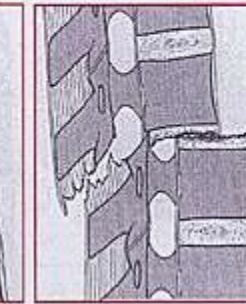
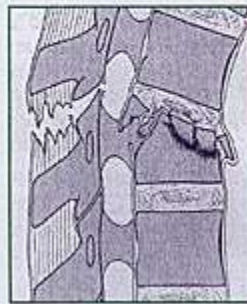


compression

B1

B2

B3

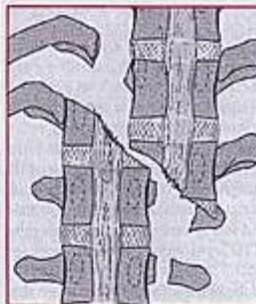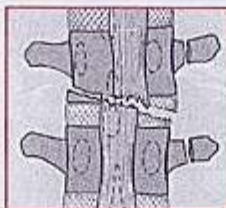
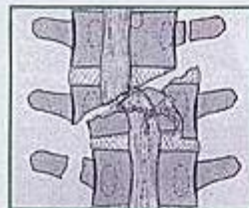


distraction

C1

C2

C3



A,B with rotation

Frankel (ASIA) classification

- A complete loss of motor end sensory functions**
- B no motor preservation, sensory function only**
- C useless motor function preserved**
- D motor function less than normal**
- E normal neurological status**

THERAPY

- **conservative**
 - **orthosis, plaster cast**
 - **bed rest**
- **surgical**
 - **posterior surgery**
 - **anterior surgery**
 - **combined**

FIRST AID

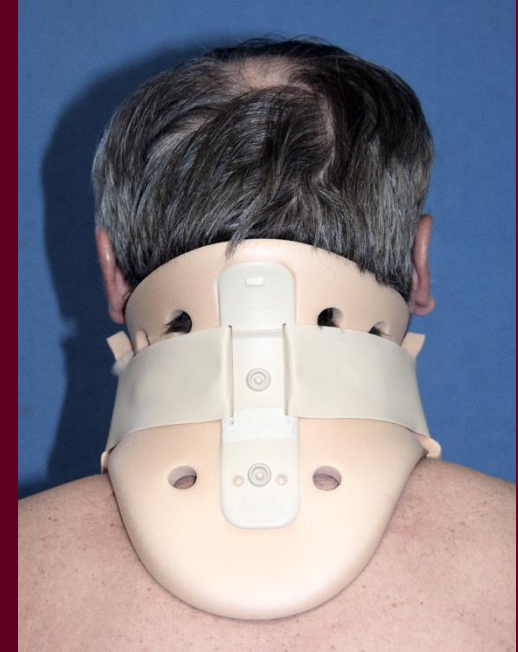
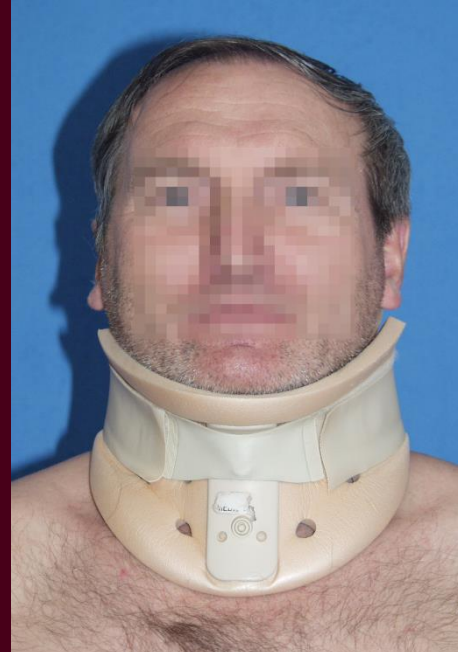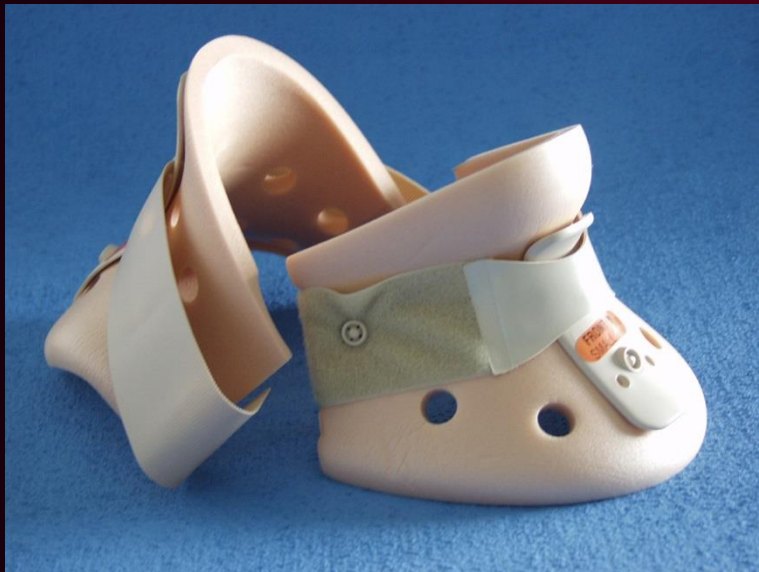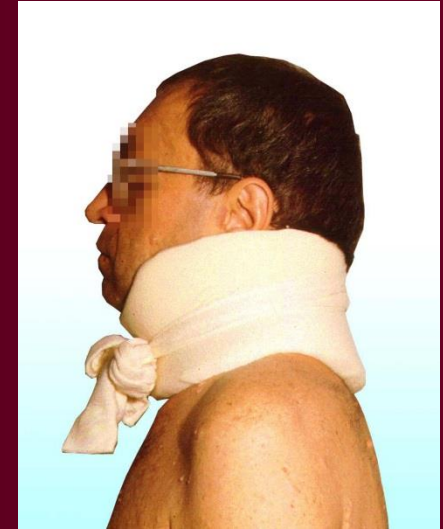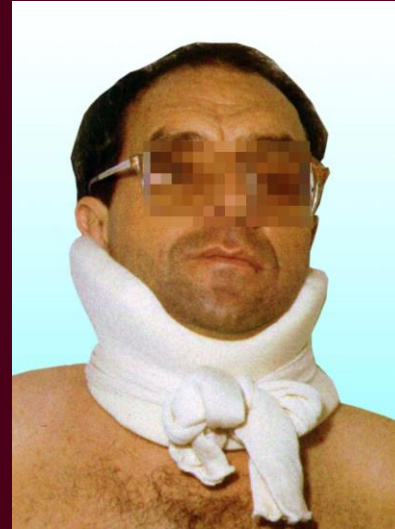- **CERVICAL SPINE FIXATION**
- **TO AVOID MOVEMENT WITH THORACIC AND LUMBAR SPINE DURING MANIPULATION**
- **SPINAL DEPARTMENT**

SURGICAL INDICATION

- **NEUROLOGICAL LESION**
 - » **OPERATION UP TO**
 - » **6 HOURS !**
- **SPINE INSTABILITY**

CONSERVATIVE THERAPY

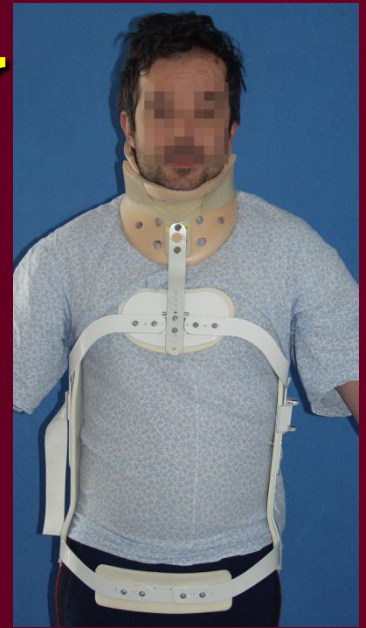- **Bed rest**
- **Collars- soft**
-Philadelphia



CONSERVATIVE THERAPY

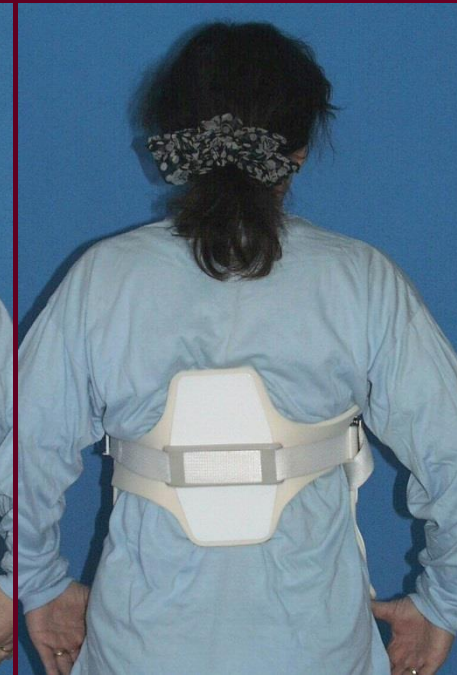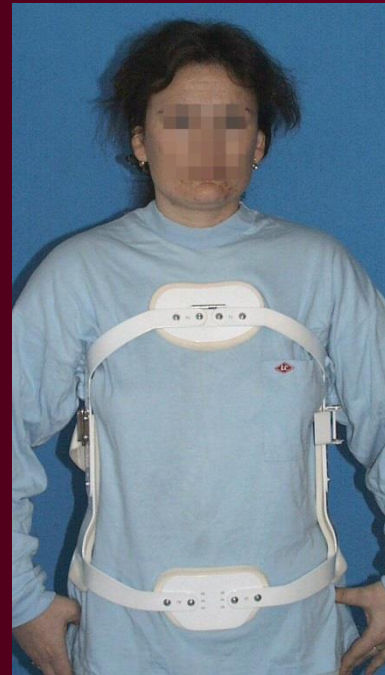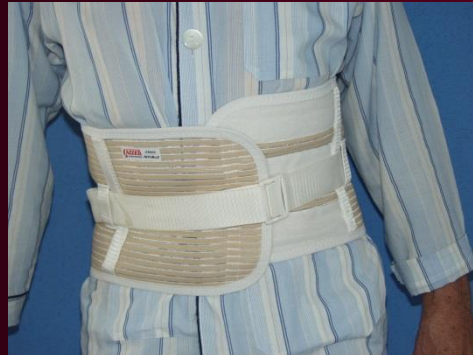T SPINE T8 - 12

- Jewett orthosis

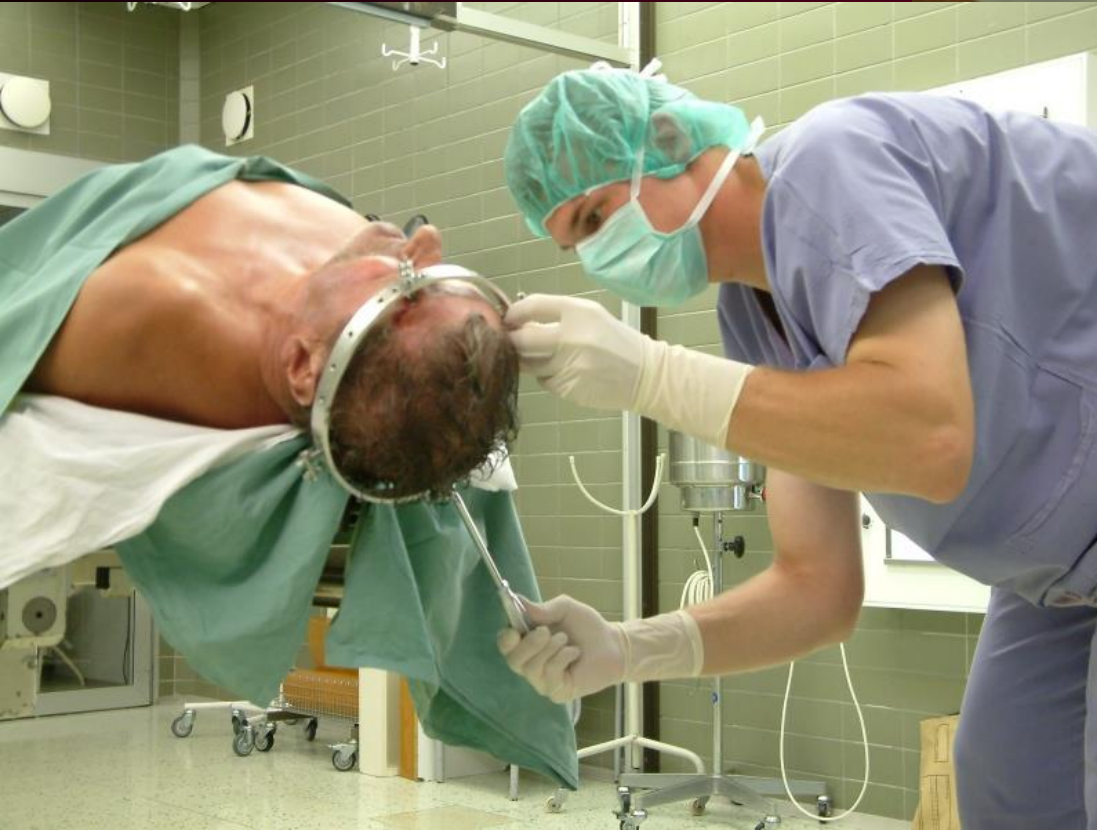
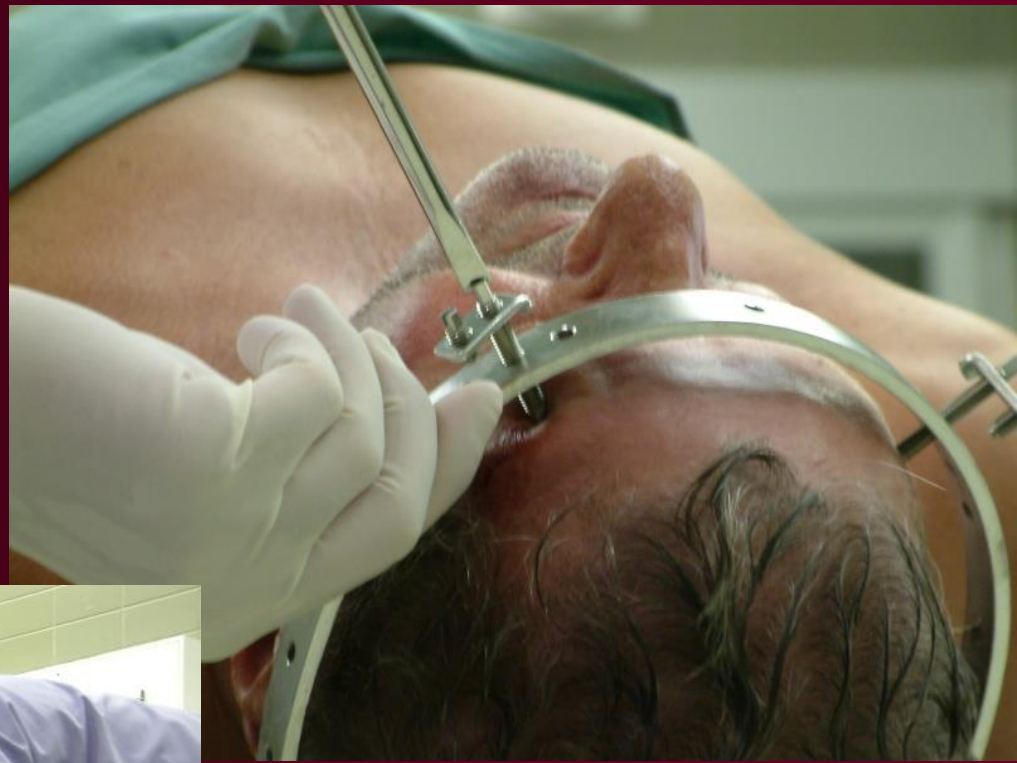
LS SPINE

- Jewett orthosis L1 - 3
- lumbar belt L4 - S1



HALO - TRACTION

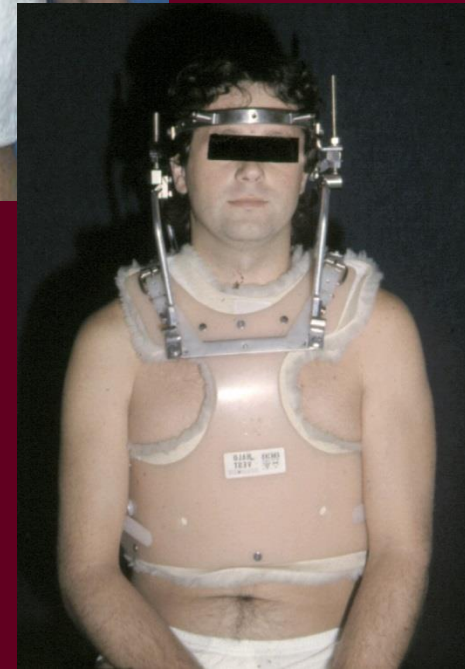
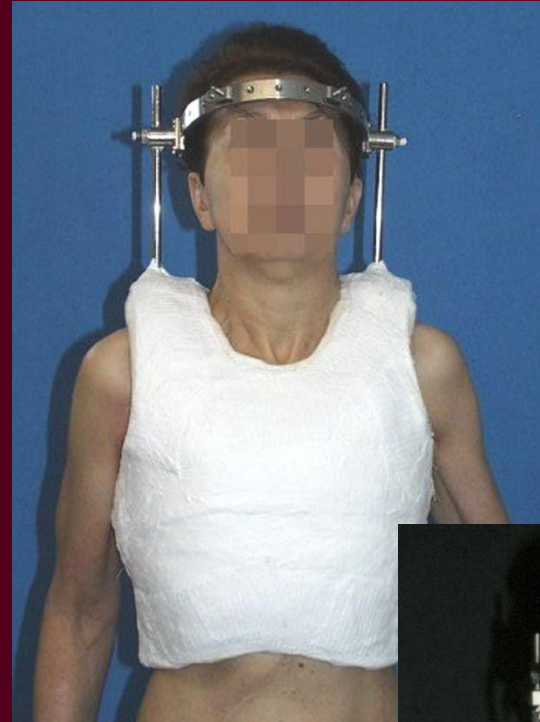
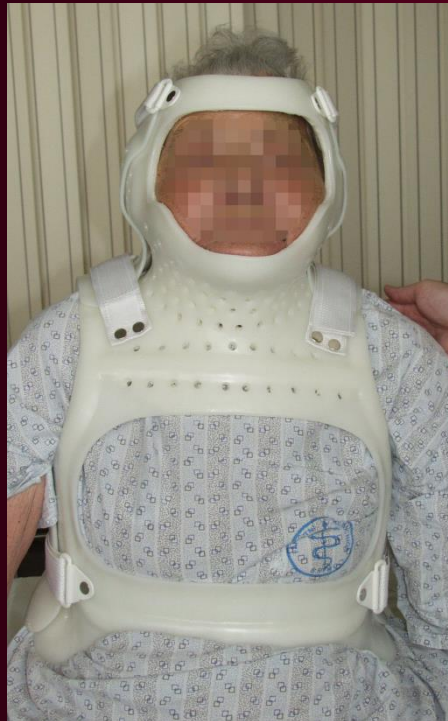
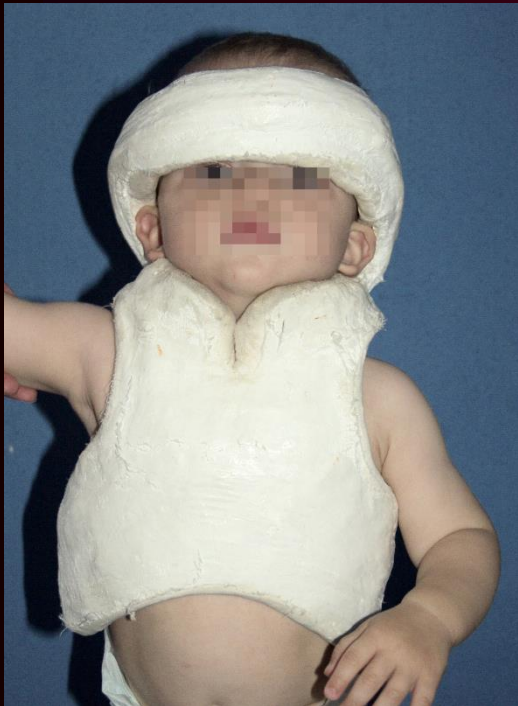CONSERVATIVE TREATMENT

-plaster casts

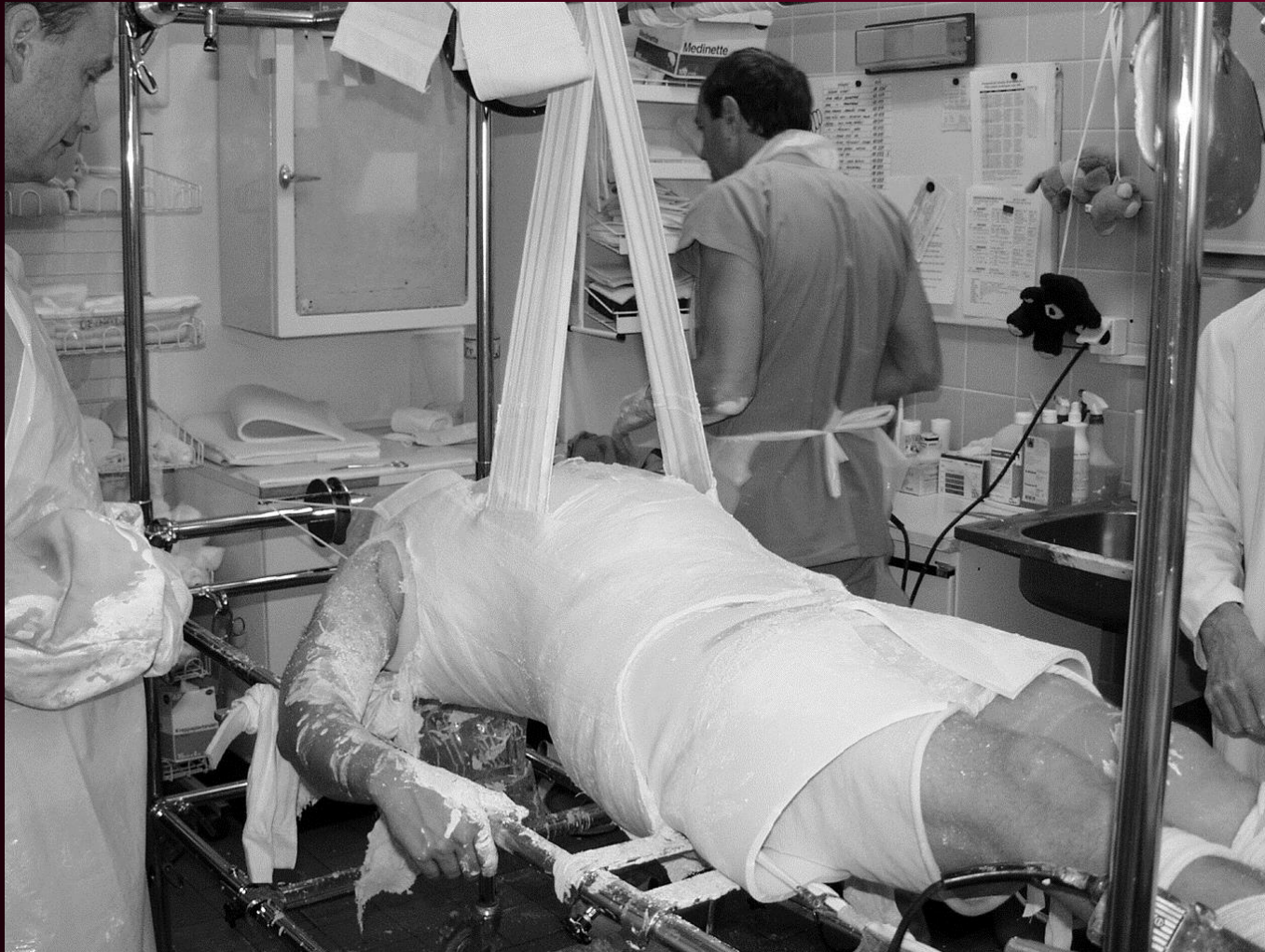C spine

- halo-cast, halo-vest
- Minerva cast / vest



CONSERVATIVE TREATMENT

-plaster cast



SURGICAL THERAPY

- **DECOMPRESSION OF NEUROLOGICAL STRUCTURES**
- **REDUCTION OF DEFORMITY**
- **HEALING WITH SOLID FUSION**

SURGICAL THERAPY

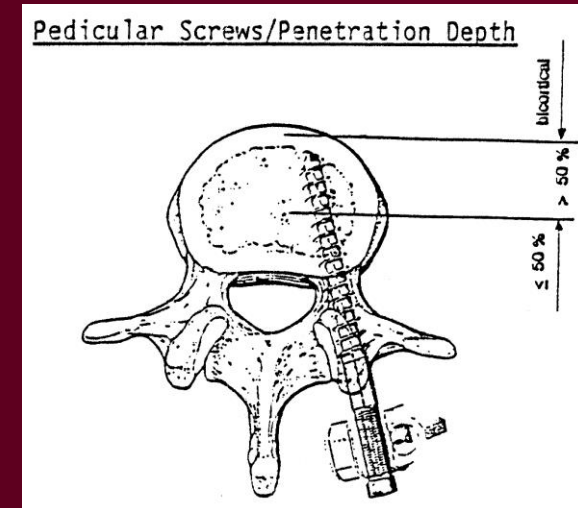
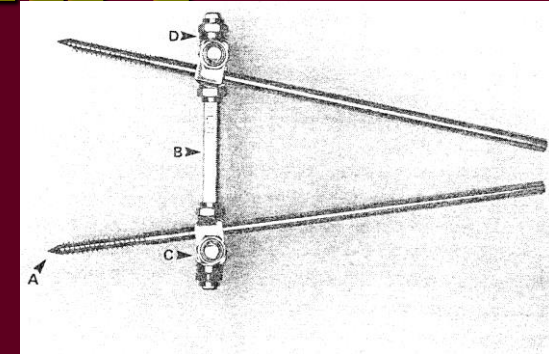
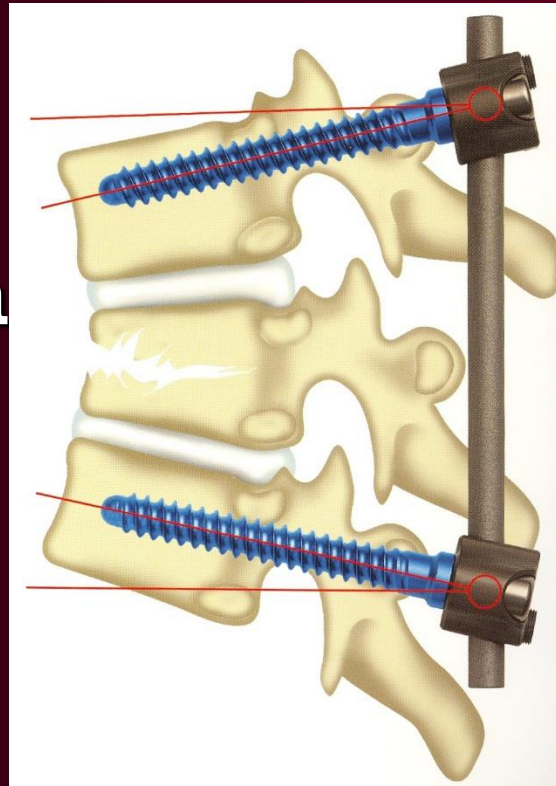
acute period

- **C spine**
 - **anterior surgery**

- **T, L spine**
 - **posterior surgery**

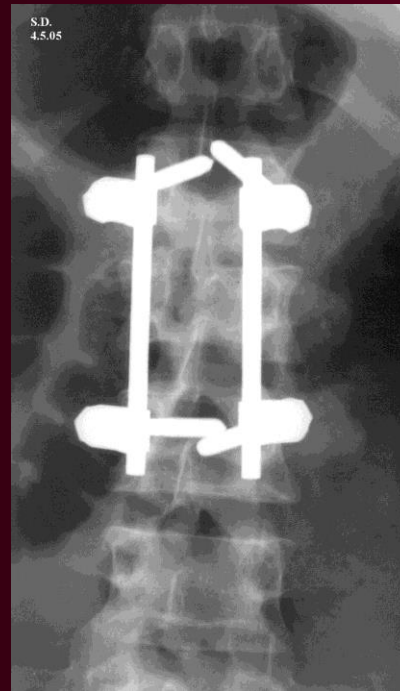
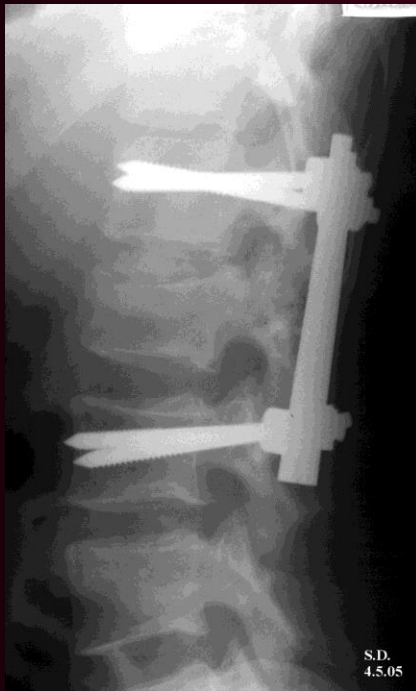
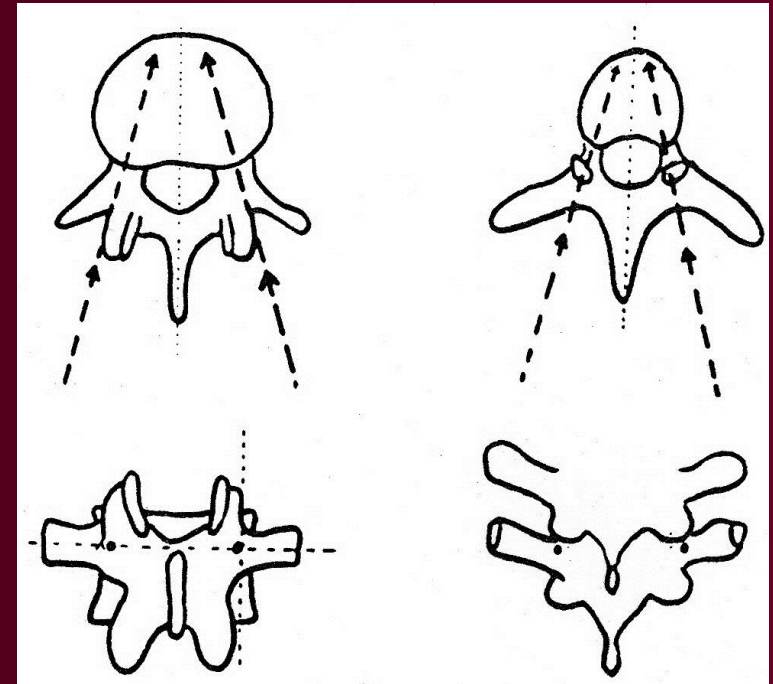
BASIC PRINCIPLES OF SURGICAL THERAPY

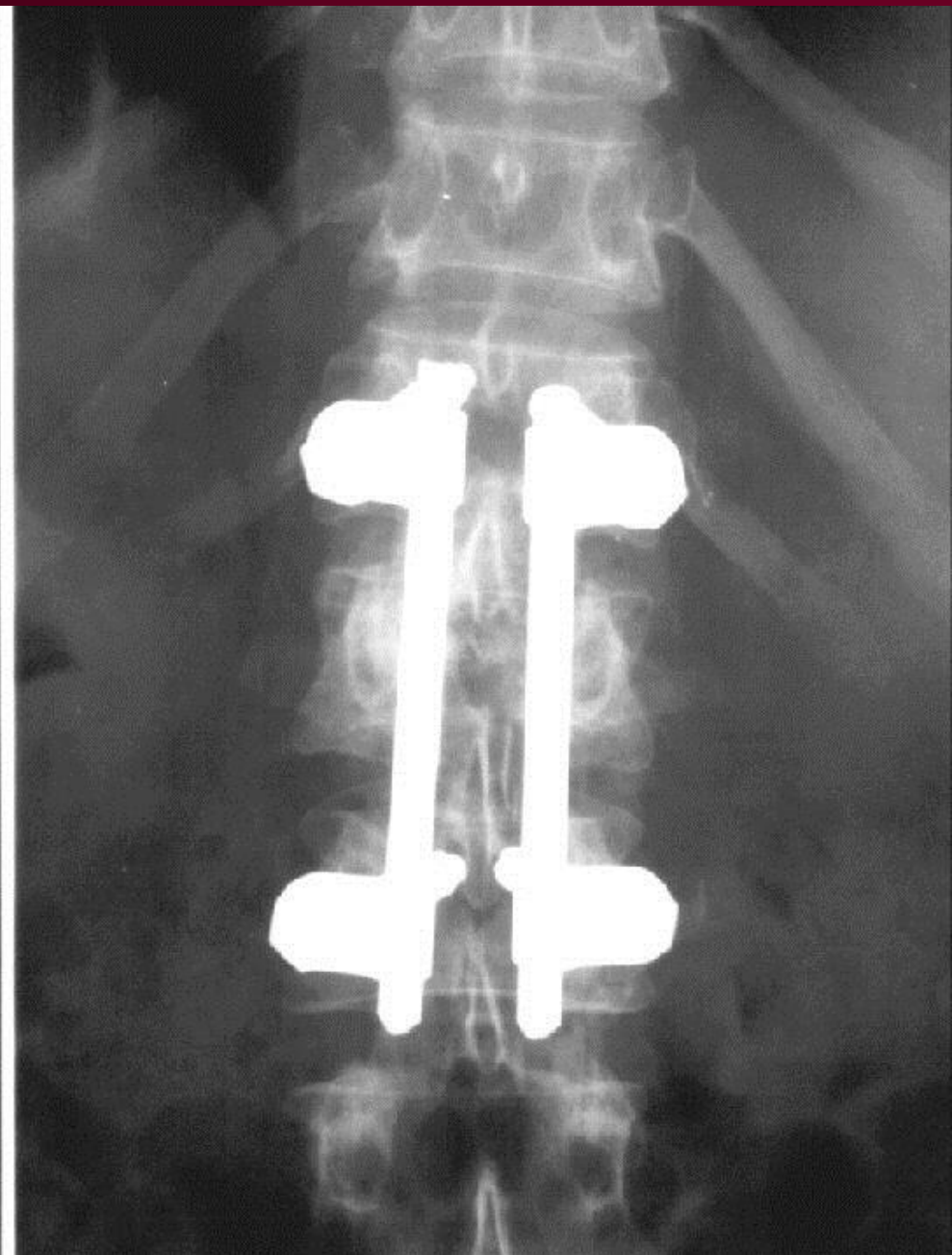
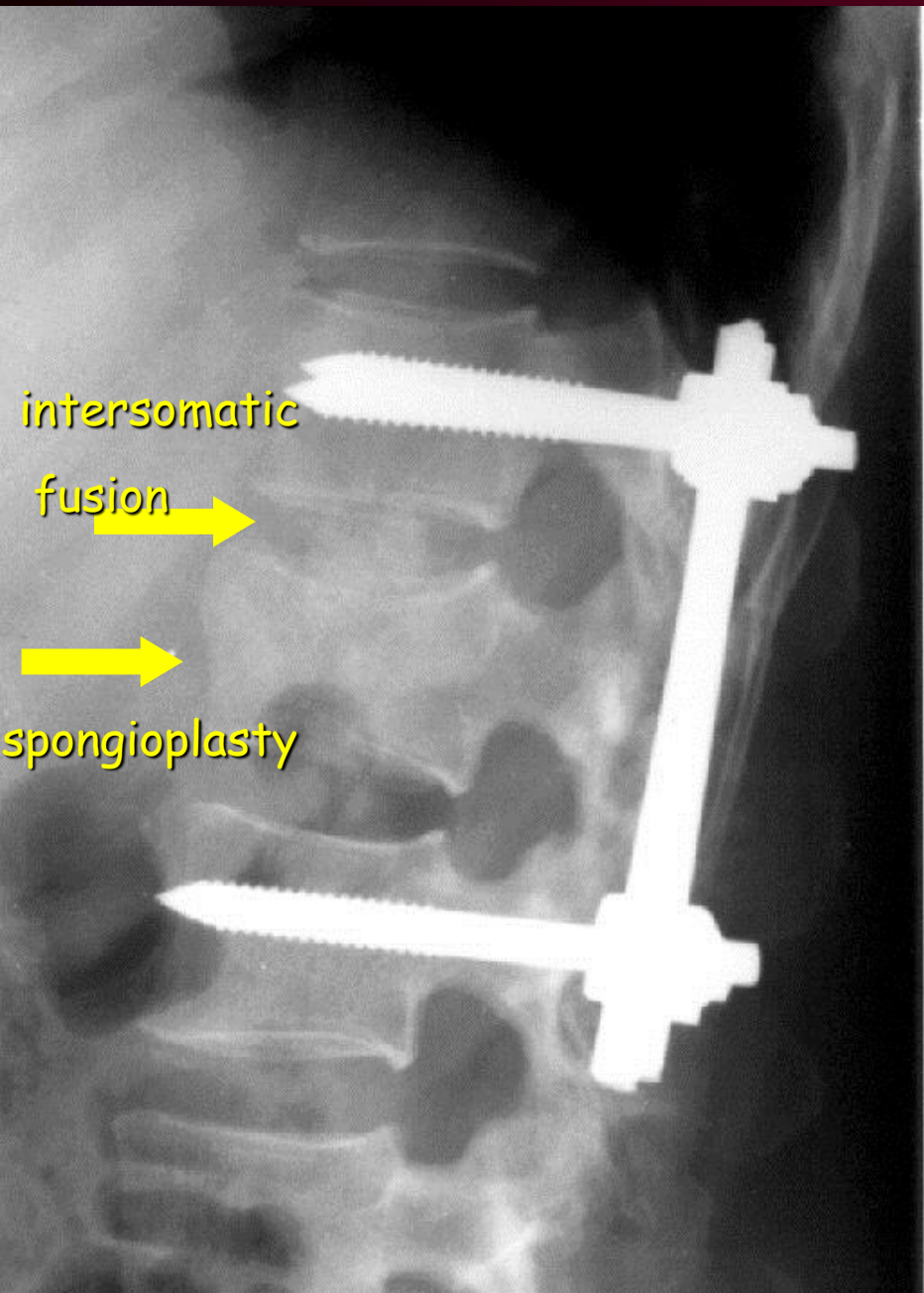
- reduction
- lordotisation
- stabilisation



POSTERIOR APPROACH TO THE T-L SPINE

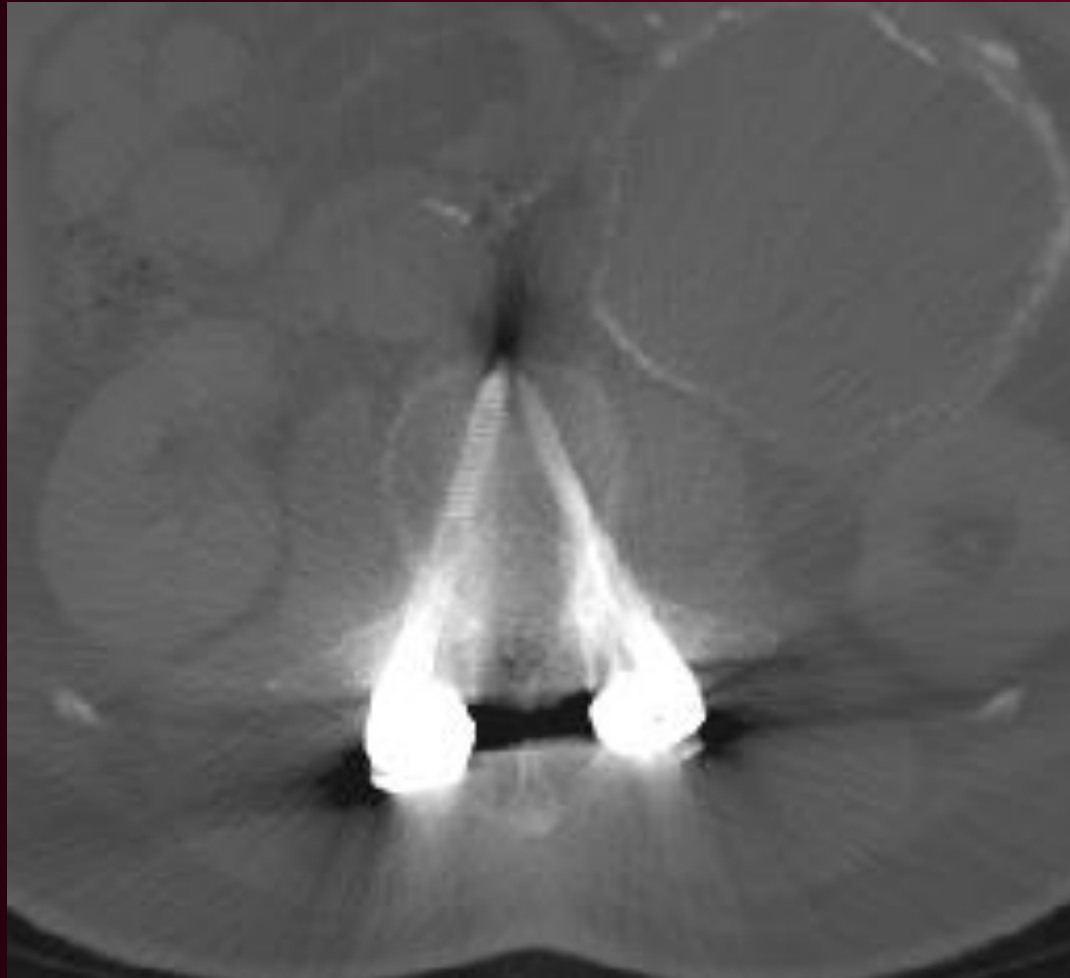
- Pedicle screws
- Bones
- Rods
- Cross-links

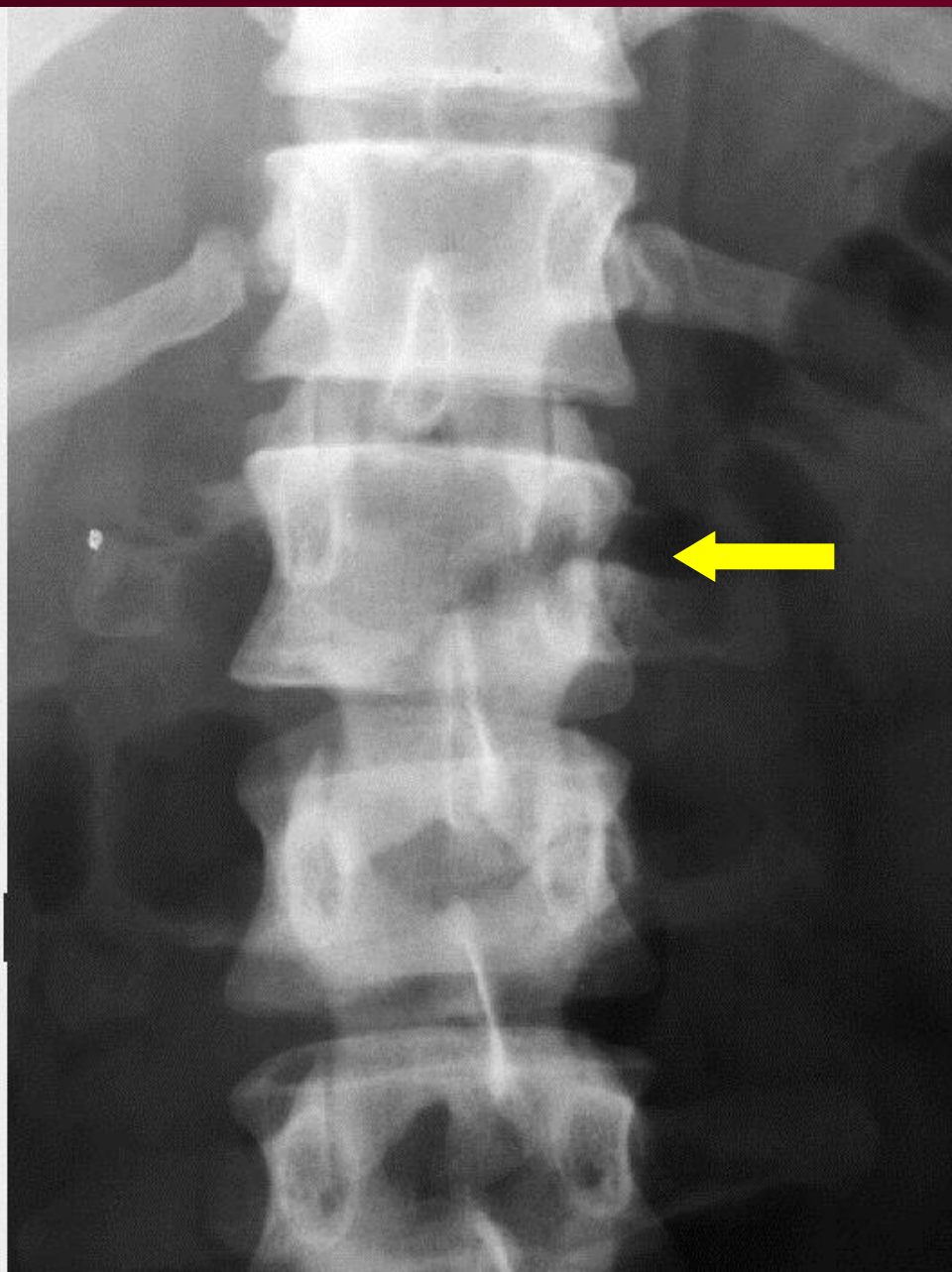
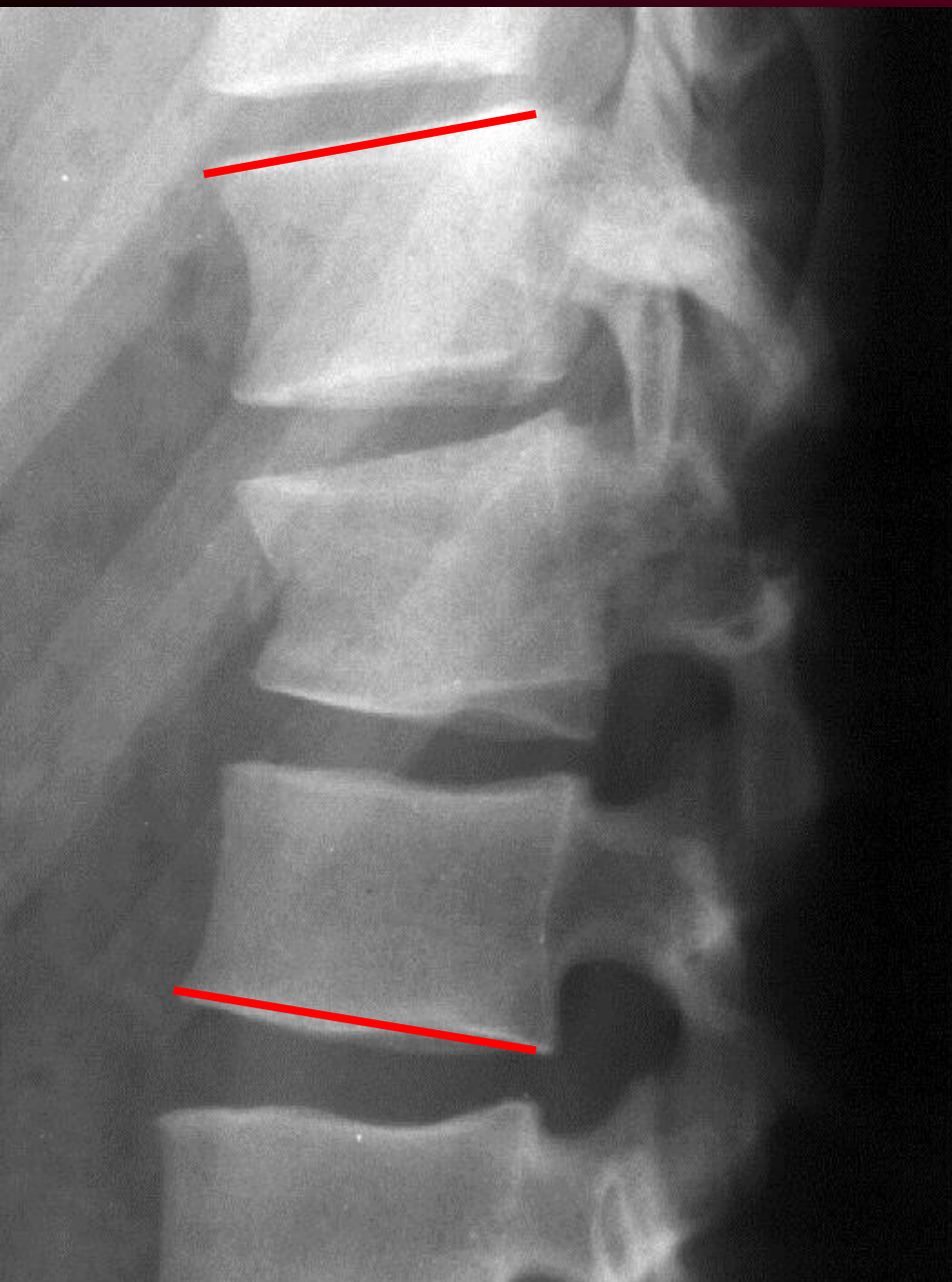


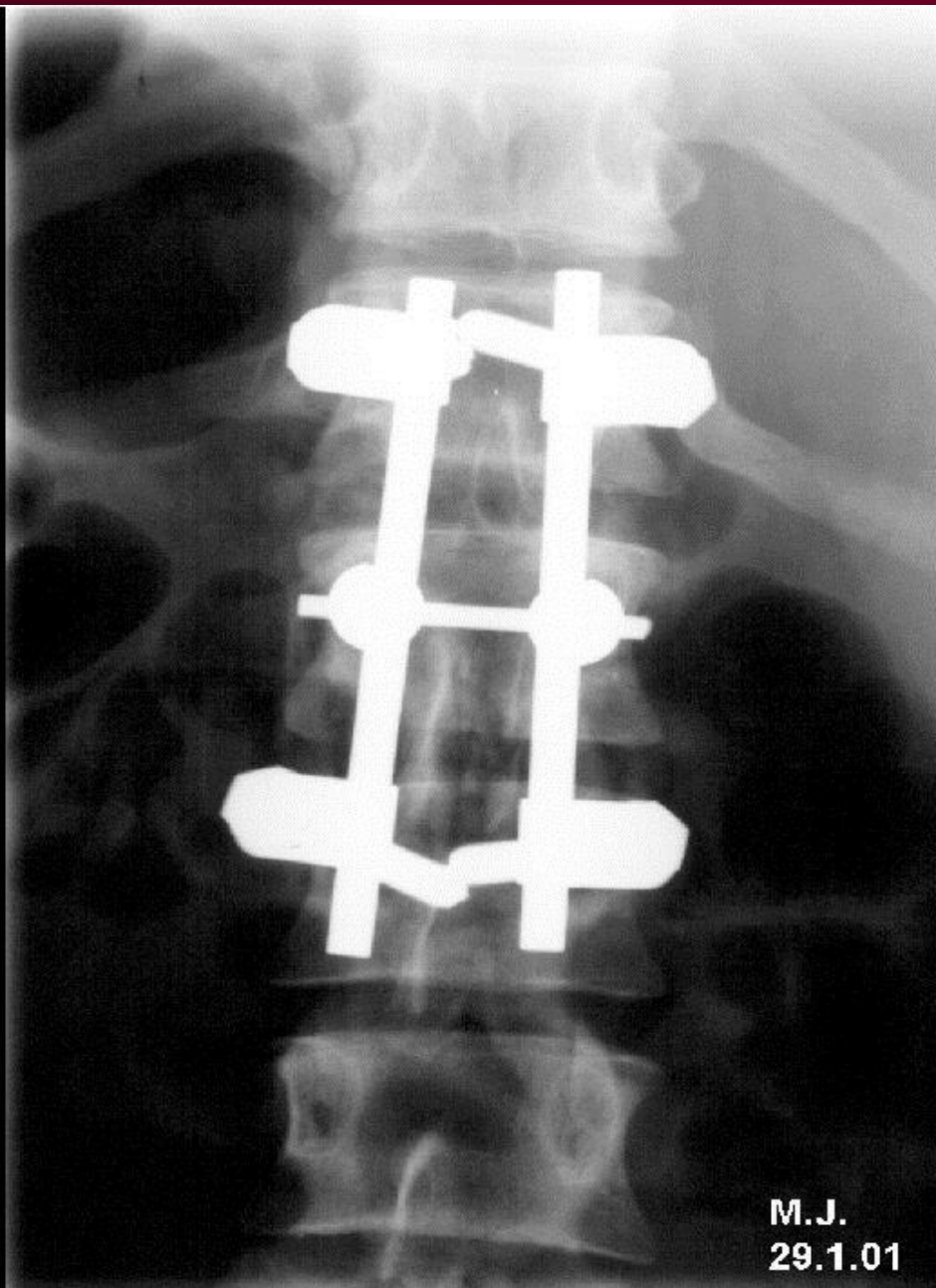
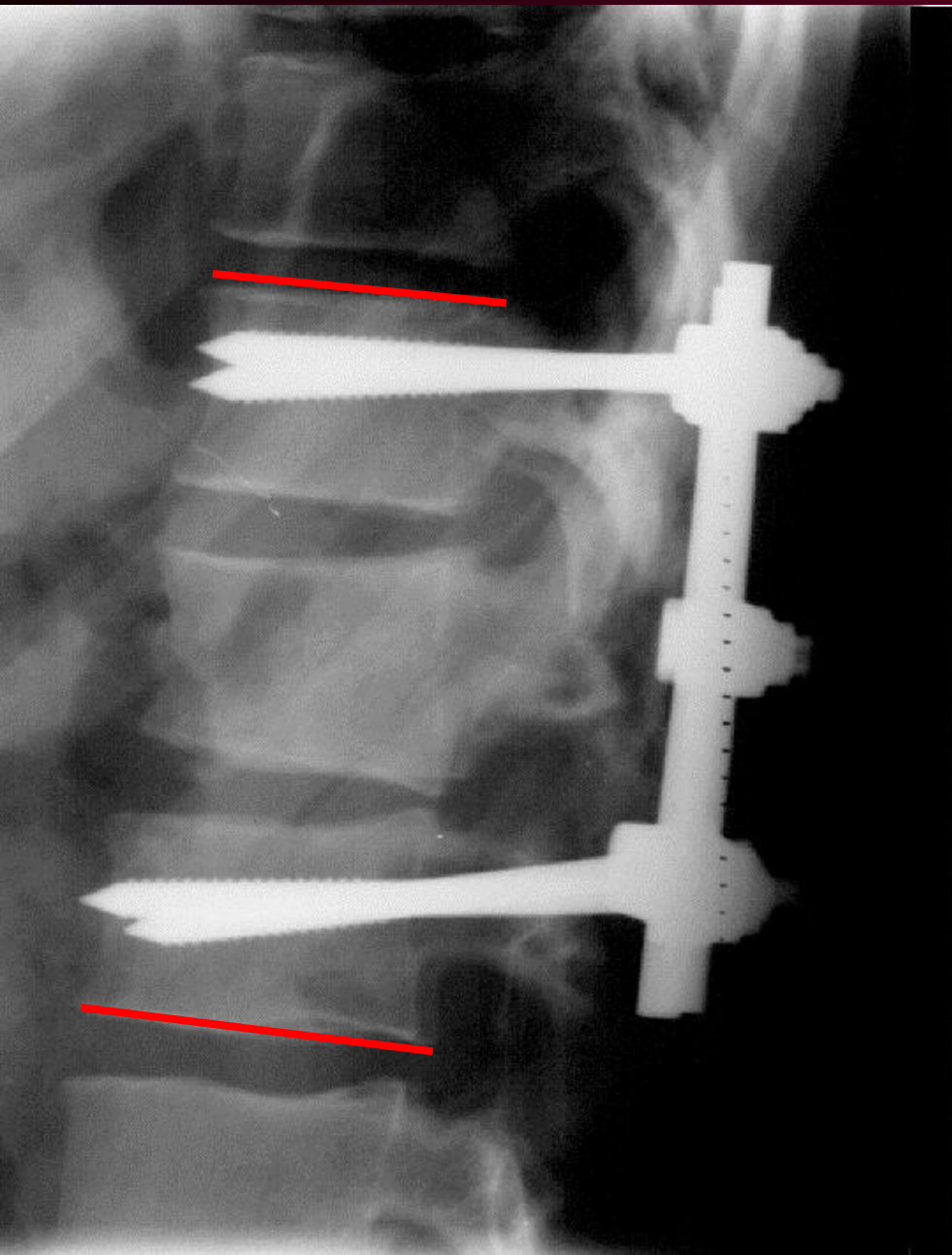


POSTERIOR STABILISATION OF THE SPINE

CT scan – TRANSPEDICULAR SCREWS



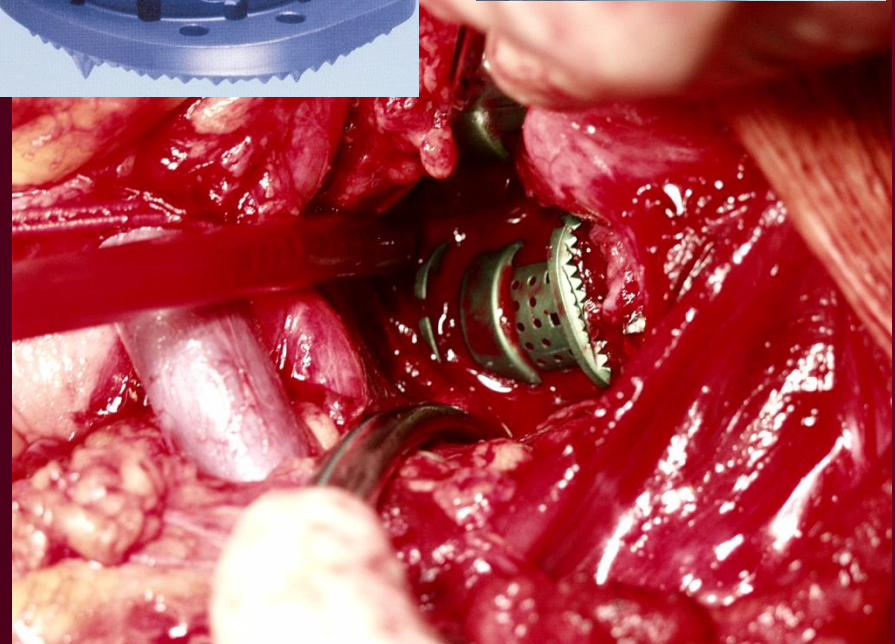
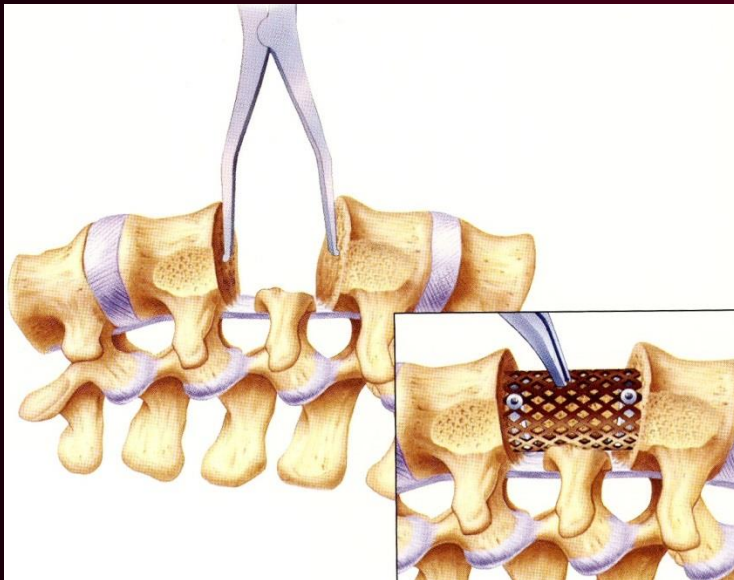
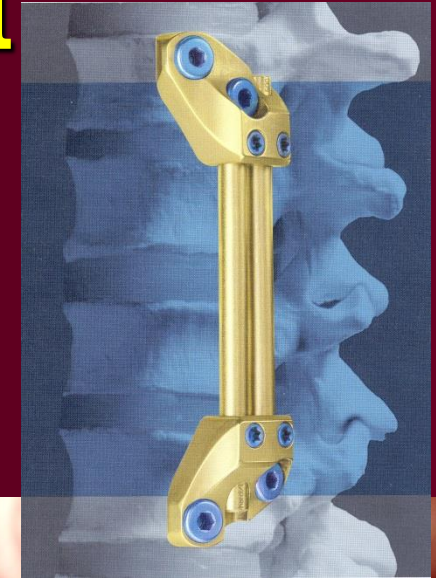


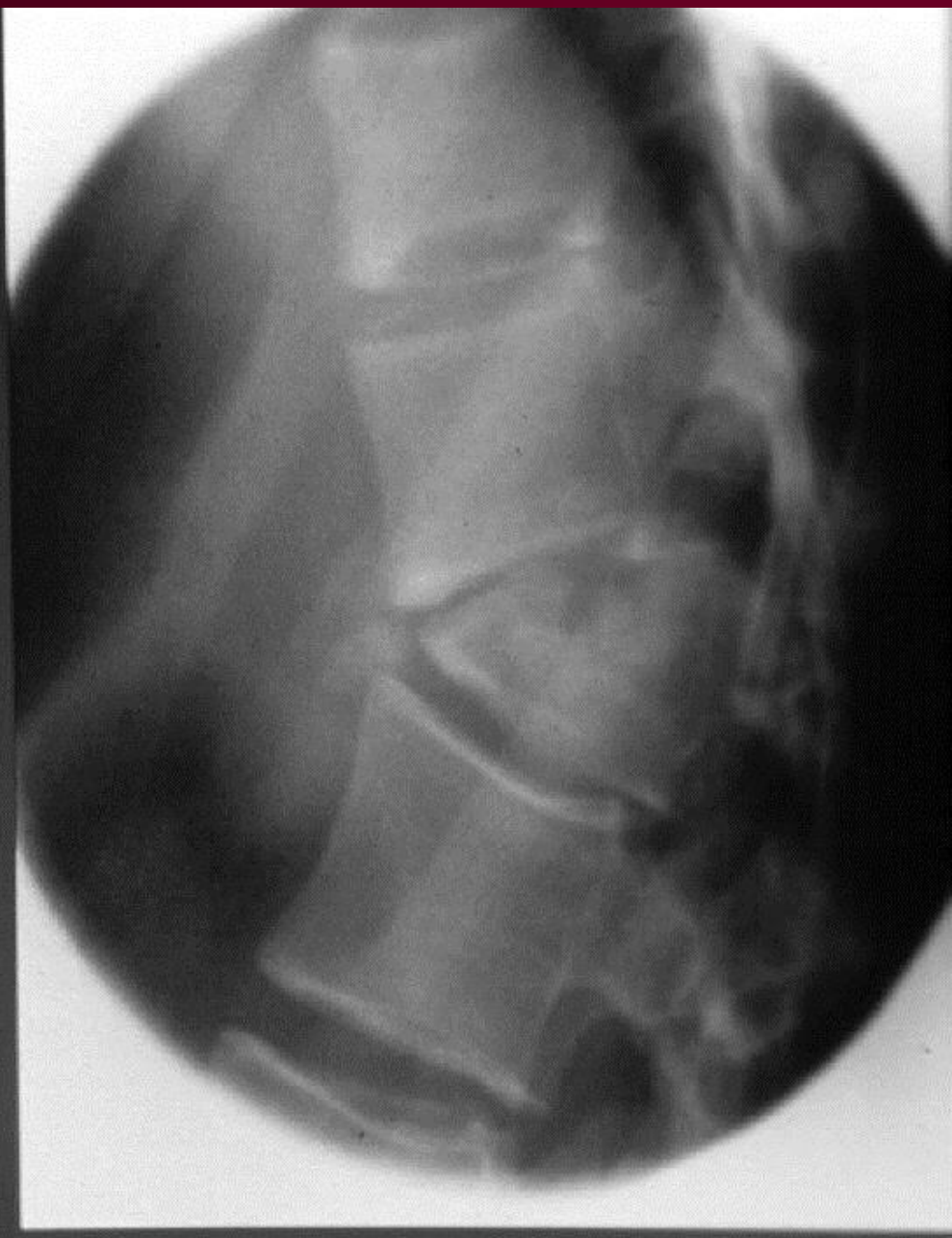
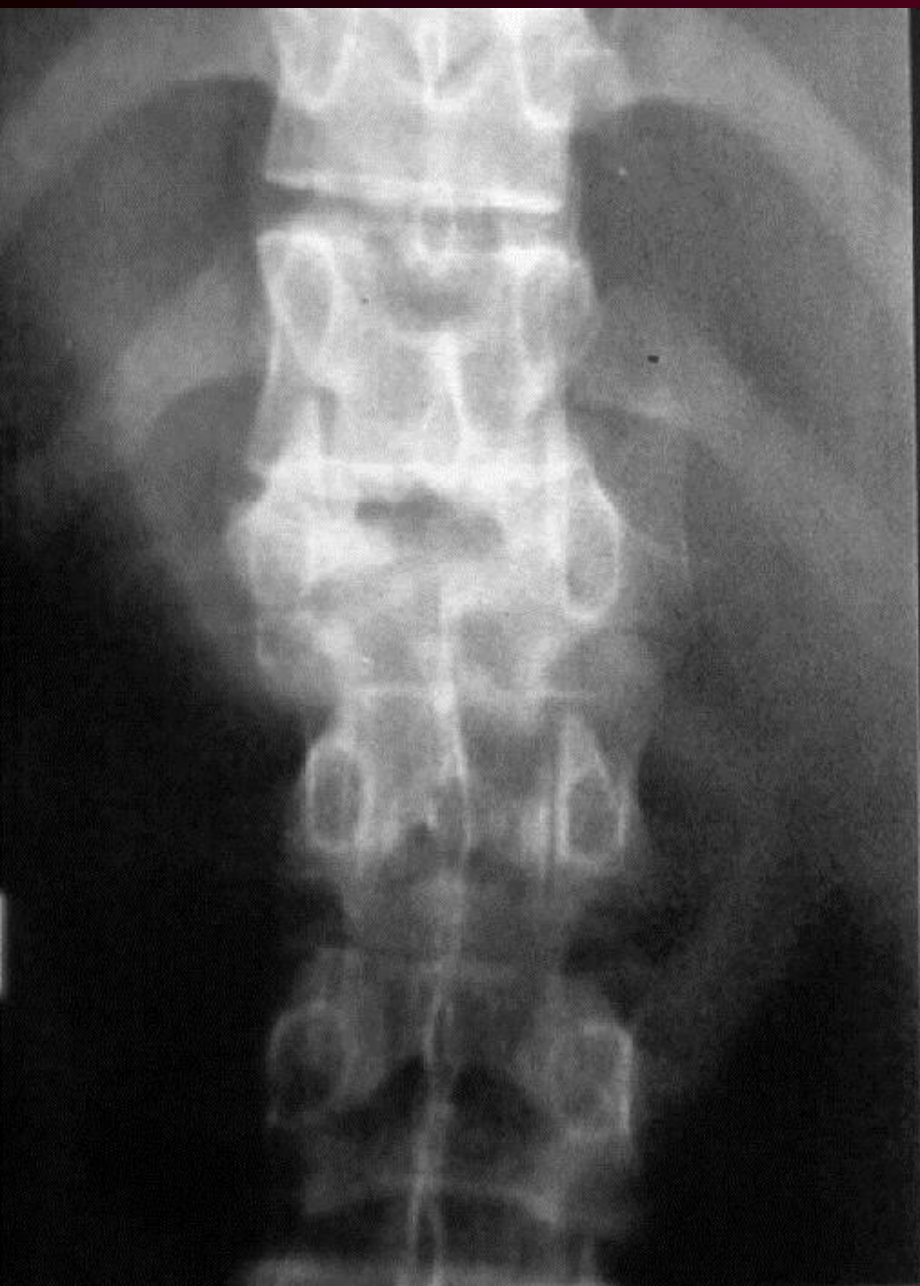
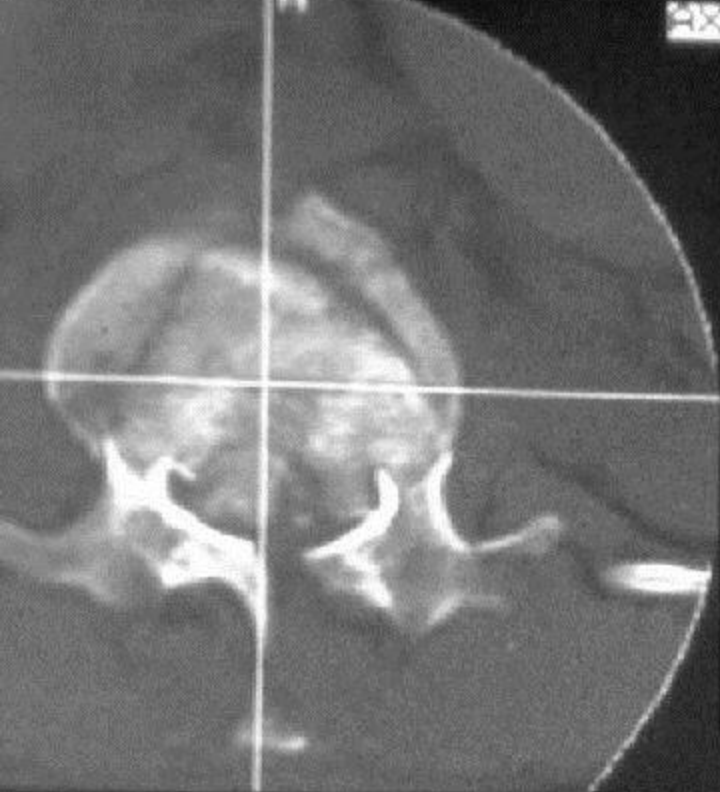M.J.
29.1.01

T-L SPINE – ANTERIOR SURGICAL APPROACH


- replacing the vertebral body
- stabilisation



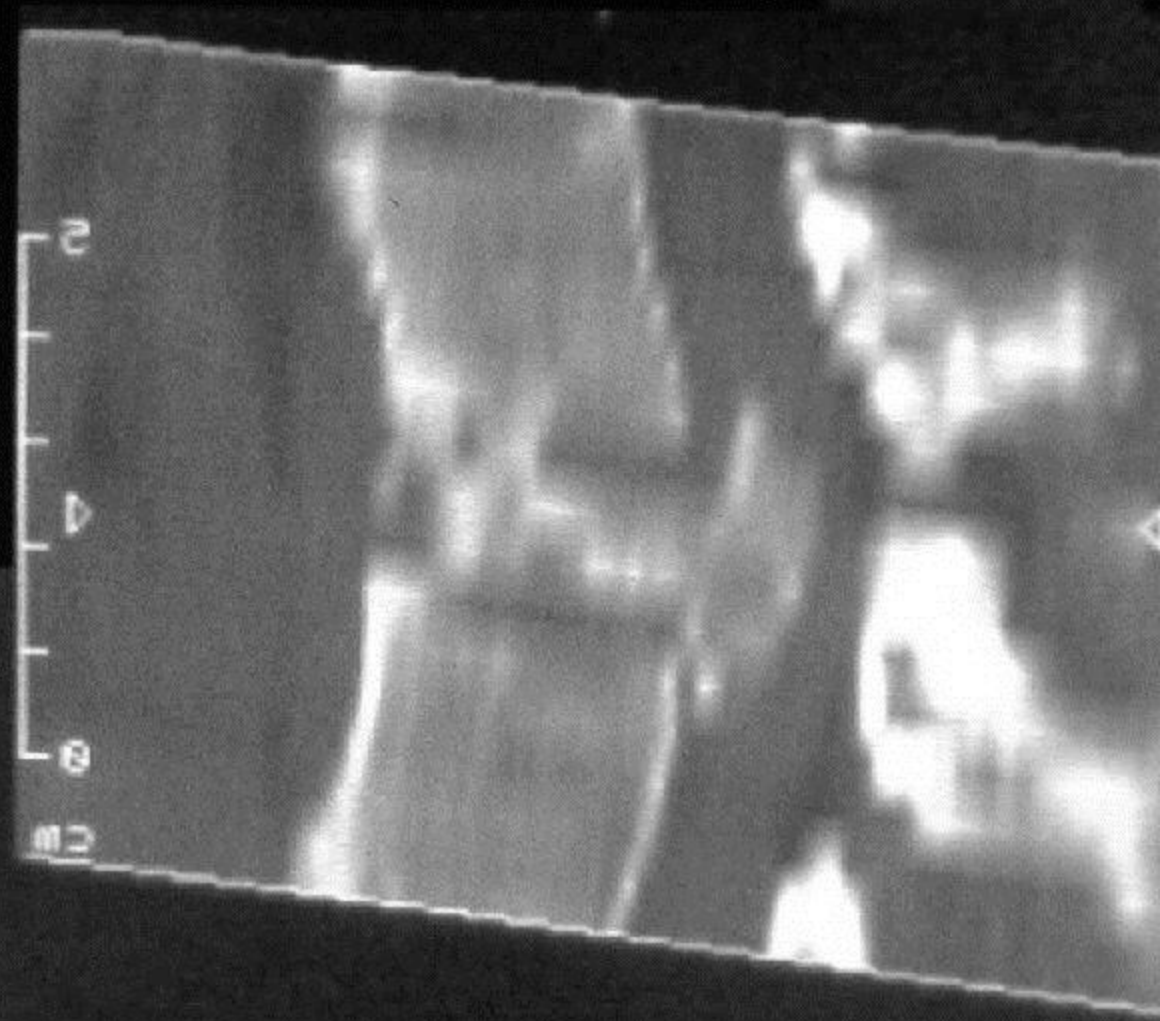




COR

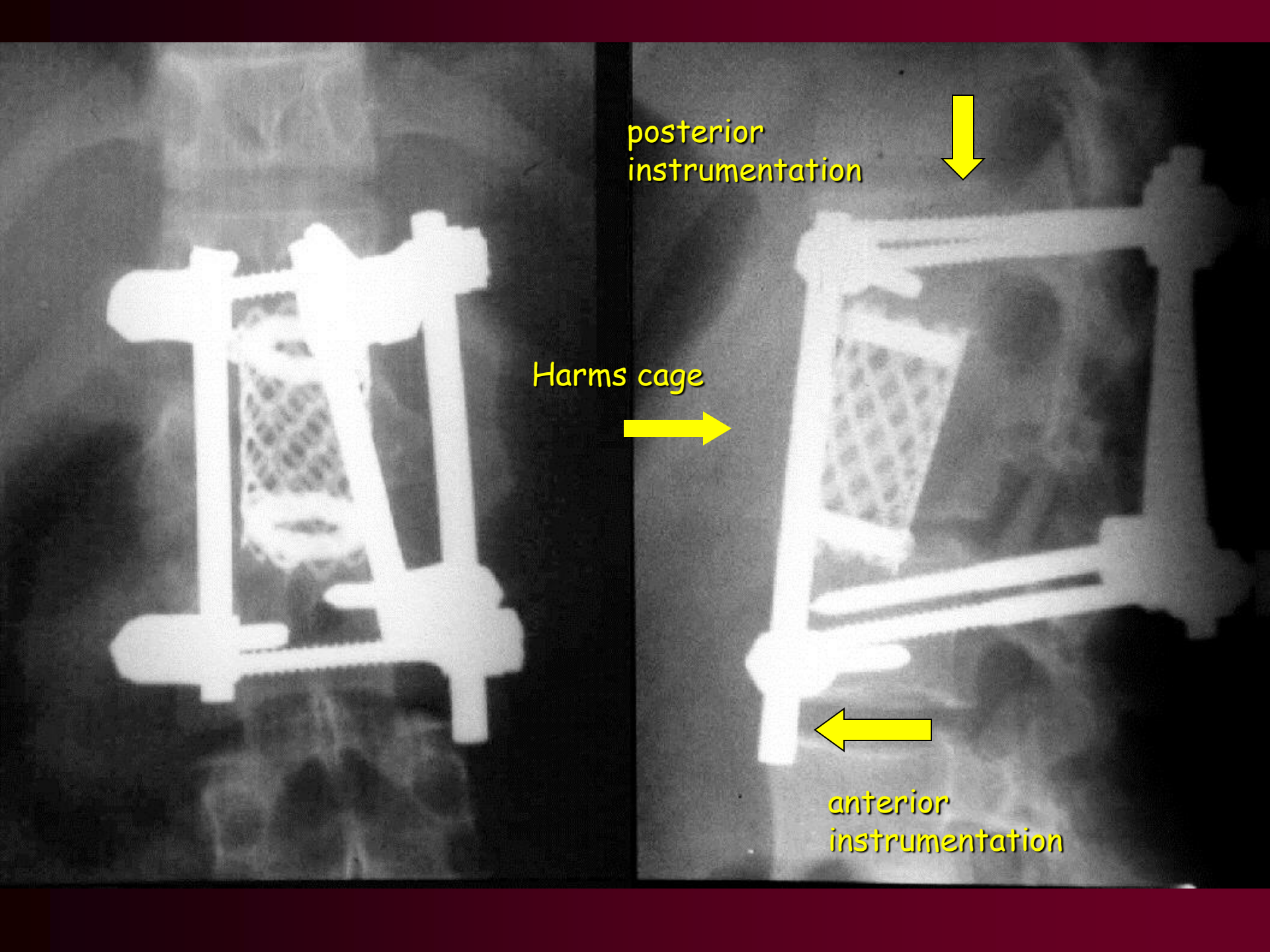


4



SAG

2
4
6
8
cm



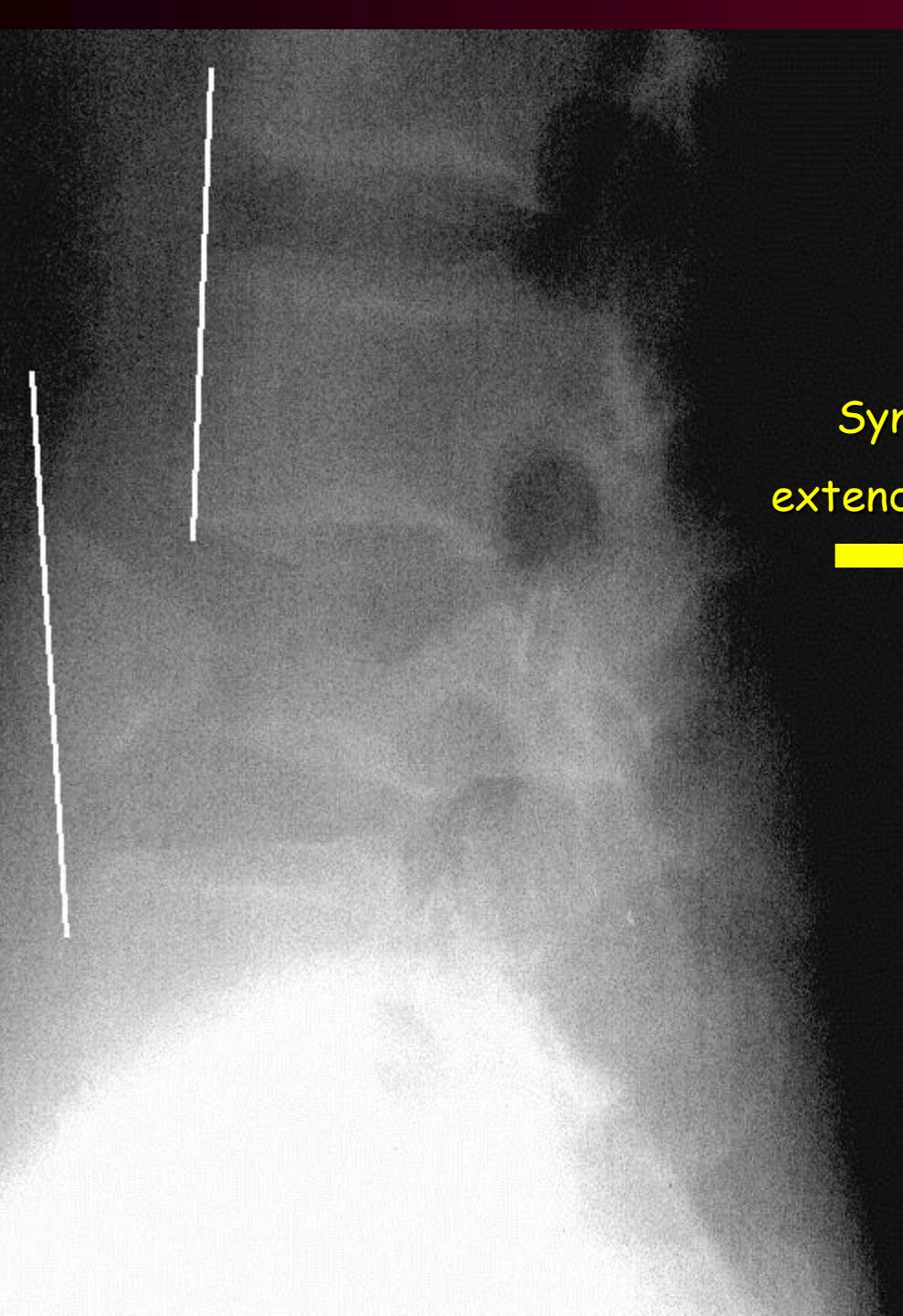
posterior
instrumentation




Harms cage



anterior
instrumentation

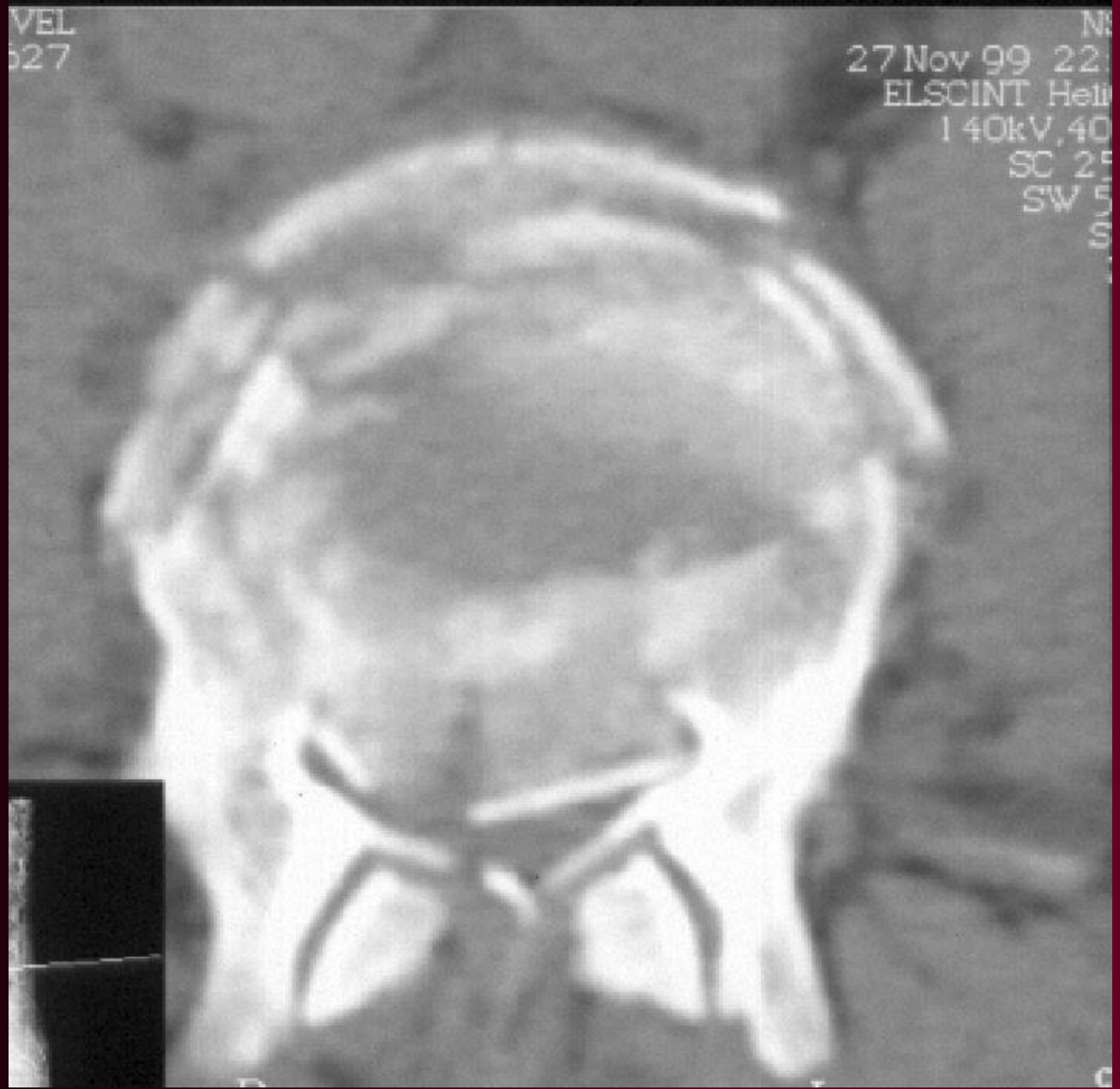


Synex
extended impl.

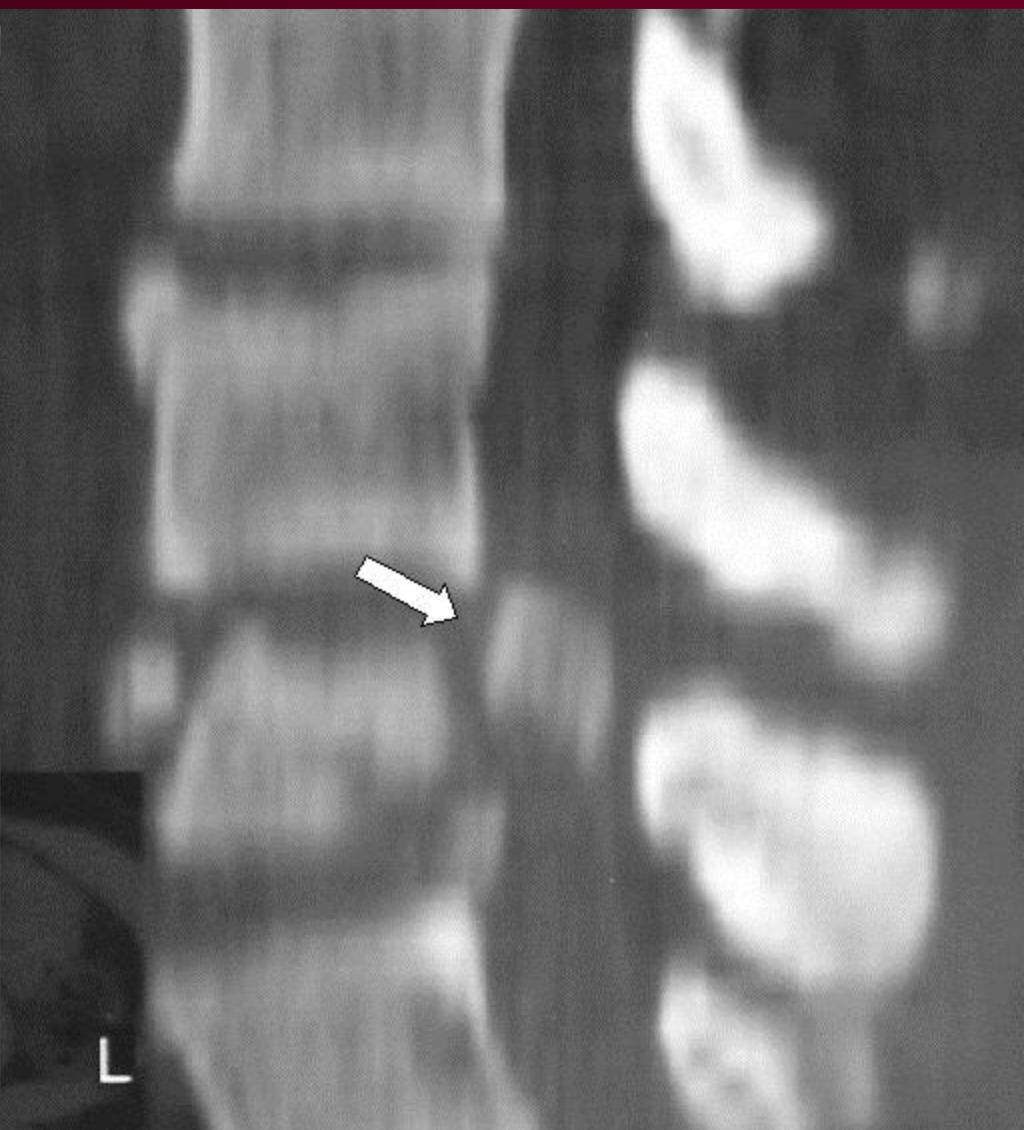
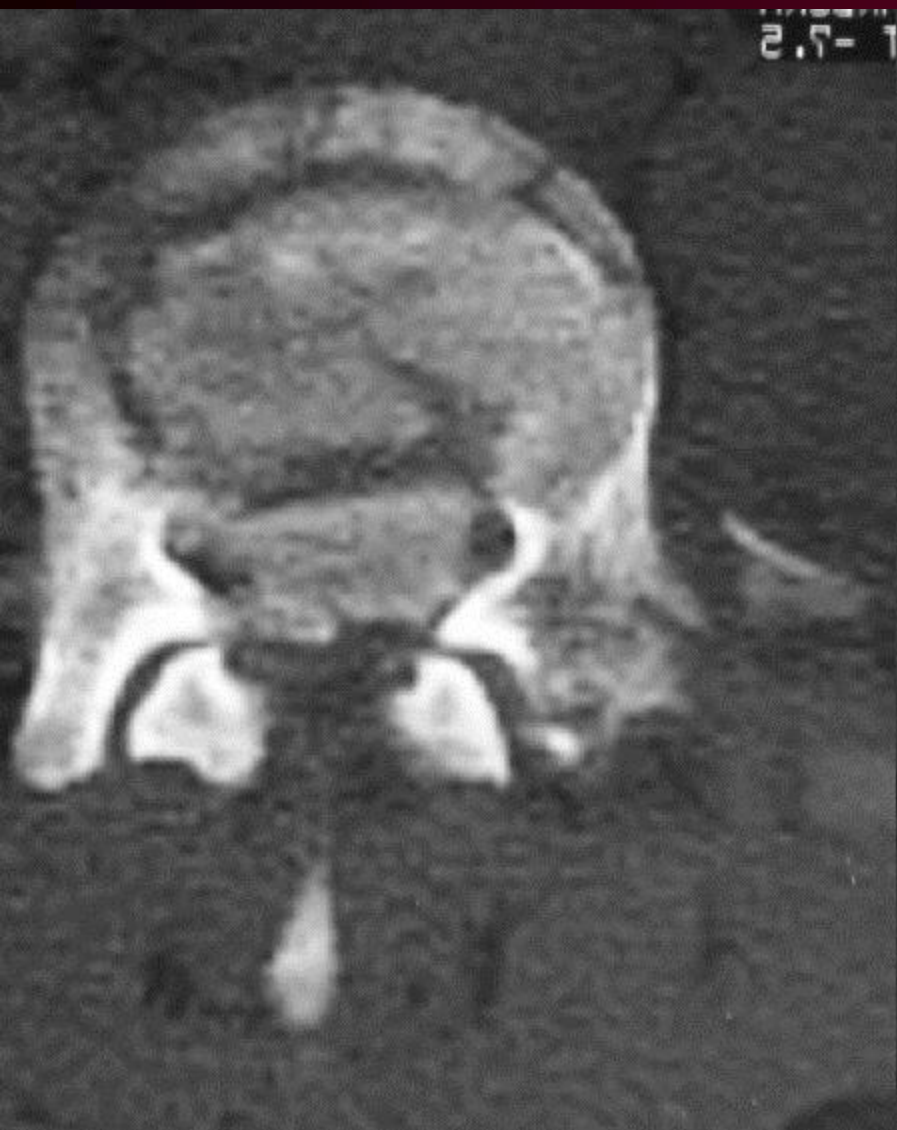
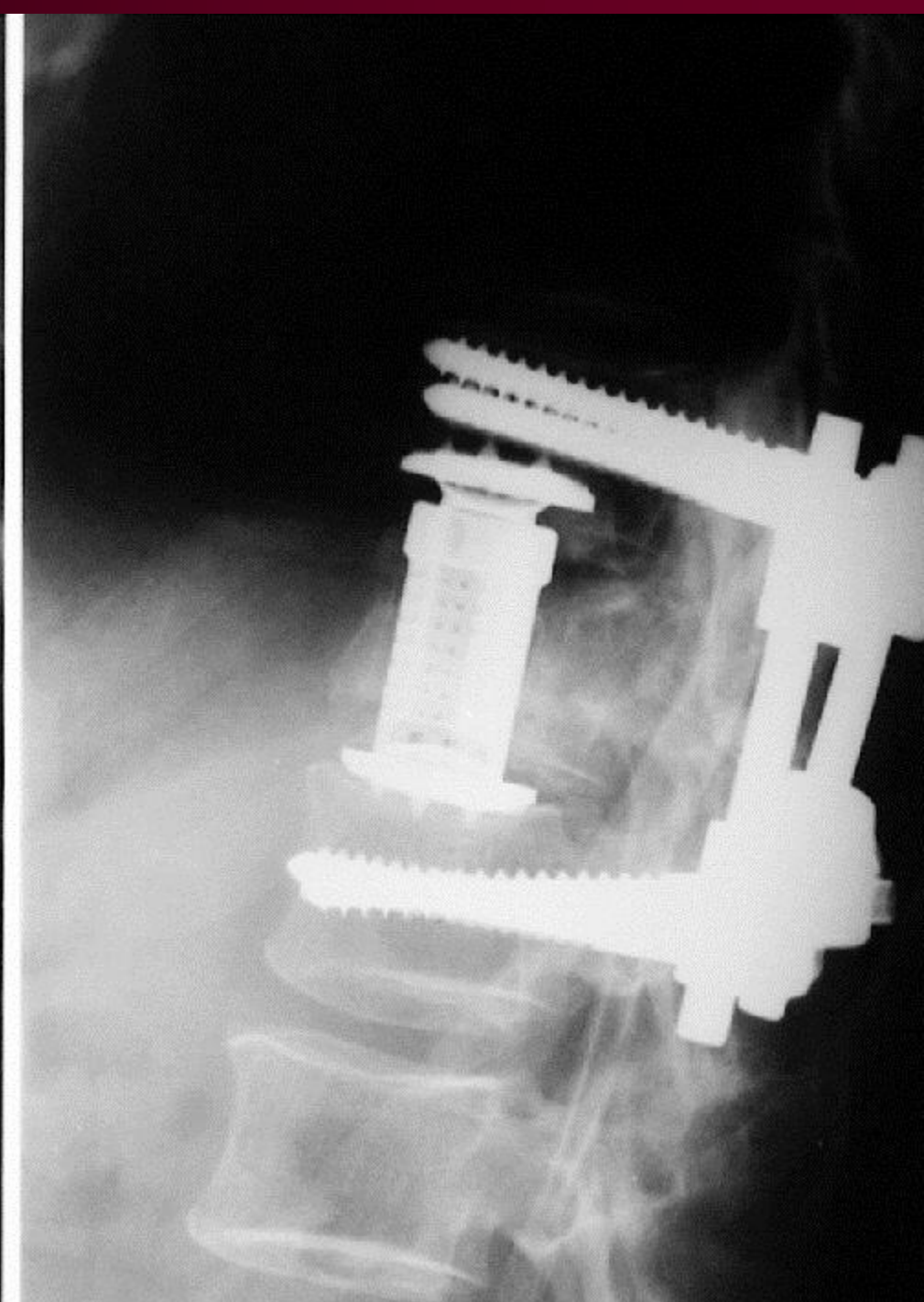
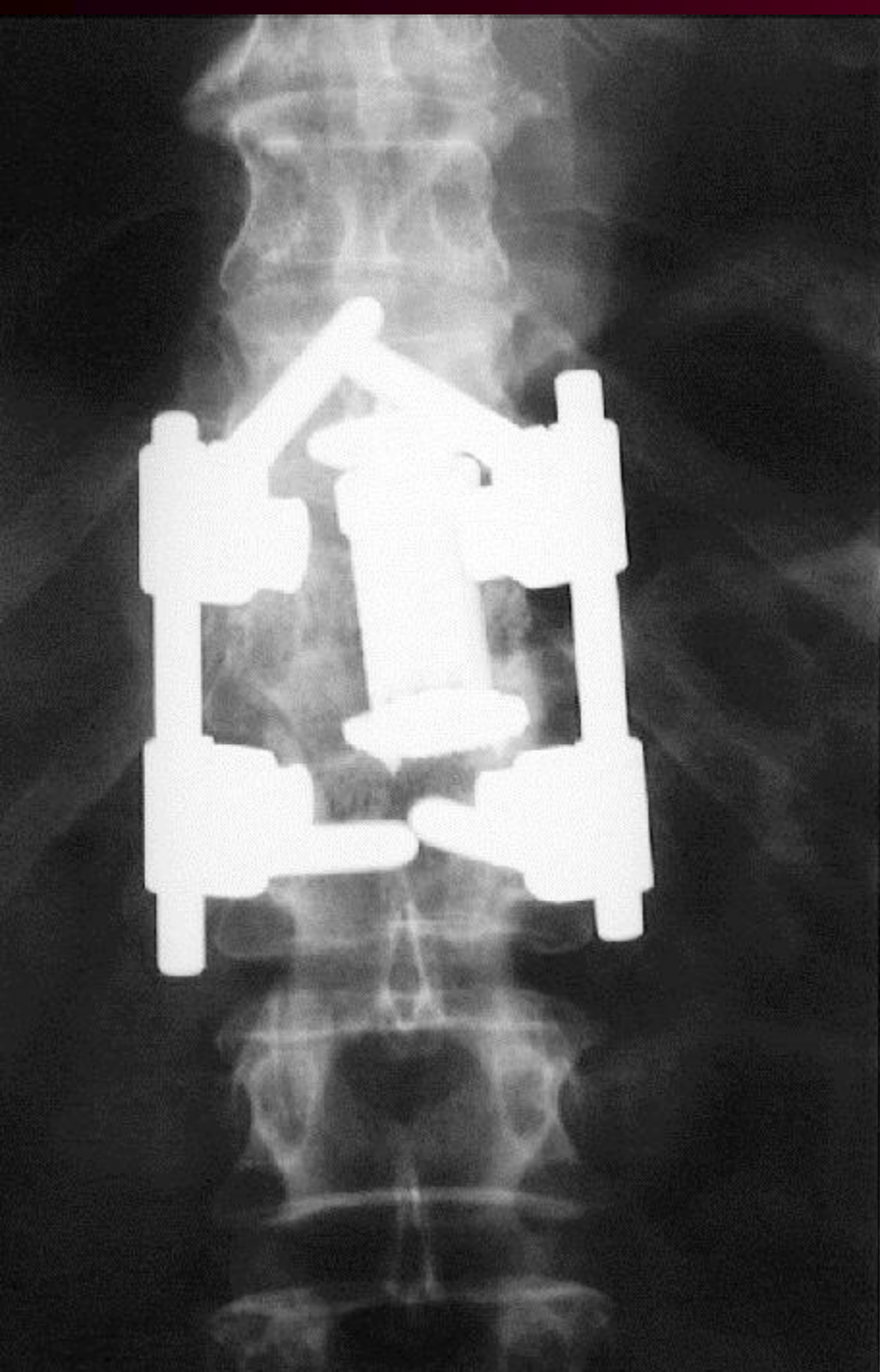
VEL
527

27 Nov 99 22:
ELSCINT Helio
140kV,40
SC 25
SW 5
S



C





C1,2 – SPINE INJURIES

Rare, big violence on OC a C-SPINE

Occipital fracture

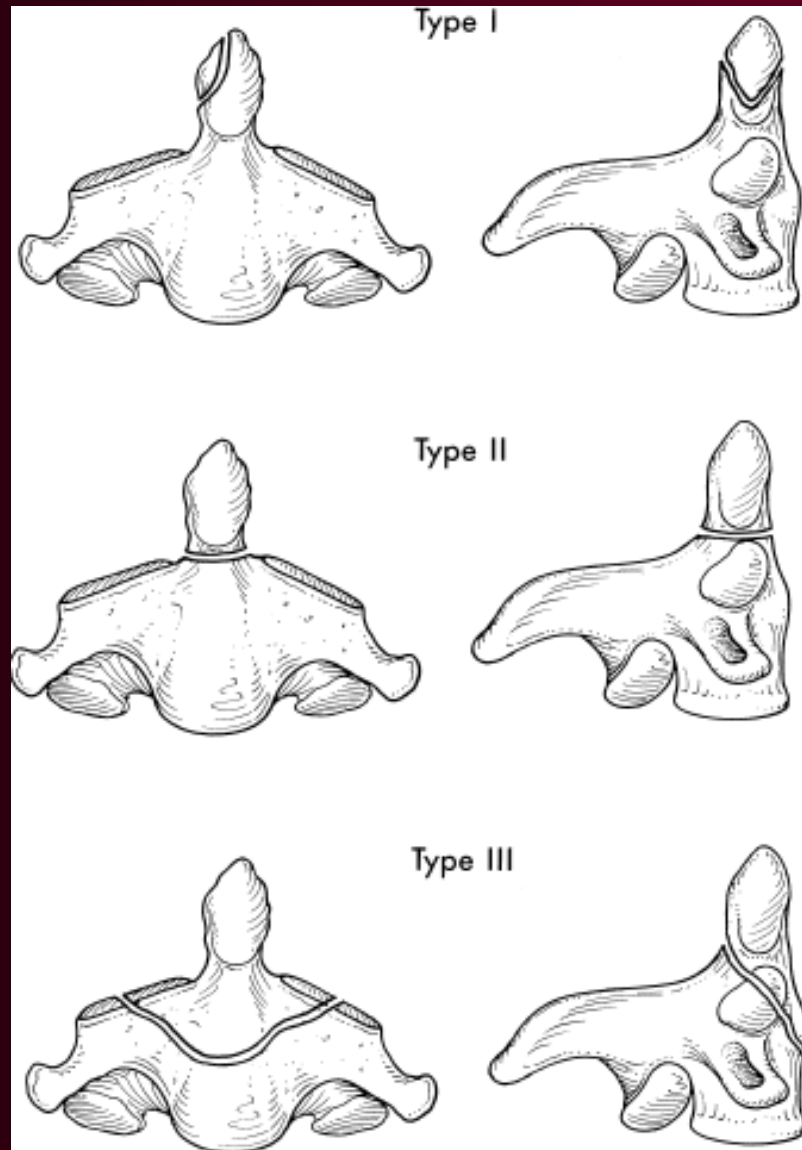
C-1 arch fracture

Odontoid C-2 fracture

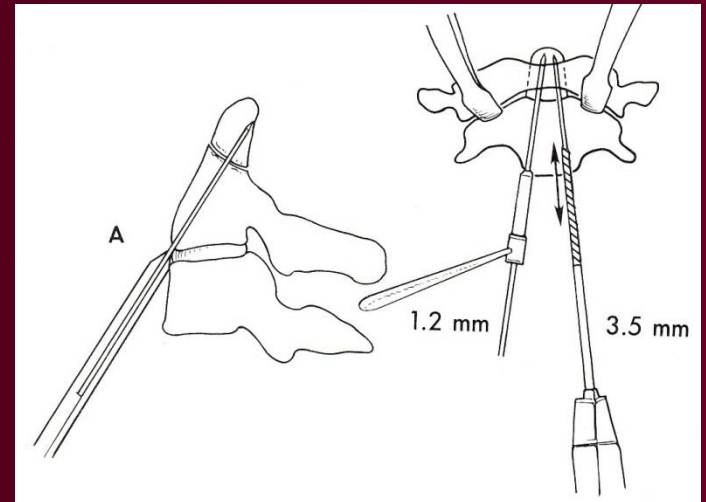
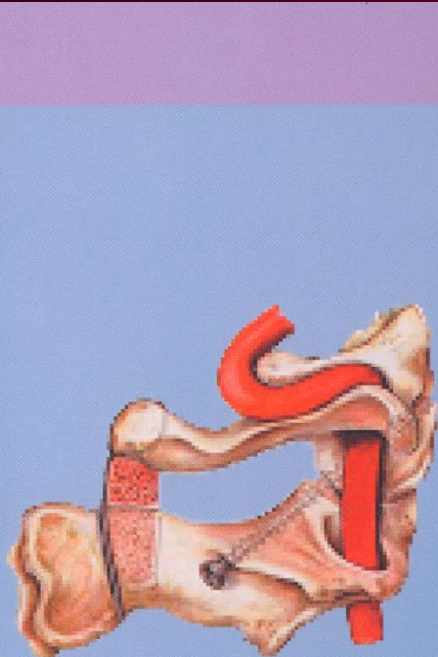
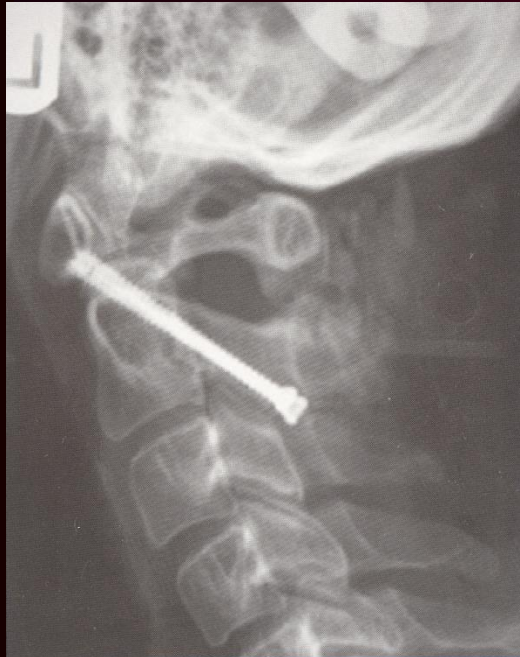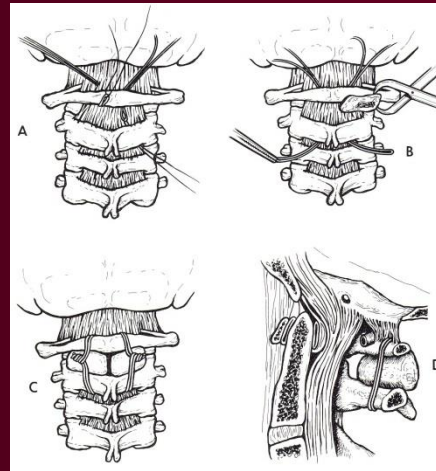
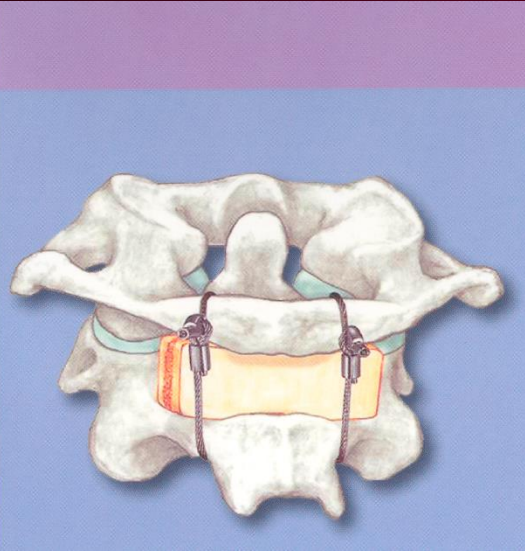
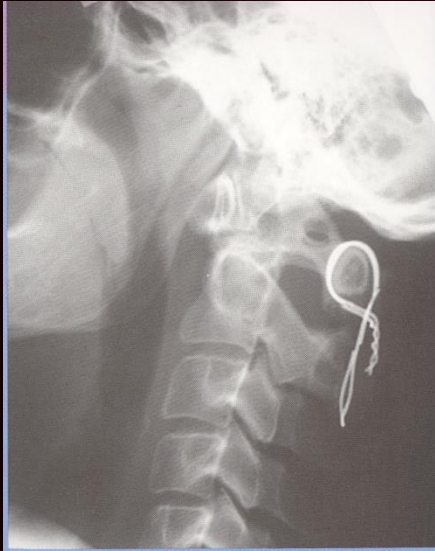Body C-2 fracture

CONSERVATIVE THERAPY

DENS FRACTURE

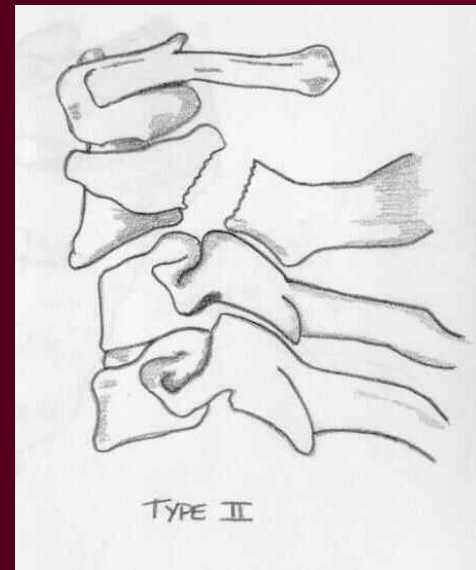
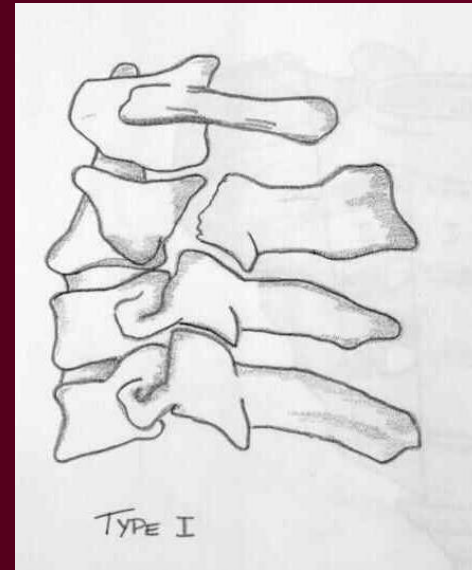
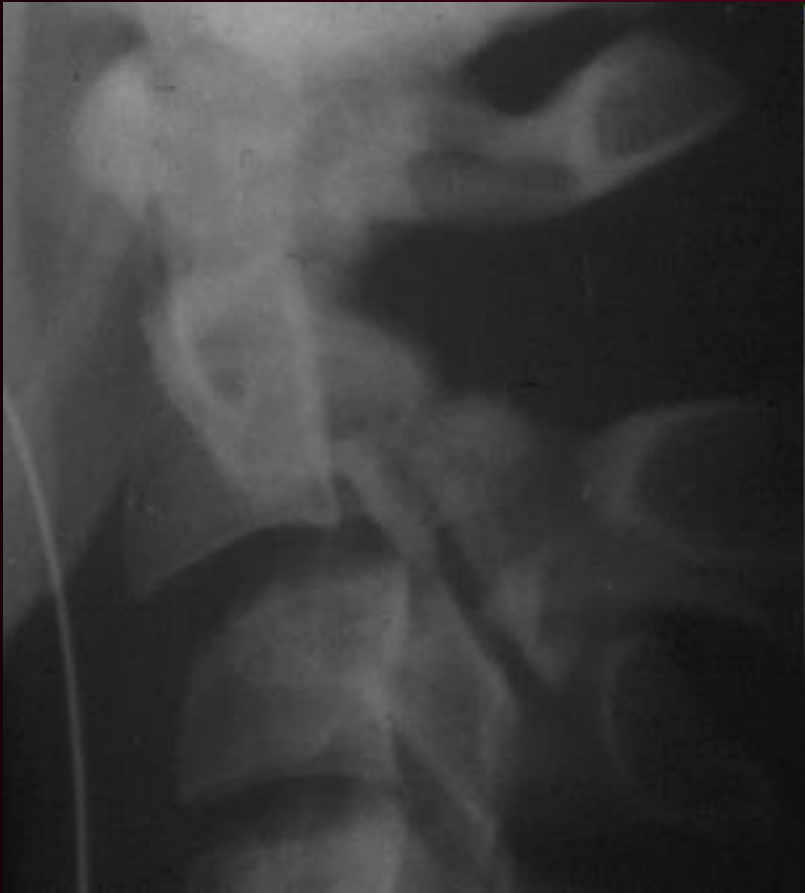

DENS FRACTURE

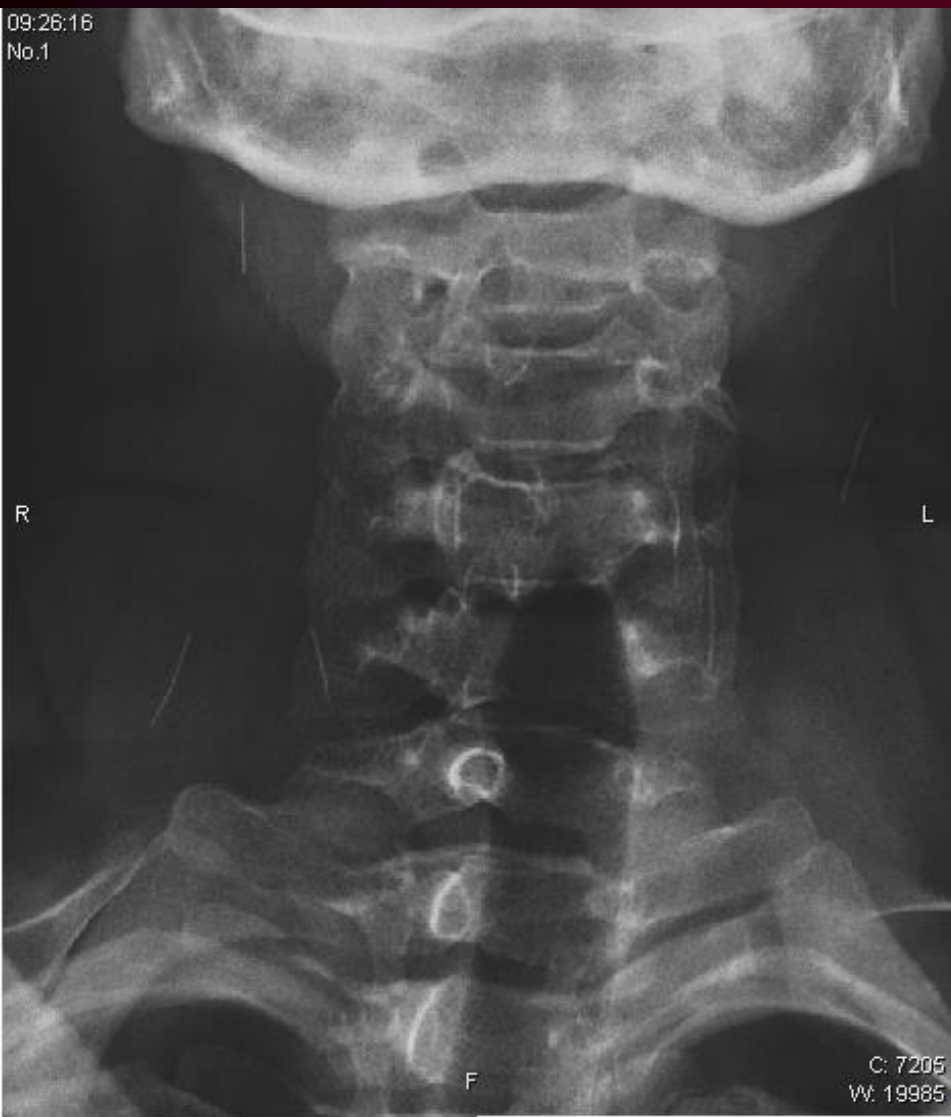

HANGMAN'S C-2 FRACTURE

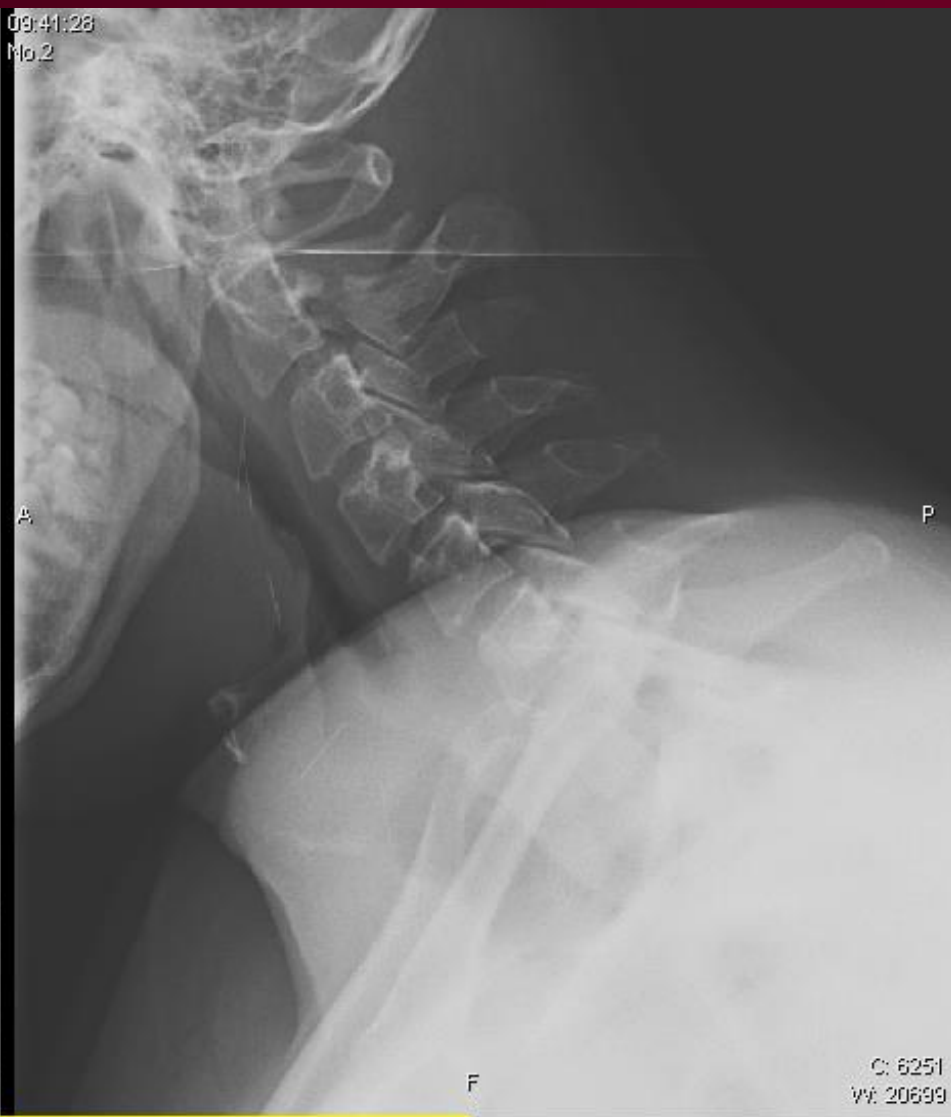TRAUMATIC SPONDYLOLISTHESIS OF AXIS



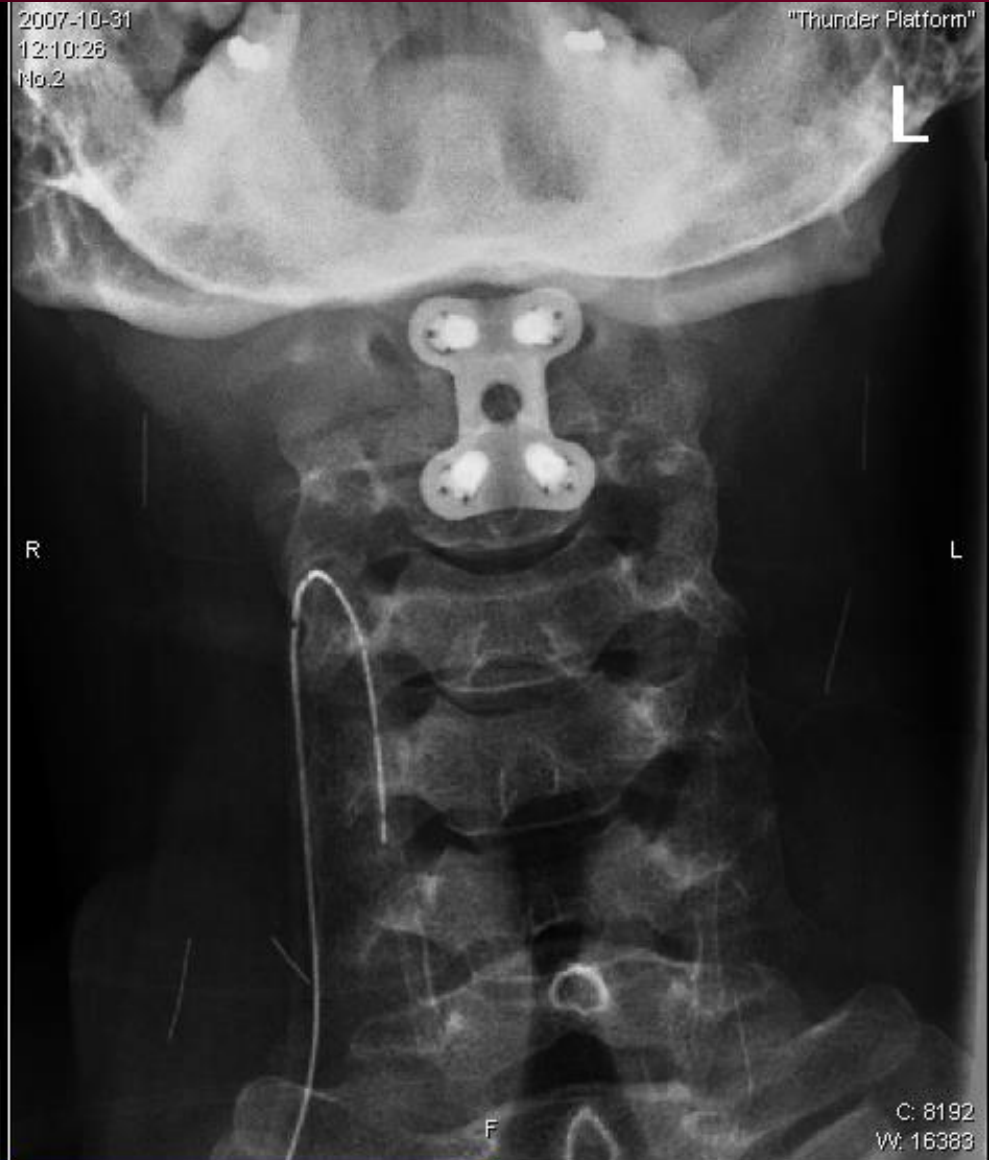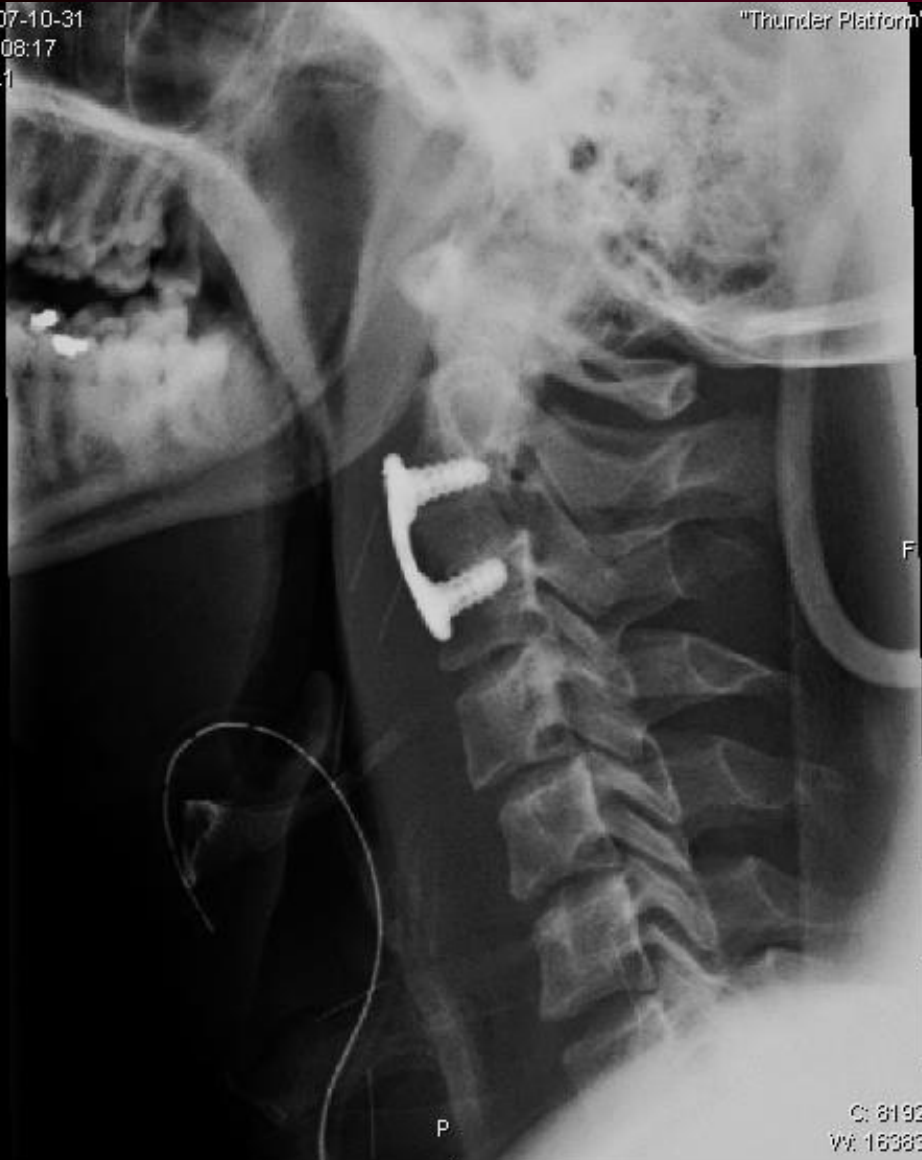09:26:16
No.1



09:41:28
No.2



Anterior fusion and plate



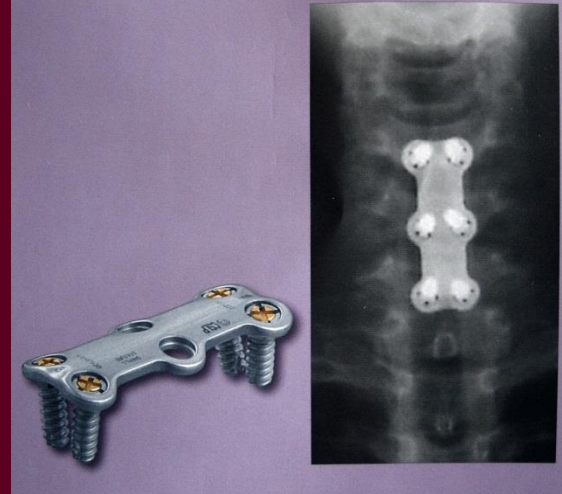CERVICAL SPINE INJURIES

- **Comminuted body fractures (burst)**
- **Injuries of discs and ligaments**
 - **disc and ligamentous disruption**
- **Combined**
 - **teardrop, fracture dislocations**

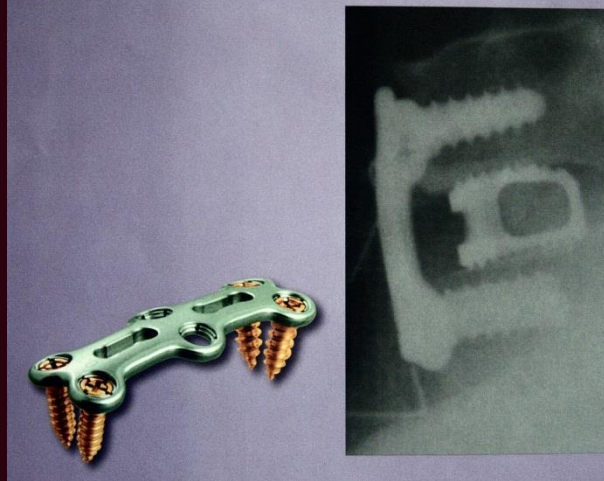
C- SPINE

- anterior surgery
 - body replacement
 - disc replacement
 - stabilisation

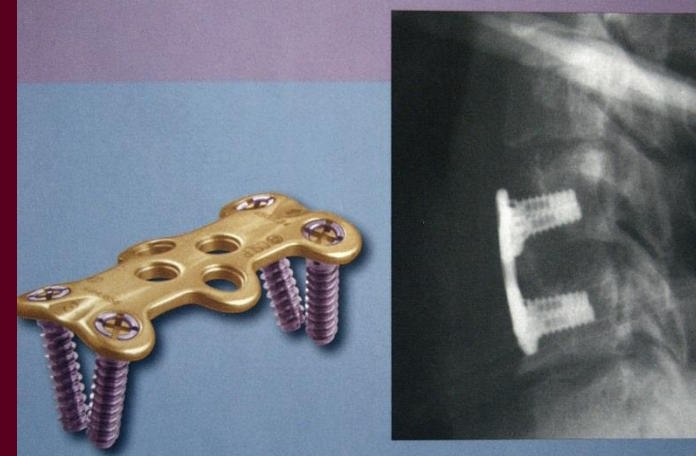
■ CSLP Small Stature



CSLP Variable Angle

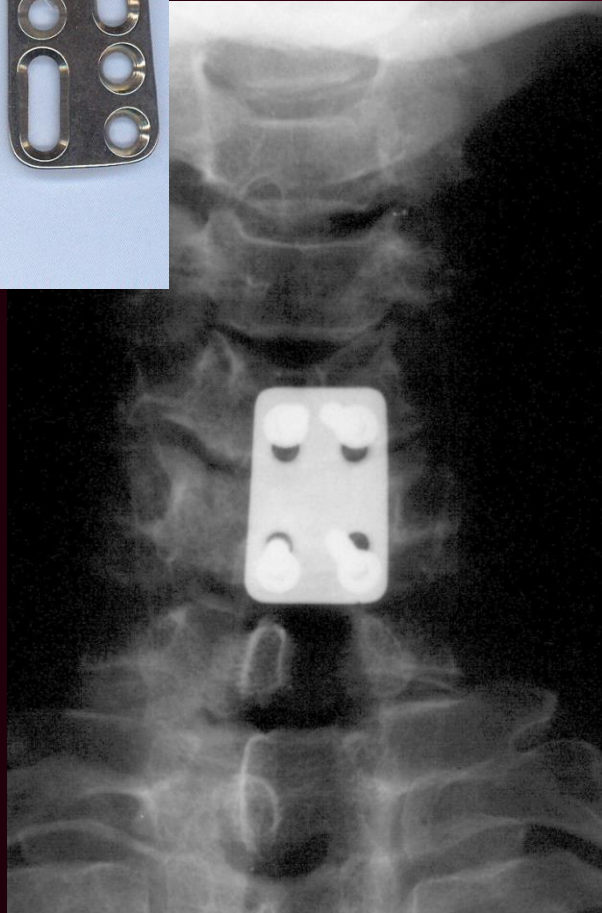


■ CSLP New Additions

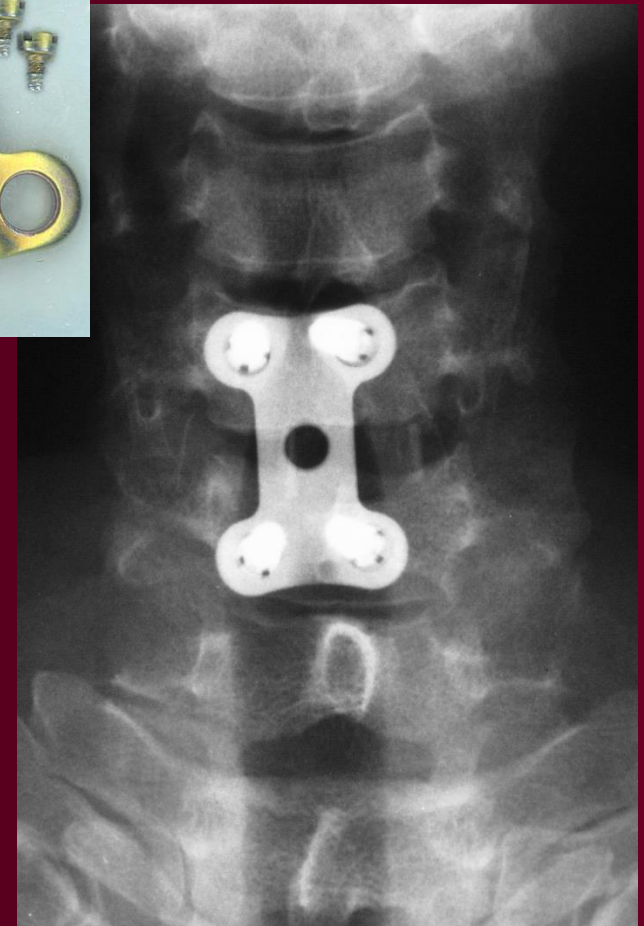

CERVICAL PLATES

- CASPAR

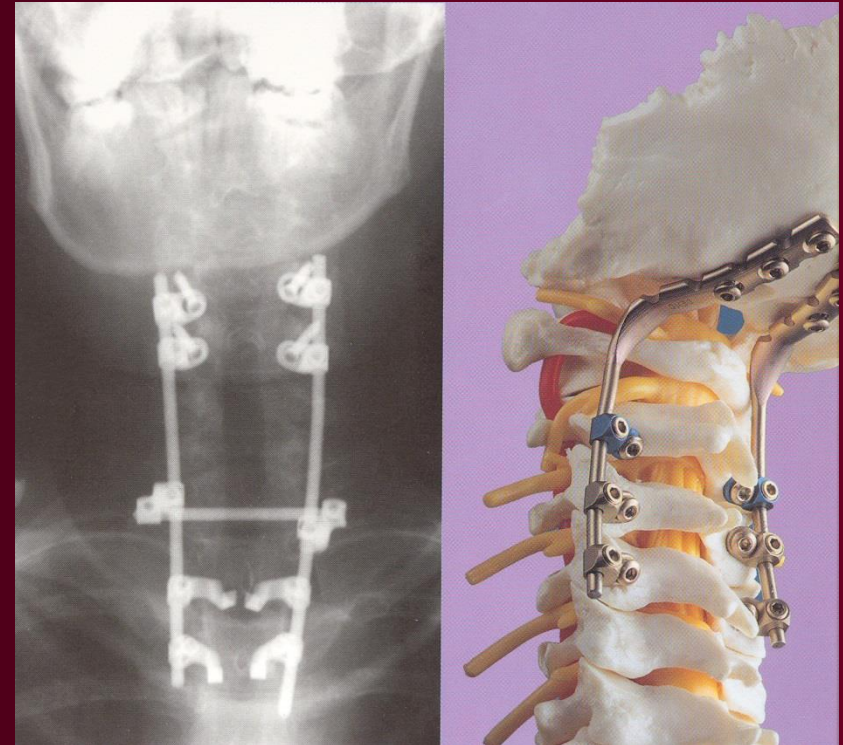
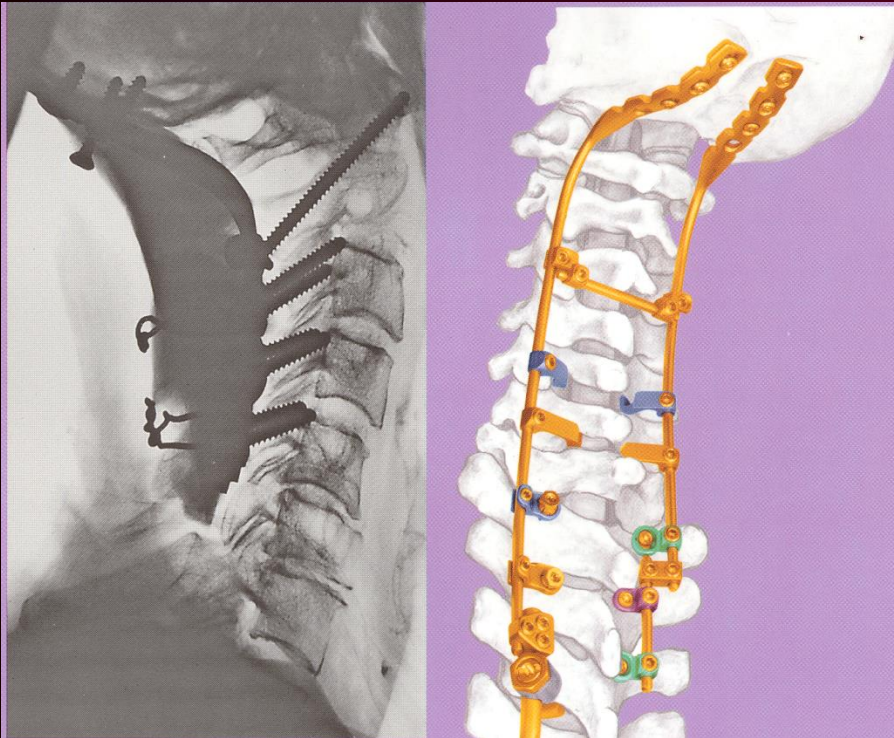


- SYNTHES



Posterior surgery STABILISATION of O-C SPINE

- Synthes
- Star Lock
- CerviFix



POSTOPERATIVE AFTERTREATMENT

- **collar**
- **Jewett orthosis, lumbar belt**
- **plaster cast**
- **0**