

Ophthalmological quiz

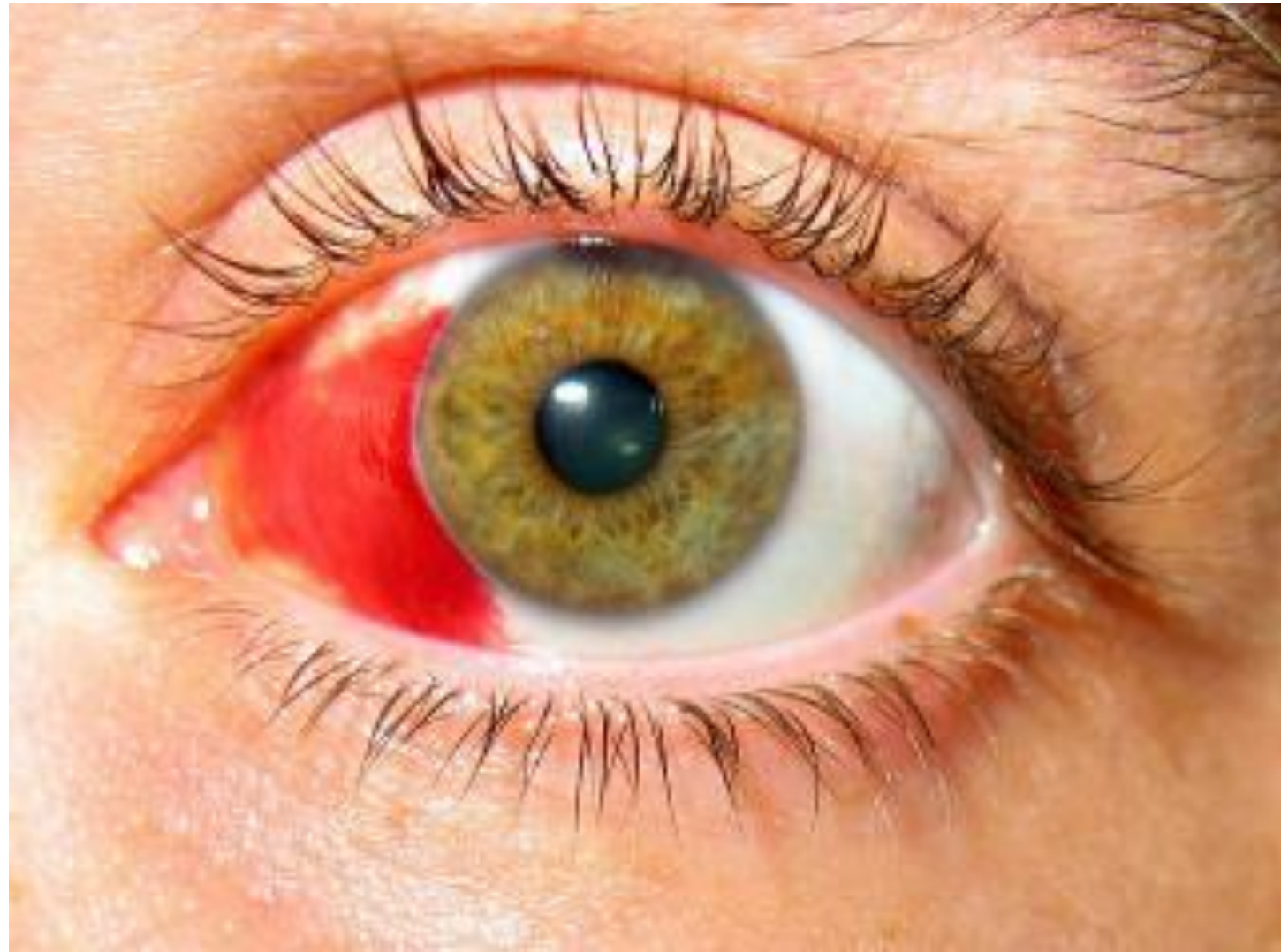Karolína Skorkovská

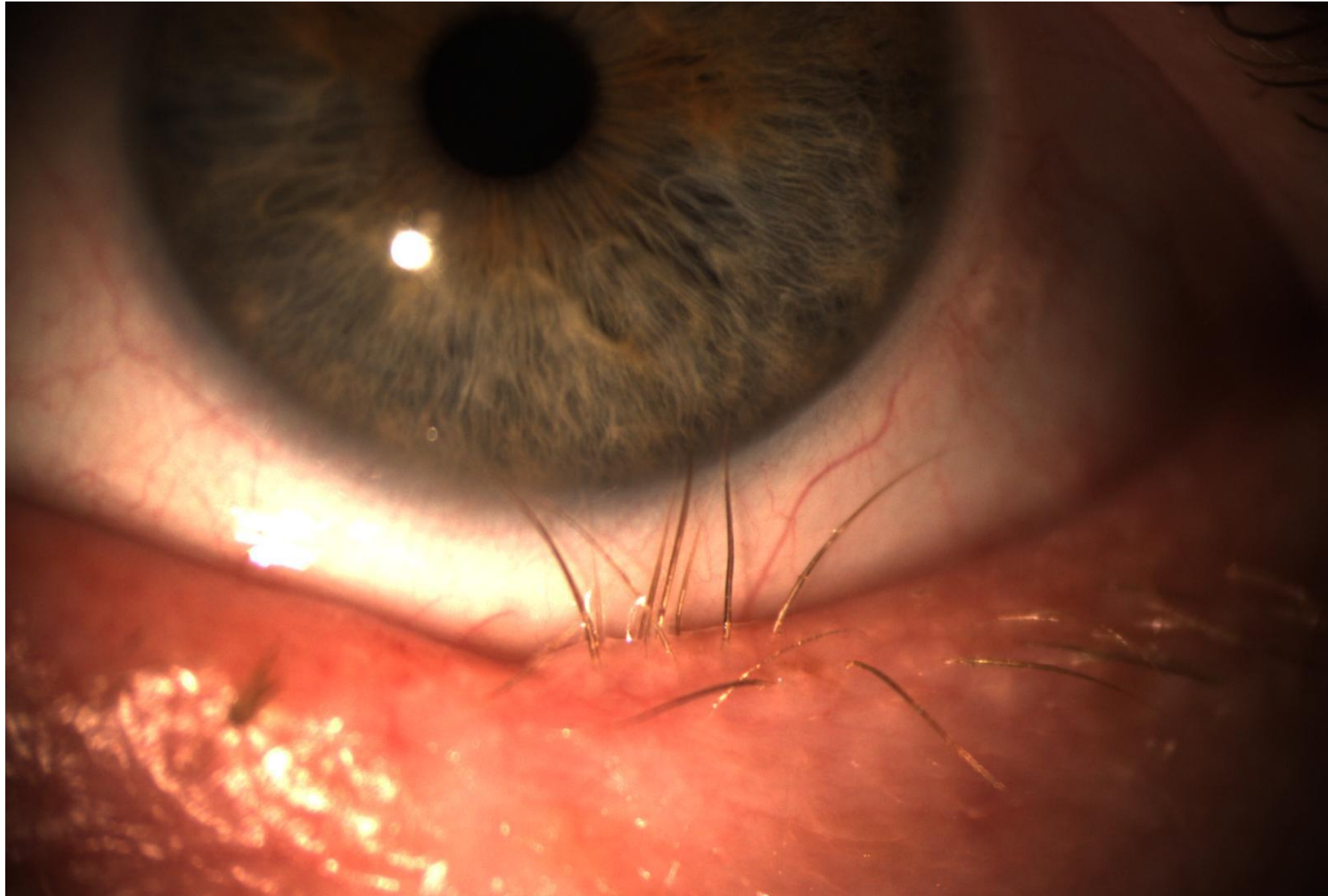
Repetition

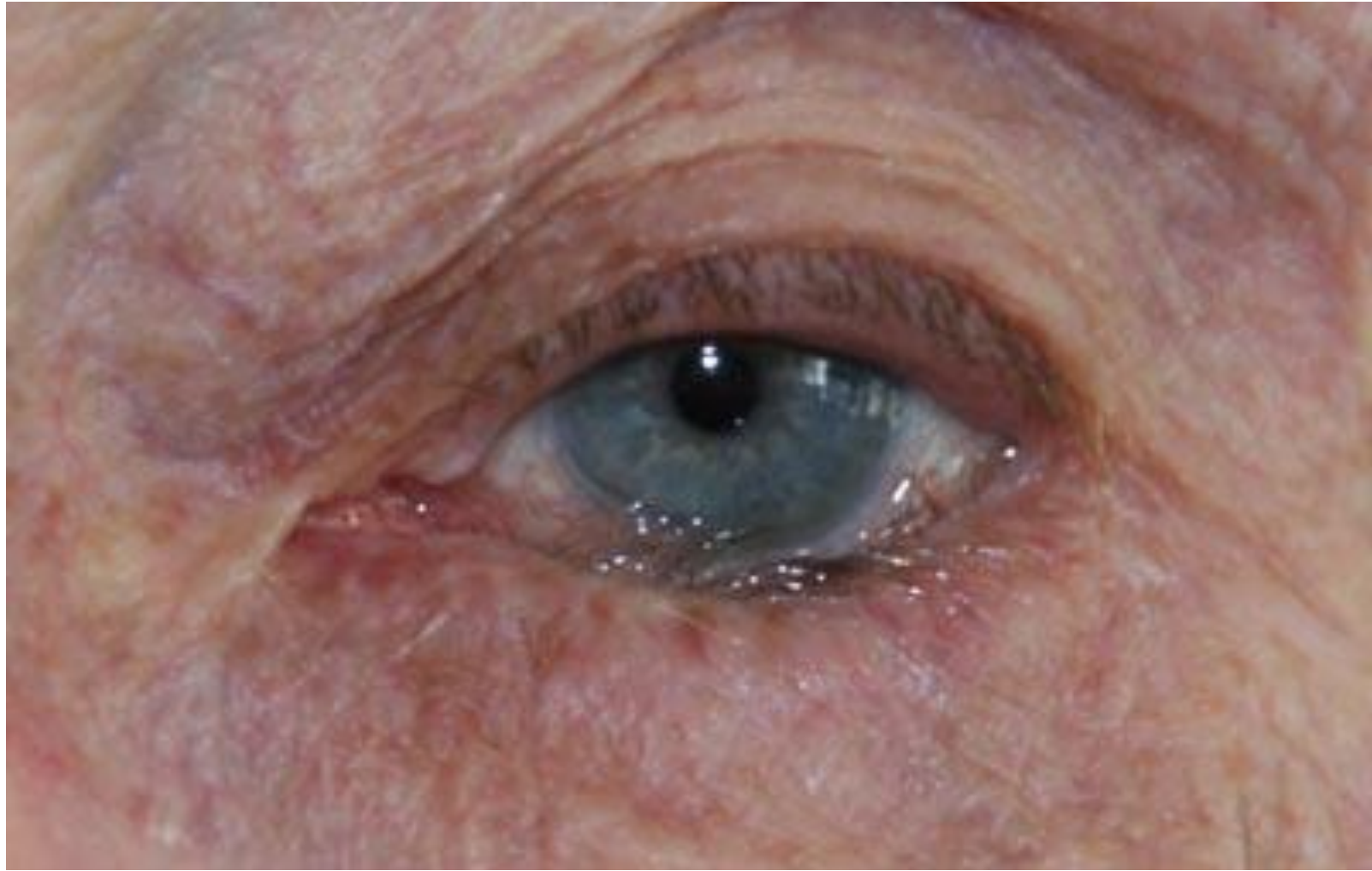
- Which types of retinal detachment do you know?
- What is the major retinal detachment surgery performed nowadays?
- Which refractive error is induced by scleral buckling?
- What are the symptoms of retinal detachment?
- Is retinal detachment an emergency or can be observed ?
- How do we examine the patient if we suspect a retinal detachment?
- Which electrophysiological examination can be useful in optic neuritis?
- Name three symptoms of optic neuritis

Repetition

- Which examination method is helpful in vitreous hemorrhage?
- How do we call the presence of an artificial intraocular lens in the eye?
- How do we call the absence of an intraocular lens?
- Which infection most often causes a keratoconjunctivitis?
- Which diseases can be associated with uveitis?
- Which medication is necessary in uveitis – mydriatics or miotics?
- Is episcleritis a serious infection that requires further diagnostics?
- Which medication is necessary in angle closure glaucoma – mydriatics or miotics?

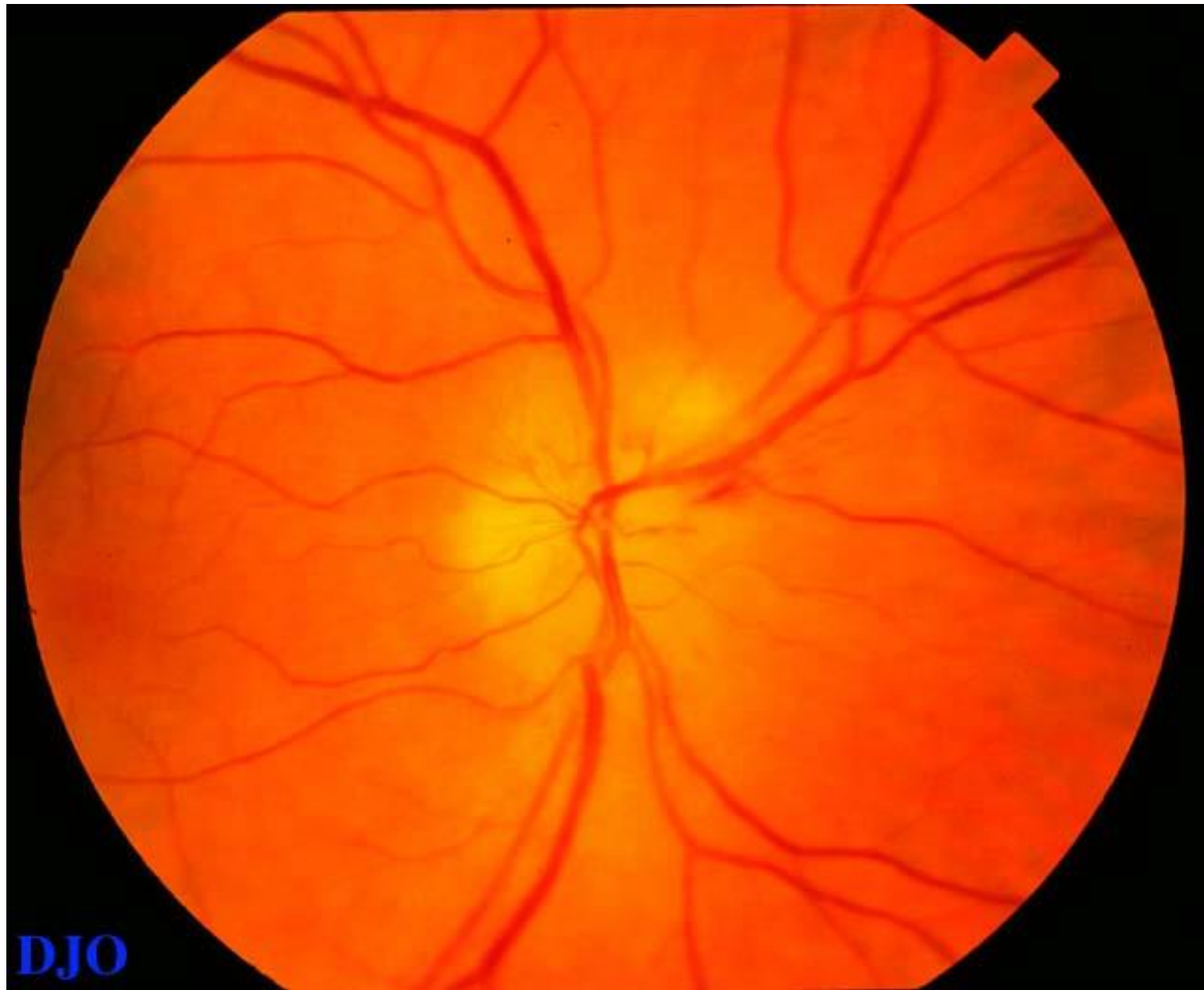





Case 1

- This is the view of the right optic disc of a 73 year old woman with a sudden decrease in vision of the right eye. The patient had a history of headache for several months and also complained of joint pains and anorexia. The fundus of the left eye was normal



DJO

Case 1

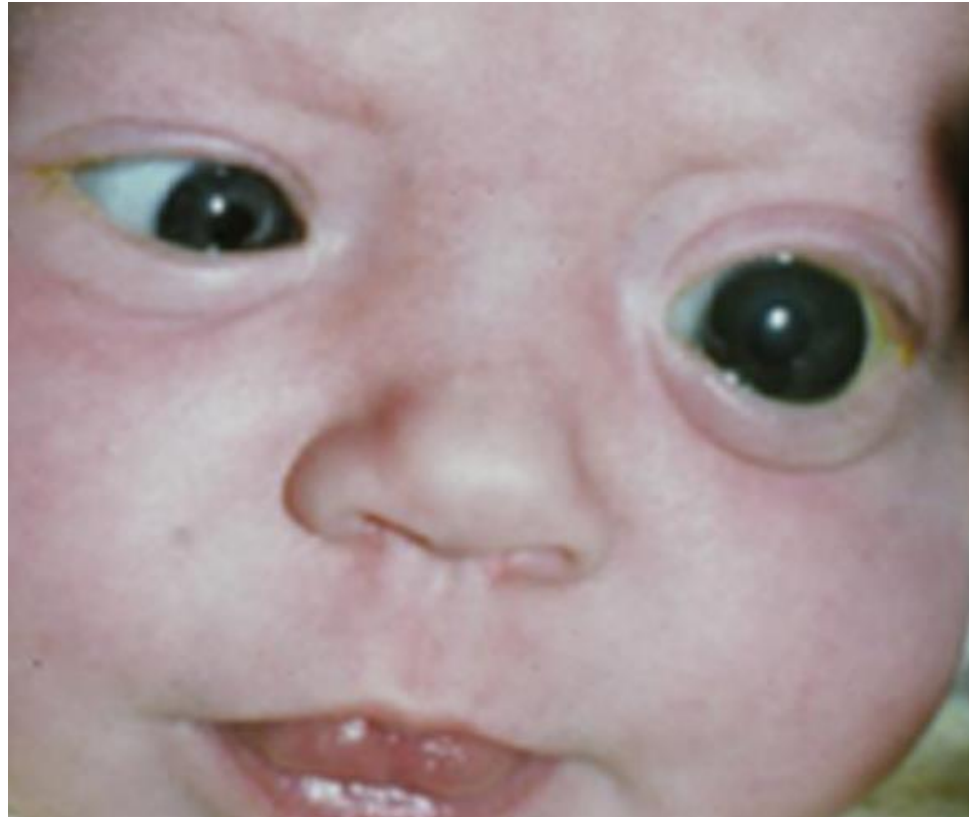- What is the differential diagnosis of this fundusoscopic picture?
- What kind of laboratory workup does this patient need?
- If this patient had an elevated erythrocyte sedimentation rate which diagnostic procedure would you perform next?
- In patients with temporal arteritis affecting one eye, what percentage of patients will go on to have involvement of the other eye?
- If there is involvement of the other eye, when does this usually occur?
- How would you treat temporal arteritis?

Case 1

- Arteritic and non-arteritic anterior ischemic optic neuropathy (AION)
- erythrocyte sedimentation rate (ESR)!
- High dose intravenous steroids

Case 2

- A 3-month-old male infant was noted to have tearing from the left eye, which had a pressure of 48 mm Hg



Case 2

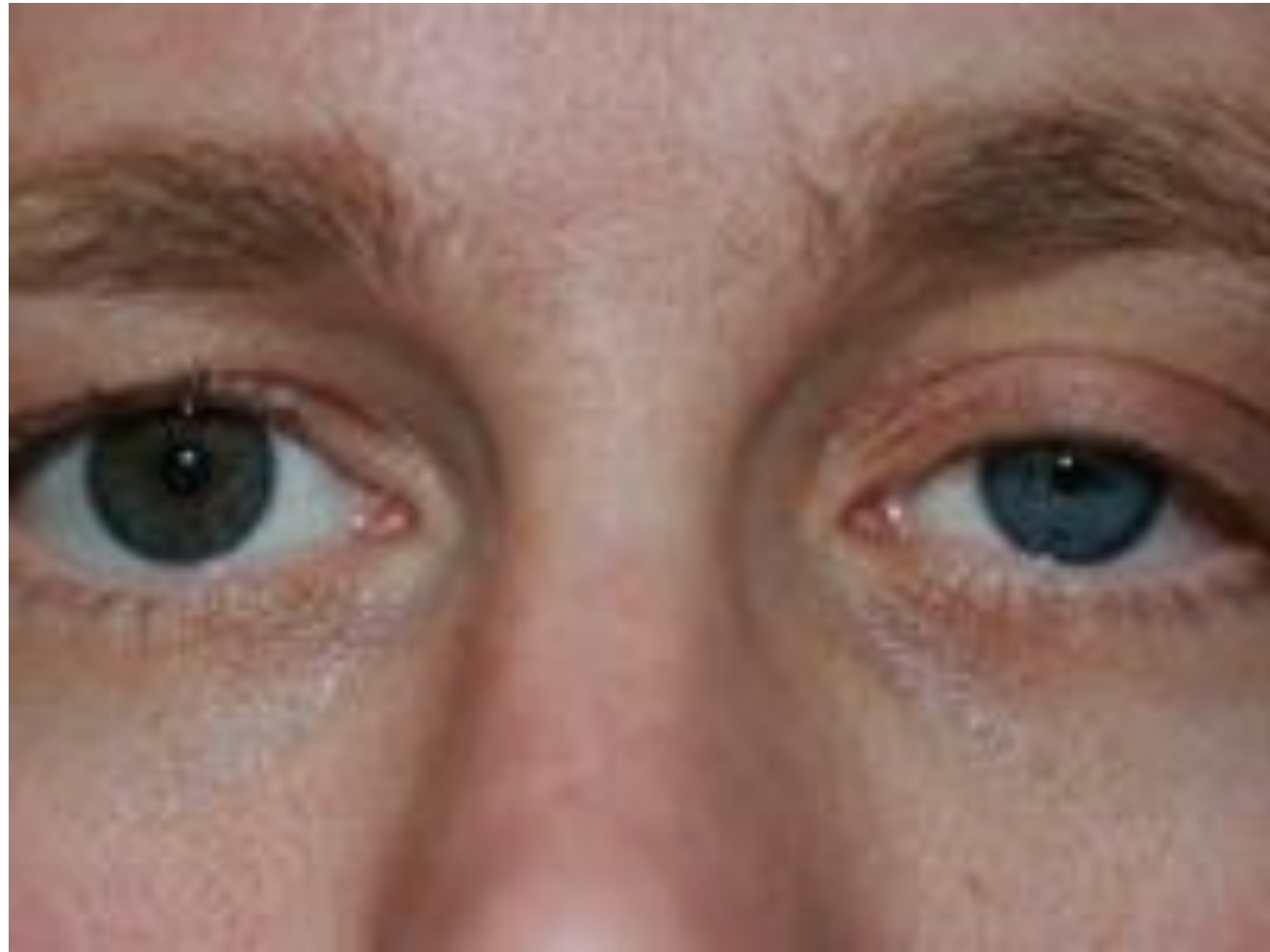1. What type of glaucoma is this?
2. What is the classic presentation?
3. What is the work-up of these patients?
9. What is the definitive treatment?

Case 2

- Primary congenital glaucoma
- The treatment is usually surgical. The optic nerve cupping may be reversible in the early stages. Goniotomy, from an ab interno approach, is preferable in children with clear corneas. Trabeculotomy, or an ab externo approach, may be needed in children with hazy corneas. If these fail, filtration surgery, tube implant surgery, or cyclodestruction may be tried. Medical treatment is usually a temporizing measure prior to surgical treatment

Case 3

- This 27 year old man has had one droopy eyelid for as long as he can remember. He has also been told that he has one green and one brown eye. Childhood photographs confirm his history regarding the duration of symptoms. He does not suffer from headaches, does not smoke, has no history of head or neck trauma or surgery, and has no neurologic symptom

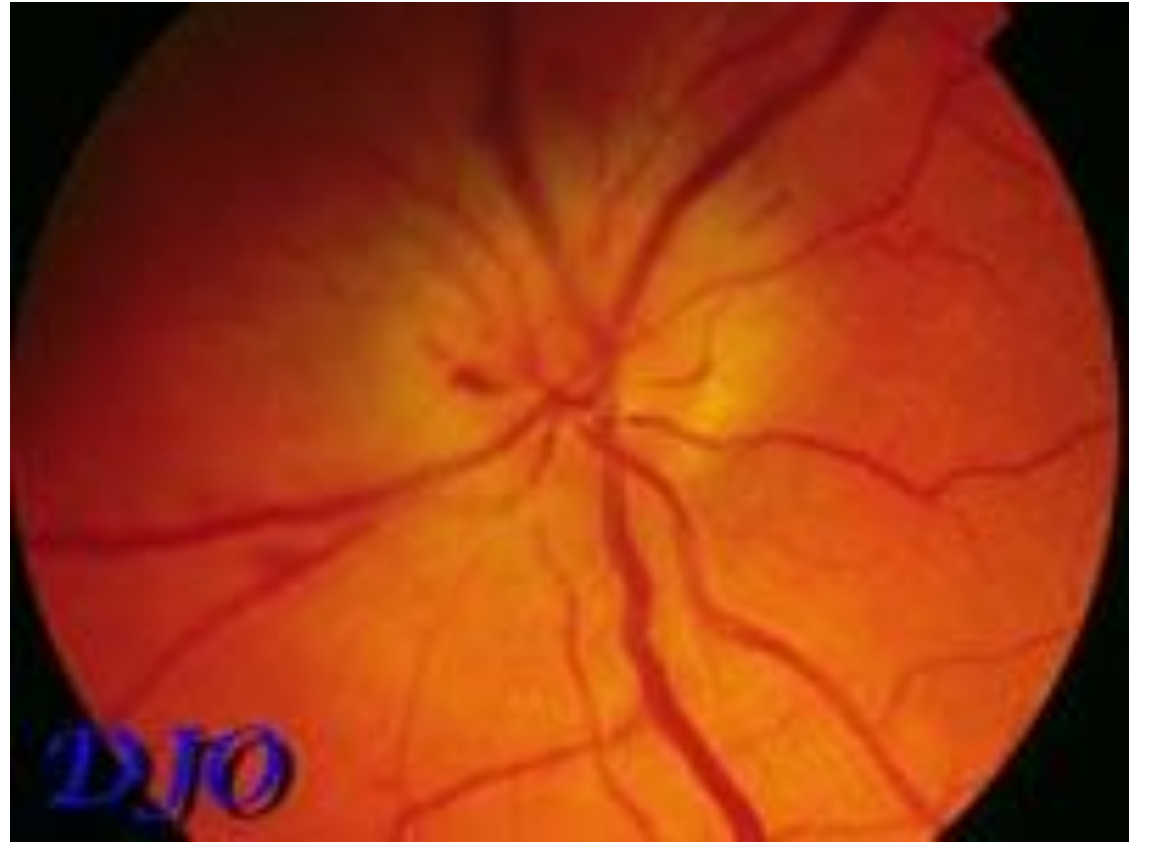
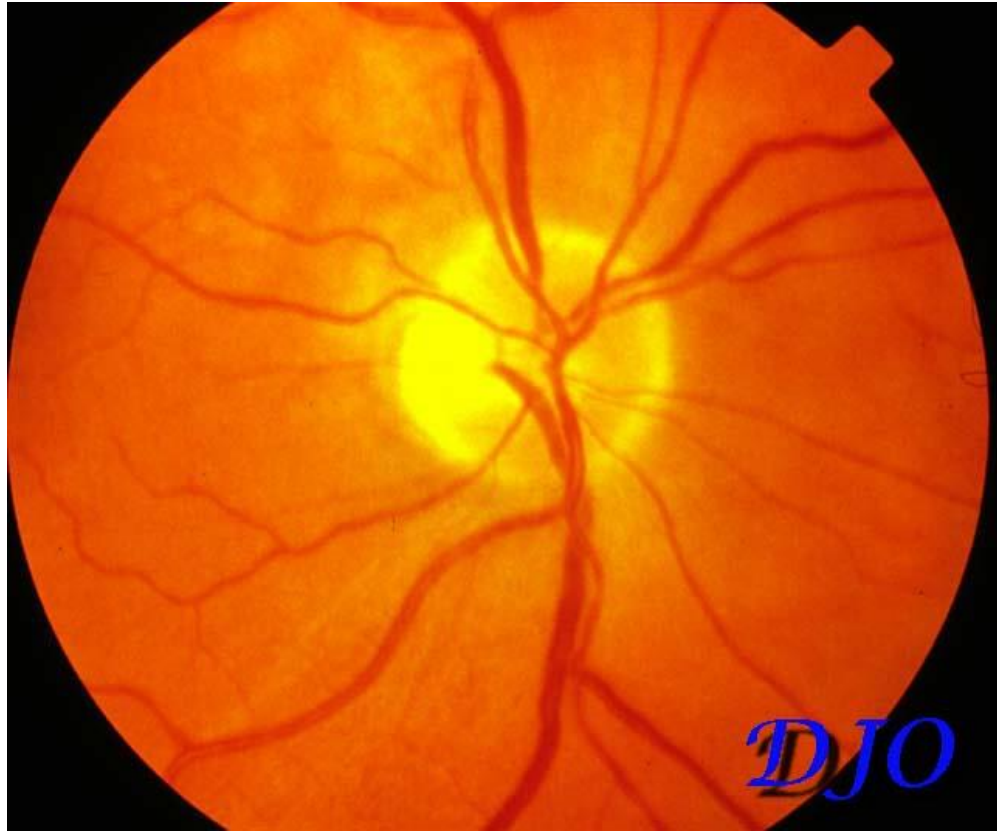


Case 3

- Which diagnosis do you suspect?
- How will his pupils respond to cocaine?
- If the onset of these symptoms and signs were acute, what workup would be appropriate?

Case 4

- A 56 year-old white man complained of blurring of the lower one-third of the vision in his left eye for the past five days. He has been treated for hypertension for six years with amlodipine. He denied headache, eye pain or diplopia. Visual acuities were 20/20 bilaterally. Color vision was normal. A left afferent pupillary defect was present. A left inferior altitudinal defect was present. The ESR was 17. The hematocrit was 49.4%.

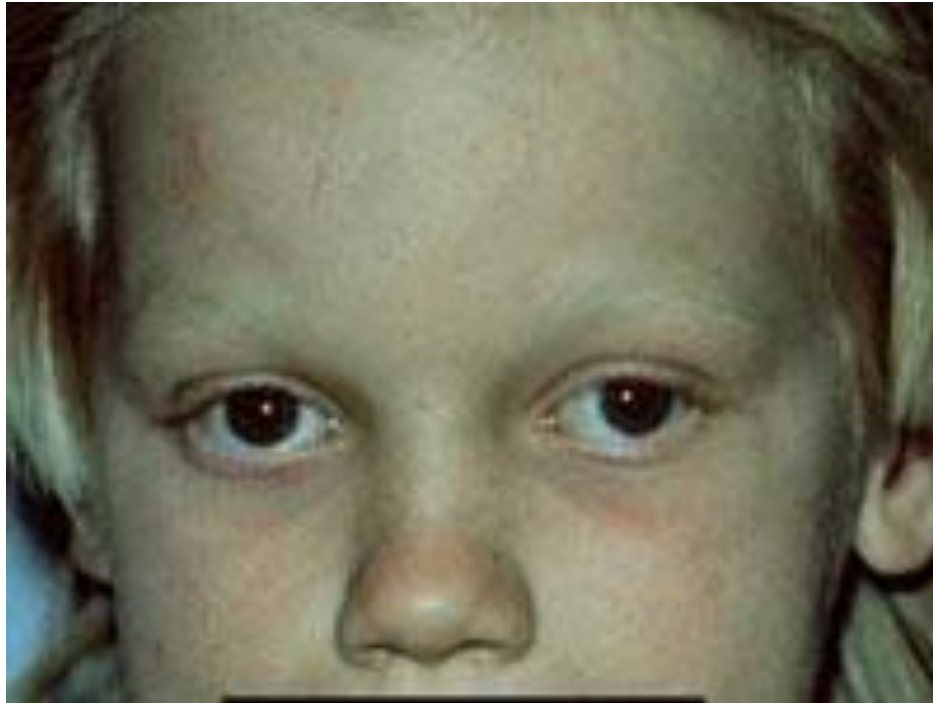

Case 4

- The photographs demonstrate a normal appearing right optic nerve with a small cup to disk ratio. The left optic nerve is edematous with several flame hemorrhages in the nerve fiber layer and on the optic nerve head. The ophthalmic history and findings are suggestive of **nonarteritic anterior ischemic optic neuropathy**.

Case 5

- This is the face of a very fair skinned boy who had decreased vision in both eyes since birth. On slit lamp examination, he had iris transillumination.

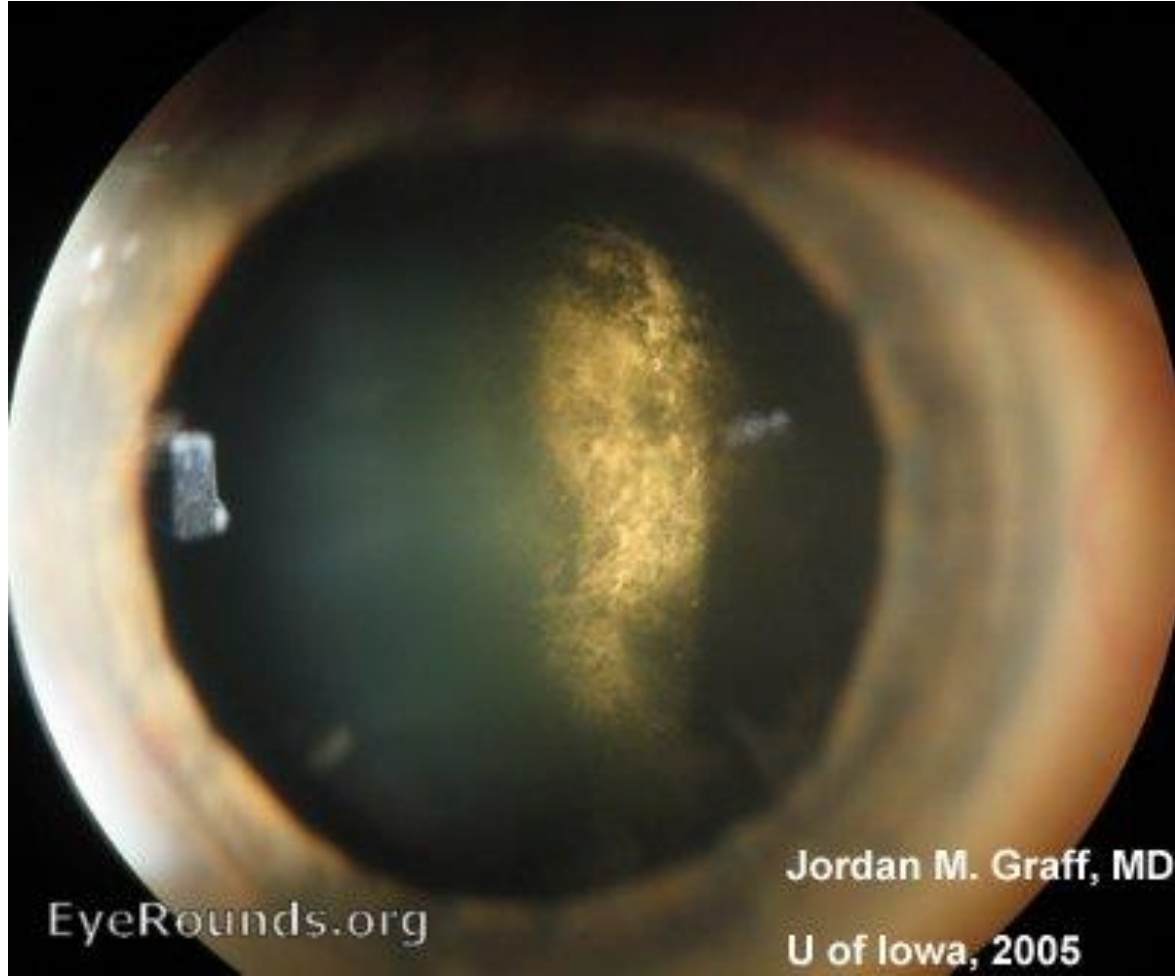


Case 5

- Oculocutaneous albinism where the skin, hair, and eyes are all affected. In ocular albinism the predominant feature is ocular hypopigmentation.
- Foveal hypoplasia is almost always associated with albinism and is the cause of decreased vision.
- Pendular nystagmus, iris transillumination defects, lightly pigmented fundus, foveal hypoplasia. Although, not present in this child strabismus is also common.

Case 6

- 50-year-old man complains of foggy vision which developed slowly over half a year
- VA 0,5
- IOP normal



EyeRounds.org

Jordan M. Graff, MD

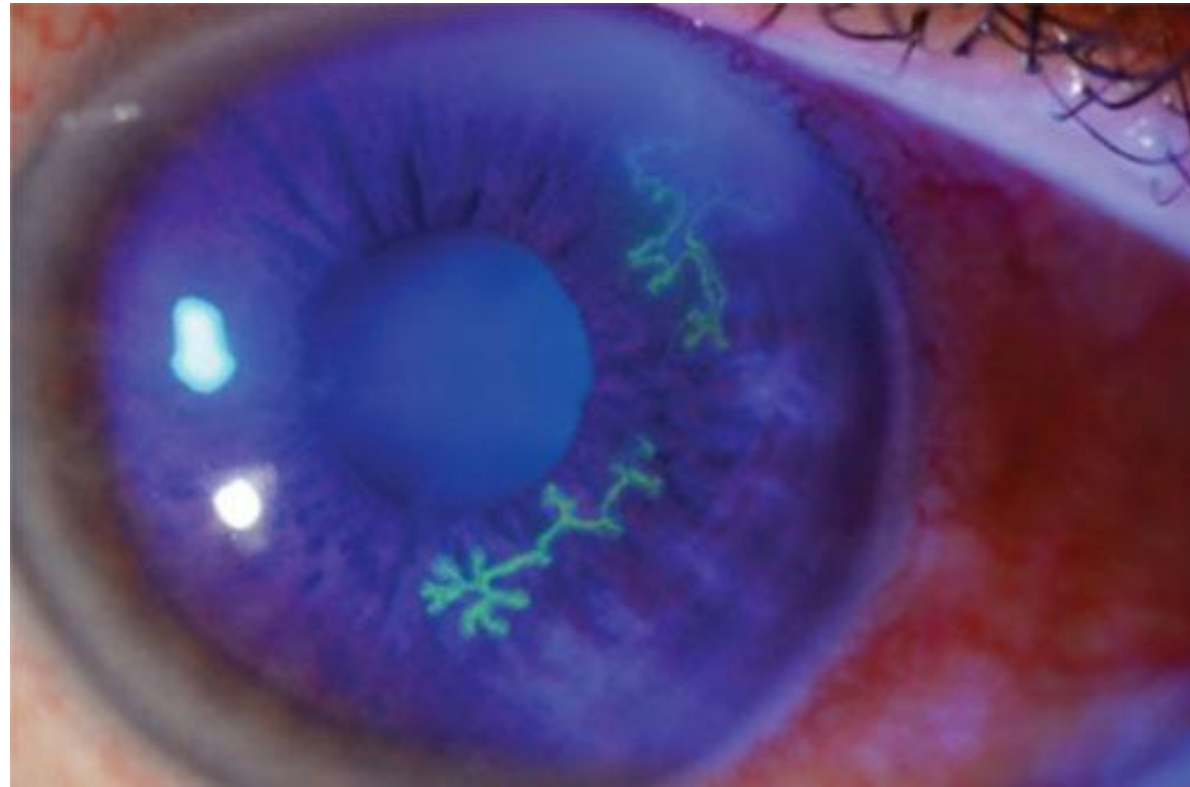
U of Iowa, 2005

Case 6

- Posterior subcapsular cataract
- Often es „complicated cataract“
- Reduces contrast sensitivity

Case 7

- Patient complains about pain, itching, epiphora and redness in one eye

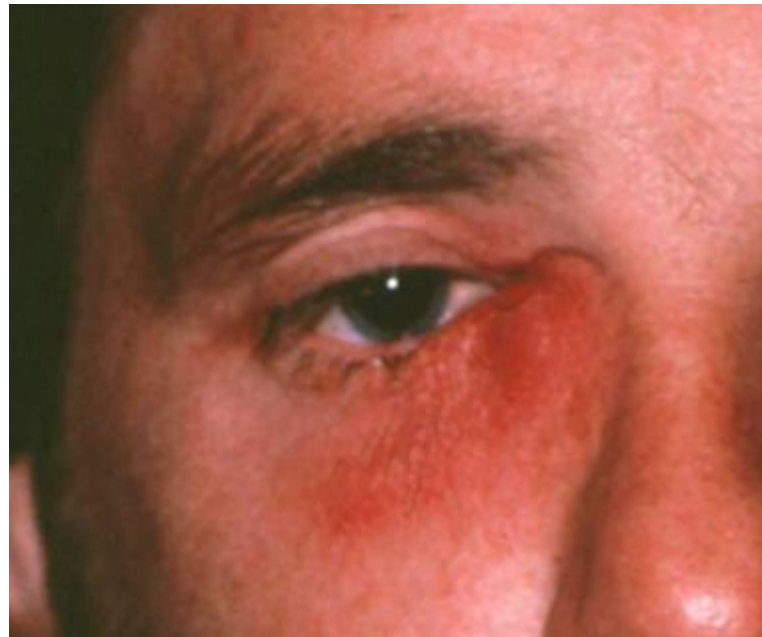

Case 7

- Herpes simplex keratitis
- It is necessary to test corneal sensitivity – reduced in HS keratitis
- Treatment with topical antiviral agents
- May progress into stromal forms of keratitis
- May be recurrent

Case 8

- Adult patient with swelling in the internal angle
- Swelling is red and painful, signs of conjunctivitis



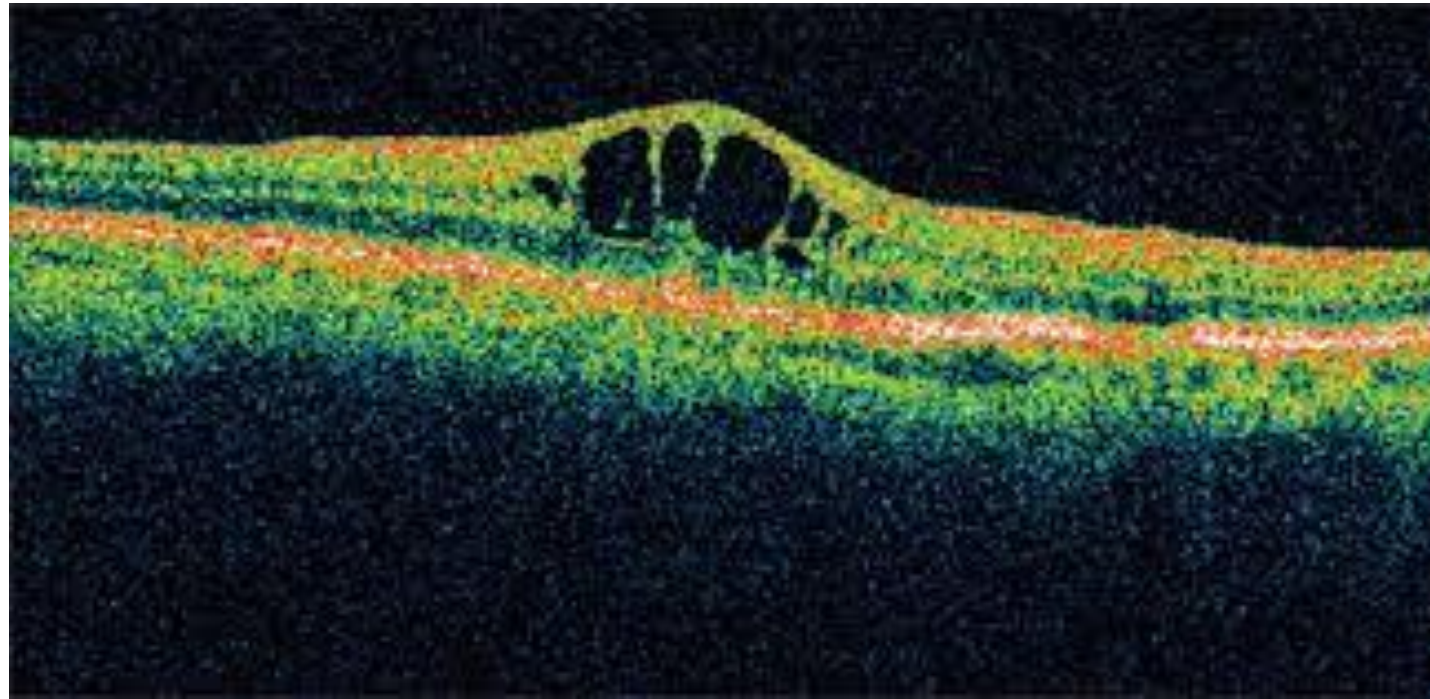
Case 8

- Acute dacryocystitis
- Treatment with systemic antibiotics
- Probing of the lacrimal pathways

Case 9

- 60-year-old male patient was diagnosed with central retinal vein occlusion 1 month ago
- Now the hemorrhages are gone but visual acuity has not yet returned to normal
- What may be the cause of decreased visual acuity?
- Which treatment would you suggest?

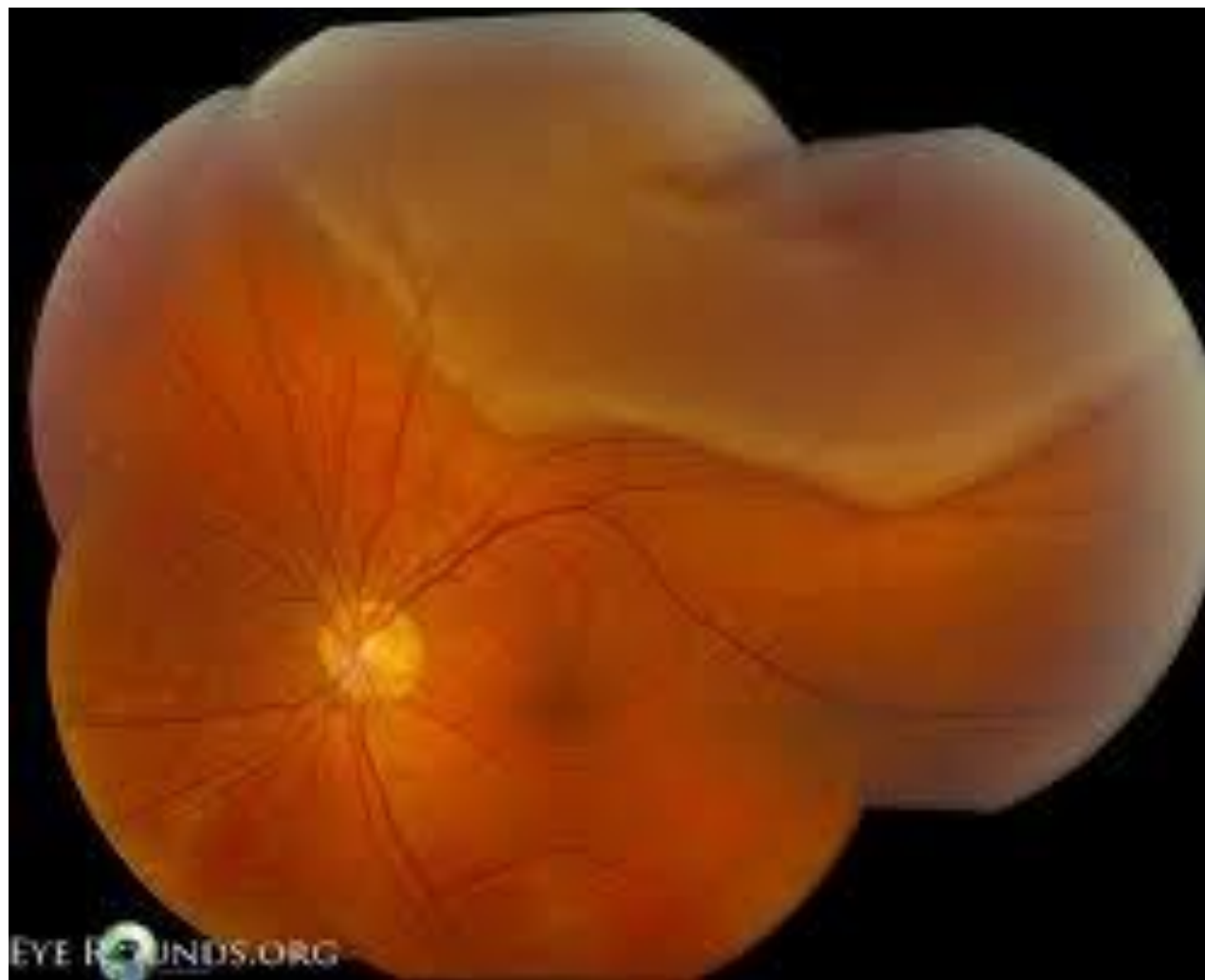Cystoid macular edema



Case 10

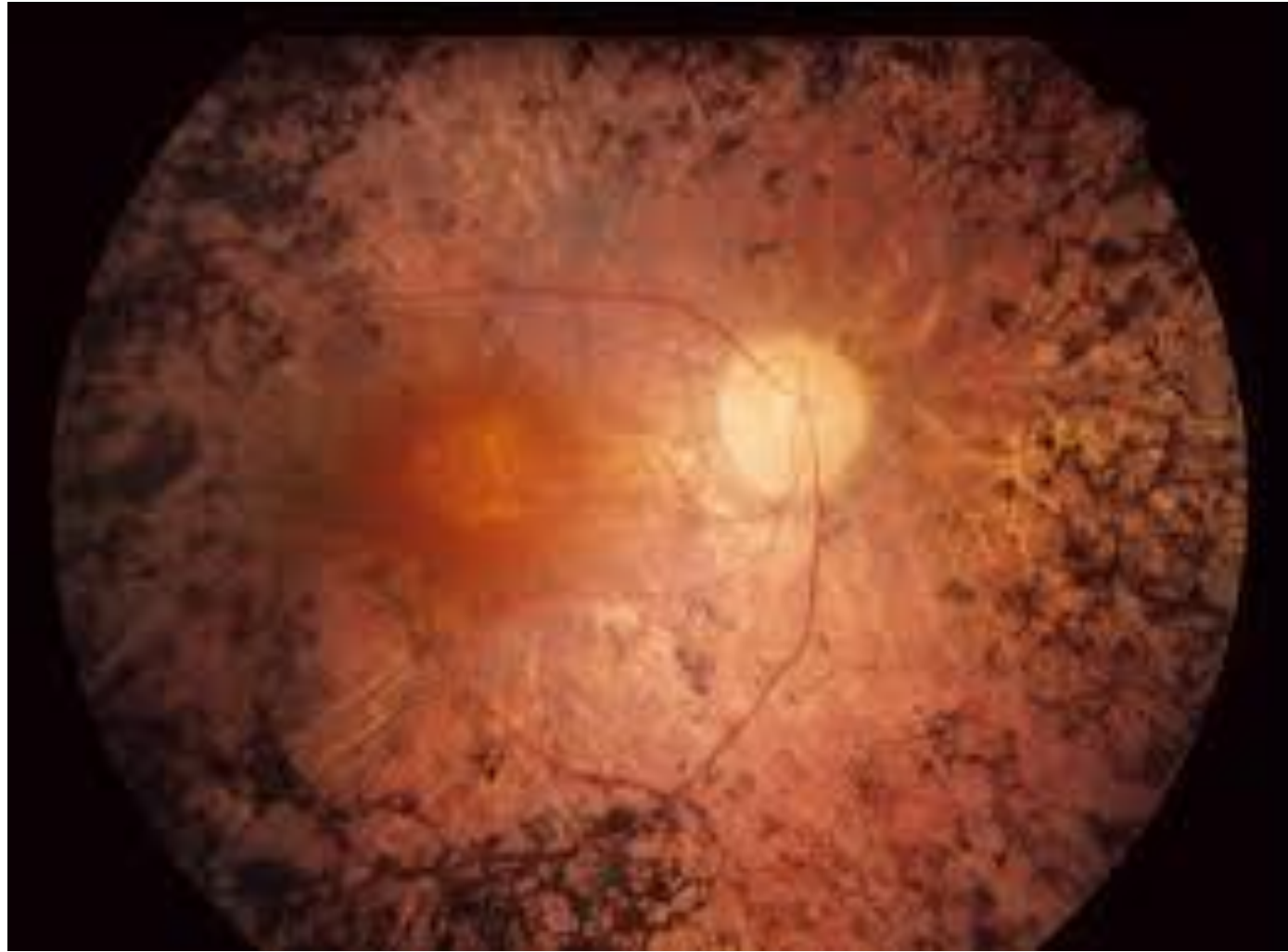- 50-year-old patient reports of a trauma a few days ago, he was hit by a piece of wood in the right eye
- Since yesterday he has noticed more floaters and a curtain from the right side developed...
- Which diagnosis would you suspect?
- What kind of treatment would you recommend?

Case 10 – retinal detachment



Case 11

- 70-year-old female patient is sent to the clinic for cataract surgery
- She has not been to an ophthalmologist for 40 years
- She complains of seeing like in a „tunnel“
- Her visual acuity is 0,8
- IOP normal



Case 11

- What is the diagnosis?
- Which disease rather causes her problems – retina or lens?
- How would you proceed in this patient, would you operate straight away?

Case 12

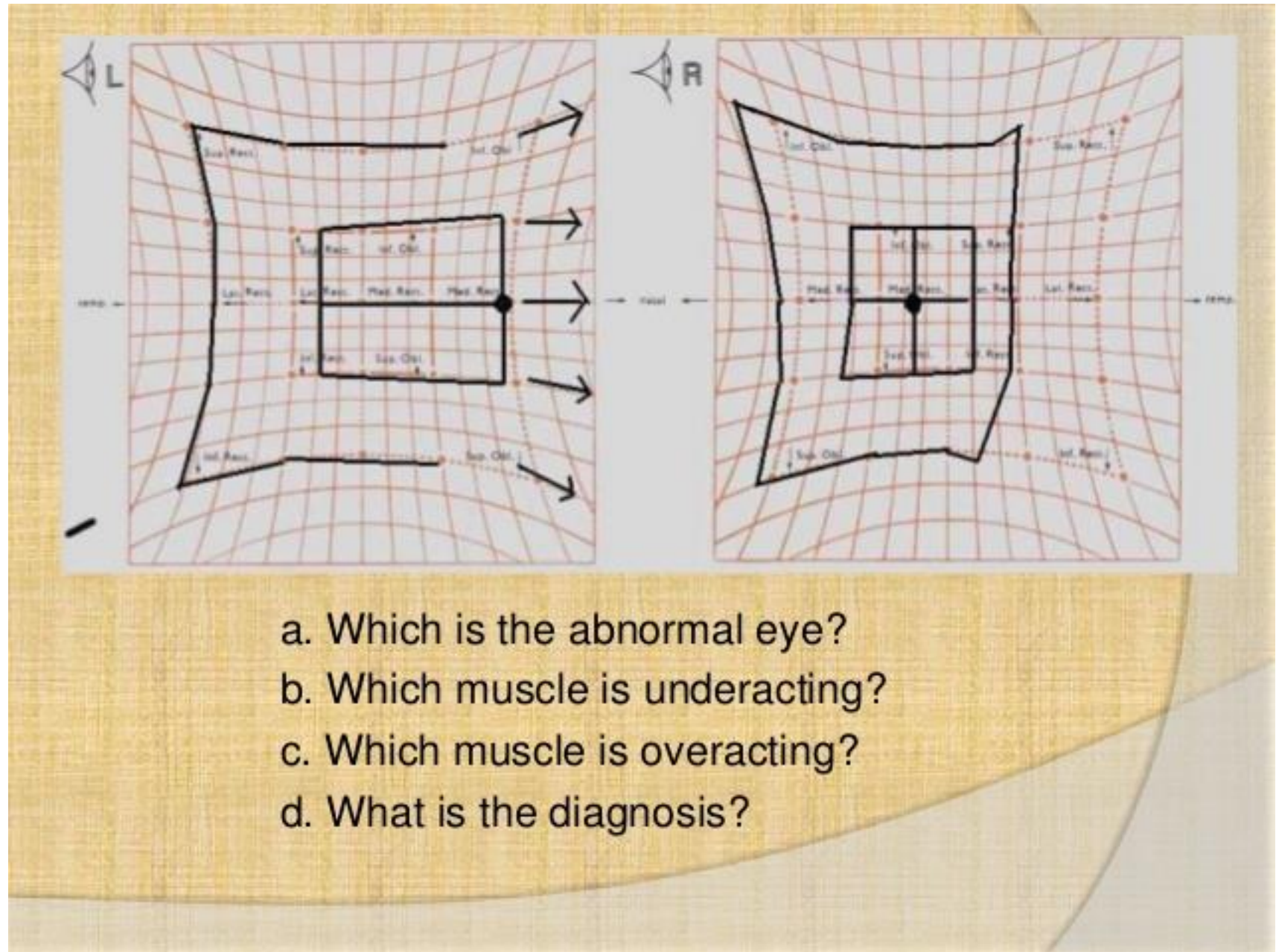
- 65-year-old female patient is sent for cataract extraction to get rid of diplopia
- VA is 0,9 (-6,0dpt/-2,0cyl/90°)
- IOP normal
- Examination reveals binocular diplopia
- What to do next?

Case 12

- Cover – uncover test : esophoria
- Confirmed by Hess

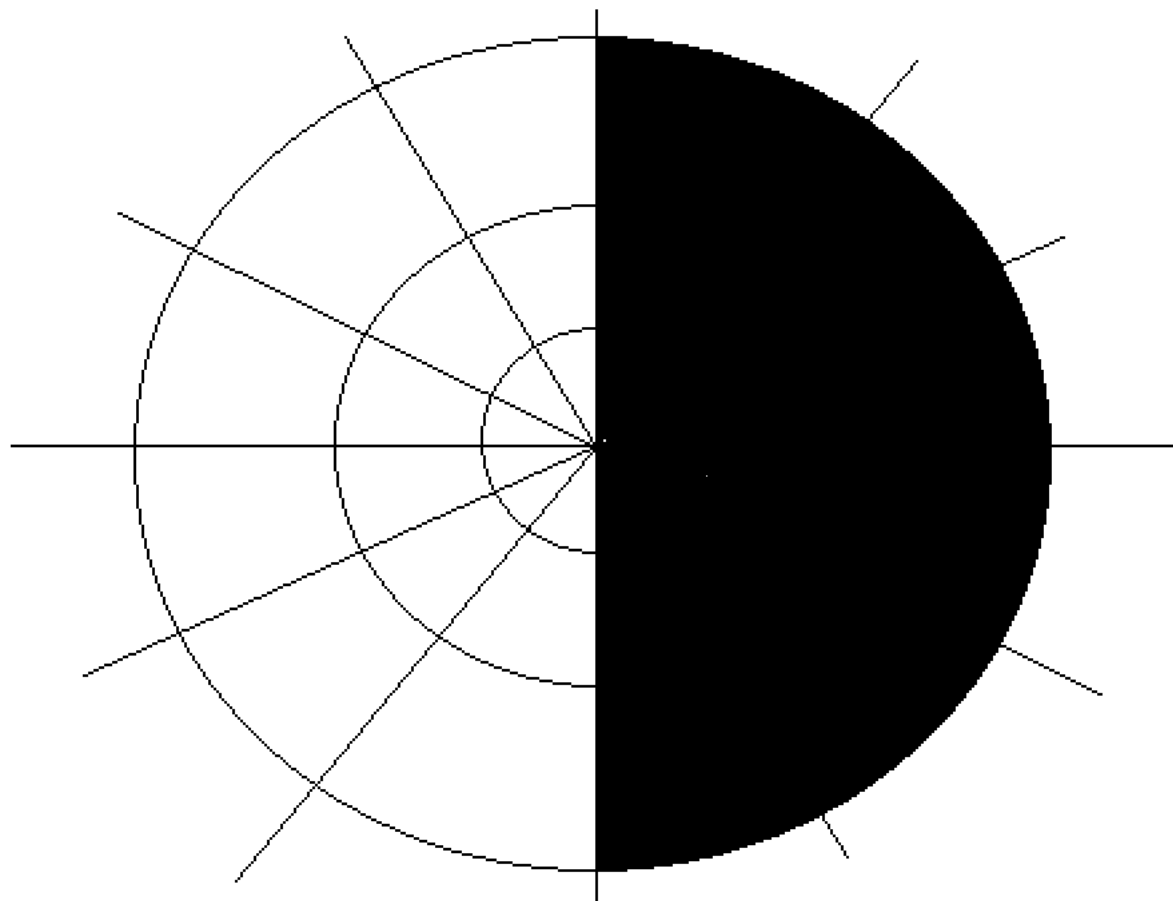
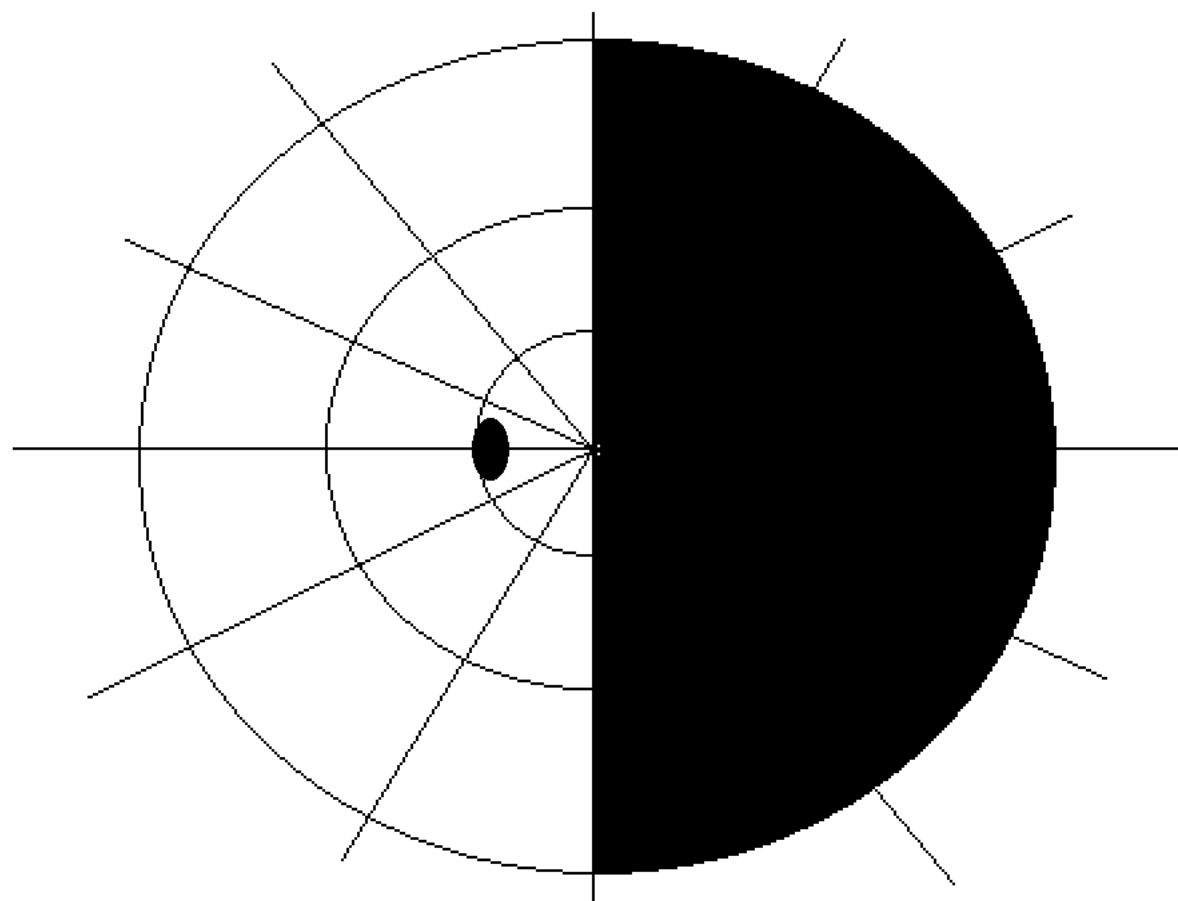
- Suggestion : perform cataract surgery on both eyes
 leave a small minus correction
 correct esophoria with prism glasses

Case 13



- Which is the abnormal eye?
- Which muscle is underacting?
- Which muscle is overacting?
- What is the diagnosis?

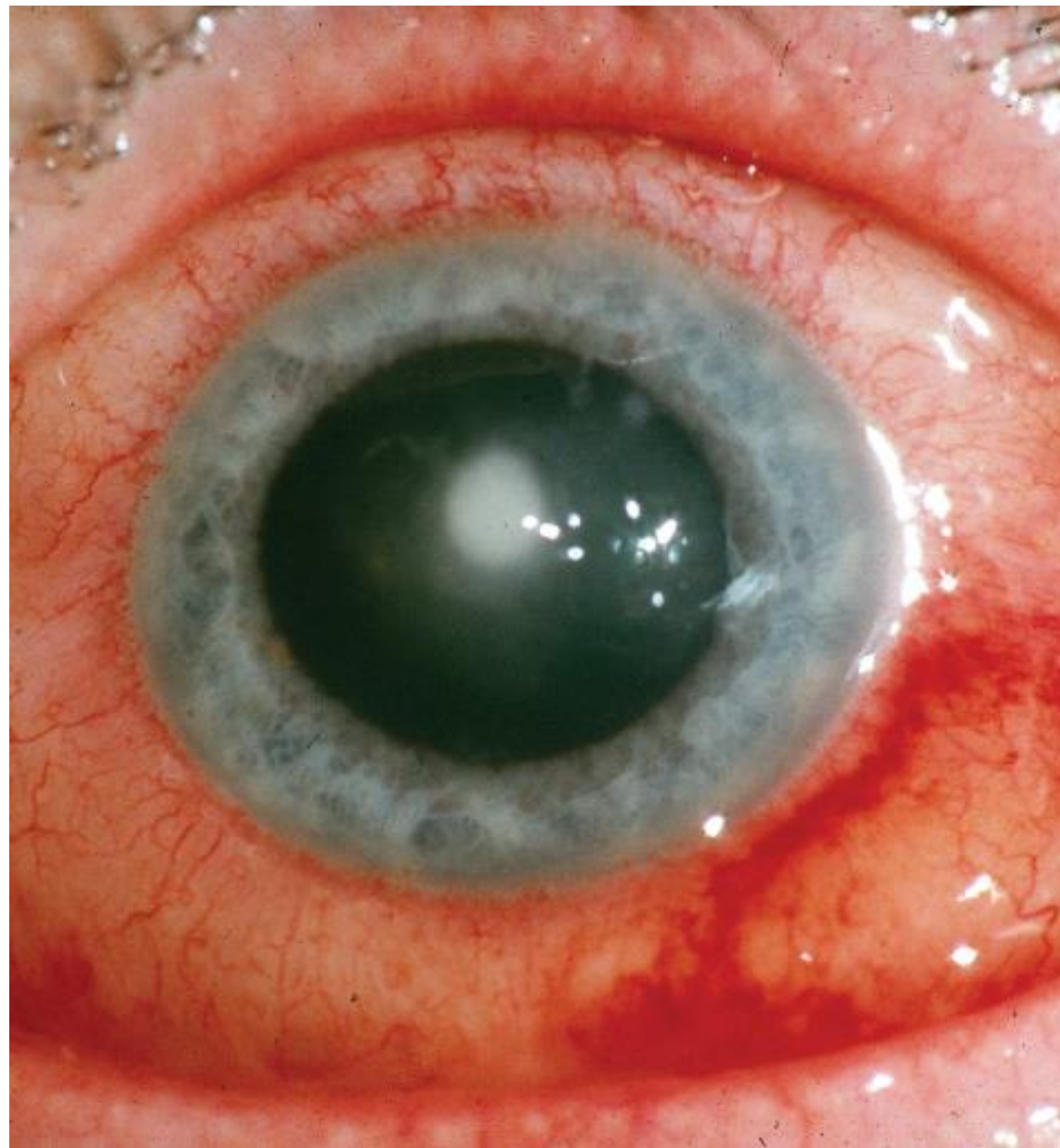Case 14



Case 15

- 25-year-old man comes to emergency because of red eye and pain
- He is myopic and wears contact lenses every day

Case 15



Case 15

- Corneal ulcer
- Treatment with antibiotics (local and systemic), mydriatic agents
- Conjunctival / corneal swab
- Culture of both the contact lenses and the container
- It is prohibited to wear contact lenses if cornea is infected