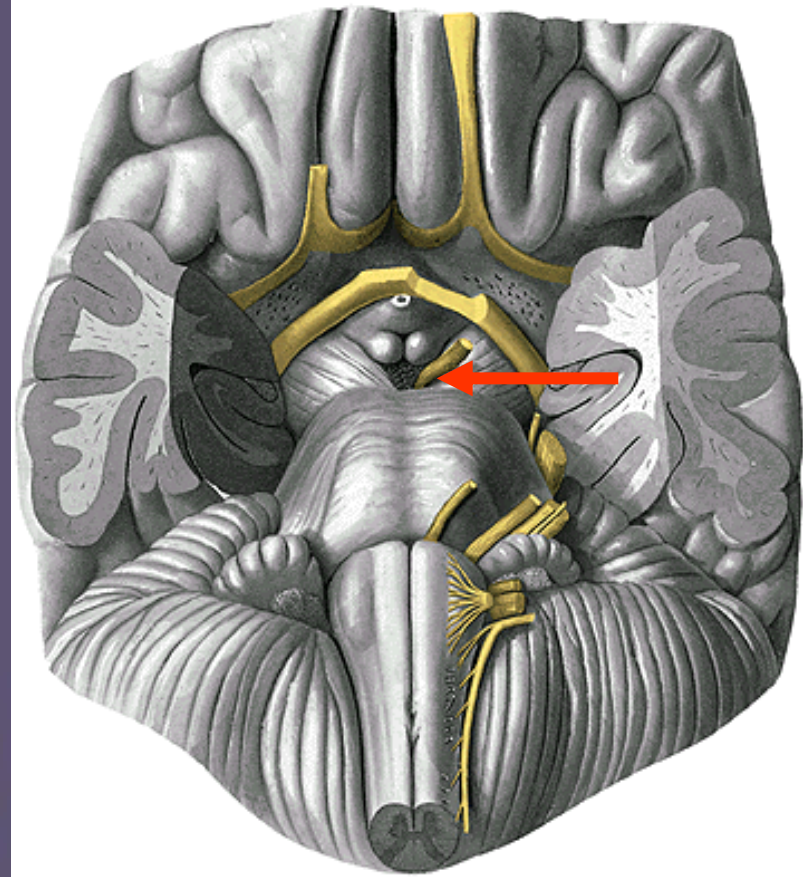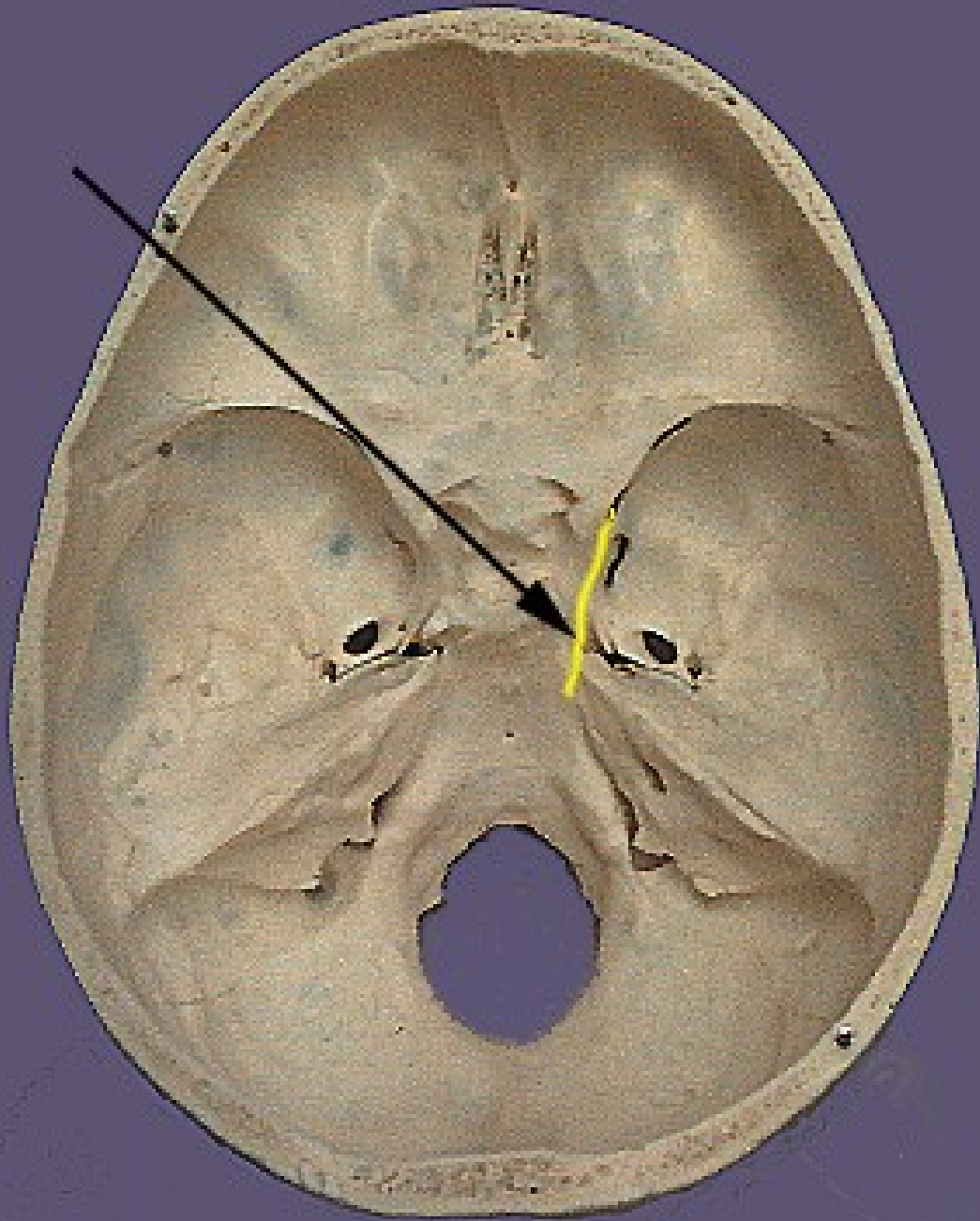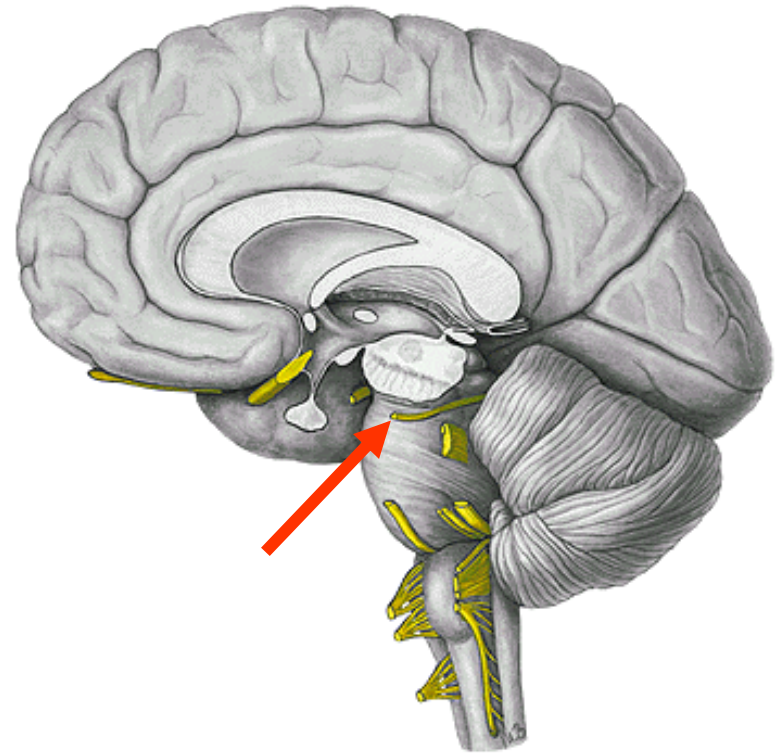
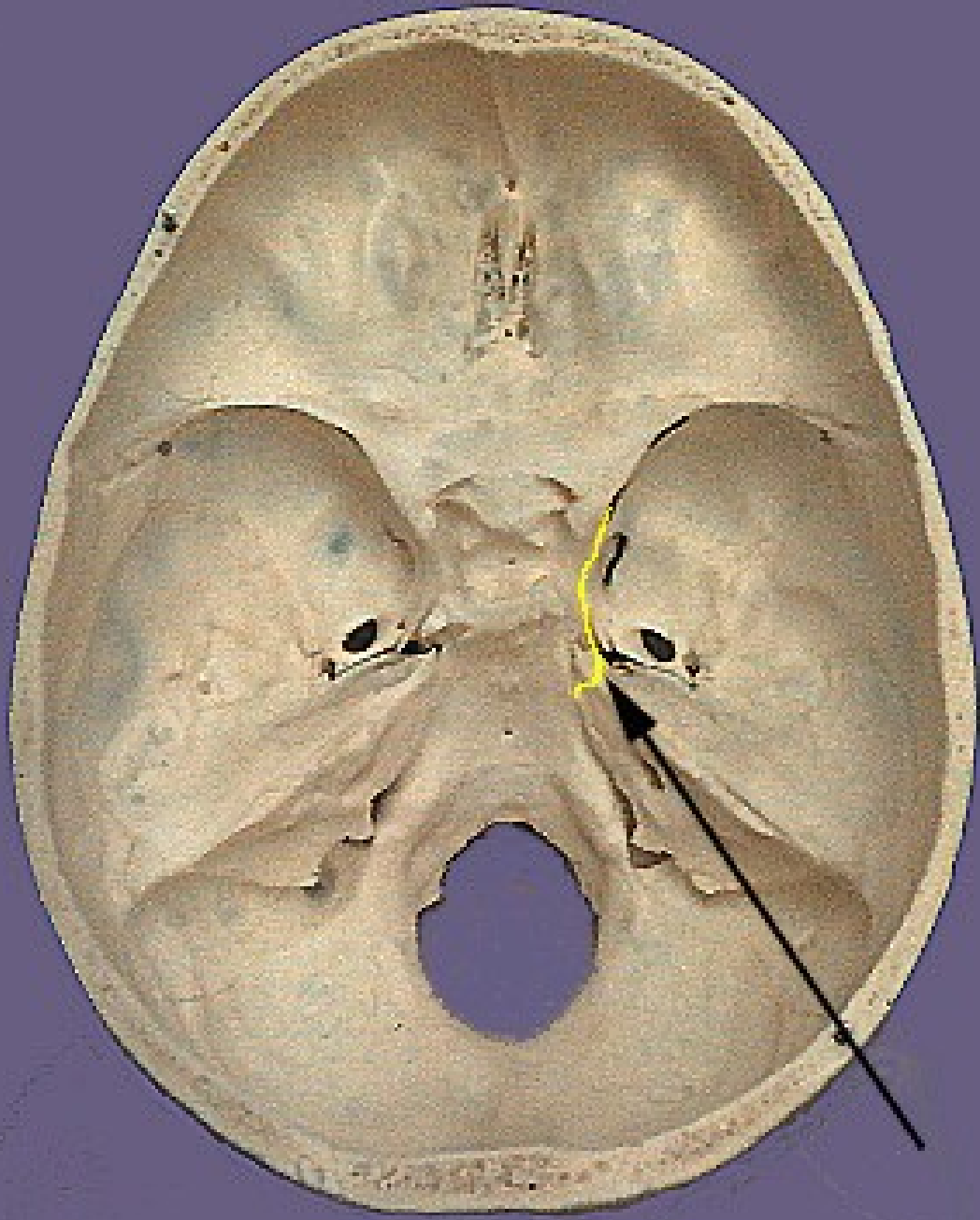
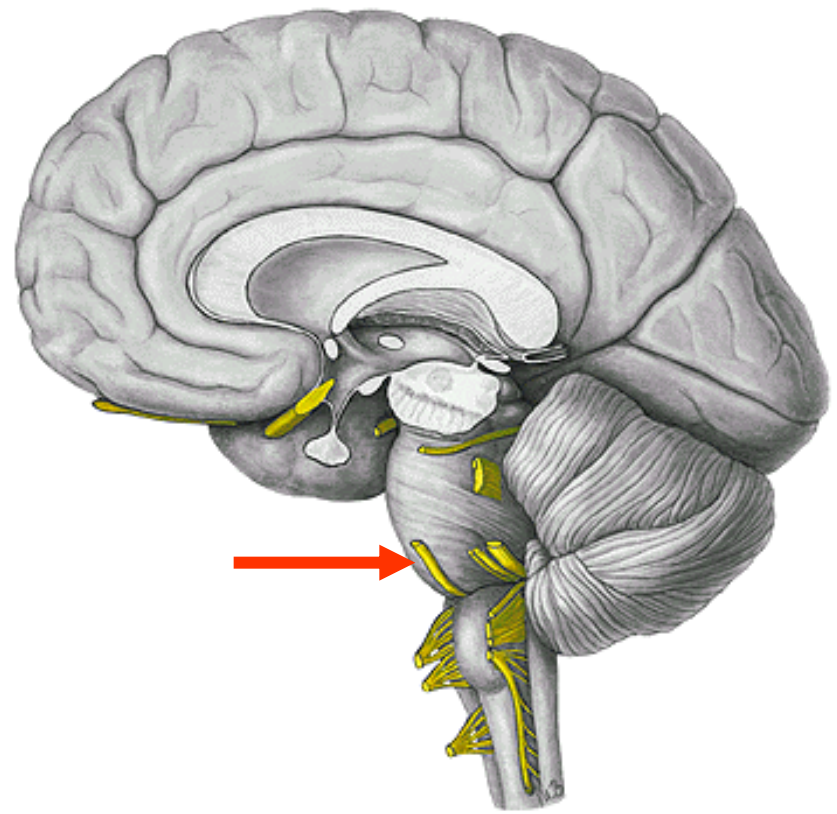
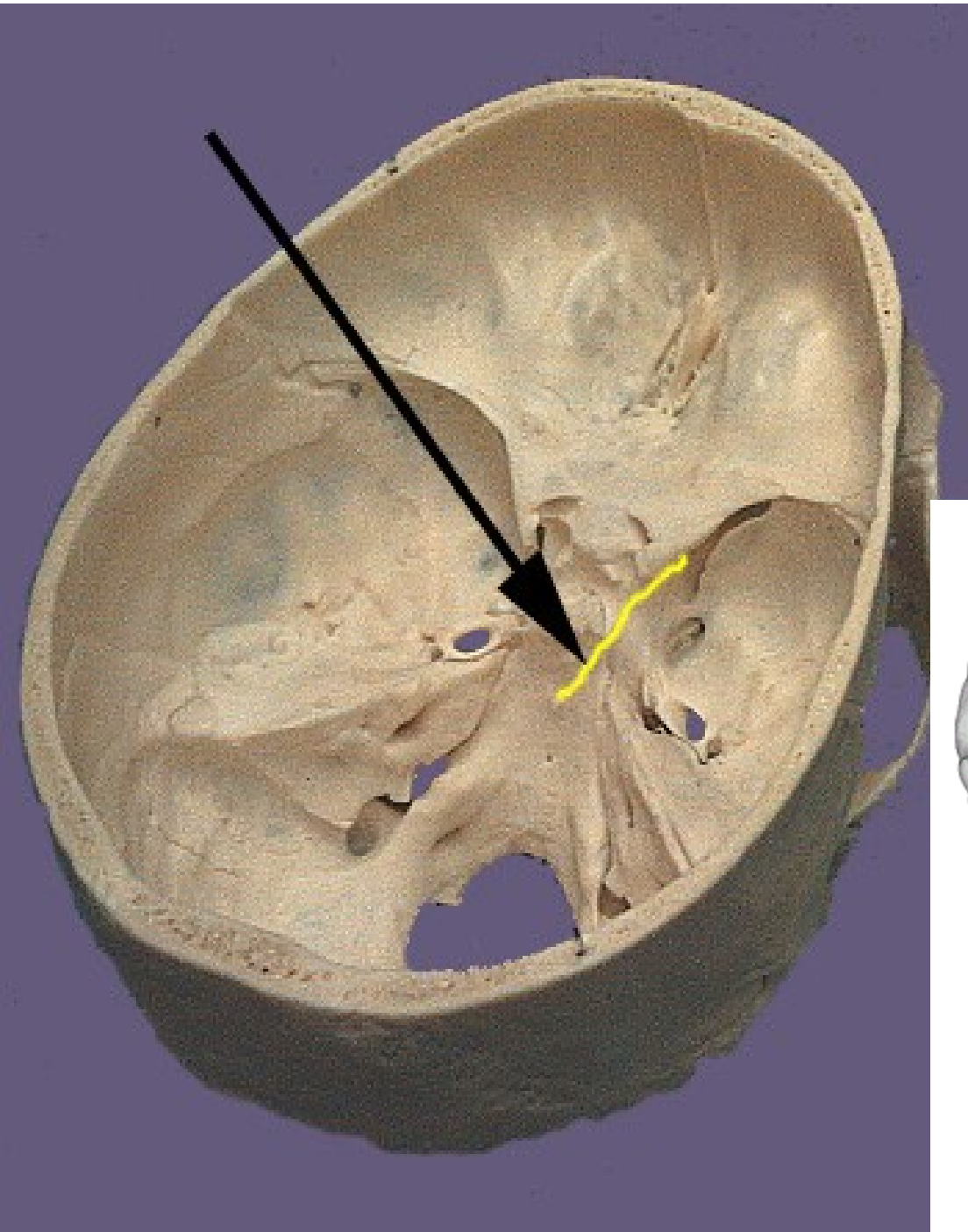


n.III.



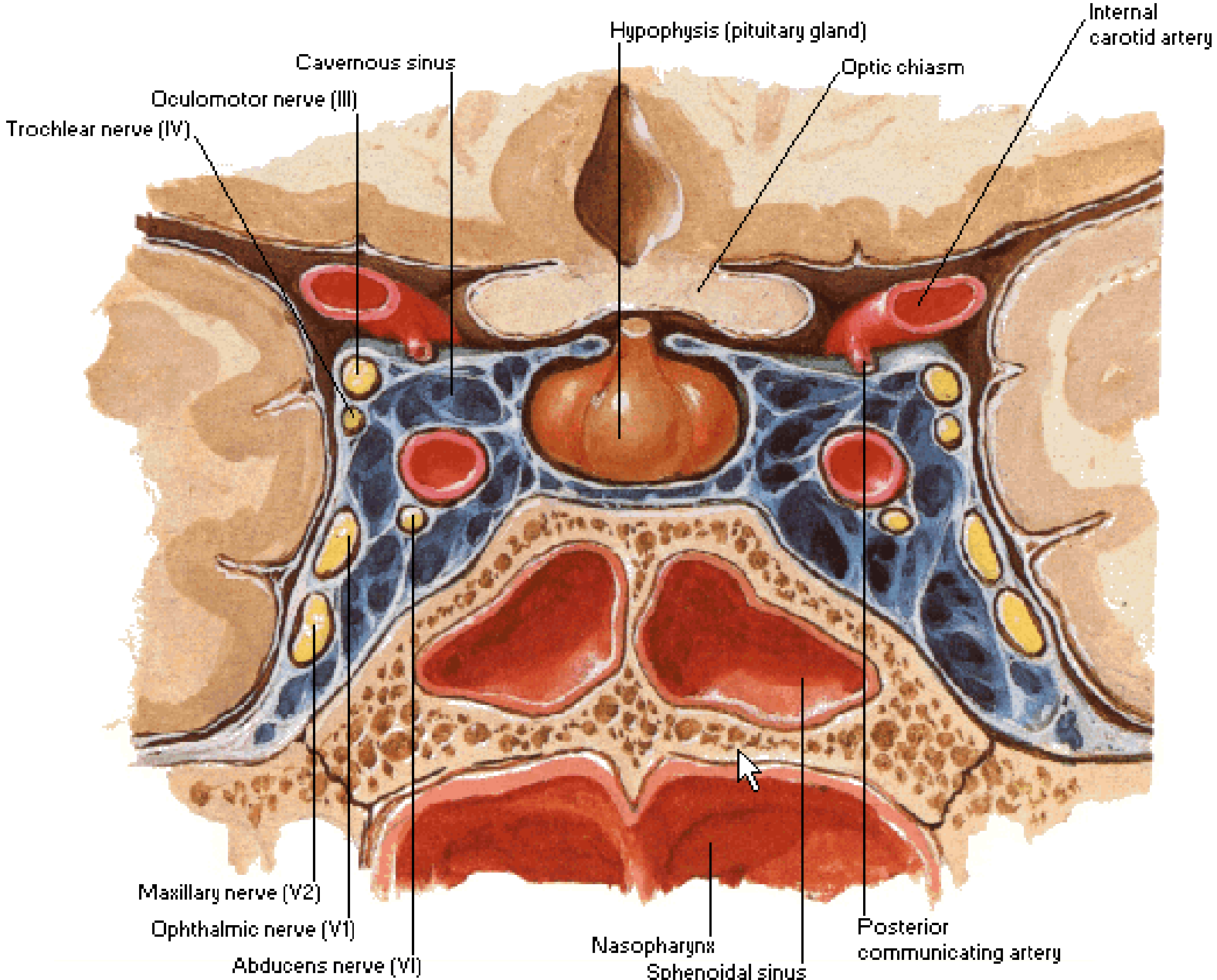
n.IV.

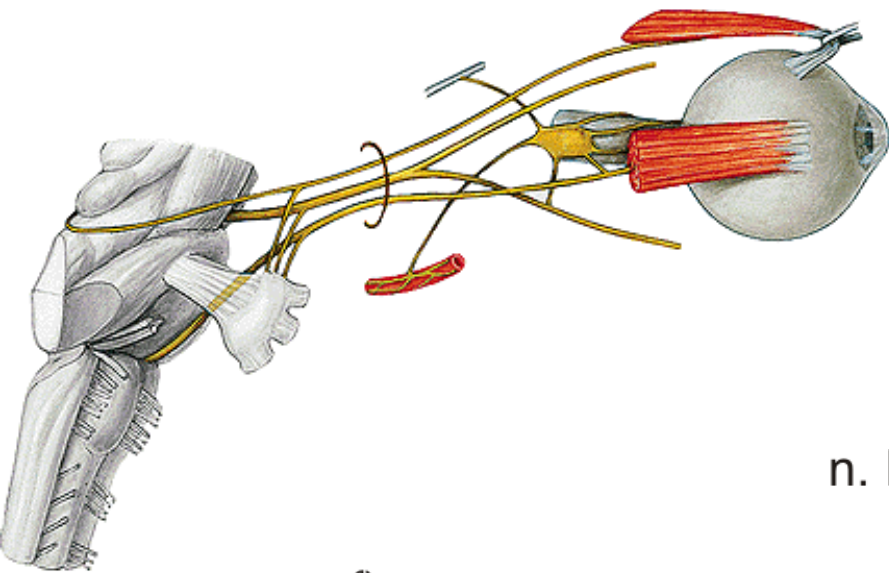
n.VI.



Cavernous Sinus

Coronal Section





Inervační oblasti n. III:

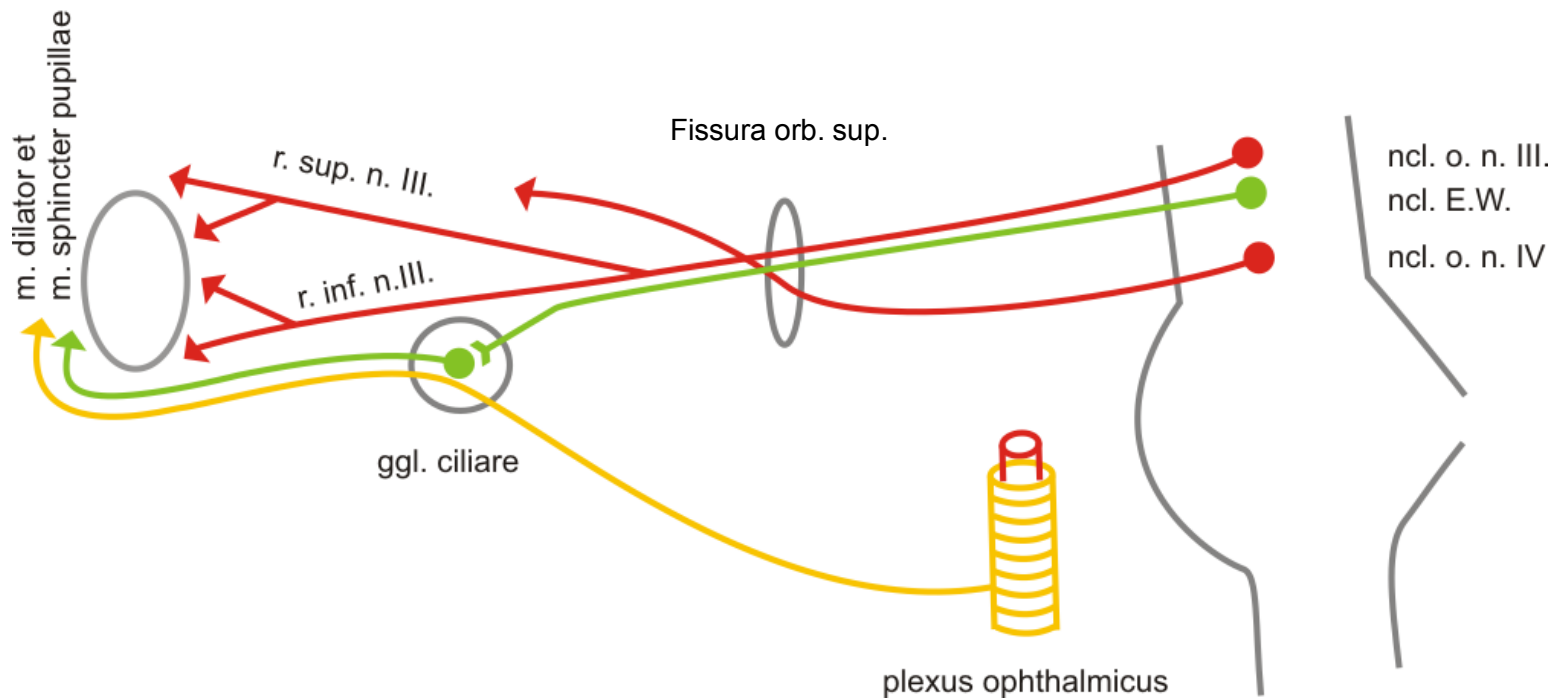
mm. recti orbitales mimo
m. rectus lat.

m. levator palpebrae sup.

m. obliquus inf.

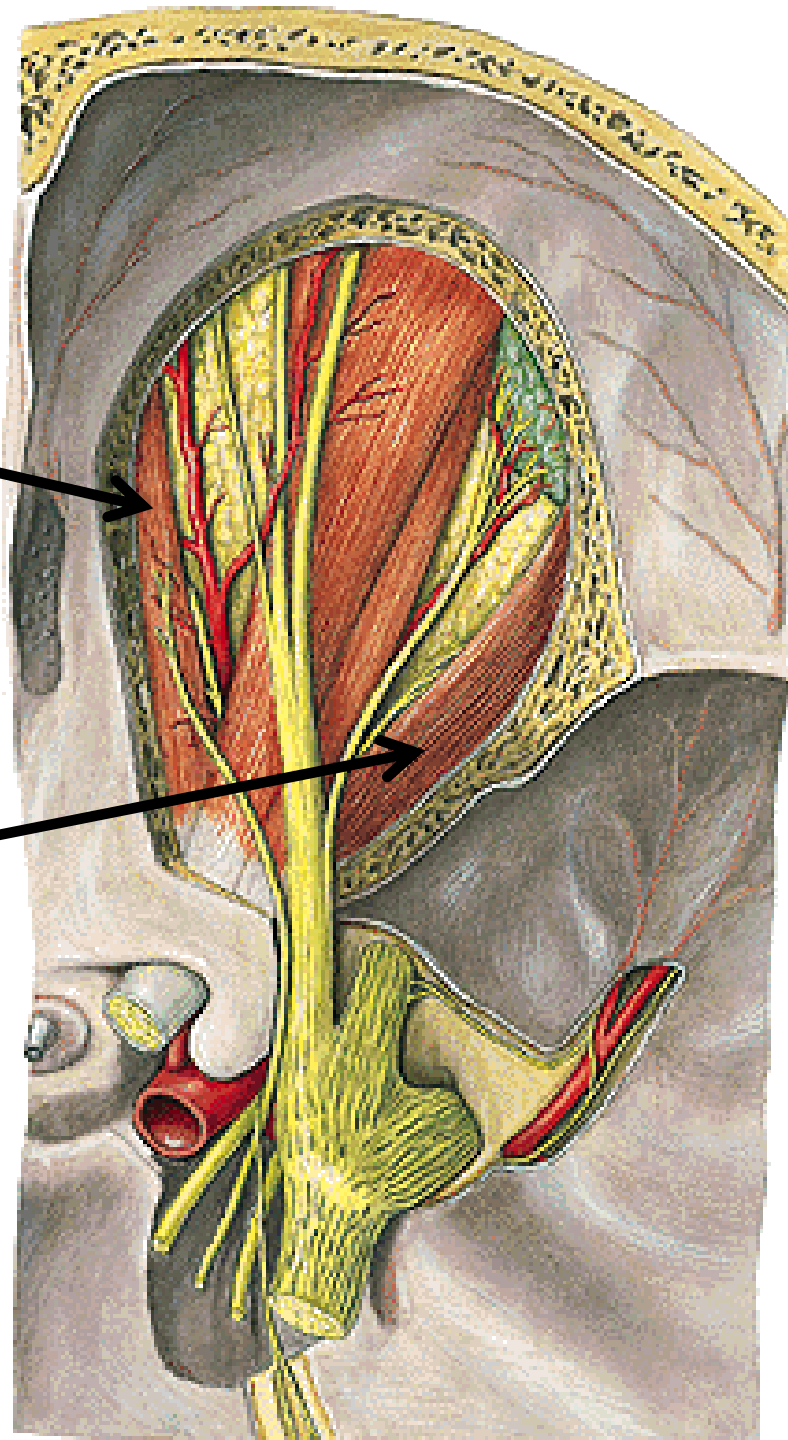
m. dilator (symp.) et sphincter pupillae
(parasymp.)

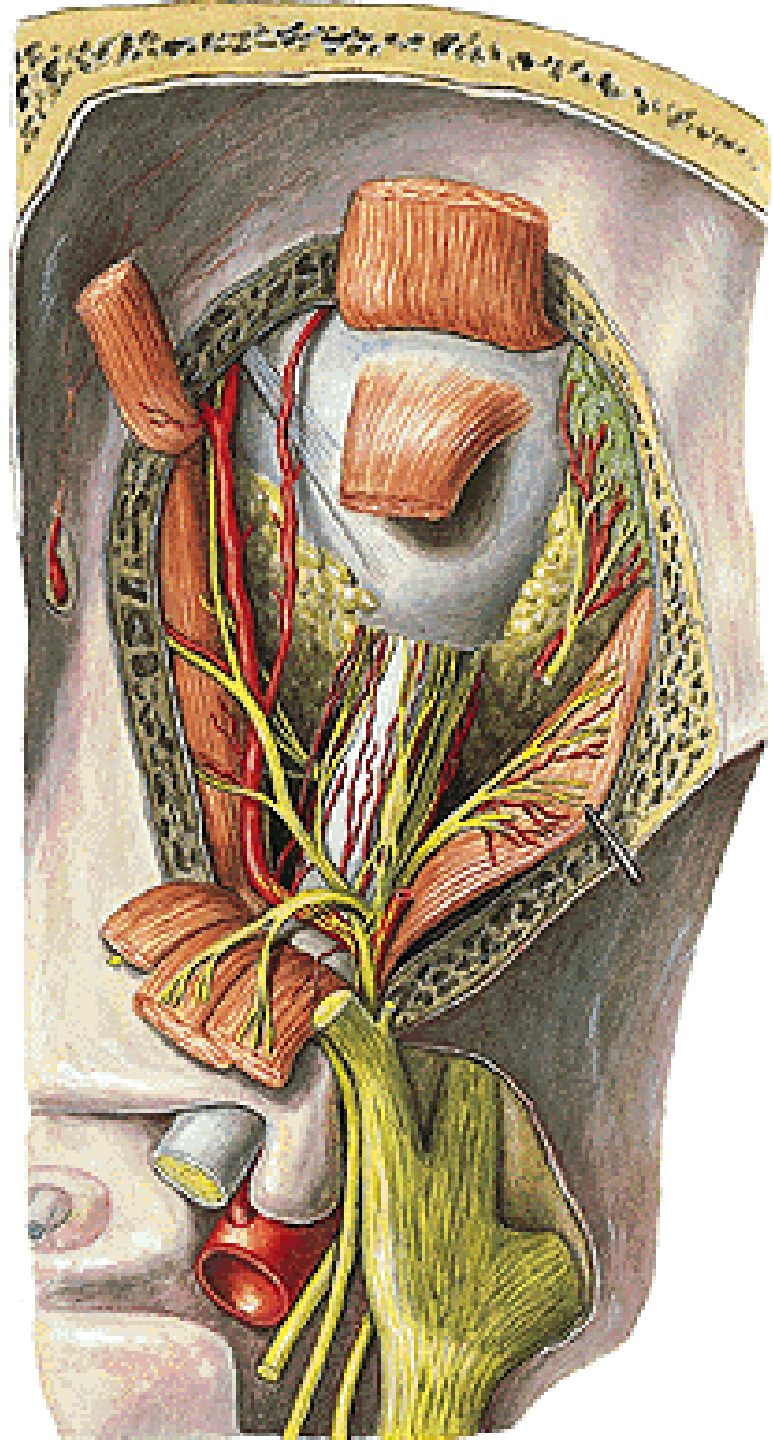
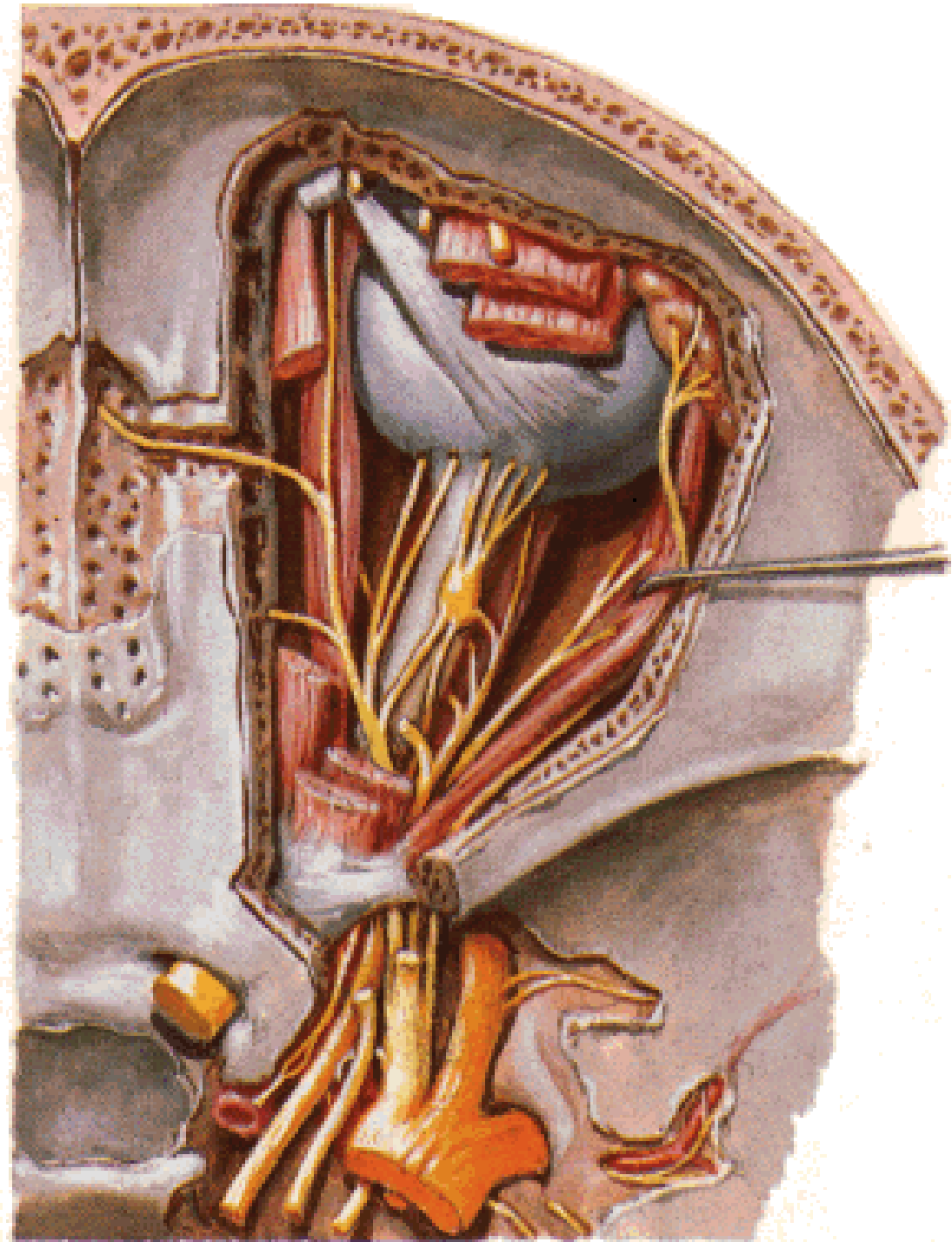
n. III. et IV.

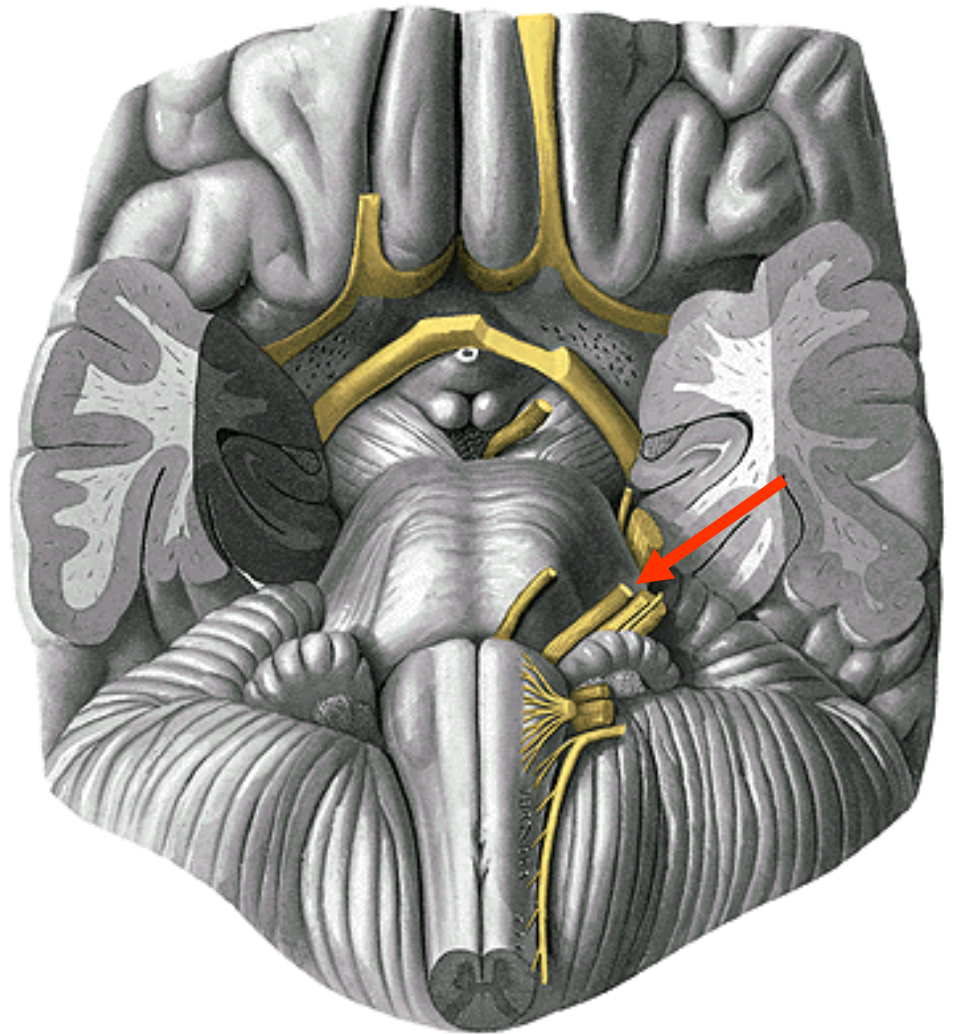
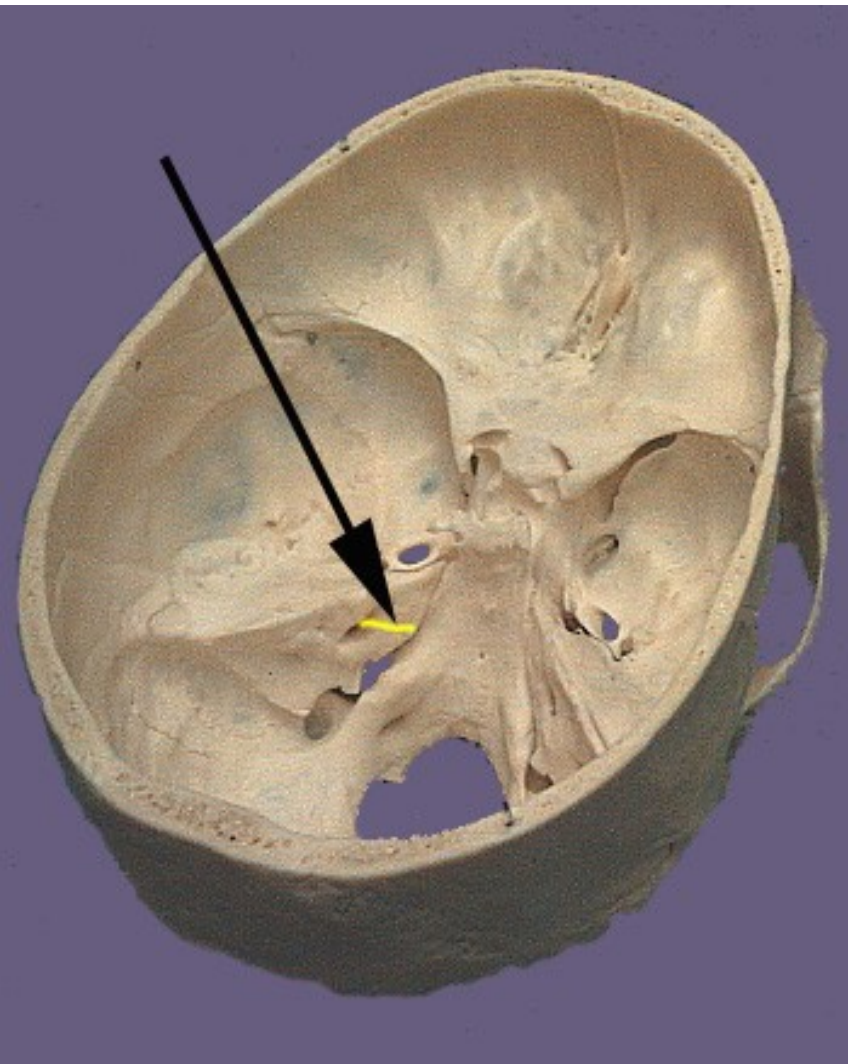


Inervační oblast n. IV.
m. obliquus sup.

Inervační oblast n. VI.
m. rectus lat.

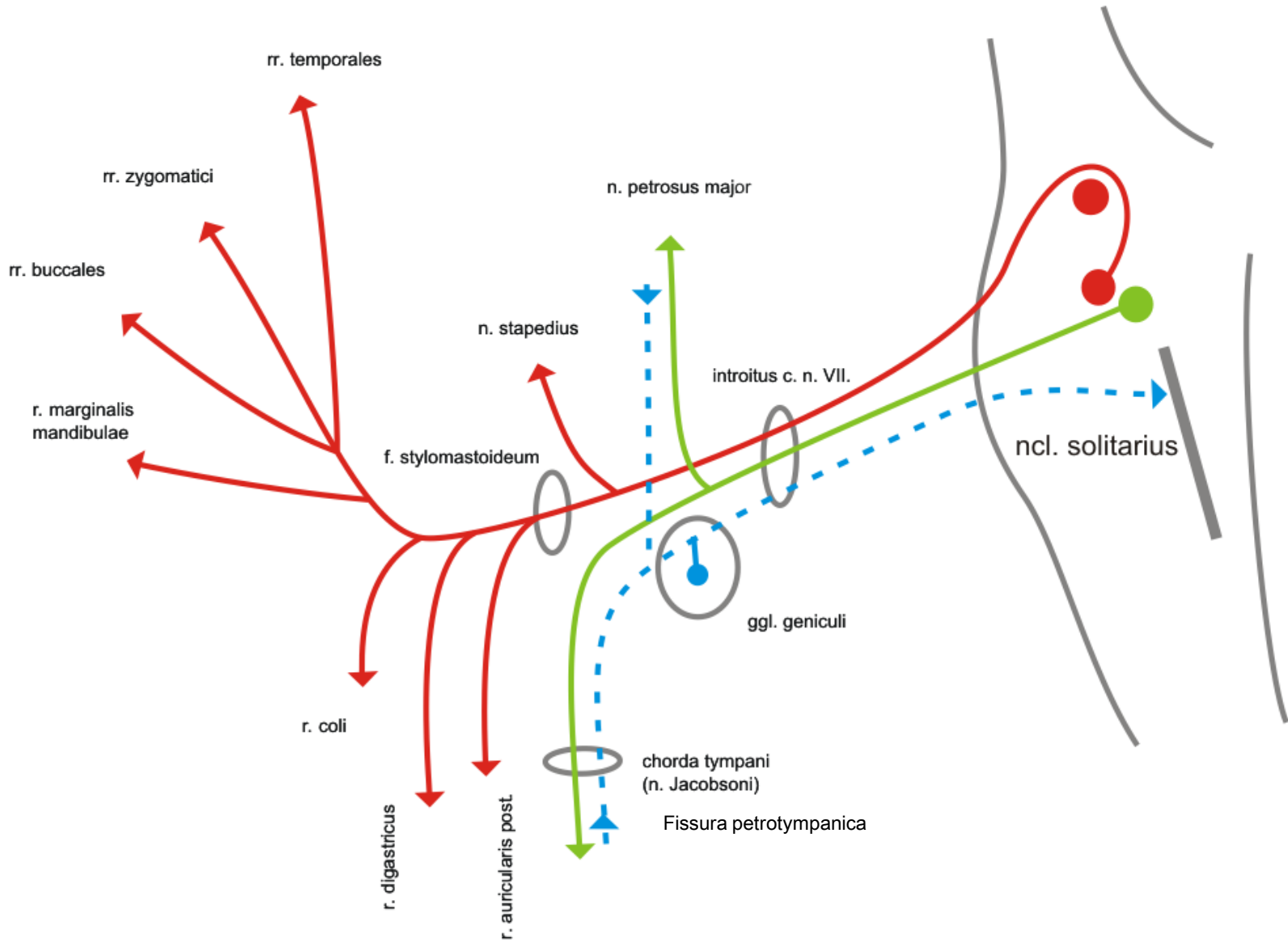






n. VII.

n.VII.



Inervační oblasti n. VII:

Mimické svaly

gl. lacrimalis

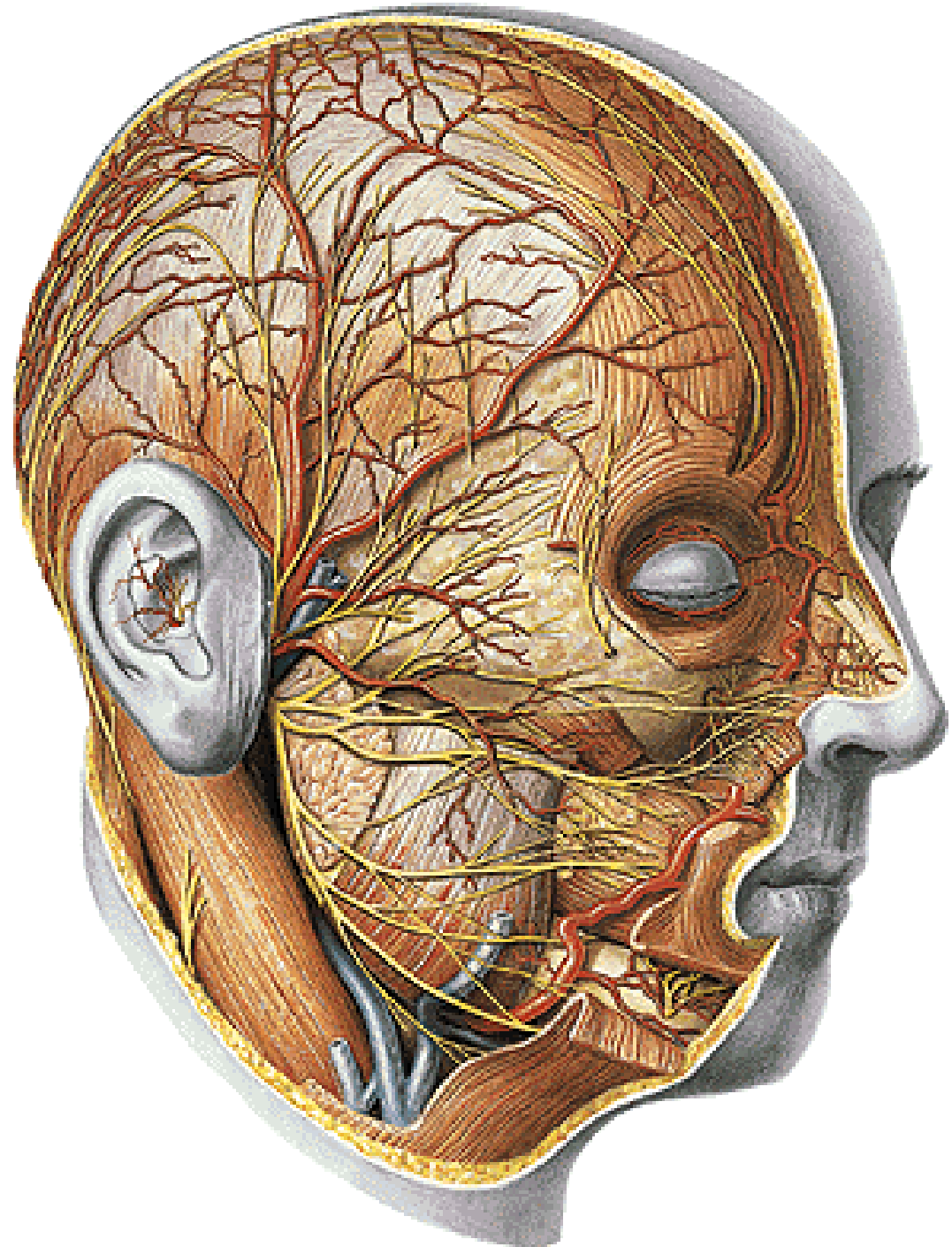
gl. submandibularis

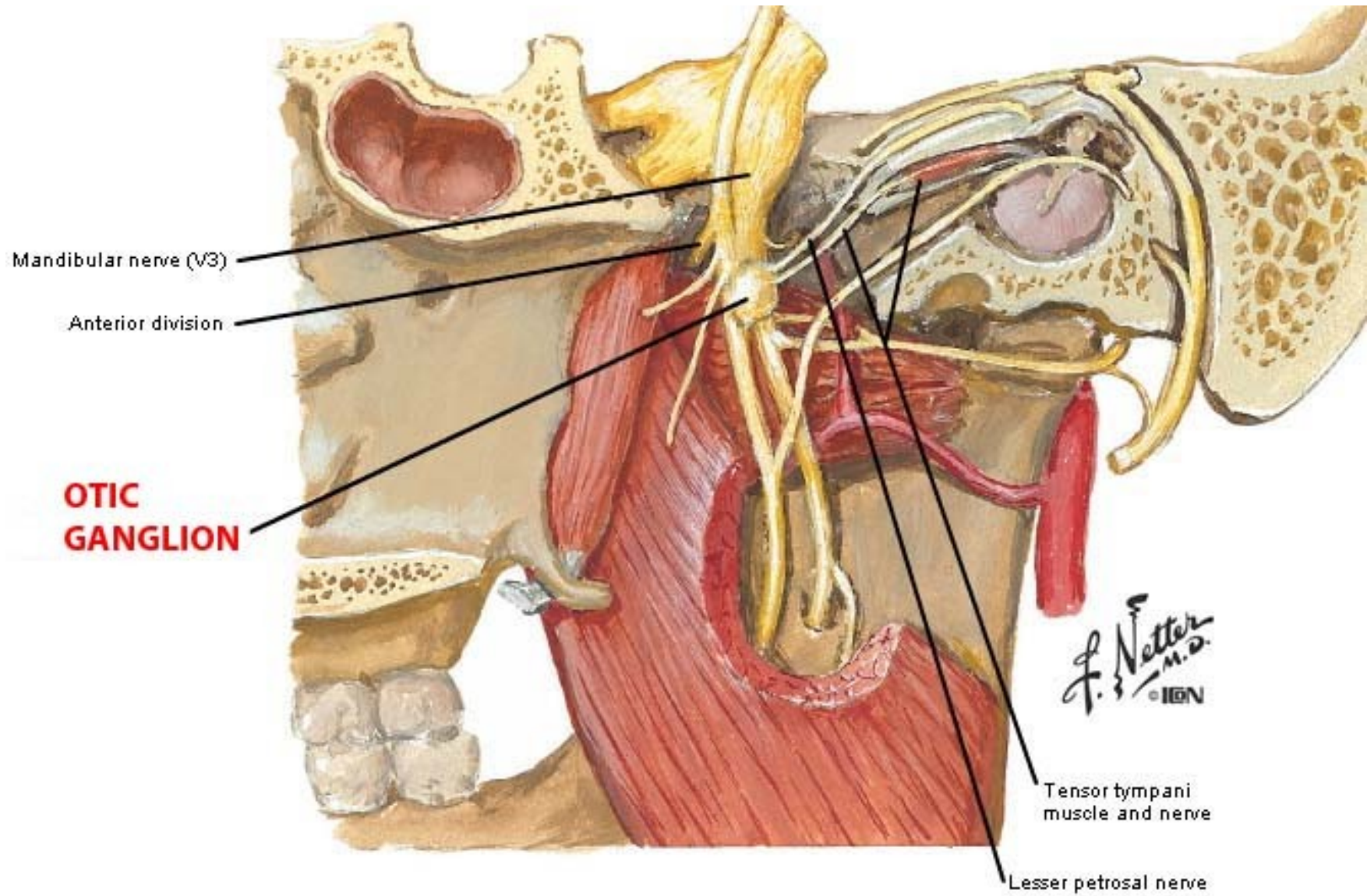
gl. sublingualis

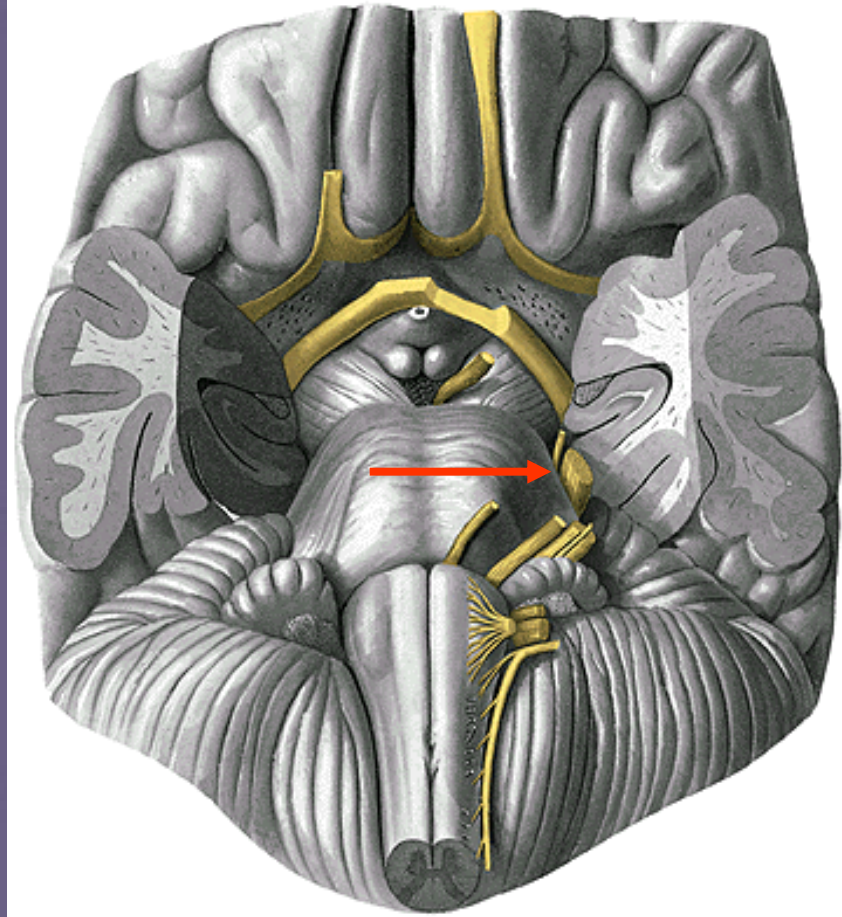
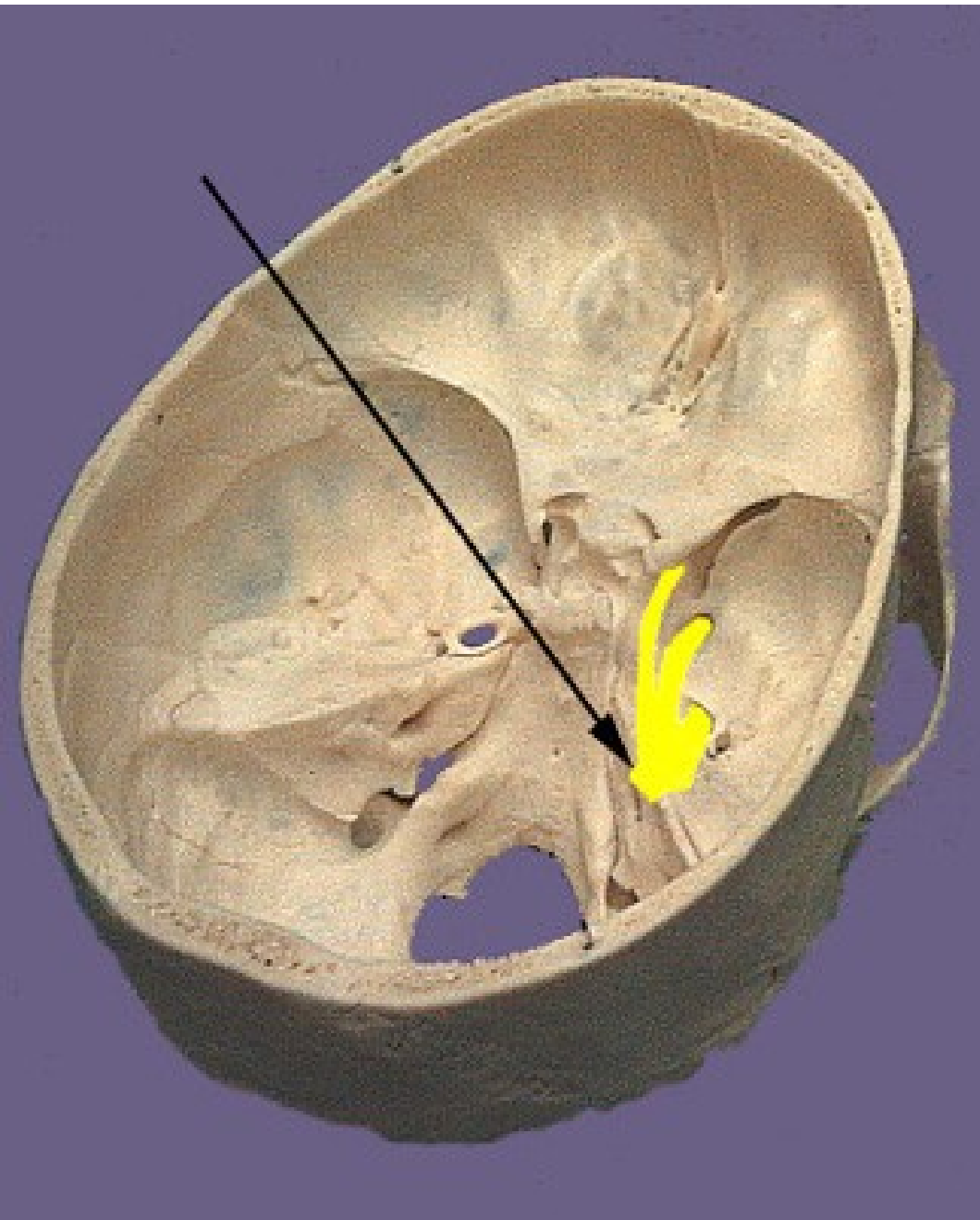
drobné slinné žl. ve sliznici
měkkého a tvrdého patra

chuťové pohárky

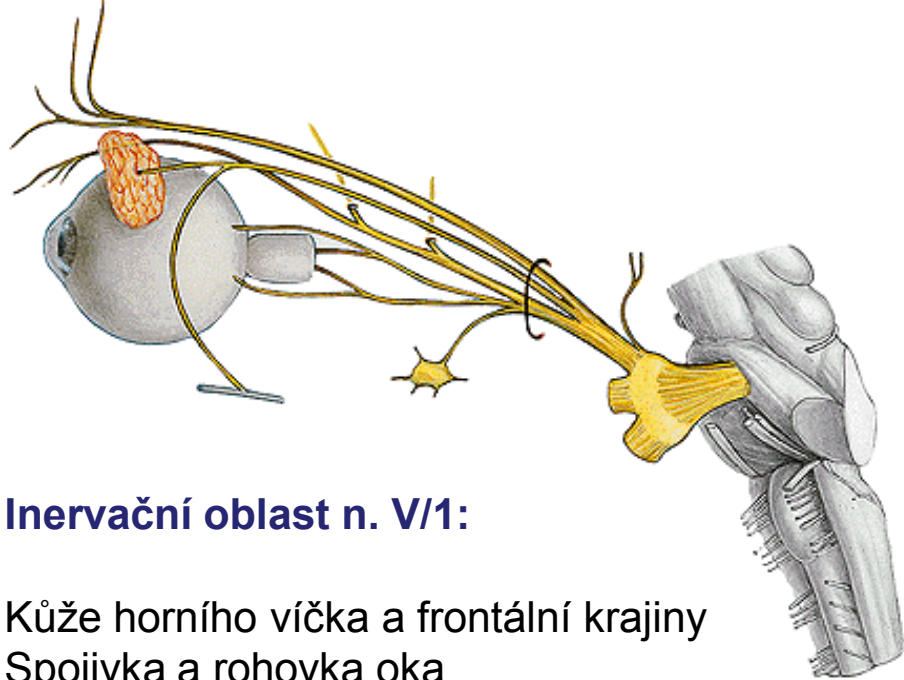
předních 2/3 jazyka a
ve sliznici měkkého a
tvrdého patra



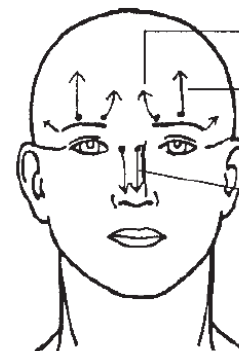
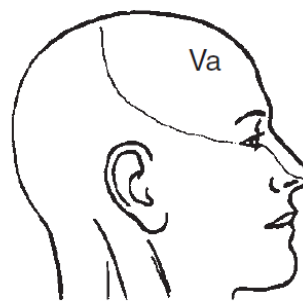




n.V.



Cutaneous distribution

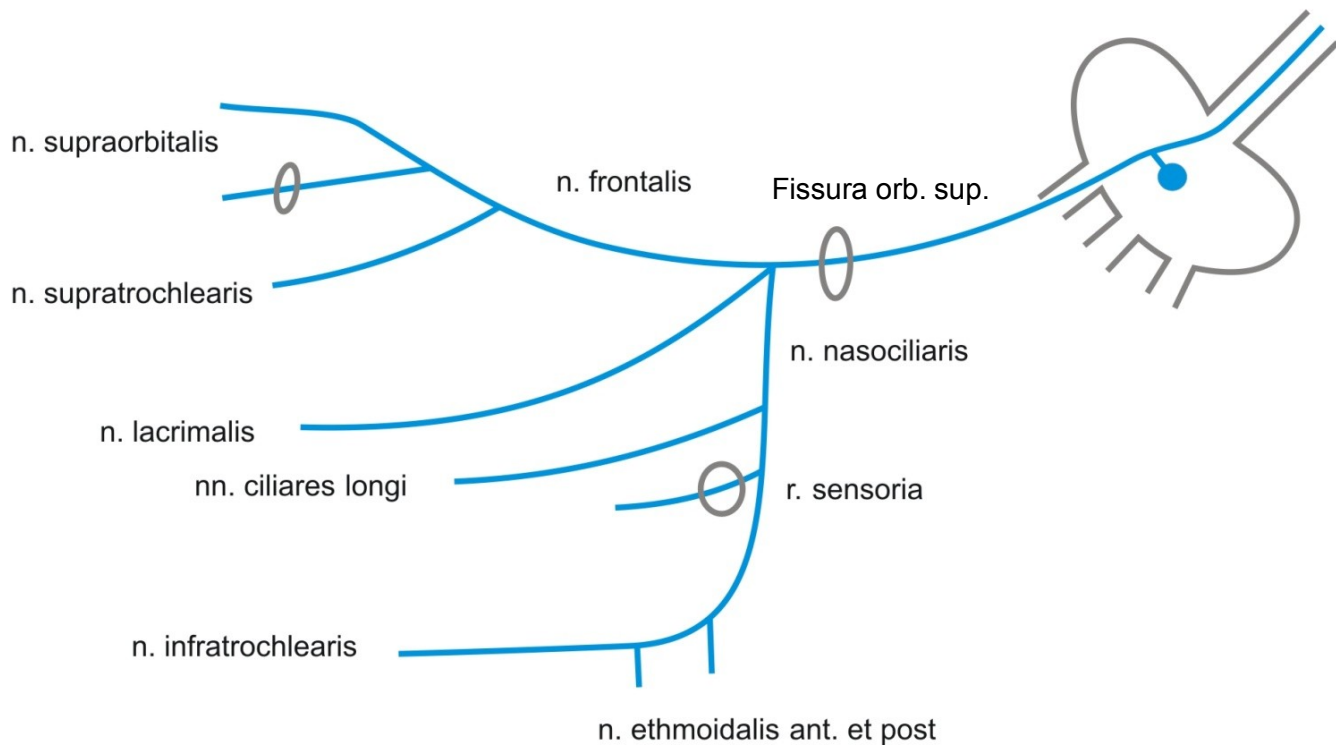


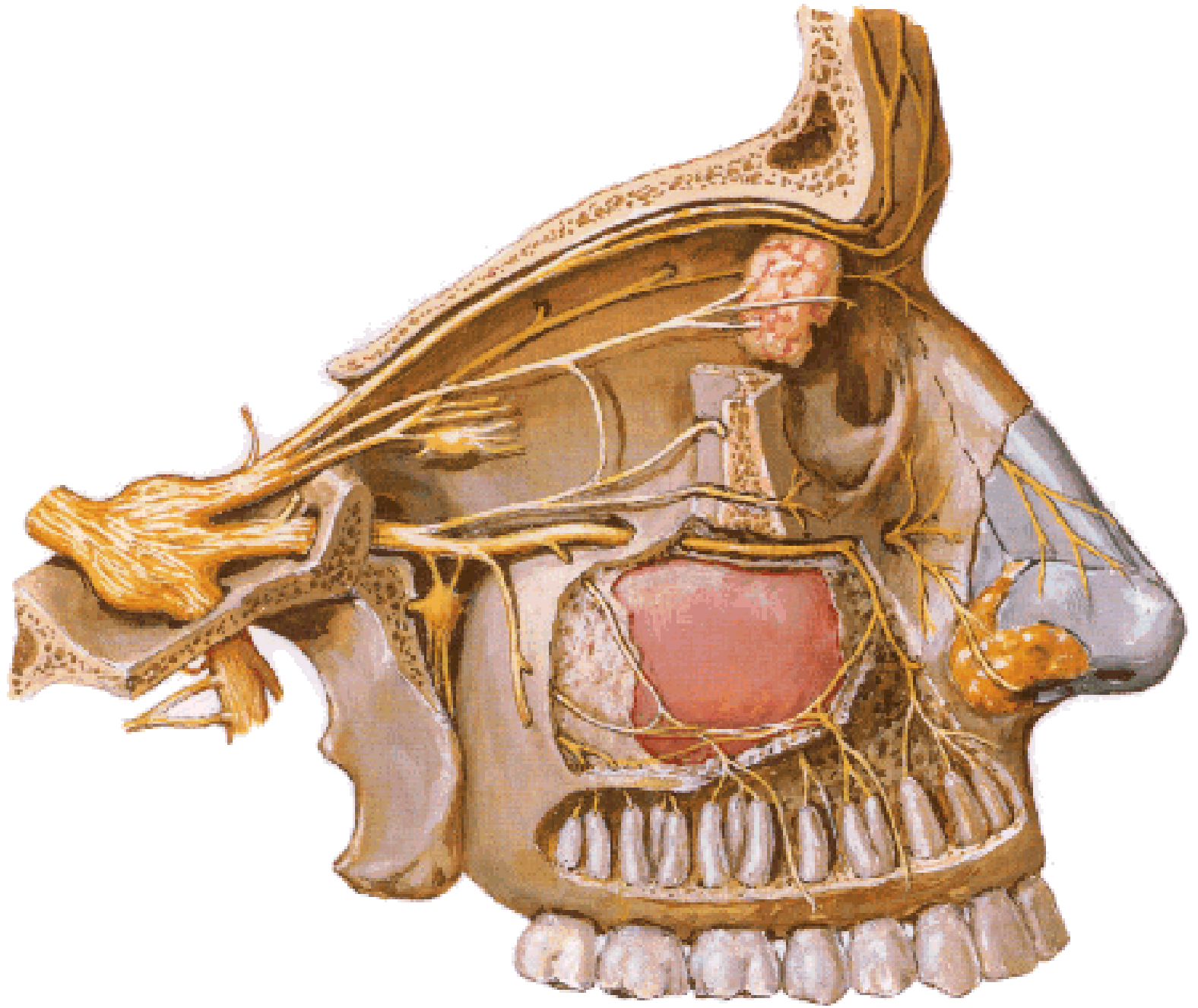
Sinus (broken circle)
 Supratrochlear
 (from frontal)
 Supraorbital
 (from frontal)
 External nasal
 (from nasociliary)

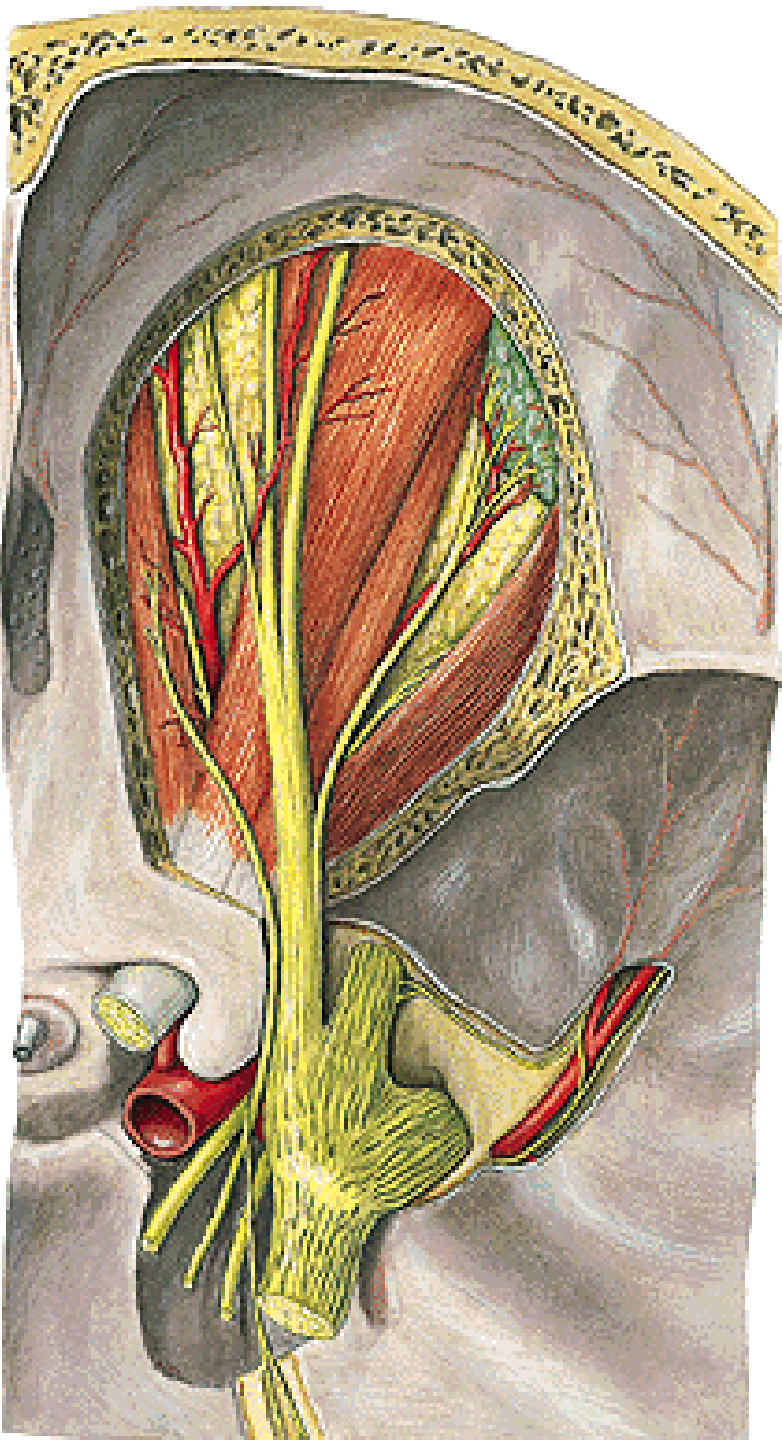
n. V/1 - n. ophthalmicus

Inervační oblast n. V/1:

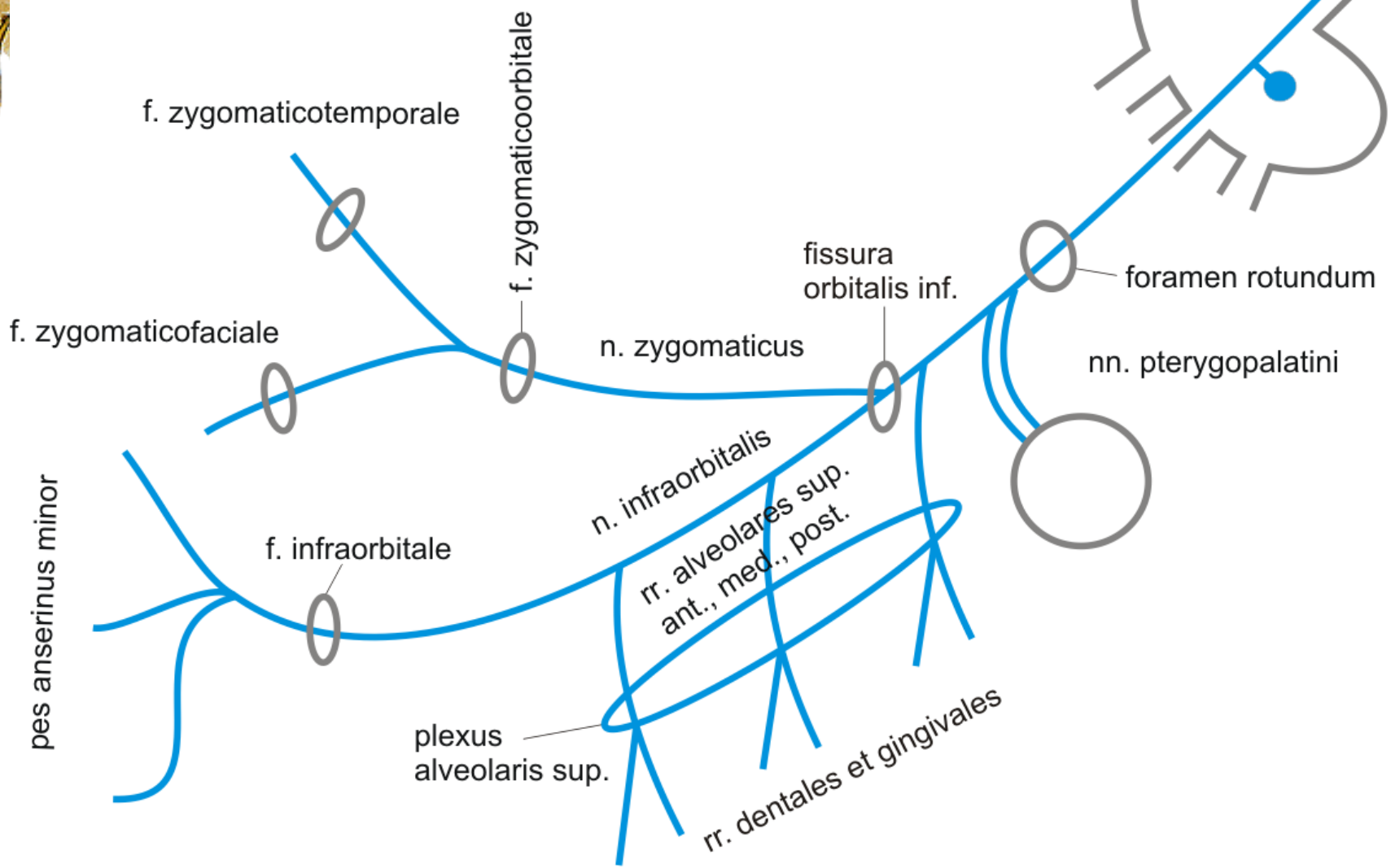

Kůže horního víčka a frontální krajiny
 Spojivka a rohovka oka
 Sliznice celulae ethmoidales

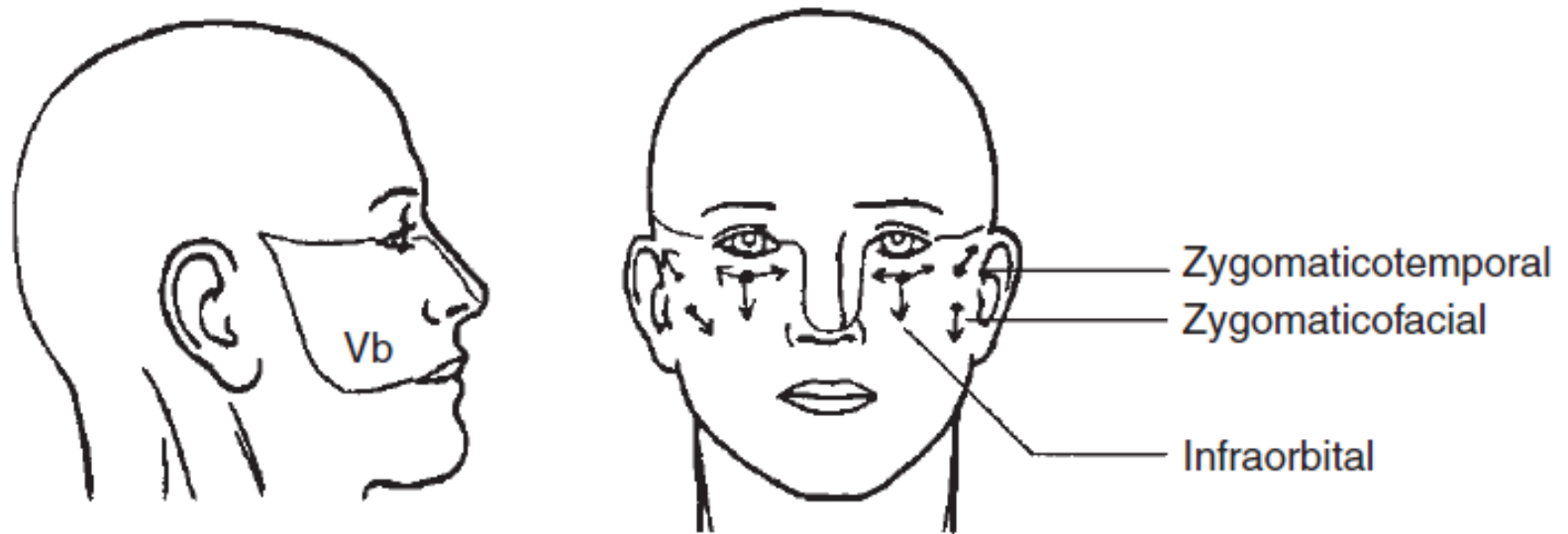






n. V/2 - n. maxillaris

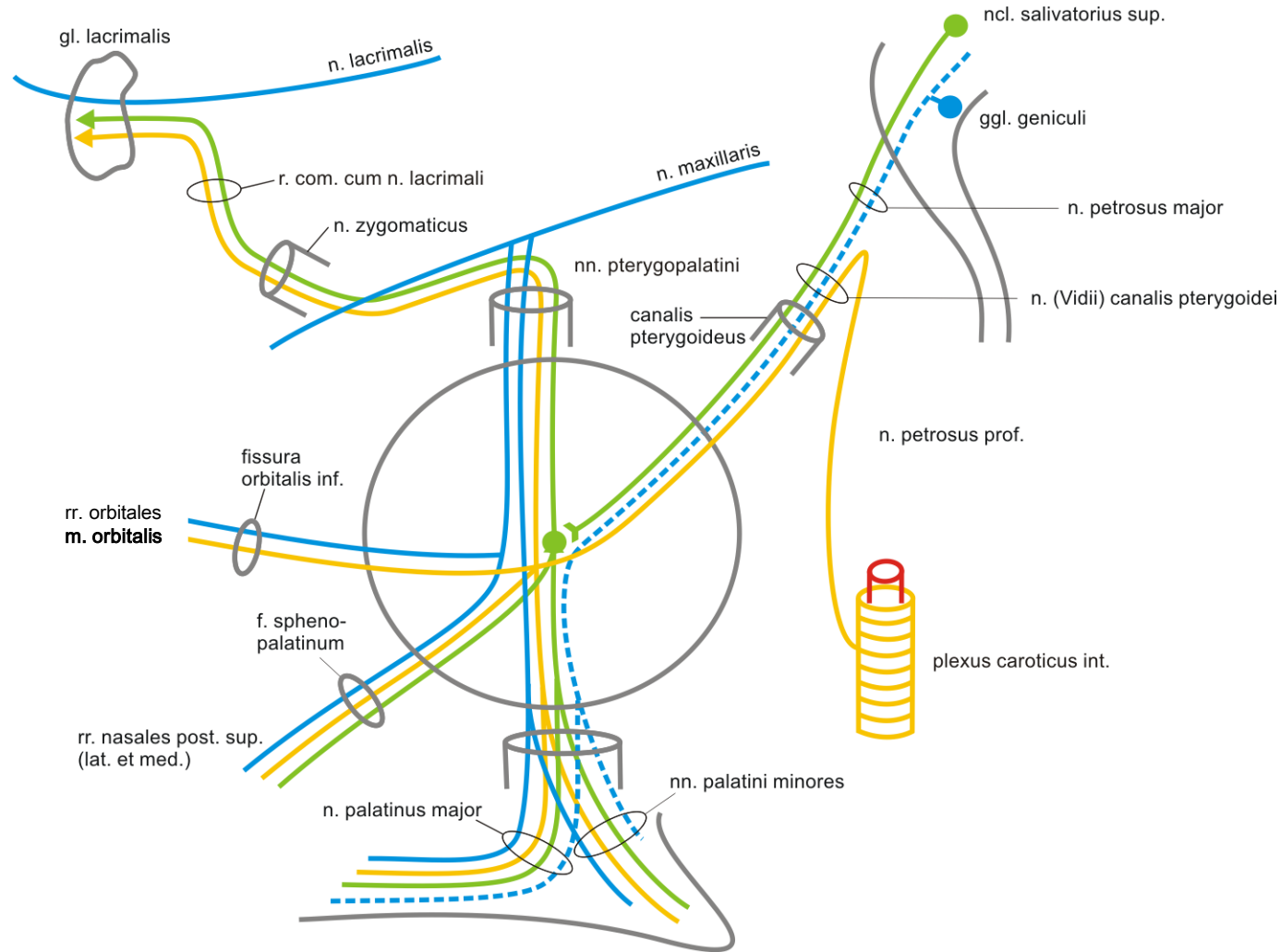




Somatosenzorická inervace n. V/2:

Kůže dolního víčka, křídel nosu, tváře,
gingiva a zuby horní čelisti

ggl. pterygopalatinum

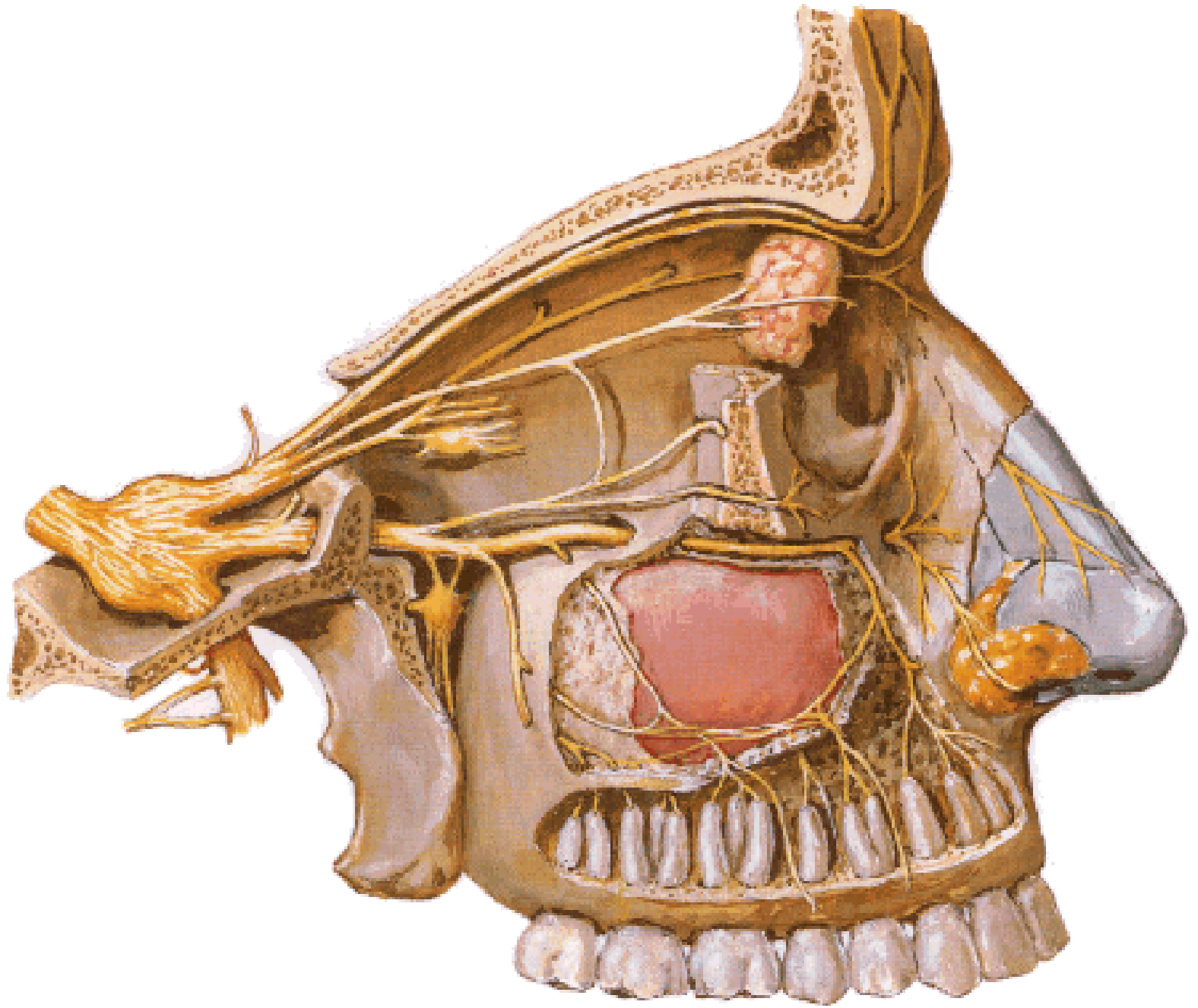


Inervační oblasti:

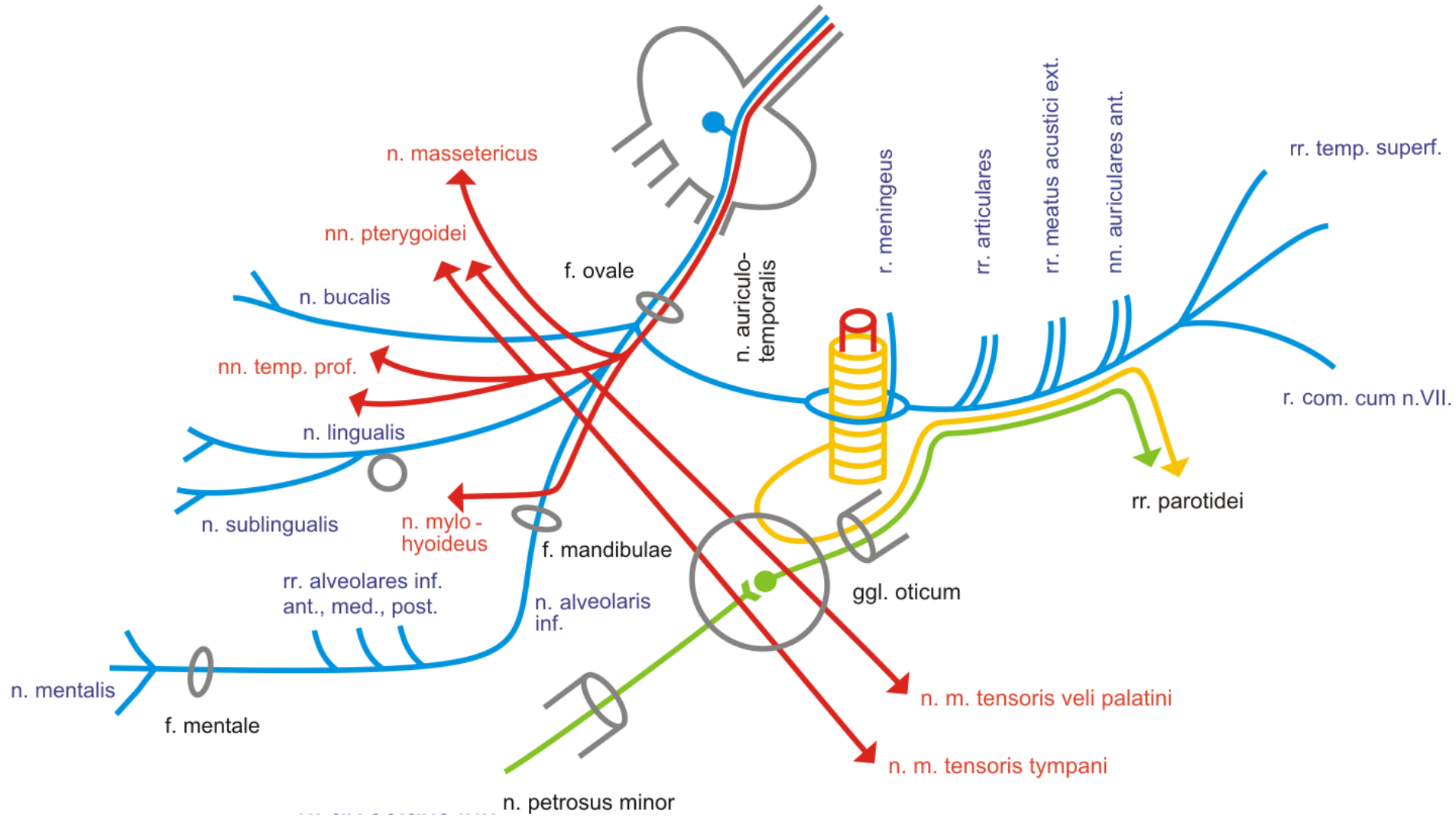
gl. lacrimalis
 m. orbitalis
 sliznice dutiny nosní
 sliznice měkkého a
 tvrdého patra

Typy nervových vláken

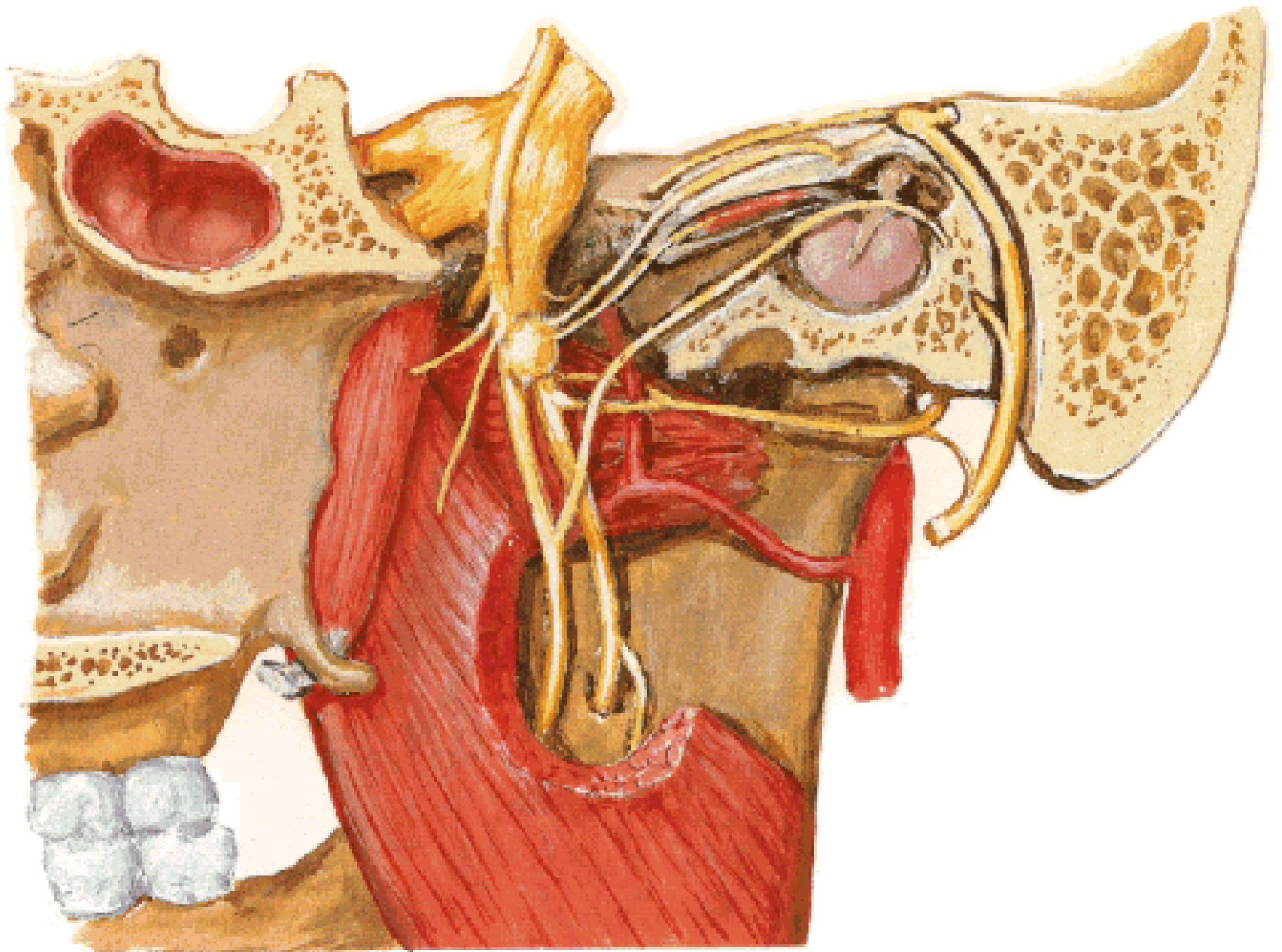
- | | | | |
|-------------------------------------------------------------------------------------|------------------|---------------------------------------------------------------------------------------|---------------|
|  | senzorická |  | sympatická |
|  | somatosenzorická |  | parasymptická |

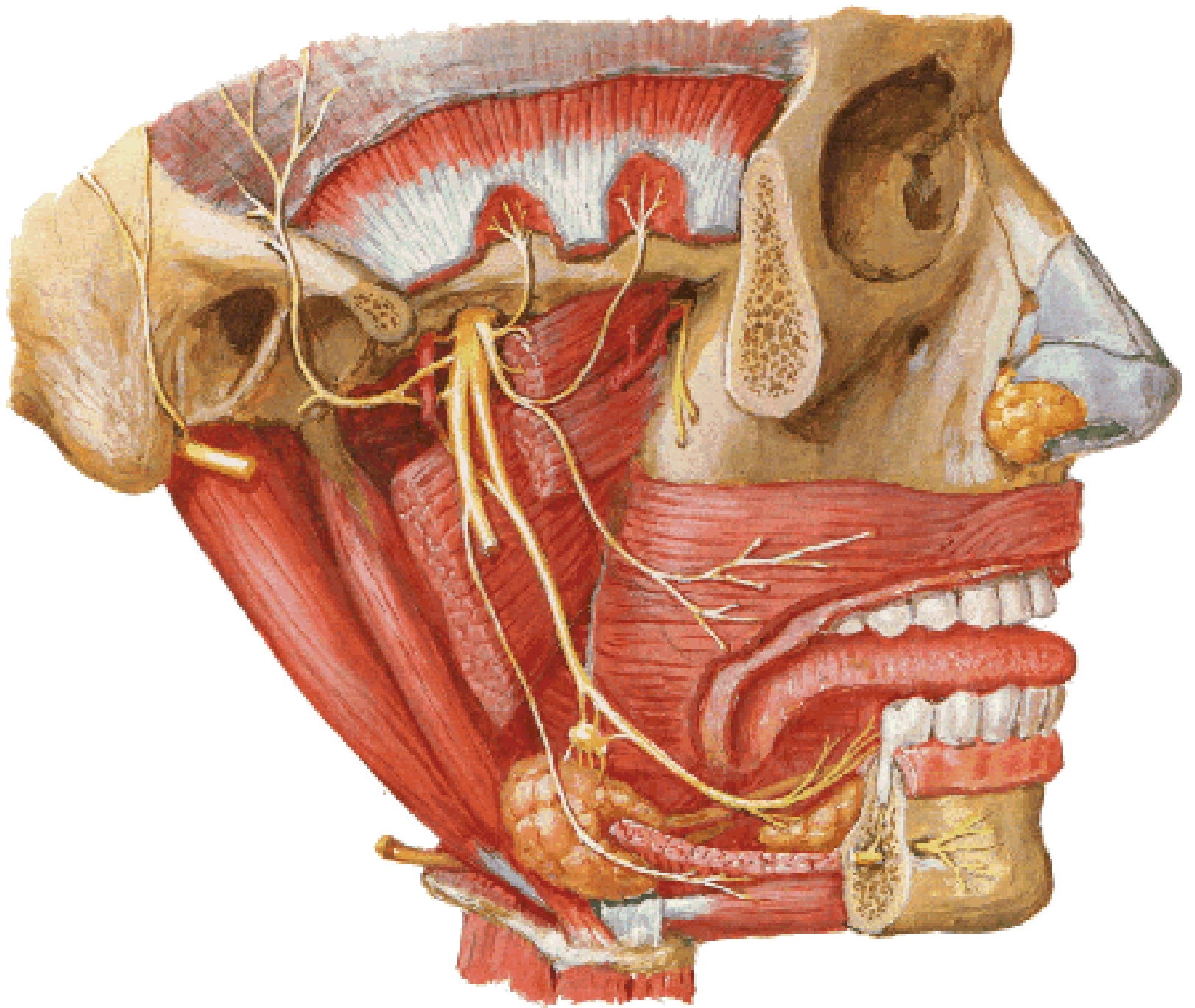


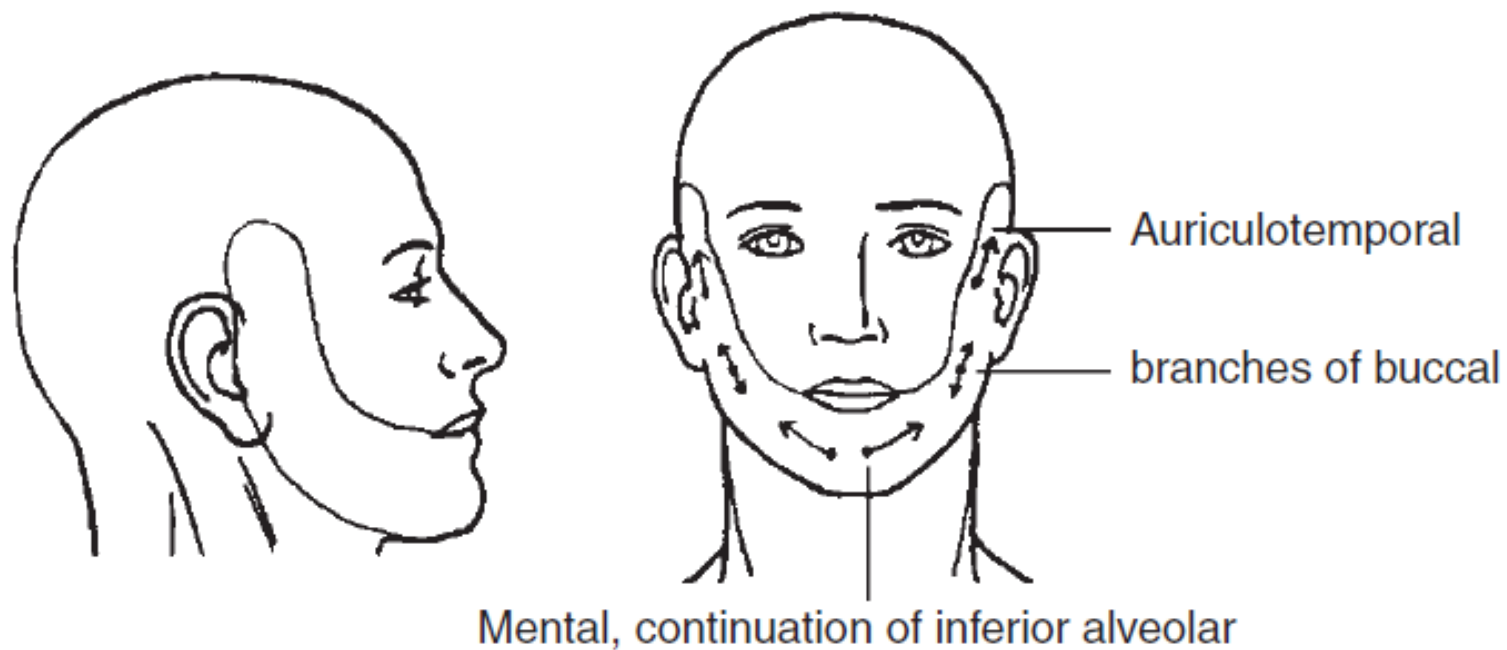
n. V/3 - n. mandibularis



n. tympanicus – n. petrosus minor – ggl. oticum = *Jacobsonova anastomóza*





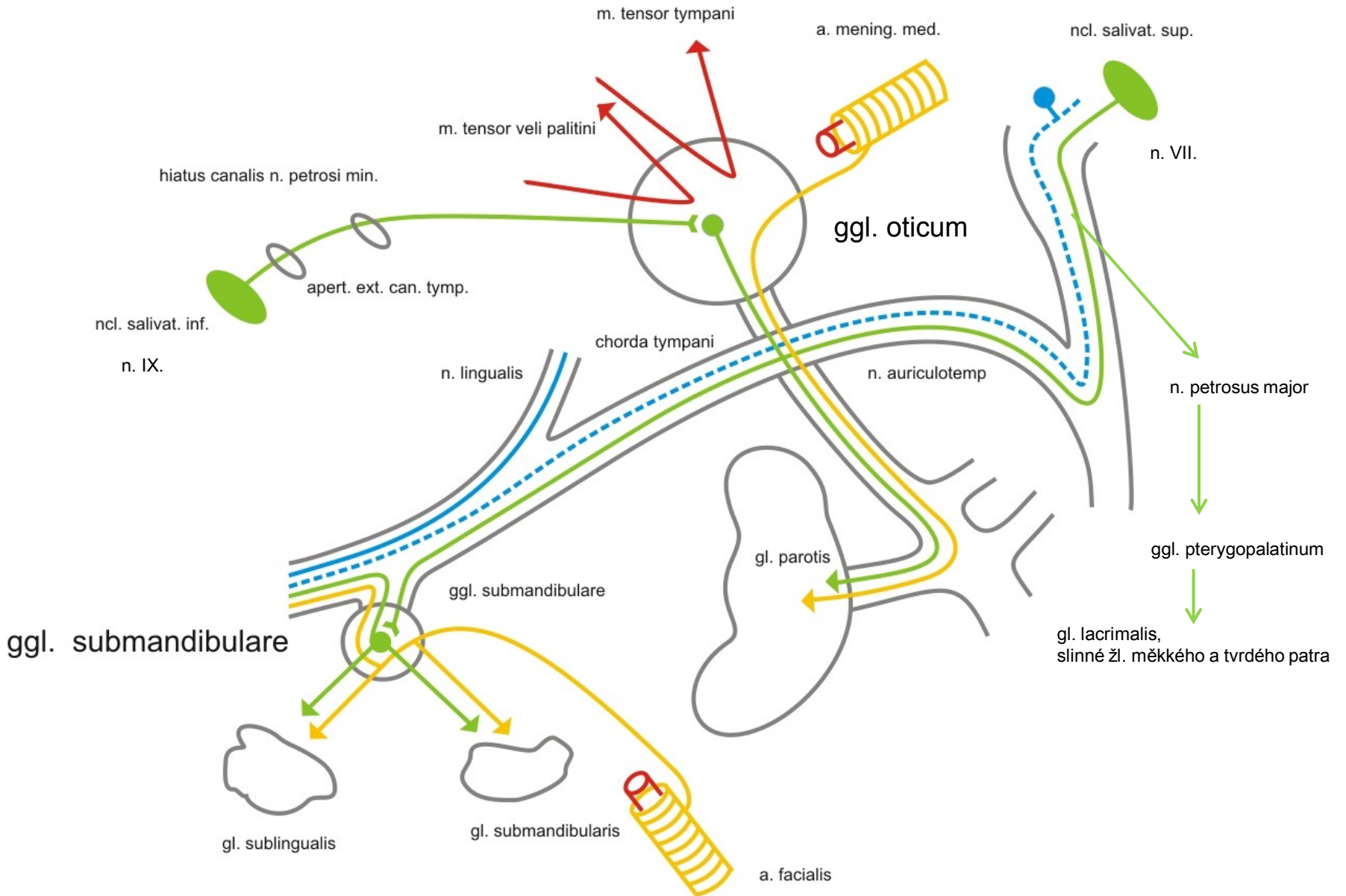


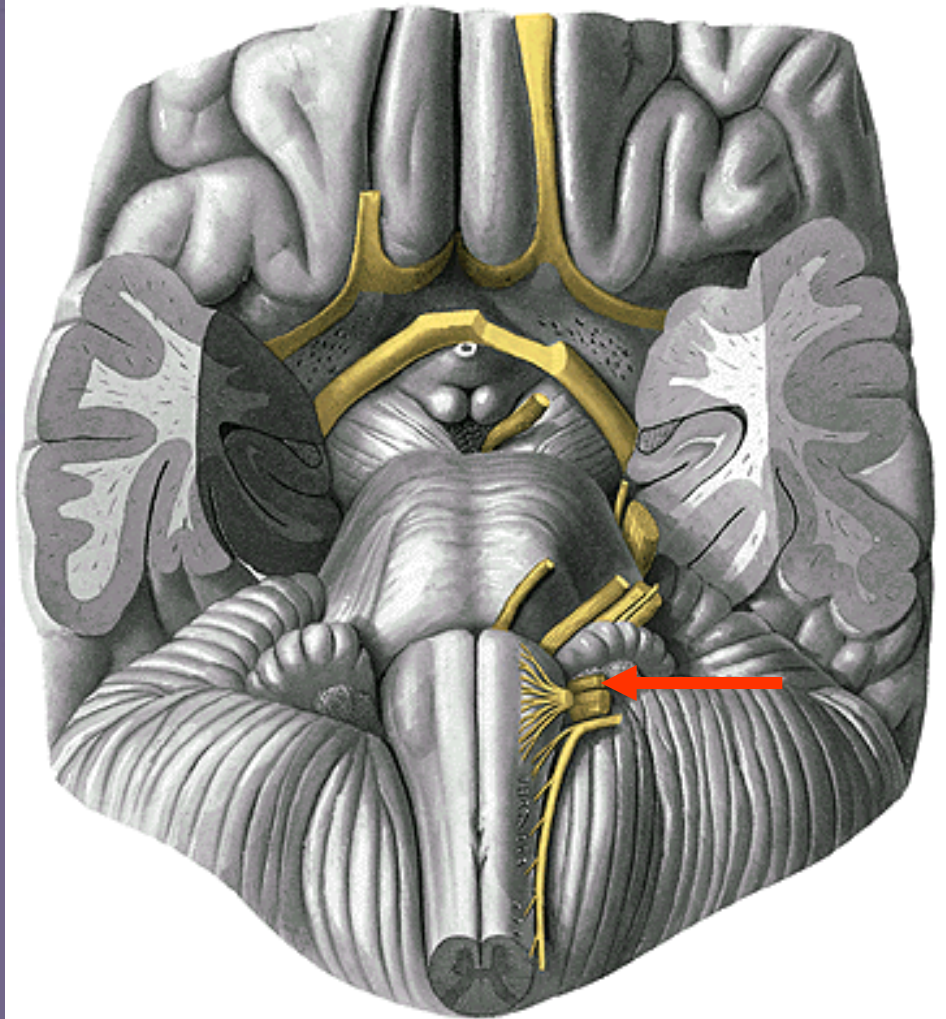
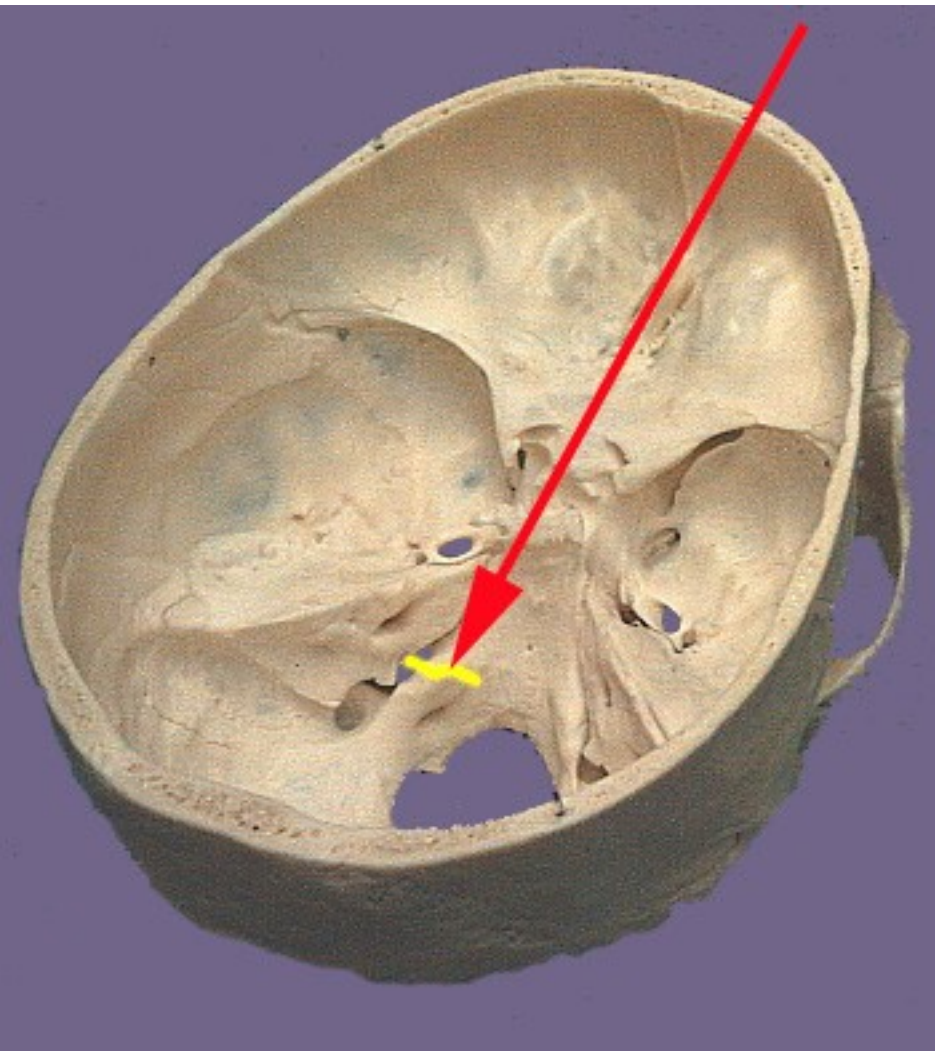
Somatosenzorická inervace n. V/3:

Kůže dolní čelisti

Gingiva a zuby dolní čelisti

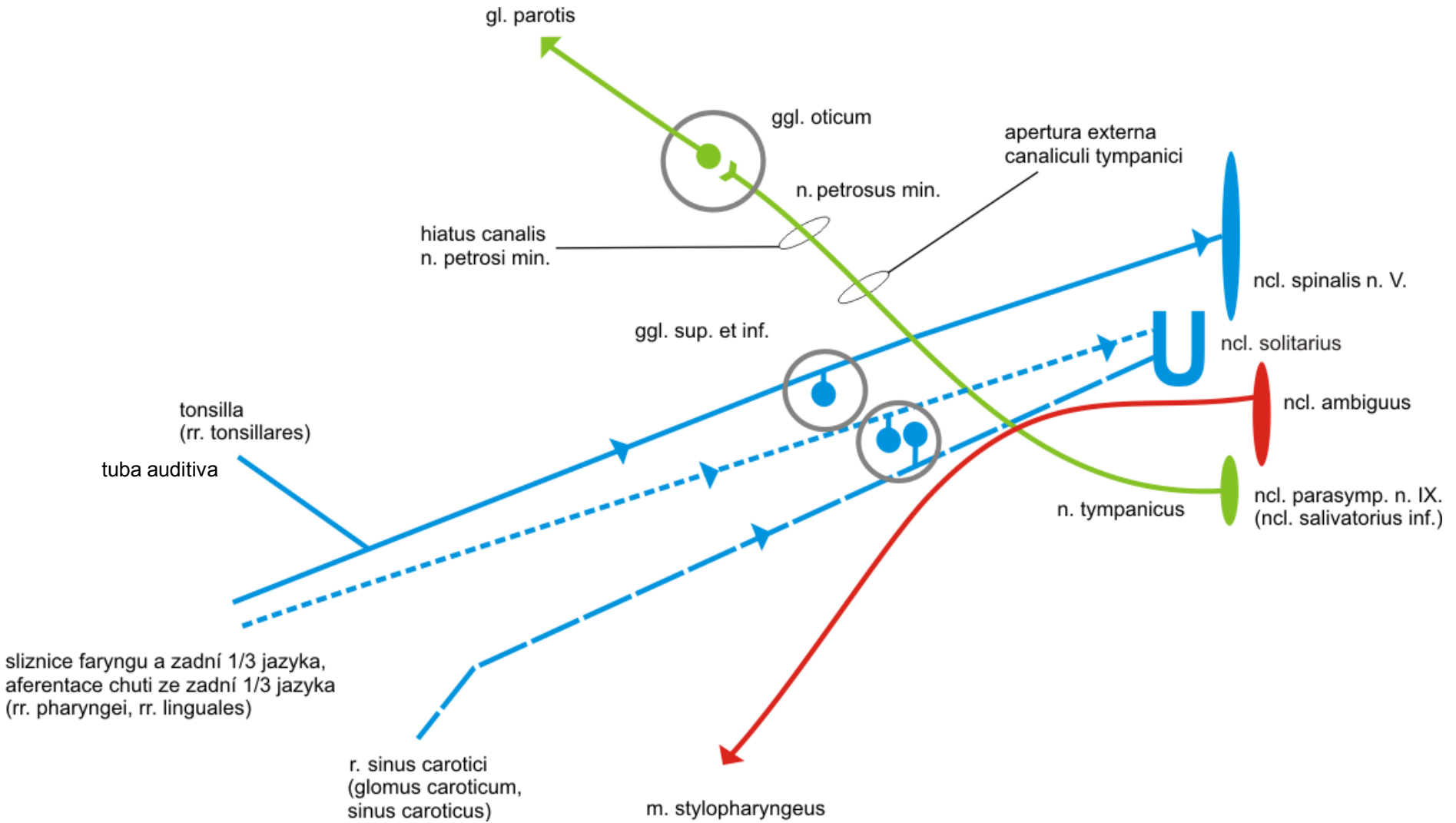
Ggl. oticum et submandibulare





n. IX.

n. IX.



Inervační oblasti n. IX:

Somatosenzoricky

- Sliznice faryngu
- Tonsilla palatina, tuba auditiva
- Sliznice zadní třetiny jazyka

Senzoricky (chuť)

- Chuťové pohárky
- zadní třetiny jazyka

Viscerosenzoricky

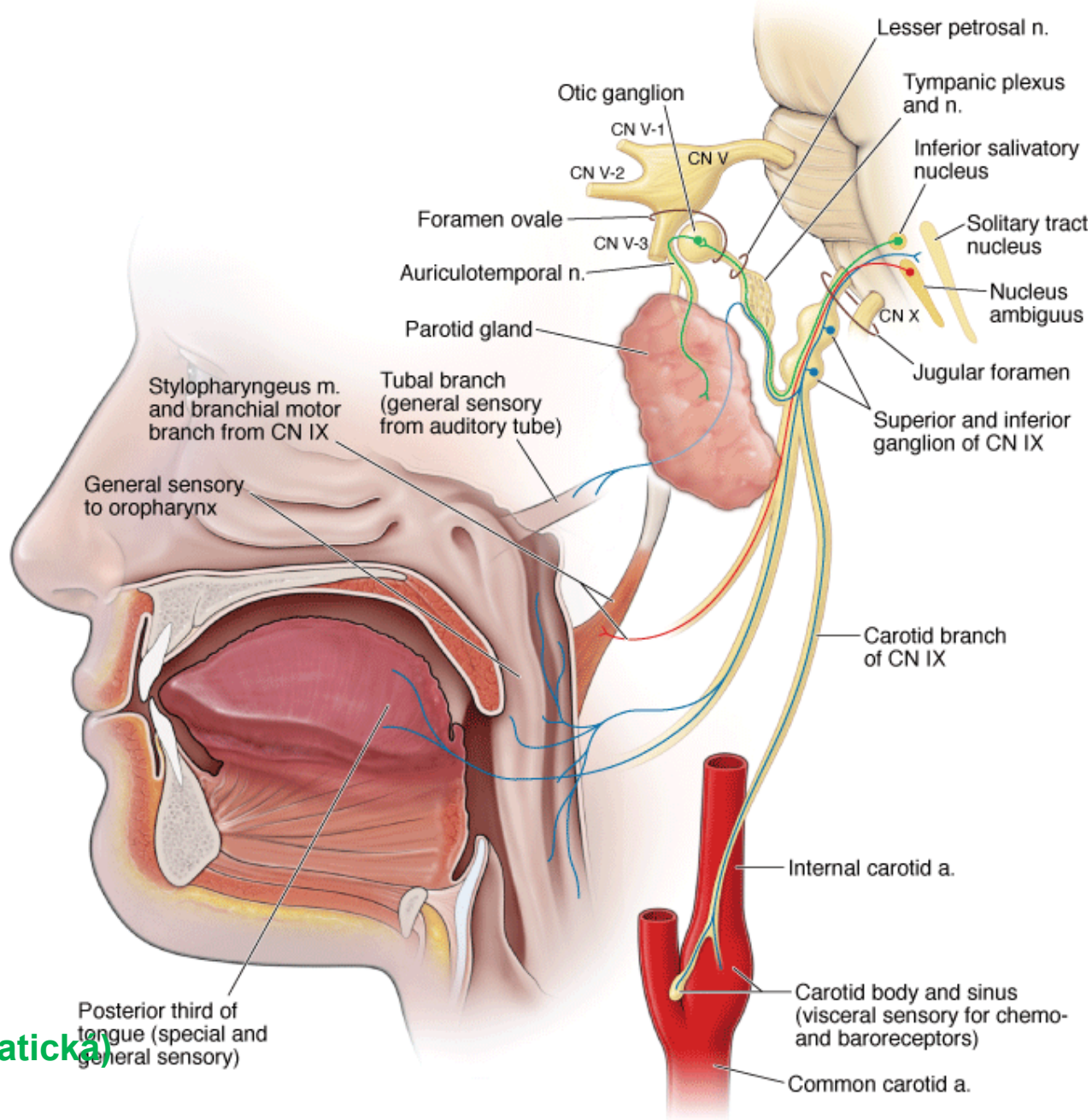
- Glomus caroticum
- Sinus caroticus

Motoricky (Branchiomotor.)

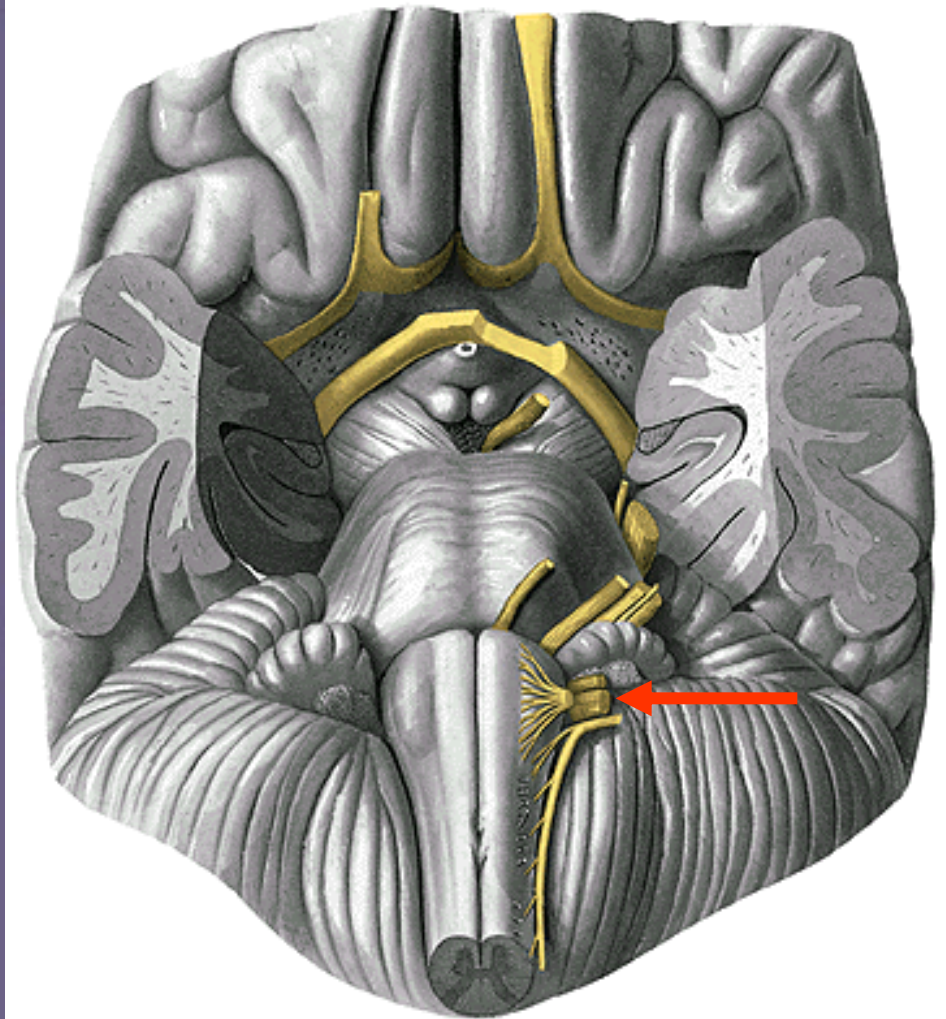
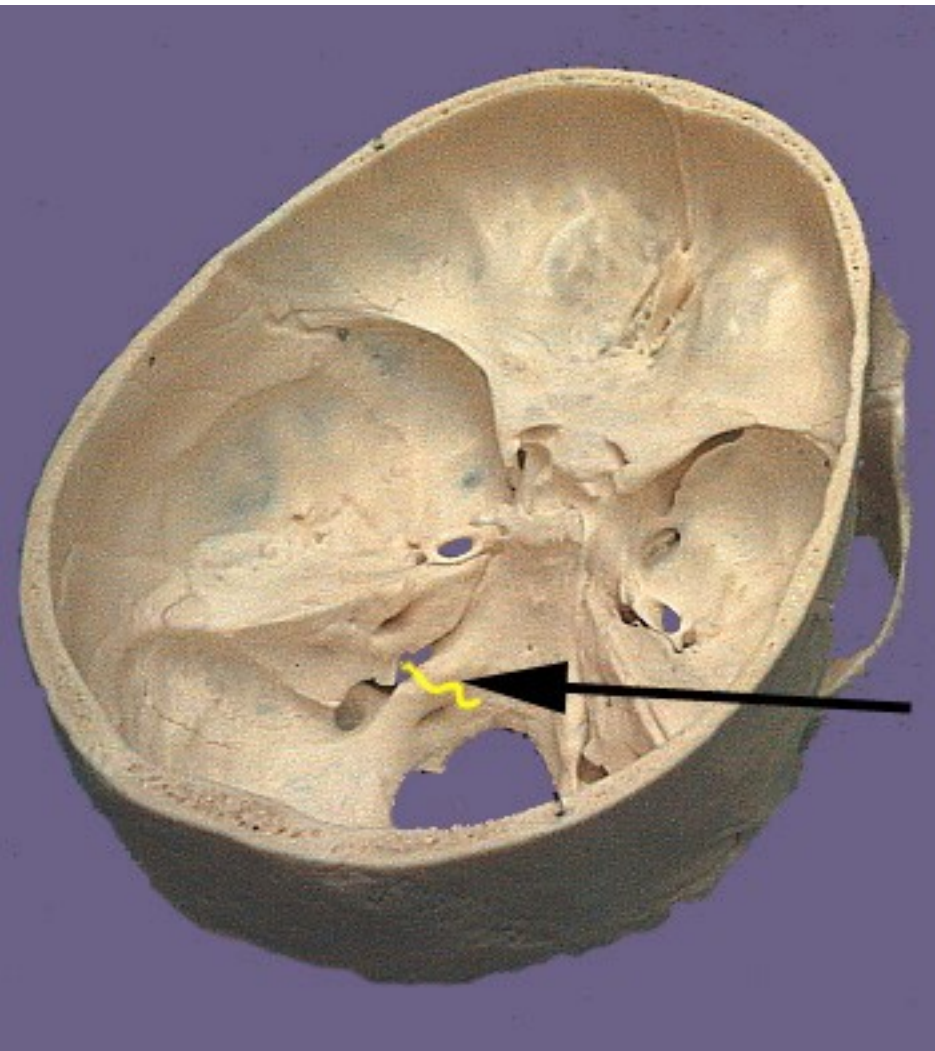
m. stylopharyngeus

Visceromotorická (parasymptická)

gl. parotis

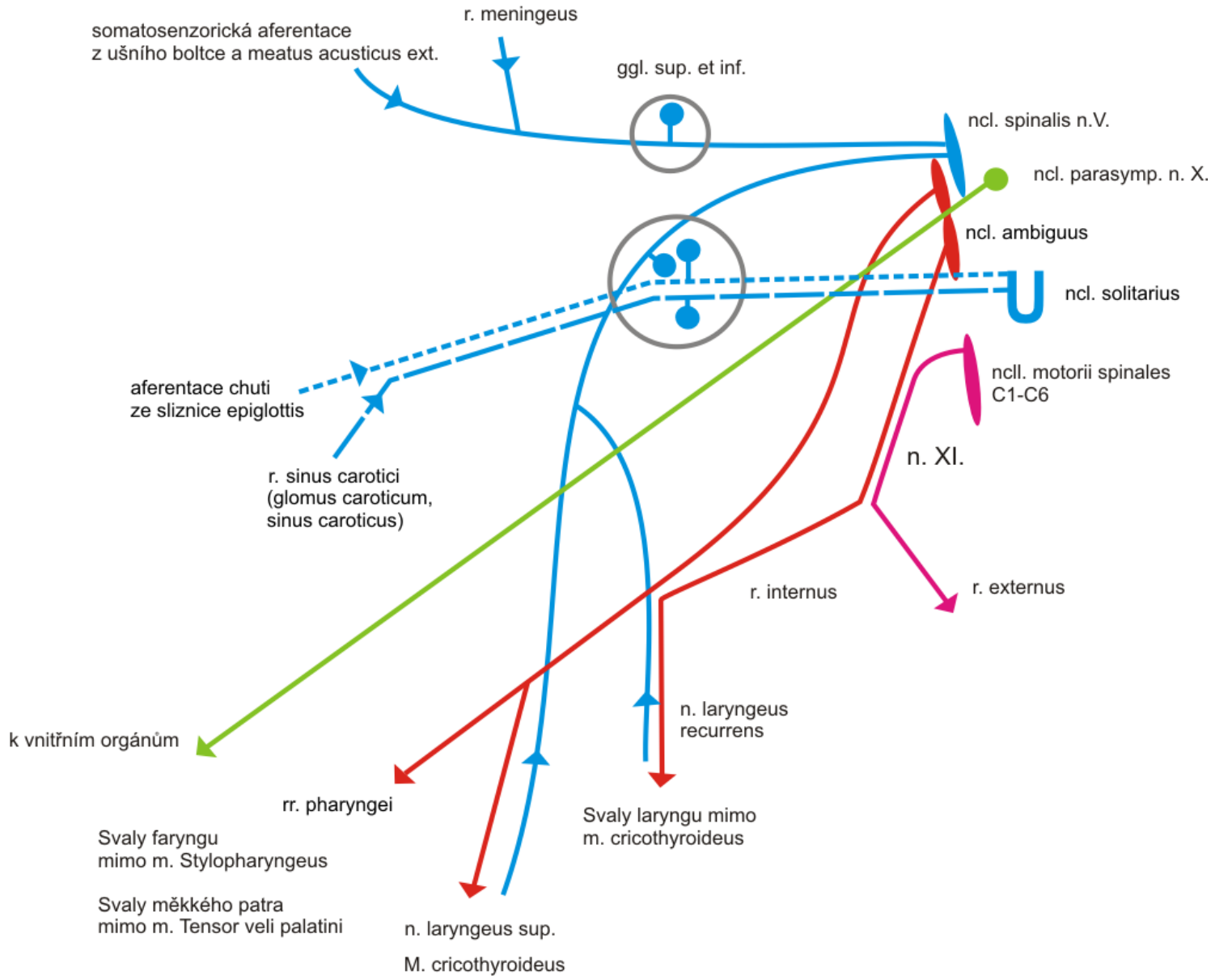


Source: Morton DA, Foreman KB, Albertine KH: *The Big Picture: Gross Anatomy*: www.accessmedicine.com
 Copyright © The McGraw-Hill Companies, Inc. All rights reserved.



n. X.

n. X.



Inervační oblasti n. X:

Somatosensorická

Ušní boltec a meatus acusticus ext.

Meningy, sliznice laryngu

Sensorická (chut')

Chuťové pohárky epiglottis

Viscerosenzorická

Glomus caroticum

Sinus caroticus

Motoricky (Branchiomotor.)

Svaly faryngu mimo m. stylopharyngeus

Svaly měkkého patra mimo m. tensor veli palatini

Svaly laryngu

m. cricothyroideus – n. laryngeus sup., r. externus

Ostatní svaly laryngu – n. laryngeus recurrens (zdroj r. internus n. XI.)

Visceromotorická (parasymptická)

Vnitřní orgány

Větve n. vagus

Malé auto **fará**ře, láme **k**amarádům **rekord**, **k**amarád **brojí esem**, **gangsterskou** cestou k **Heleně rezavé**.

r. **m**eningeus

rr **a**uriculares

rr. **p**haryngei

rr. **l**aryngei sup.

rr. **c**ardiaci cervicales sup.

n. laryngeus **r**ecurrens, n. lar. inf.

rr. **c**ardiaci cervicales inf.

rr. **c**ardiaci thoracici

rr. **b**ronchiales

rr. tracheales,

rr. **o**esophagei, plexus oesophageus,

plexus pulmonalis

truncus vagalis ant., post. -----rr. **g**astrici ant. post.,

rr. **c**oeliaci

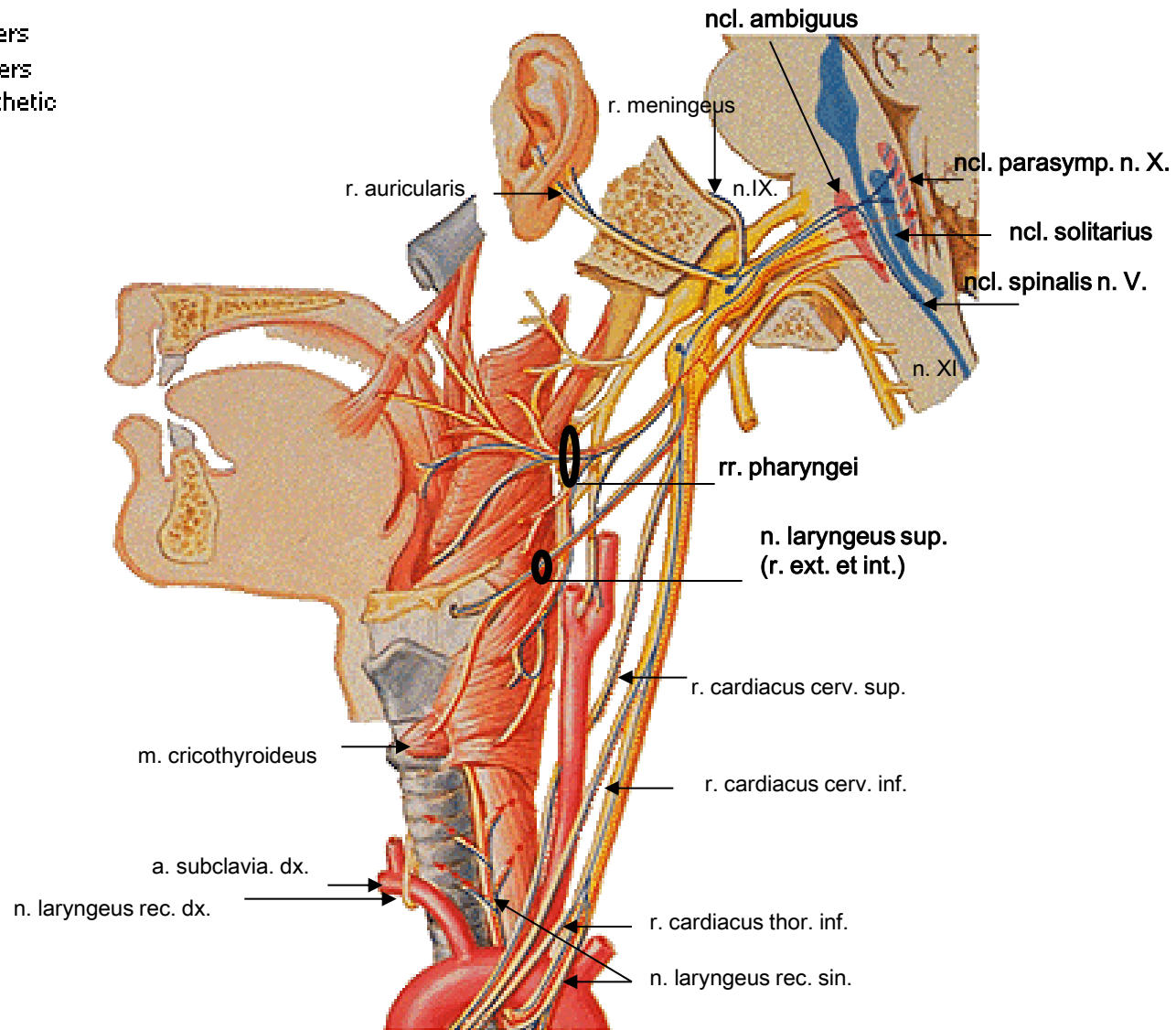
rr. **h**epatici

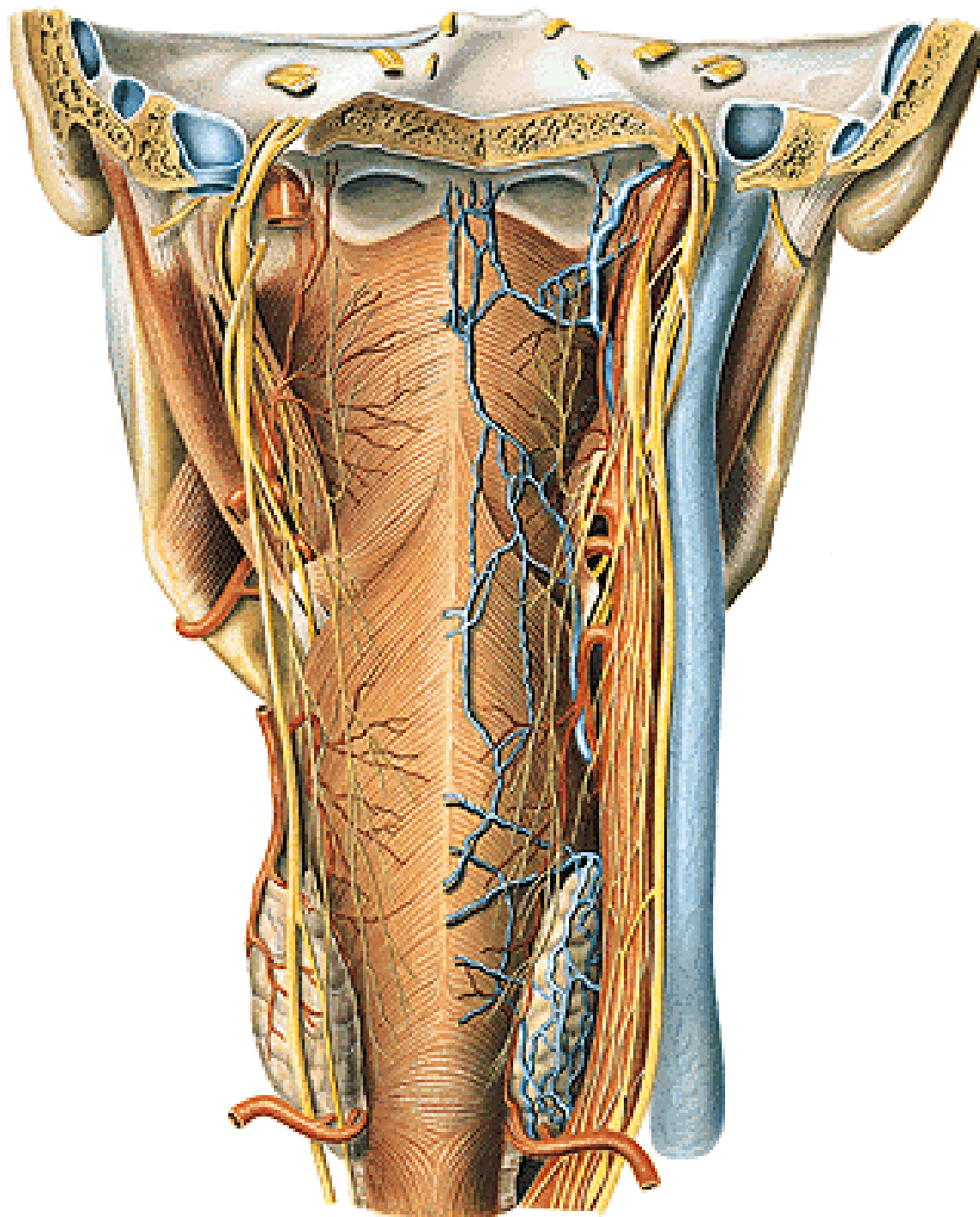
rr. **r**enales

Vagus Nerve

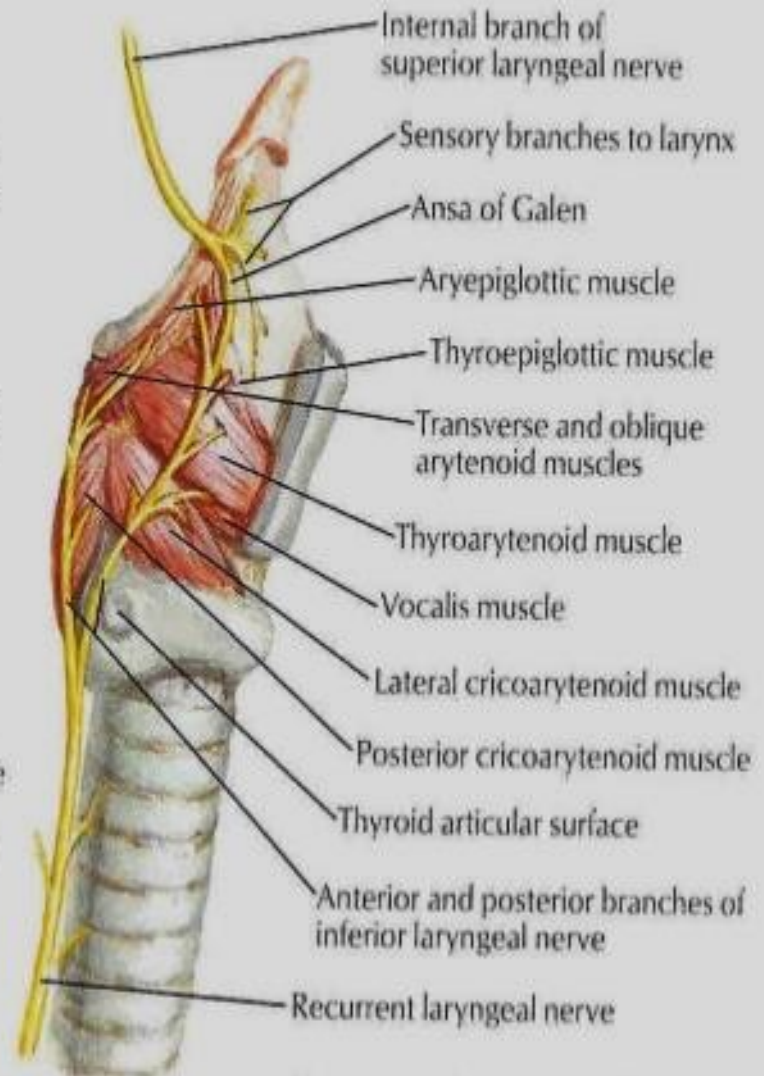
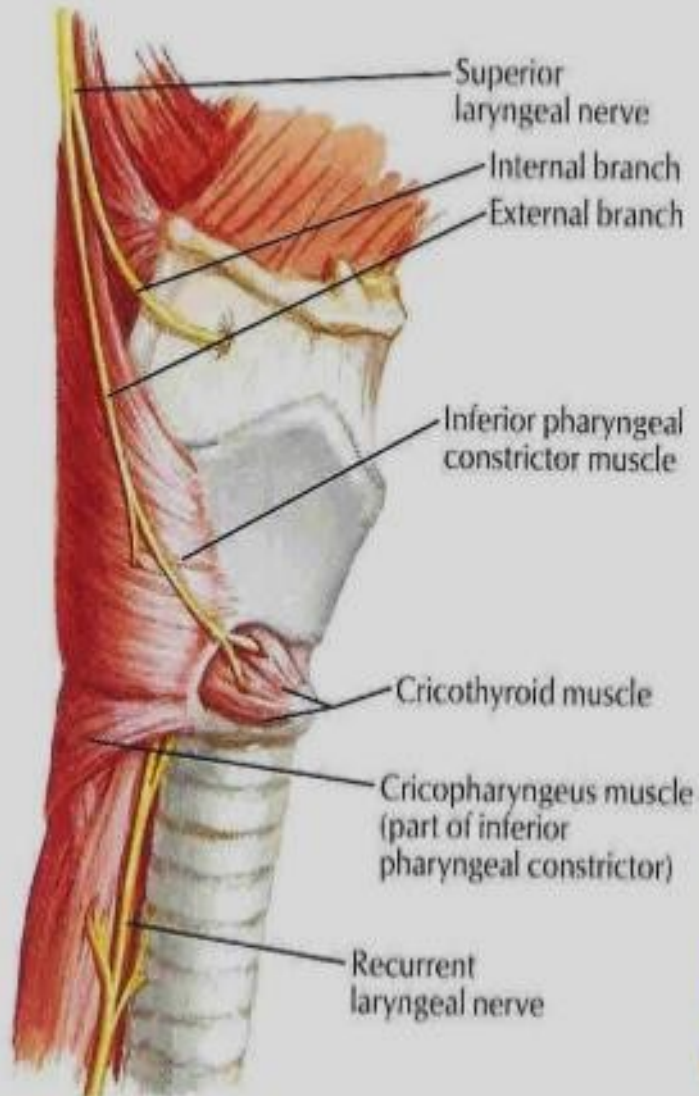
Schema - Enlargement of Proximal Portions

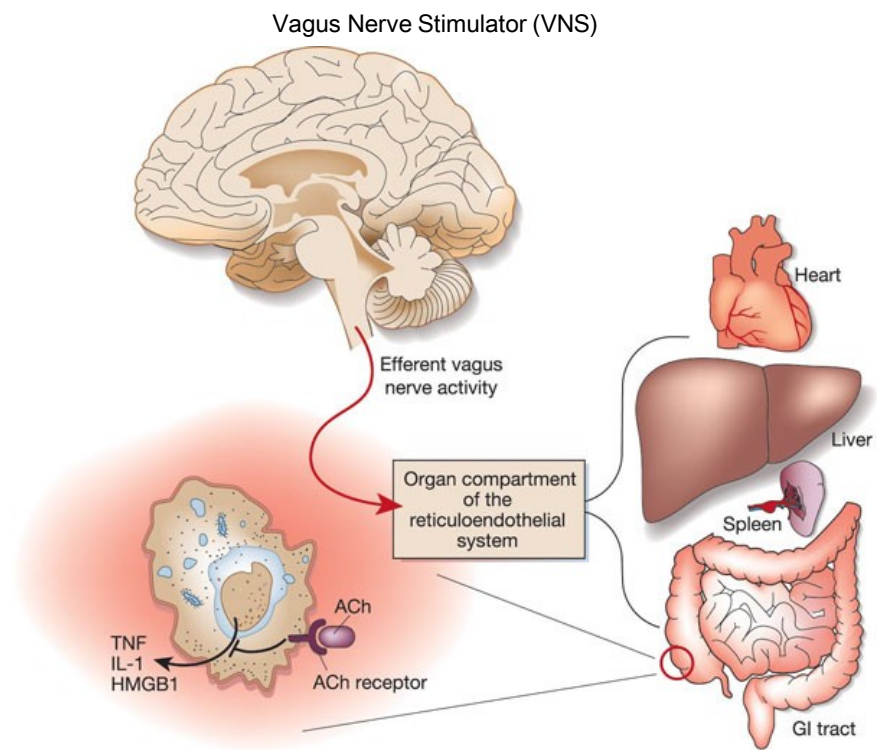
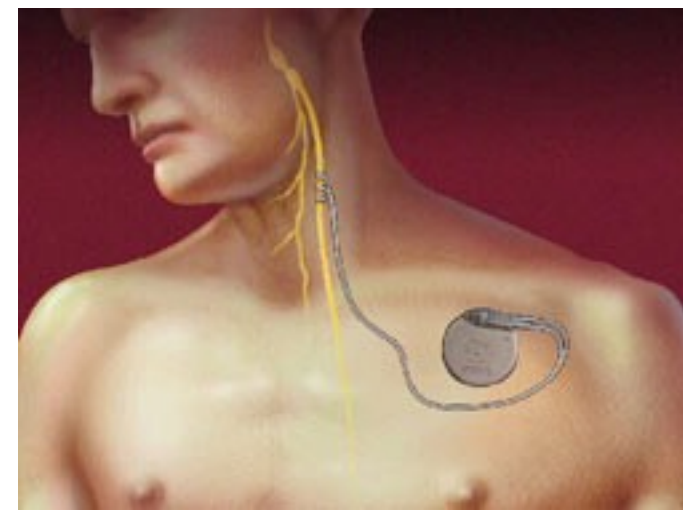
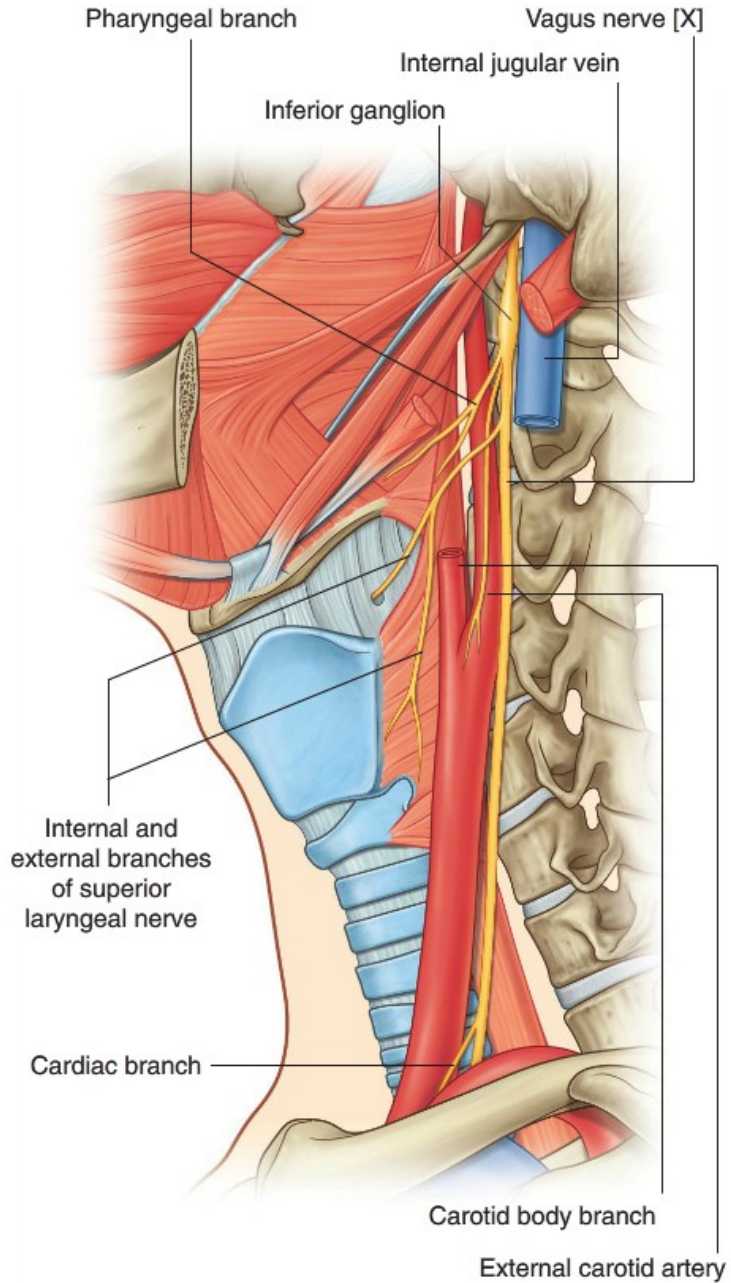
- Efferent fibers
- Afferent fibers
- ⋯ Parasympathetic fibers

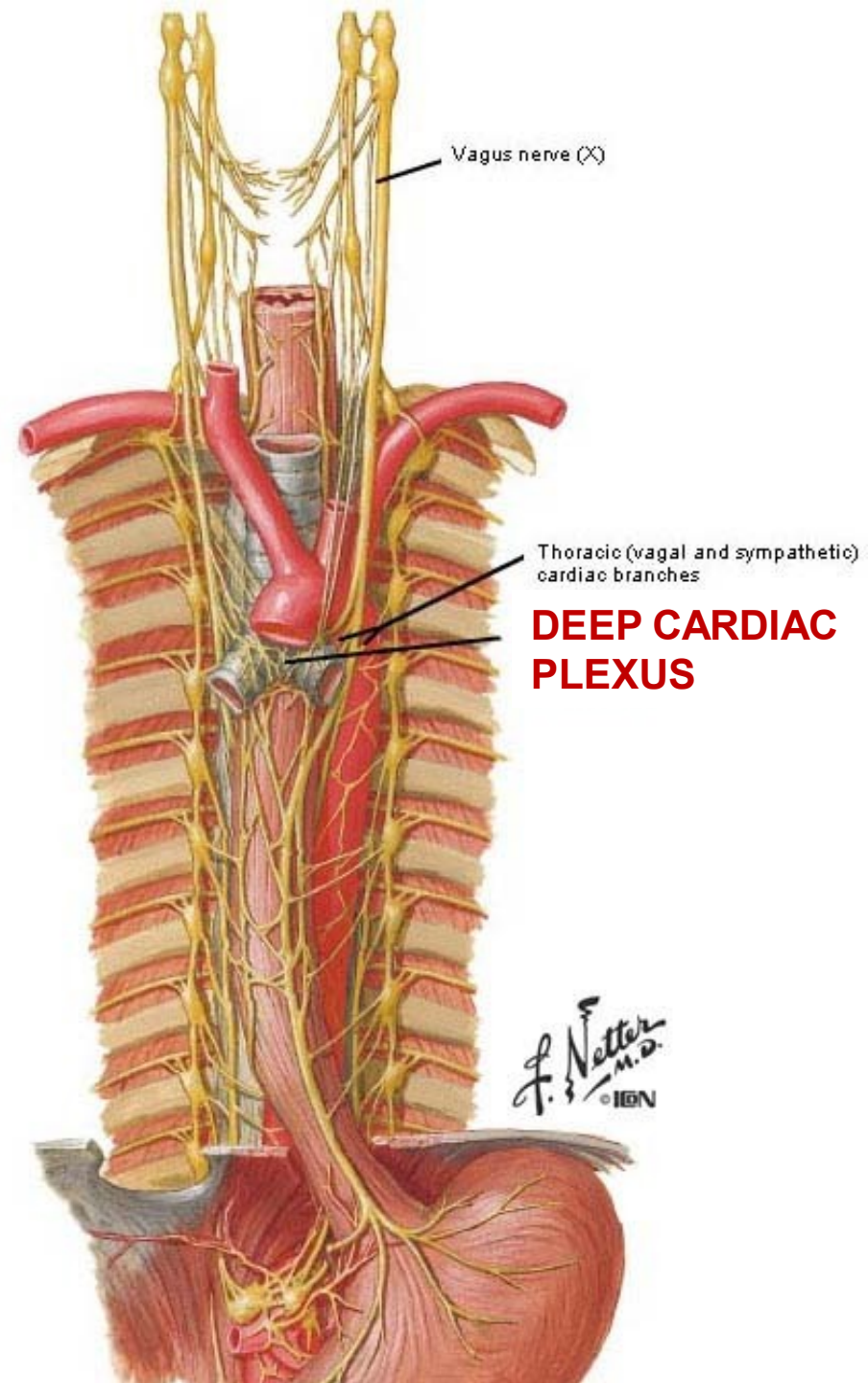
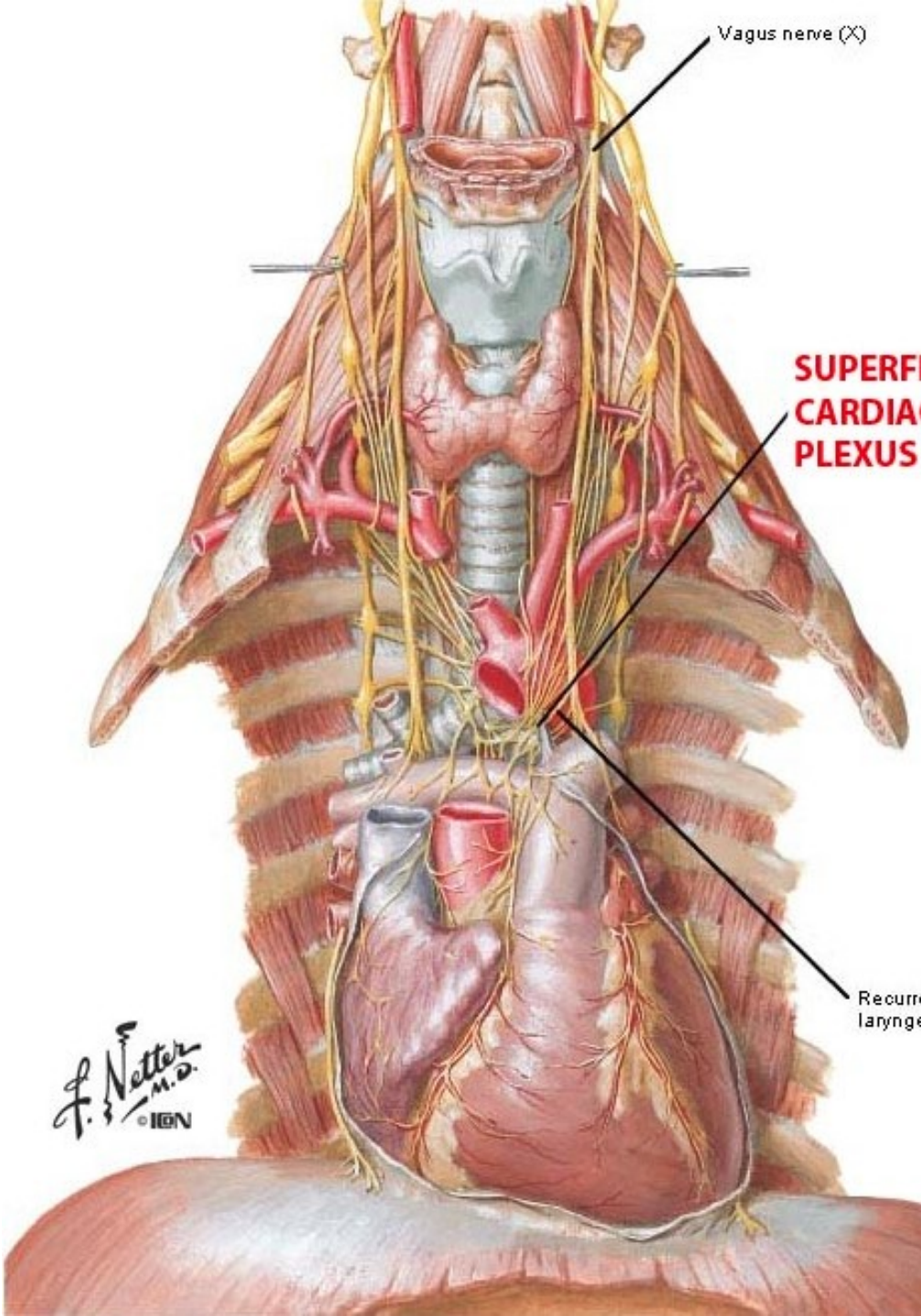


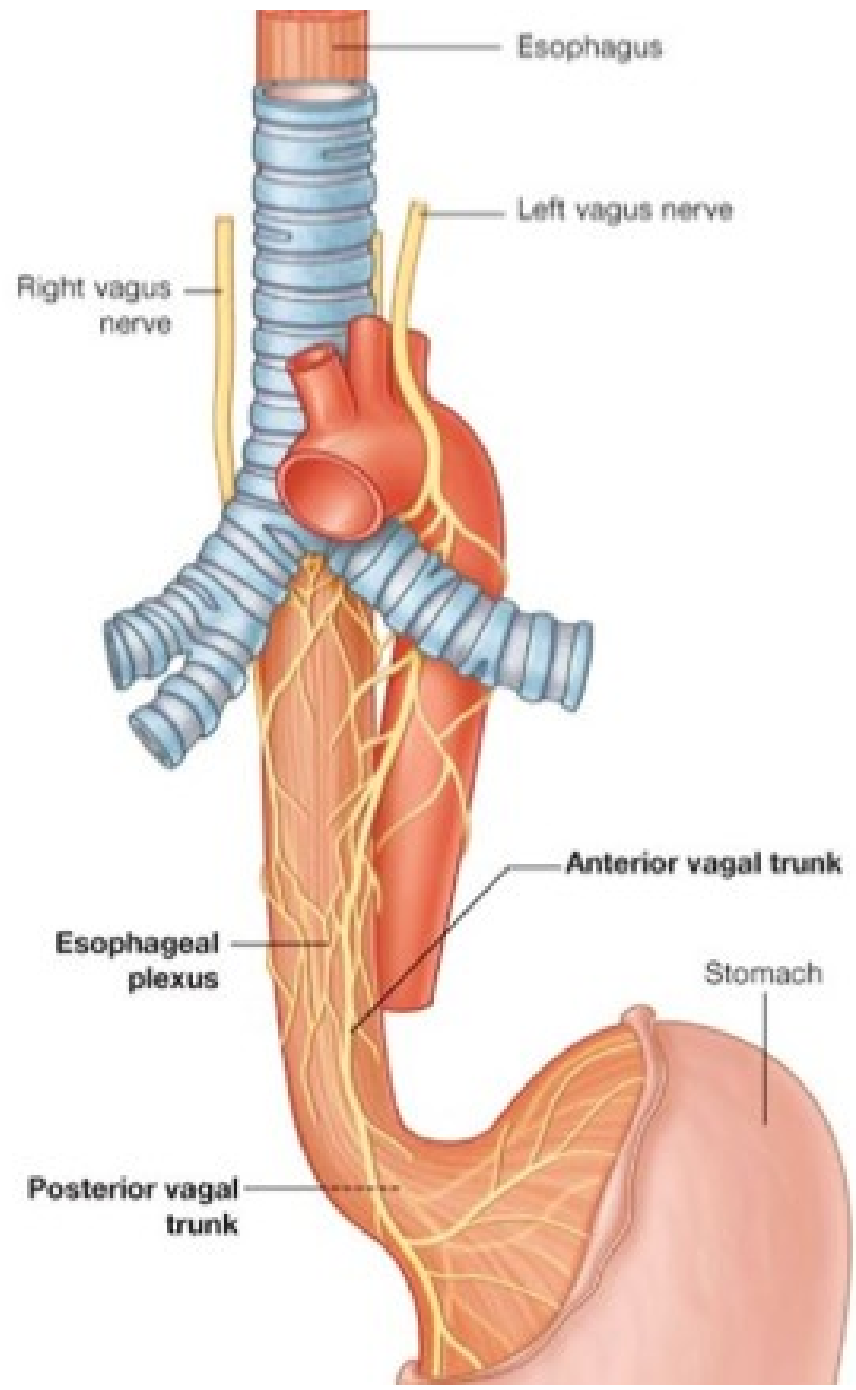


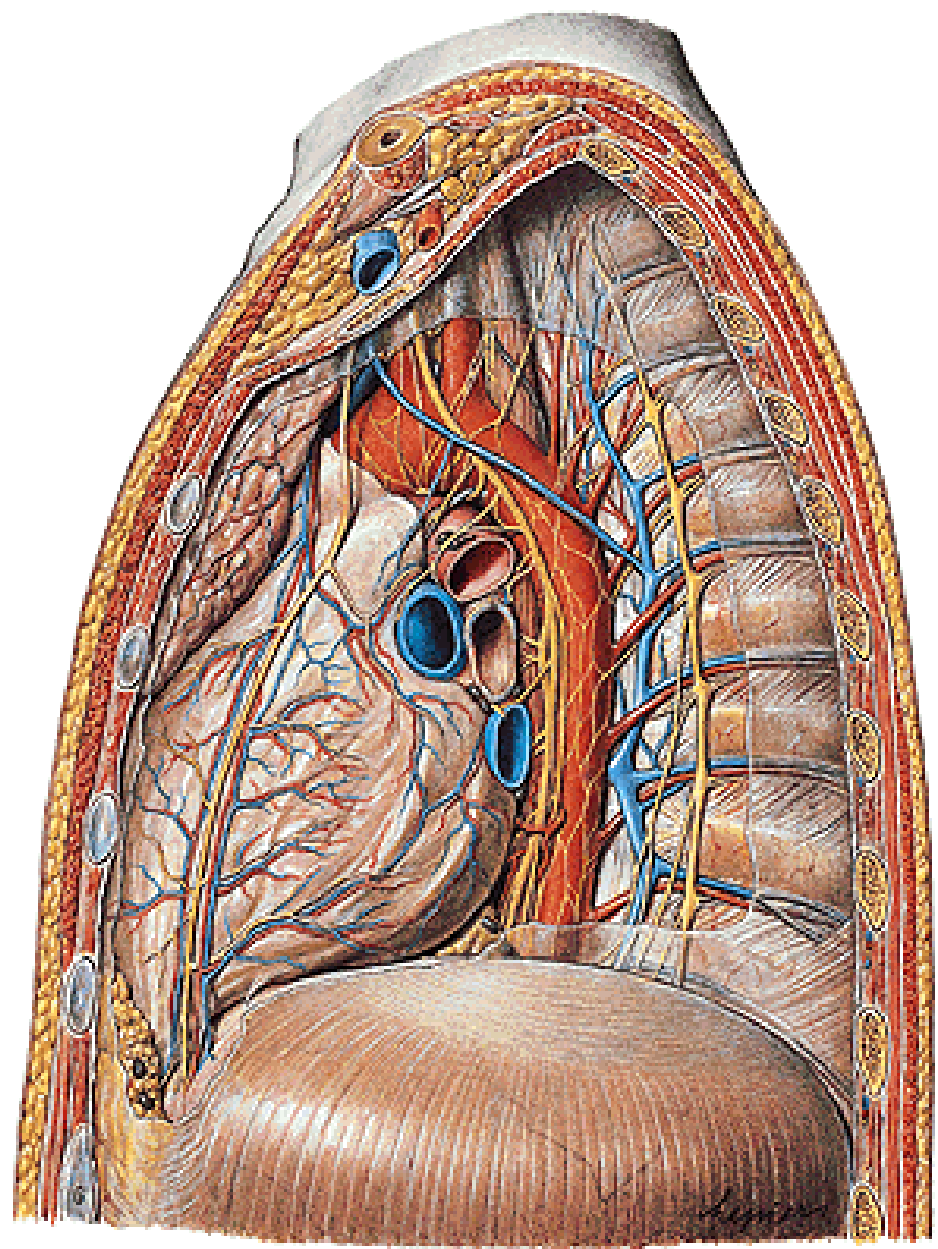
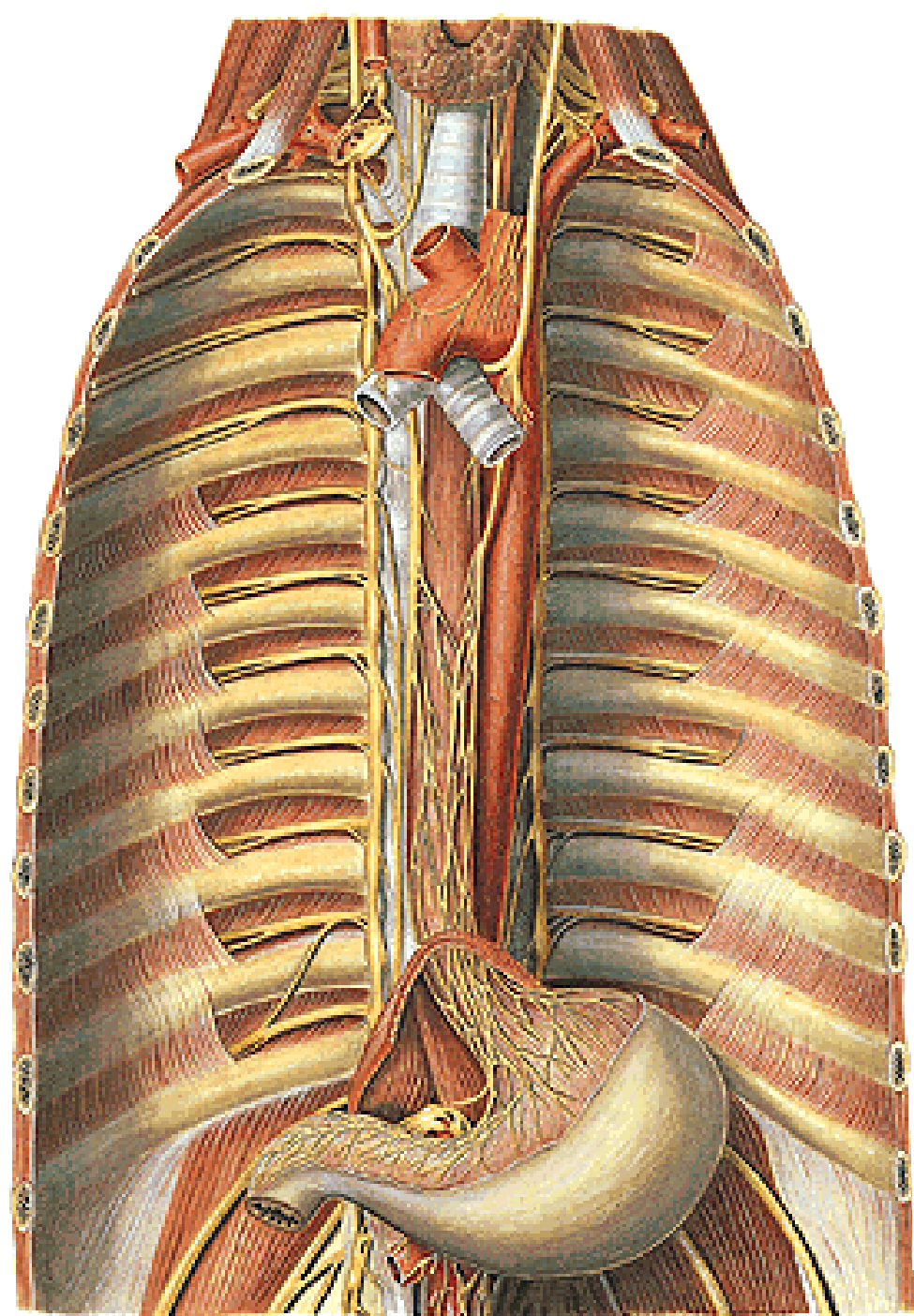
NERVE SUPPLY OF LARYNX

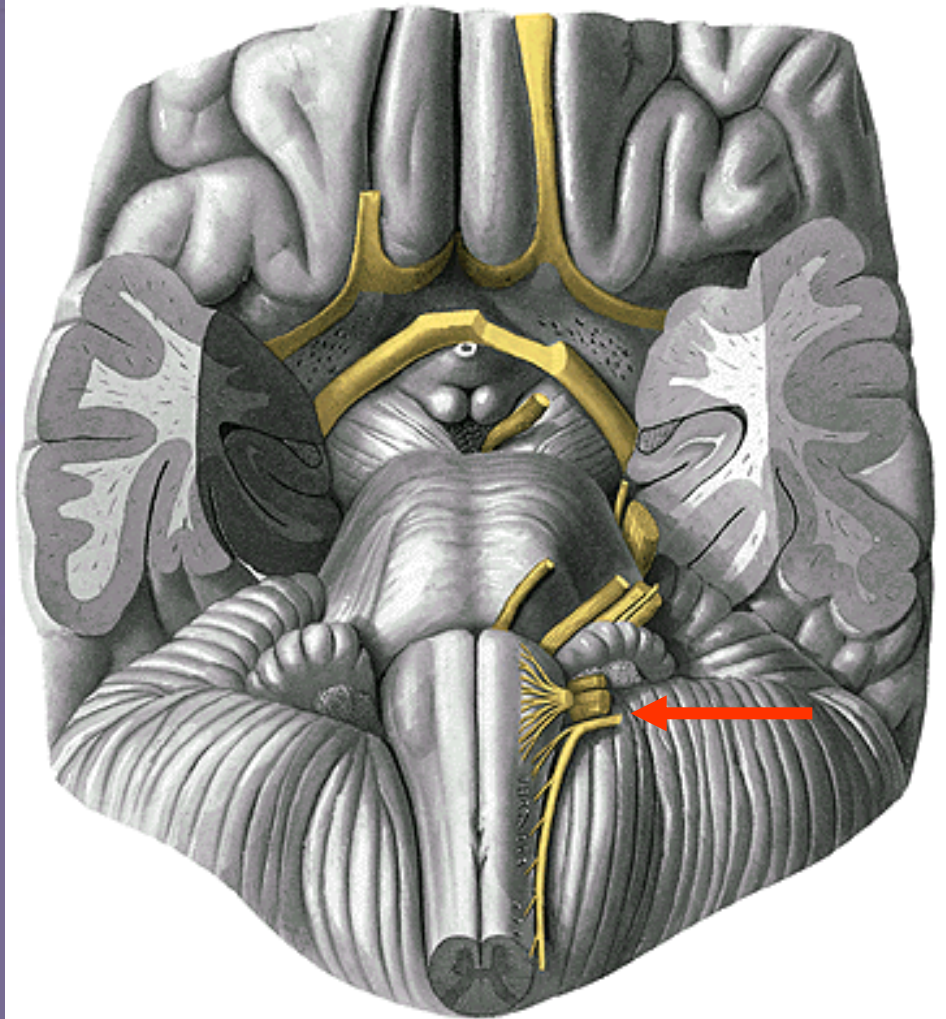
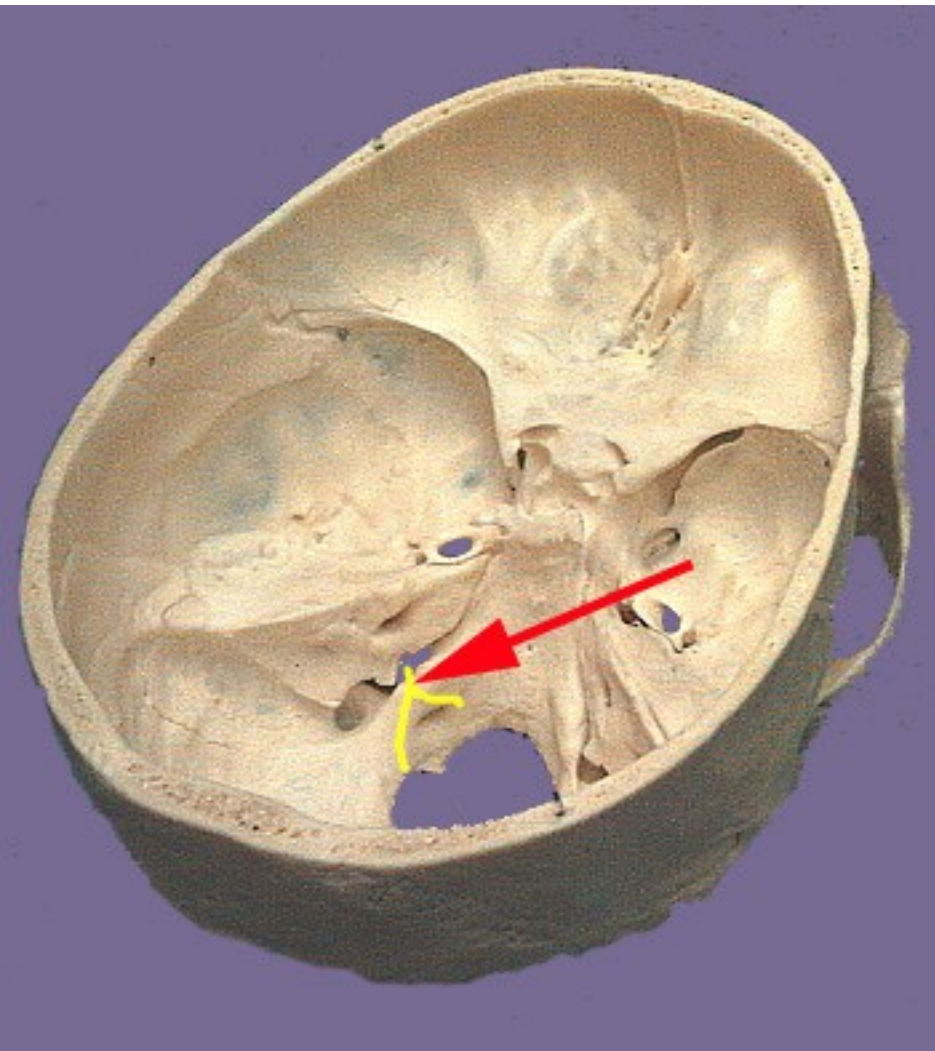






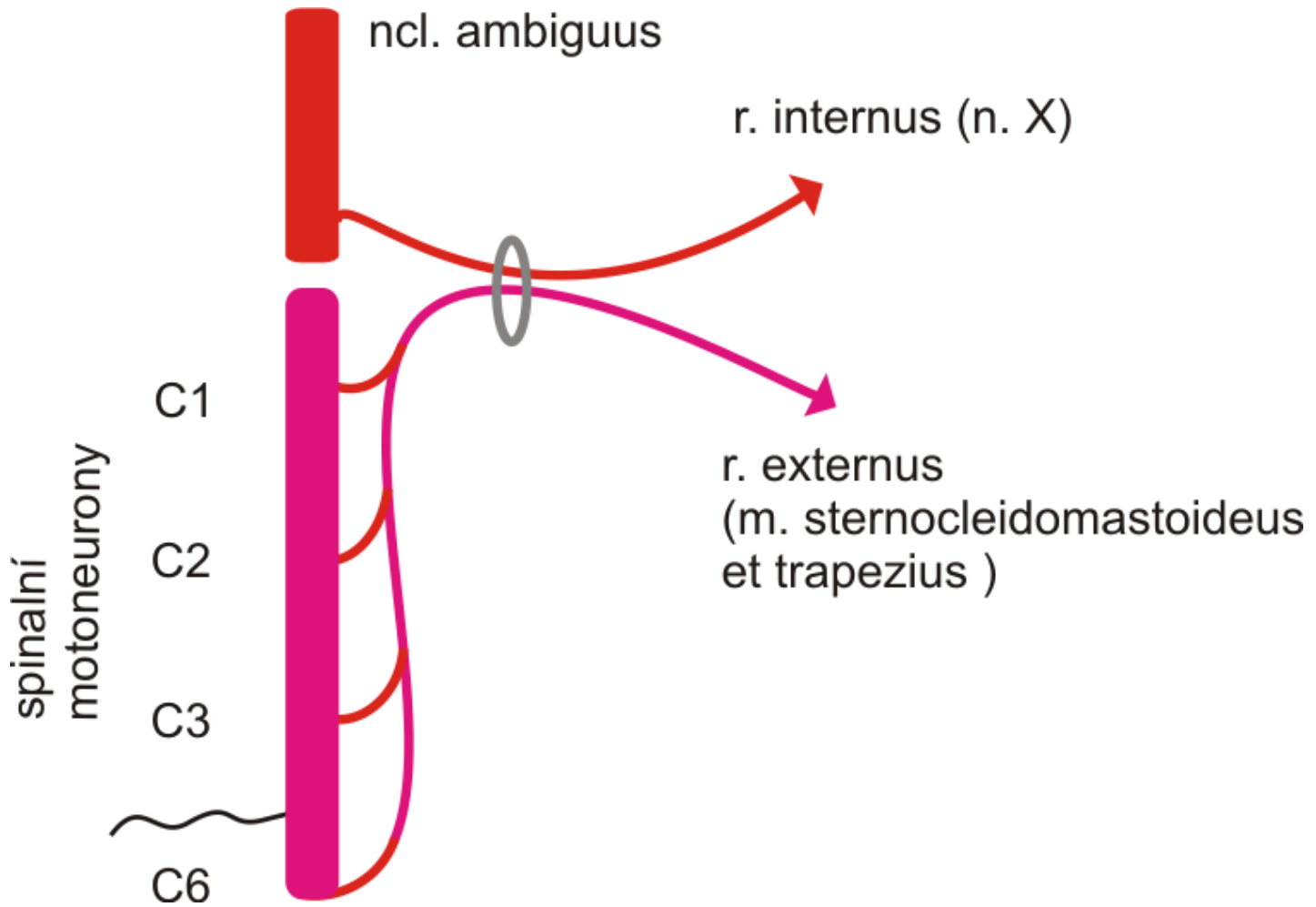


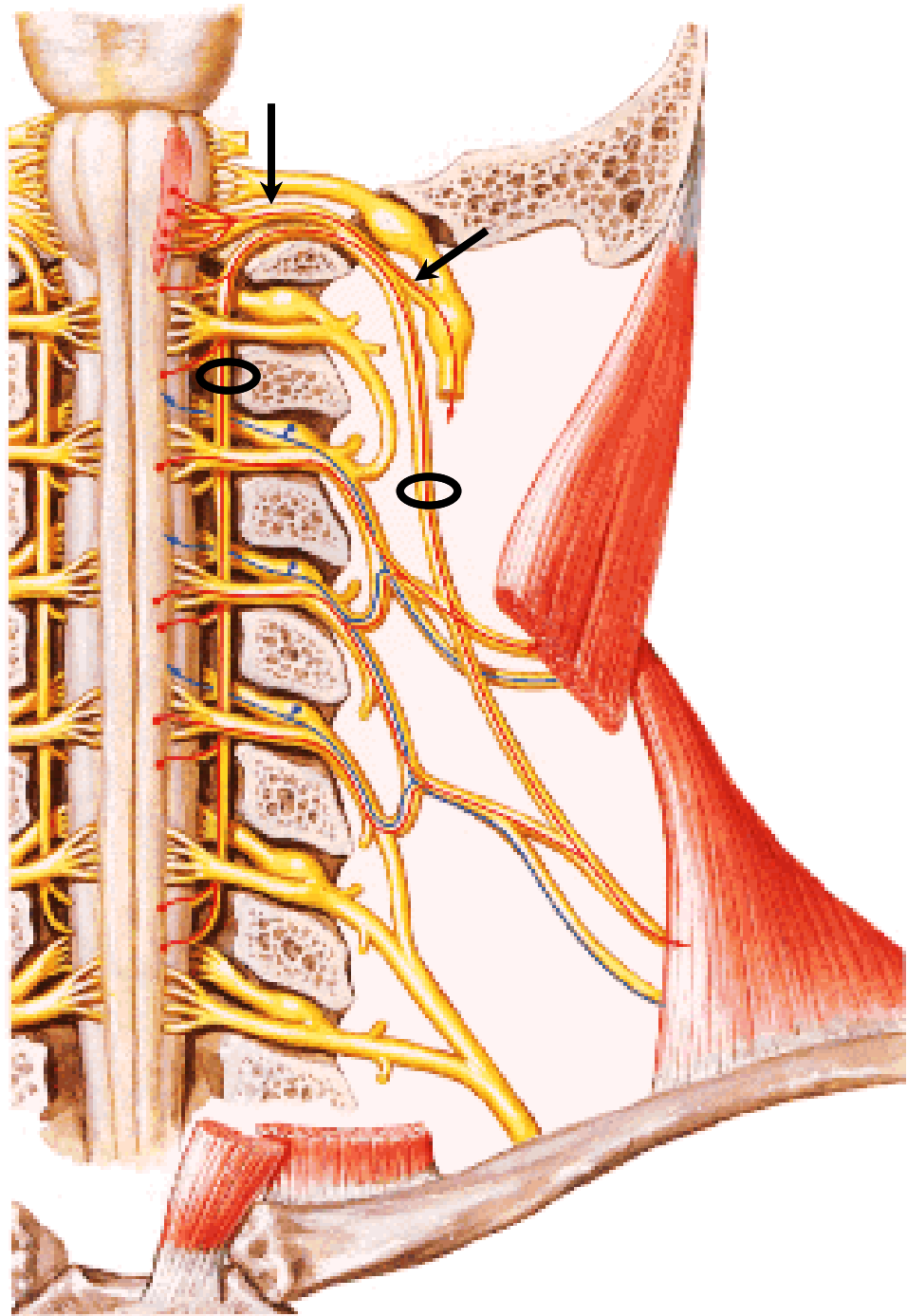


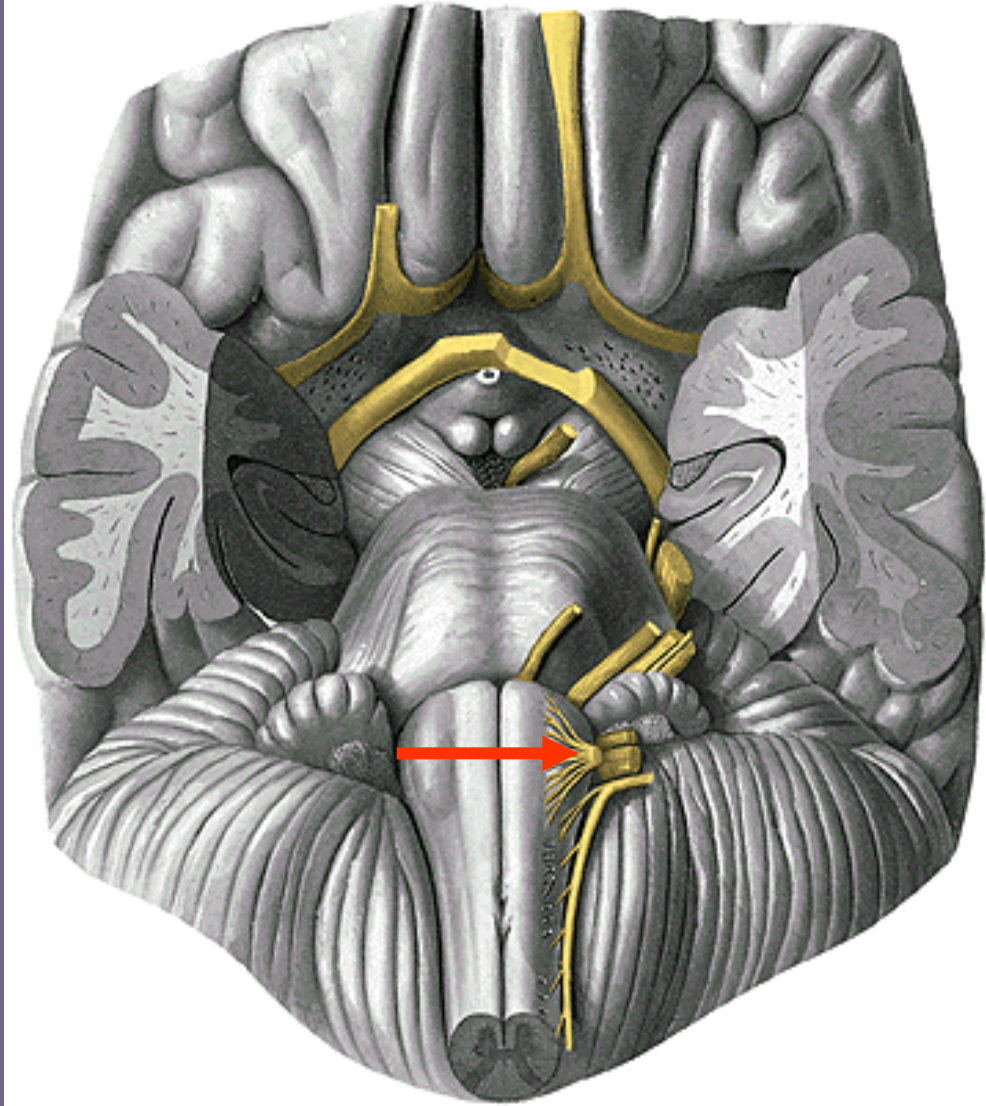
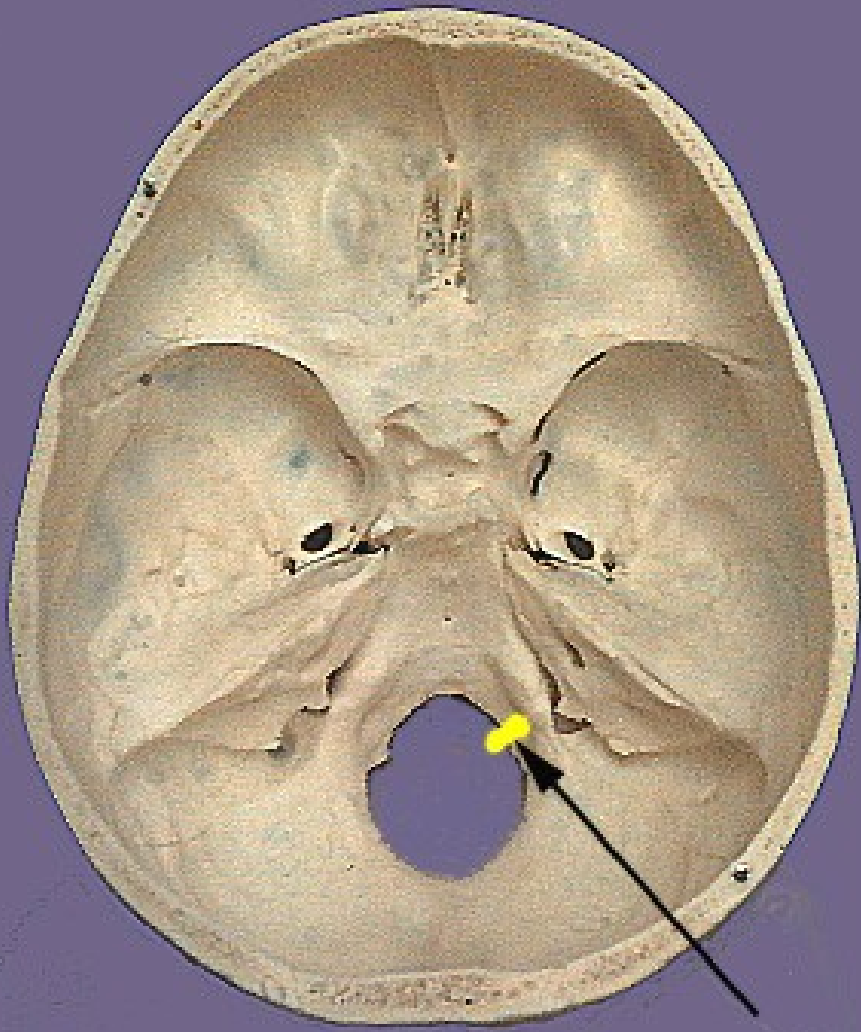


n. XI.

n. XI.

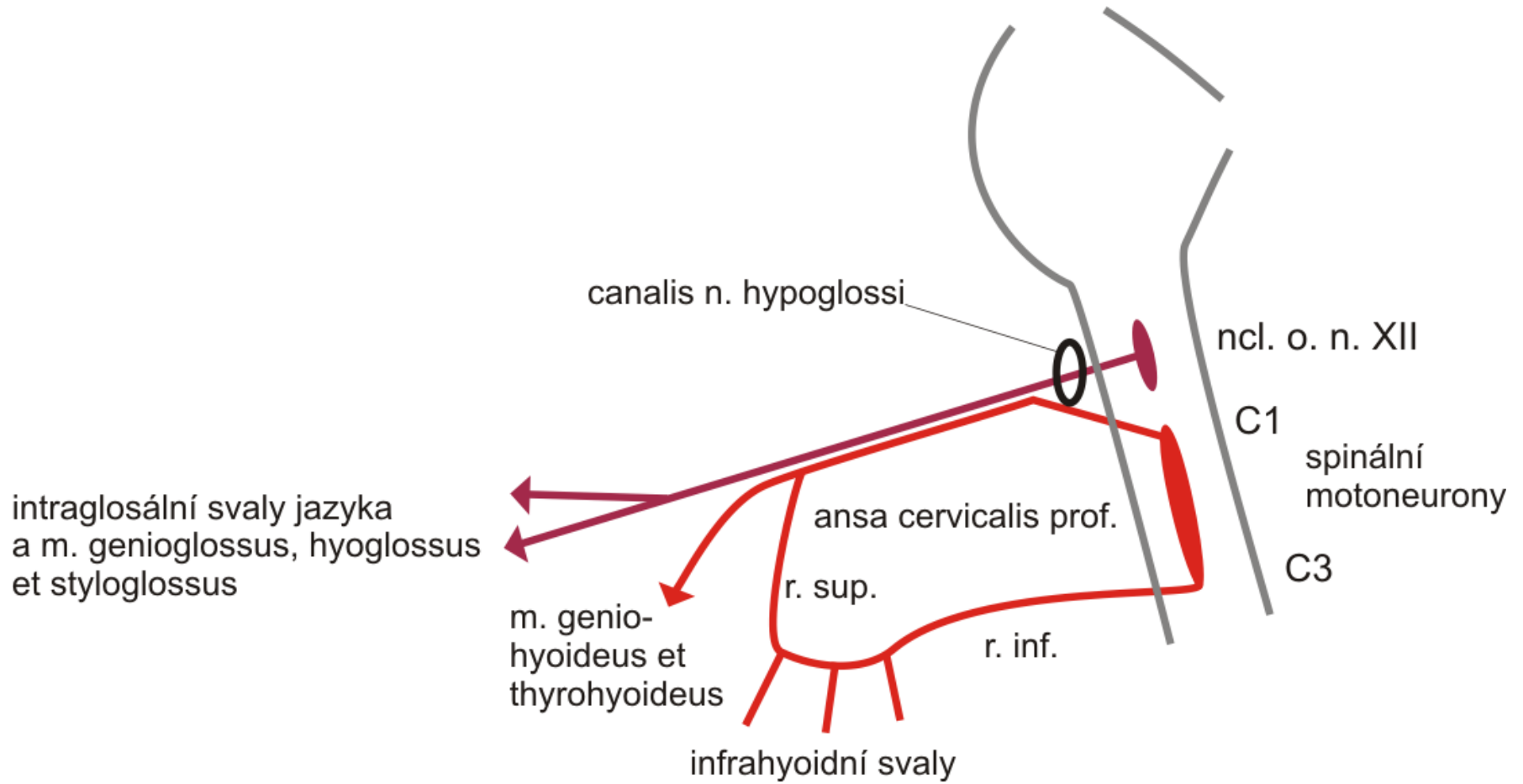


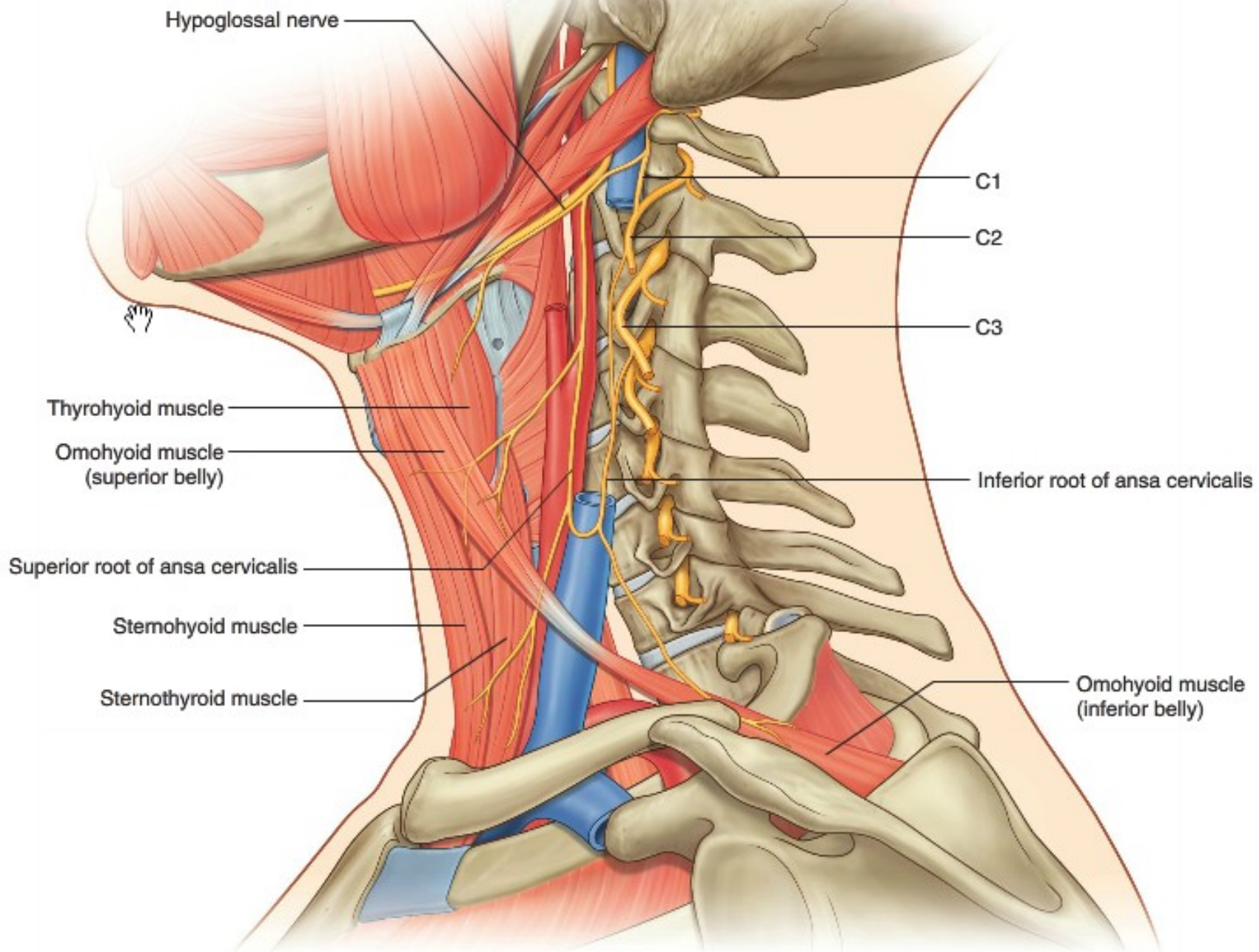




n. XII.

n. XII.





Leze n. hypoglossus – jazyk na stranu nepoškodeného nervu

