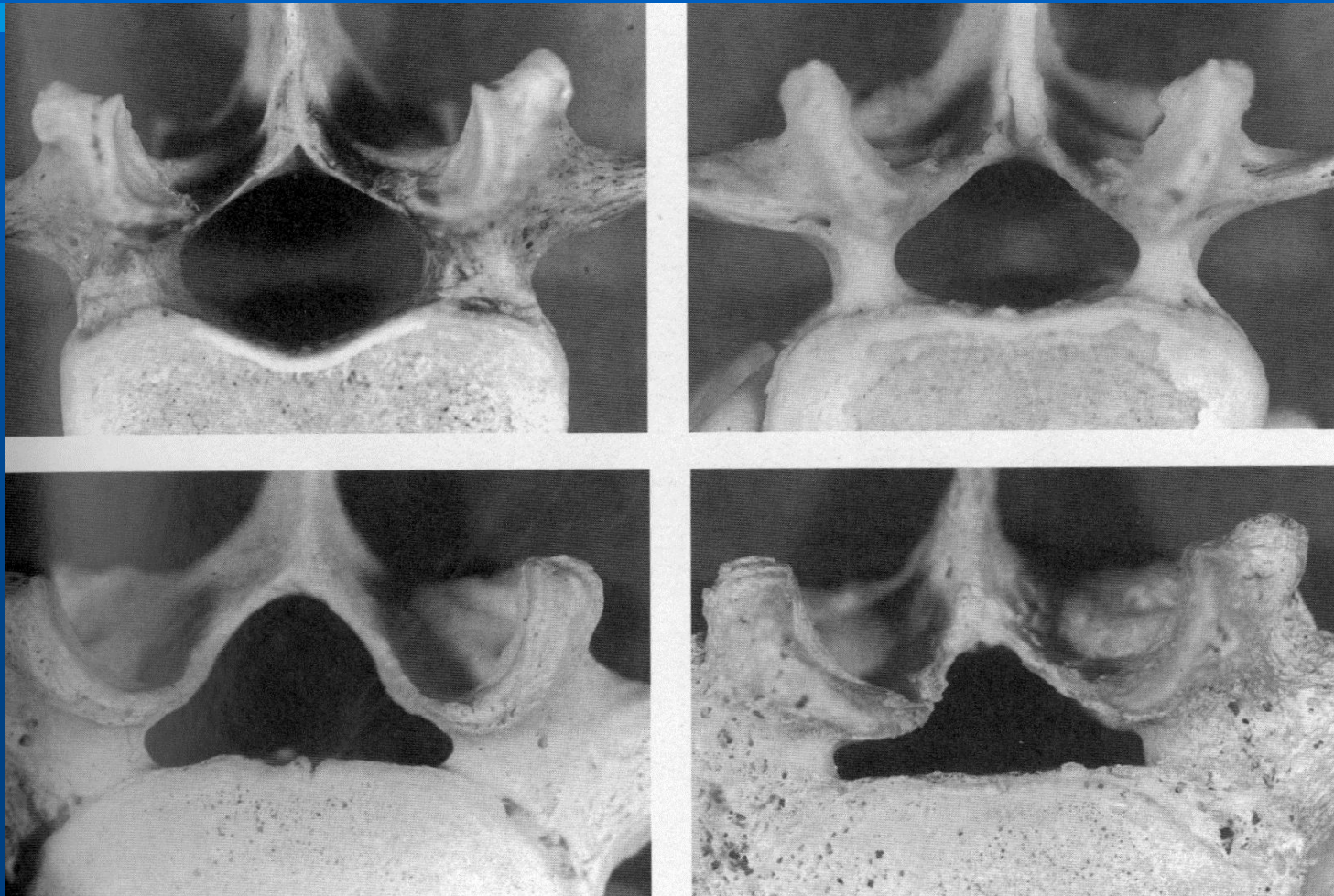


SURGERIES IN BACK PAIN MANAGEMENT

Chaloupka R., Repko M.

Variability of spinal canal shape



Management of back pain

1. diagnosis - 1% organic origin
2. conservative
3. surgery only in known and clear diagnosis

Spine deformities

- **Degenerative scoliosis – connected with spinal stenosis**
- **Pain unsuccessfully treated conservatively, with neural deficit**

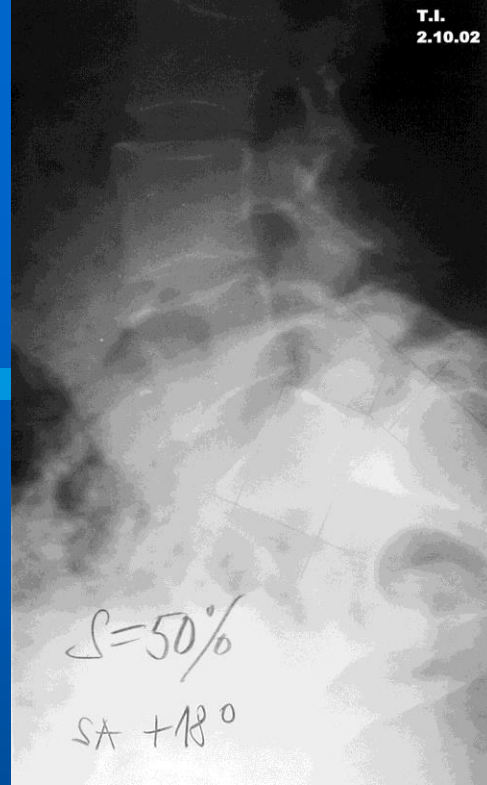Spondylolysis

- isthmus reparation
- posterolateral fusion with instrumentation

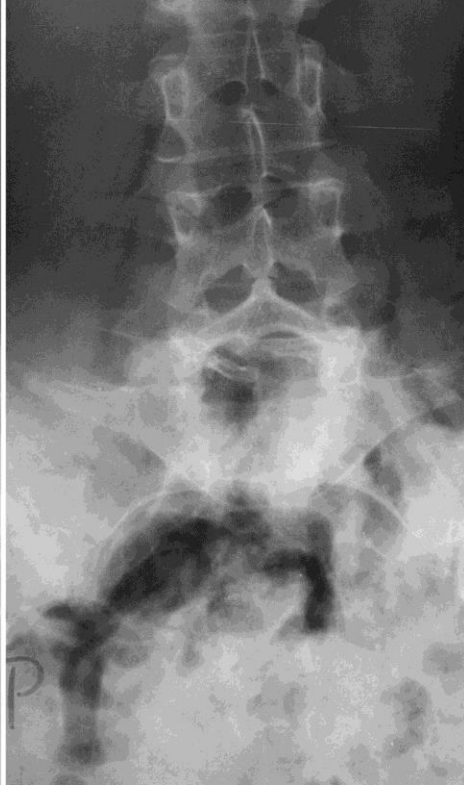Spondylolisthesis

1. Decompression
2. Posterolateral fusion w/wo instrument.
3. PLF, decompression, instrumentation
4. partial – complete reduction, post. instrum.
+ 360° fusion: PLIF - TLIF, ALIF

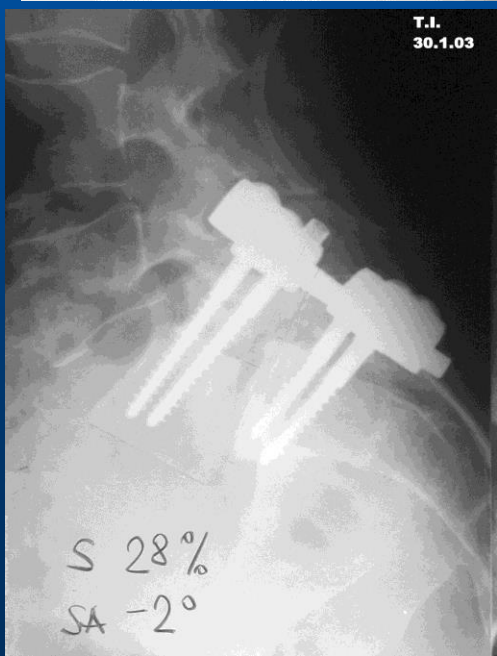
T.I.
2.10.02



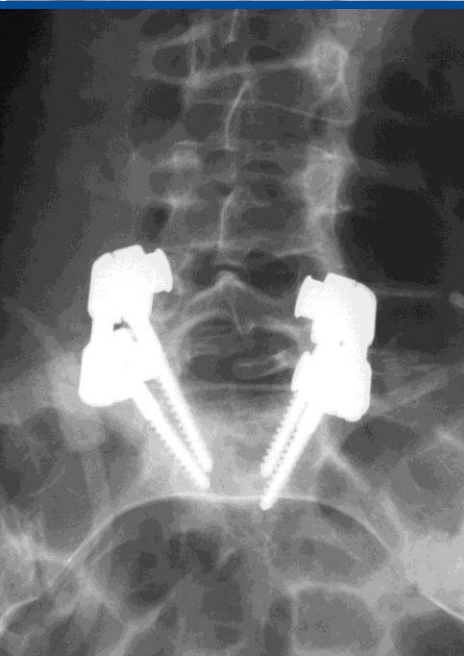
S=50%
SA +18°



T.I.
30.1.03



S 28%
SA -2°



IVANA 398/03

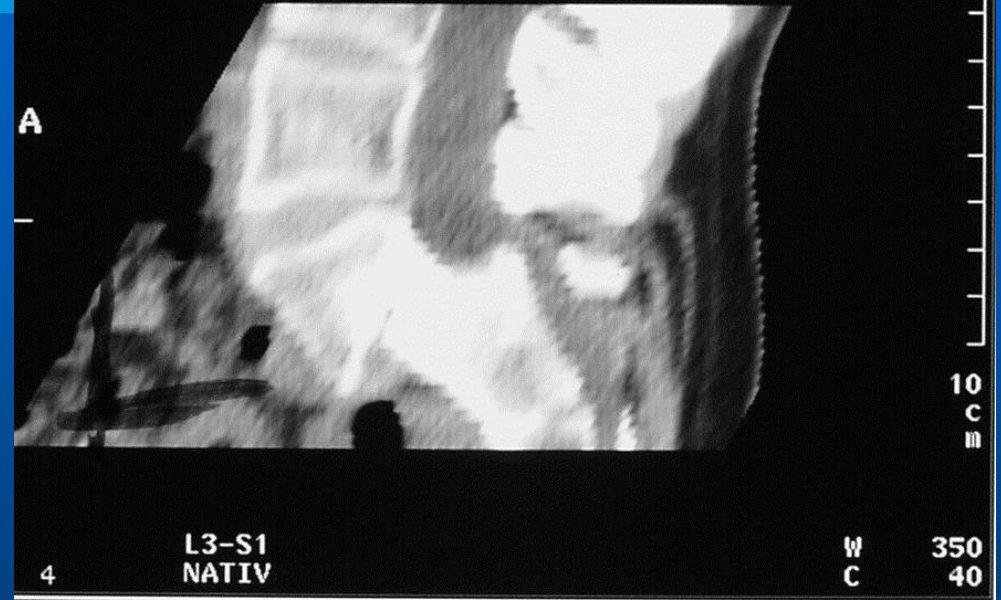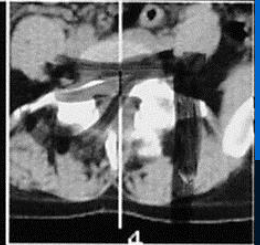
675218/1018

H

21-JAN-2003

IMA 44

Ref Scan 3
Ref TP -882.5

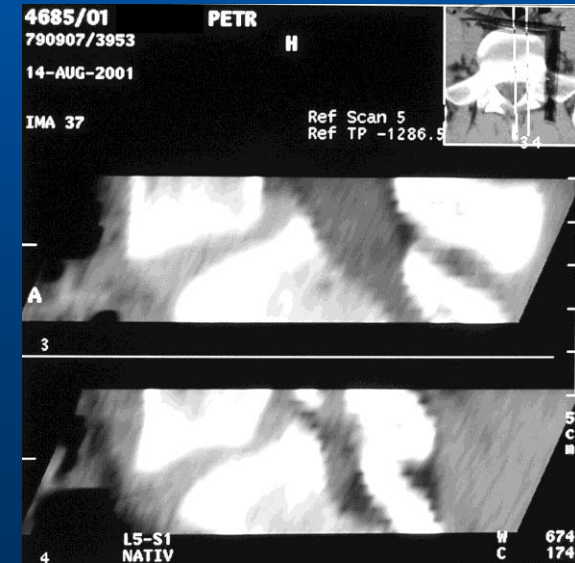
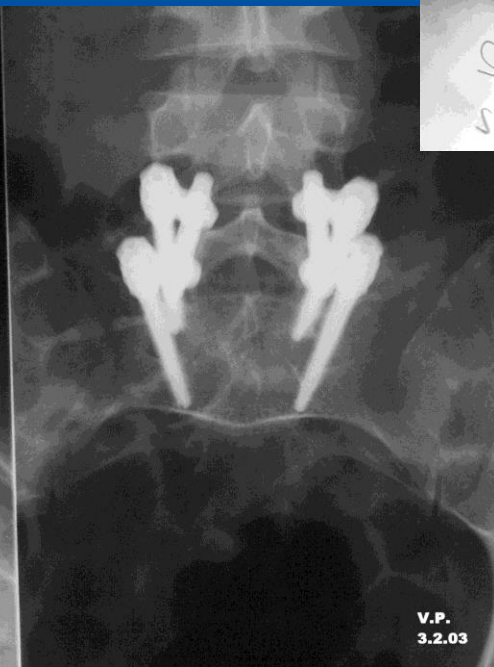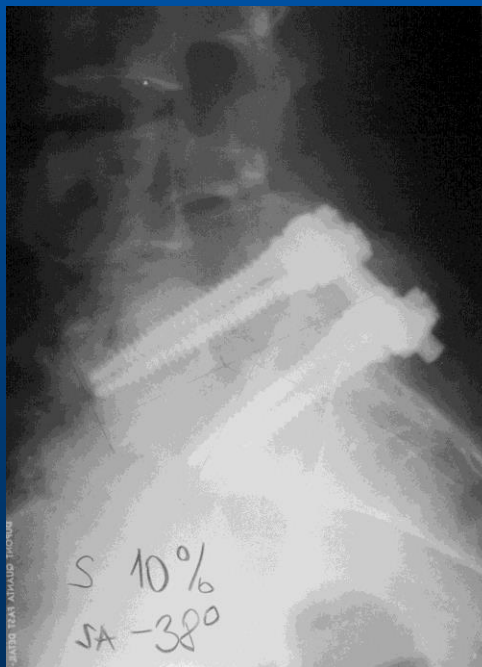
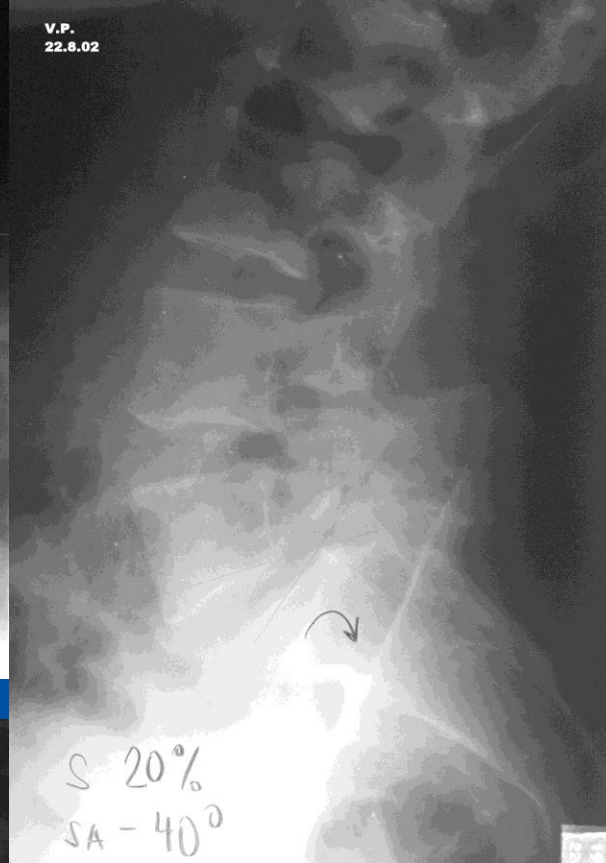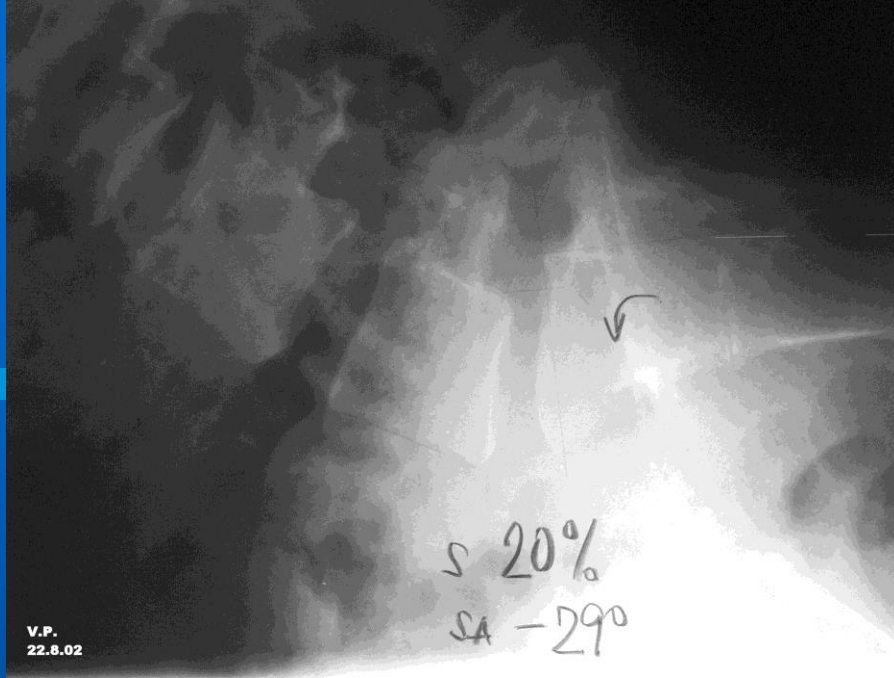


4

L3-S1
NATIV

W 350
C 40





Spine tumours

- imminent/present vert body colaps
- imminent/present neural deficit
- neural deficit progression

Life expectancy more than 3 months
(6 weeks?)

Indication of surgery type

- tumour localisation
- tumour extent
- age
- condition of patient

Posterior surgery

- posterolateral decompression
- decompression+instrumentation
- decomp., instrum., fusion

Anterior surgery - decompression, vertebral body replacement

- bone cement with K-wires
- pelvic autograft
- allograft
- cages - Harms
 - expansive – Synex,

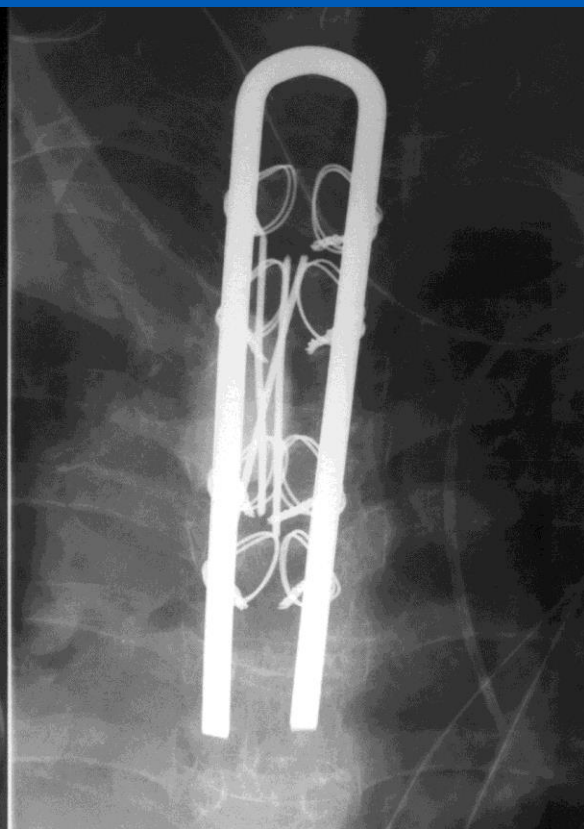
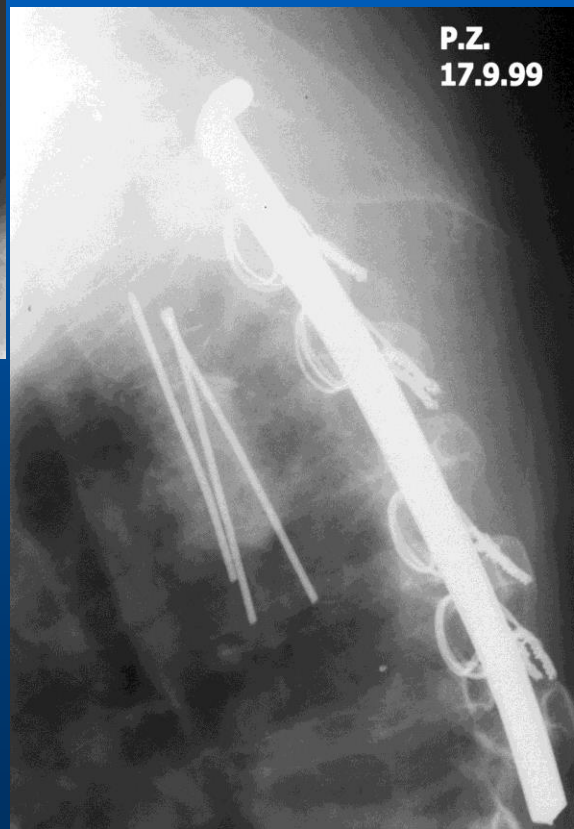
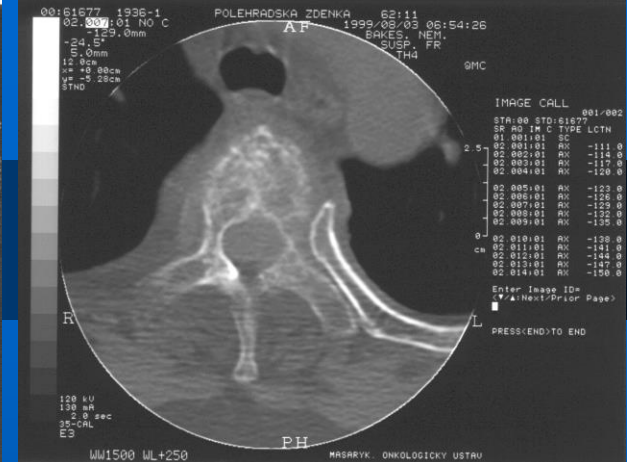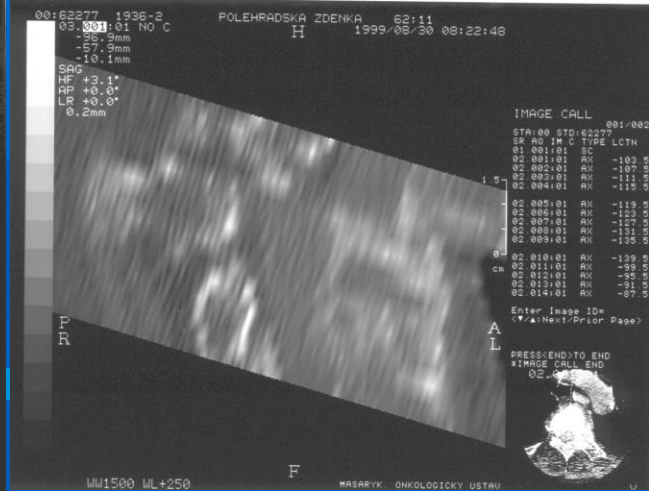
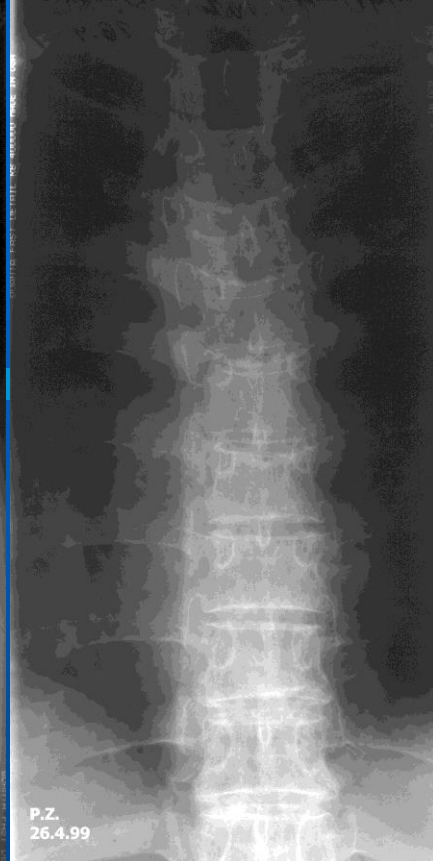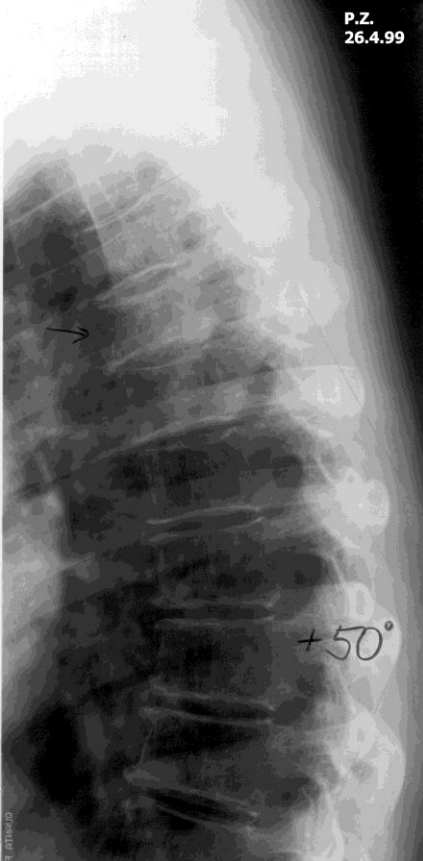X-tens

Combined surgeries

- 2 simultaneous surgeries
- one day with turning the patient
- 2 stages – one week interval
(bleeding during surgery)

Goals of surgical treatment

- improvement/prevention of neural deficit
- restoring spine stability
- pain relief
- improving quality of life

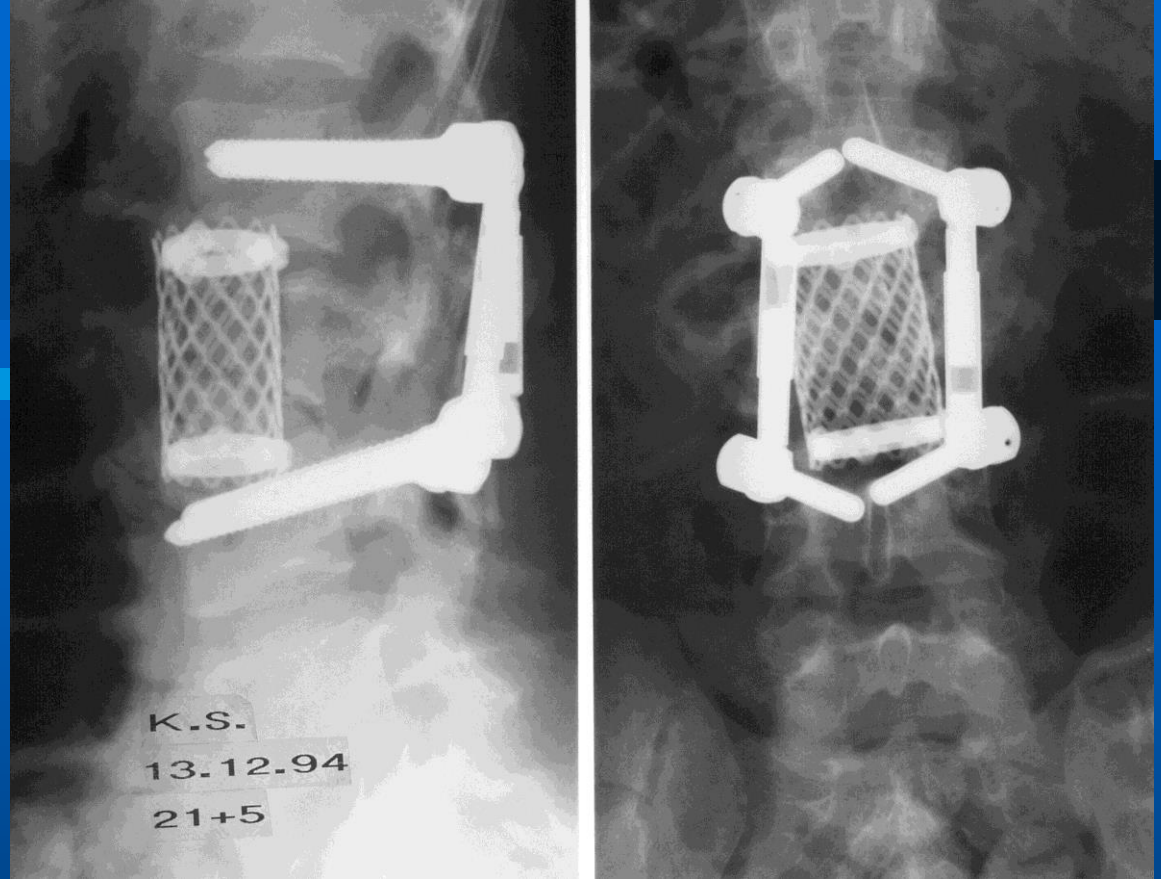
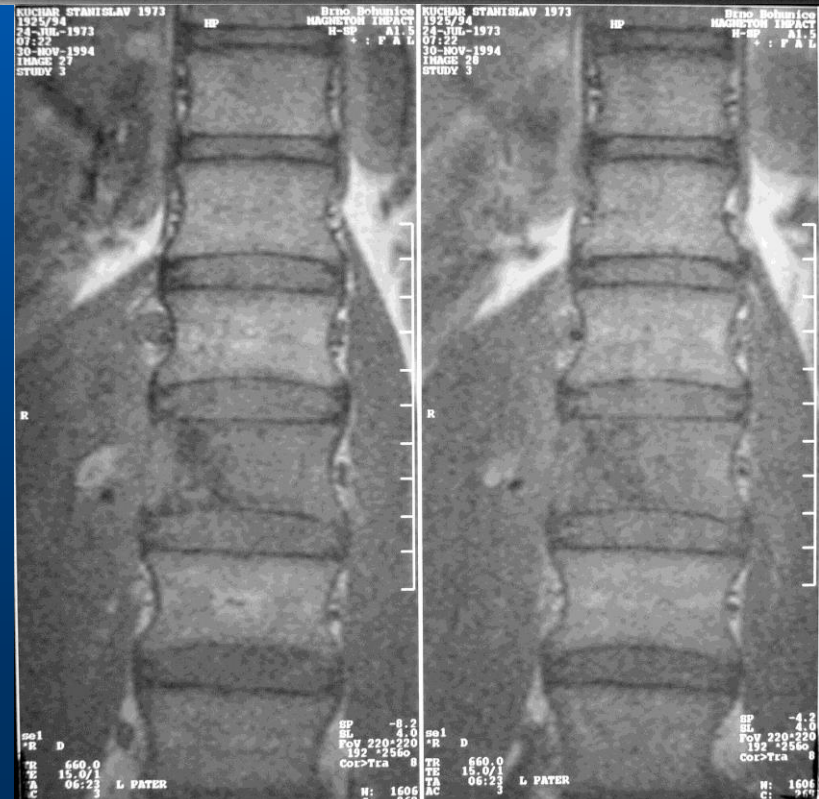

SOMATOM DR RADIOL. KLINIKA FN OLOMOUC
 KUCHAR STAN. 1973 FN 31A KU HC2
 09-NOV-94 FRONT 1 25
 14:20:29 H/SP
 DU5:032
 SCAN 25

LEFT

5 CM

TI 7
 KV 125 M 350
 AS .41 C 40
 SL 4
 GT 0
 TP 111
 NATIV L3



Osteomyelitis of spine

- unsuccessful antibiotic treatment
(2 weeks)
- fistula, abscessus formation
- neural deficit and its worsening

Anterior surgeries

- removal of involved tissues
- autograft replacement
- instrumentation (anterior - posterior)

Degenerative disc disease (osteochondrosis)

- dysfunction
- instability
- stabilization

Disc herniation

- only clear cases (symptoms, MRI, exam)
- radicular symptoms, unsuccessful conservative treatment - 6 weeks
- cauda equina syndrome

!! Disc protrusion - no indication of surg !!

Discectomy - decompression

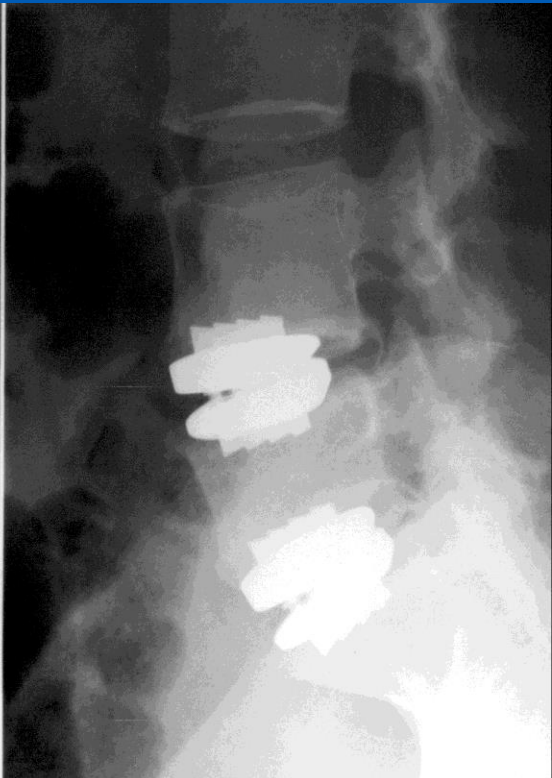
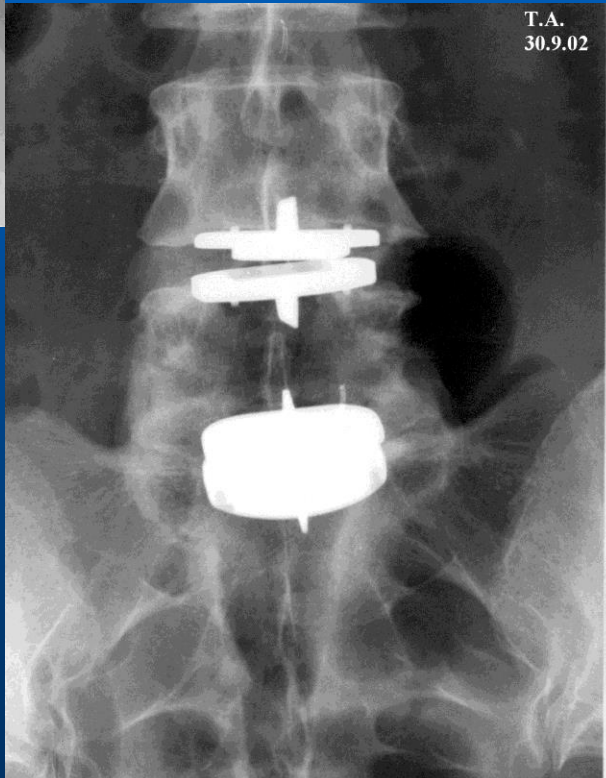
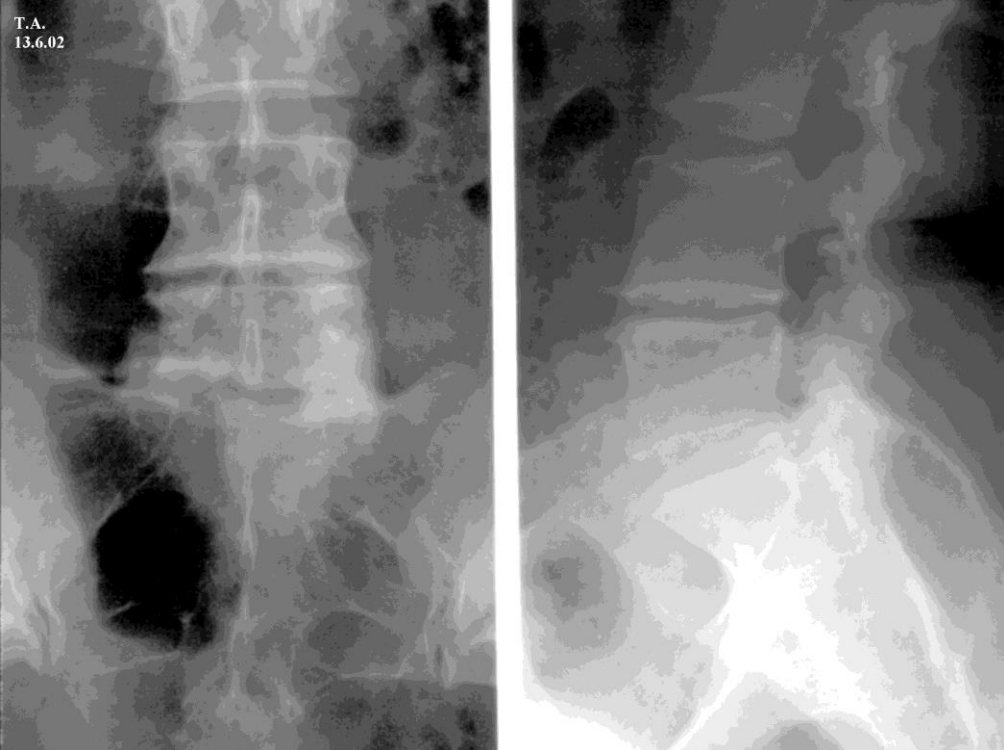
- conventional - open
- with microscope – less invasive
- endoscopic

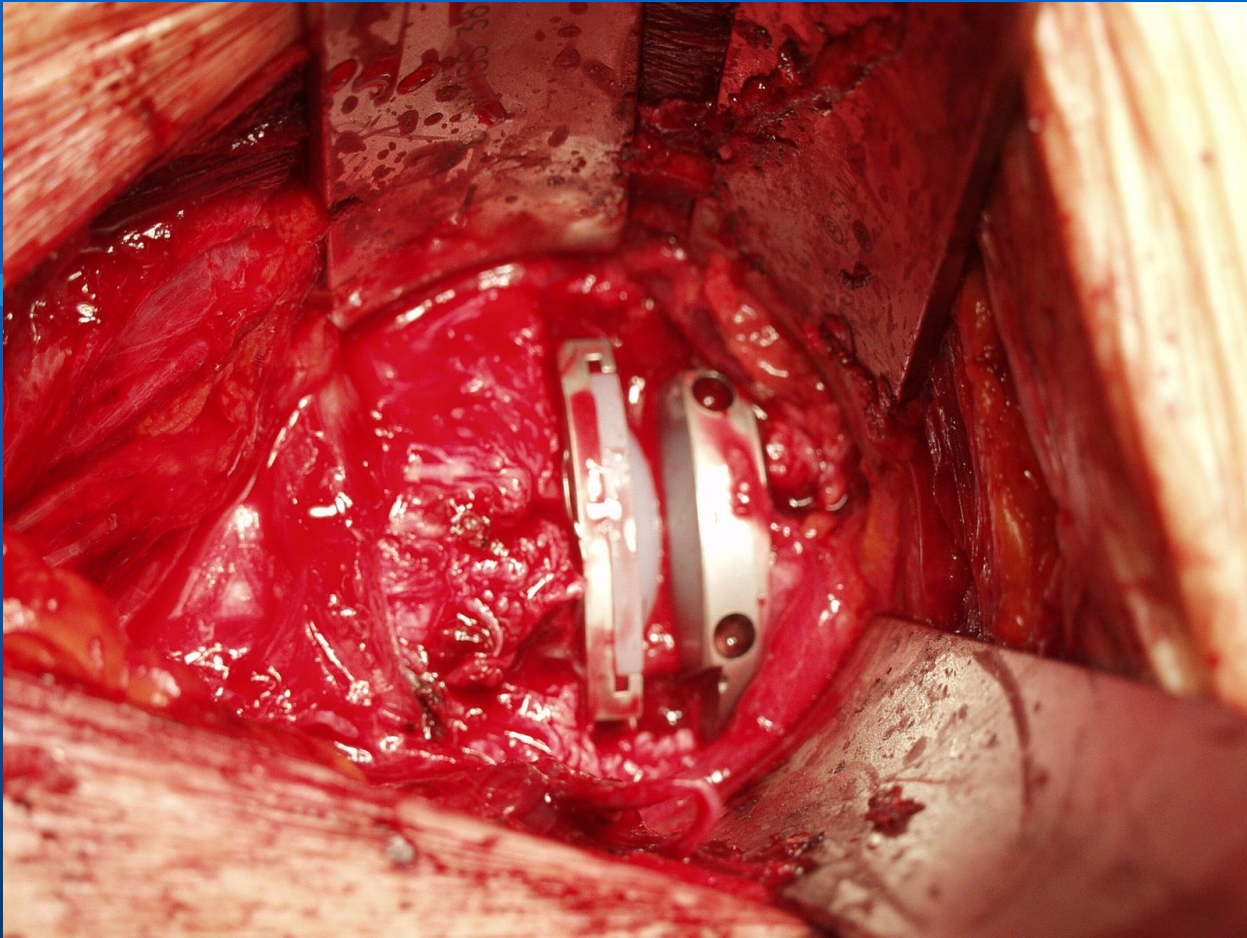
Total disc endoprosthesis

(titanium plates - PE)

- conservative treatment of back pain more than 6 months (L2 - S1)
- normal i.v. joints
- without spondylolisthesis
- spinal stenosis
- disc narrowing (4 mm)

T.A.
13.6.02

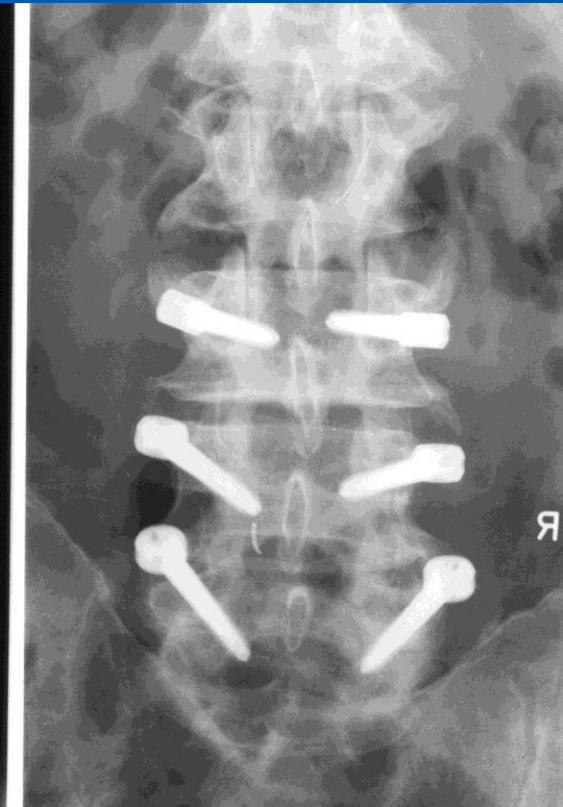
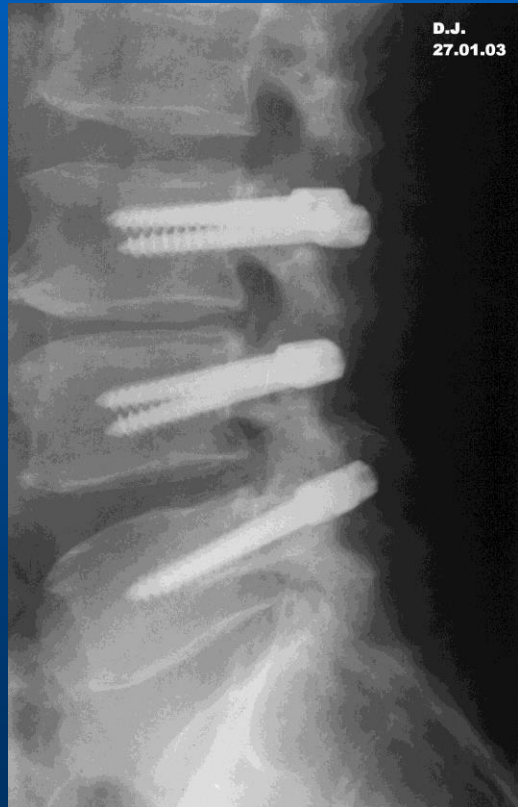
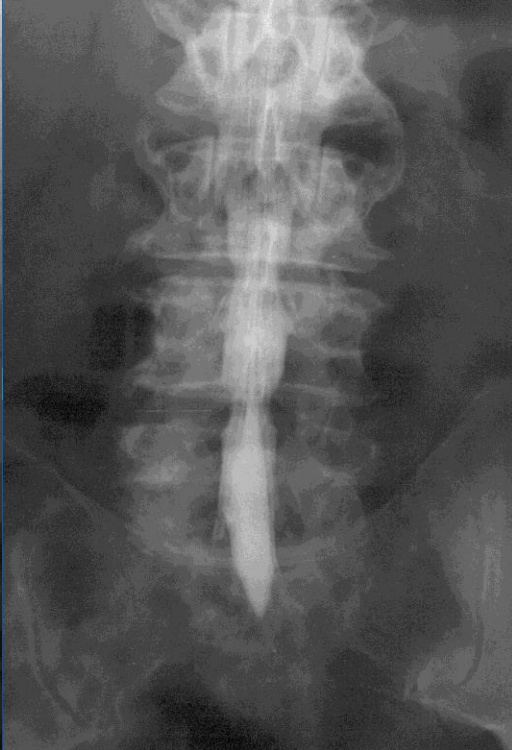
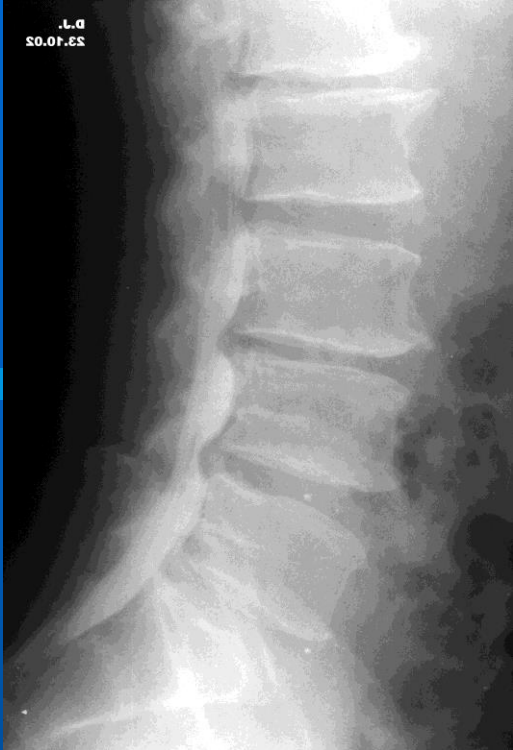
Dynamic stabilization

Titanium screws connected with cord and plastic spacer (without fusion)

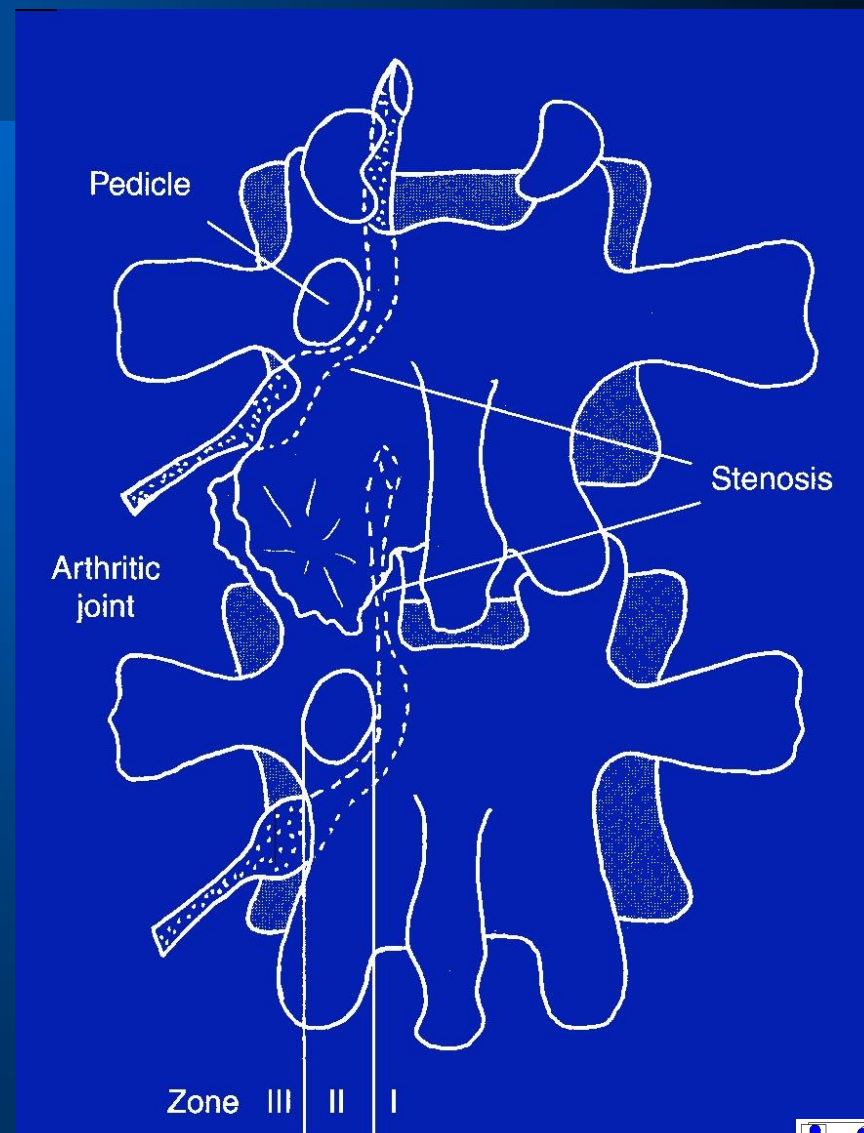
- angle, translational instability
- connected with disc herniation
- spinal stenosis



Spinal stenosis

2. Lateral

- lateral recessus
- radicular canal
- foramen



Etiology, pathomechanism

- Theory of nerve structures compression (ischemia, oedema, inflammation)
- Theory of vascular compression – multilevel stenosis (venous congestion)

clinical cases

- congenital stenosis 3 – 13%
- acquired 75%
- combined others

Radiological definition of LS stenosis

Verbiest – AP canal diameter

- relative 10 – 12 mm

- absolute below 10 mm

Dural sac area below 75 mm²

two levels below 100 mm²

Lateral recessus below 3 mm

Clinical symptoms = LS stenosis

- none (20% pts. above 60 yrs.)
= „narrow spine canal“
- radicular syndrome
- cauda equina syndrome
- neurogenic claudication

Neurogenic claudication

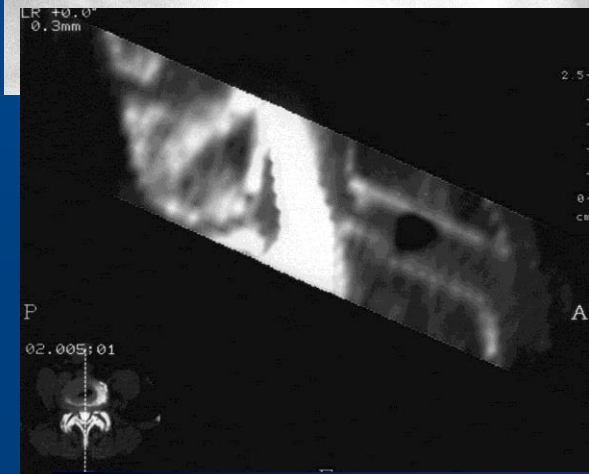
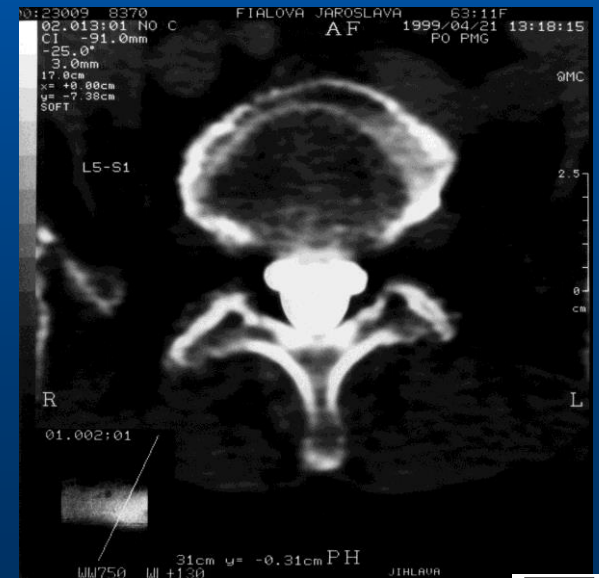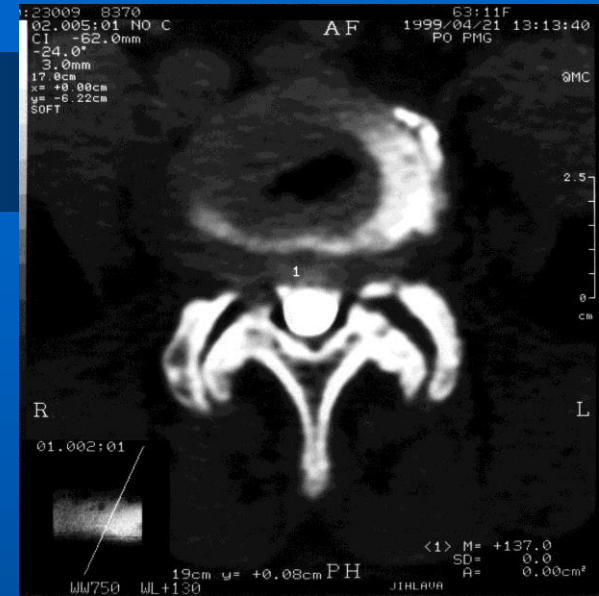
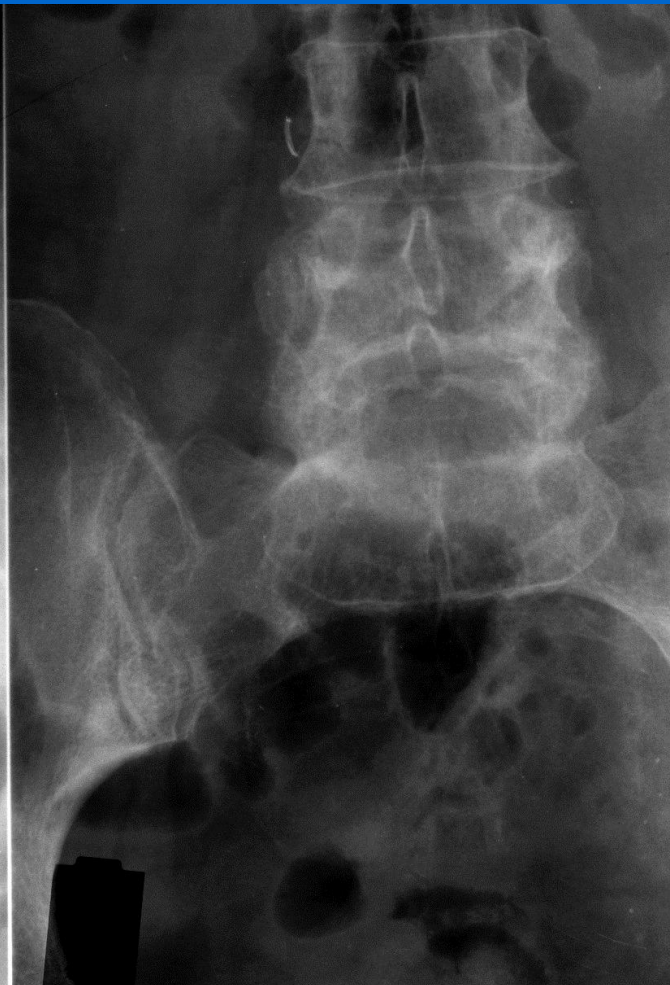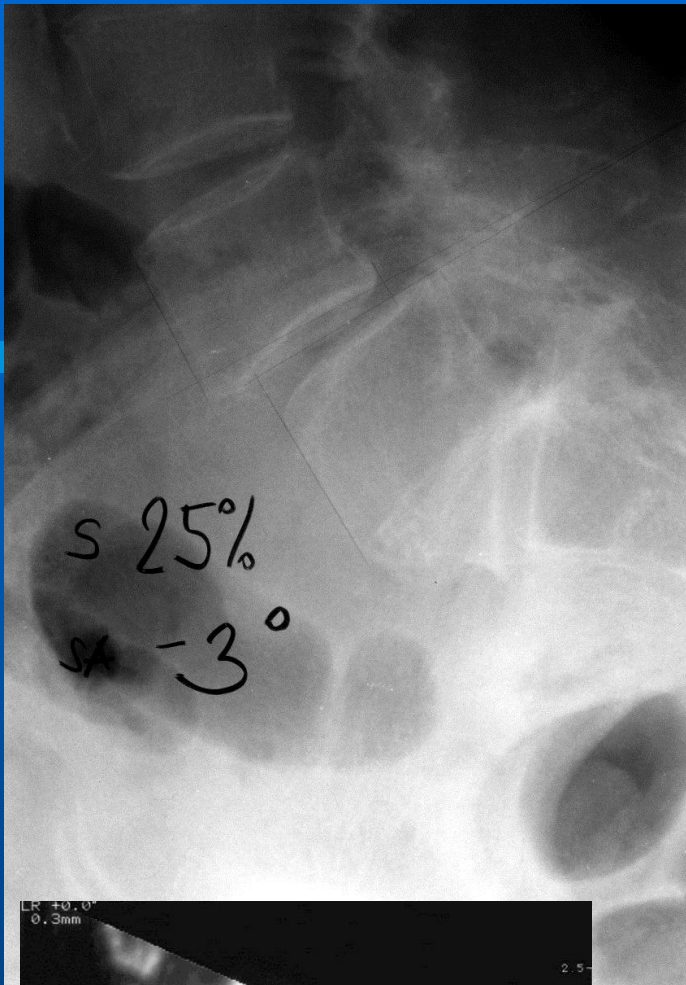- standing, gait – pain, paresthesia, weak lower extremities
- worsening – extension, downhill gait
- improvement – sitting, squatting, flexion
- gait limited - fluctuate

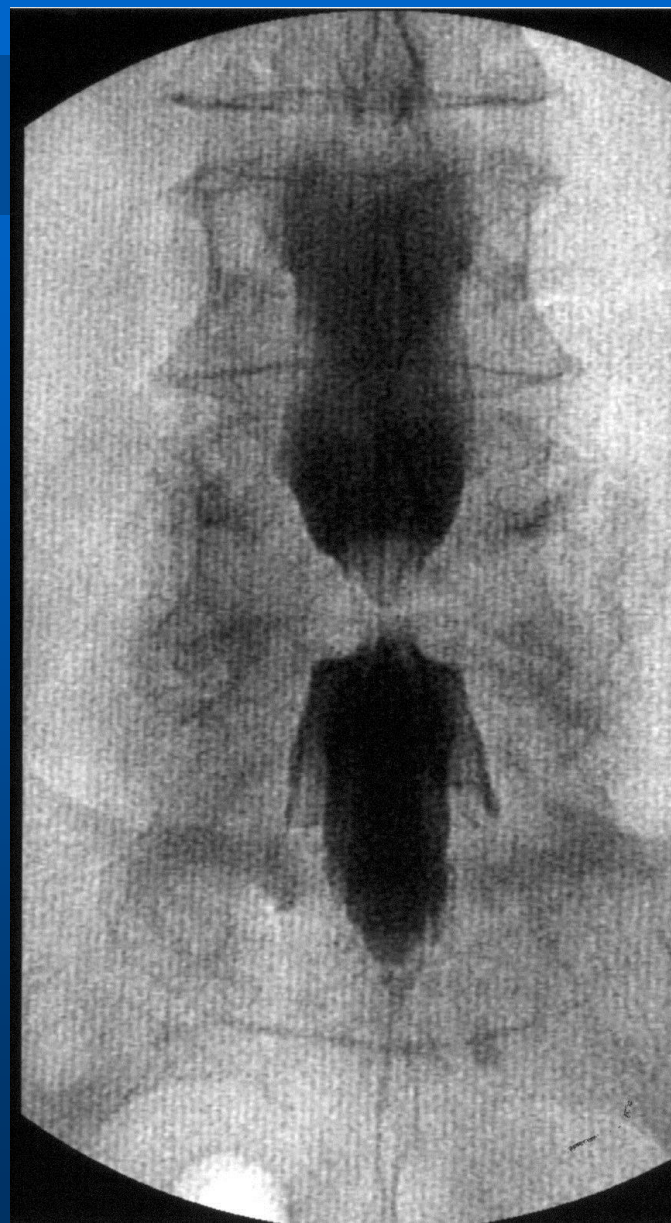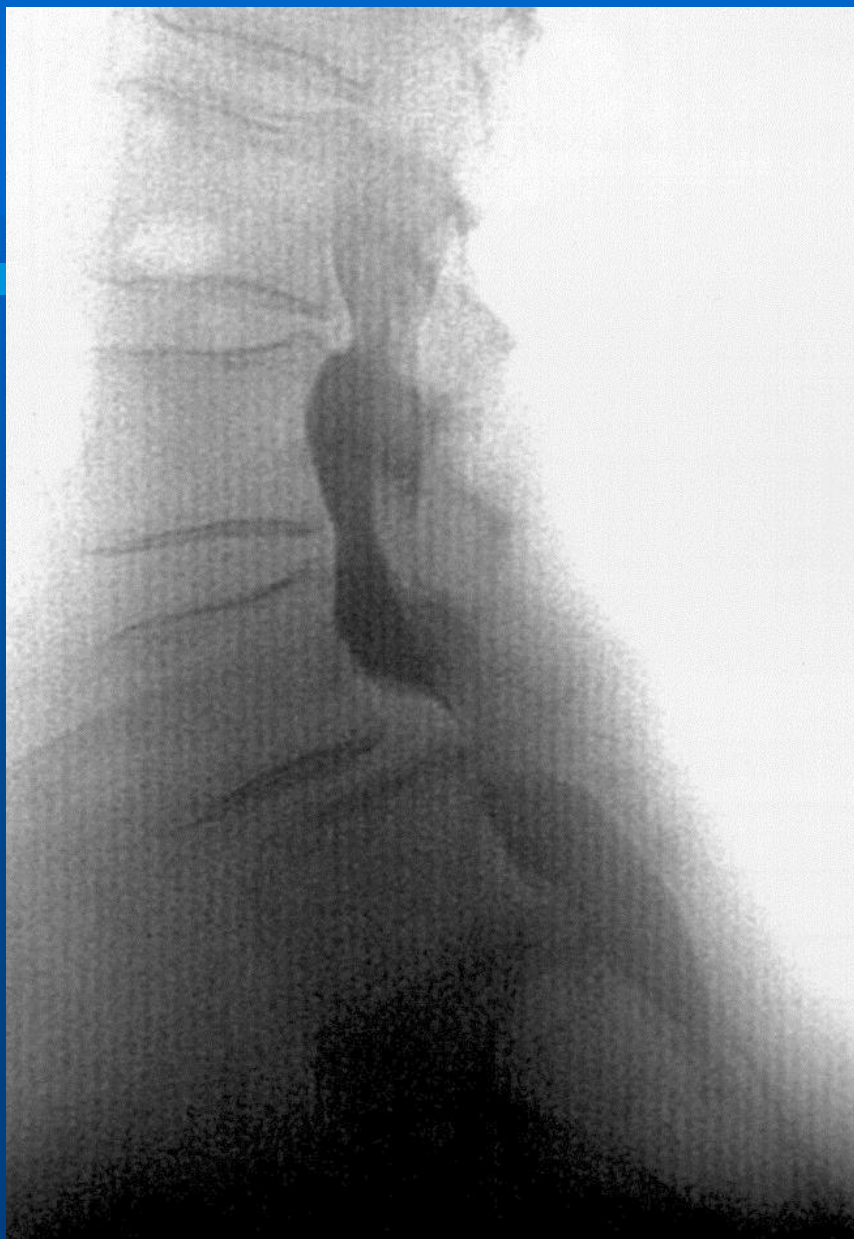
Neurogenic claudication

- stenosis of minimum 2 levels
- intermitent hypoxia of cauda equina
- disorder of venous drainage
- mild back pain
- 1/3 of pts. with paresis

Diagnostics

- anamnesis, Oswestry quest.
- neurological examination
- treadmill gait
- EMG
 - 50% pts. radiculopathy bilat.
 - 20% monoradiculopathy
- EMG after stress

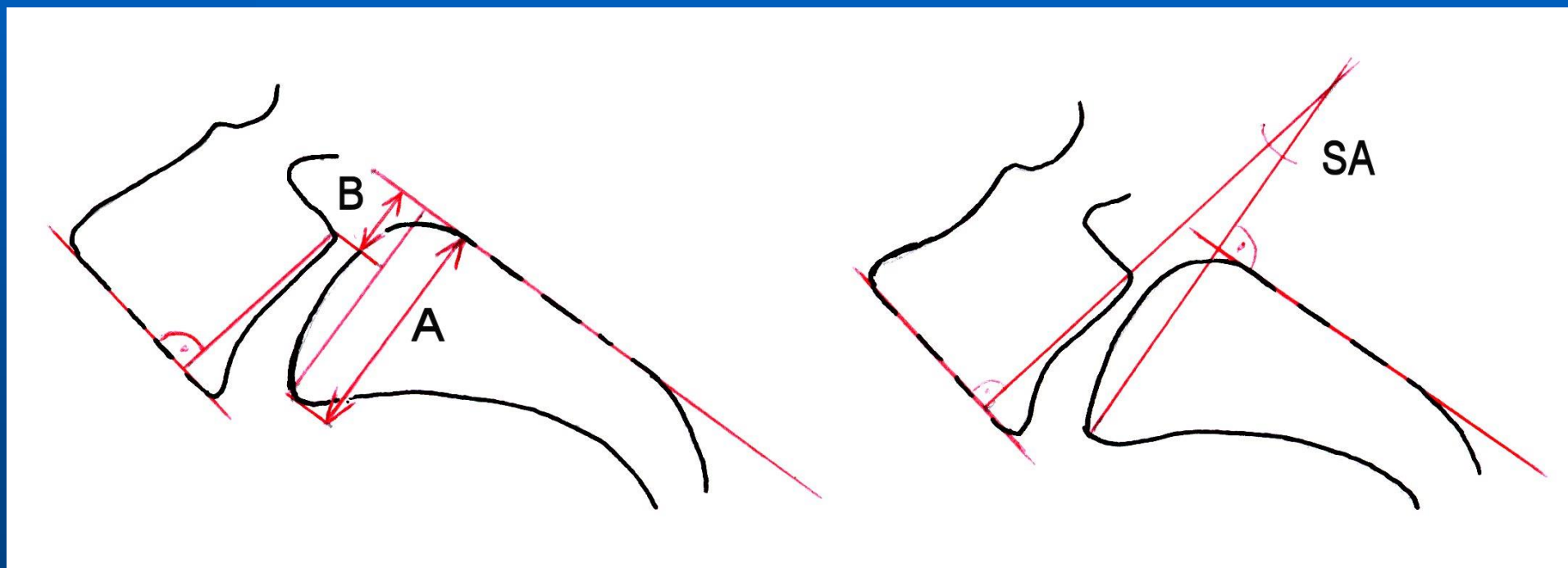




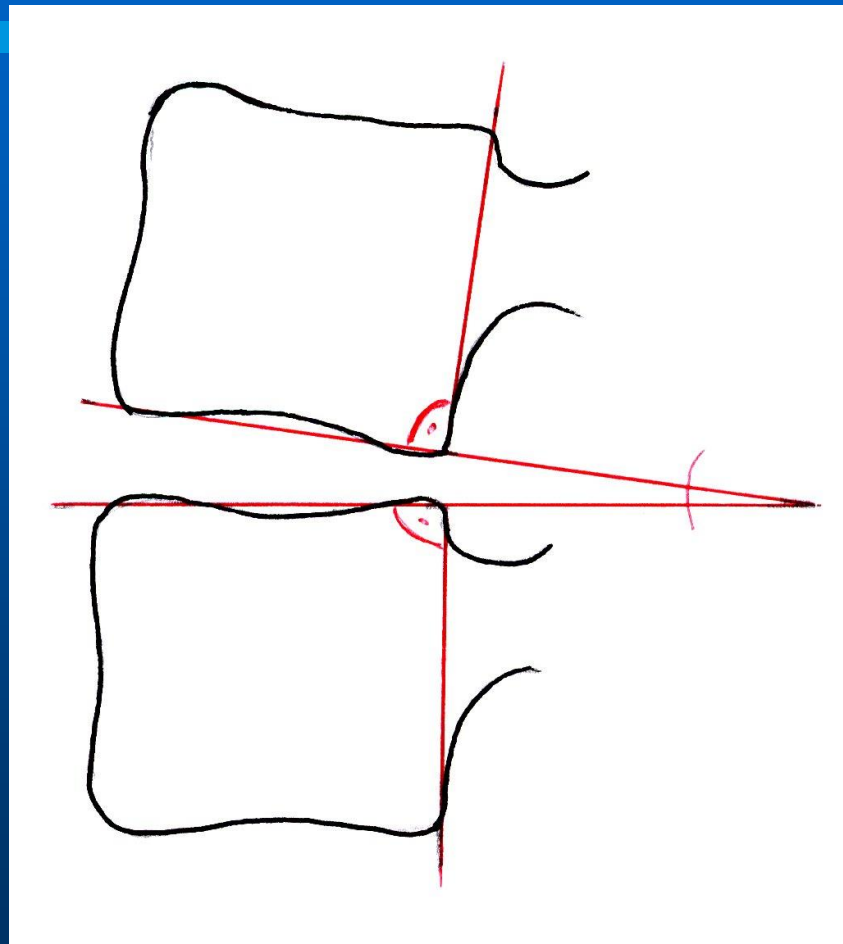
X-rays of L spine

- plain: AP and lateral
- functional (flexion / extension)

X-rays: Wiltse and Winter method of measurement



Dupuis et al. method



Instability: flexion/extension

- translational $\geq 8\%$

Wood et al. 1994

- rotational $> 11^\circ$

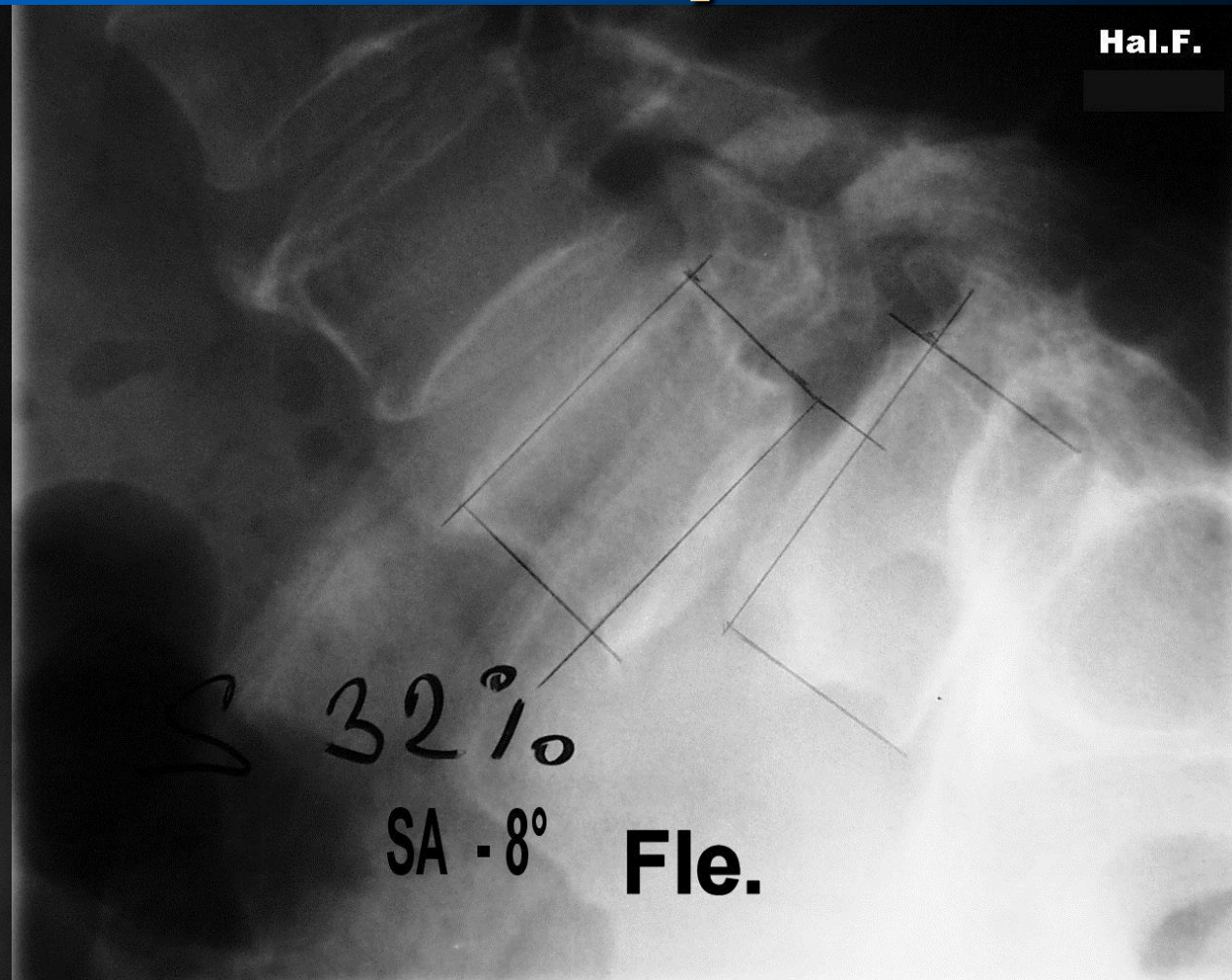
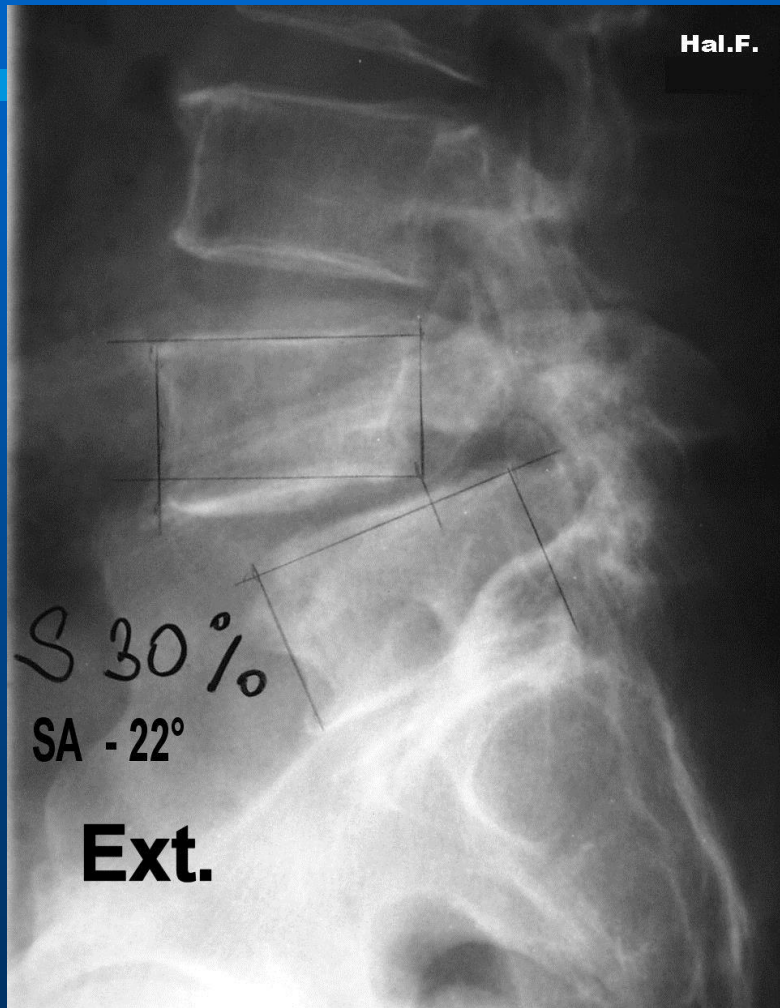Louis 1985

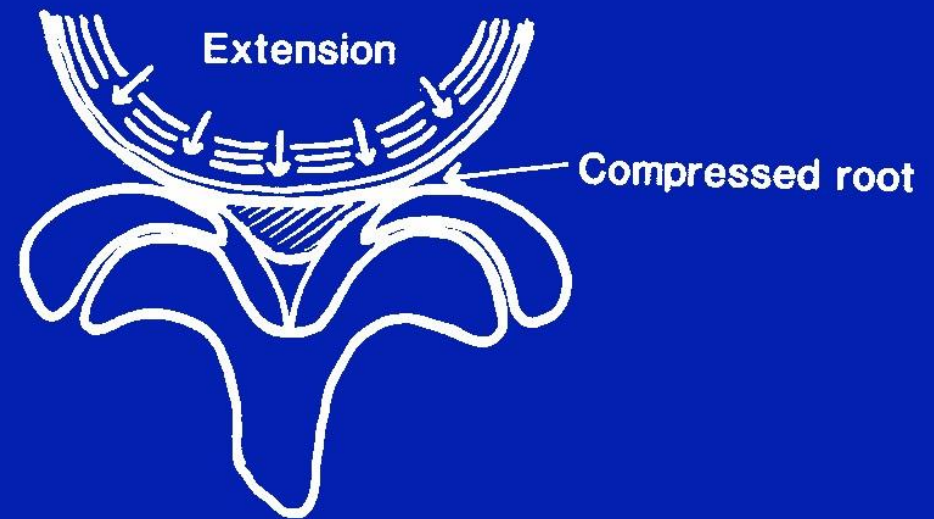
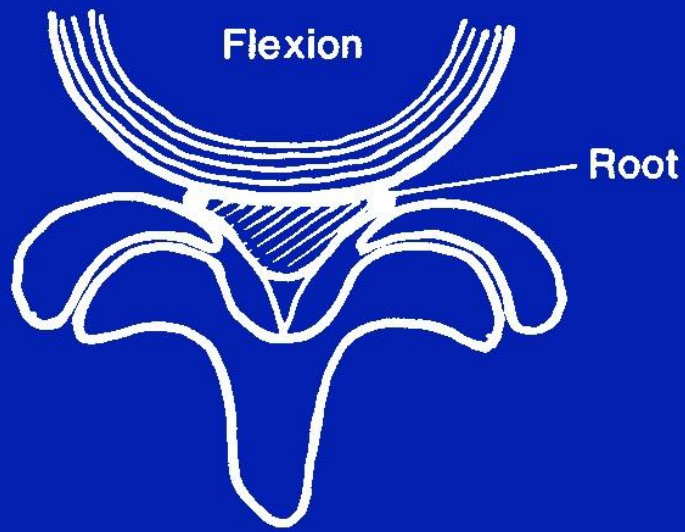
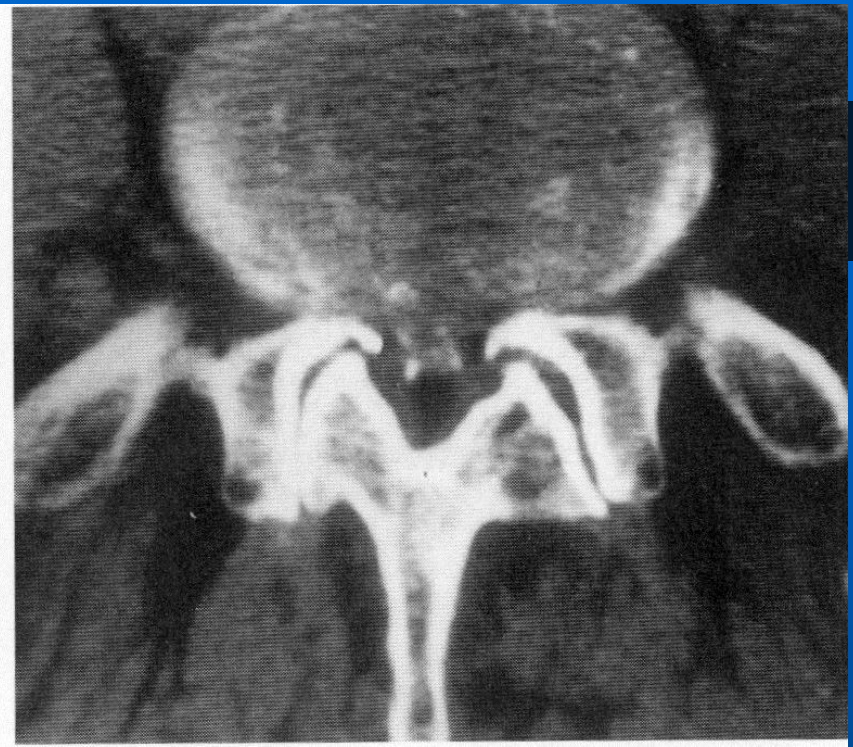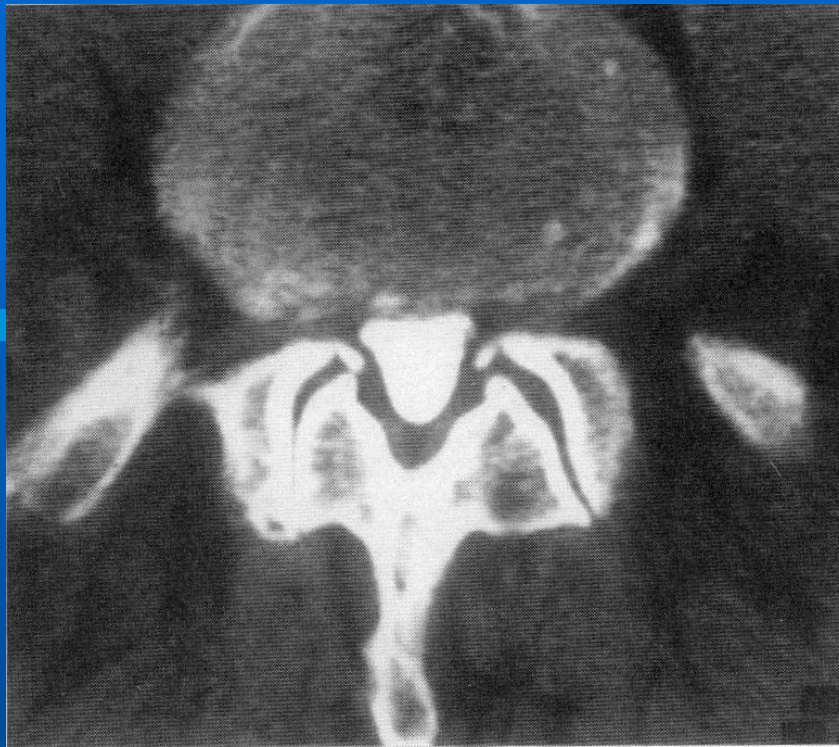Wood et al. 1994

Instability surgery:

- fusion and instrumentation
- dynamic stabilization

Radicular deficit of L5 - 51 yrs






MRI examination

- false positive 7-21%
- functional MRI flexion/extension
- MRI myelography


Thompson scale

Grade 1




normal MRI

2




disc degeneration
mild

3




moderate

4

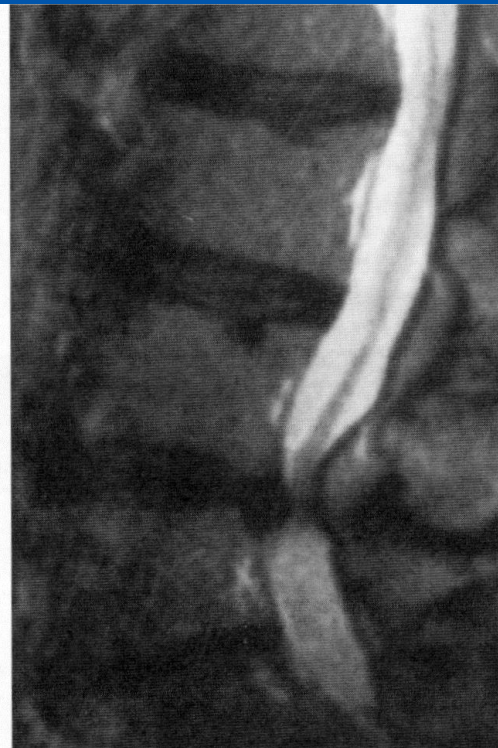
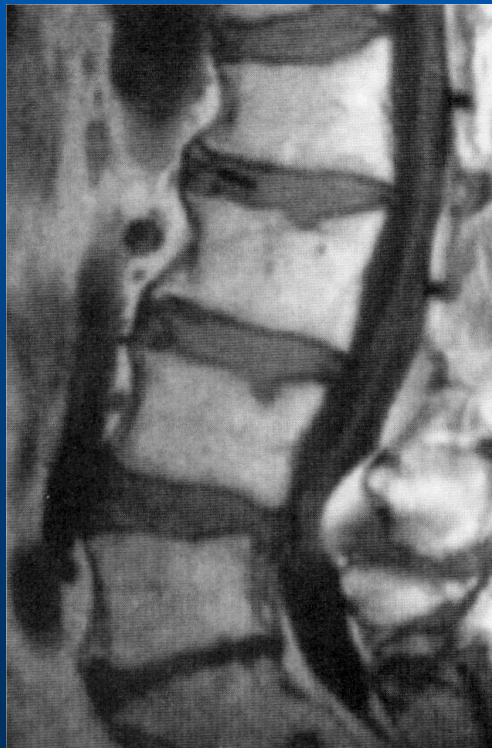
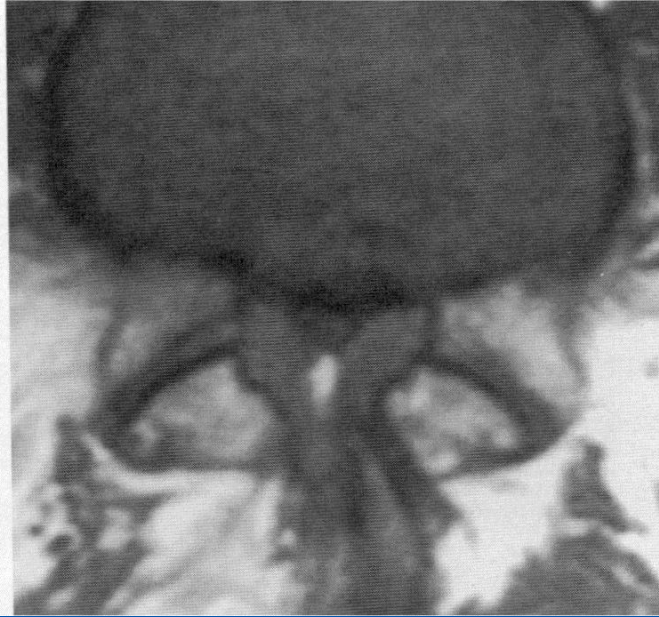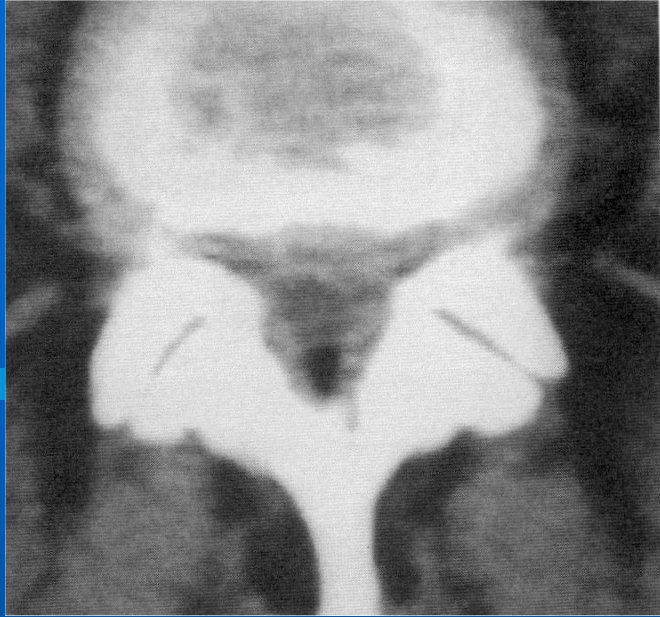severe

5

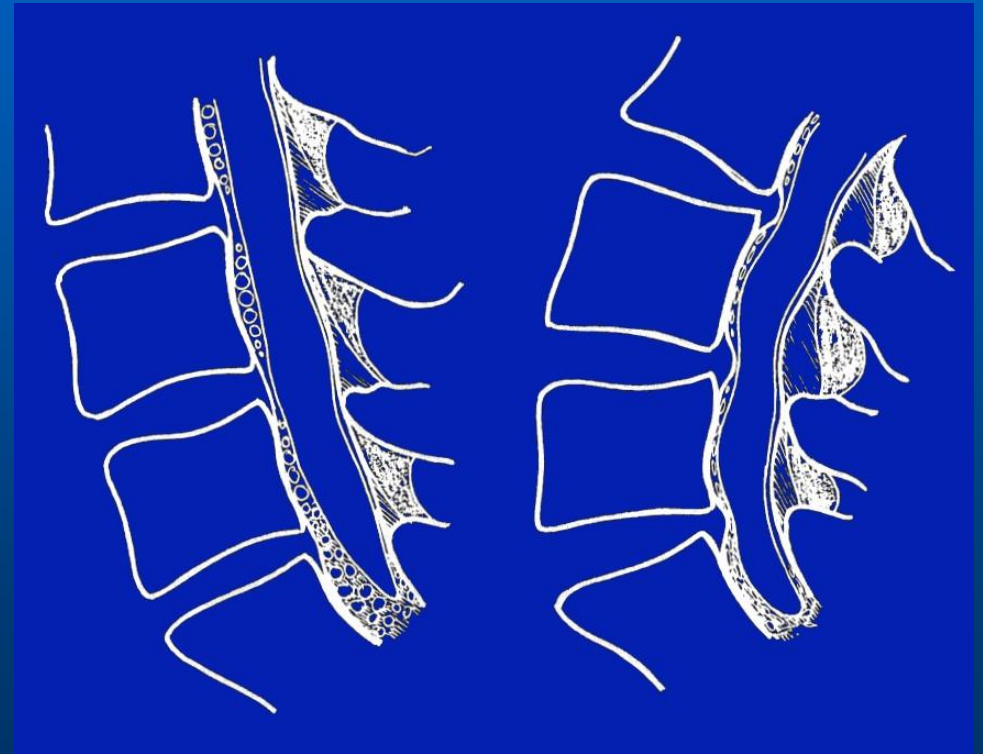
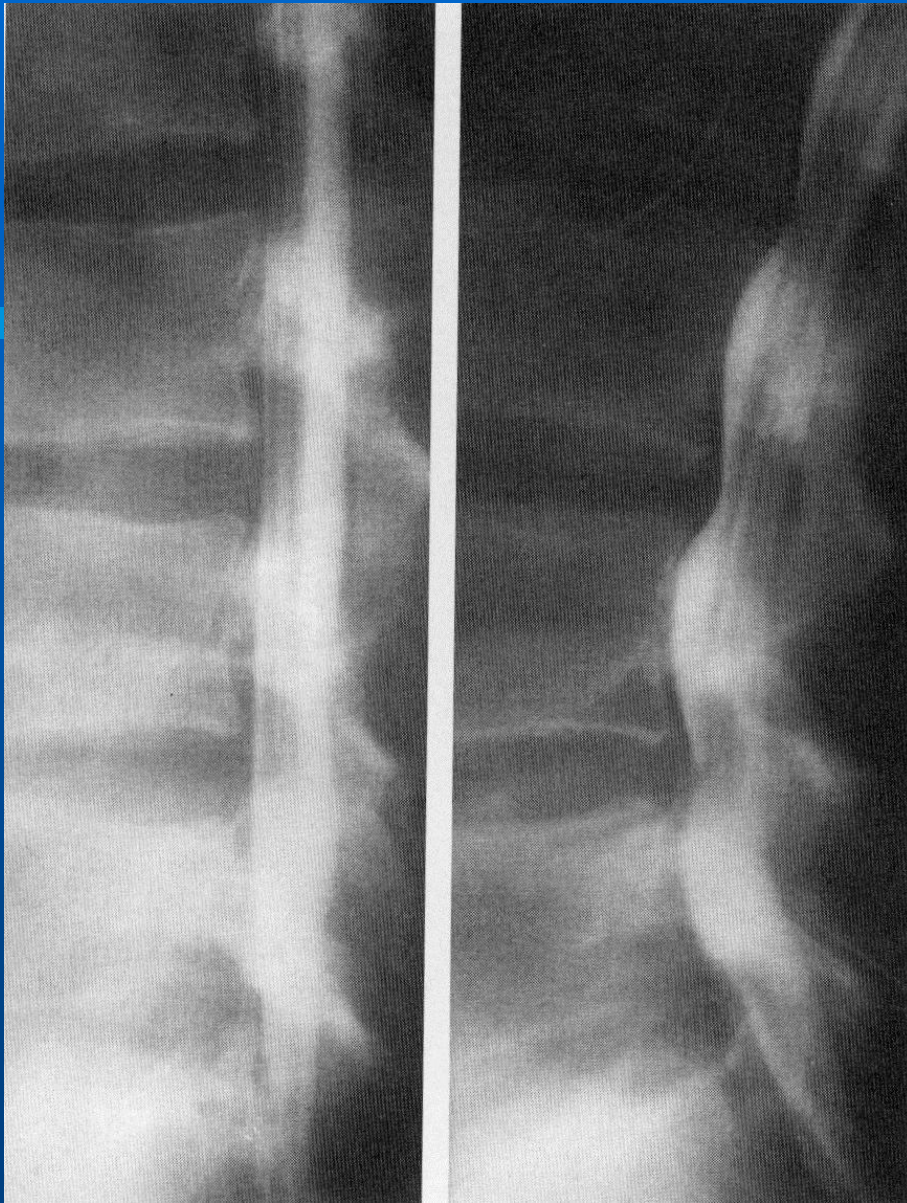

severe



Contrast perimyelography in the past

- now MRI is standard
- functional X-rays



Management of mild and middle forms

- physiotherapy, orthotics, analgetics, NSAIR drugs
- psychofarm. / antidepressive drugs
- calcitonin ?
- epidural corticosteroids ?

Pain clinic

- drugs
- nerve blocks, injections
- psychologist
- invasive implants technologies

Spinal cord / epidural stimulation

- neuropathic pain
- careful selection of patients
- failed back surgery syndrome
 - only partial pain relief

Spinal cord stimulation

- percutaneous implantation
(electrodes 4 – 8 polar) epidural
- laminotomy in loc. anesthesia,
testing period of 1 month
pain relief more than 50%,
then definitive implantation

Middle form of LSS – surgery indication

- symptoms more than 3 months, unsuccessful conservative treatment

- gait 20 - 200 m

- Oswestry quest. 40 - 65 %

- VAS 4 - 7

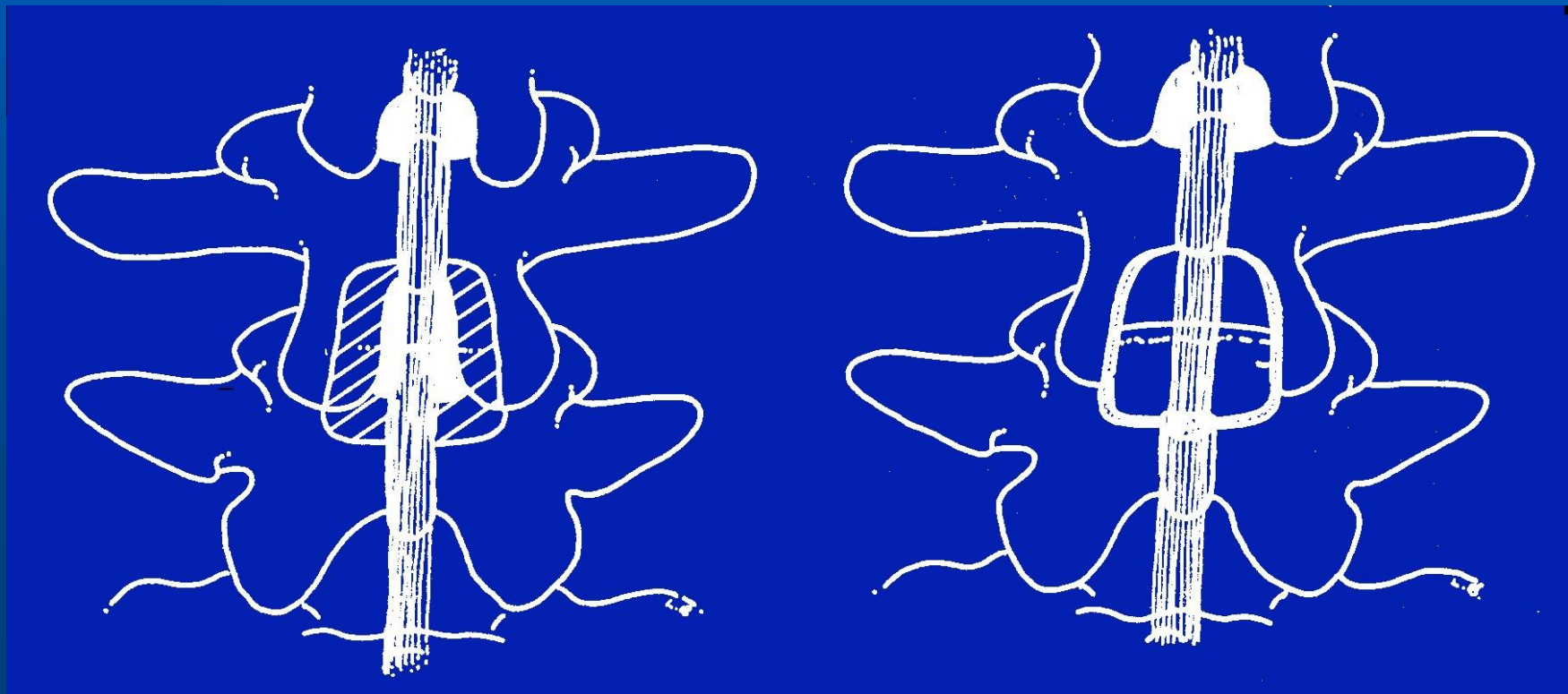
- dural sac area below 100 mm²

Treatment of severe, progressive forms

- PosteroLat. Decompression
- PL. Dec. + fusion (F)
- PLD + F + instrumentation
(transpedicular screws)

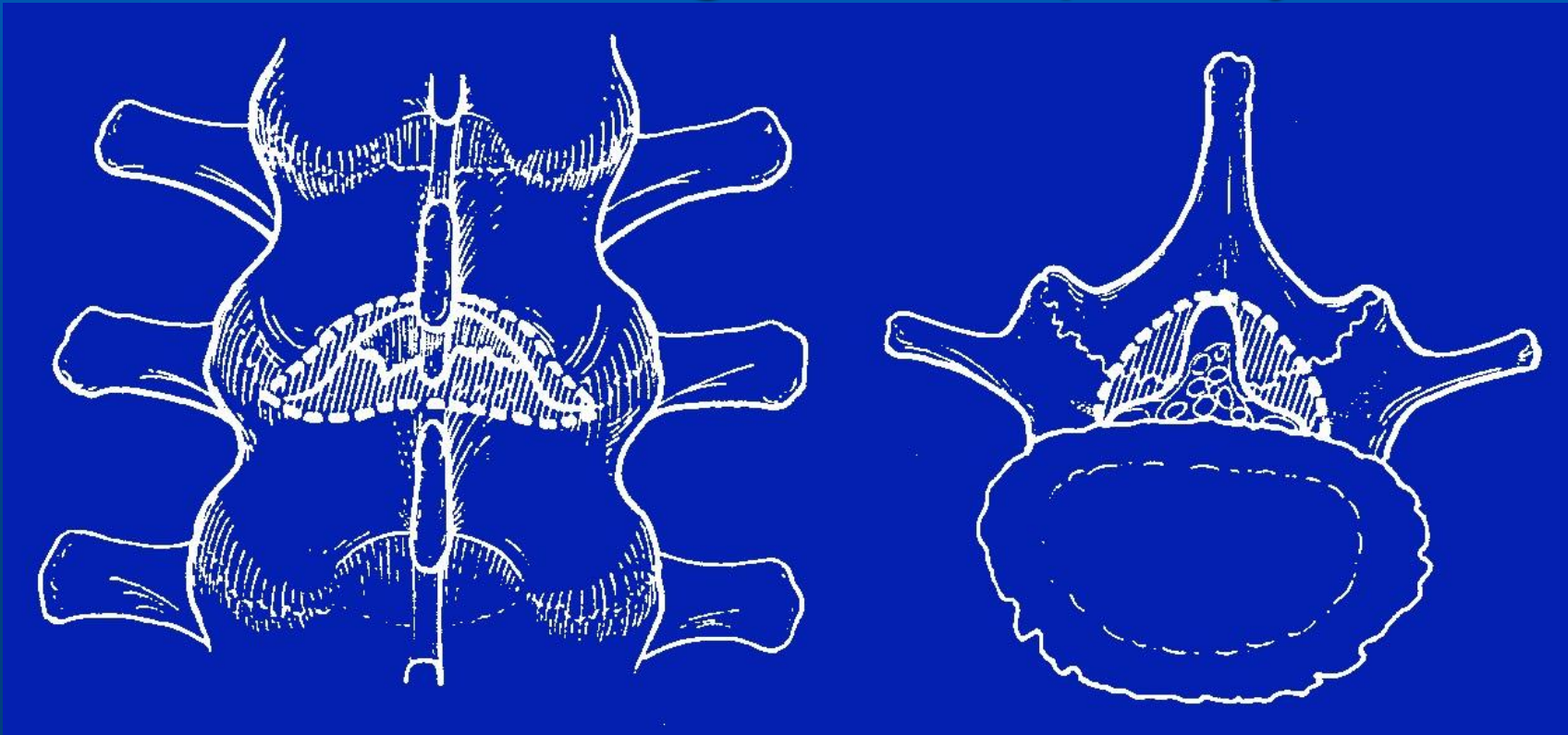
decompression

posterolateral – laminectomy

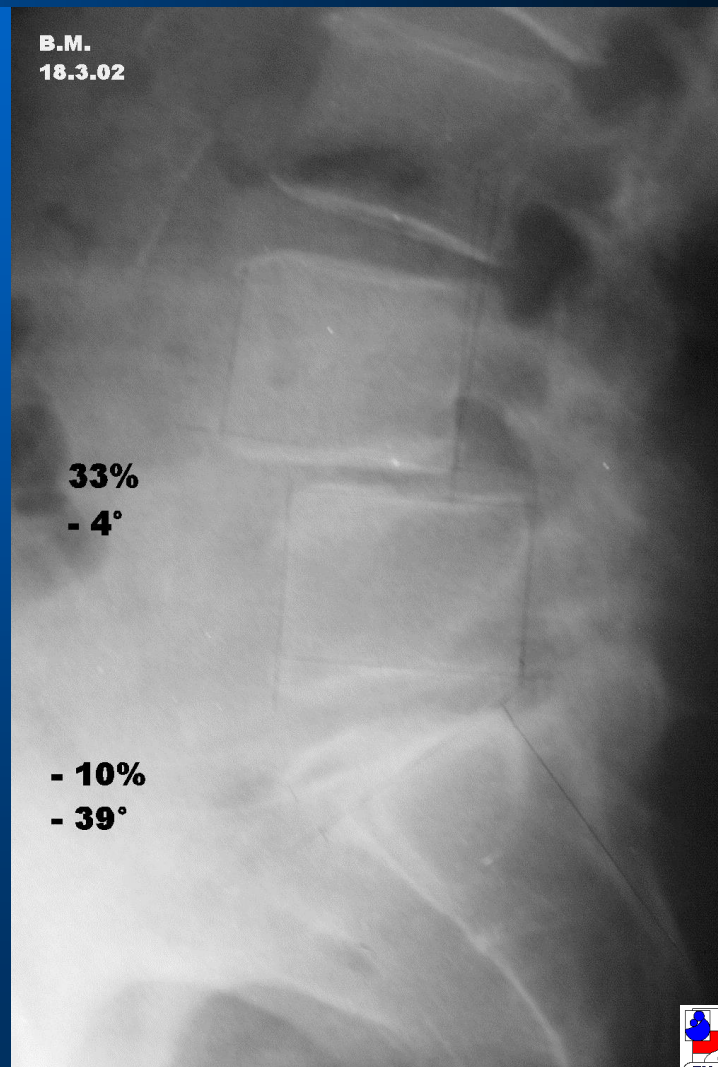
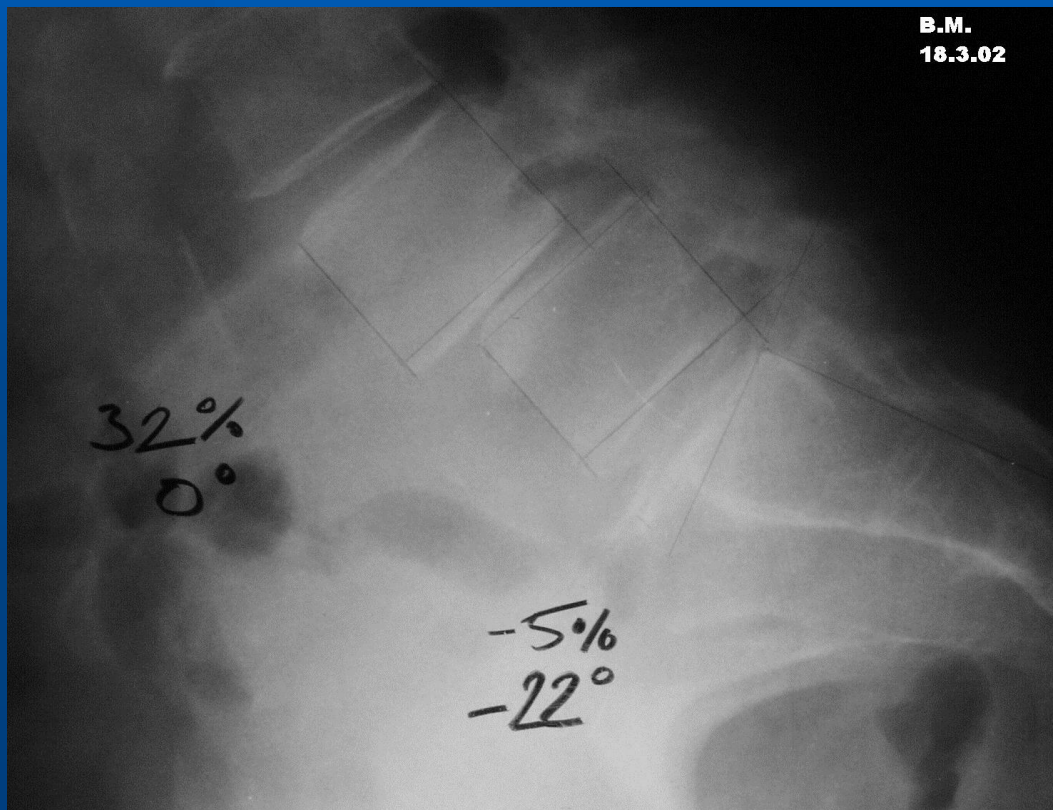


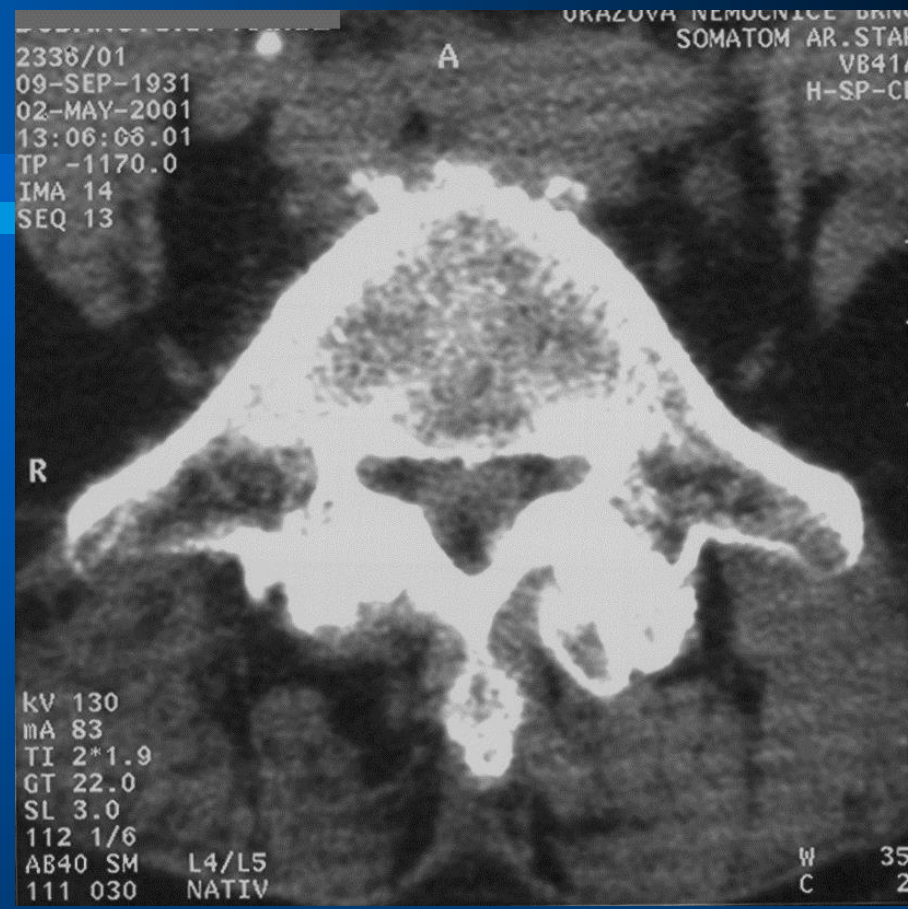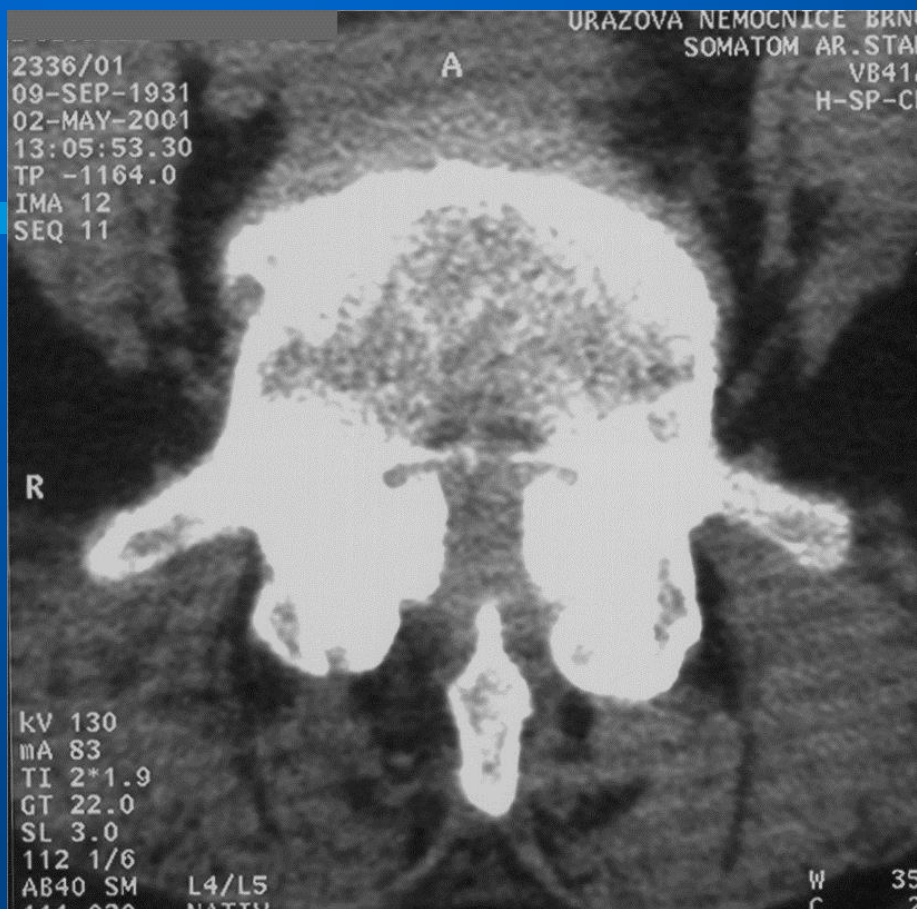Selective decompression

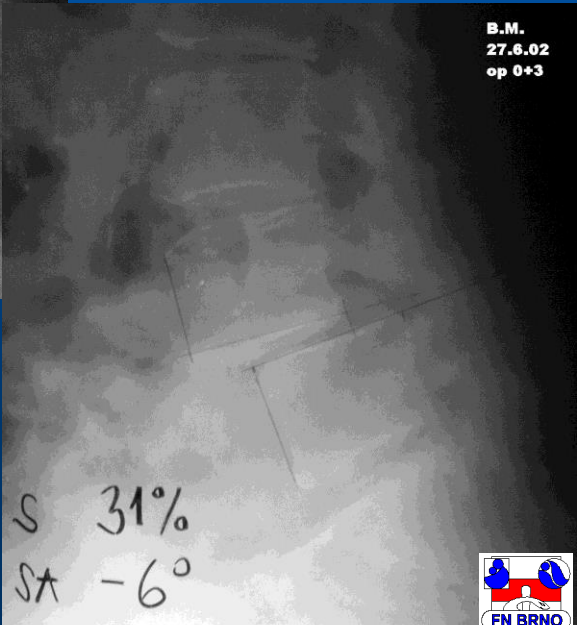
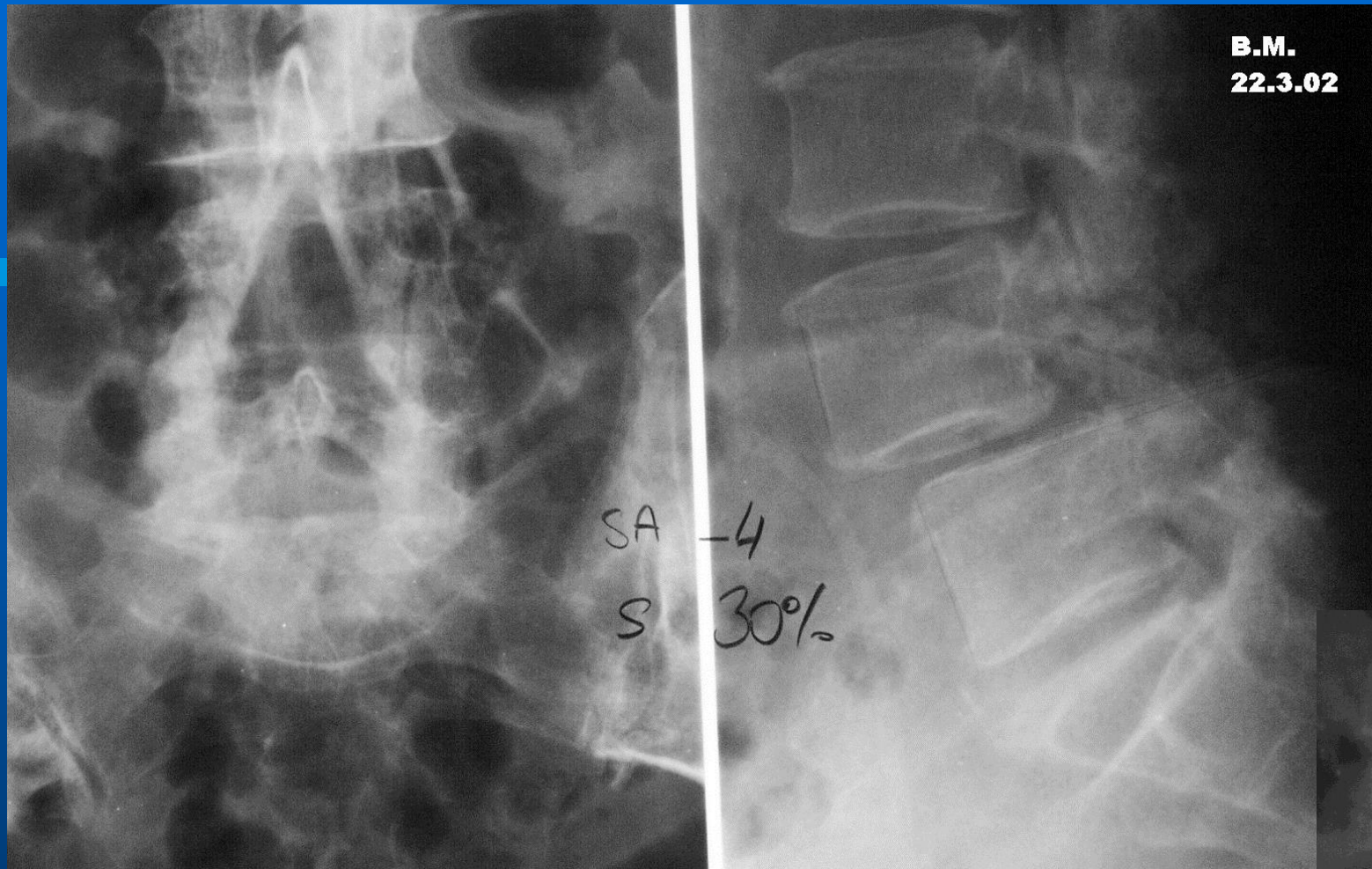
undercutting laminoplasty



Decompression + PL fusion







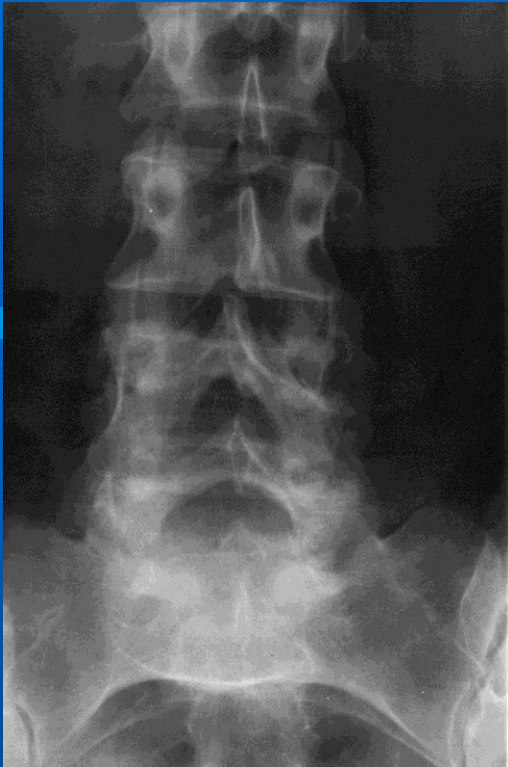Decompr., fusion, transped. screws

Posterolateral fusion

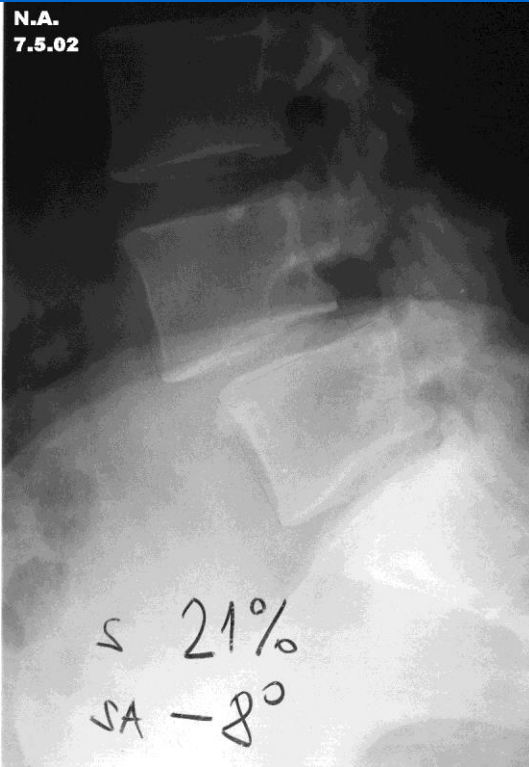360° fusion - PLIF (grafts, cages)

TLIF

(combined surgery + anterior fusion)



N.A.
7.5.02

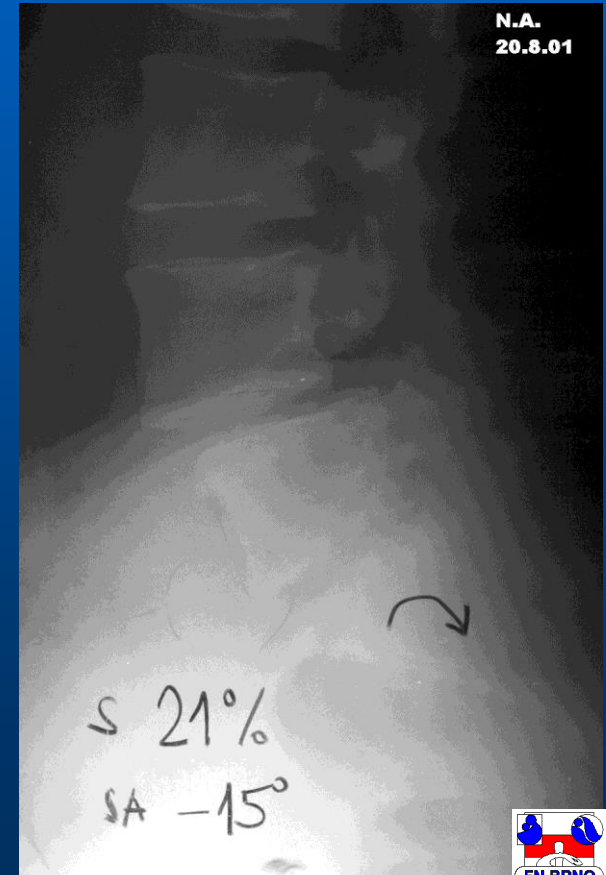

S 21%
SA -8°



N.A.
20.8.01

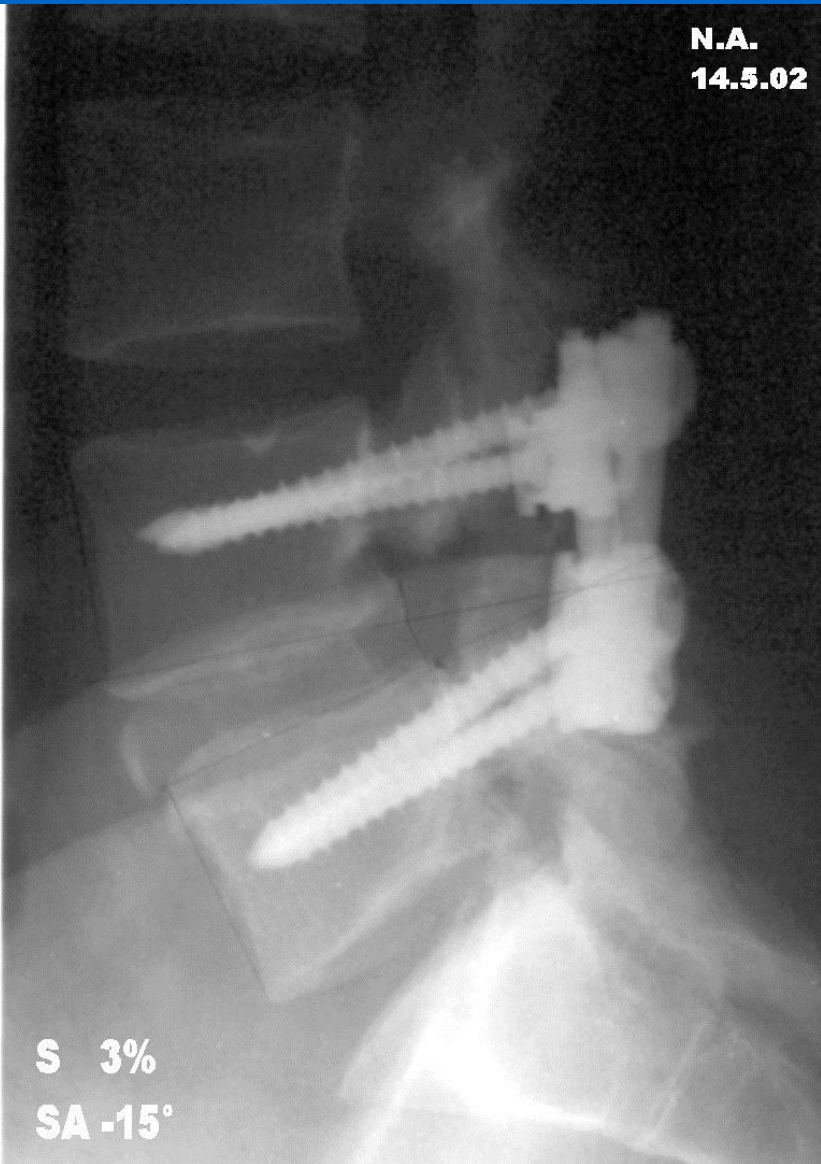
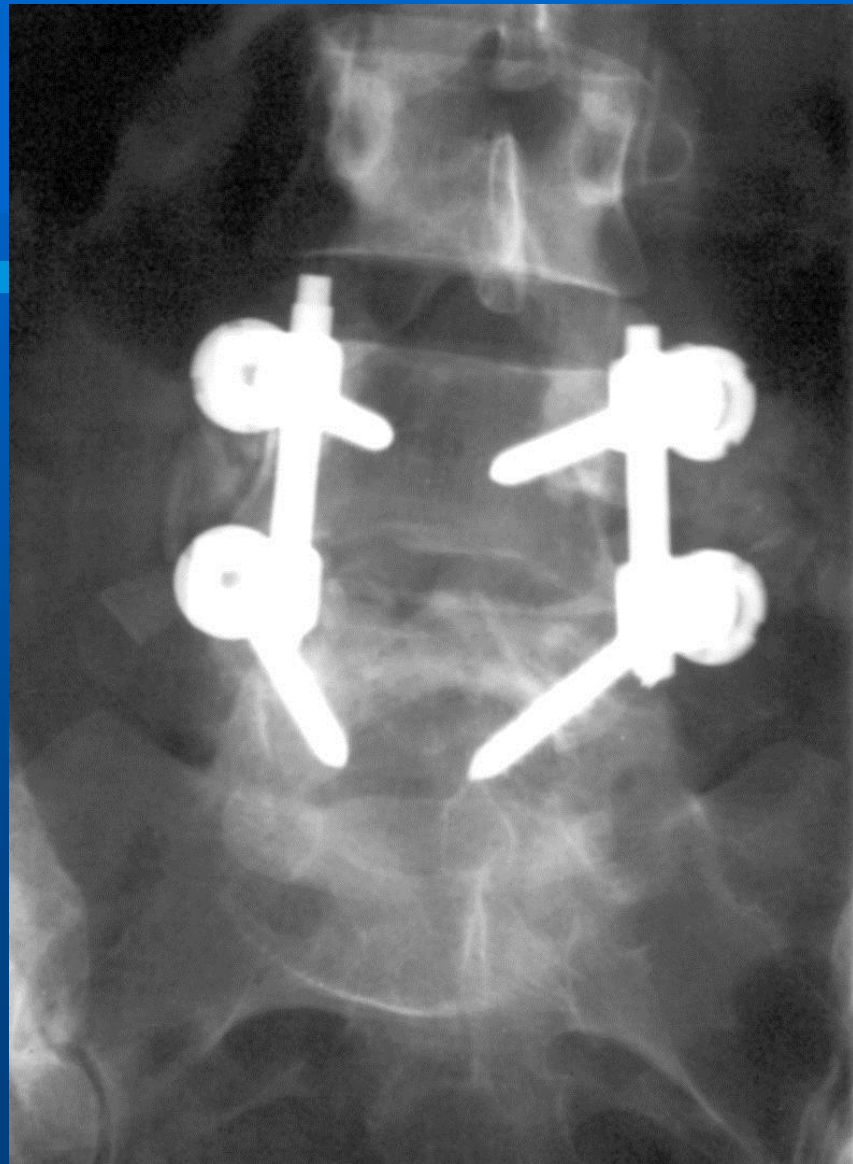
S 24%
SA +4°


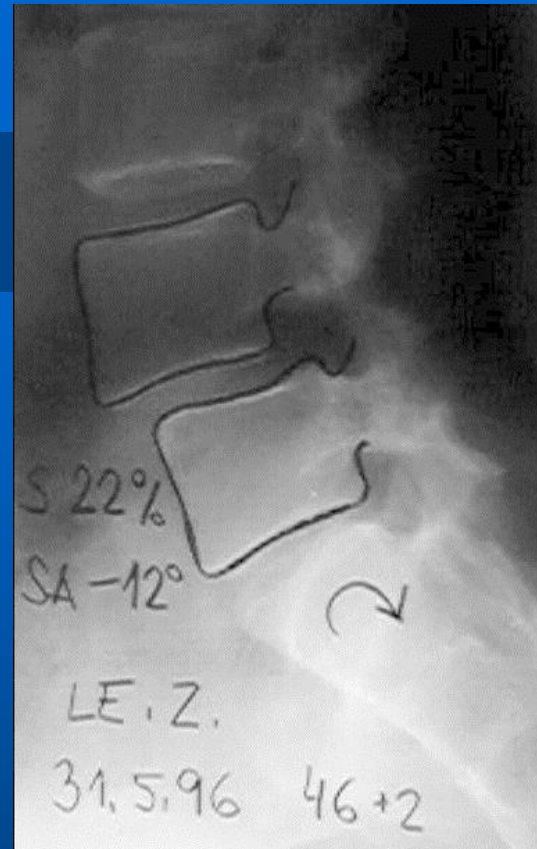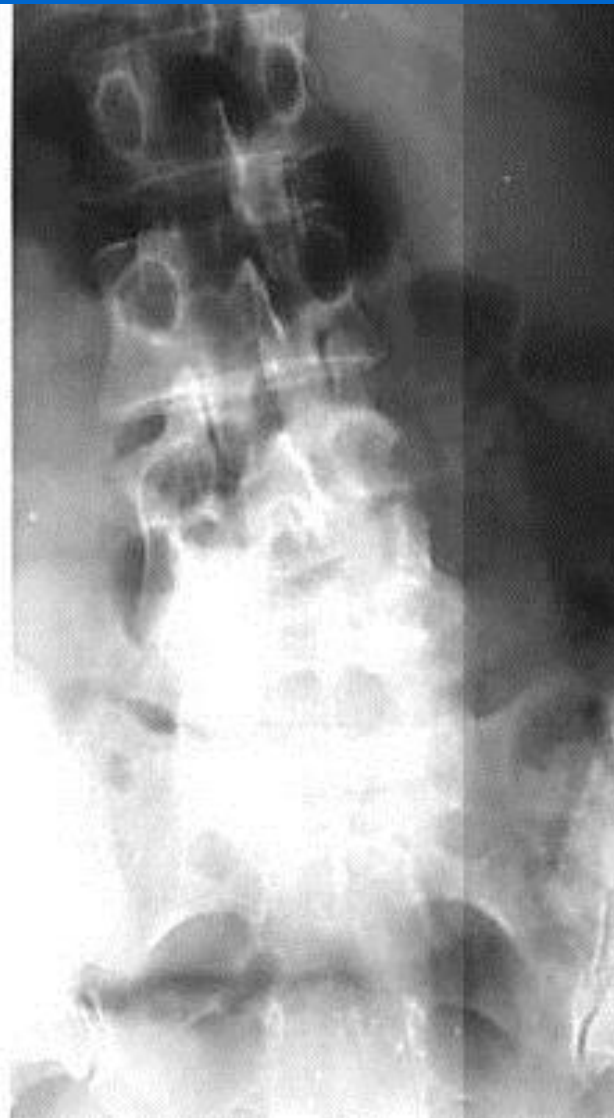
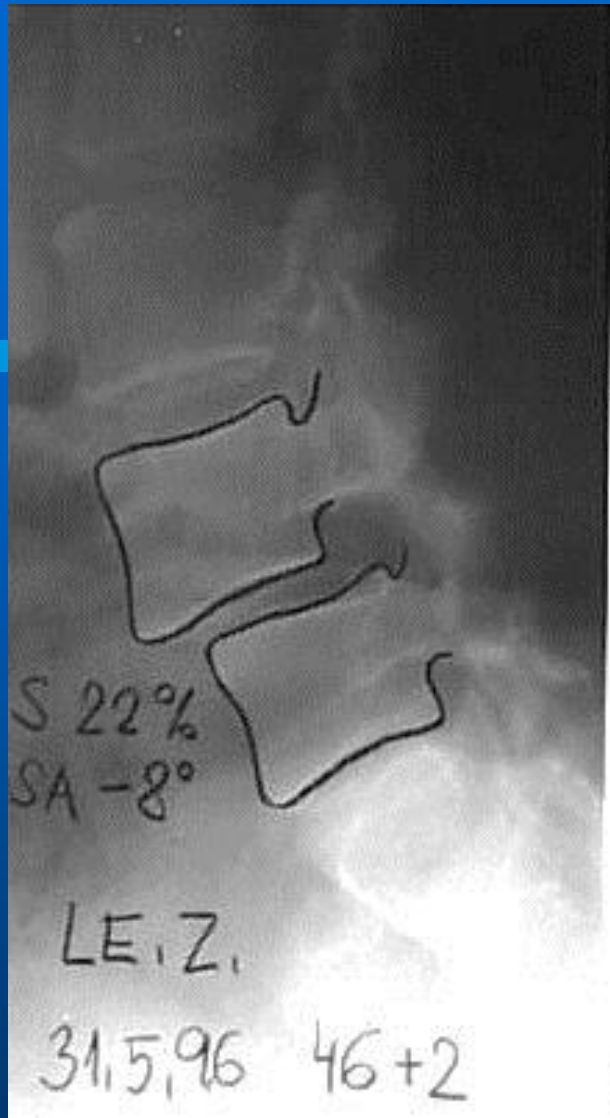


N.A.
20.8.01

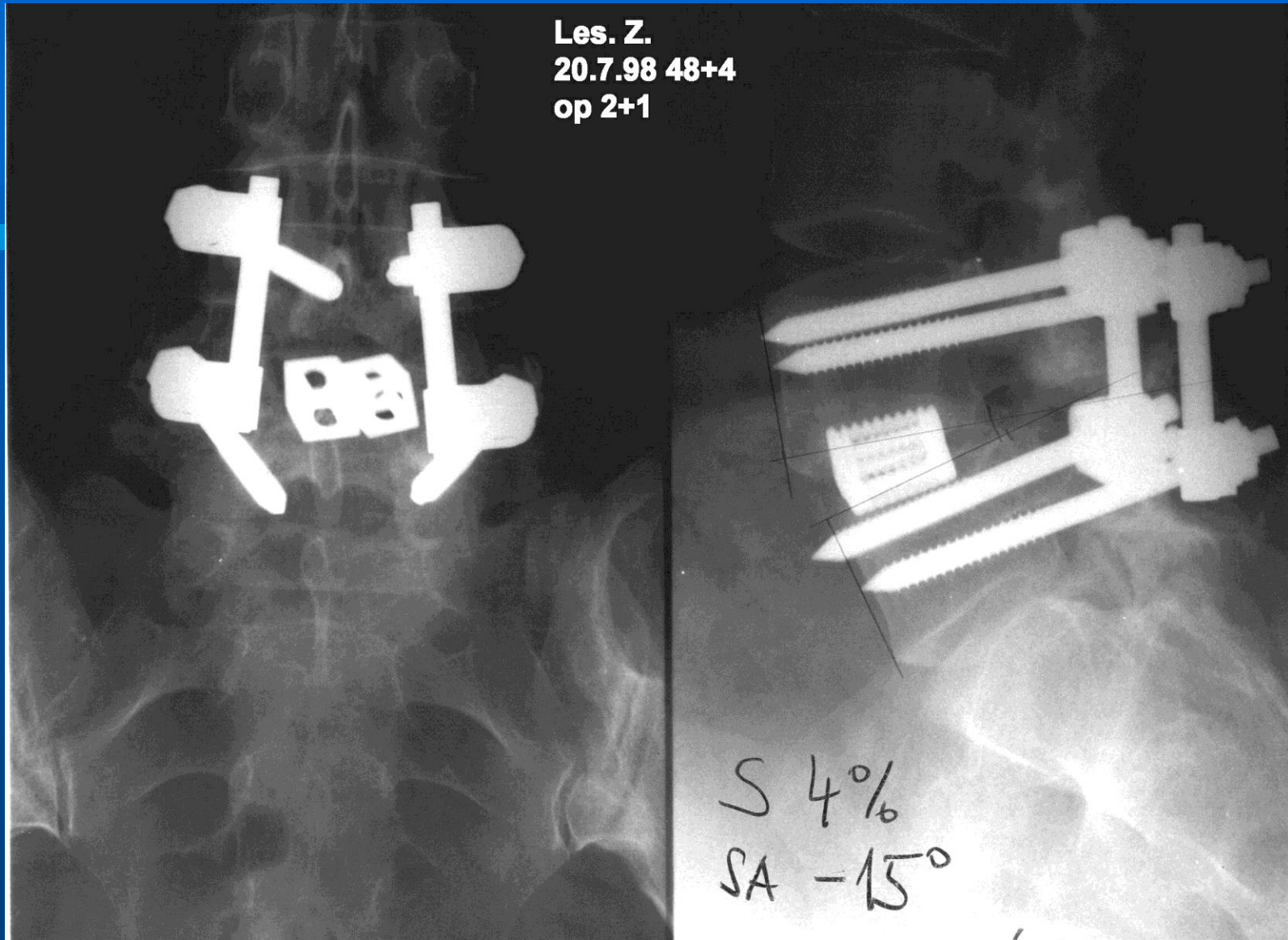
S 21%
SA -15°



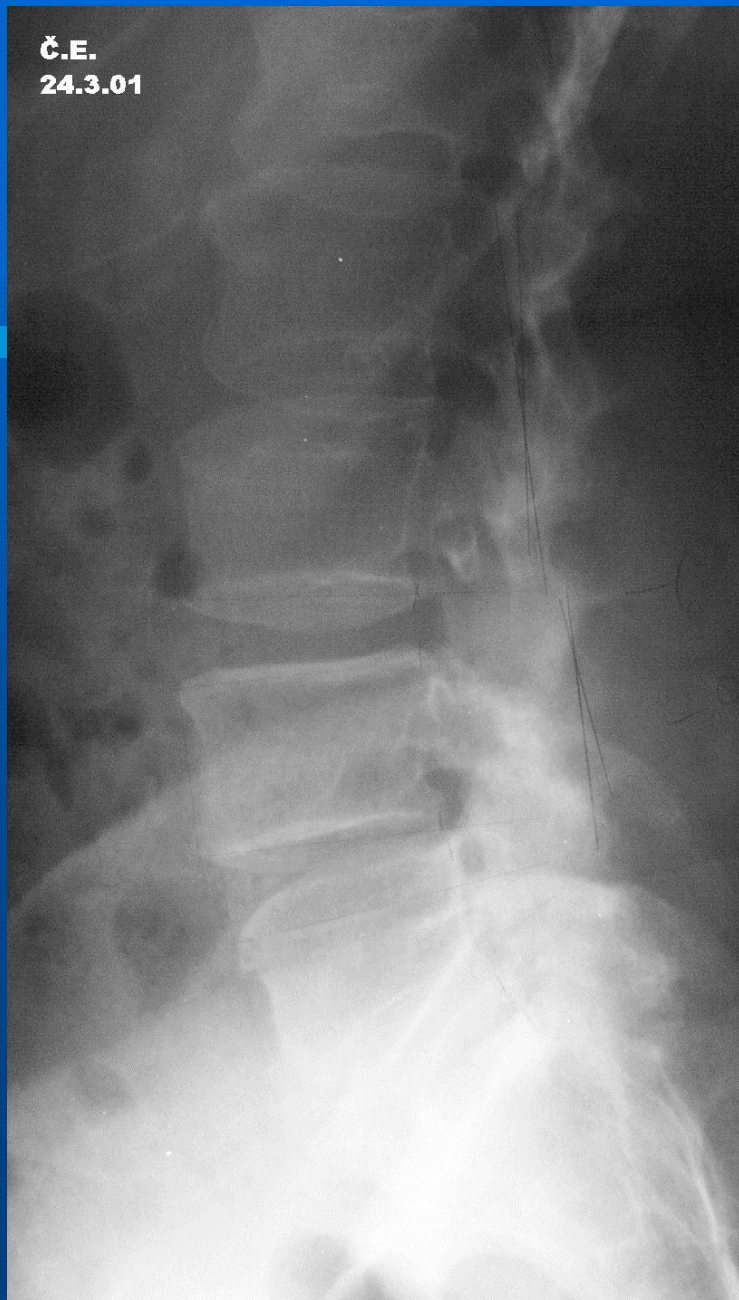




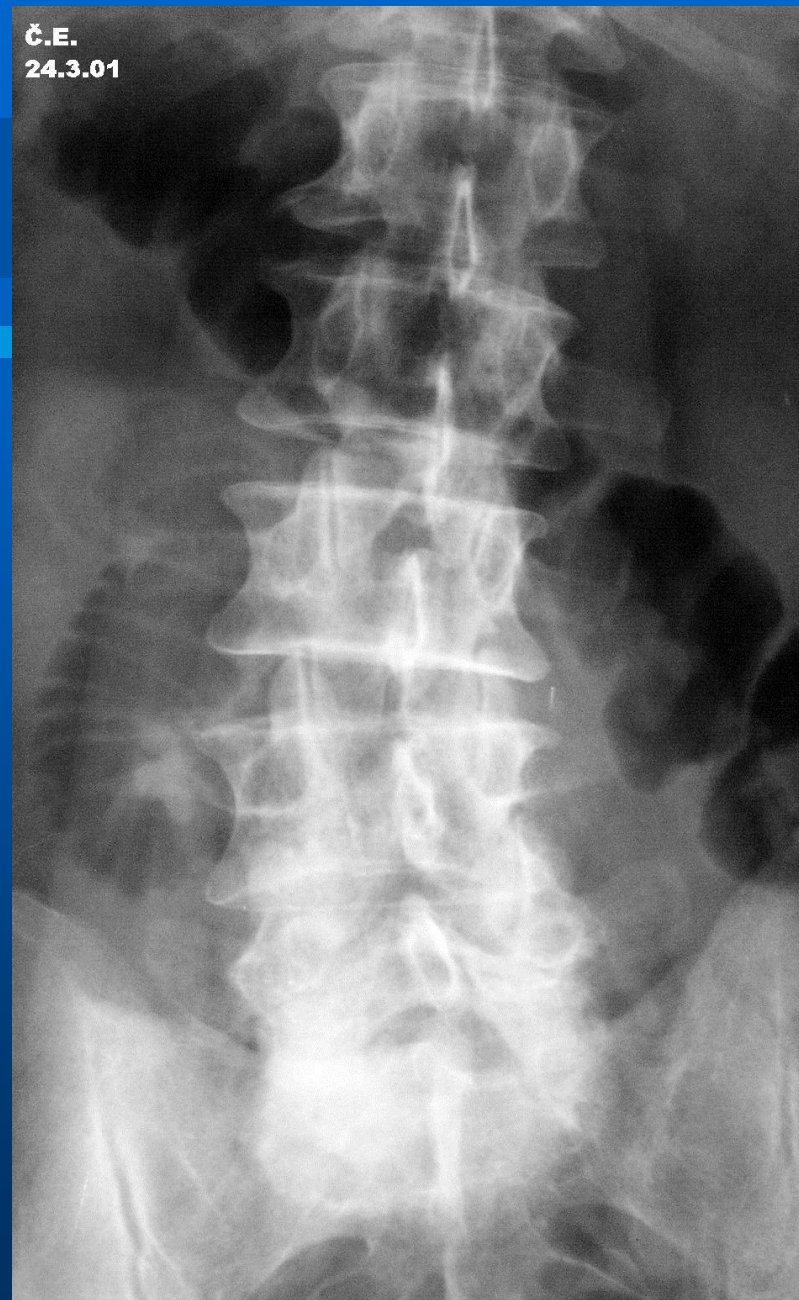Les. Z.
20.7.98 48+4
op 2+1

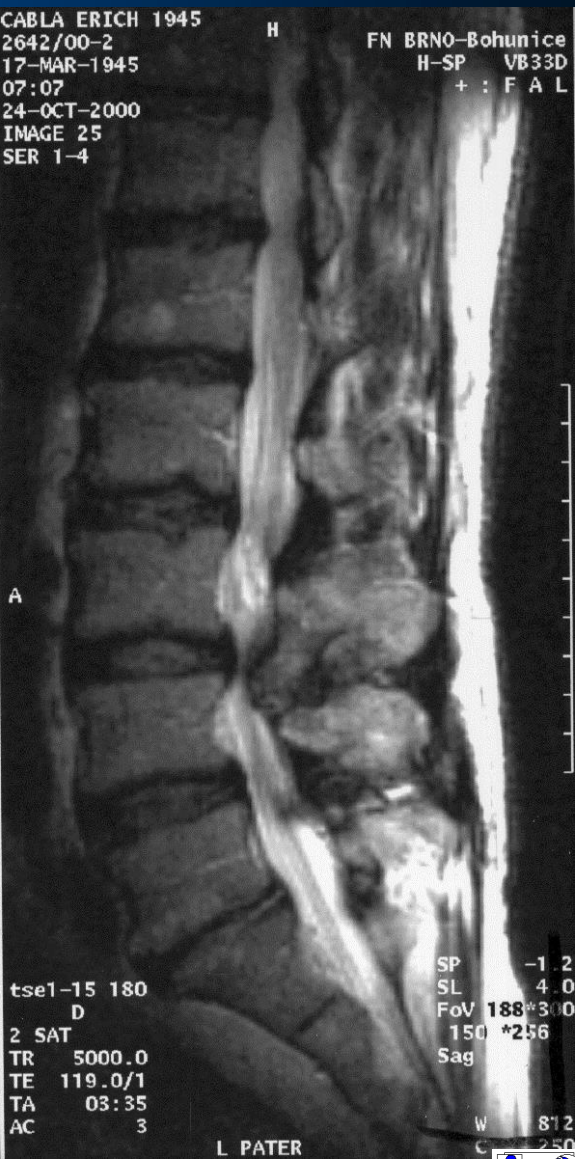
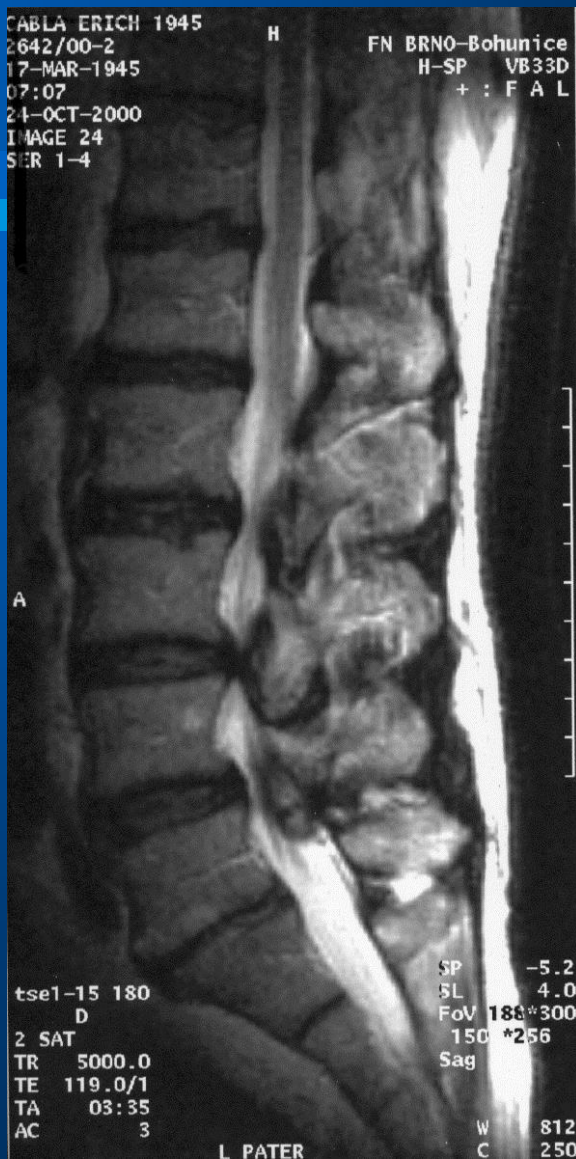
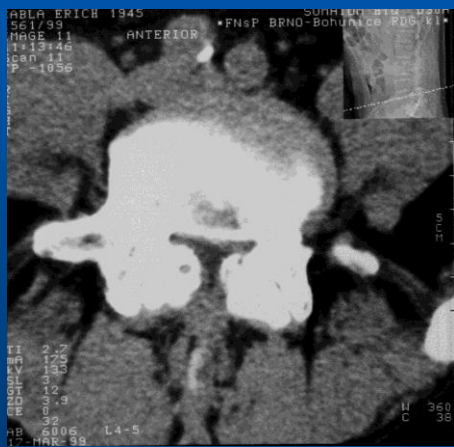
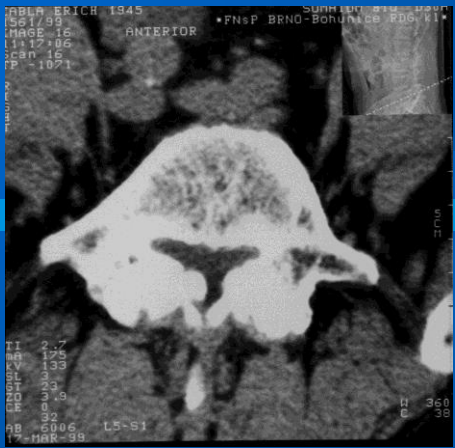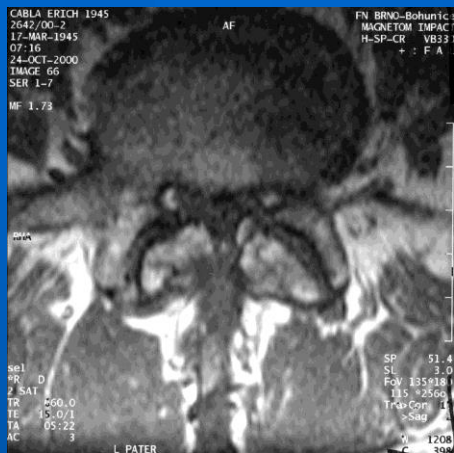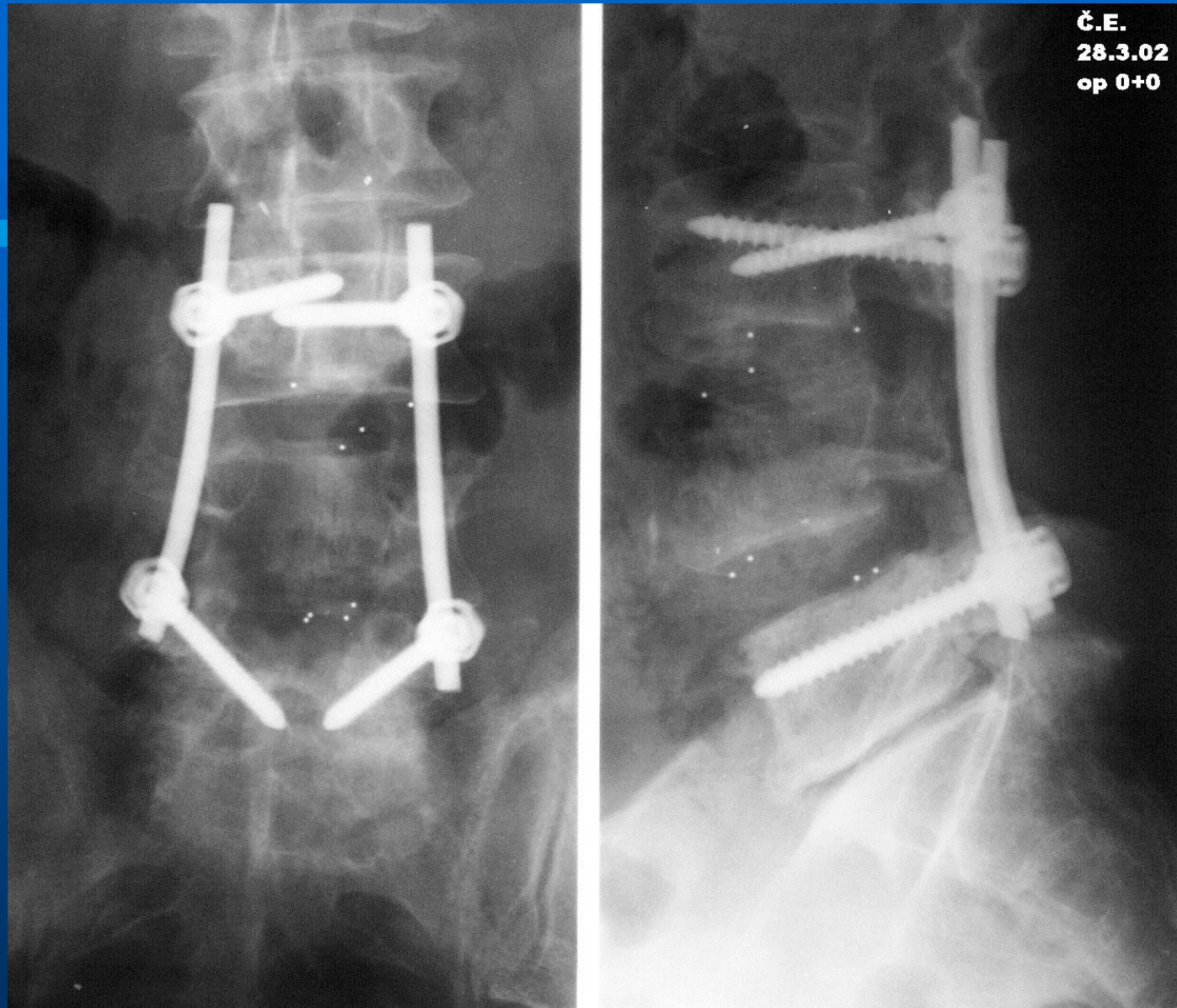Č.E.
24.3.01



Č.E.
24.3.01







Complications

- dural sac tears, root injury
- wound infection
- urinary infection, lung embolism
- ament delirant syndrome
- late - instability above fusion

Results of surgeries

Katz et al. 1997 improved 85%

Airaksinen et al. 1977
improved 62%

Conclusion

- conservative management
- surgery – clear diagnosis