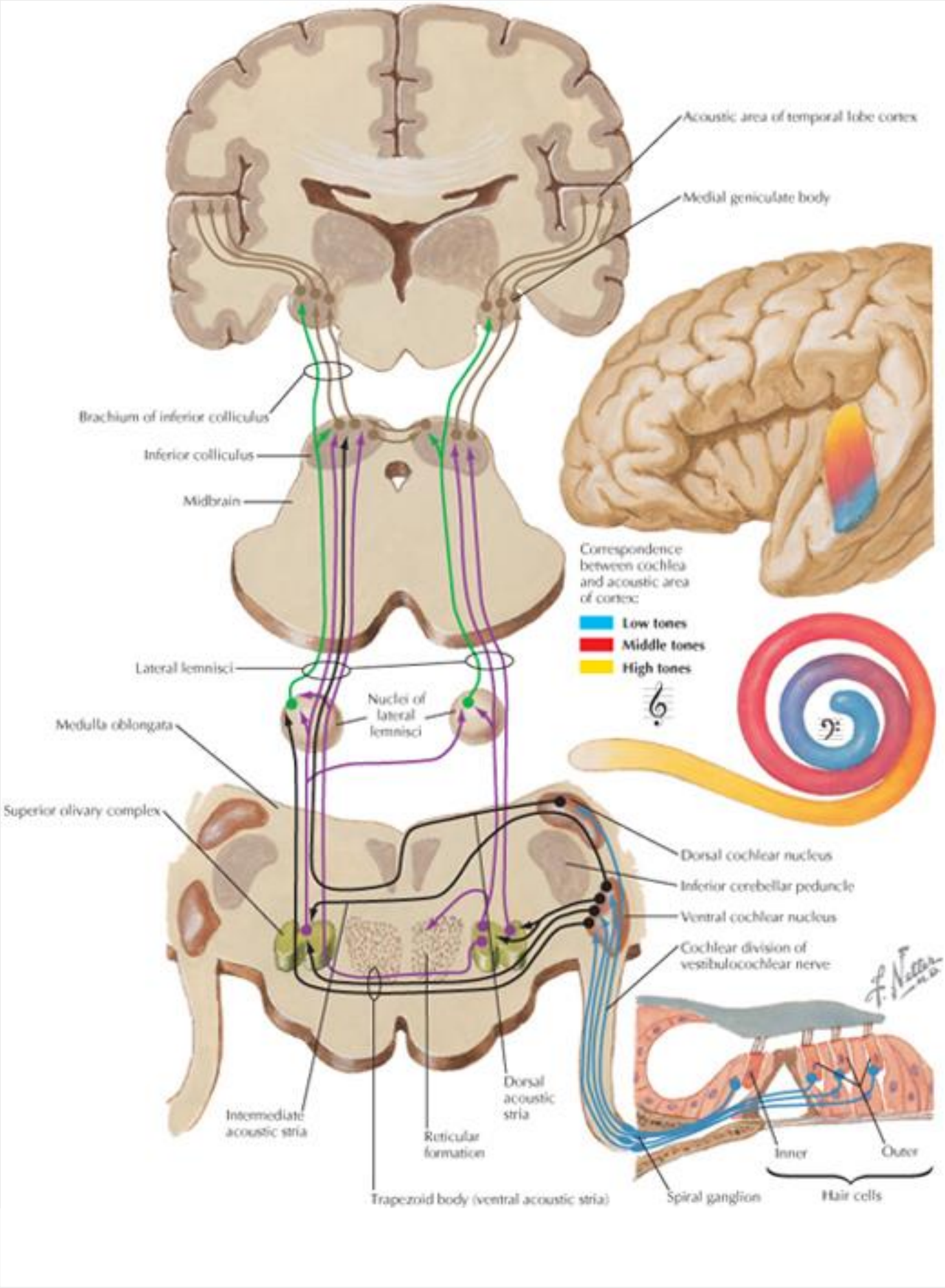
Acoustic area of temporal lobe cortex
Medial geniculate body
Brachium of inferior colliculus
Inferior colliculus
Midbrain
Correspondence between cochlea and acoustic area of cortex
Low tones
Middle tones
High tones
Lateral lemnisci
Nuclei of lateral lemnisci
Medulla oblongata
Superior olivary complex
Dorsal cochlear nucleus
Inferior cerebellar peduncle
Ventral cochlear nucleus
Cochlear division of vestibulocochlear nerve
Dorsal acoustic stria
Intermediate acoustic stria
Reticular formation
Trapezoid body (ventral acoustic stria)
Inner
Outer
Spiral ganglion
Hair cells