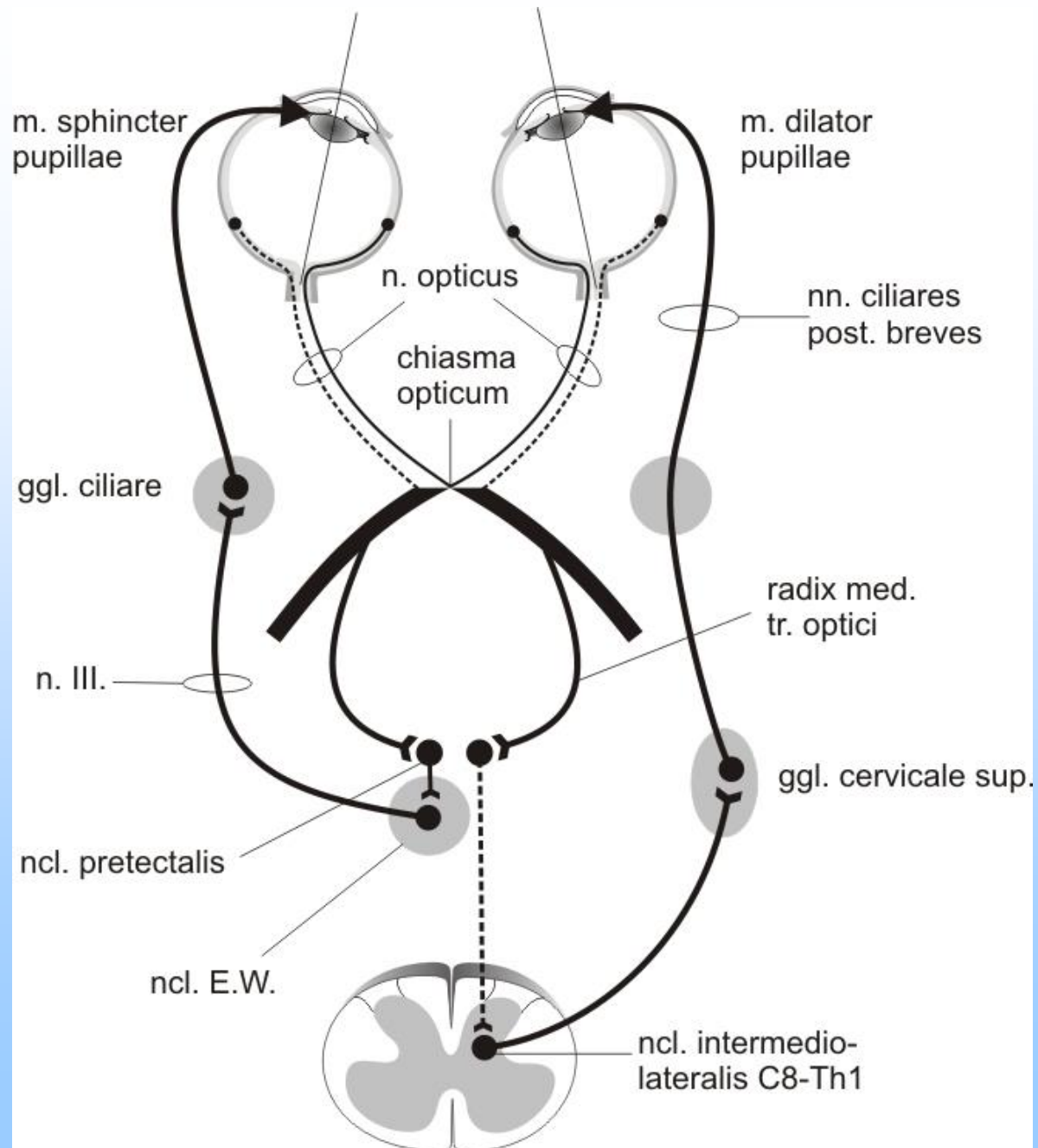


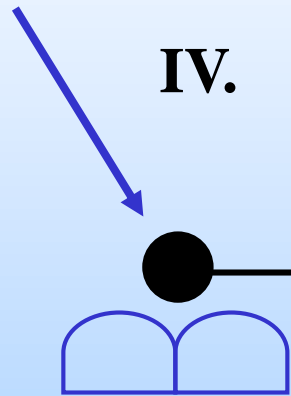
# PUPILLARY LIGHT REFLEXES



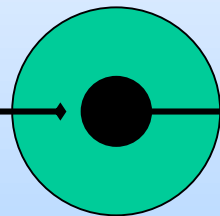
# PATHWAY FOR PUPILLARY LIGHT REFLEX - miosis

## I.-III. neuron - retina

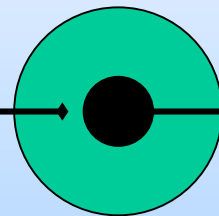
radix medialis  
tracti n. optici



IV.

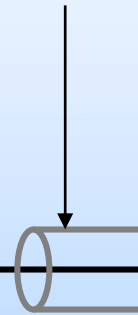


V.



VI.

nn. ciliares post. breves



ncl. preectalis

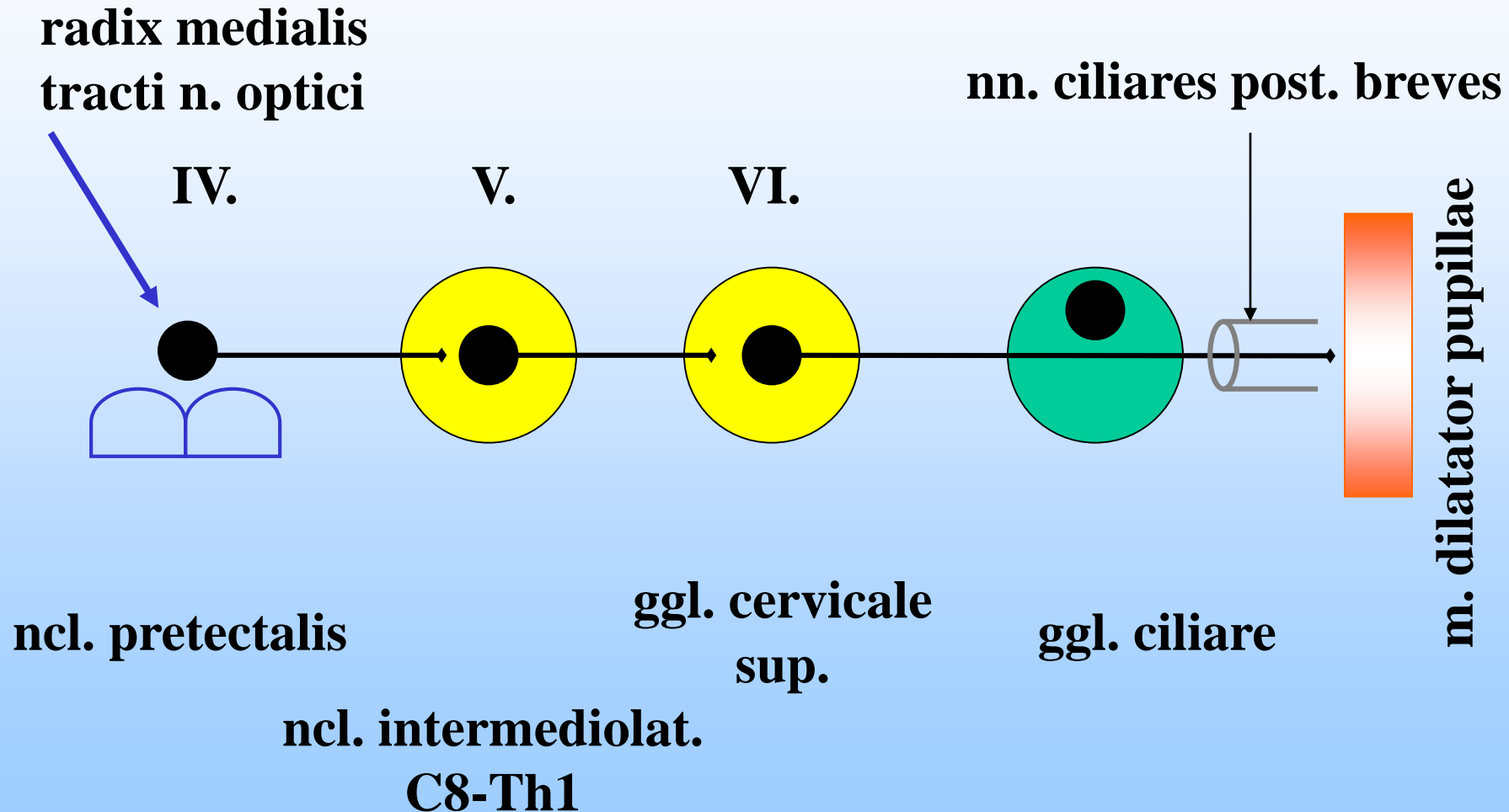
ncl. E.W.

ggl. ciliare

m. sphincter pupillae

# PATHWAY FOR PUPILLARY LIGHT REFLEX - mydriasis

## I.-III. neuron - retina



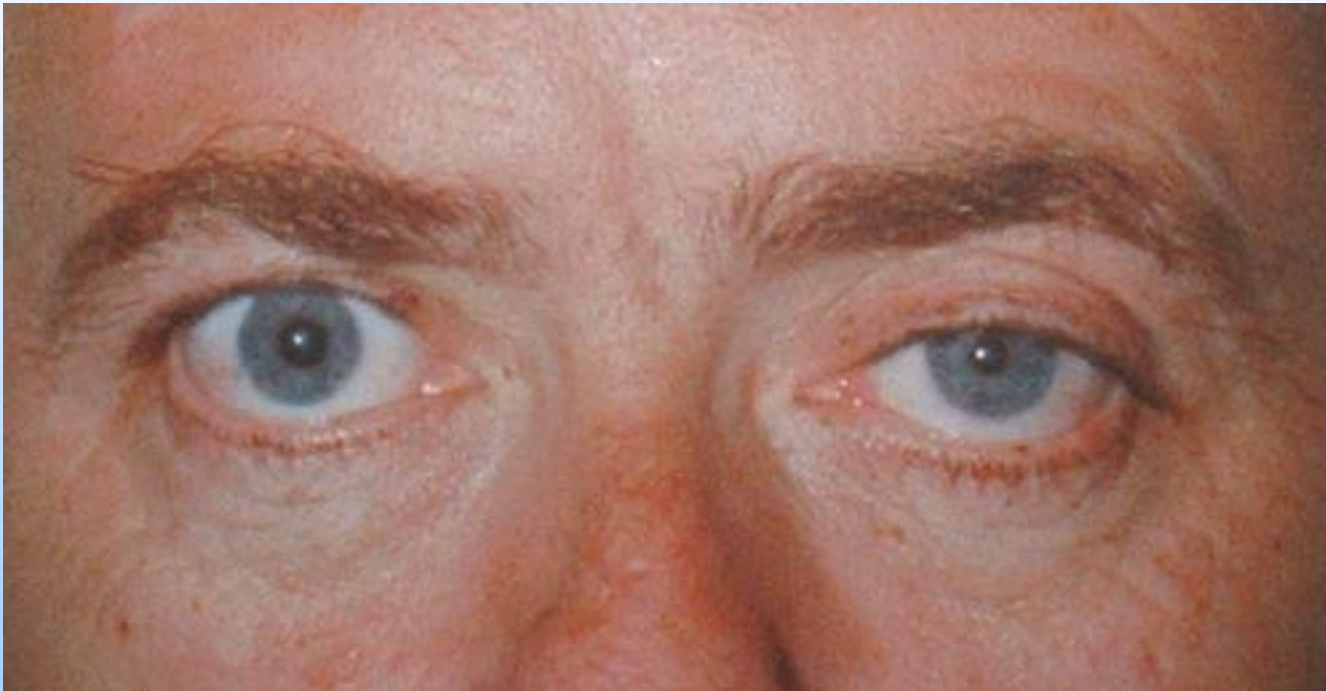# Horner's syndrome

## Horner's triad:

**miosis**

partial ptosis (a weak, droopy eyelid)

enophthalmos (inset eyeball)



the lesion of the cervical sympathetic trunk, preganglionic as well as postganglionic (plexus caroticus)

- Budgeova ciliospinálního centra

# ACCOMODATION PATHWAY

## Cortex/Visual pathway

