

Expressing positions in medical terminology

By Denzel Gordon, Hiromasa Hideshima, Tonje Hem

March 2017

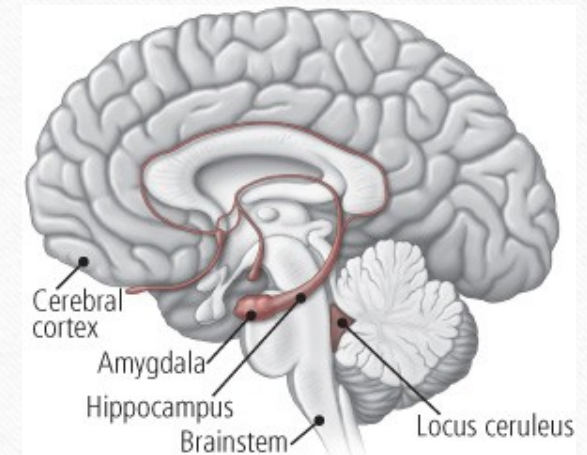
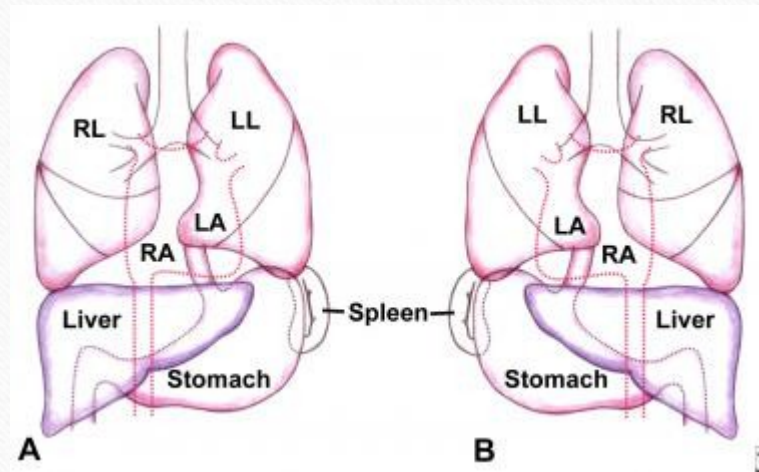
General terms

- Locus, i, m. (more specific – *locus caeruleus*)/ Situs, us, m (more abstract – *situs inversus*)
- topo- (Greek prefix)

e.g. **topophobia** = fear of a certain place or situation, e.g stage fright

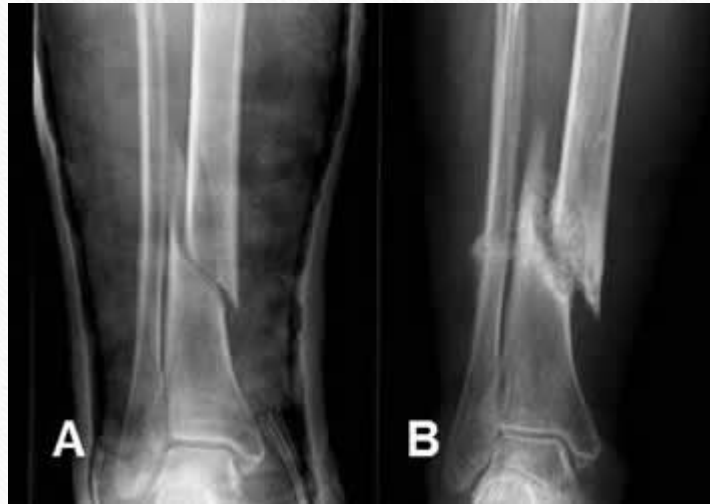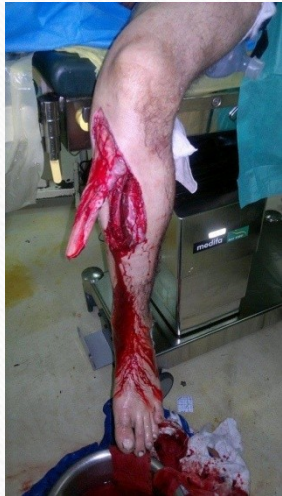Situs inversus totalis

Locus caeruleus

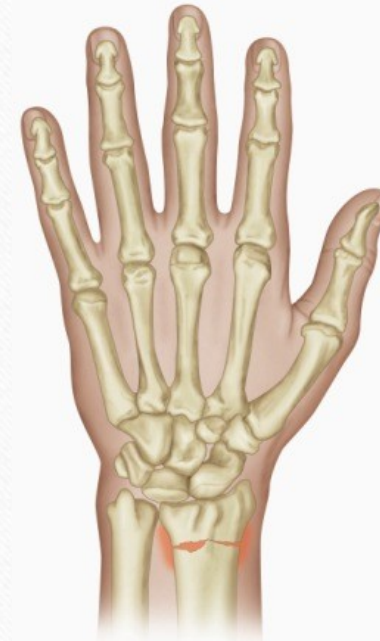

- In situ = in the (afore-mentioned) place
- Loco typico = in the typical place (where it is usual to get an injury)

Fractura tibiae in situ

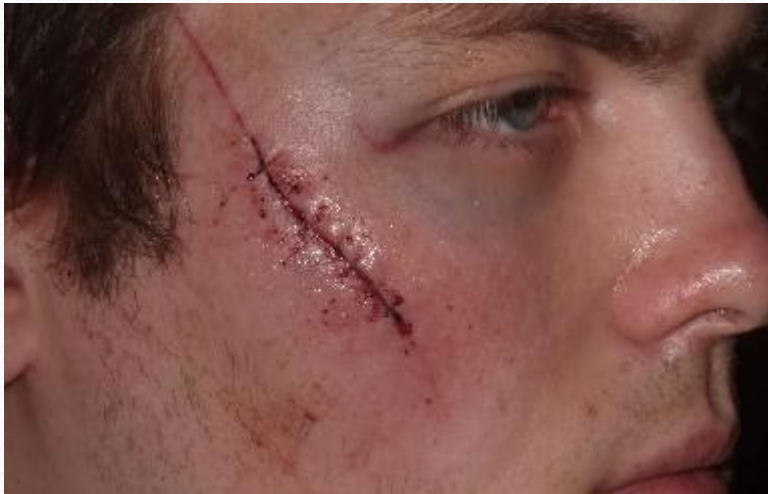

Fractura radii loco typico

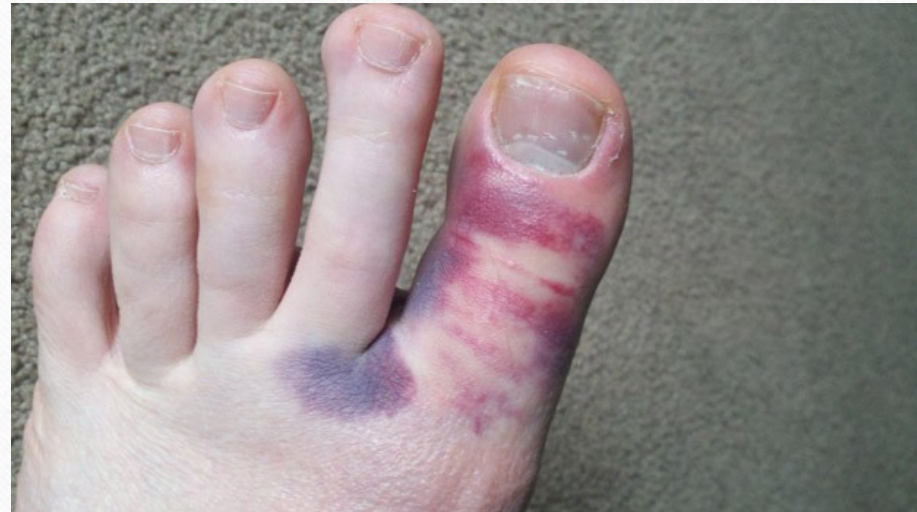

- Loco cicatricis = in the place of the scar (cicatrix, icis, f = scar)
 - Eodem loco = in the same place
-

Curatio loco cicatricis

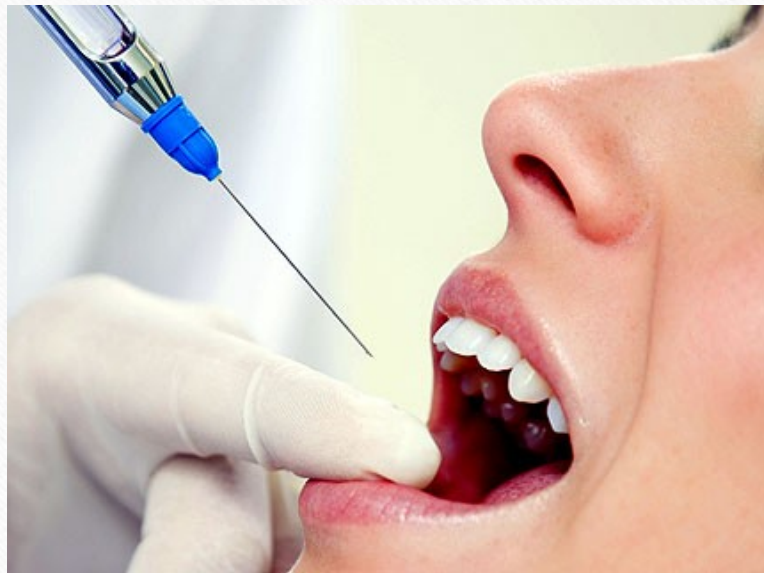

Fractura hallucis et contusio eodem loco

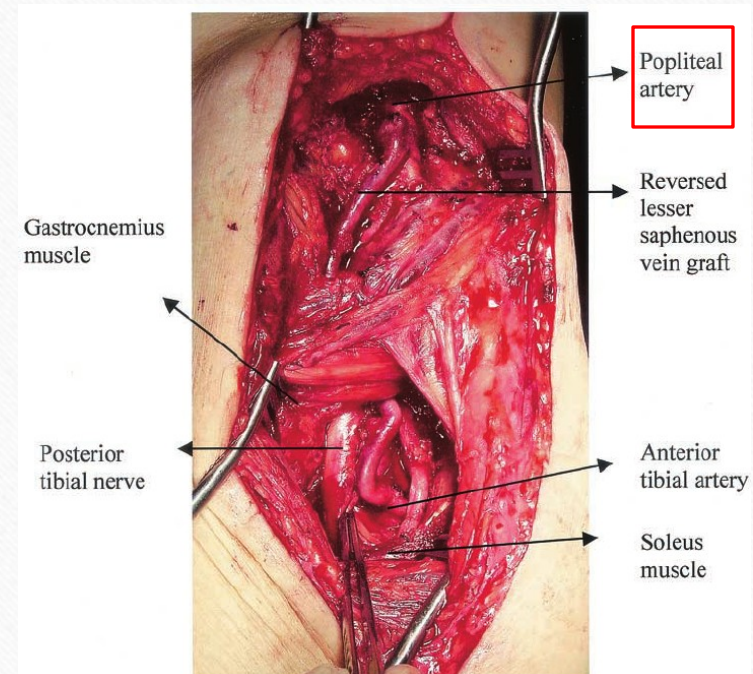


- Localis, e = local
- Positio, onis, f = position, location

Anaesthesia localis



Positio arteriae popliteae



Lateral position

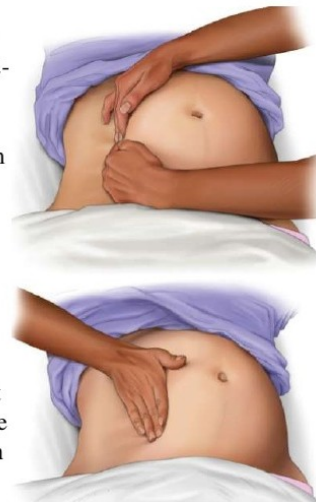“Later” - prefix

- Relates to the side – ‘lateropositio’ a shift to one side or displacement to one side. *Lateropositio uteri.*

- Left uterine displacement - patient's left side with the 2-handed technique

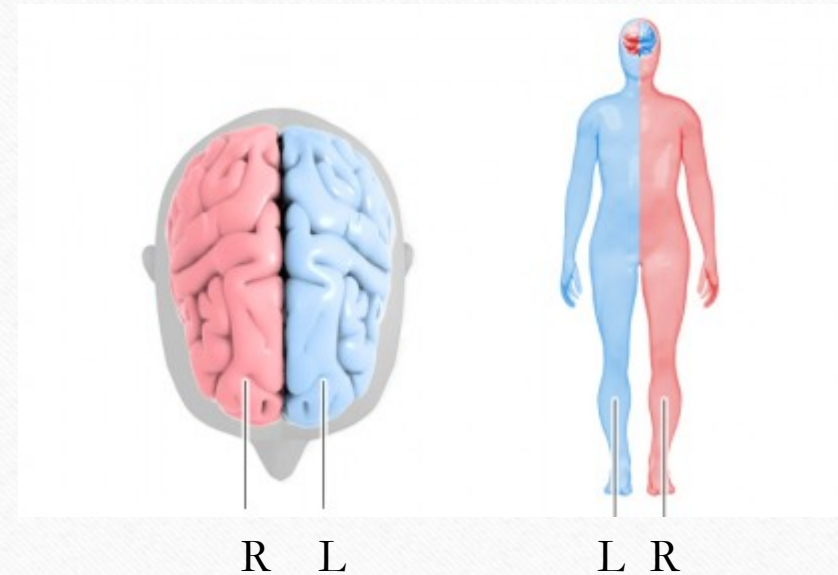

- The patient's right side with the 1-handed technique, depending on the positioning of the resuscitation team.

- If chest compressions remain inadequate after lateral uterine displacement or left-lateral tilt, immediate emergency cesarean section should be considered.



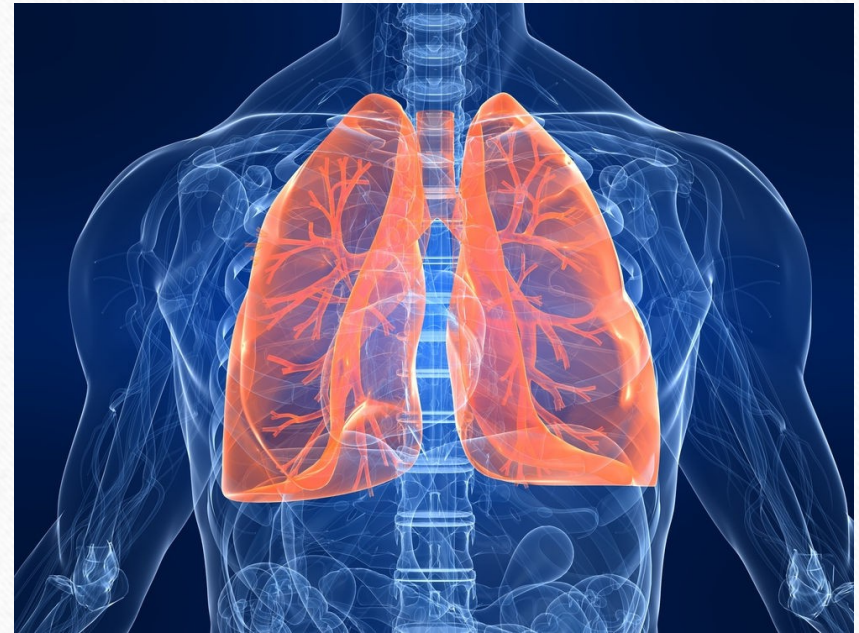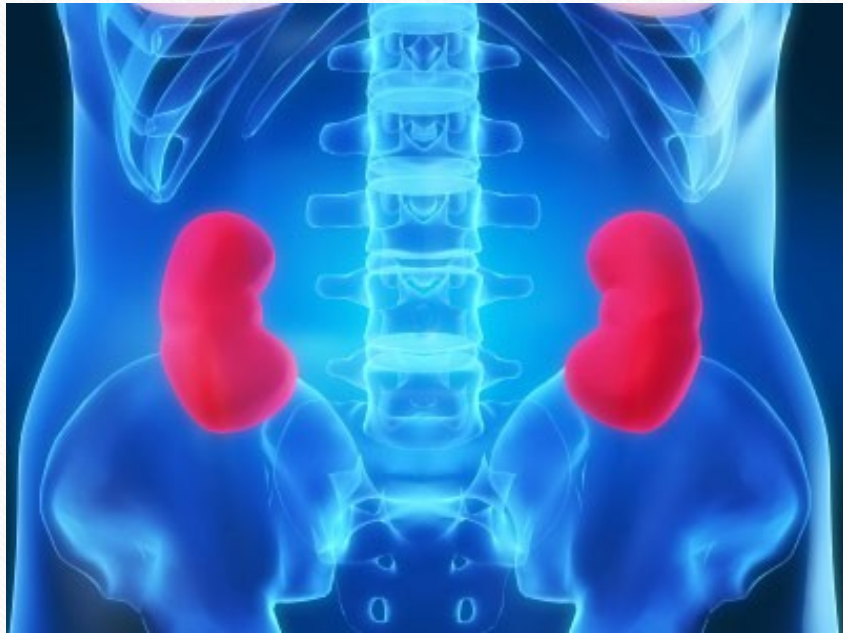Lateris dextri (l.dx), Lateris sinistri (l.sin)

On the right side – the right one, On the left side – the left one respectively



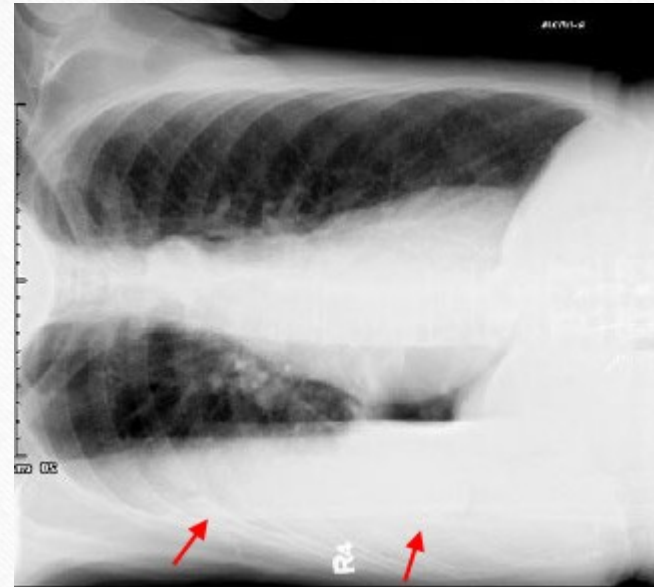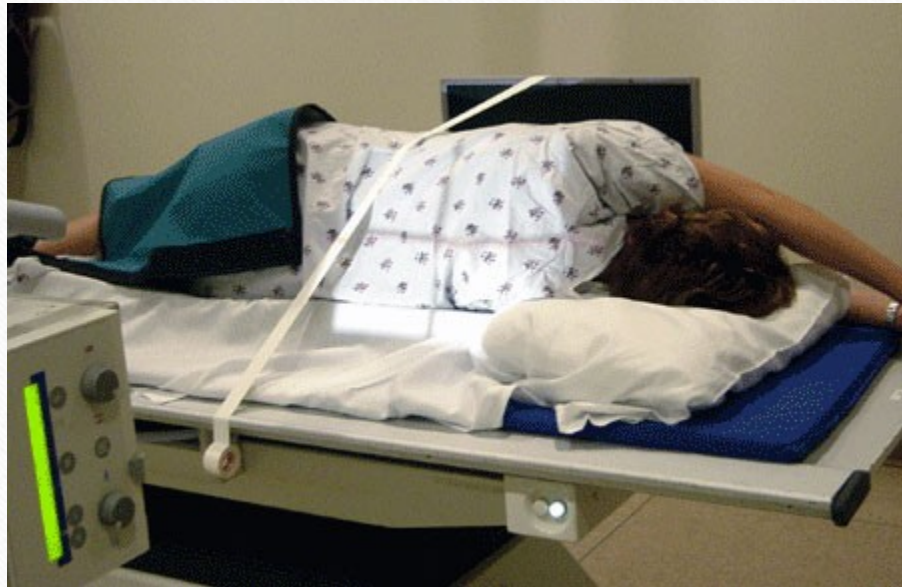Lateris utriusque (l.utr)

On both sides



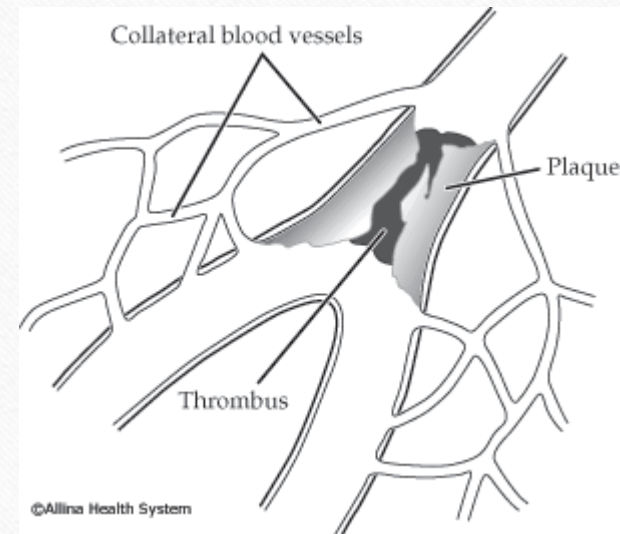
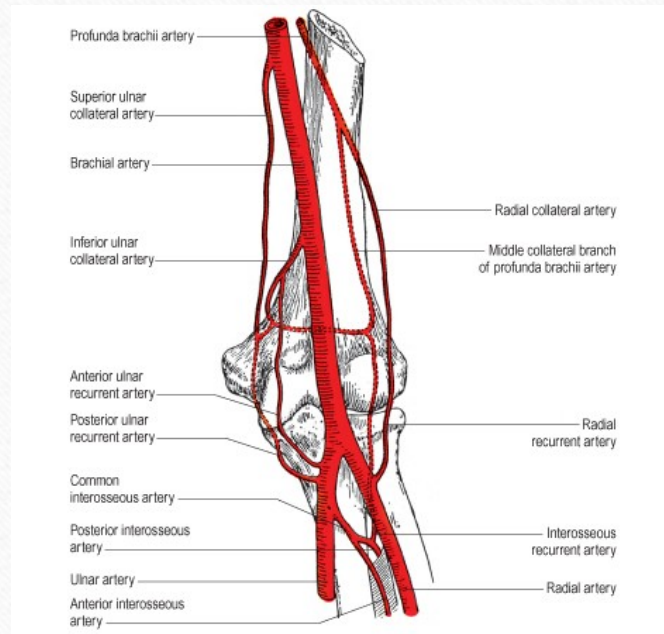
Bi-lateralis, e

Bilateral: E.g. *Decubitus bilaterales* = bilateral bedsores/pressure ulcers



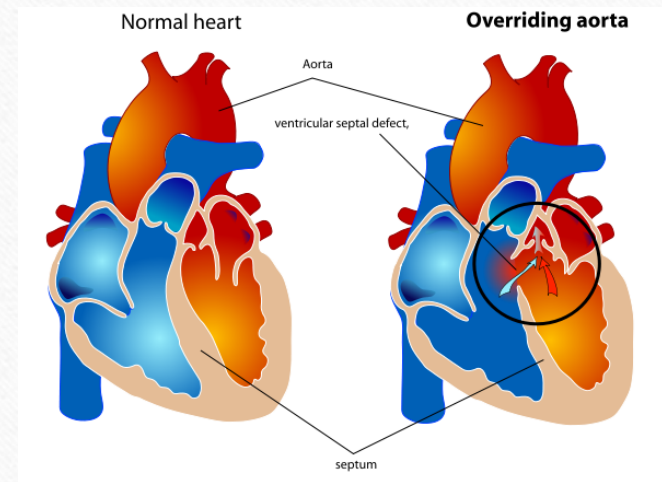
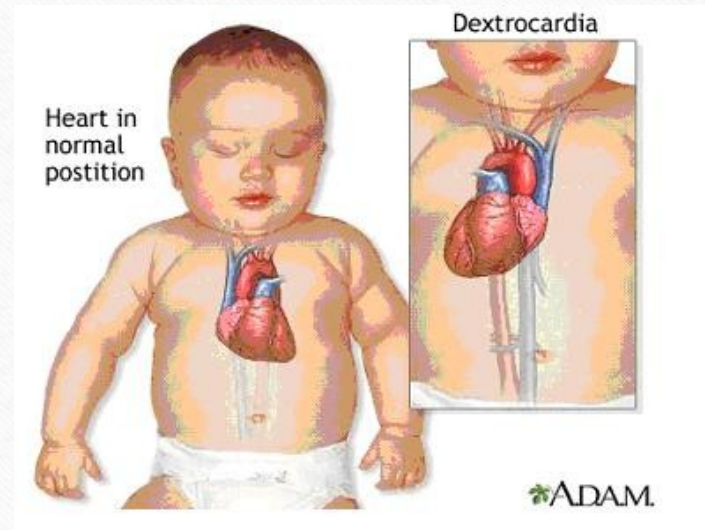
Collateralis, e

- Located on the same side, eg. *arteria collateralis*



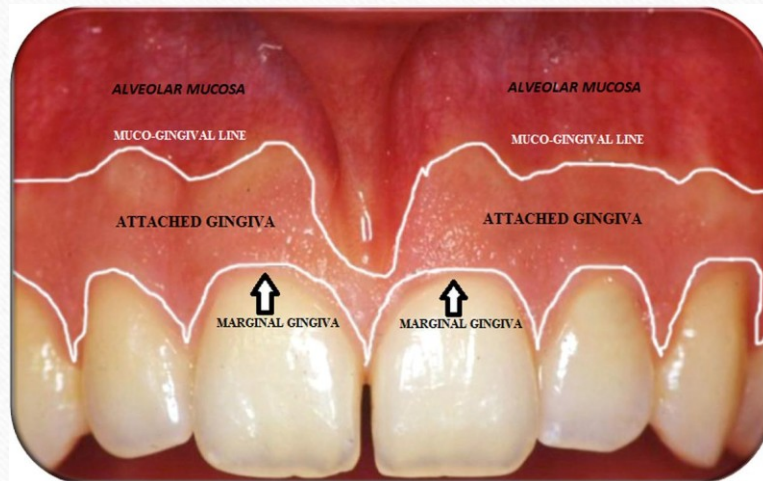Sinistro-/dextropositio

- Reversal of an organ to the left /right – sinistro/dextroposition of the heart. Can be described as a congenital anomaly in which an anatomically correct heart is displaced to the right in the thoracic cavity

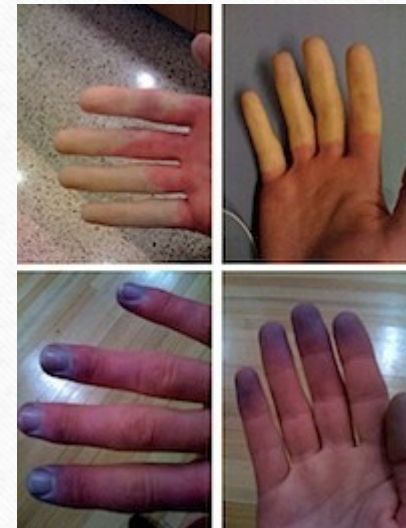

Marginalis, e Acralis, e (G.)

Marginal, eg. *Gingivitis marginalis*. The crest of the free gingiva surrounding the tooth like a collar. It is about 1 mm wide and forms the soft tissue portion of the gingival sulcus.

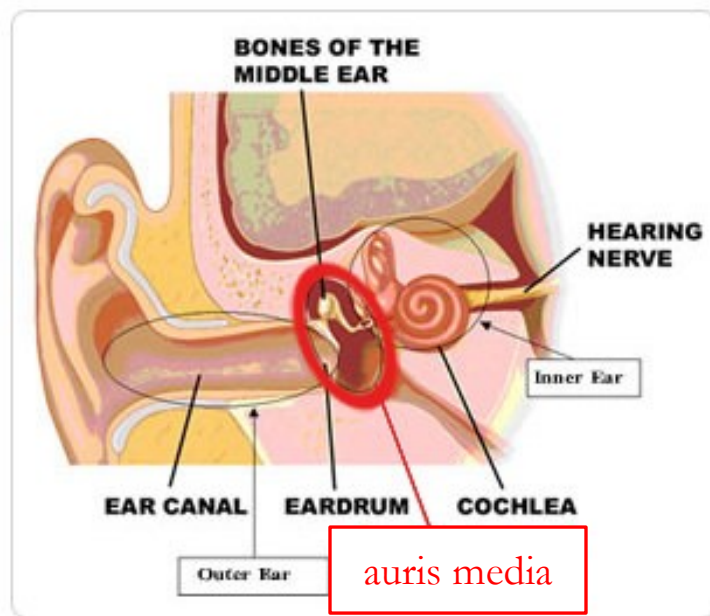


Referring or belonging to extremities of peripheral areas, eg. *Cyanosis acralis*



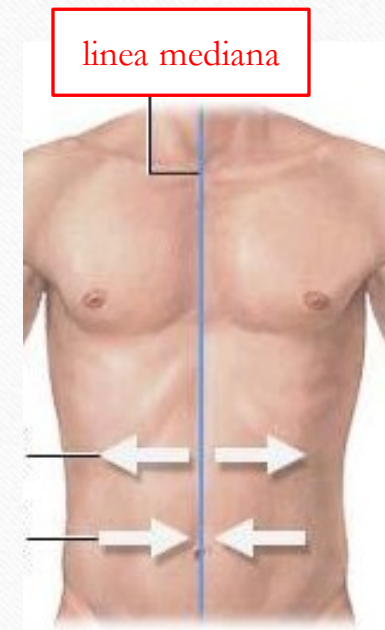
Medial position

Medius, a, um



Medianus, a, um

= exactly in the middle

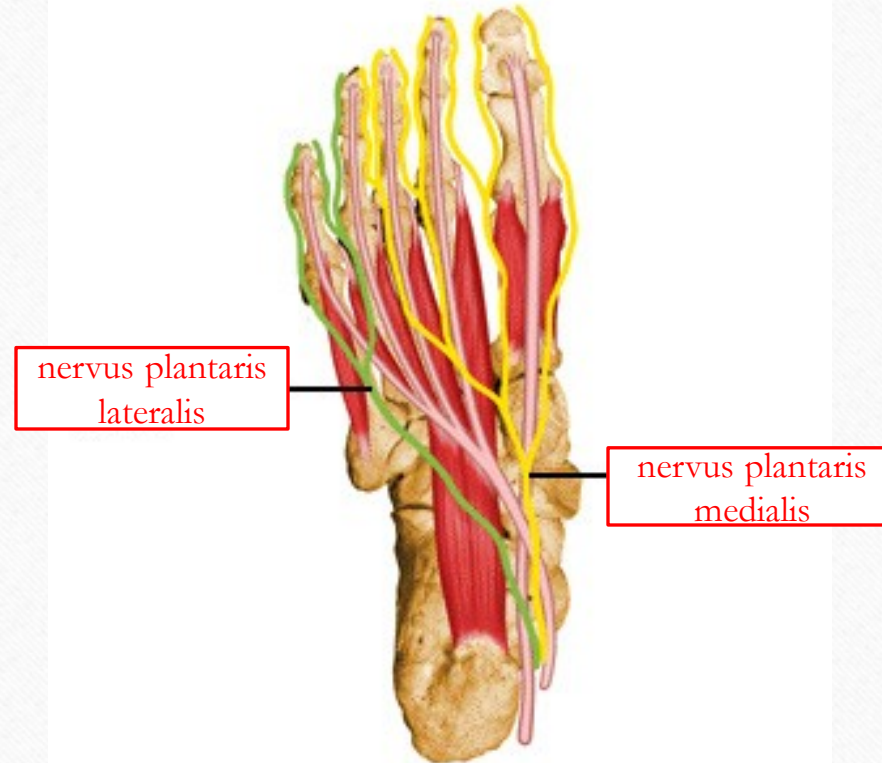


Medialis, e

relating to structures located close to the midline of the body

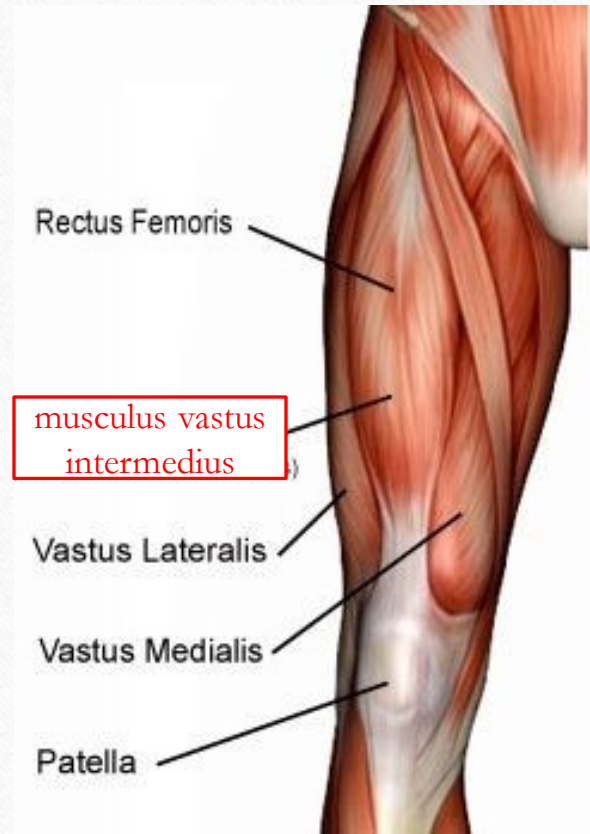
Lateralis, e

refers to structures to the sides (left/right)



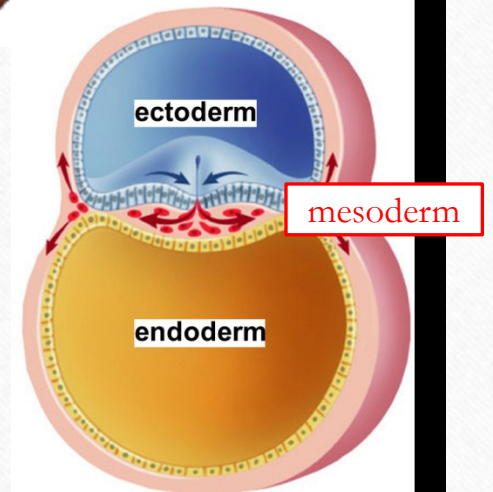
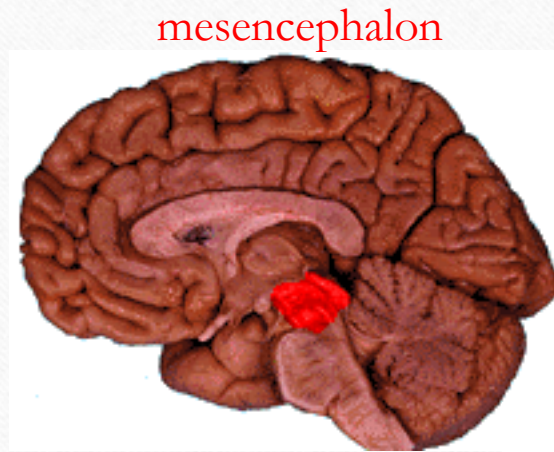
Intermedius, a, um

Located between two things



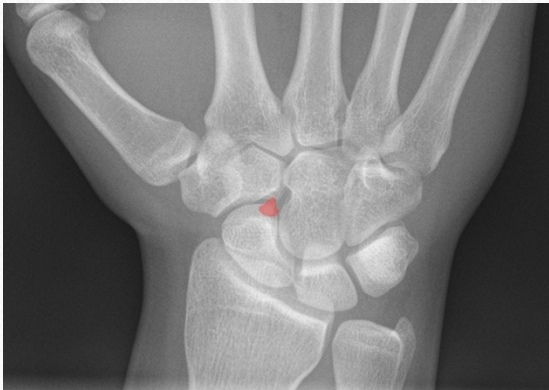Meso- (prefix)

middle, intermediate, halfway

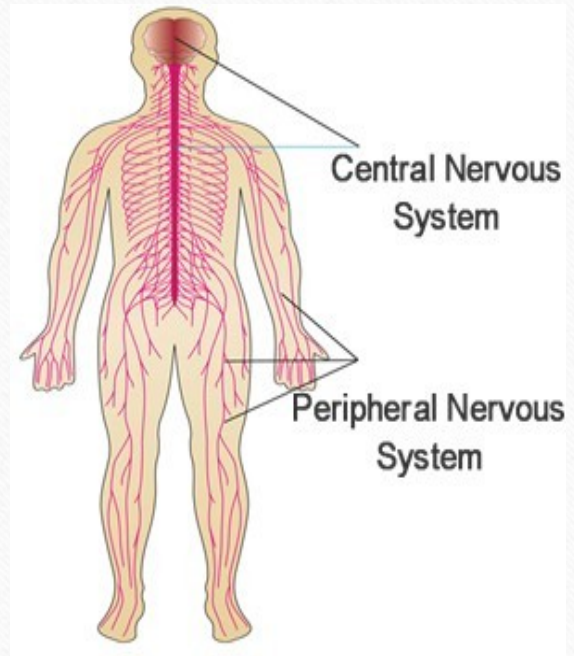


Centralis, e
central

os centrale



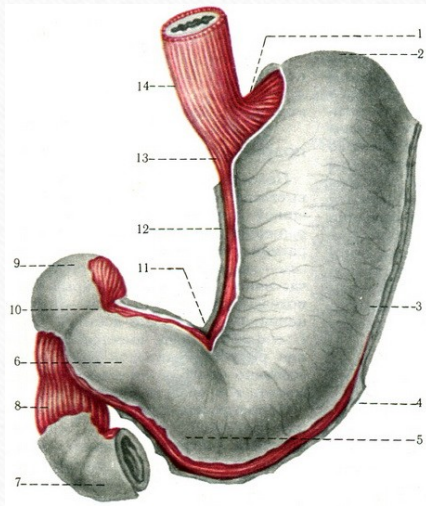
systema nervosum
centrale



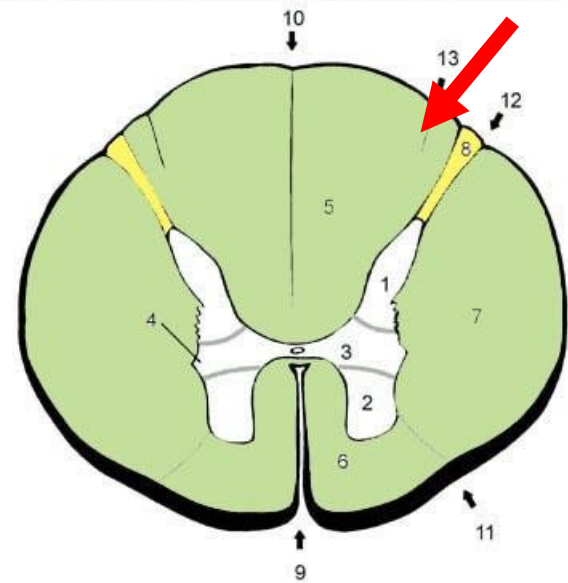
Anterior position/before

- Anterior, anterieus = the position meaning above something (anterius is for neutral gender)
- Antero = prefix meaning before, eg. If you want to give two adjectives (direction) describing position.

Paries anterior gastris



Funiculus anterolateralis



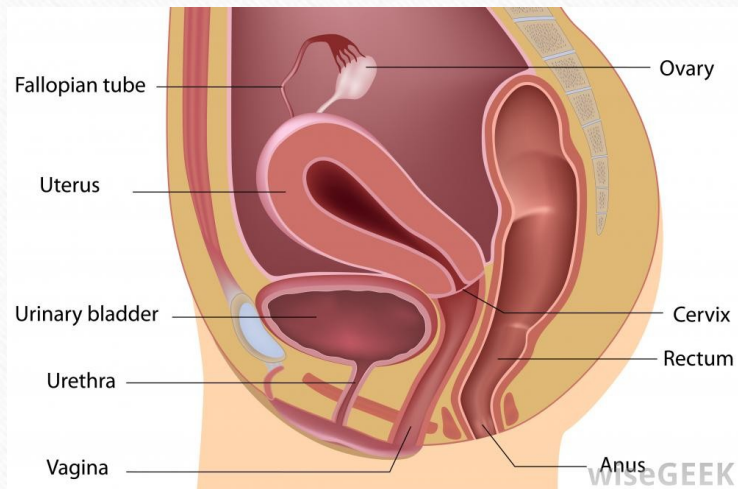
- **Prefixes**

- Ante- = before (position)

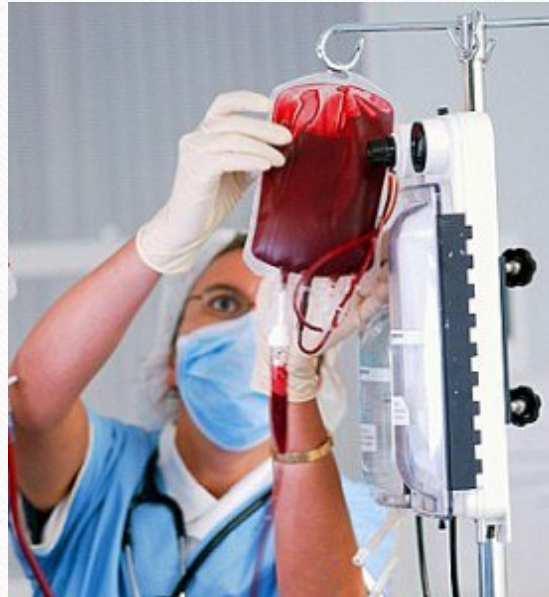- Prae- = before (time)

- Pro- = before (in front of, ie protraction of mandible)

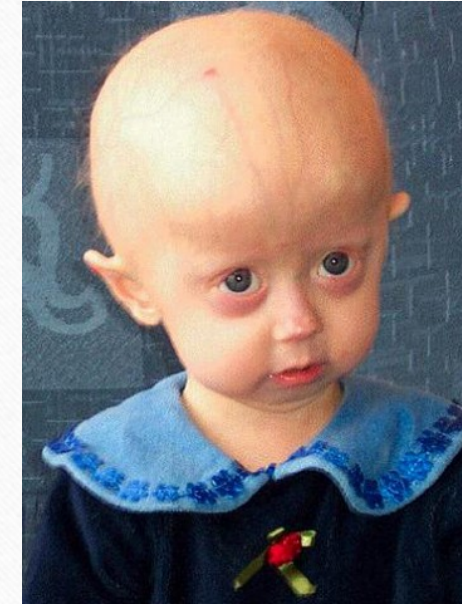Antepositio uteri



Transfusio praeoperativa



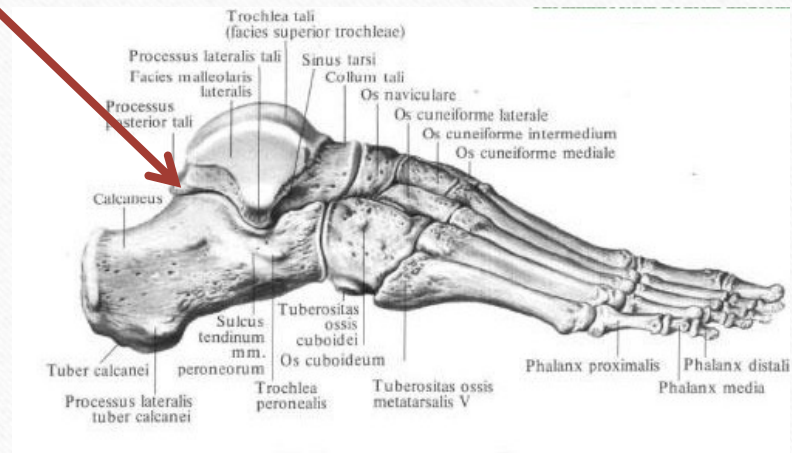
Progeria adutorum



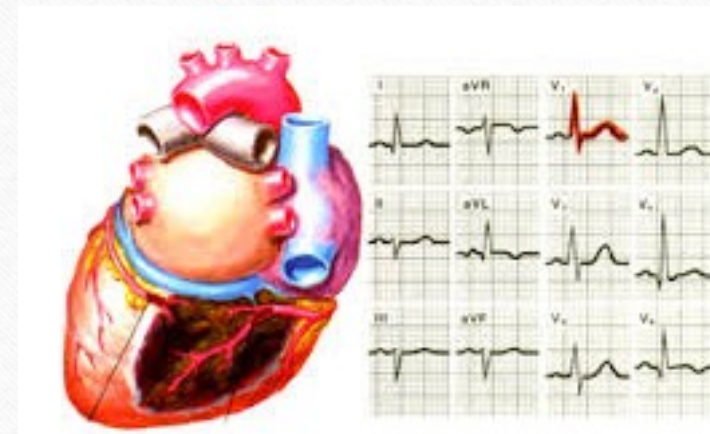Posterior position/after sth

- Posterior, ius (comp. form) – meaning behind or towards rear or dorsal surface of the body.
- (prefix) postero – prefix to mean behind or dorsal end

Processus posterior tali



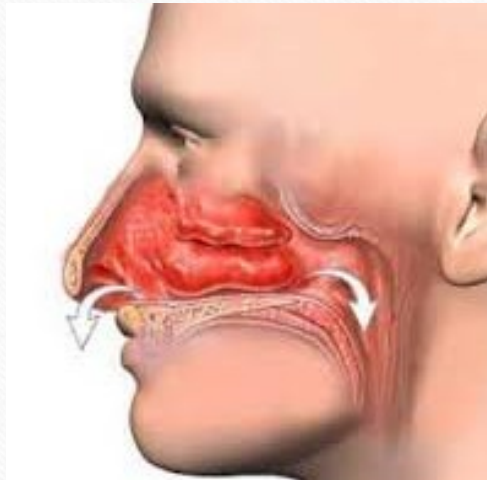
Infarctus posterolateralis



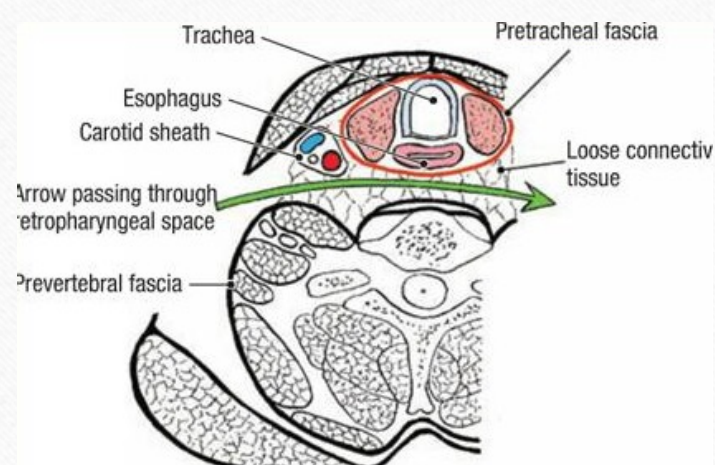
Prefixes

- Post – (L.) - after, behind or later
 - Retro – (L.) – back, backwards
 - Meta – (L.) – along with, among, beyond
-

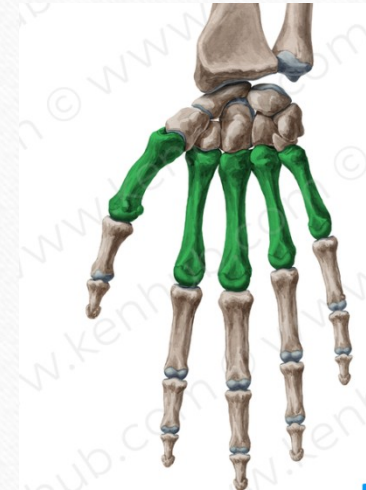
Regio postnasalis



Spatium retropharyngeum

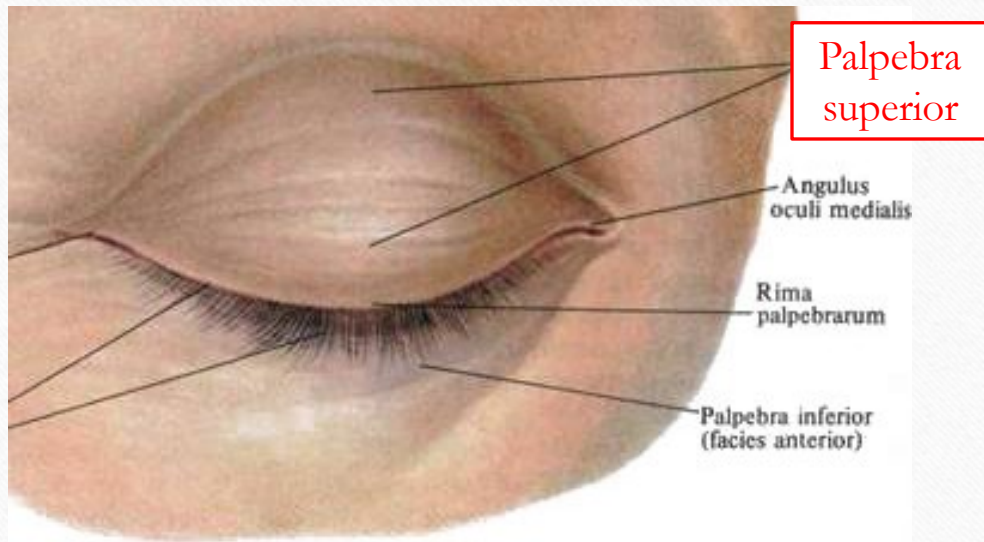


Ossa metacarpalia

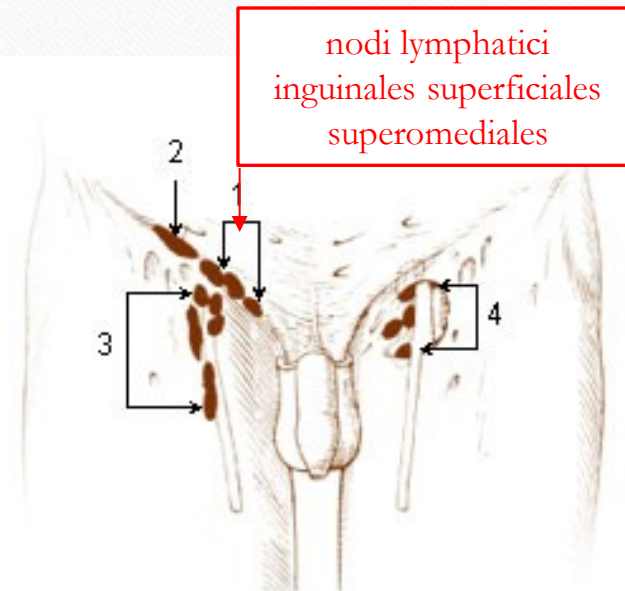


Superior position

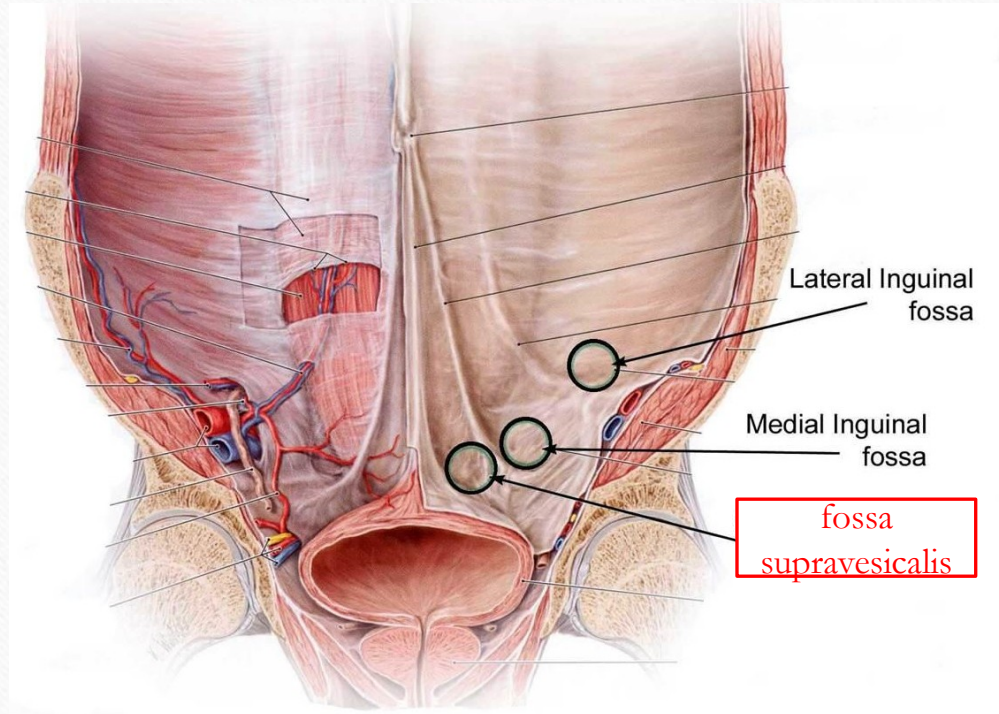
Superior, ius (comp. adj. / adverb)
higher, upper / above



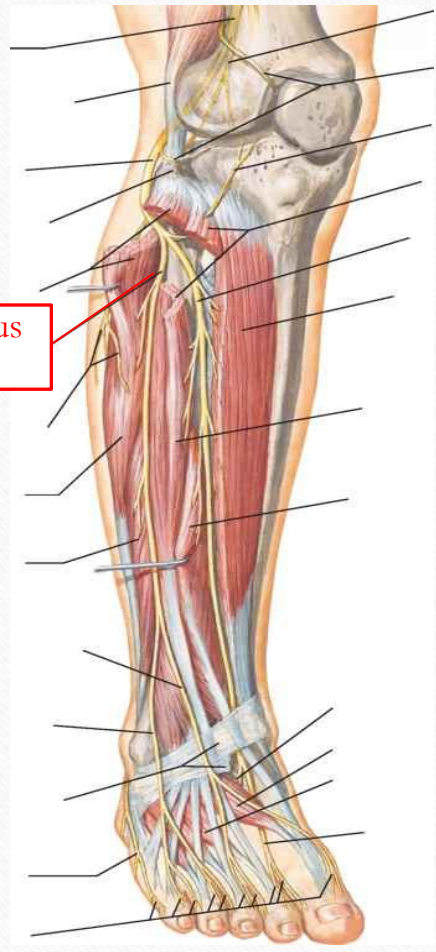
Supero- (prefix)
above, over, beyond



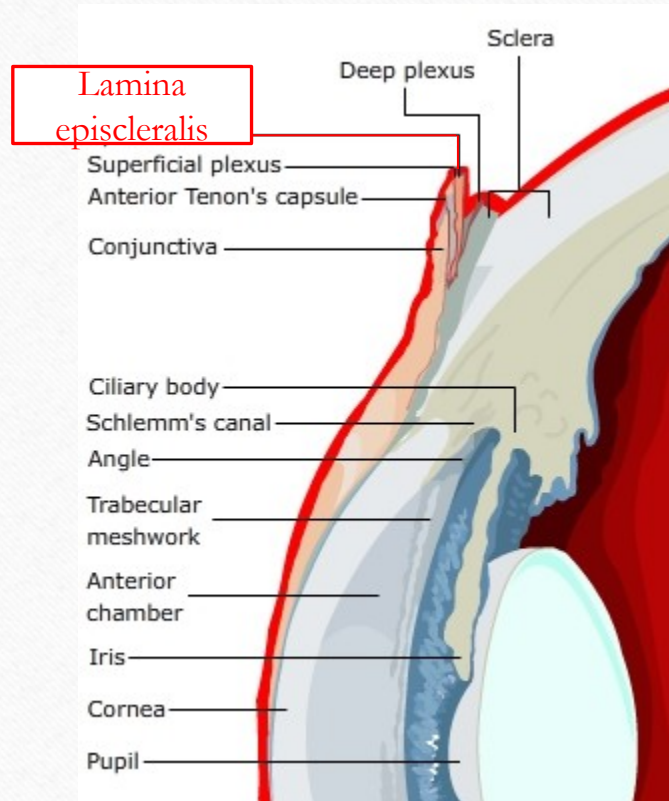
Supra- / Super- (prefix)
over/ on the surface of



nervus peroneus superficialis



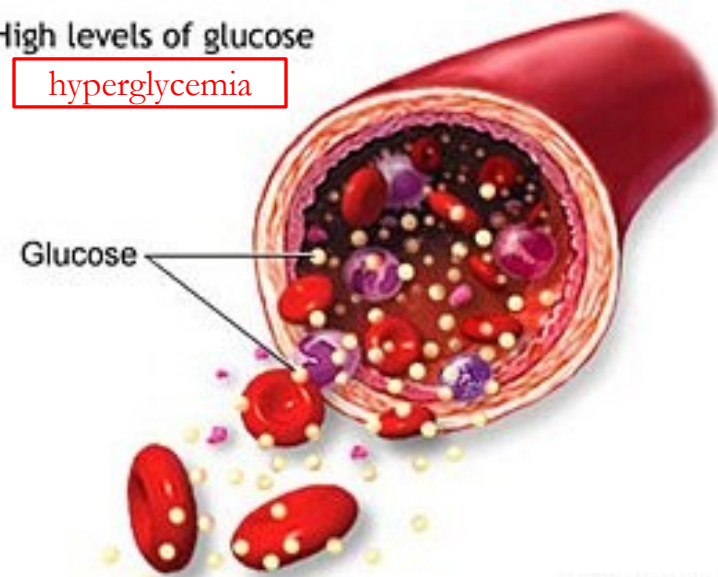Epi- (prefix)
on the surface of



Hyper- (prefix)
over, above, excessive

High levels of glucose

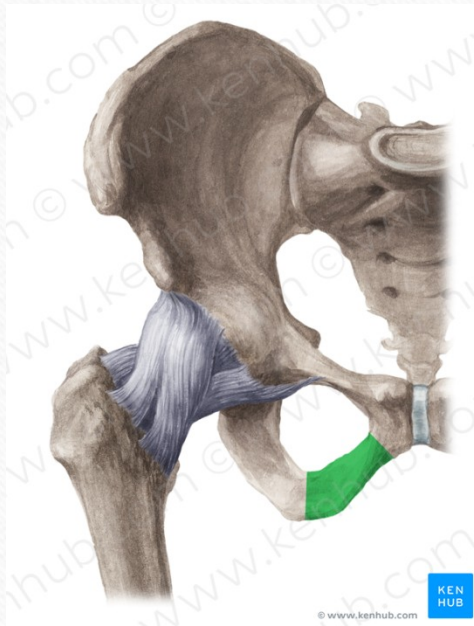
hyperglycemia



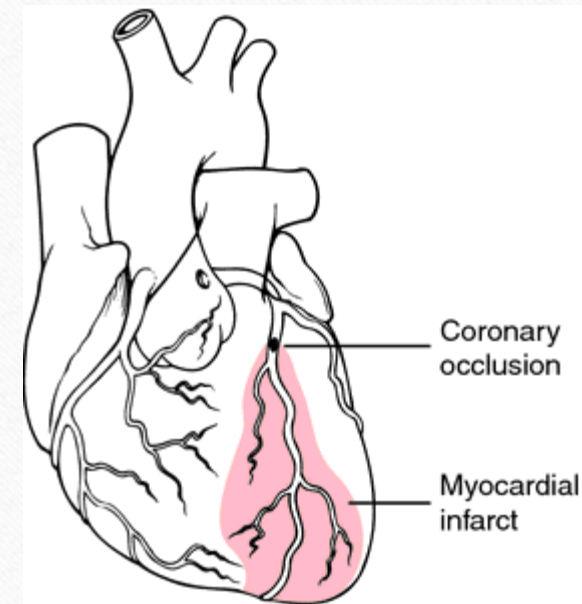
Inferior position

- Inferior, ius = beneath/inferior to (comparative, inferius is for neutrals)
- Infero- = position when using several adjectives (prefix)

Ramus ossis pubis inferior

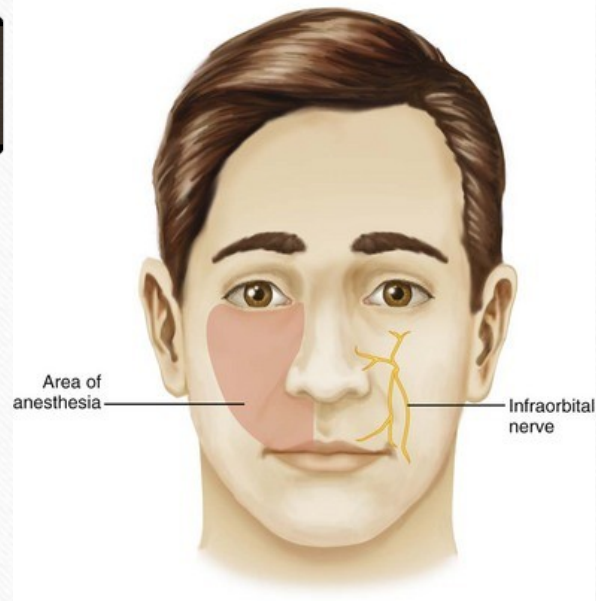


Infarctus inferoposterior

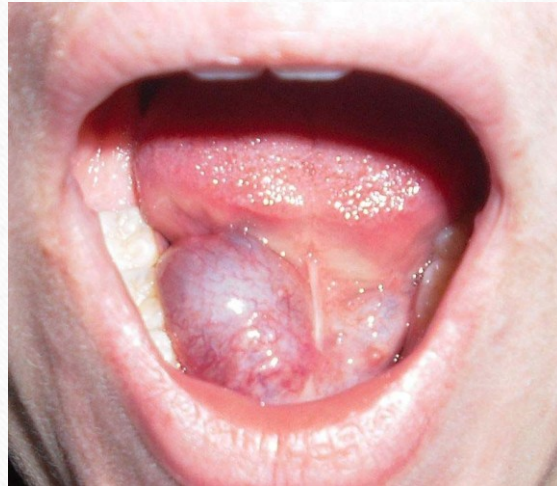

- **Prefixes**
- Infra- = when describing location
- Sub- = below describing location
- Hypo- = rarely used to describe location

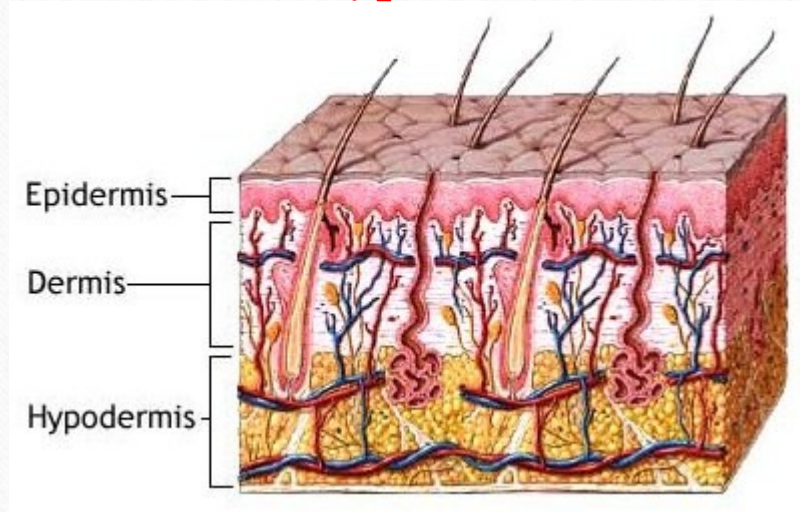
Nervus infraorbitalis



Glandula sublingualis



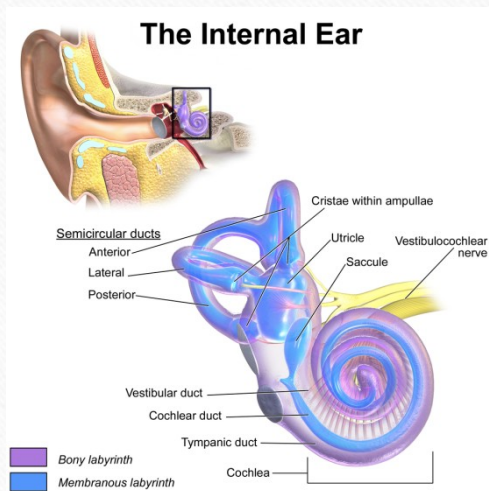
Hypodermis



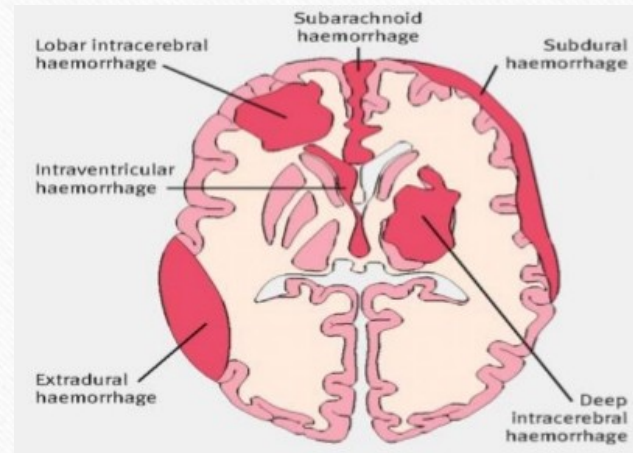
Internal position

- Internus, a, um - internal, deep, inward
- (prefix) Intra (L.) - between, within
- (prefix) endo (G.) – inside, within

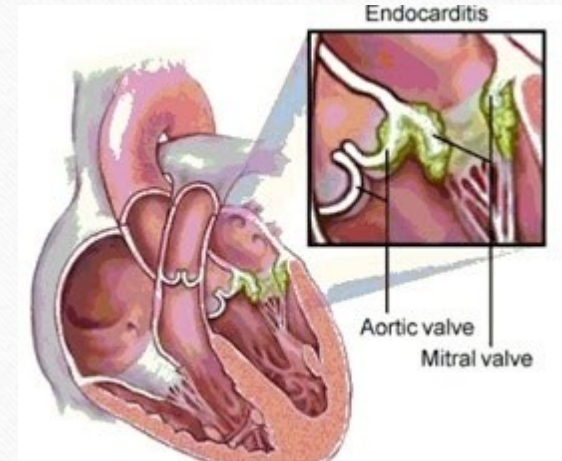
Auris interna



Haemorrhagia intracranialis

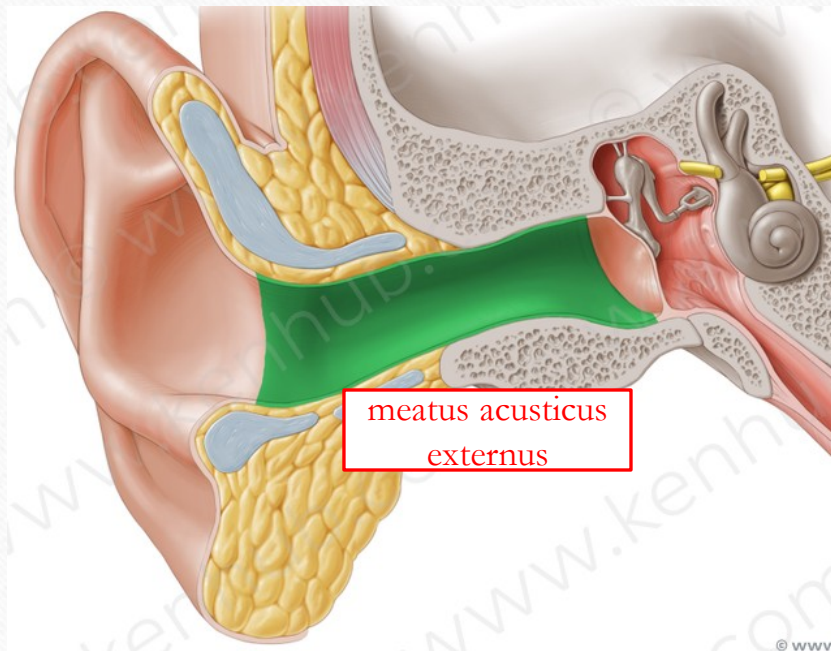


Endocarditis



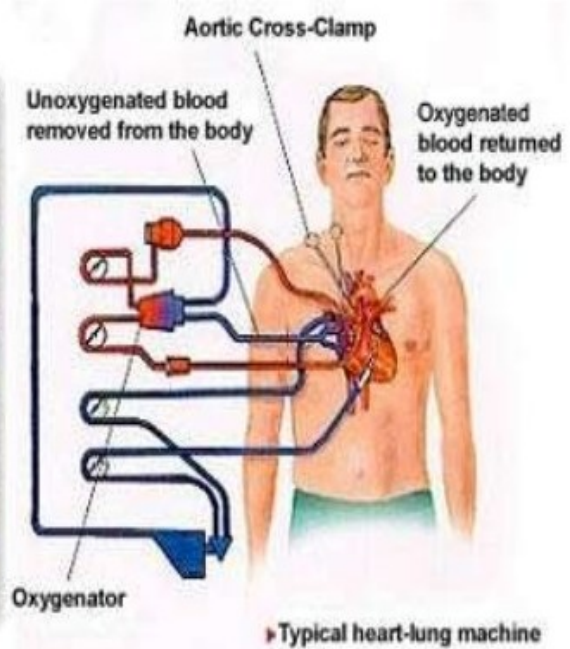
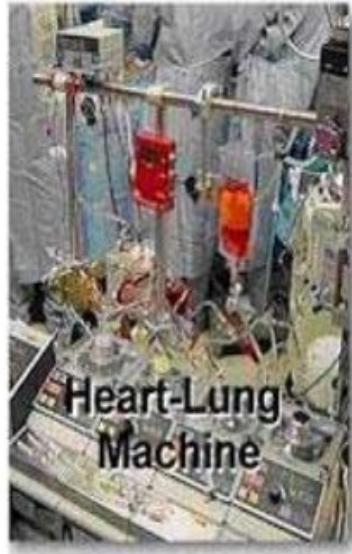External position

Externus, a, um
external



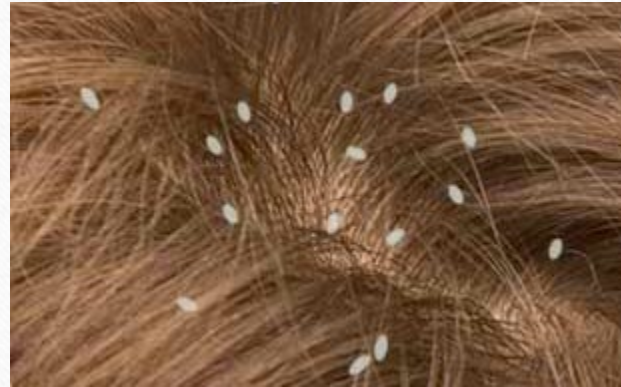Extra- (prefix)
outer

Circulatio extracorporalis

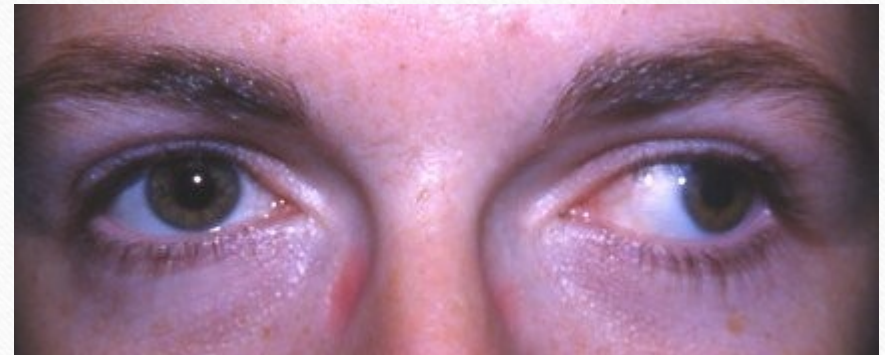

Ecto- / Exo- (prefix)
outside

ectoparasitus



exotropia



Translate from Latin to English

- Nervi supraclaviculares mediales
- Septum intermedium
- Venae superficiales membri superioris
- Venae episclerales
- Ductus sublingualis major

Answers

- Nervi supraclaviculares mediales
- Medial supraclavicular nerves

- Septum intermedium
- Intermedial septum

- Venae superficiales membri superioris
- Superficial veins of upper limb

- Venae episclerales
- Episcleral veins (small veins in the sclera in the corneal margin)

- Ductus sublingualis major
- Major sublingual duct

Revision Questions

(by Akimasa Iijima and Ole Victor Hesse)

1. Translate “in typical location” = Loco typico
2. Translate “local anesthesia” = Anaesthesia localis
3. Original form and translation of “l. utr.” = lateris utriusque
4. Translate “pain of bilateral hand” = dolor manus bilateralis
5. Translate “in the middle ear” = in aure media
6. Create adjective using prefix of “anterior” and “lateral”
Anterolateralis, e

Revision Questions

7. Which of following prefixes does not represent posterior/after?
 - a. post-
 - b. caudo-
 - c. retro-
 - d. meta-
8. Which gland contains “suprarenal cortex”?
9. When Rx saying “nitroglycerin sublingual”, how is drug administered to patient?
10. What is opposite prefix of “ecto”?