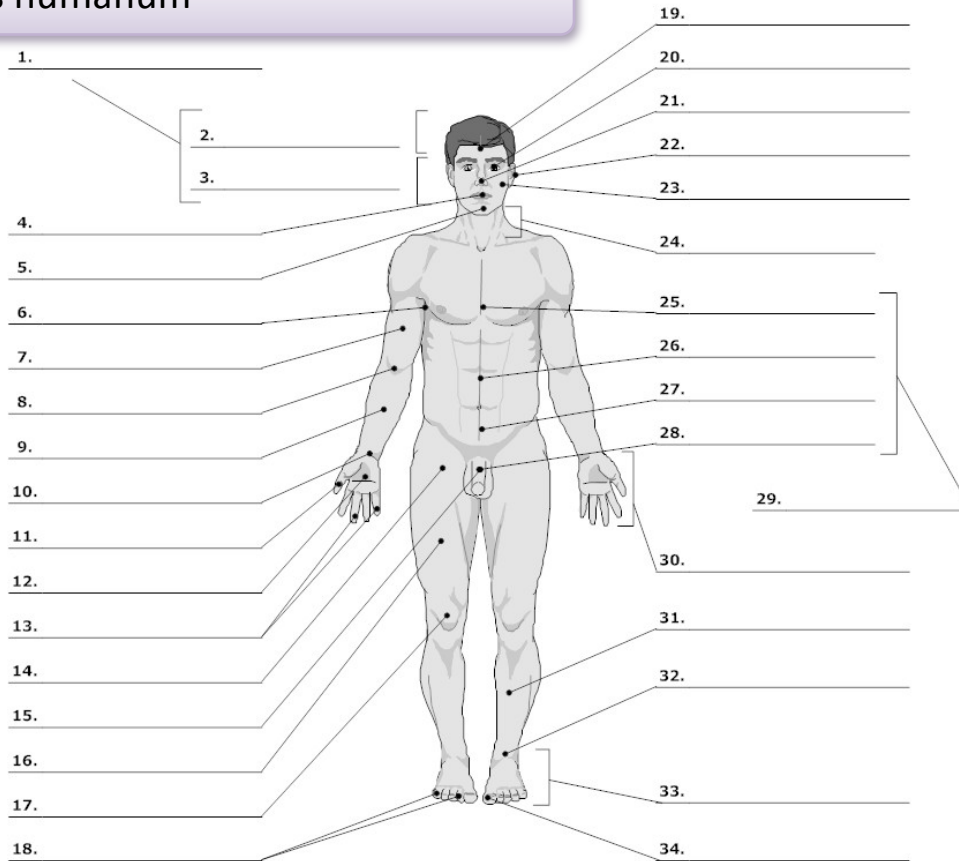


**PART I : EXERCISES/VOCABULARY**

**Corpus humanum**

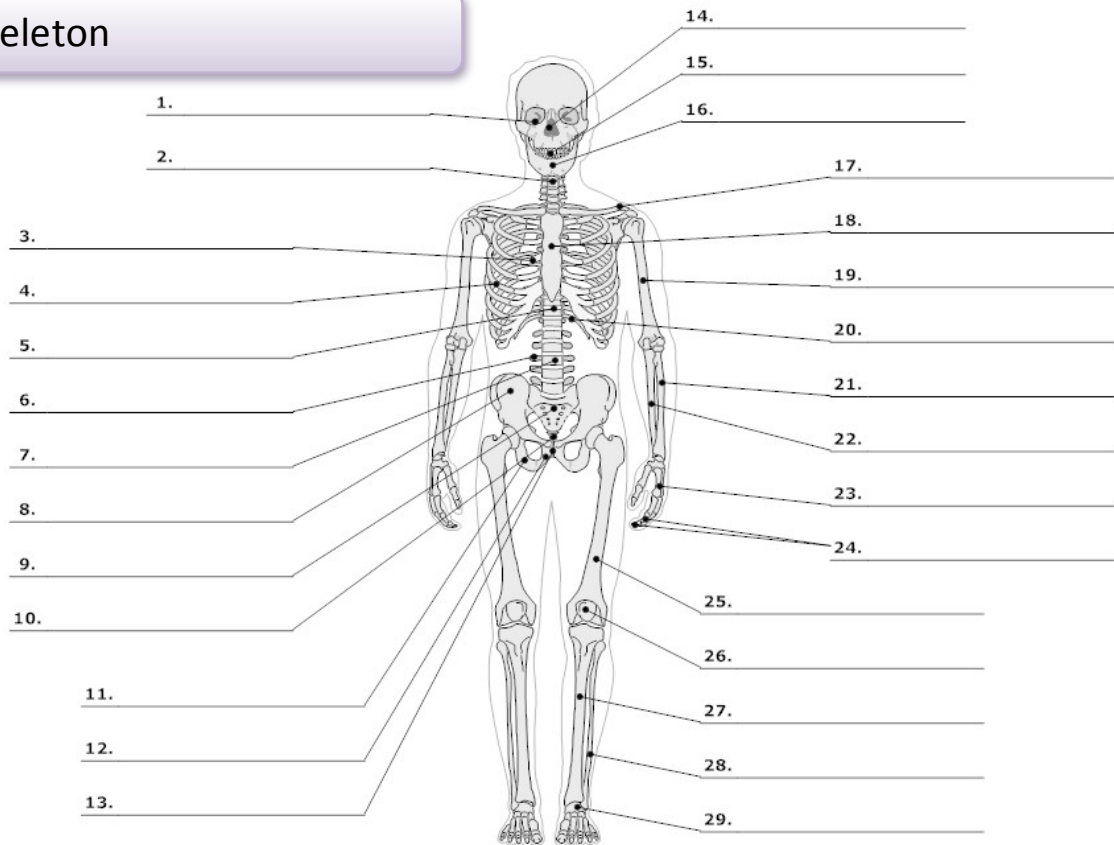


LifeART Collection Images Copyright © 1989-2001 by Lippincott Williams & Wilkins, Baltimore, MD

0. <b>corpus, oris, n.</b>	body	16. <b>femur, oris, n.</b>	thigh, femur
<b>cutis, is, f.</b>	skin	17. <b>genu, us, n.</b>	knee
1. <b>caput, itis, n.</b>	head	19. <b>frons, frontis, f.</b>	forehead
2. <b>capilli, orum, m.</b>	hair	20. <b>oculus, i, m.</b>	eye
3. <b>facies, ei, f.</b>	face	21. <b>nasus, i, m.</b>	nose
4. <b>os, oris, n.</b>	mouth	22. <b>auris, is, f.</b>	ear
<b>lingua, ae, f.</b>	tongue	23. <b>bucca, ae, f.</b>	cheek
5. <b>mentum, i, n.</b>	chin	24. <b>collum, i, n.</b>	neck (mainly on bones)
6. <b>axilla, ae, f.</b>	armpit, axilla	<b>cervix, icis, f.</b>	neck, cervix (mainly on soft parts/organs)
7. <b>brachium, ii, n.</b>	upper arm, brachium	25. <b>pectus, oris, n.</b>	chest
8. <b>cubitus, i, m.</b>	elbow	26. <b>abdomen, inis, n.</b>	belly, abdomen
9. <b>antebrachium, ii, n.</b>	forearm	27. <b>hypogastrium, ii, n.</b>	hypogastrium
10. <b>carpus, i, m.</b>	wrist	29. <b>truncus, i, m.</b>	trunk
11. <b>pollex, icis, m.</b>	thumb	30. <b>manus, us, f.</b>	hand
12. <b>palma, ae, f.</b>	palm (of the hand)	31. <b>crus, cruris, n.</b>	lower leg, shank
13., 18. <b>digitus, i, m.</b>	finger	32. <b>tarsus, i, m.</b>	tarsus
14. <b>sulcus, i, m.</b> <sup>1</sup>	fold, groove	<b>talus, i, m.</b>	anklebone, talus
15., 28. <b>penis, is m.</b>	penis	33. <b>pes, pedis, m.</b>	foot
		34. <b>hallux, ucis, m.</b>	big toe

<sup>1</sup> sulcus glutealis

**Skeleton**



LifeART Collection Images Copyright © 1989-2001 by Lippincott Williams & Wilkins, Baltimore, MD

0.	<b>skeleton, i, n.</b>	skeleton	<b>scapula, ae, f.</b>	shoulder blade, scapula
	<b>os, ossis, n.</b>	bone	18. <b>sternum, i, n.</b>	breastbone, sternum
	<b>cranium, ii, n.</b>	skull	19. <b>humerus, i, m.</b>	arm bone, humerus
1.	<b>orbita, ae, f.</b>	orbit	20. <b>arcus, us, m.<sup>2</sup></b>	arch
2.	<b>collum, i, n.</b>	neck (mainly on bones)	21. <b>radius, ii, m.</b>	radial bone, radius
	<b>cervix, icis, f.</b>	neck, cervix (mainly on soft parts/organs)	22. <b>ulna, ae, f.</b>	elbow bone
3.	<b>thorax, acis, m.</b>	thorax (chest with ribs)	23. <b>metacarpus, i, m.</b>	metacarpus
4.	<b>costa, ae, f.</b>	rib		wrist
5.	<b>discus, i, m.</b>	disc	24. <b>phalanx, gis, f.</b>	one of the finger bones, phalange
6.	<b>processus, us, m.</b>	process (an outgrowth of tissue)	25. <b>femur, oris, n.</b>	thighbone, femur
7.	<b>vertebra, ae, f.</b>	vertebra	26. <b>patella, ae, f.</b>	kneecap, patella
8.	<b>pelvis, is, f.</b>	pelvis	27. <b>tibia, ae, f.</b>	shinbone, tibia
	<b>coxa, ae, f.</b>	hip, hip joint	28. <b>fibula, ae, f.</b>	calf bone, fibula
	<b>os ilii (ilia, ilium, n.)</b>	ilium	29. <b>metatarsus, i, m.</b>	metatarsus
9.	<b>os sacrum (sacer, a, um)</b>	sacral bone		
10.	<b>coccyx, gis, f.</b>	tailbone, coccyx		
11.	<b>os ischii (ischium, ii, n.)</b>	ischium		
12.	<b>os pubis (pubes, is, f.)</b>	pubis		
13.	<b>symphysis, is, f.</b>	symphysis		
14.	<b>nasus, i, m.</b>	nose		
15.	<b>dens, dentis, m.</b>	tooth		
16.	<b>mandibula, ae, f.</b>	jawbone		
17.	<b>clavicula, ae, f.</b>	collarbone, clavicle		

<sup>2</sup> arcus costalis