

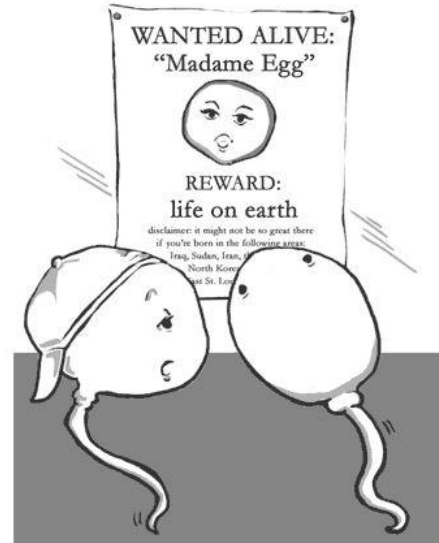
FEMALE GENITAL ORGANS

Organa genitalia feminina

RNDr. Michaela Račanská, Ph.D.

spring 2017

copyright 2005 baby-gaga.com



There's a new one up every month now that they're TTC



Department of Anatomy
MU Brno, Czech Republic



FEMALE GENITAL ORGANS

Internal female genitals:

ovarium

tuba uterina

uterus

vagina

External genitals:

labia majora pudendi

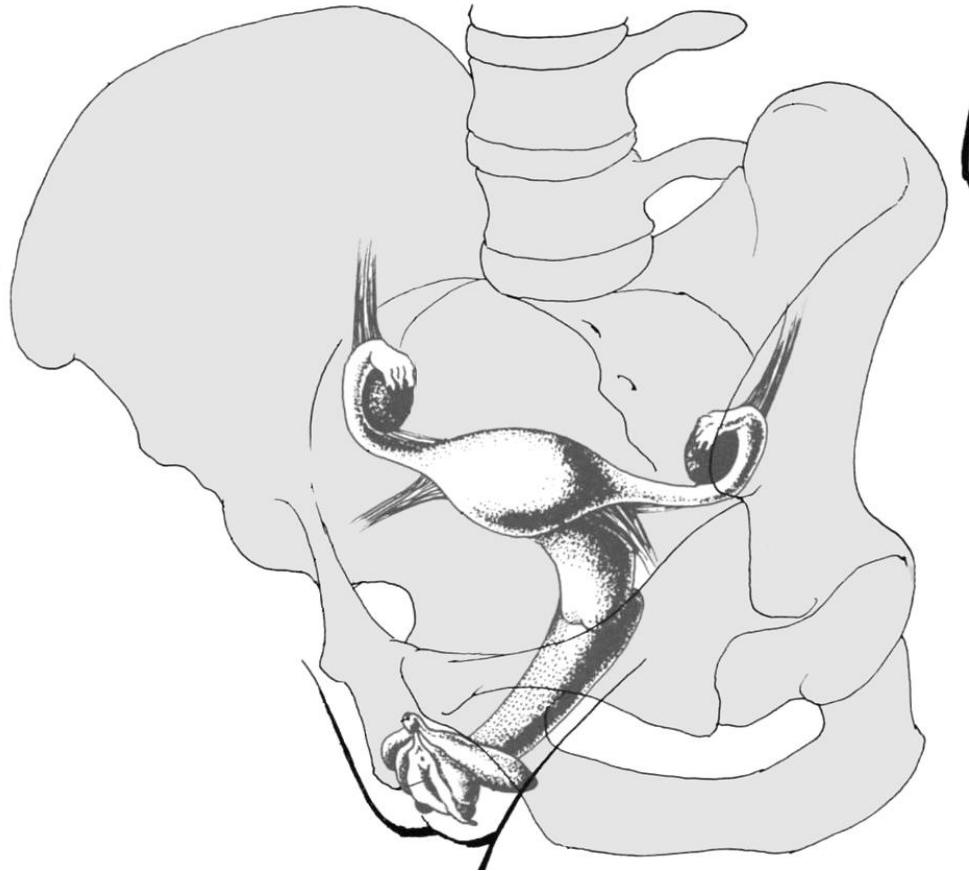
labia minora pudendi

clitoris

vestibulum vaginae

bulbi vestibuli

gl. vestib. maj. et min.



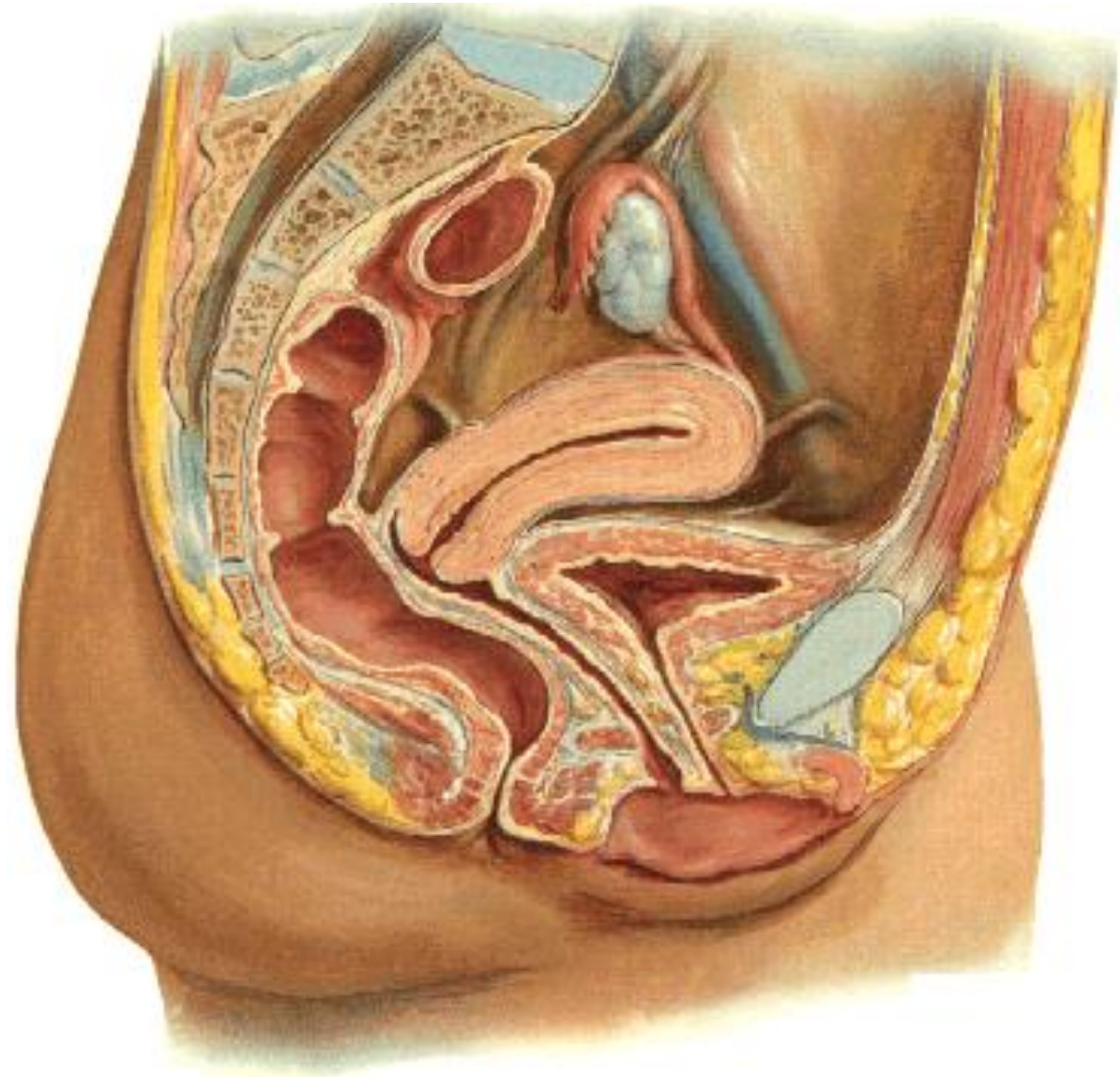
Internal female genital organs

Ovary (ovarium)

**Phalopian tube (*tuba
uterina*)**

Uterus

Vagina

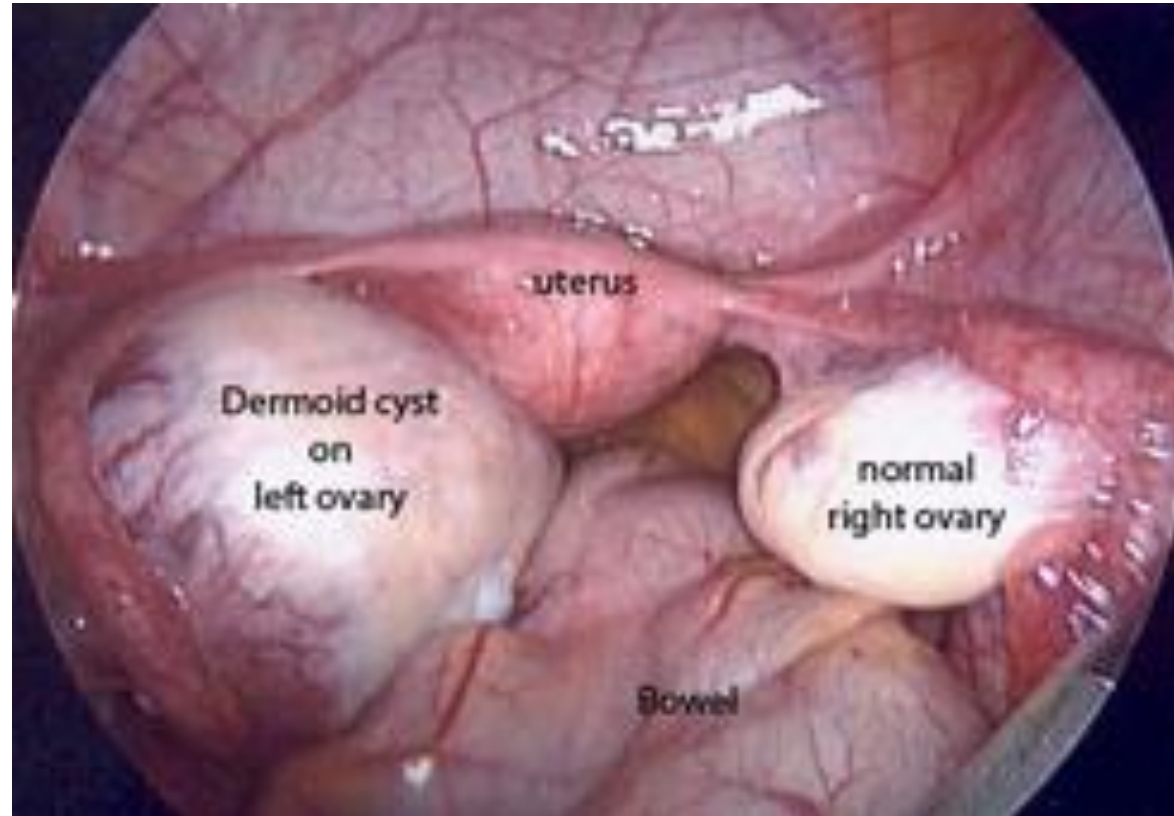


Ovarium

Produces germ cells

Endocrine function

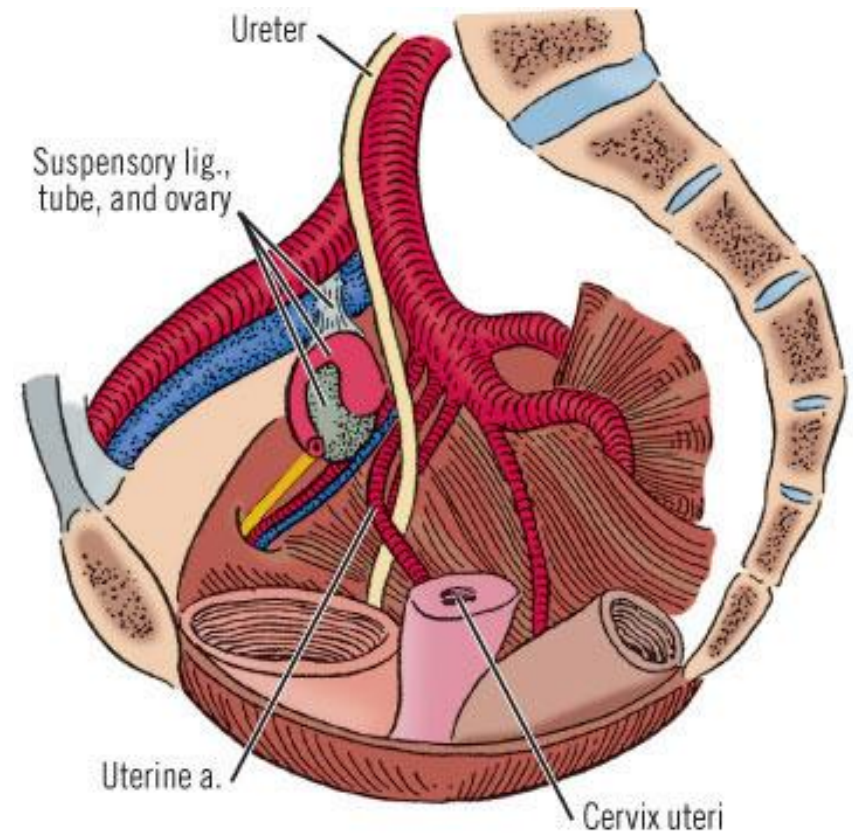
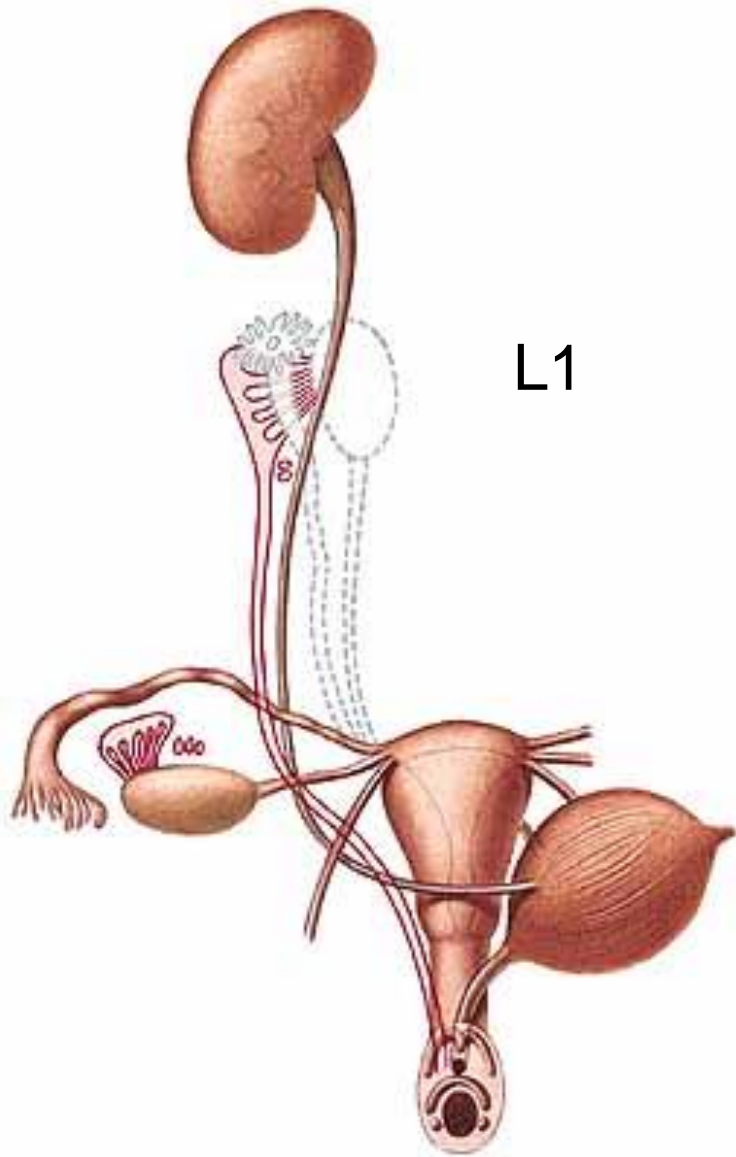
6-10g, 3-5cm



depends on functional state

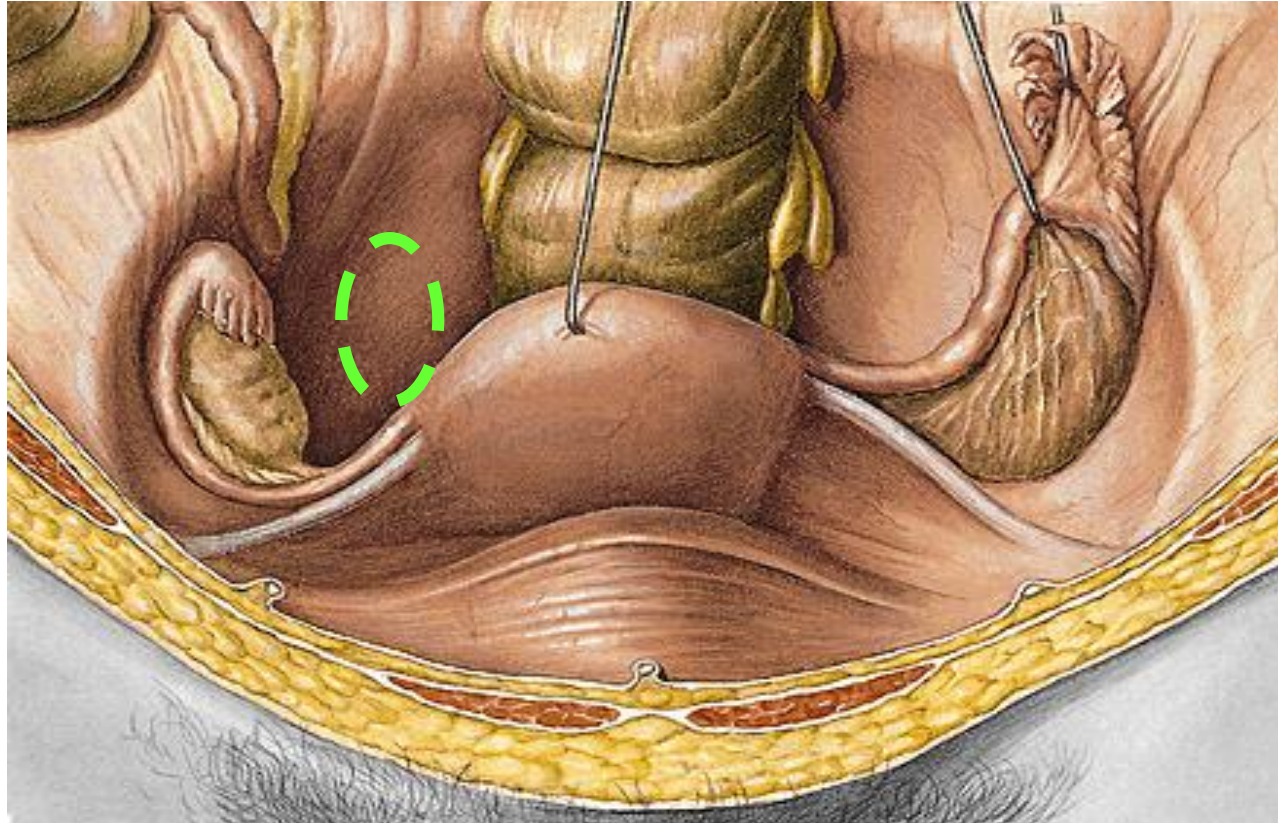
Descend of the ovaries

At the beginning: **abdominal cavity**-
end of i.u. development: **fossa iliaca**
- 1. year: **fossa ovarica**
- after giving a birth: **Claudius pit**



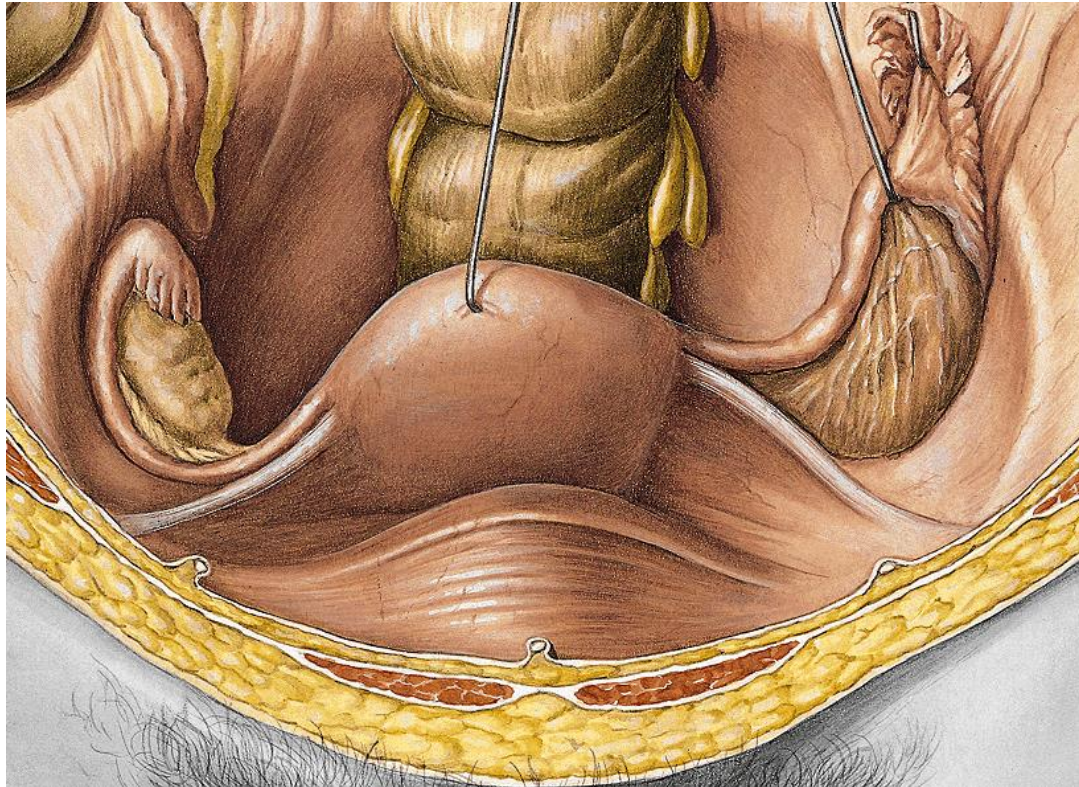
LOCALIZATION OF OVARY

Female gonads, paired, lie in shallow depressions, one on each side of the upper pelvic cavity



Nullipara – fossa ovarica (in front of a. iliaca int.)

Multipara – Claudius fossa (behind a. iliaca int.)



**Axis passes
longitudinally!**

Extremitas

**tubaria (upper)
uterina (lower)**

Facies: med., lat.

Margo

liber (post)

**mesovaricus (ant,
hilus)**

Ovarian cycle

Lig. suspensorium ovarii (vasa ovarica)

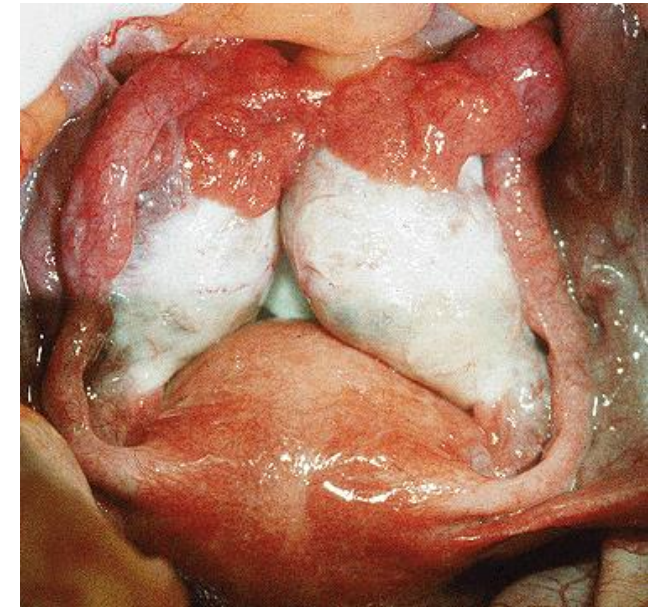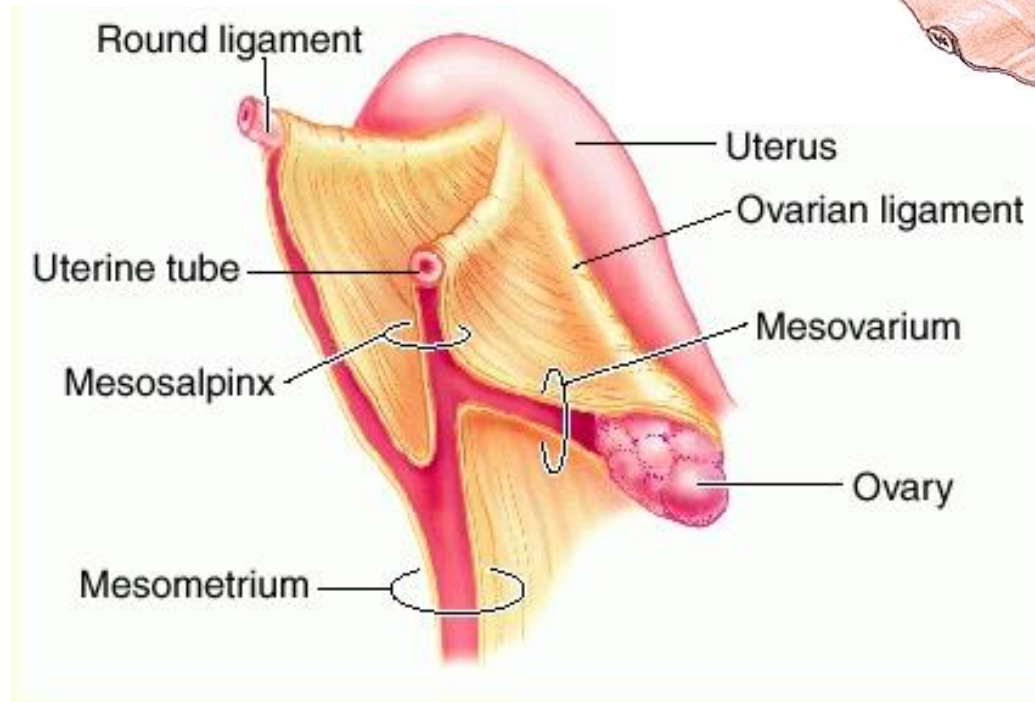
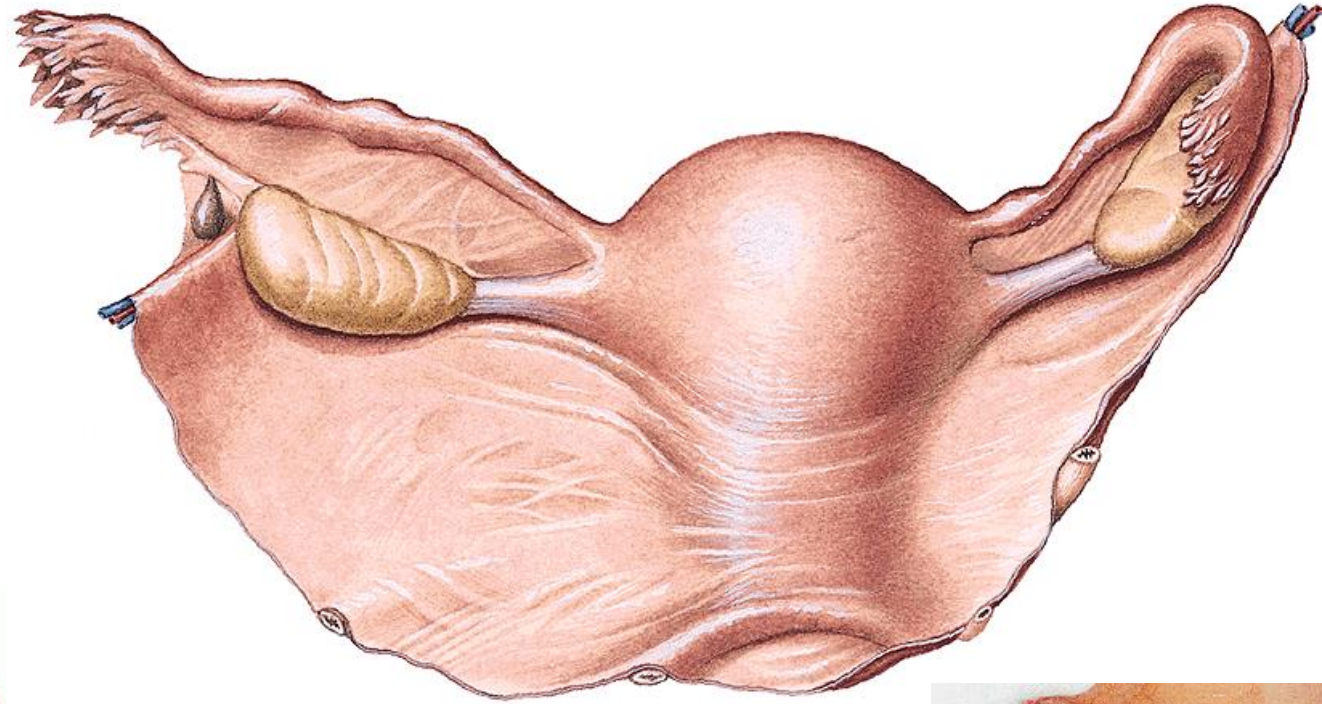
HANGING APPARATUS

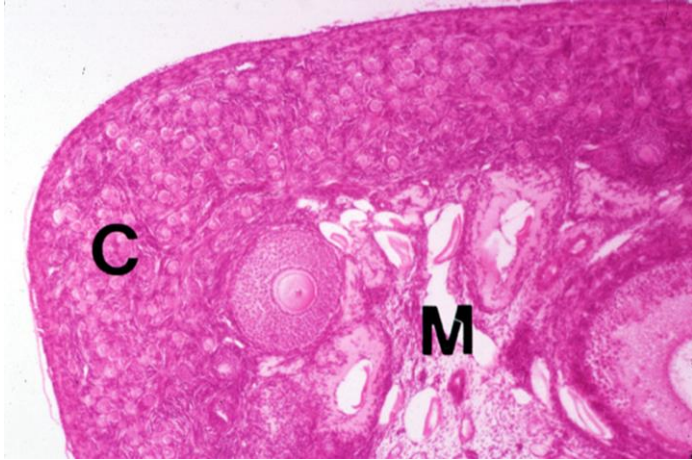
Lig. ovarii proprium

Hilus ovarii

Mesovarium

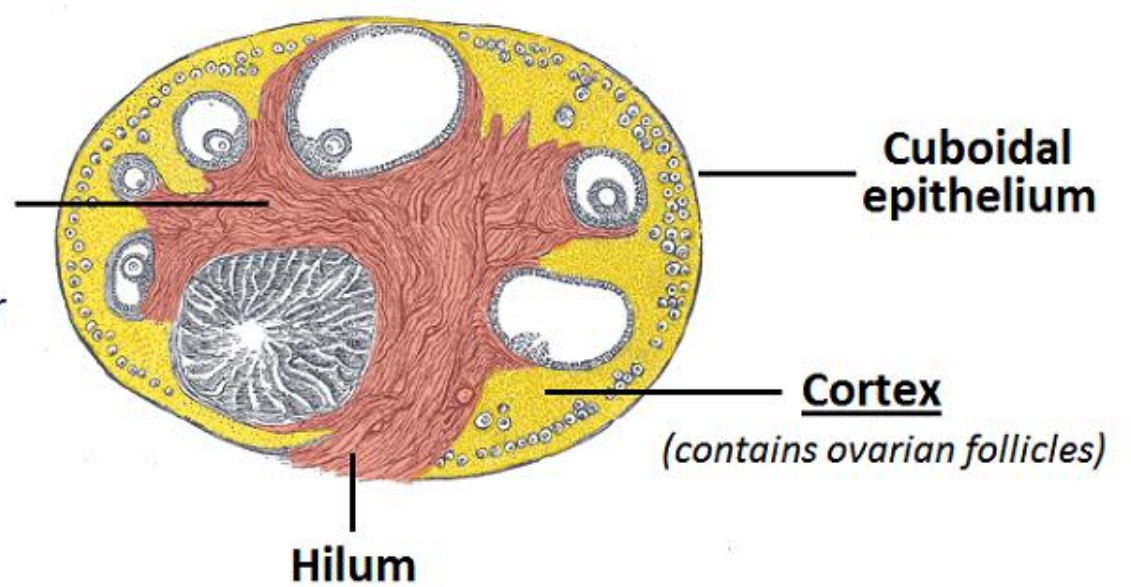
Lig. latum uteri





Ovary - cortex with follicle, medulla

Medulla
(contains neurovascular structures)



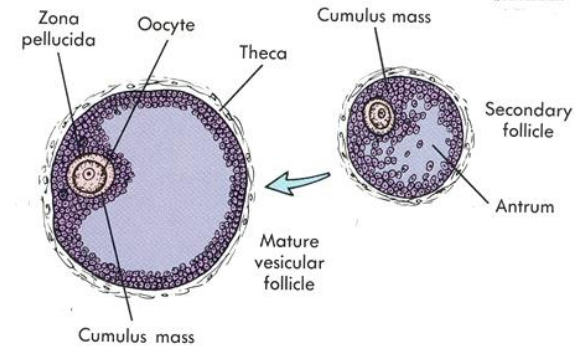
Tunica albuginea
Cortex ovarii:

Folliculi ovarici - primarii

- secundarii

- vesiculosi (Graaf)

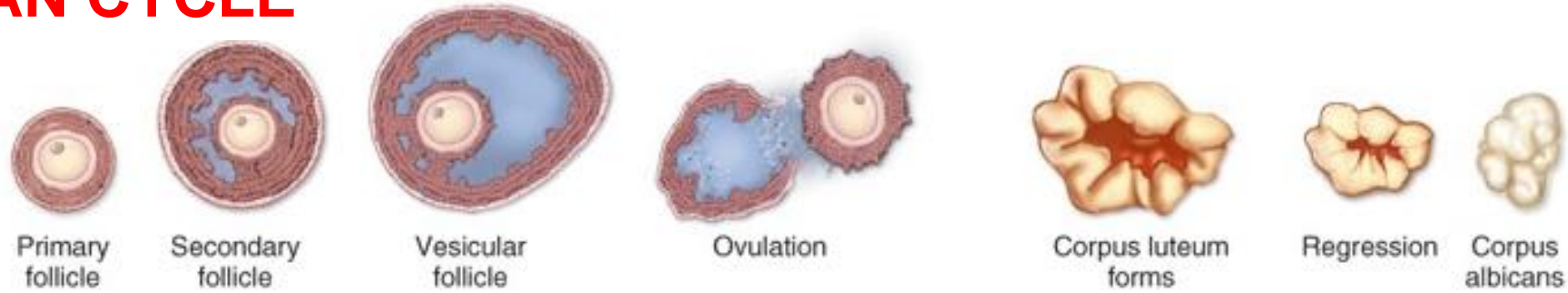
matured oocyt



Medulla ovarii

conn. tissue, blood and lymph vessels, nerves, smooth muscle

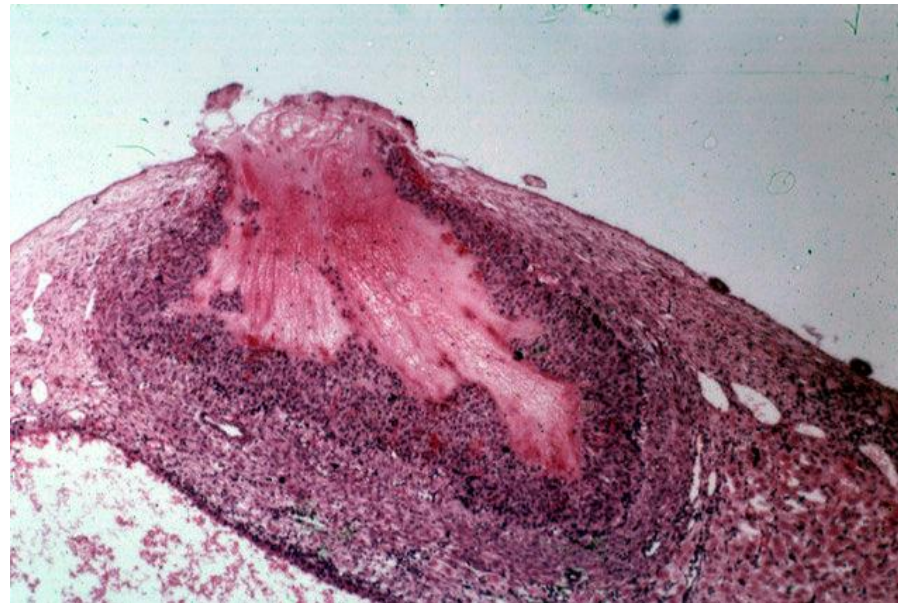
OVARIAN CYCLE



**Follicular stage
(Estrogen)**

Ovulation

Luteal stage (progesterone)



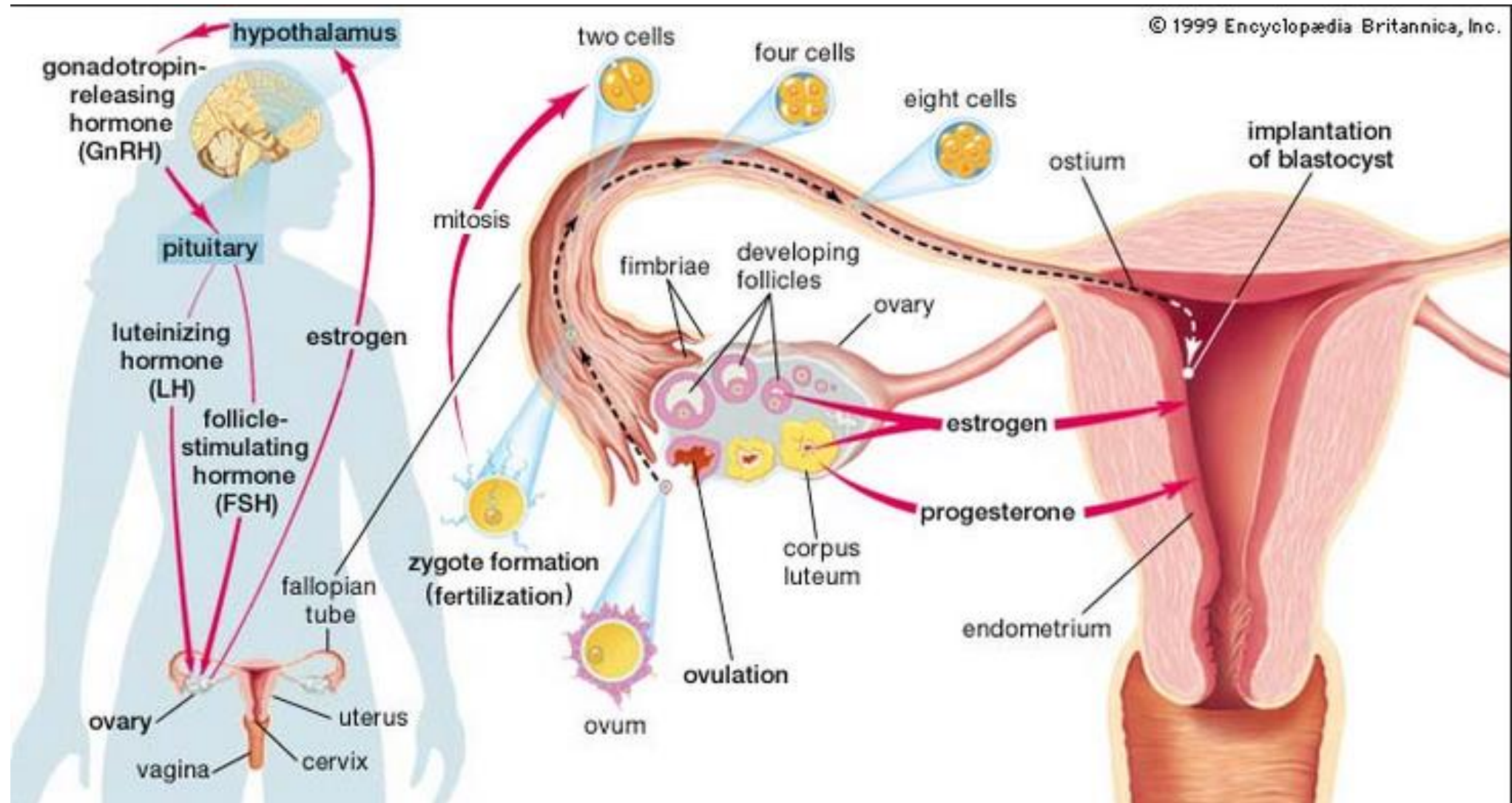
**c. l. graviditatis
c. l. menstruat. > corpus
albicans**

**At birth 2 million follicles
Puberty 300,000-400,000
Only 400 ever mature –
one egg/month through reproductive years (from
puberty (menarche) (12-13) until menopause (45-55))**

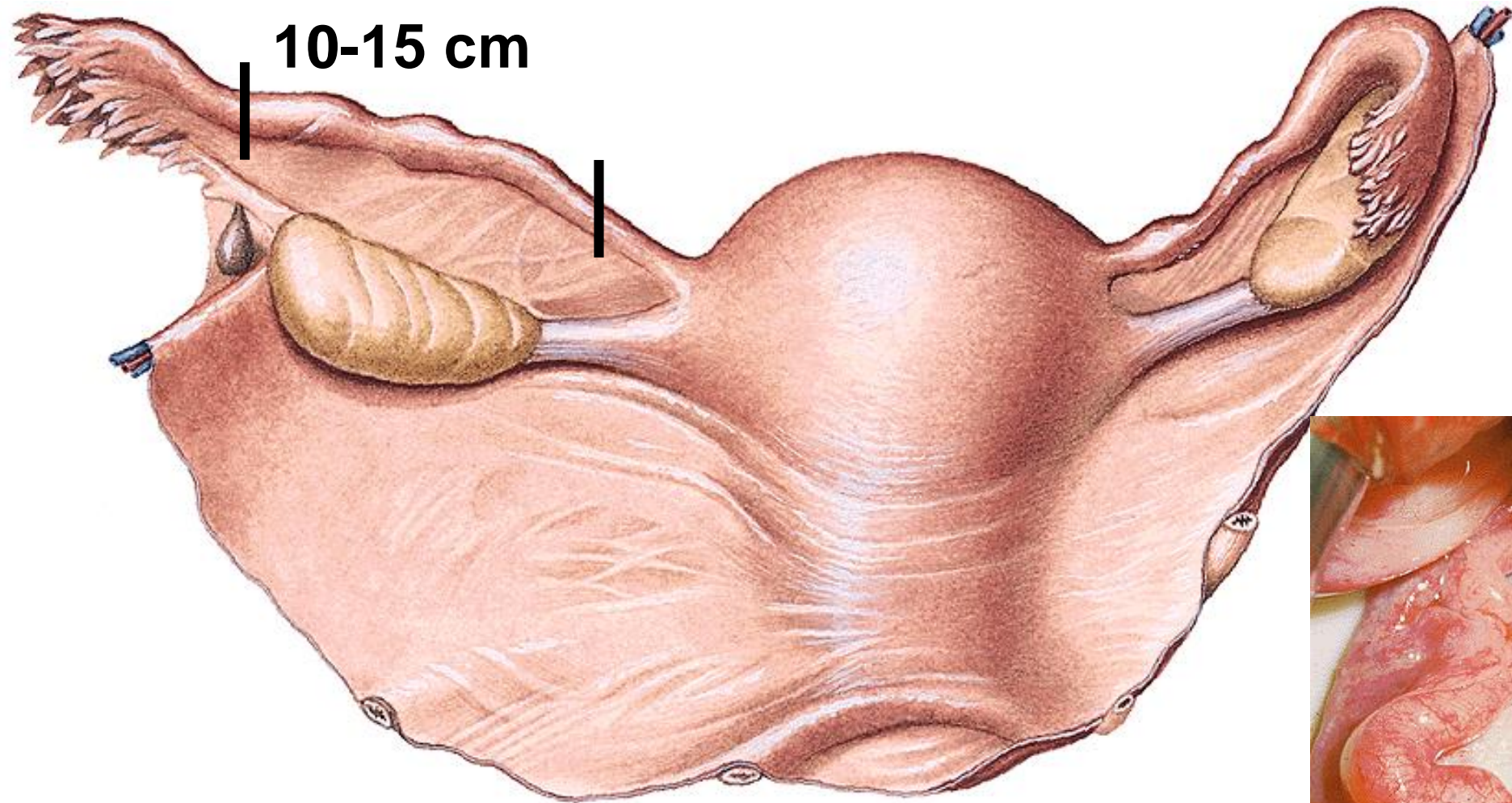
Hypophysis a) FSH b) LH = gonadotropin hormones

Ovarian cycle

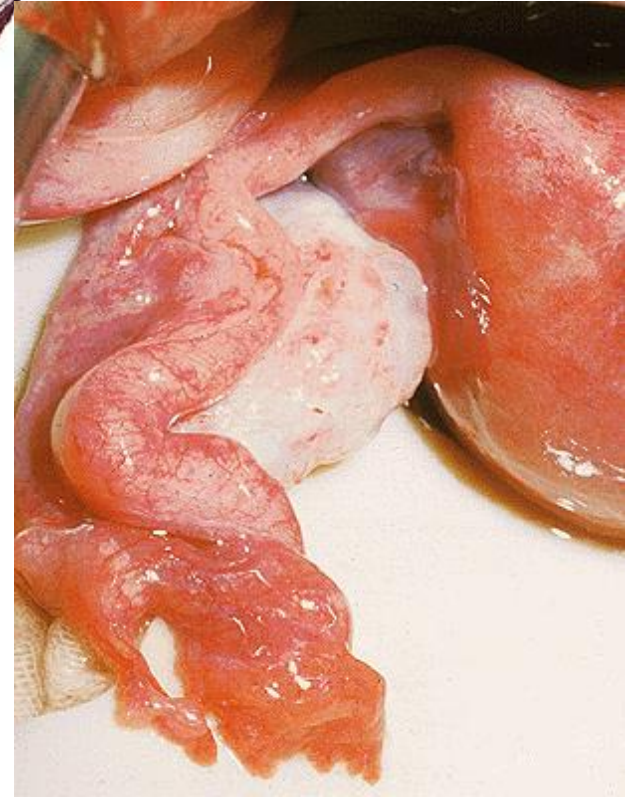- Hormones levels cycle in the female on a monthly basis
- Ovarian cycle drives the uterine cycle



Tuba uterina (salpinx)



**Ostium abdominale - infundibulum (fimbriae) -
ampulla - isthmus - pars uterina - ostium
uterinum**



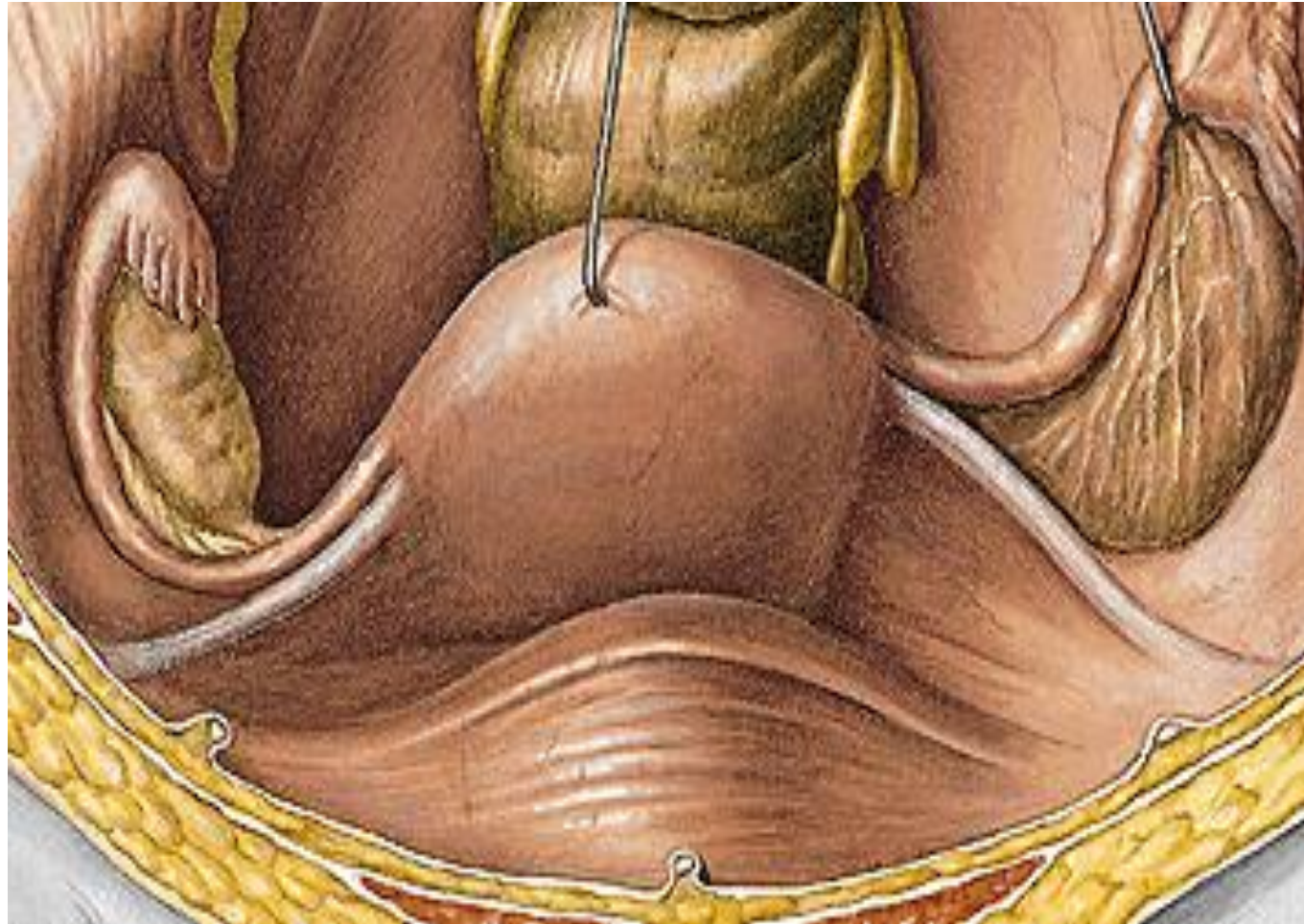PHALOPIAN TUBE COURSE

Isthmus – transversally (laterally) to the wall of pelvis minor

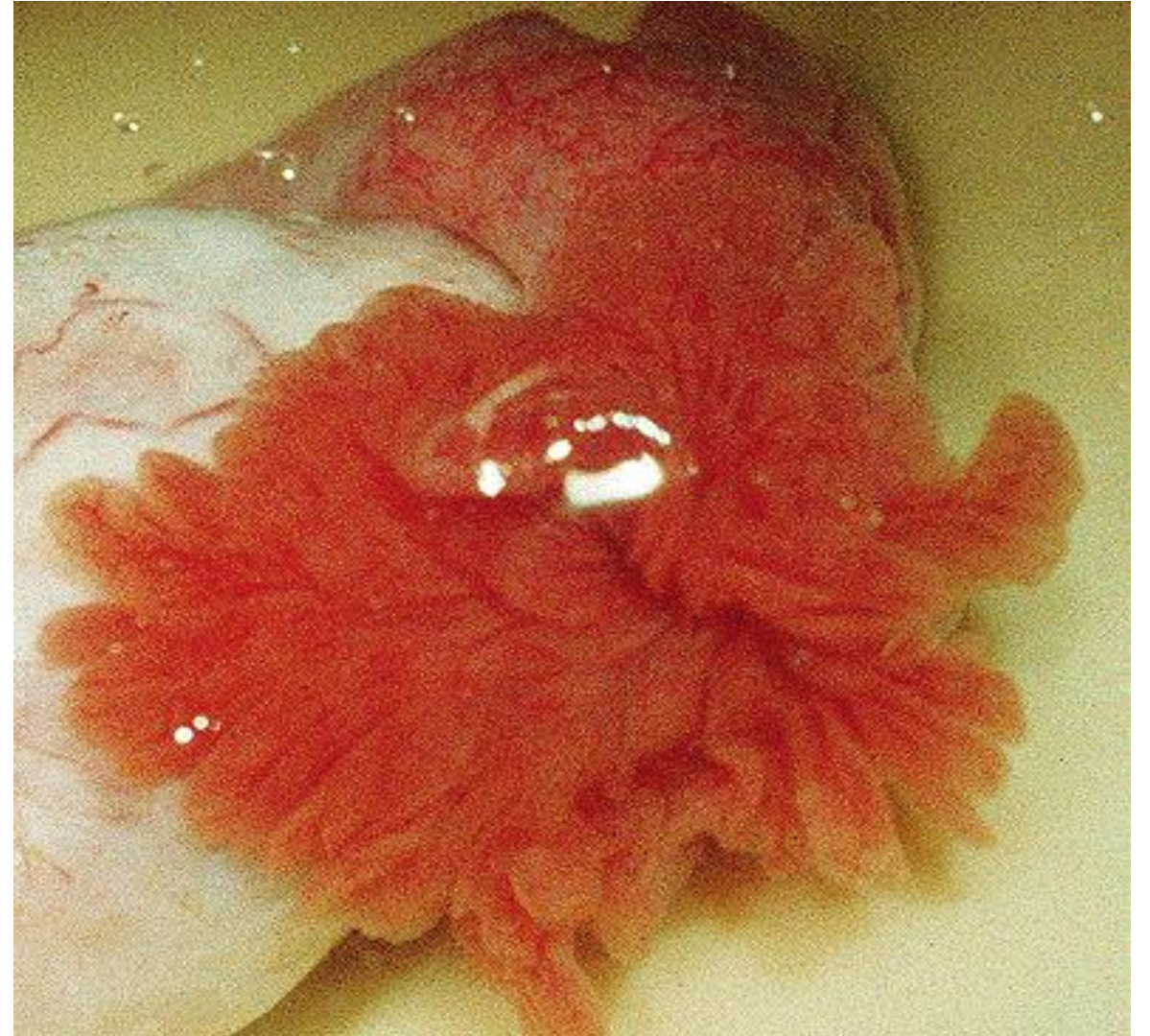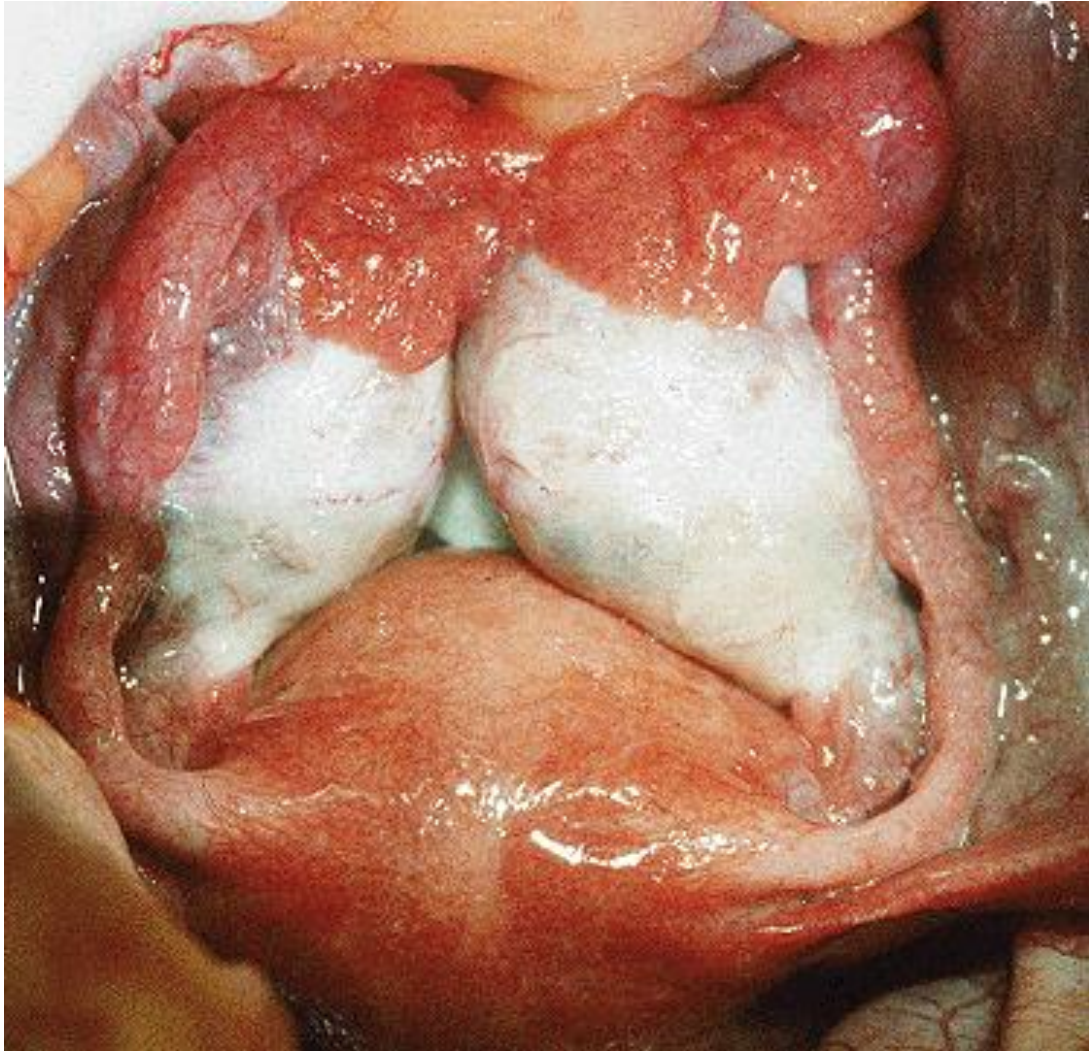Ampulla - dorsocranially to the upper pole of ovary

Infundibulum - dorsocaudally

Fimbriae - rotated to fac. medialis et superior ovarii

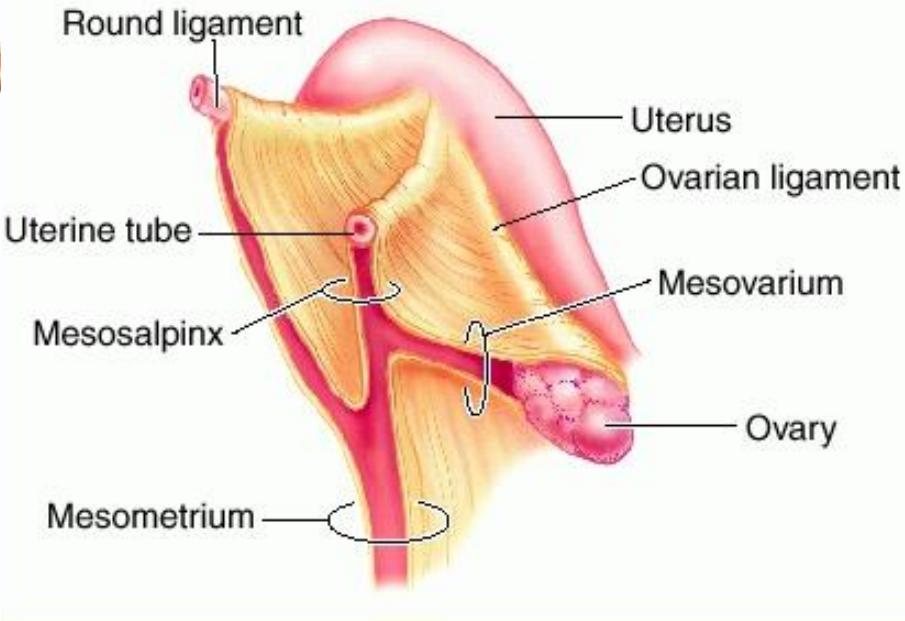
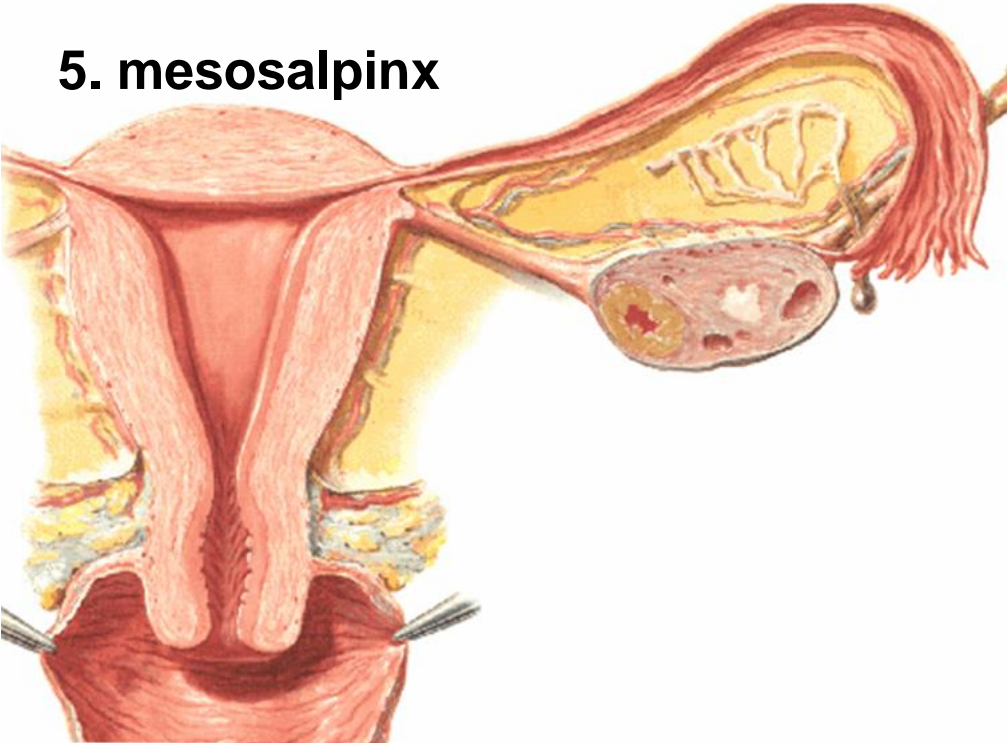
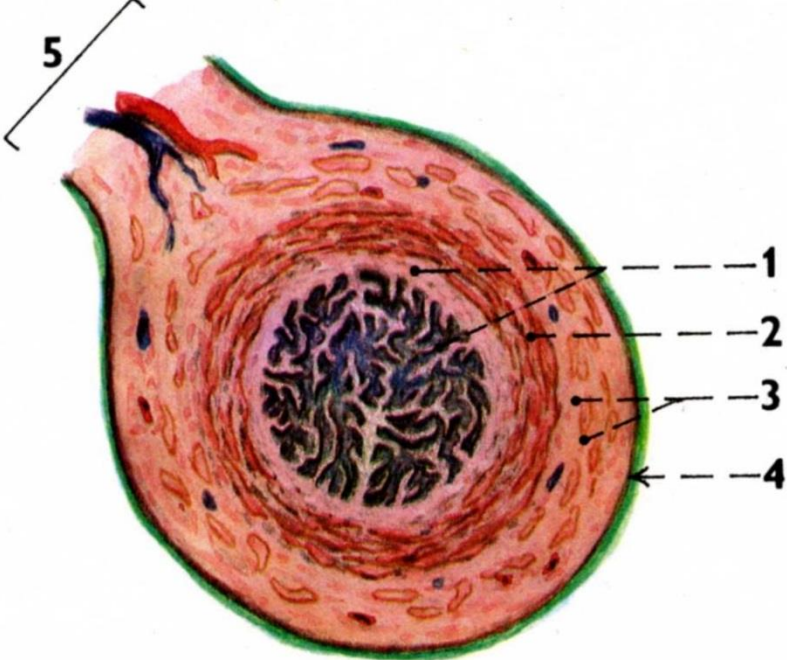


OSTIUM ABDOMINALE TUBAE UTERINAE



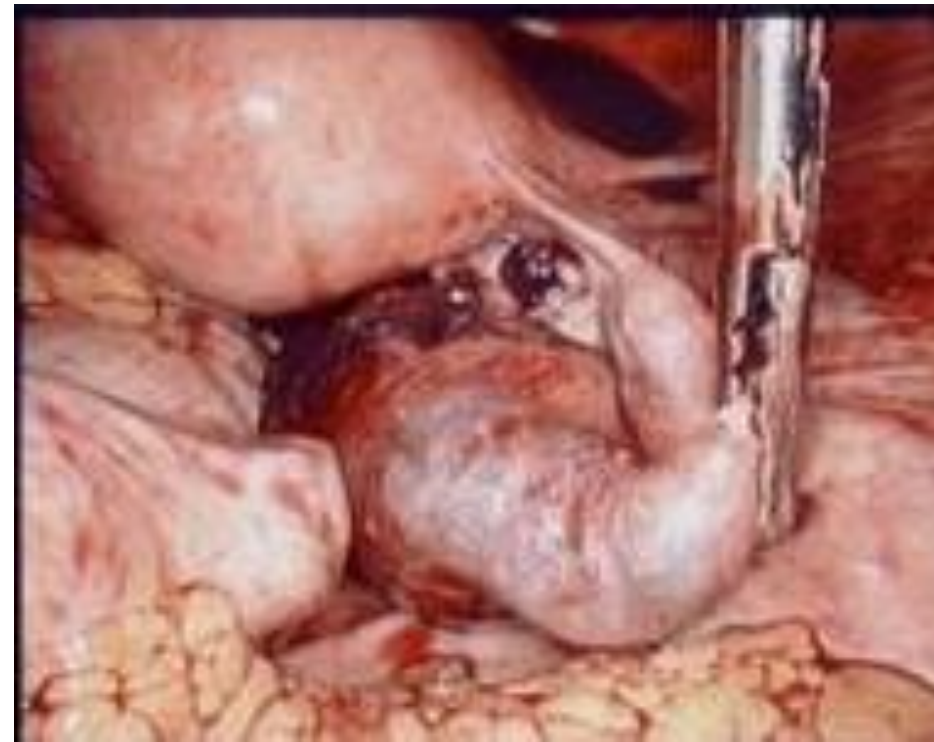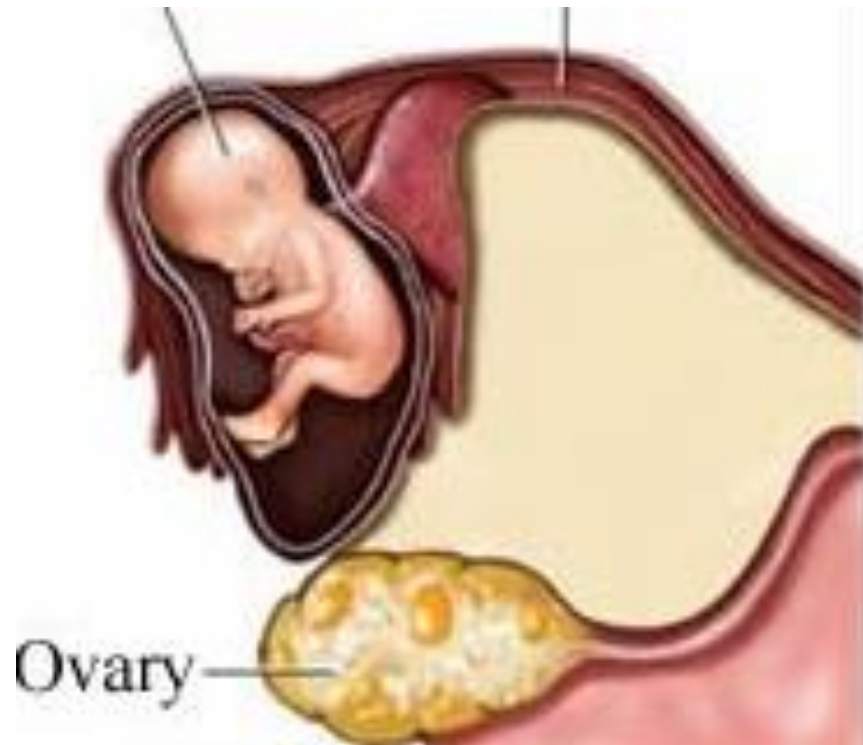
HISTOLOGY OF PHALOPIAN TUBE

- 1. Mucosal folds
(cylind. epithelium cilliated)
- 2. Circular muscular layer
- 3. Longitudinal muscular layer
- 4. tunica serosa
- 5. mesosalpinx

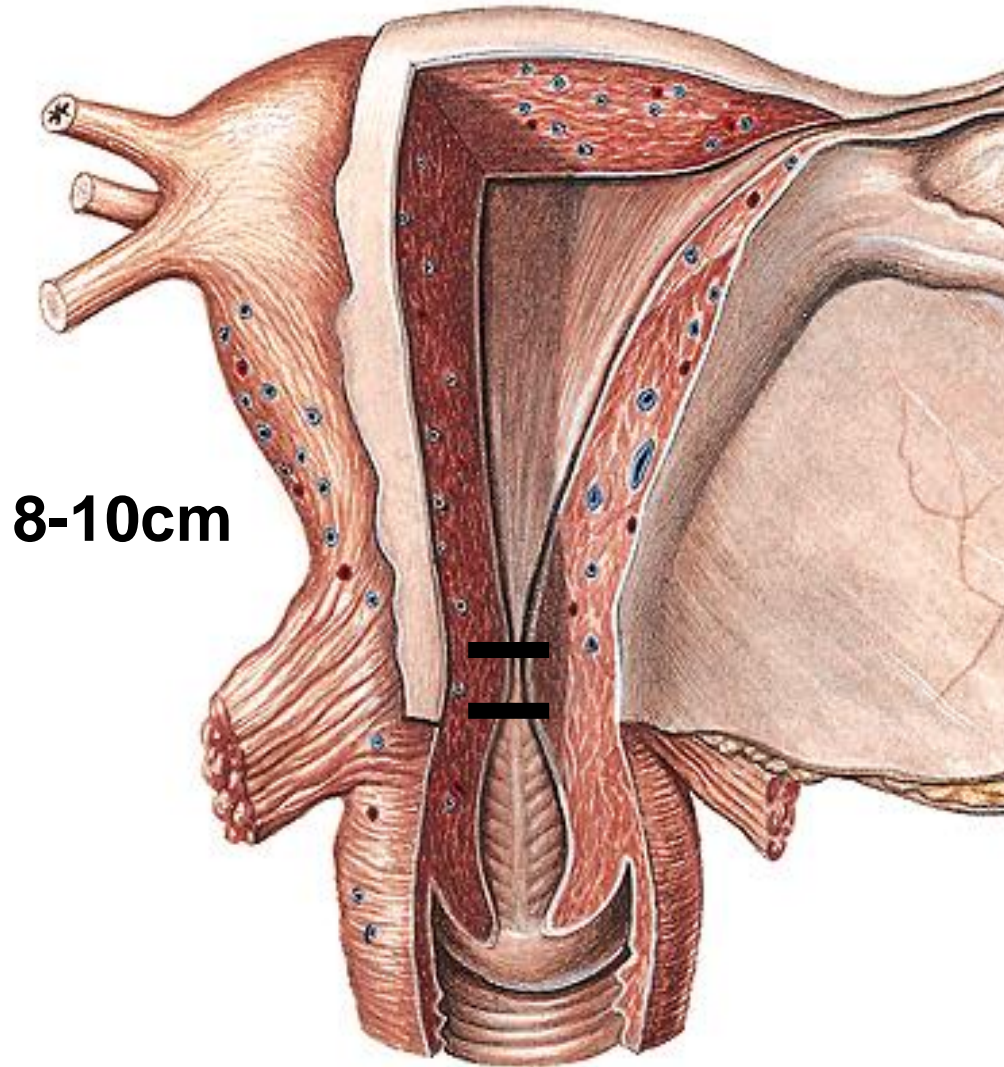


CLINIC NOTE

Changes of the mucosa (inflammations!) could causes that the tube is not passable for the egg => extrauterine pregnancy (Ectopic tubal pregnancy)!!!!



Uterus, hystera



Corpus

- fundus
- cornua – dex. et. sin.:
lig. ovarii propr. , lig. teres uteri
- margines- dx., sin.: lig. latum,
- facies intestinalis
vesicalis

Isthmus (1 cm)

- ## Cervix
- portio supravaginalis
 - vaginalis (cervix)

Cavum uteri (3 ml)

Canalis isthmi

Ostium internum canalis cervicis

Canalis cervicis (plicae palmatae)

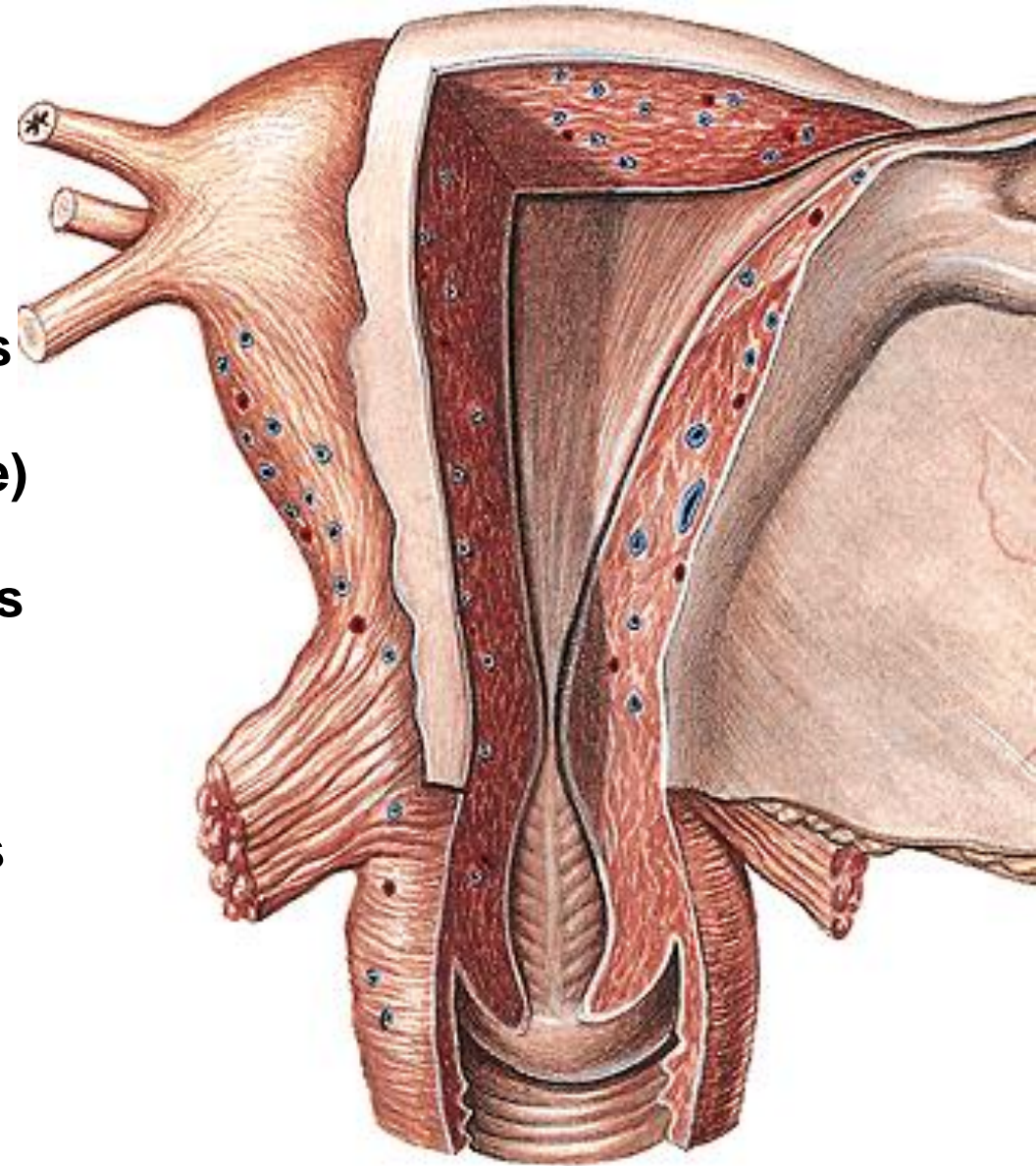
**Ostium externum canalis cervicis
(= ostium uteri)**

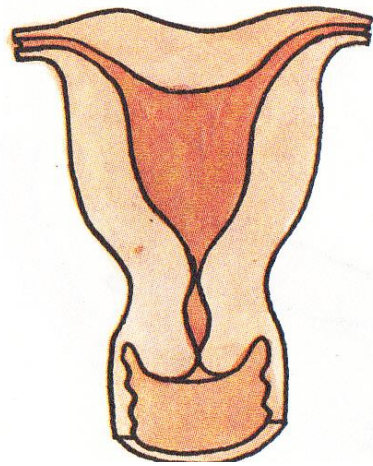
Cervix

portio supravaginalis

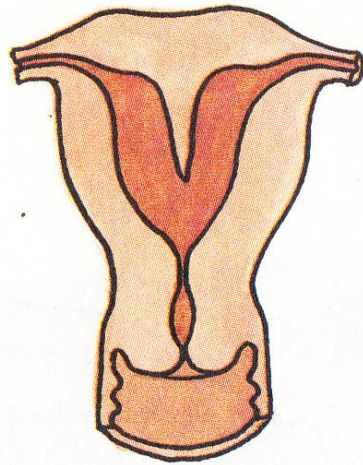
portio vaginalis

Fornix vaginae

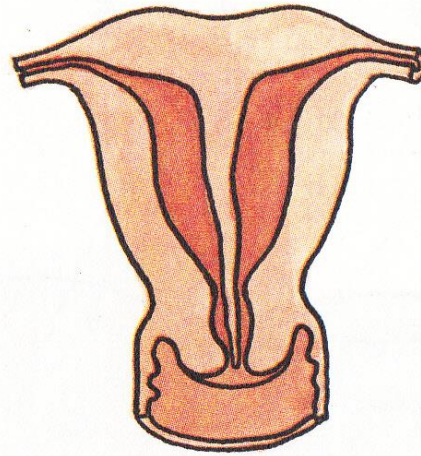




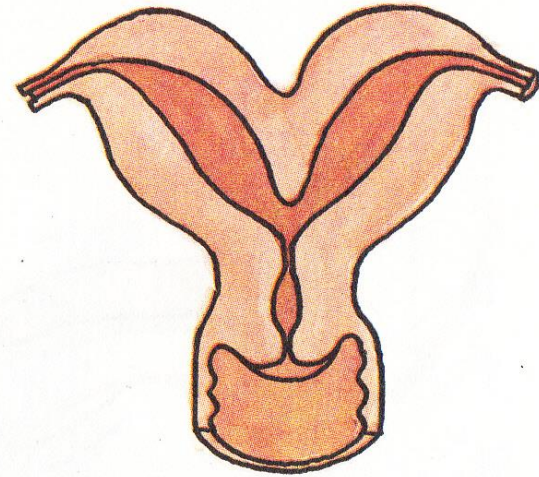
uterus arcuatus



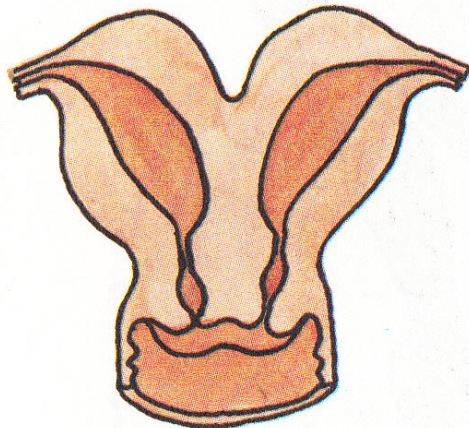
uterus subseptus



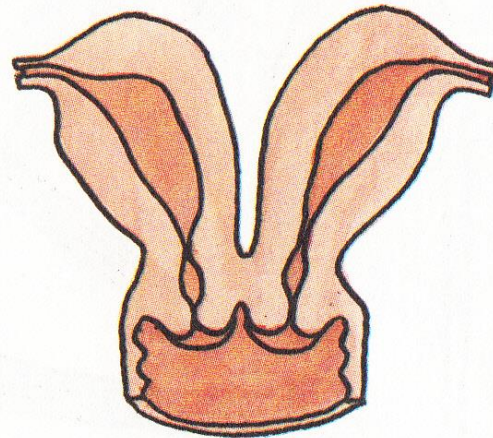
uterus septus



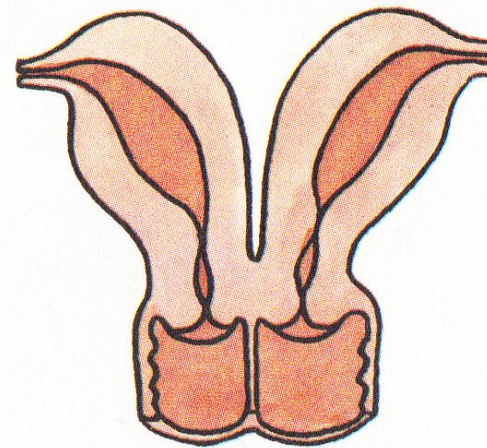
uterus bipartitus



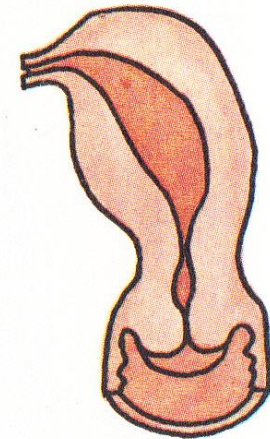
uterus duplex



uterus duplex



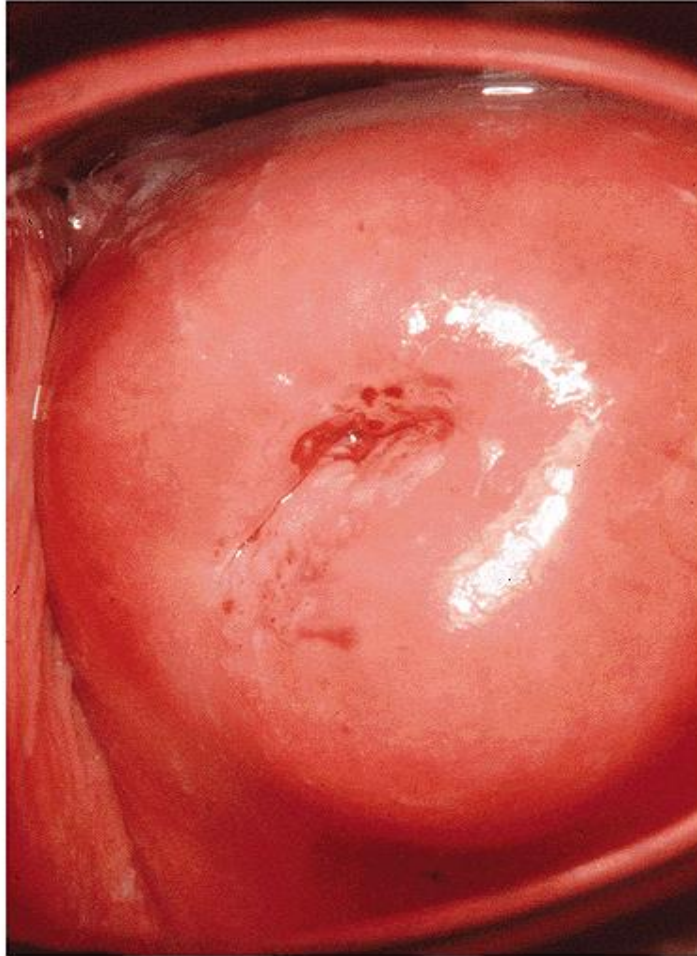
**uterus duplex
cum vagina septa**



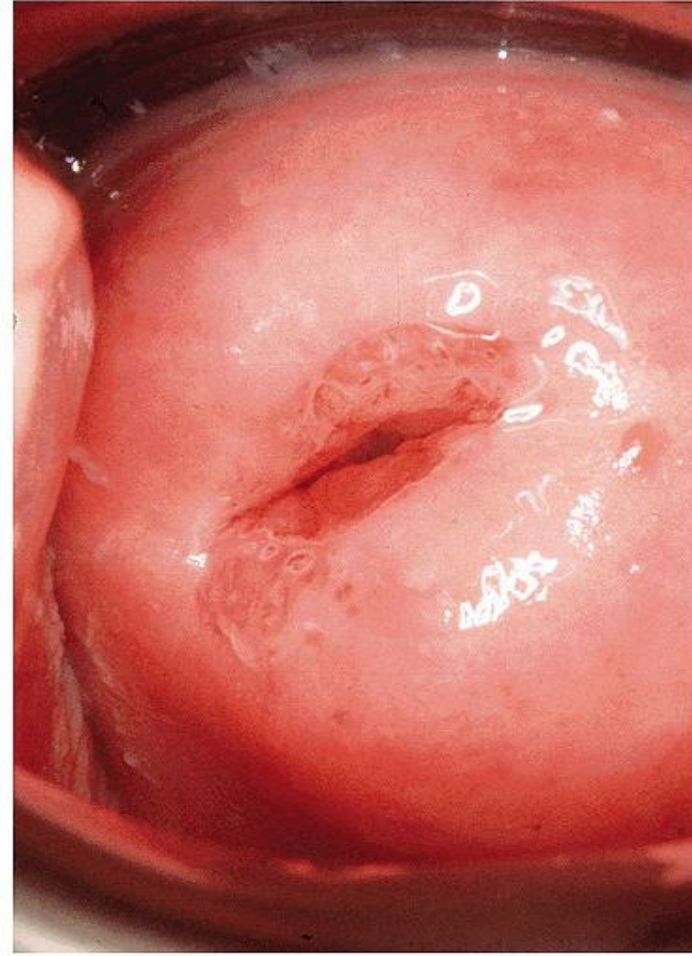
uterus unicornis

OSTIUM UTERI (OSTIUM EXTERNUM CANALIS CERVICIS)

NULLIPARA



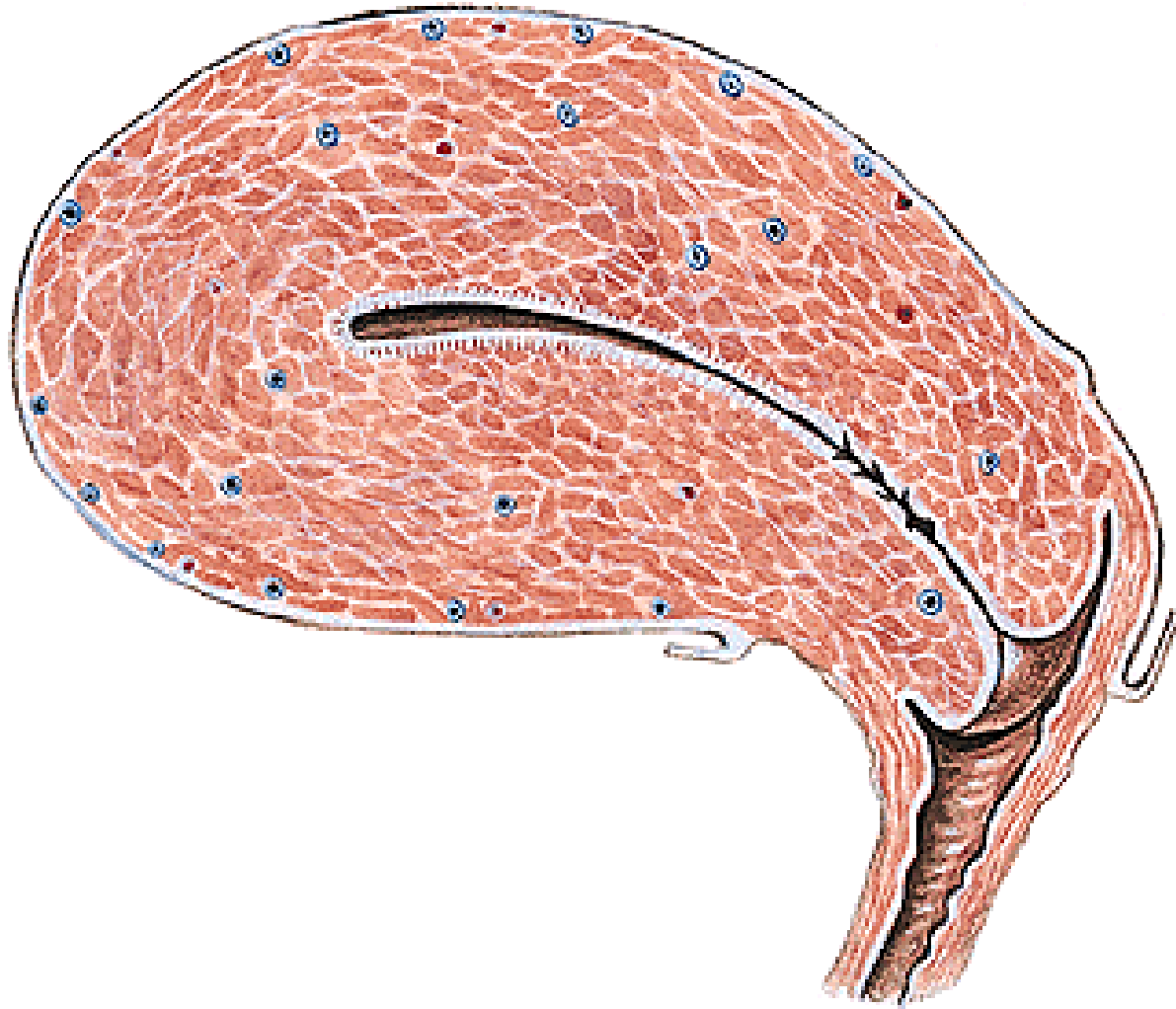MULTIPARA



Labium anterius et posterius

Epithel of the vagina x epithel of the uterus!!!

HISTOLOGY OF UTERUS



Endometrium

Myometrium

Perimetrium

ENDOMETRIUM

Simple cylindric epithelium

zona basalis

zona functionalis

glandulae uterinae

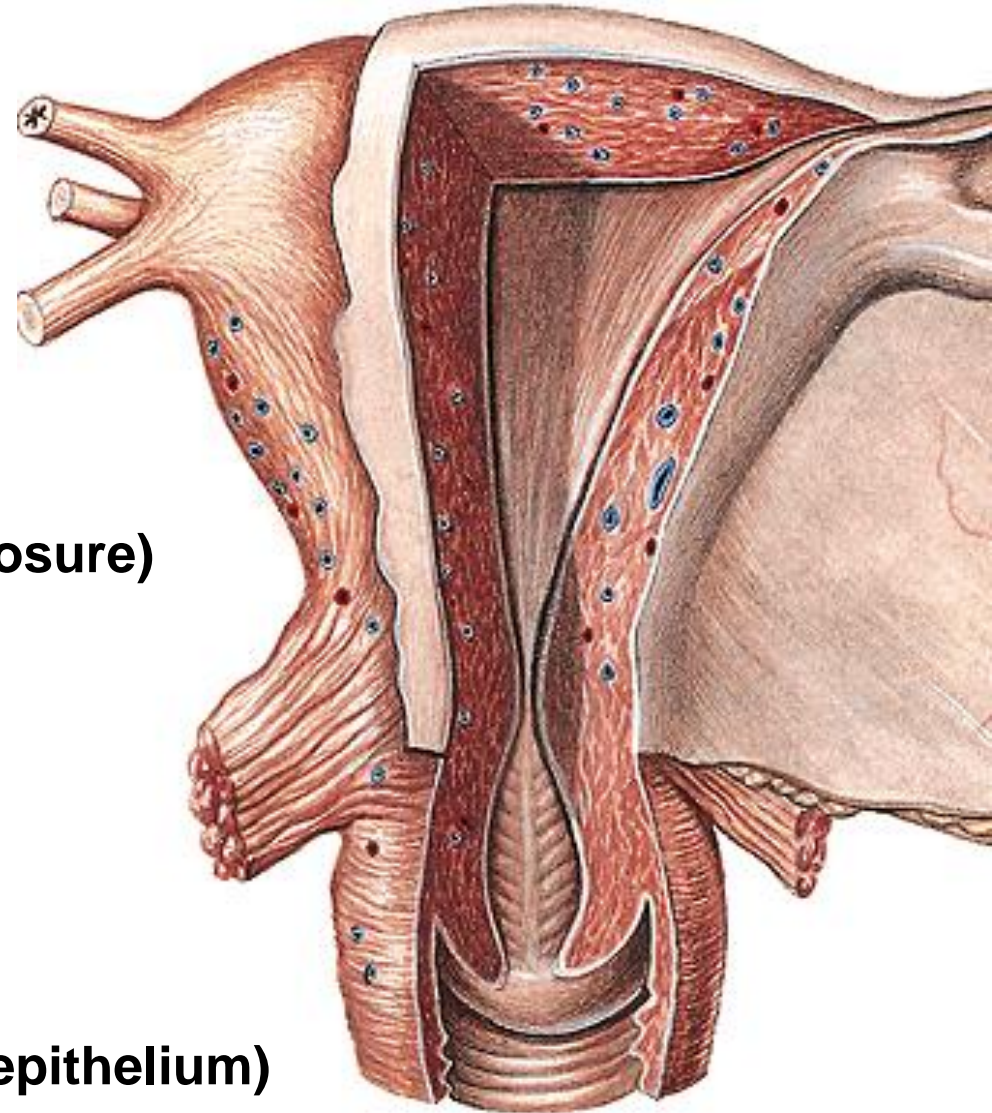
glandulae cervicales (mucose closure)

menstruation cycle

menarche

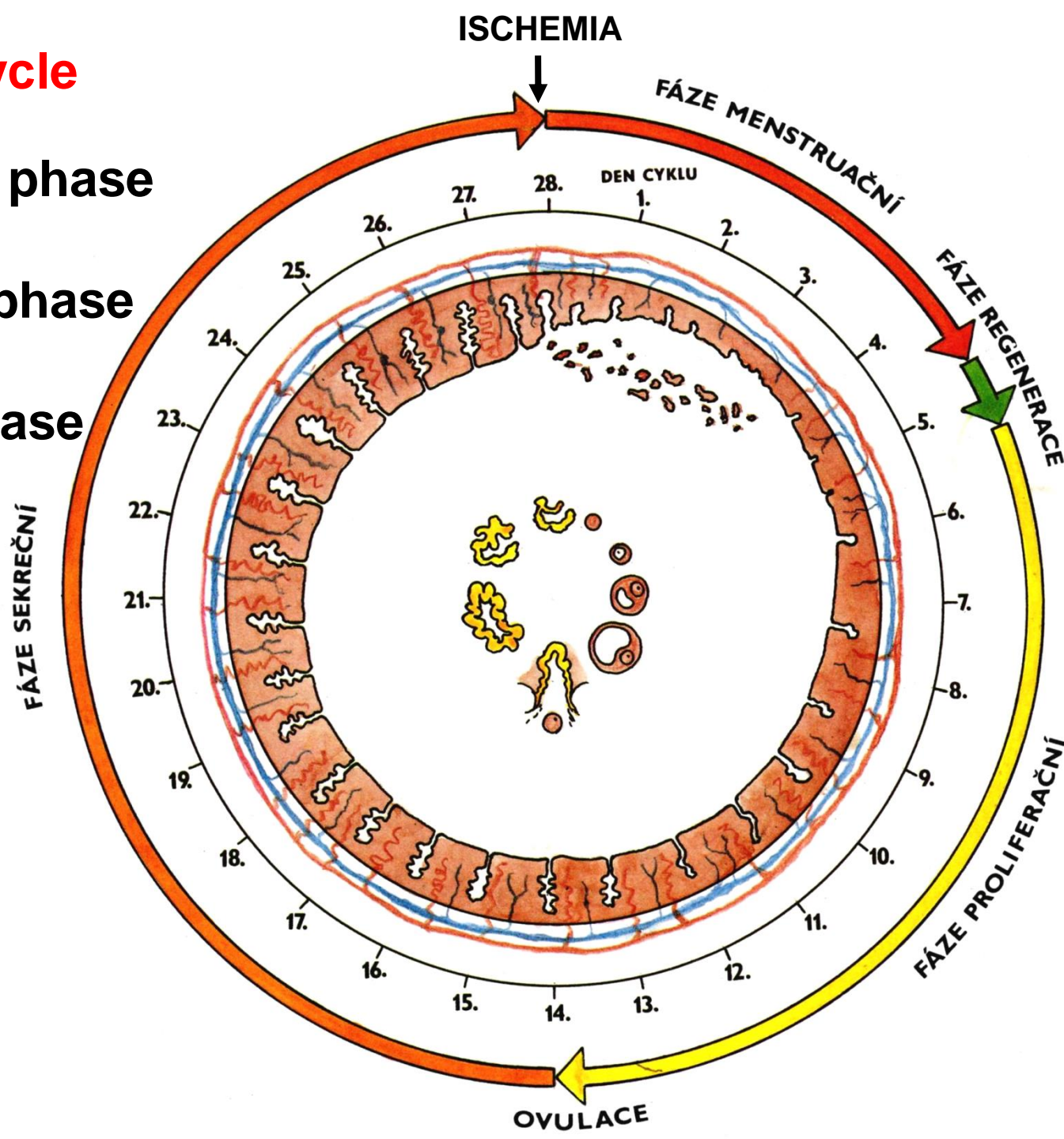
menopausa (climacterium)

ostium uteri (multilayer stratified epithelium)



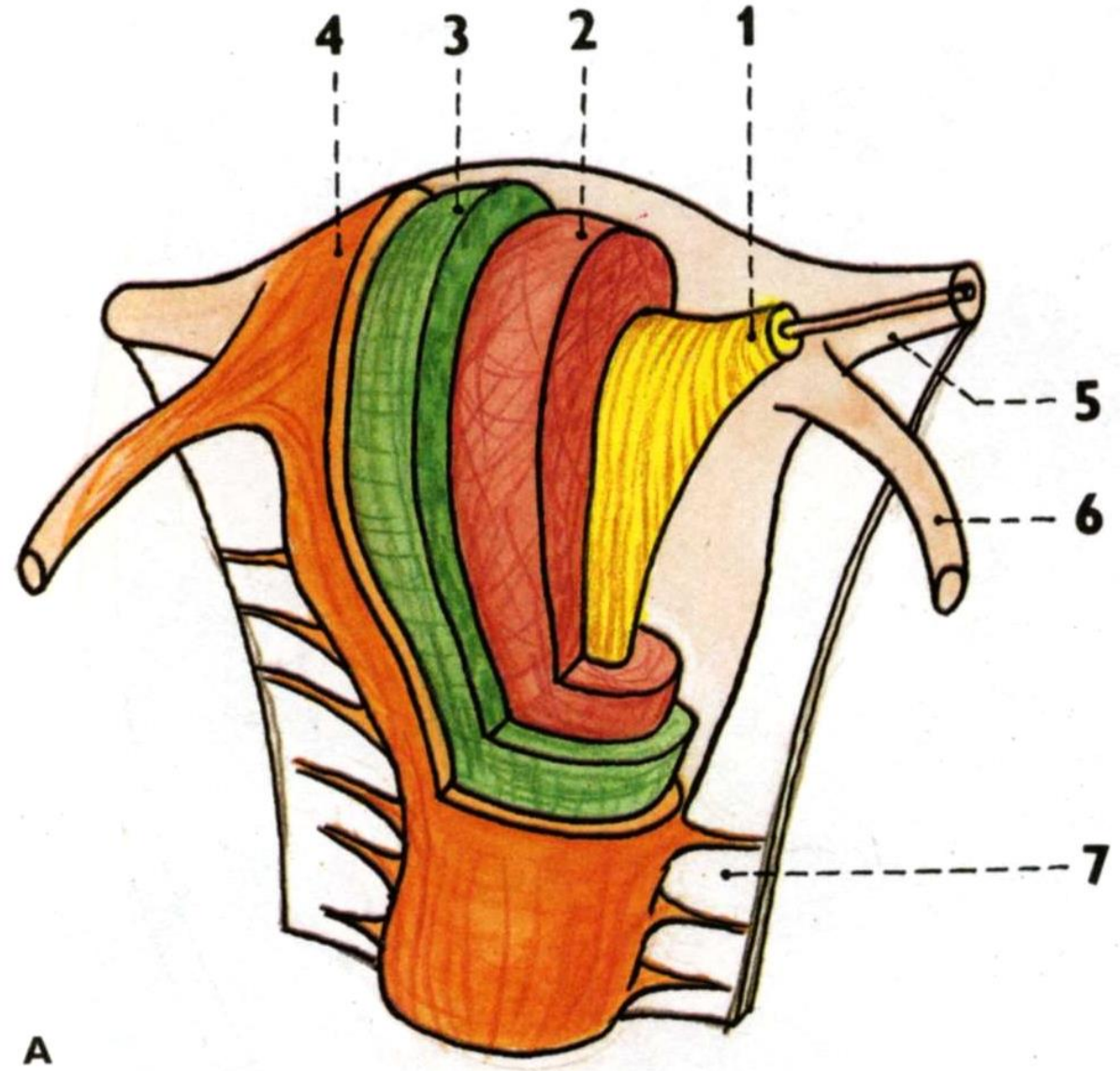
Menstruation cycle

1. Menstruation phase
2. Proliferation phase
3. Secretory phase
4. Ischemia

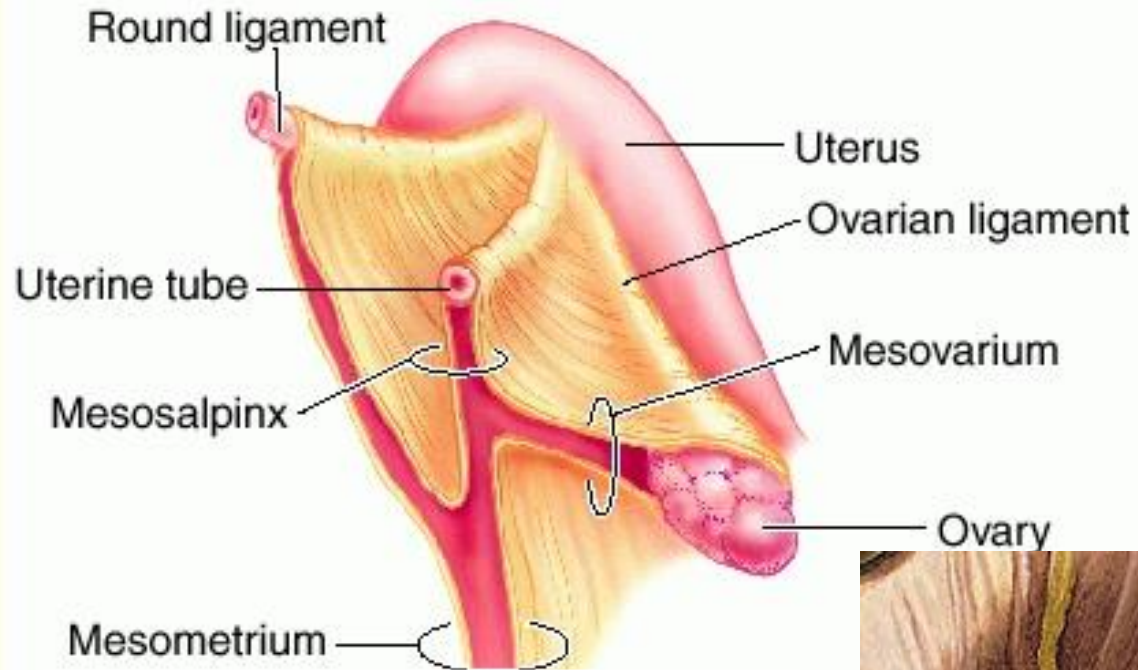


MYOMETRIUM

1. stratum submucosum
2. stratum vasculosum
3. stratum supravasculosum
4. stratum subserosum



PERIMETRIUM (VISCERAL PERITONEUM)

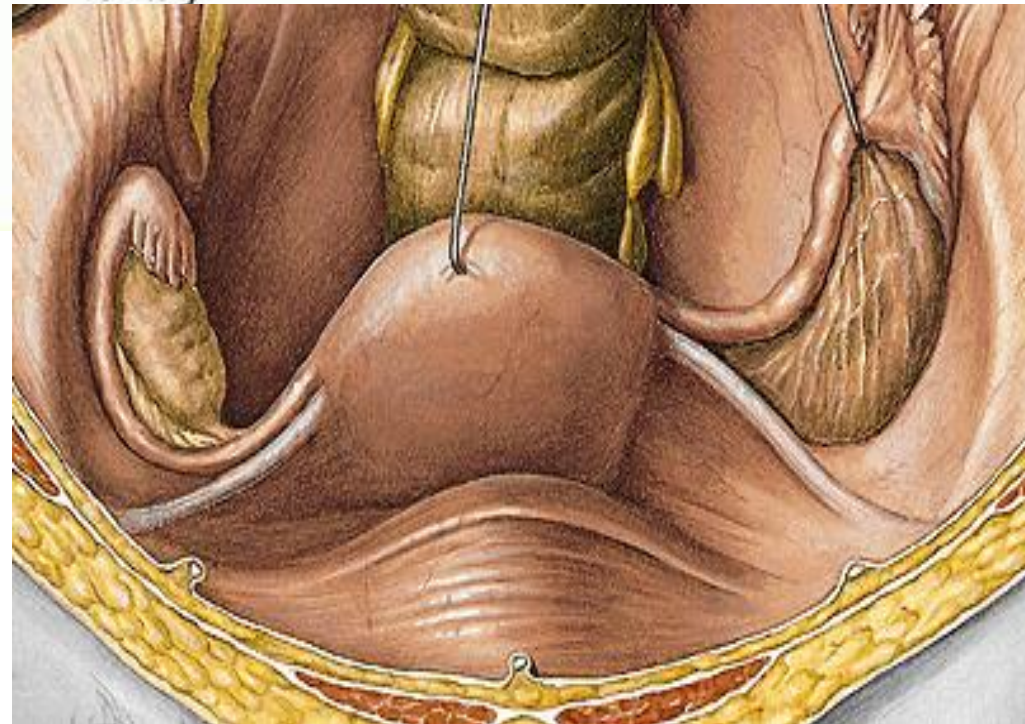


Lig. latum uteri

Mesosalpinx

Mesovarium

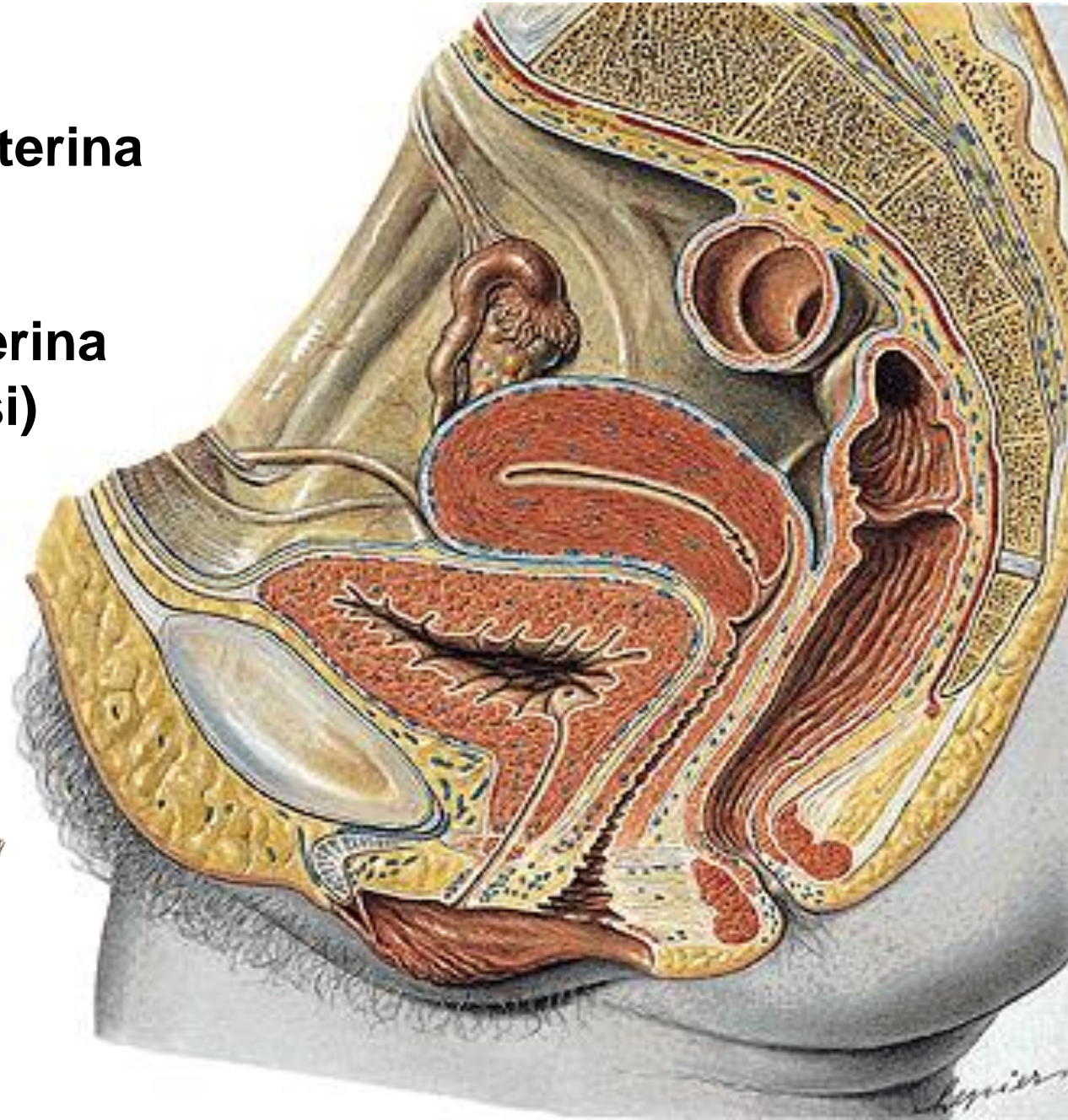
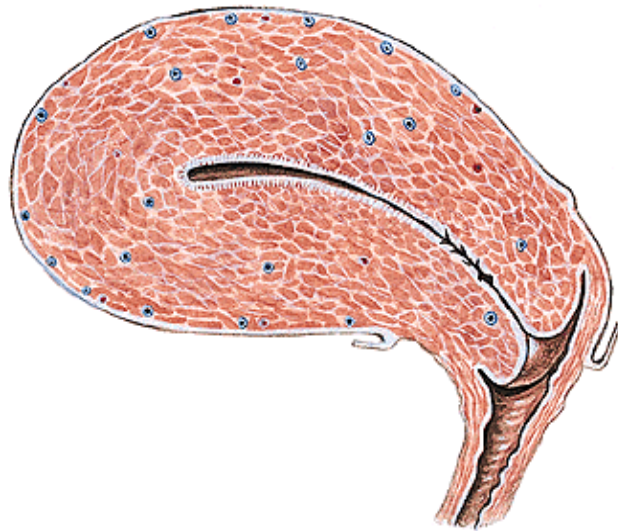
Lig. teres uteri



PERIMETRIUM

Excavatio vesicouterina

**Excavatio rectouterina
(cavum Douglasi)**



PARAMETRIUM

Lig. pubouterinum

lig. pubovesicale

lig. vesicouterinum

Lig. cardinale uteri

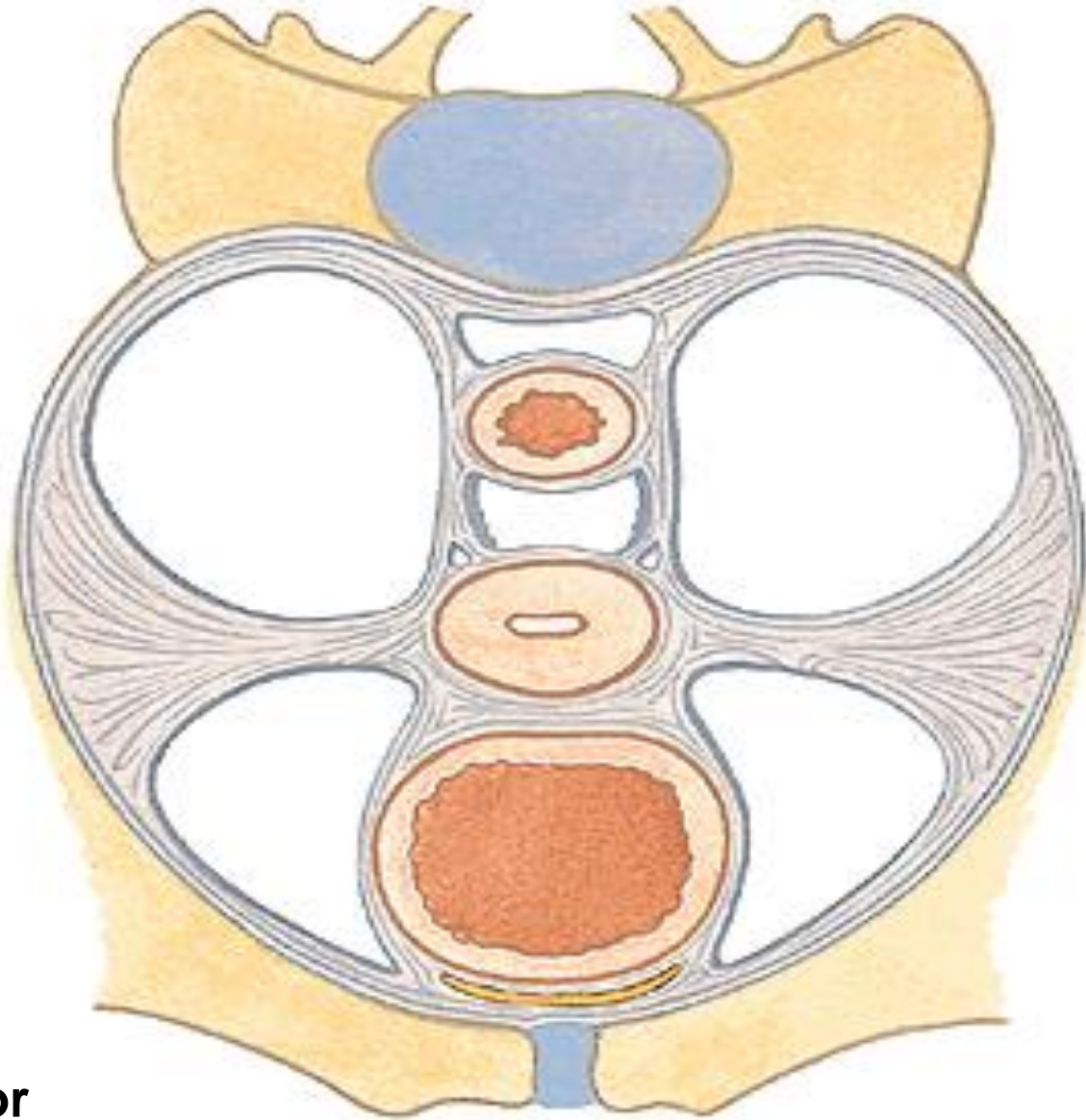
Lig. sacrouterinum

plica sacrouterina

m. rectouterinus

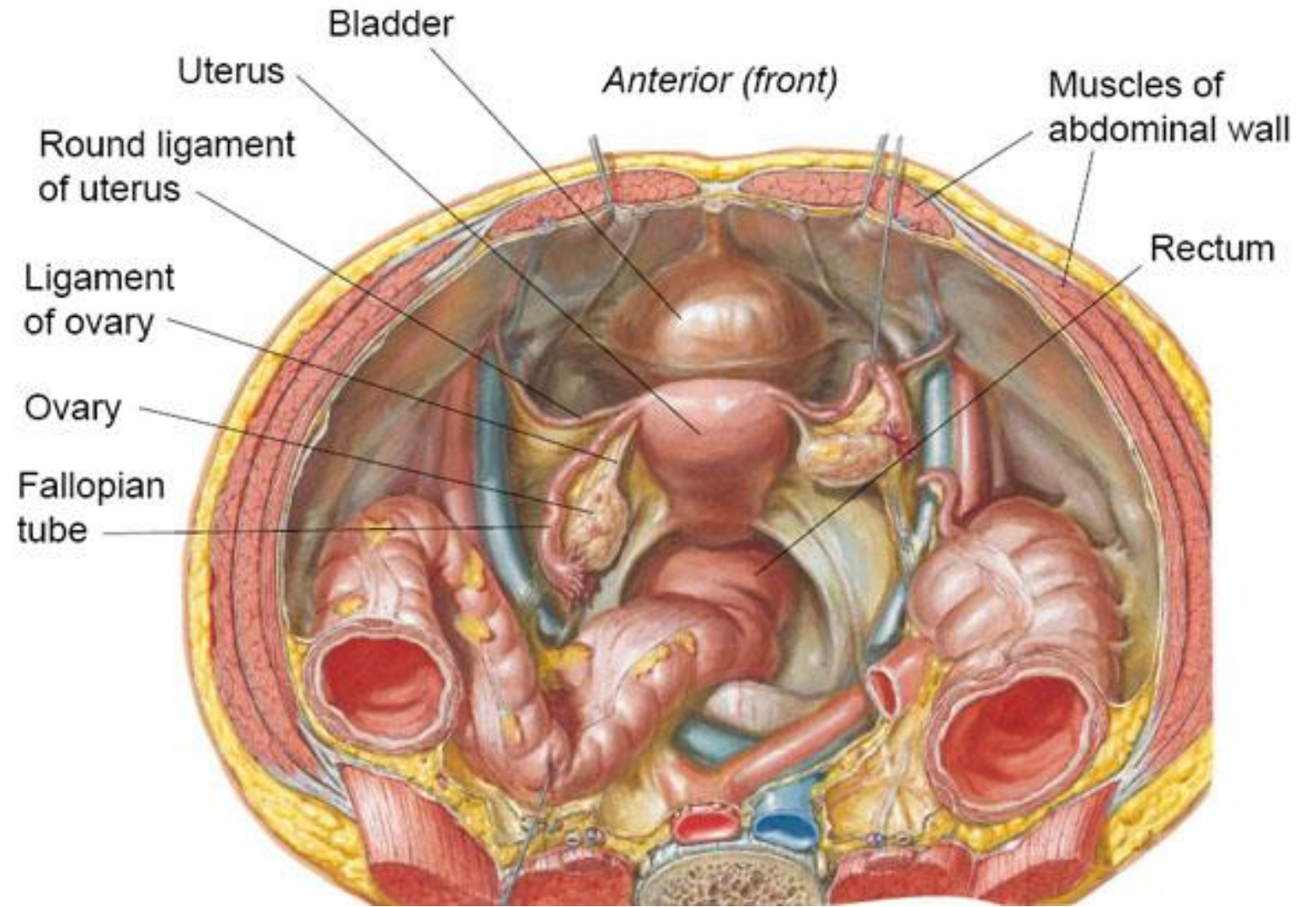
Lig. teres uteri

**Part of fixation apparatus
Together with the pelvic floor**



Plica sacrouterina

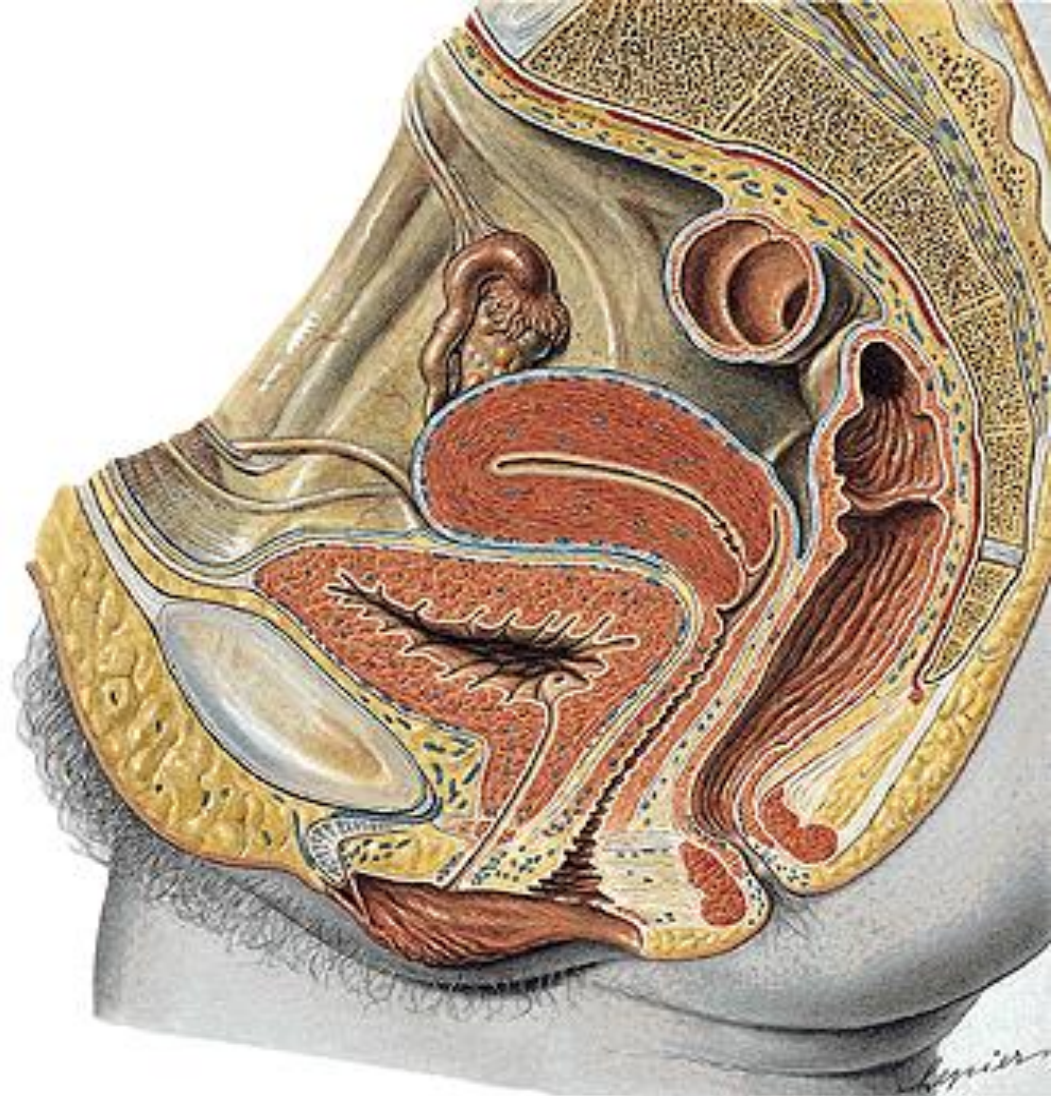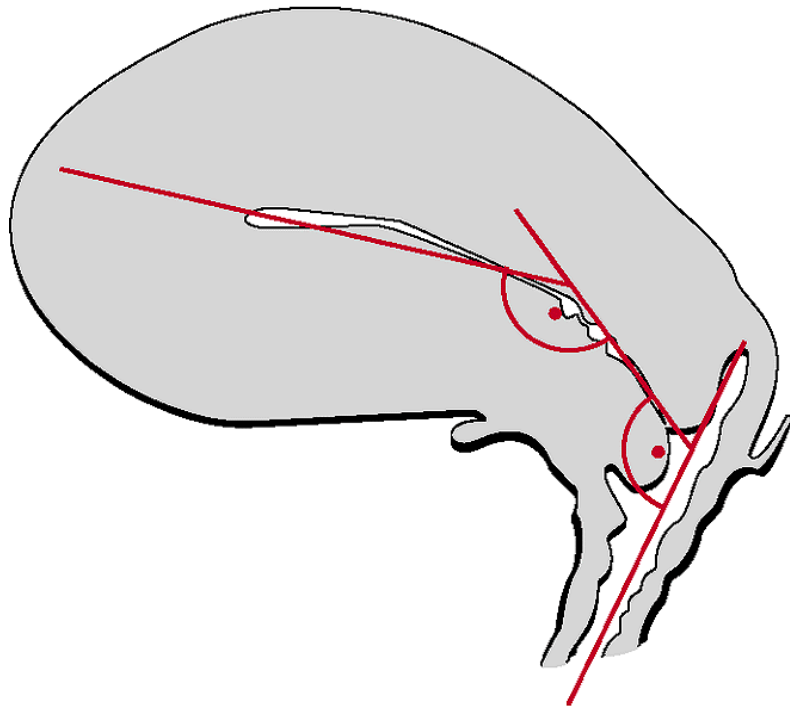
Lig. teres uteri



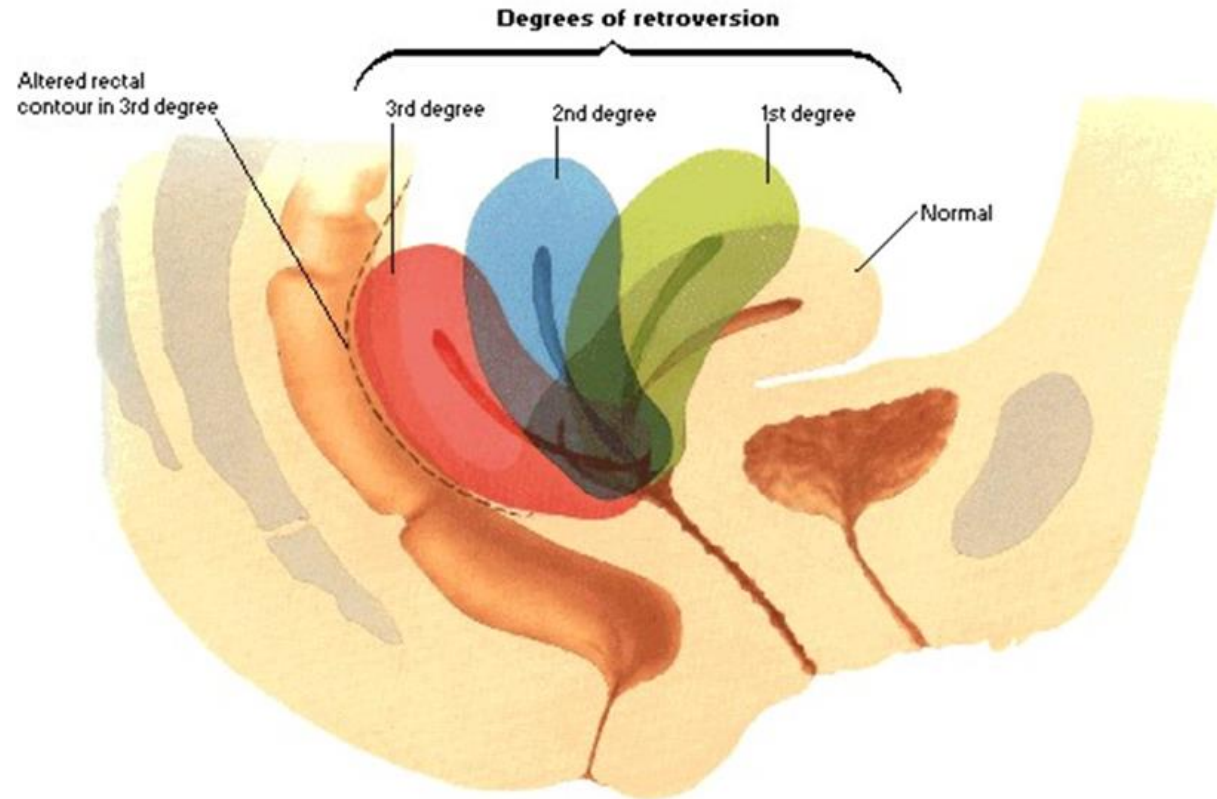
POSITION OF UTERUS

Anteversión ($70^{\circ} - 100^{\circ}$)

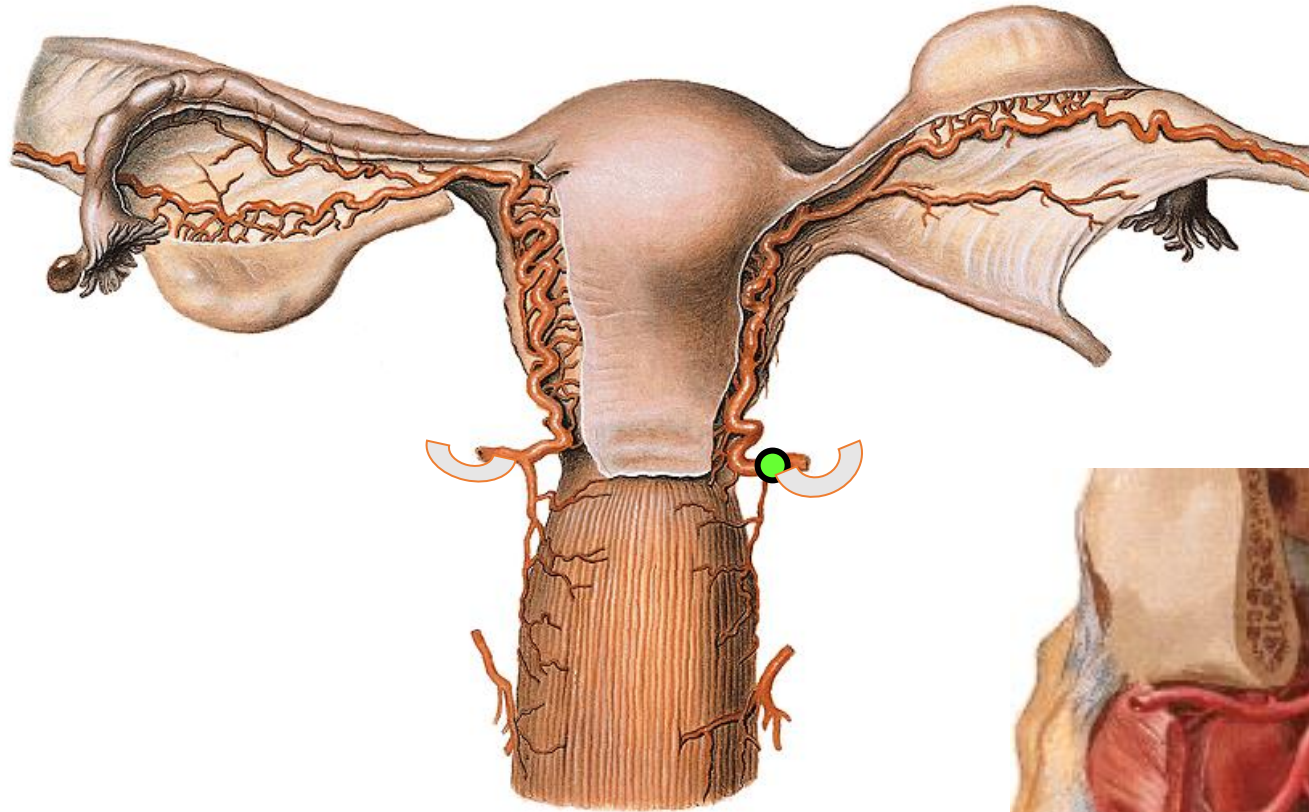
Anteflexión (100°)



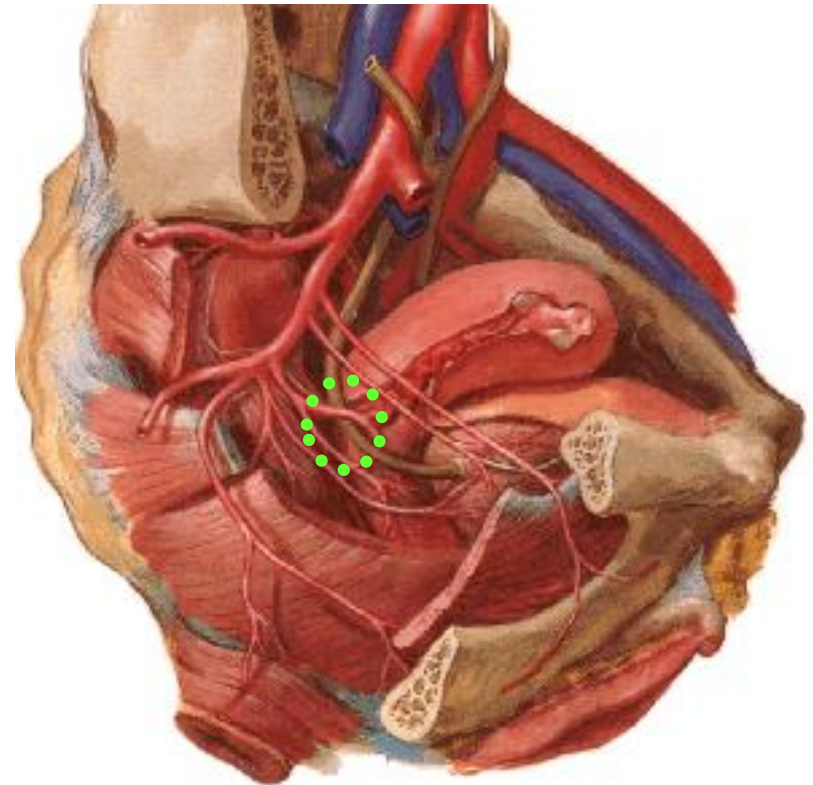
POSITION OF UTERUS

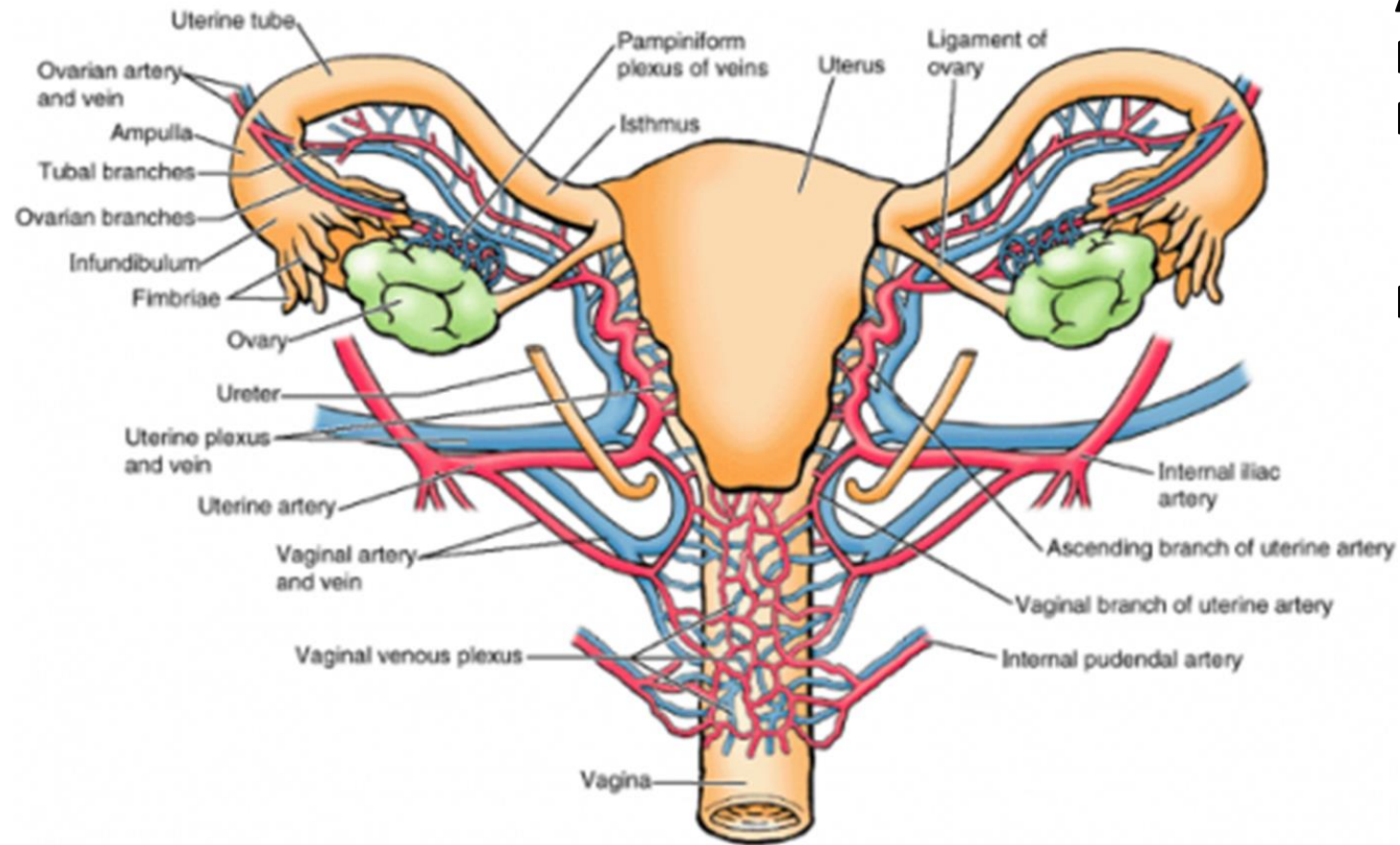


Arteria uterina – anastomosis with a. ovarica (ovarian arcade)



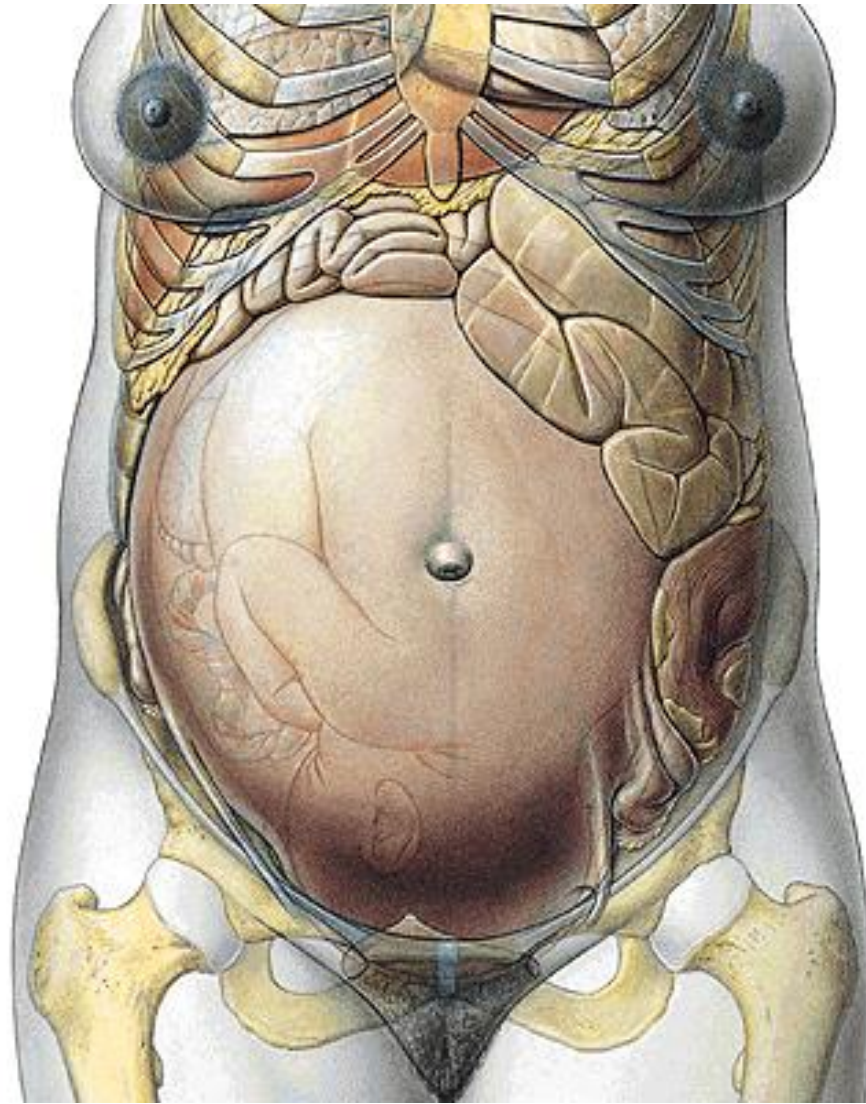
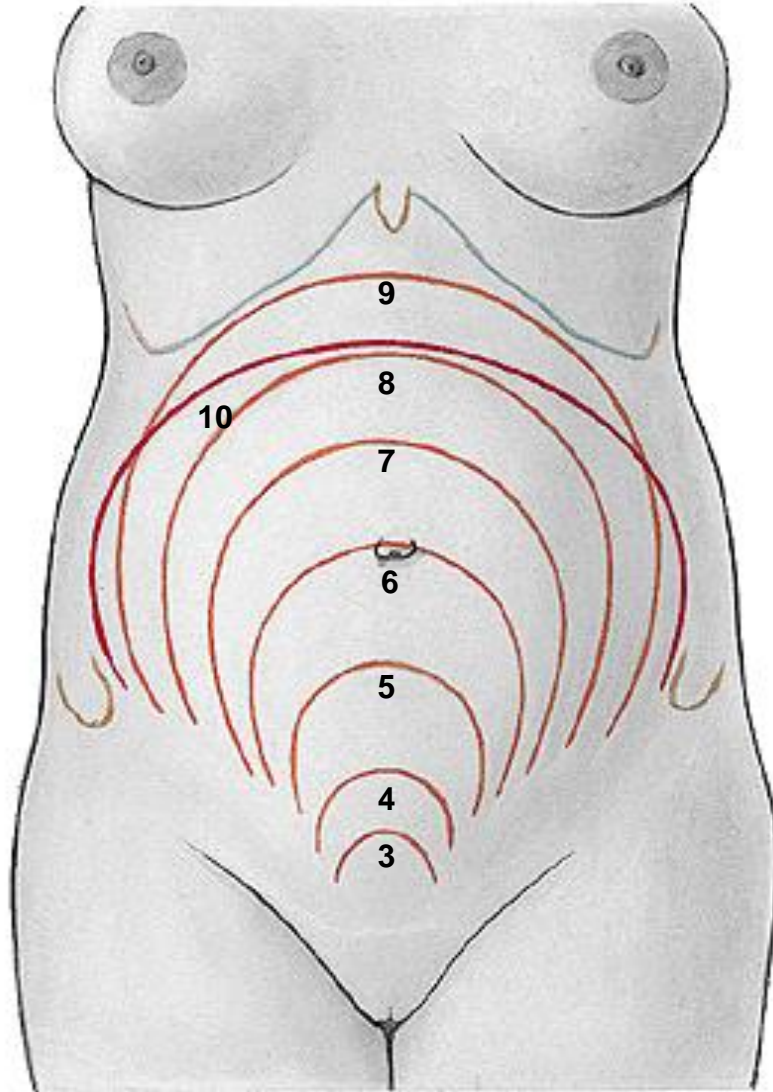
**Uterine artery crosses ureter
(2 cm from uterine margin
1,5 cm from fornix vaginae)**

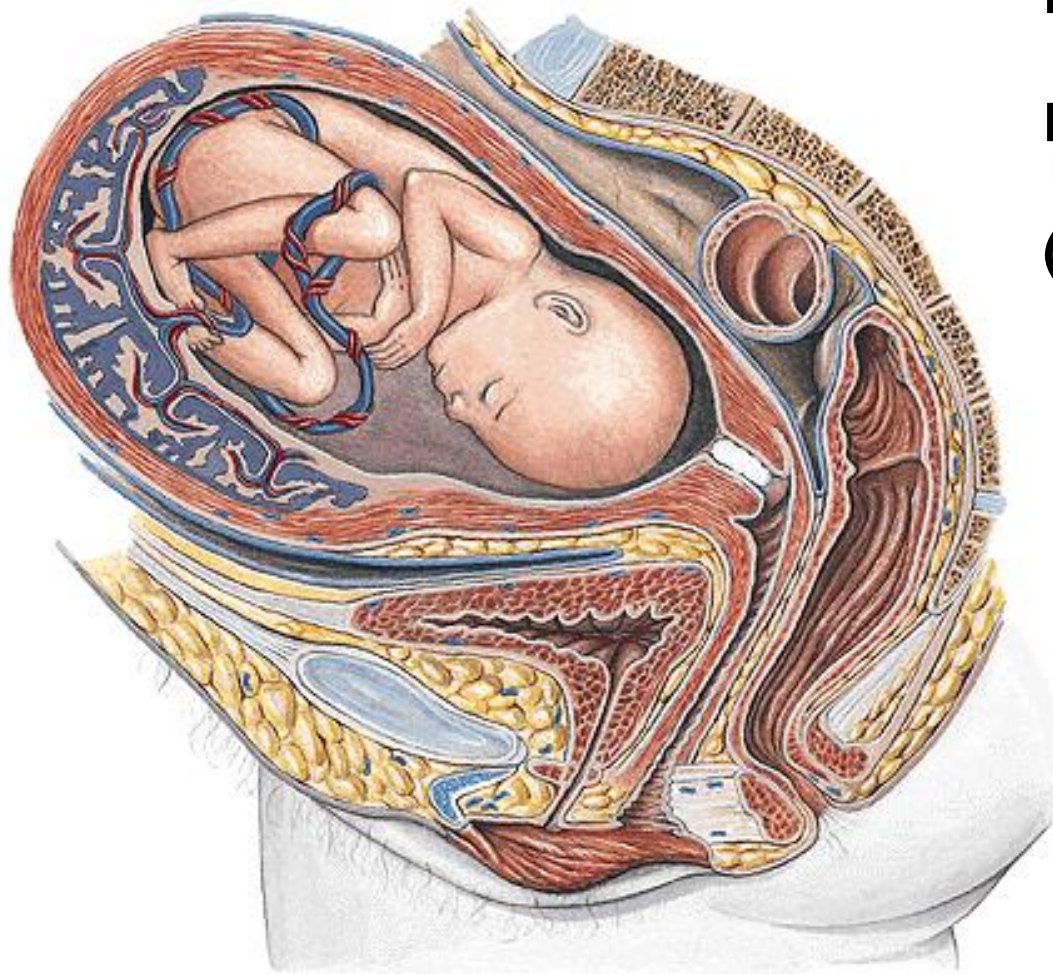



A. uterina x ureter
Plexus venosus uterovaginalis
III. lumbales, iliaci int., iliaci ext.
nodus lymph.uterinus (Bayer),
inguinales spf., sacrales
Plexus uterovaginalis

GRAVIDITY



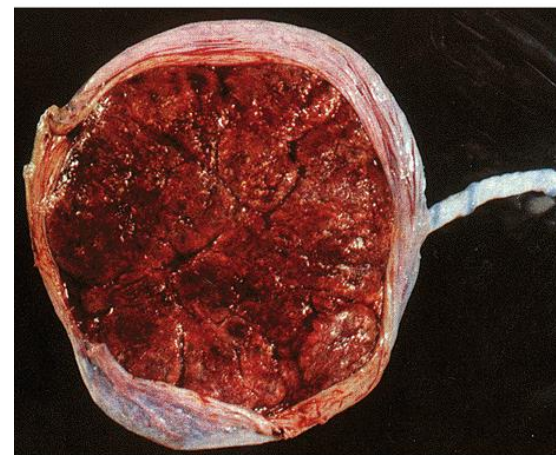
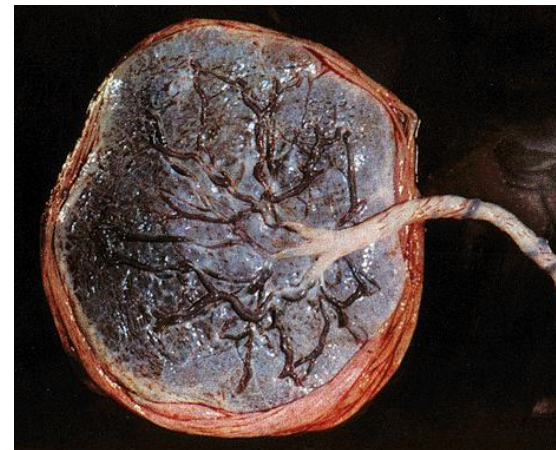

uterus graviditatis – 1000 g

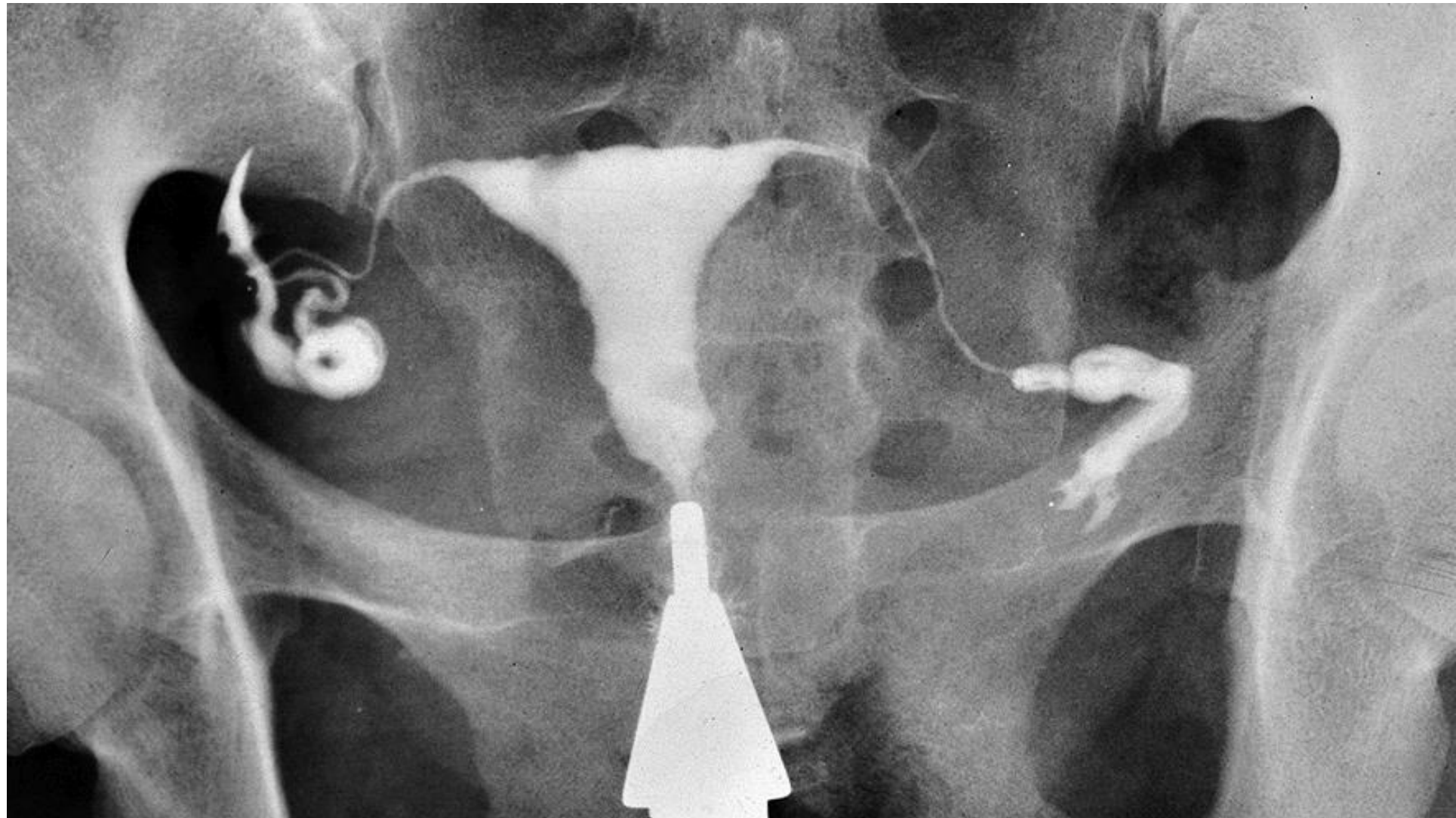
Placenta

Funiculus umbilicalis – 50 cm

(v.umbilicalis, aa. umbilicales)



HYSTEOSALPINGOGRAPHY



VAGINA

Position of vagina

Ventrocaudal direction

Ventrally:

urinary bladder

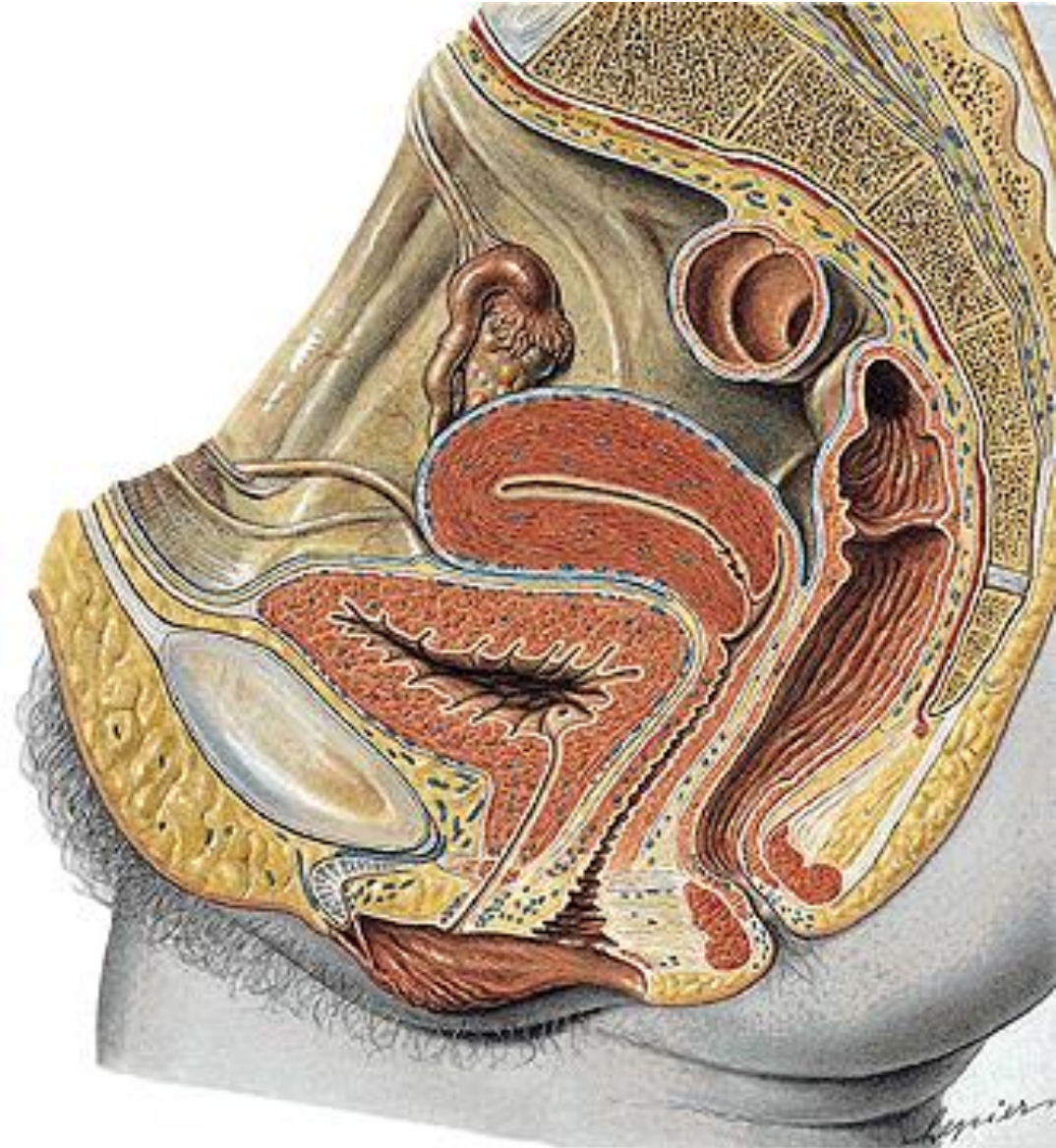
urethra - septum urethrovaginale

Dorsally:

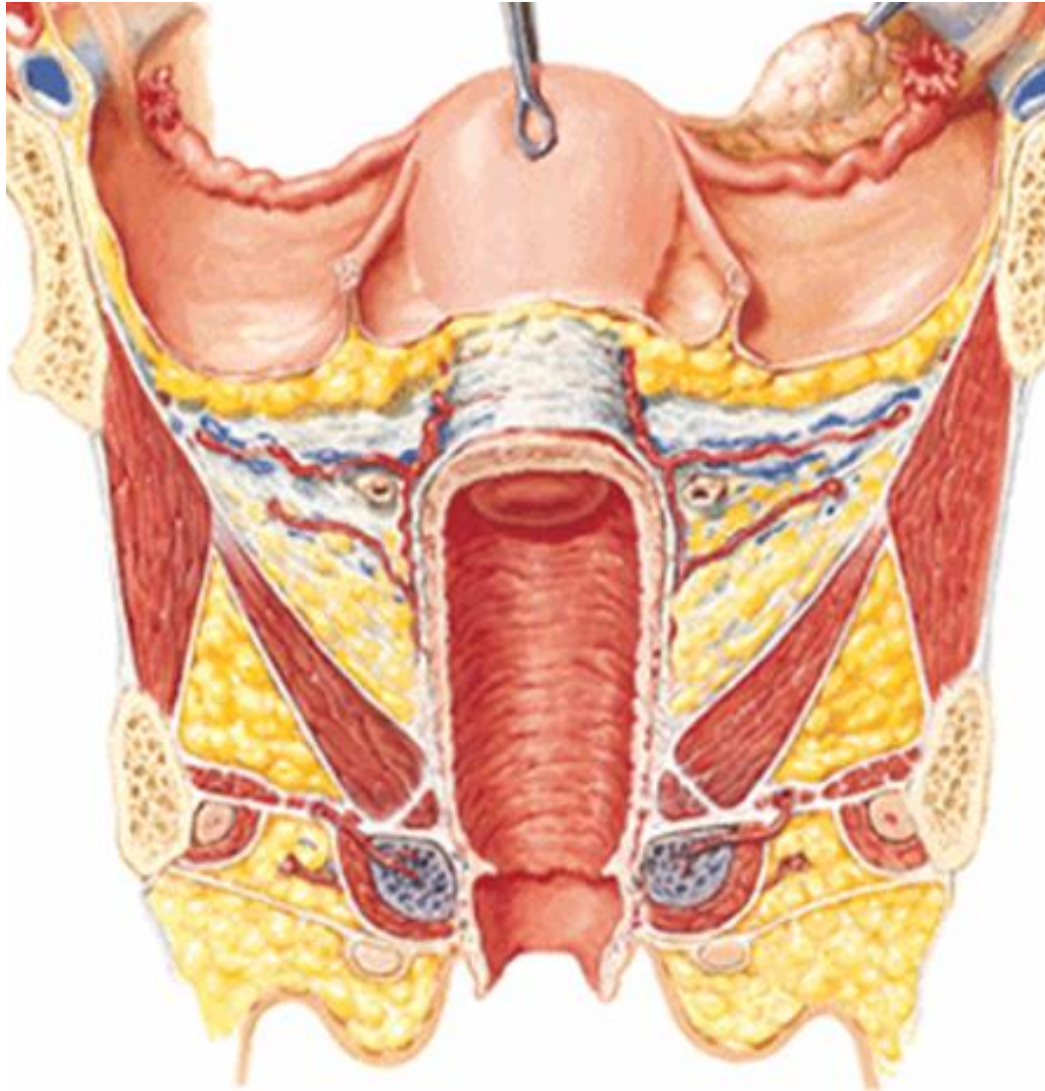
excavatio rectouterina

rectum - septum rectovaginale

centrum perineale



VAGINA (KOLPOS)



Fornix vaginae

pars anterior et posterior

receptaculum seminis

Paries anterior

crista urethralis

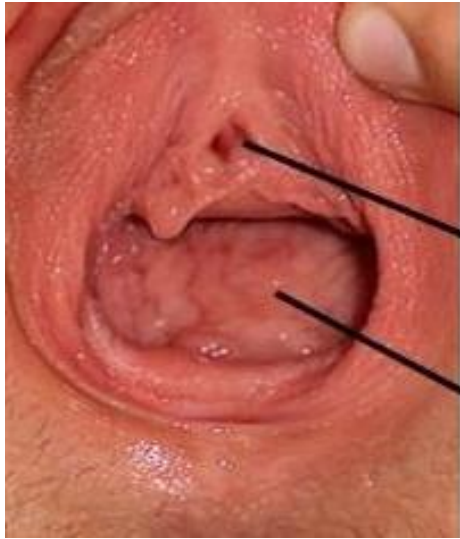area trigonalis vaginae

Paries posterior

Rugae vaginales

Columna rugarum ant. et post.

**Ostium vaginae
(vestibulum vaginae)**



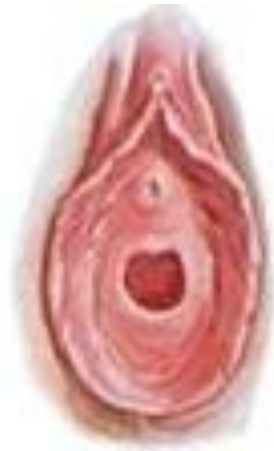Ostium urethrae ext.

Ostium vaginae

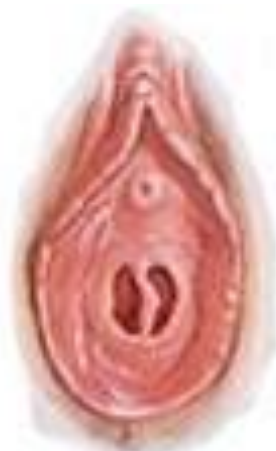Ostium vaginae - hymen

Defloration

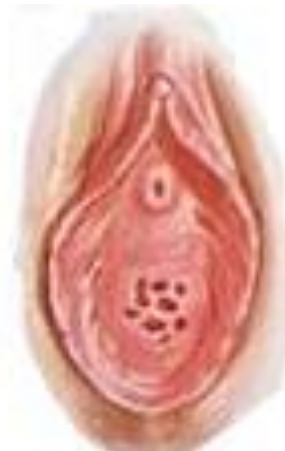Carunculae hymenales



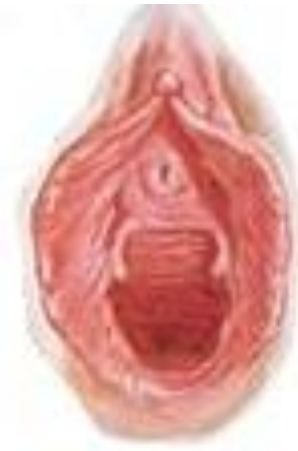ANNULAR
HYMEN



SEPARATE
HYMEN

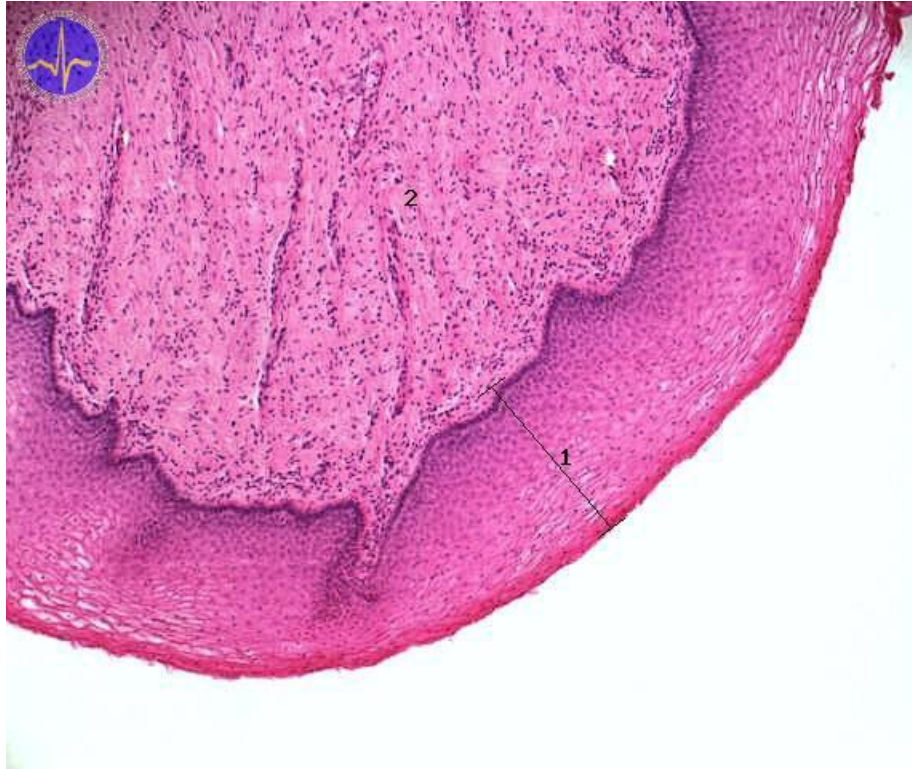

CRIBRIFORM
HYMEN



PAROUS
INTROITUS

HISTOLOGY OF VAGINA



Mucouse membrane

Multilayer squamous epithelium

No glands !!!

submucouse tissue – venous net

Muscular layer

inner - circular

outer - longitudinal

Adventicia (paracolpium)

Serosa – excavatio rectouterina

A. uterina

- **a. vaginalis**

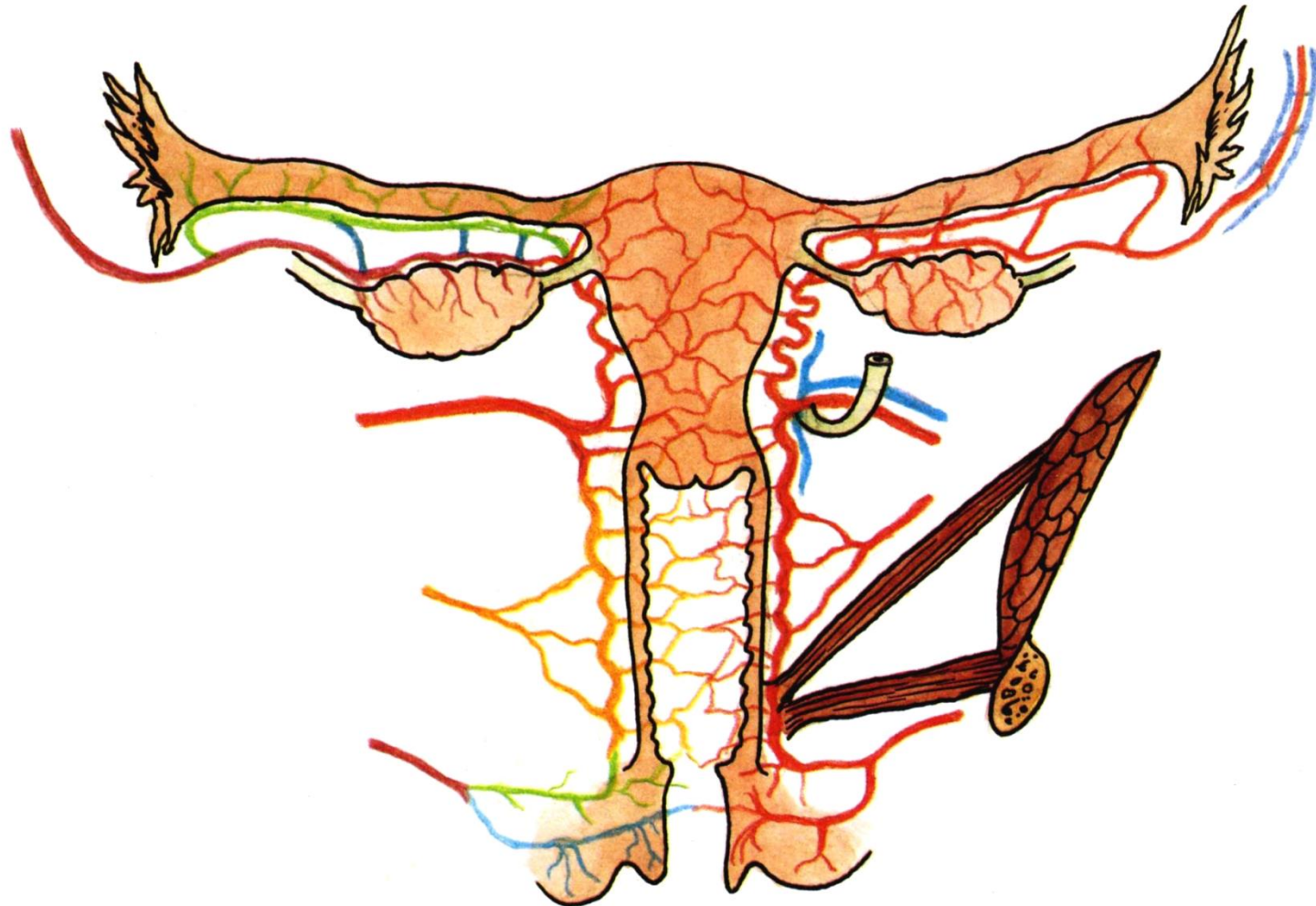
A. rectalis media

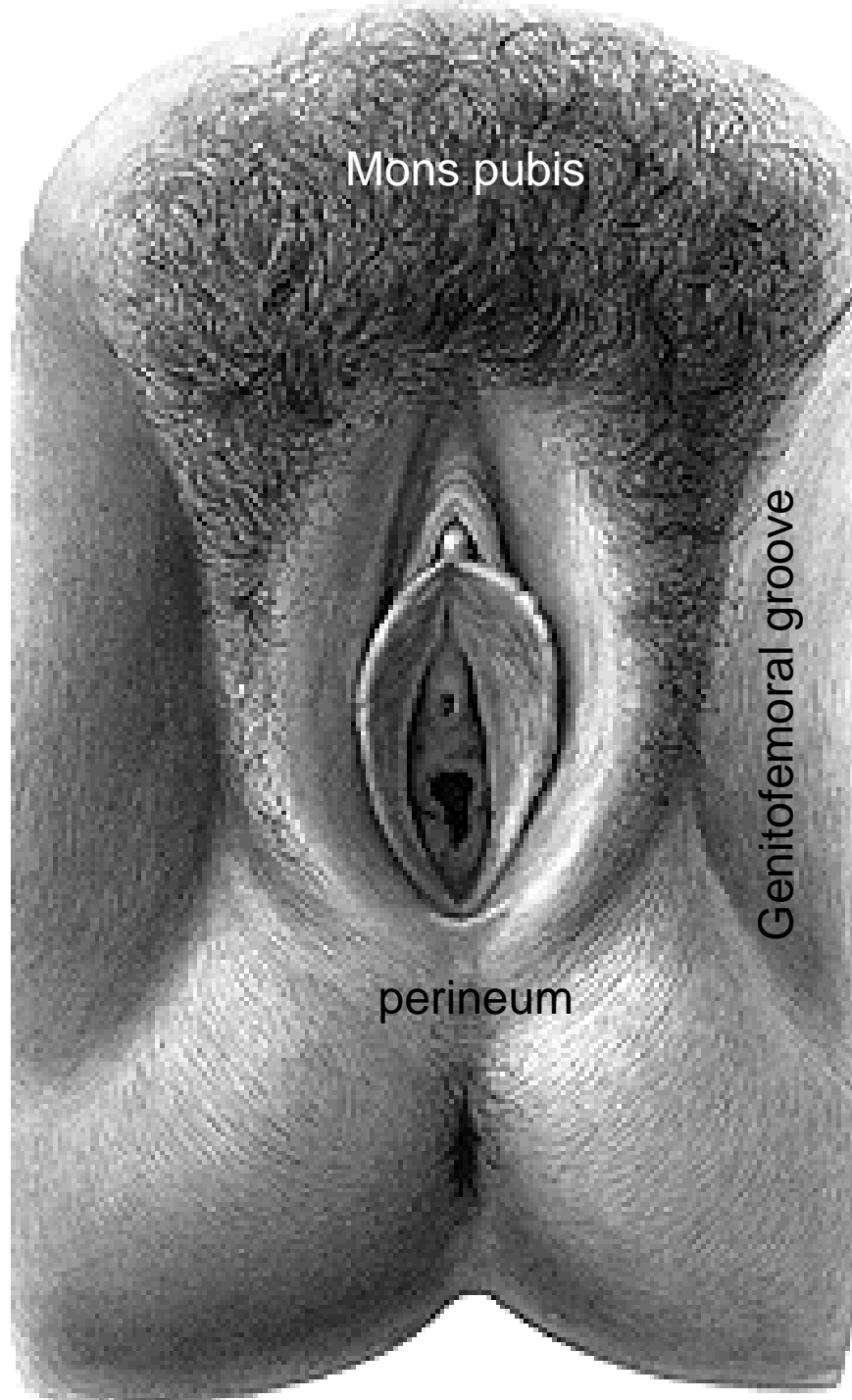
A. pudenda int.

Plexus venosus uterovaginalis

Nll. iliaci int., ext, inguinales spf.

Plexus uterovaginalis, n. pudendus





Organa genitalia feminina externa

Mons pubis (pubes, fatty tissue)

Labia majora pudendi

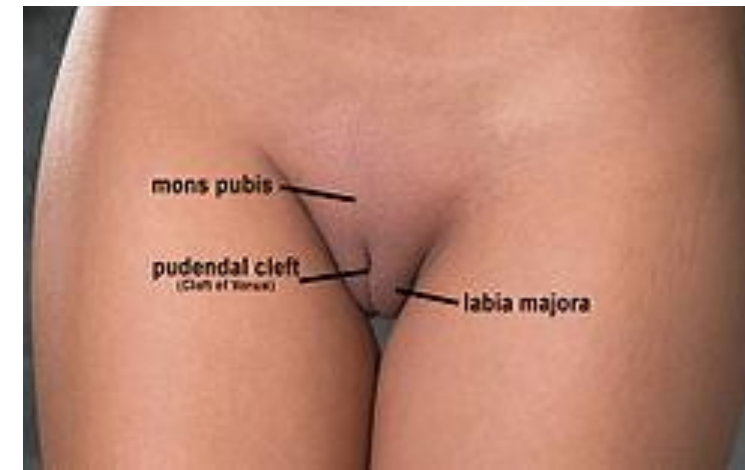Labia minora pudendi

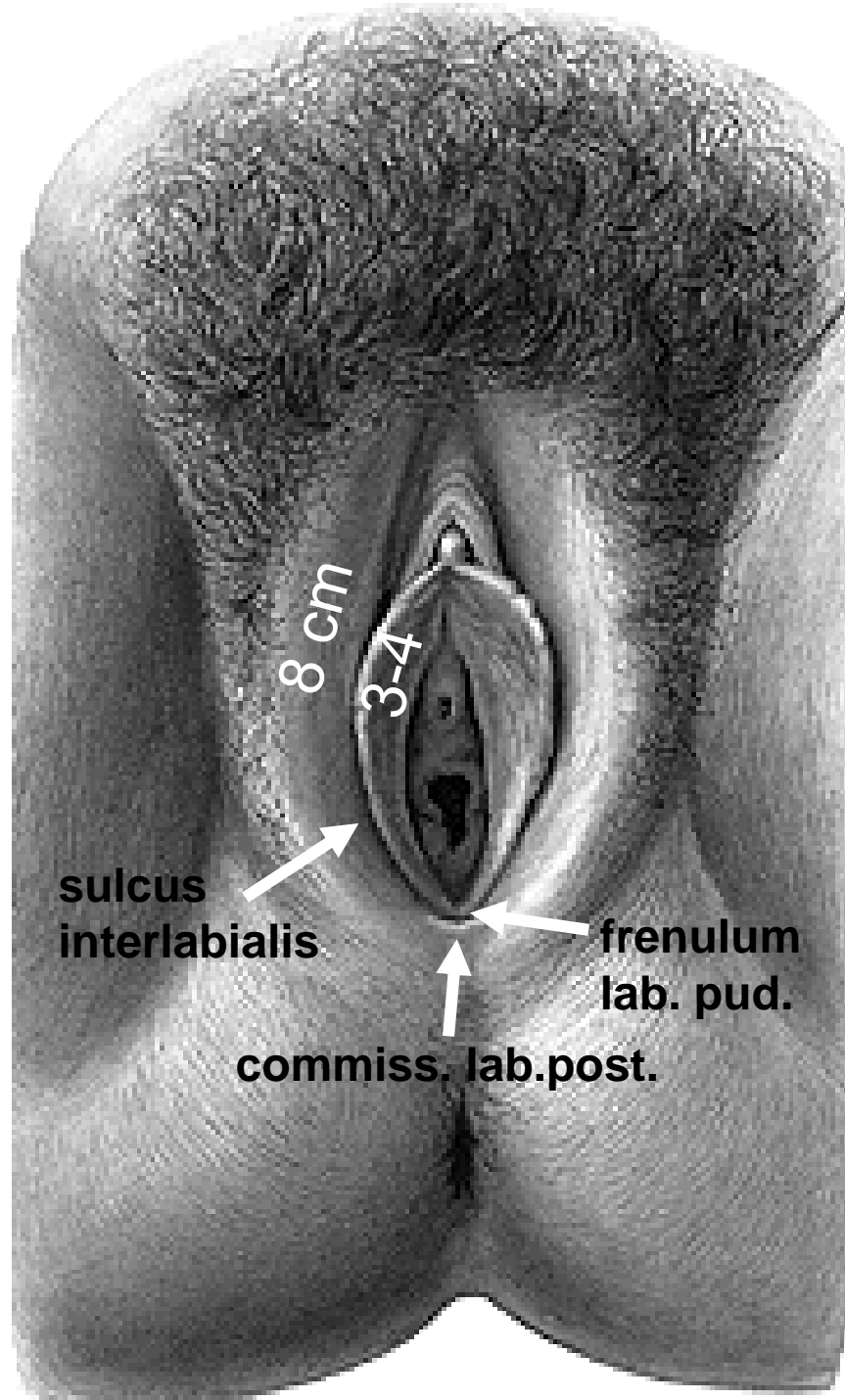
Vestibulum vaginae

Clitoris

Bulbi vestibuli

Gll. vestib. maj. et min.





Labia majora pudendi

Sulcus genitofemoralis

Rima pudendi

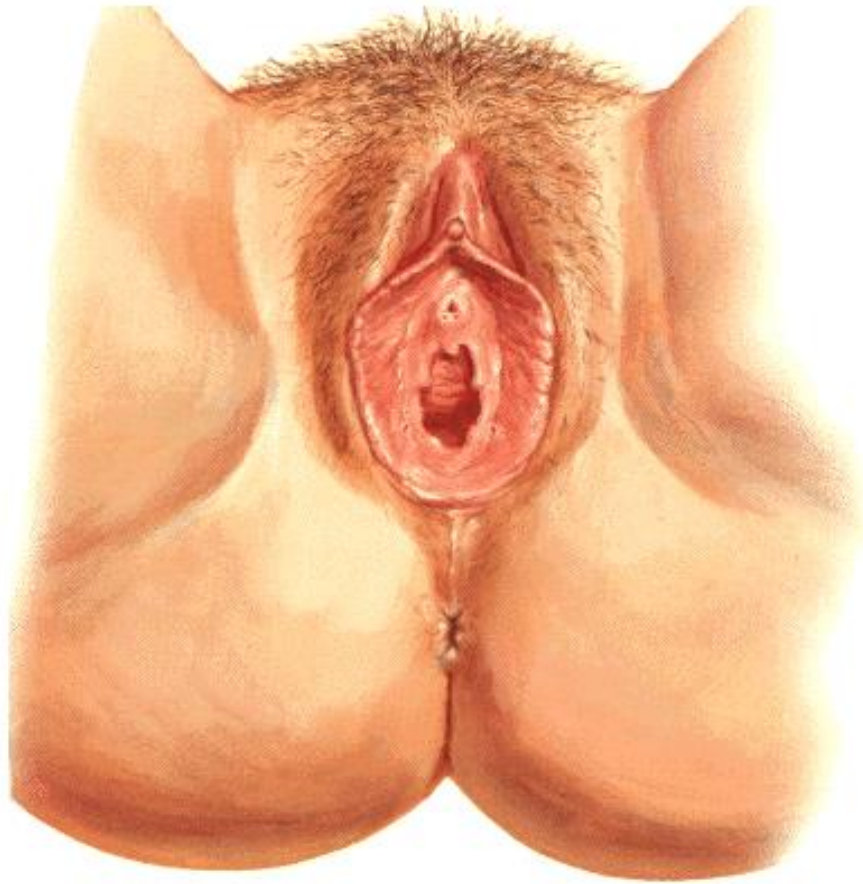Commissura labiorum ant.

Perineum (raphe perinei)

Connective tissue, fat

lig. teres uteri

Labia minora pudendi



Sulcus interlabialis

Vestibulum vaginae

Smegma – sebaceous glands

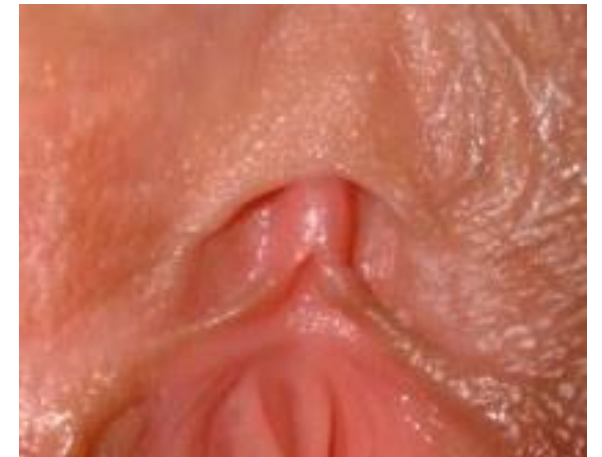**Elastic and collagenous connective tissue,
venous plexus, nerve endings**

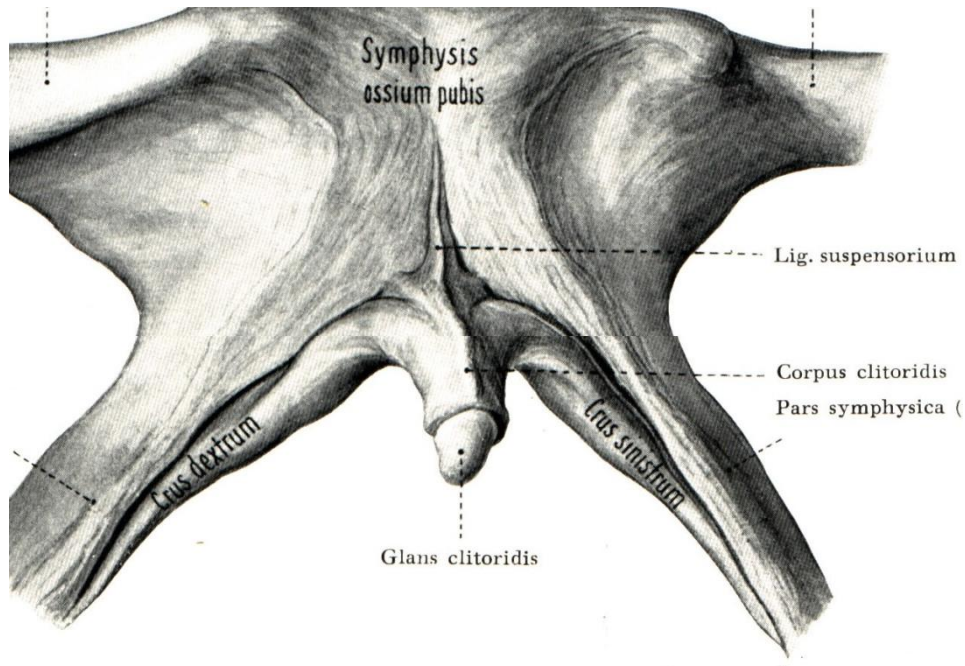
Frenulum labiorum pudendi

Fossa navicularis
between vagina and frenulum

Praeputium clitoridis

Frenulum clitoridis





CLITORIS

**Crura clitoridis
(crista phallica)**

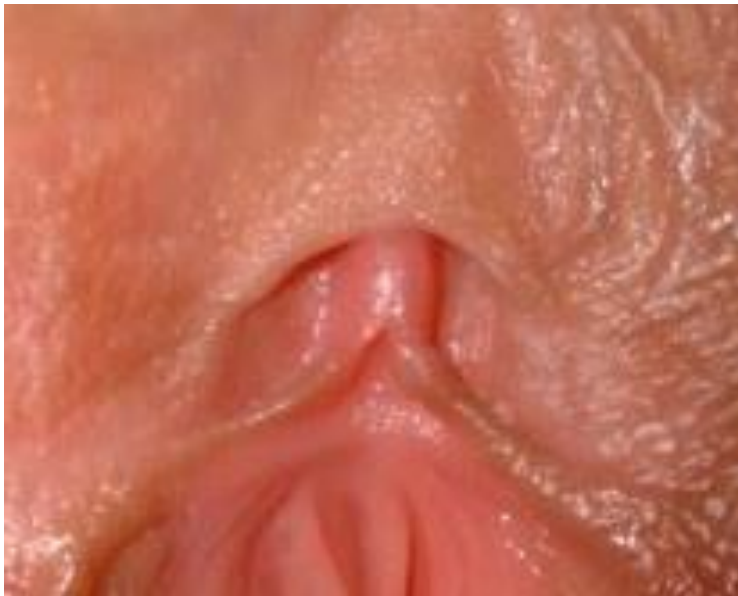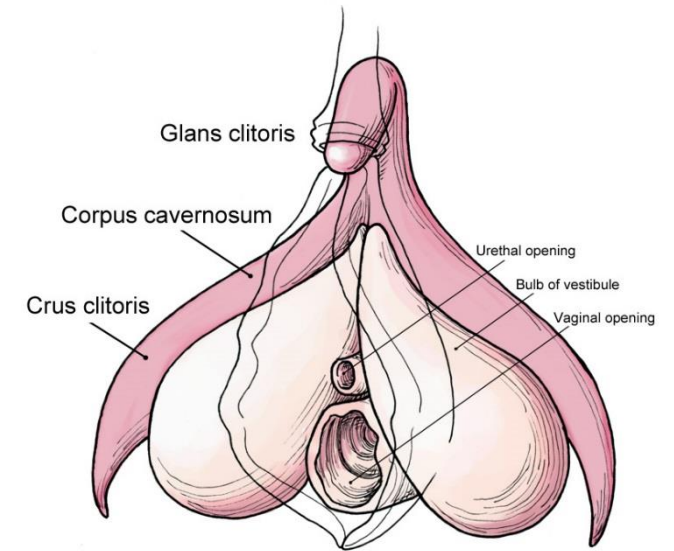
Corpus clitoridis

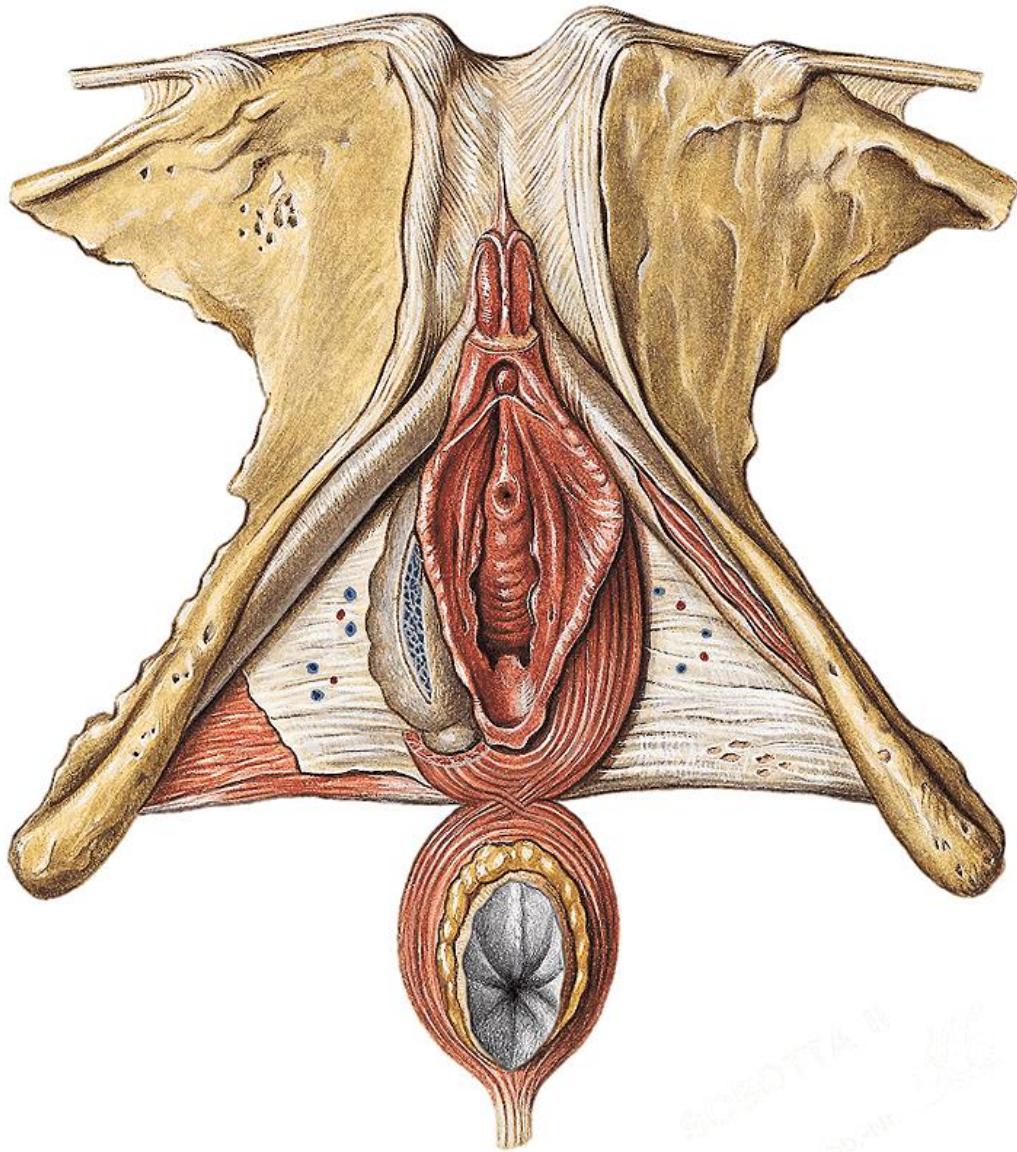
Glans clitoridis

Praeputium clitoridis

Frenulum clitoridis

Corpora cavernosa clitoridis





Lig. fundiforme clitoridis

Lig. suspensorium clitoridis

M. ischiocavernosus

VESTIBULUM VAGINAE

between labia minora pudendi

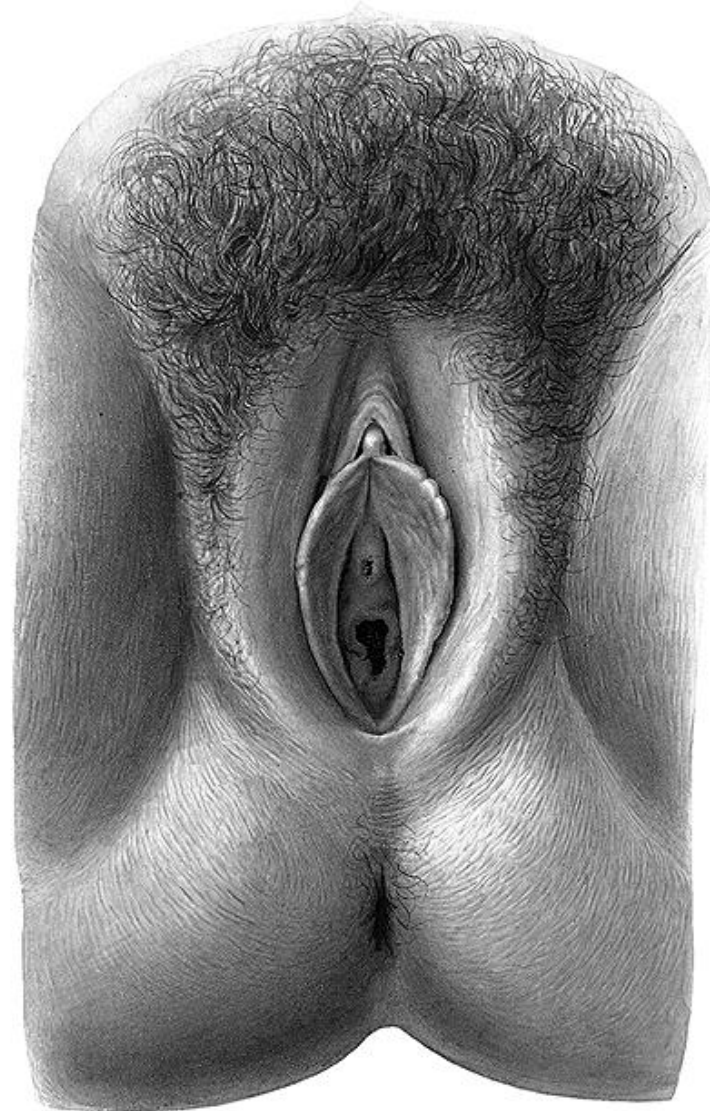Glans clitoridis
(praeputium et frenulum clitoridis)

Ostium urethrae externum
(papilla urethralis, gl. vestib. minores
- between ostium urethrae et. and
vestibule of the vagina, rare in human females)

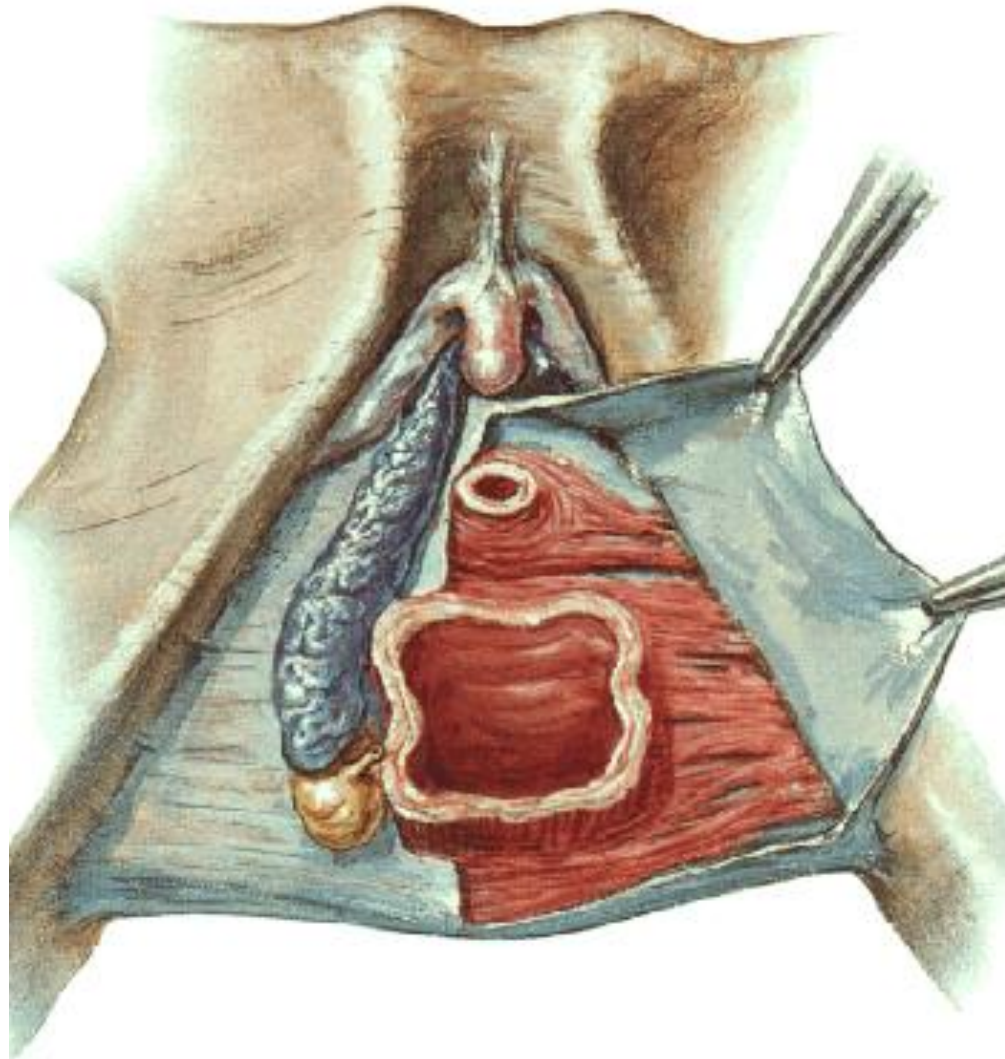
Ostium vaginae (hymen)

Fossa navicularis

Frenulum labiorum pudendi
(commisura labiorum pudendi)



BULBI VESTIBULI



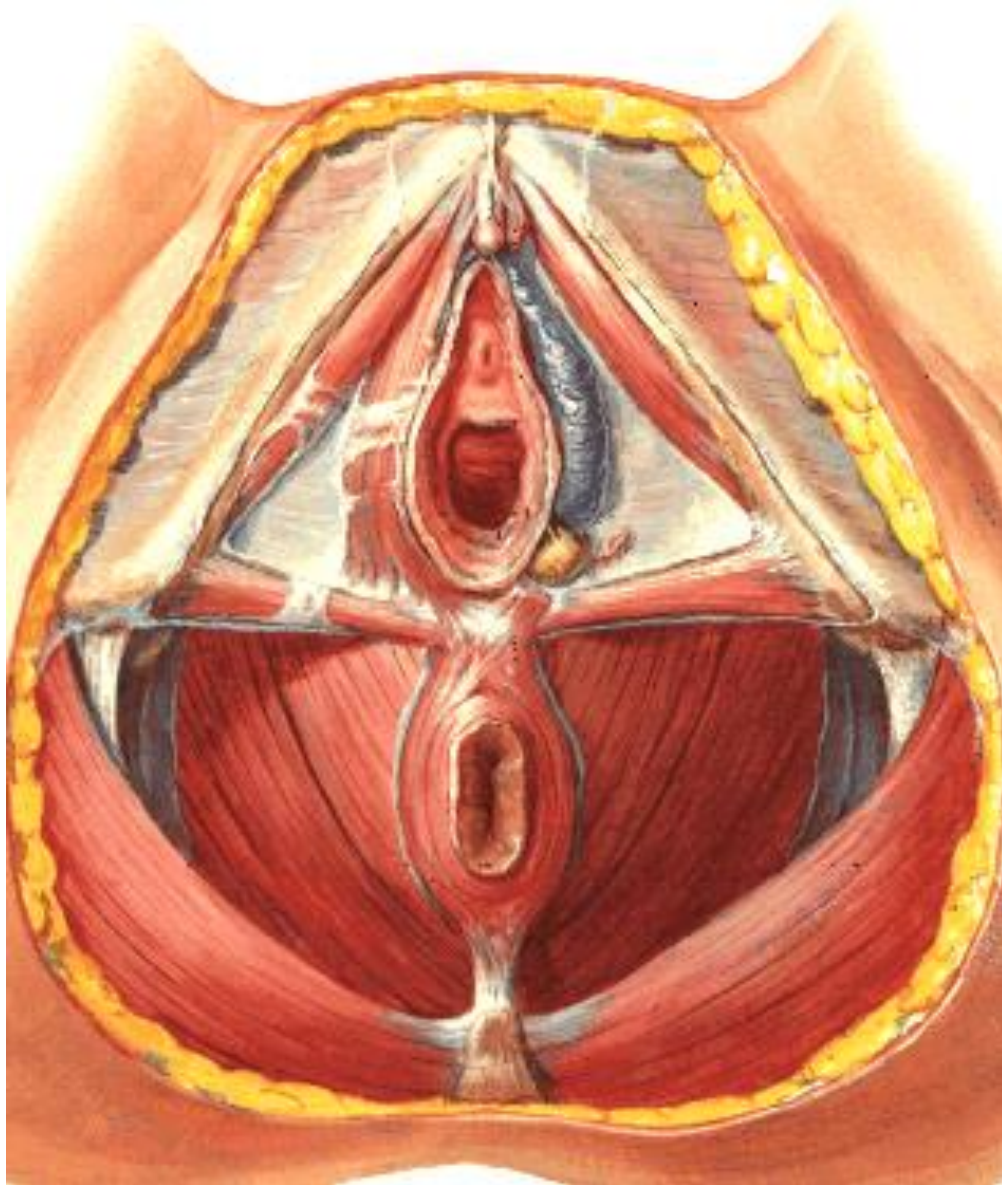
**Erectile bodies
(corpus spongiosum)**

**On (below) diaphragma
urogenitale**

**m. bulbospongiosus
(from centrum tendineum
perinei to the dorsum
clitoridis)**

**commisura bulborum
(between glans clitoridis and
ostium urethrae ext.)**

GLANDULAE VESTIBULARES MAJORES (BARTHOLINI)

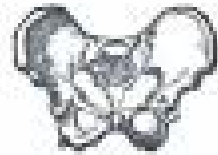
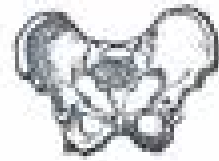
**On the diaphragma
urogenitale
Dorsally from bulbi
vestibuli**

m. bulbospongiosus

**Open to the vestibulum
vaginae**

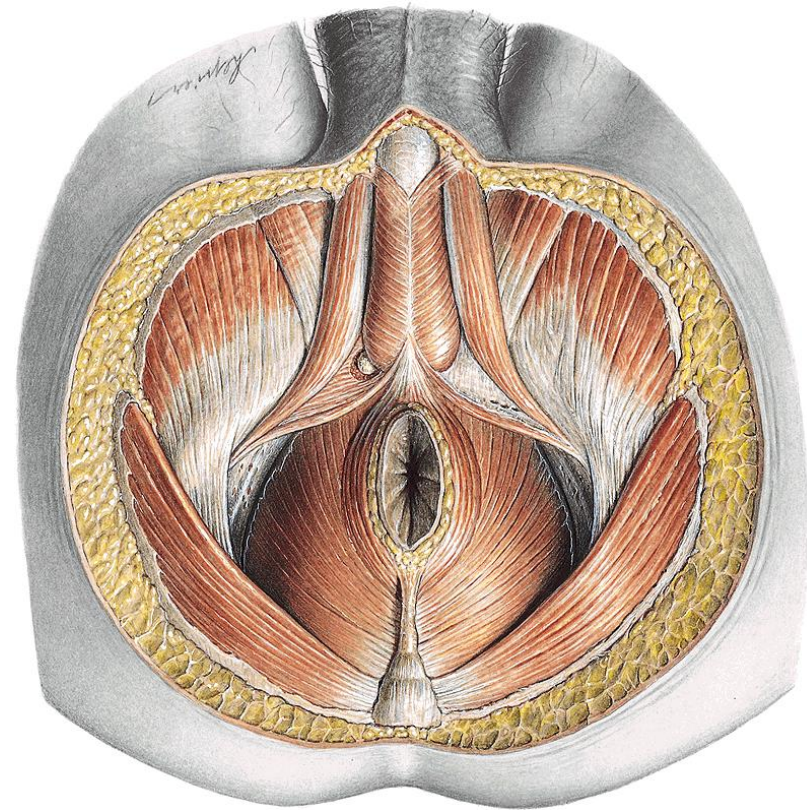
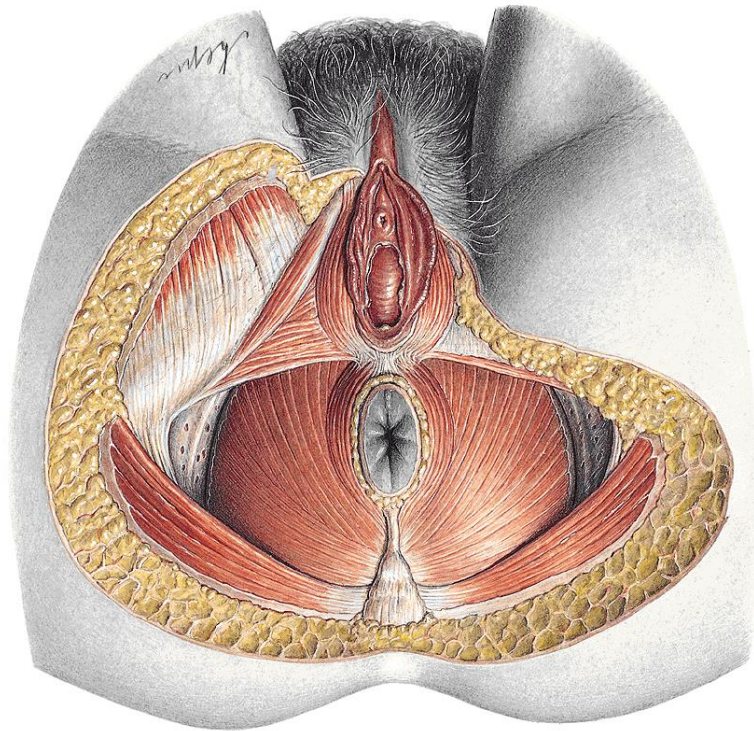
PELVIC FLOOR



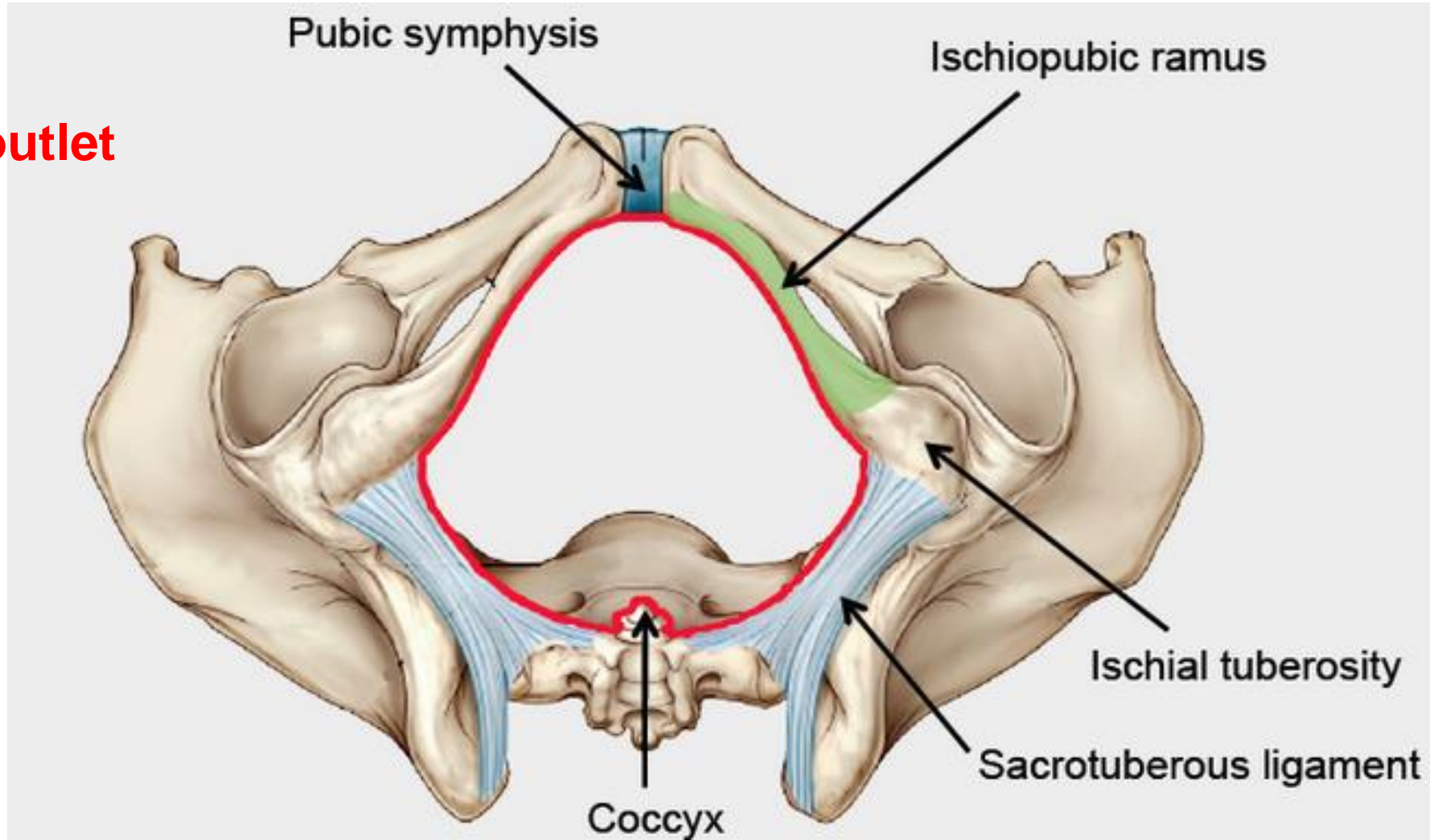
Hip hip

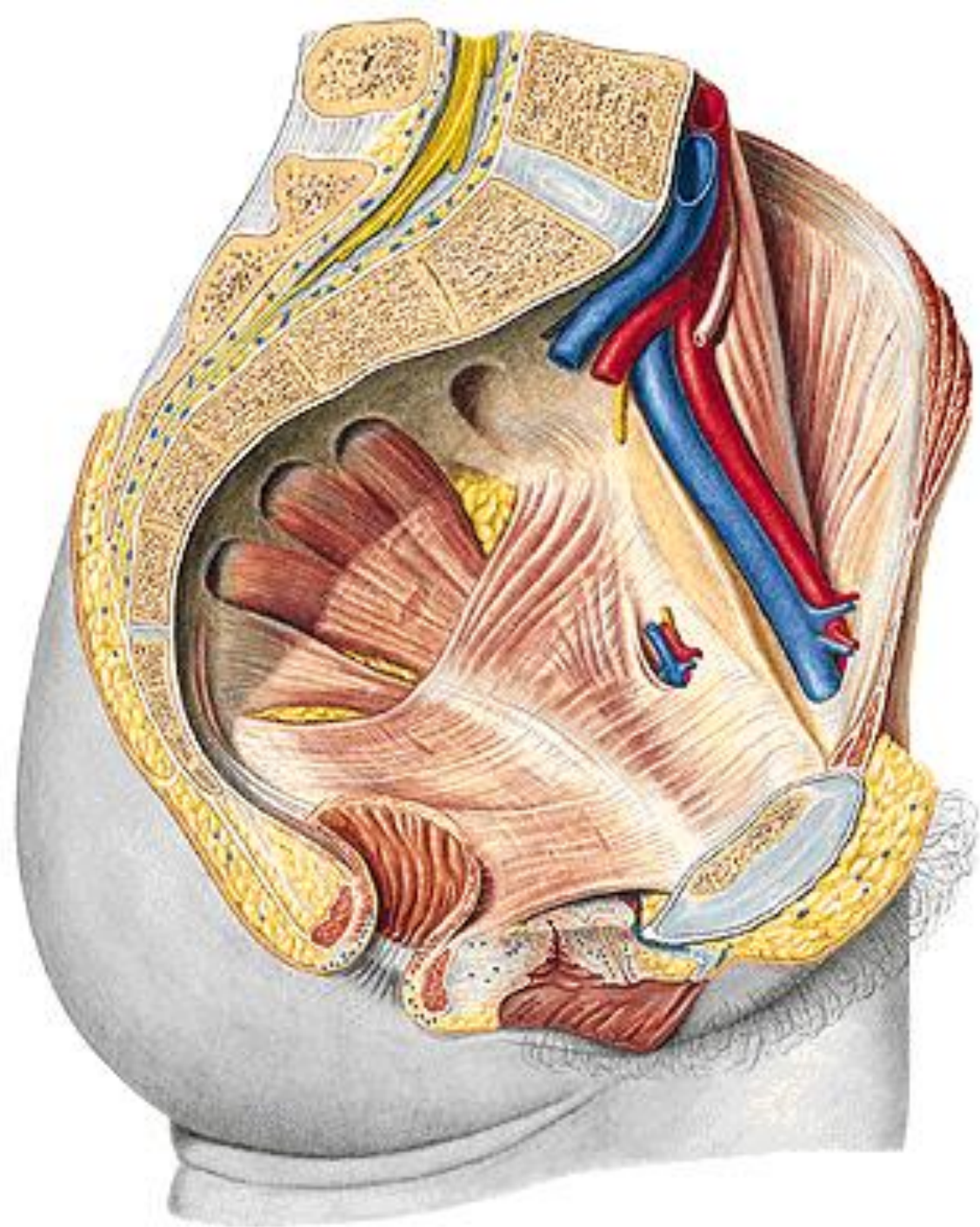
Hooray!

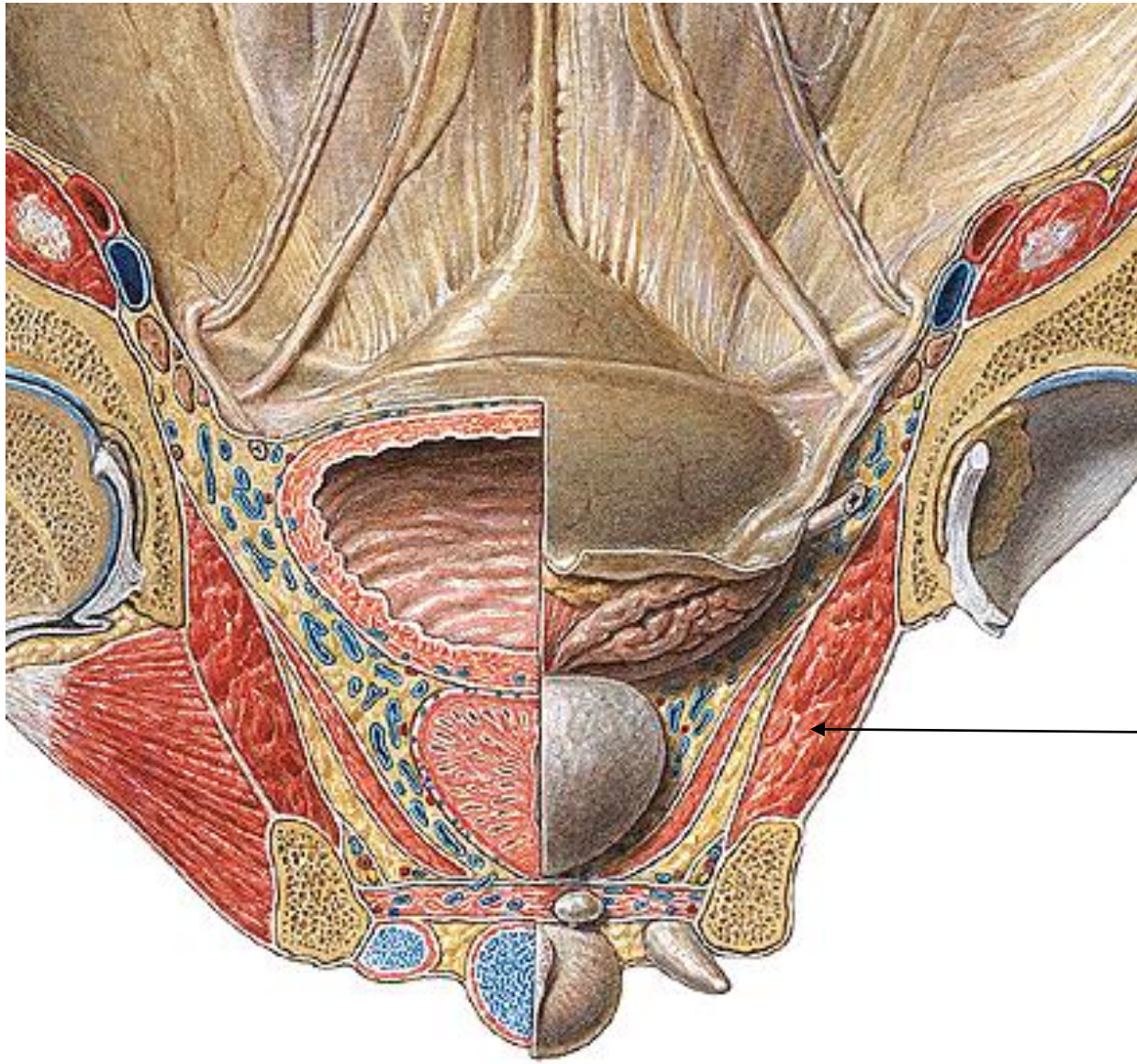
- **Diaphragma pelvis**
- **Perineal membrane (Deep perineal pouch , diaphragma urogenitale)**
- **Superficial perineal pouch**



Pelvic outlet



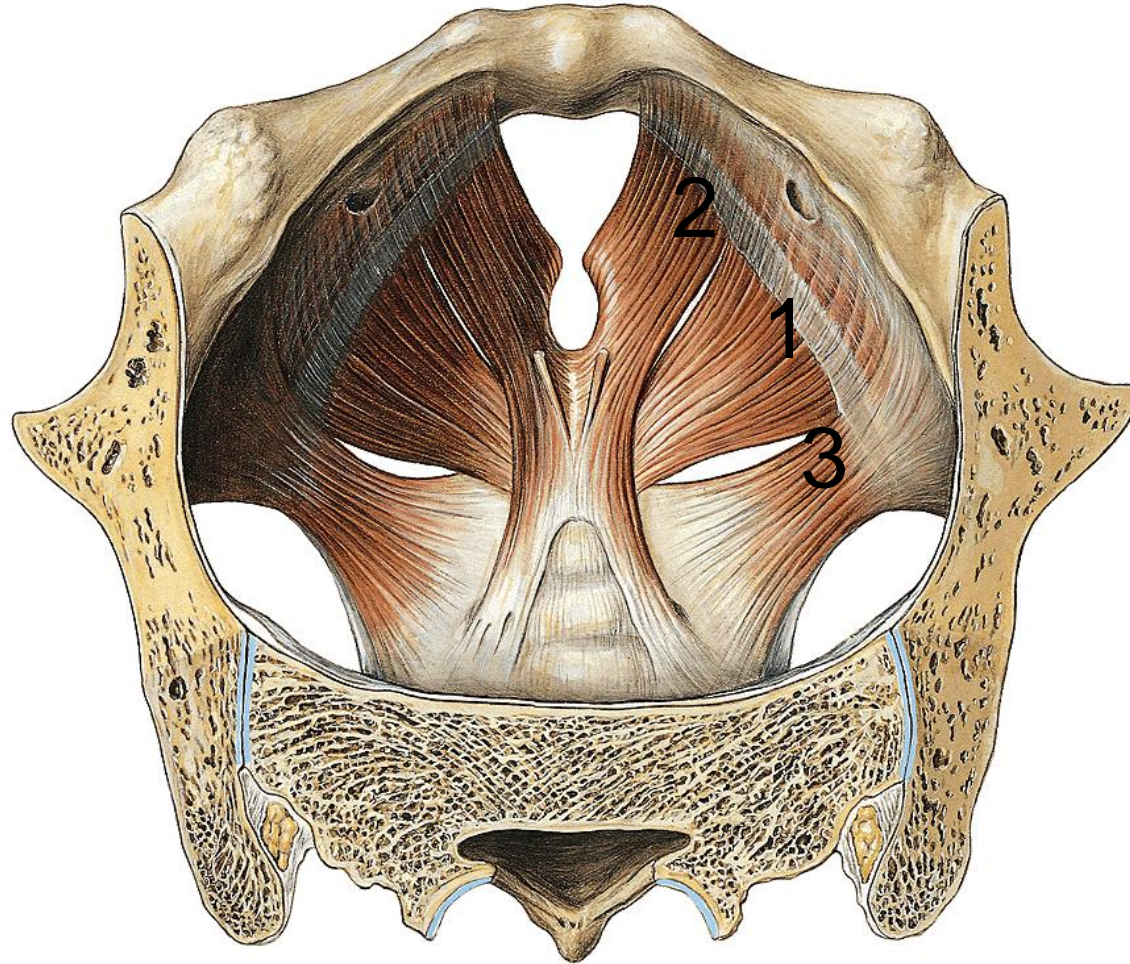




m. obturatorius int.

MUSCLES OF THE PELVIC DIAPHRAGM

Diaphragma pelvis



M. levator ani

1 pars iliaca

2 pars pubica

Hiatus urogenitalis
opening for rectum

3 M. coccygeus

Fascia diaphragmatis pelvis
sup. et inf.

Innervation: *sacral plexus*

Support the pelvic viscera, assist in the constriction of the rectum and vagina

M. levator ani

1 pars iliaca (iliococcygeus)

O: *arcus tendineus m.levatoris ani*

I: *anococcygeal lig., coccyx*

2 pars pubica (pubococcygeus PC)

O: *ramus sup. ossis pubis*

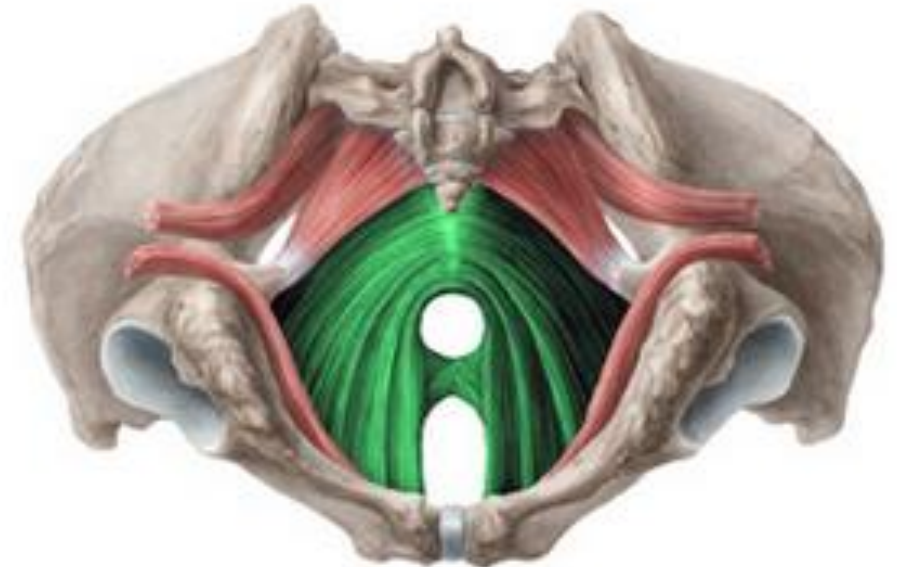
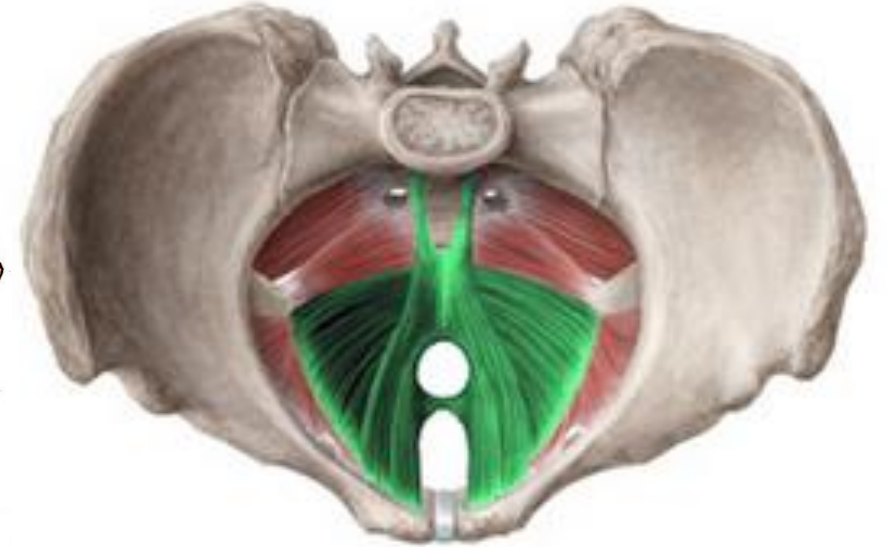
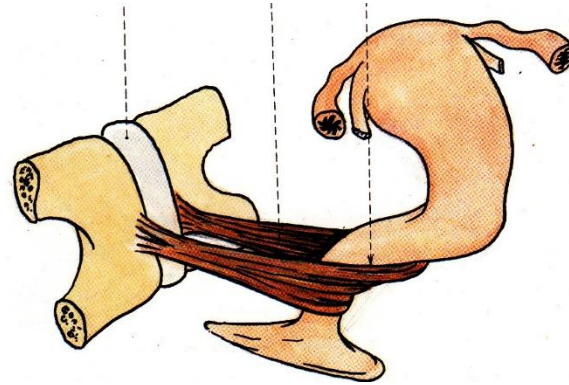
I: *coccyx, ventral sacrococcygeal lig.*

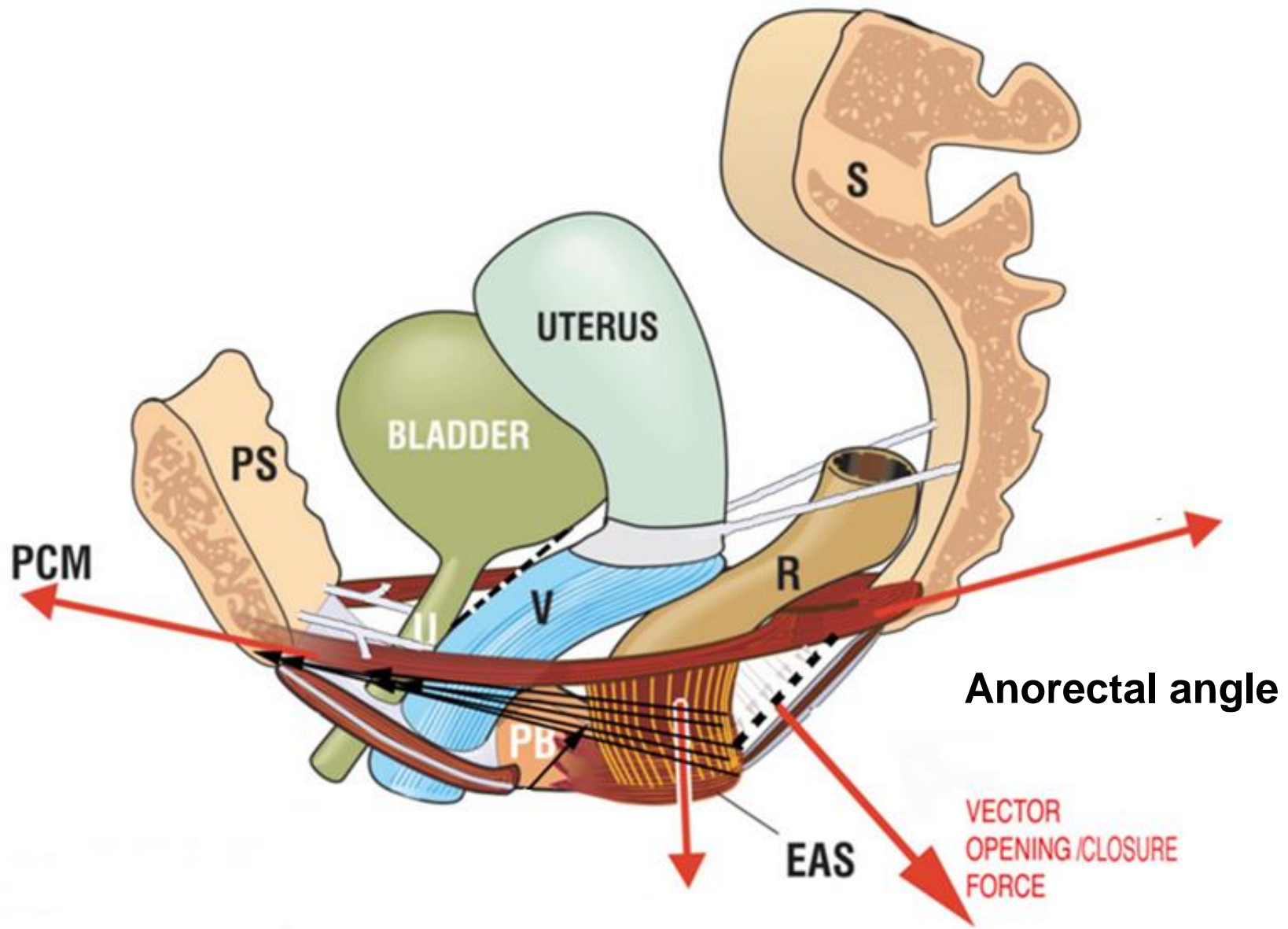
Medial part of PC - **M. levator prostatae, M. pubovaginalis**

PERINEAL BODY – fibromuscular node between A and UG

Intermediate part of PC – **M. puborectalis** – blends with the deep external anal sphincter

Innervation: *sacral plexus*



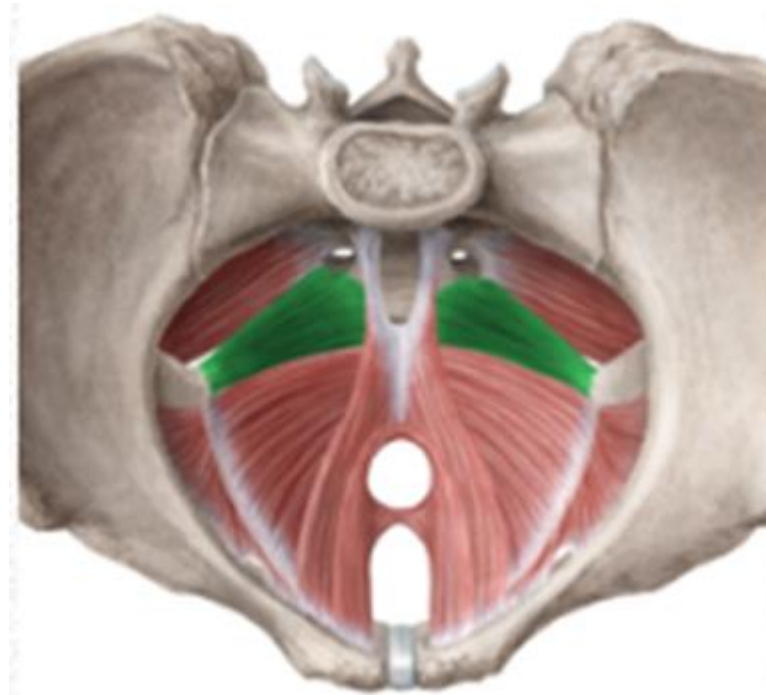


M. coccygeus

O: *spina ischiadica*

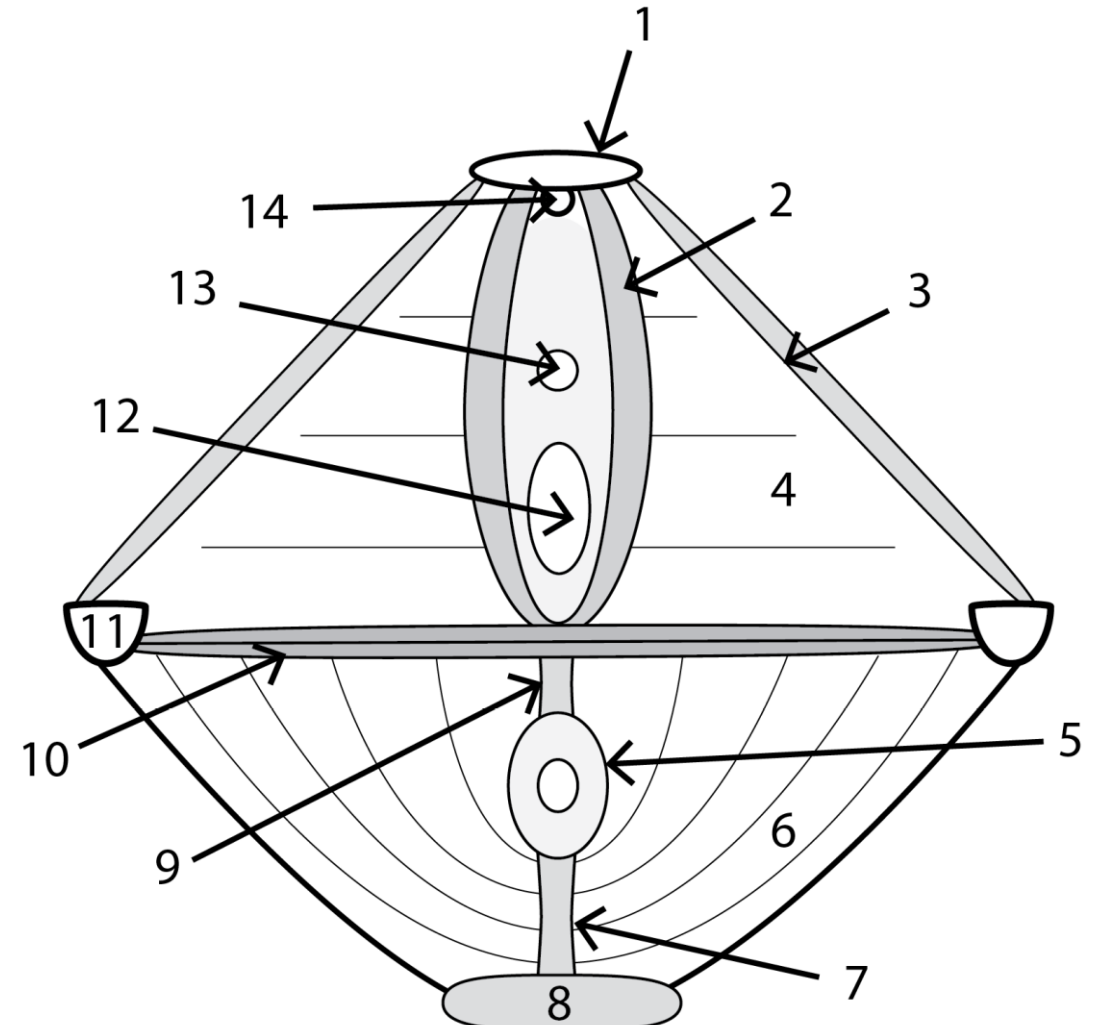
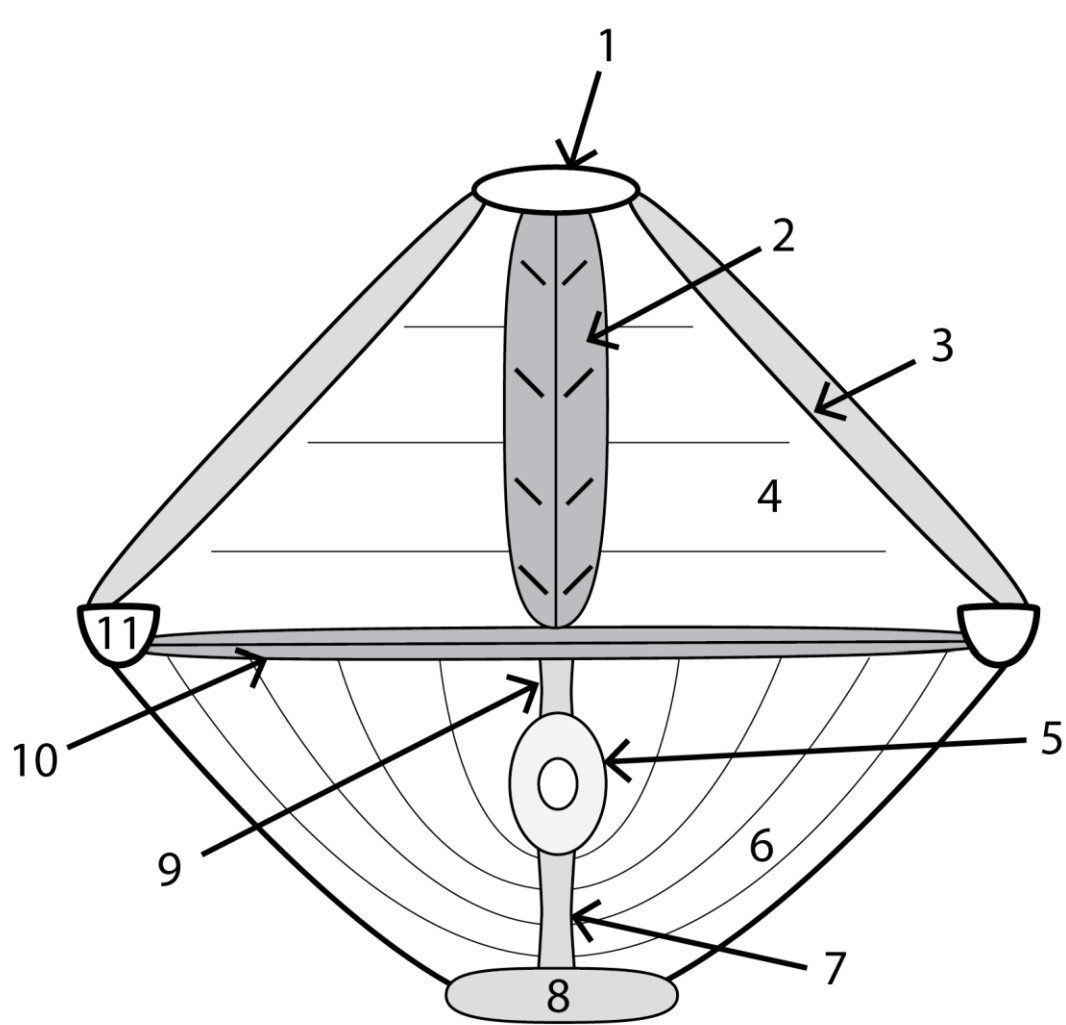
I: *lateral parts of the coccyx and sacrum*
(*lies on the sacrospinal lig.*)

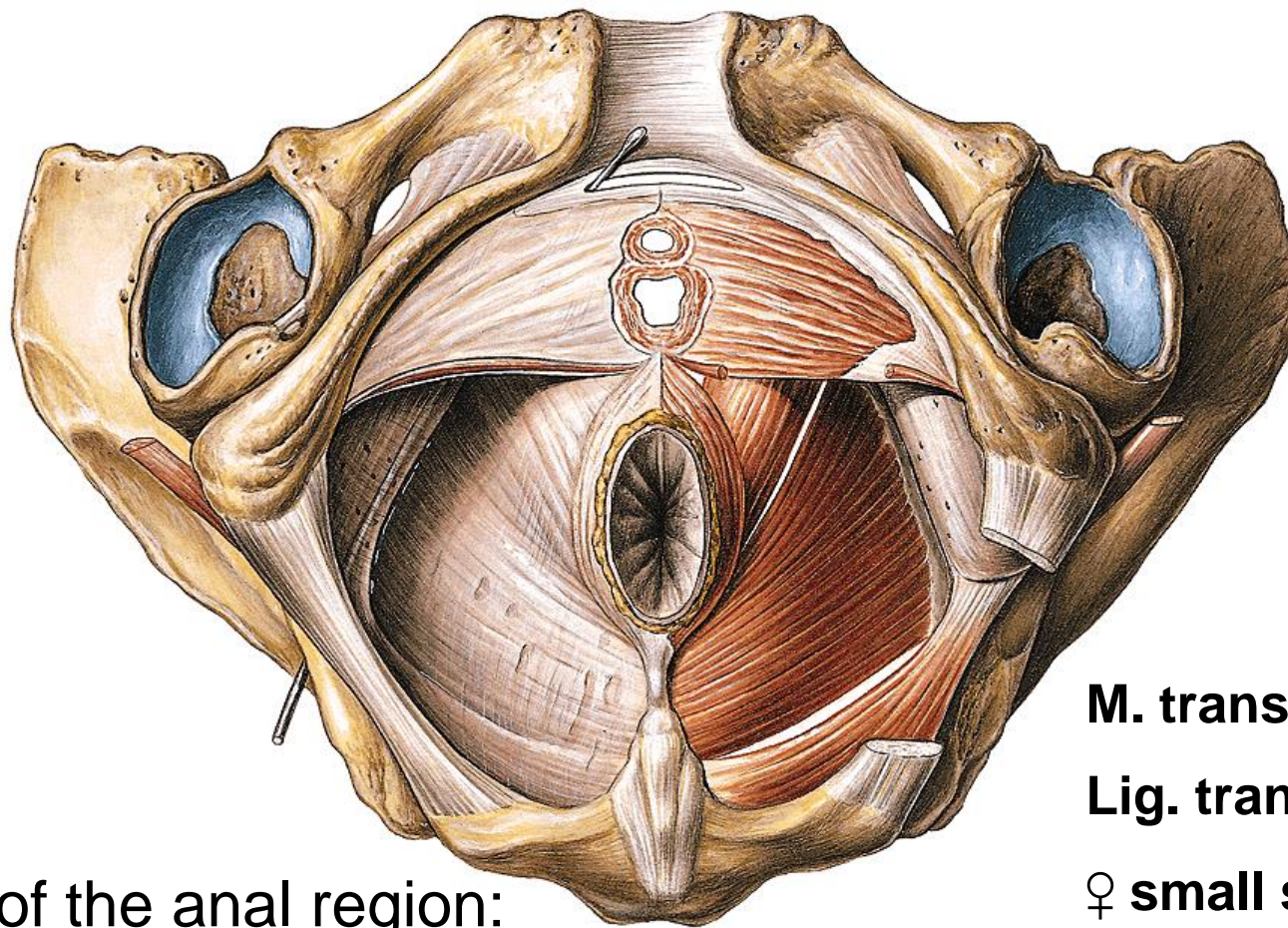
Innervation: *sacral plexus*



PERINEUM

Overlies the pelvic outlet, separated from the pelvic cavity with the pelvic diaphragm
2 triangular parts: anal region, urogenital region





Muscles of the urogenital region:

**Urogenitale diaphragma
=deep perineal pouch**

Muscles of the anal region:

M. sphincter ani externus

Sacral plexus

Lig. anococcygeum

Fascia diaphragmatis urogenitalis

sup. et inf. –pelvic membrane

M. transversus perinei prof.

Lig. transversum perinei in ♂ anteriorly

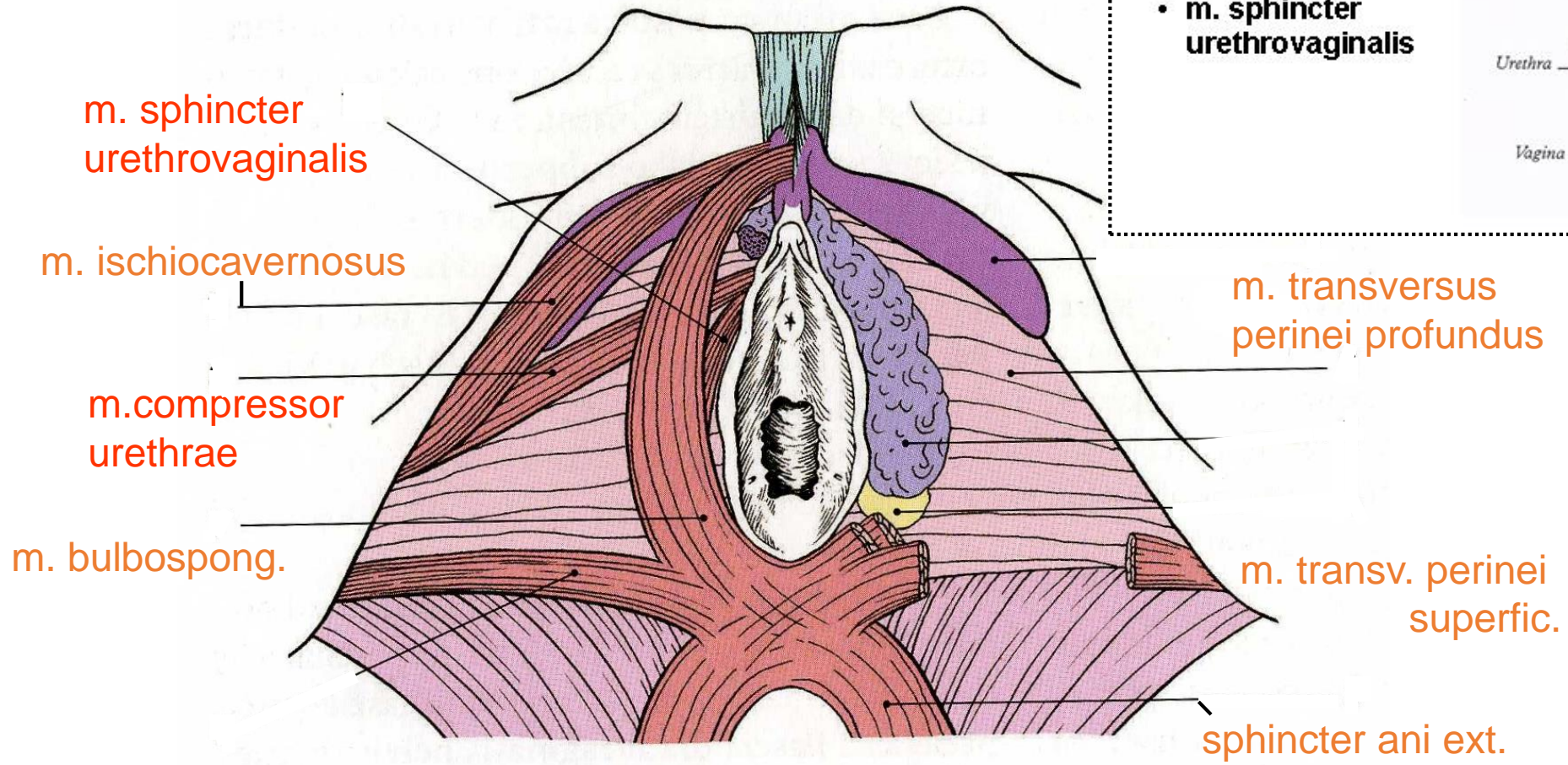
♀ small smooth muscles posteriorly

M. sphincter urethrae externus

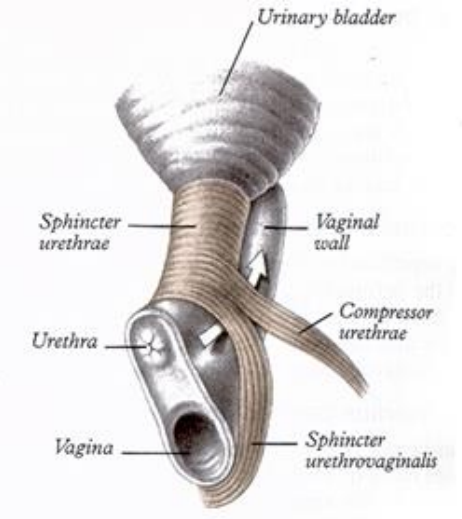
(in ♀ m. sphincter urethrovaginalis)

M. compressor urethrae in ♀ only

Inn. N. pudendus



- m. sphincter urethrae
- m. compressor urethrae
- m. sphincter urethrovaginalis



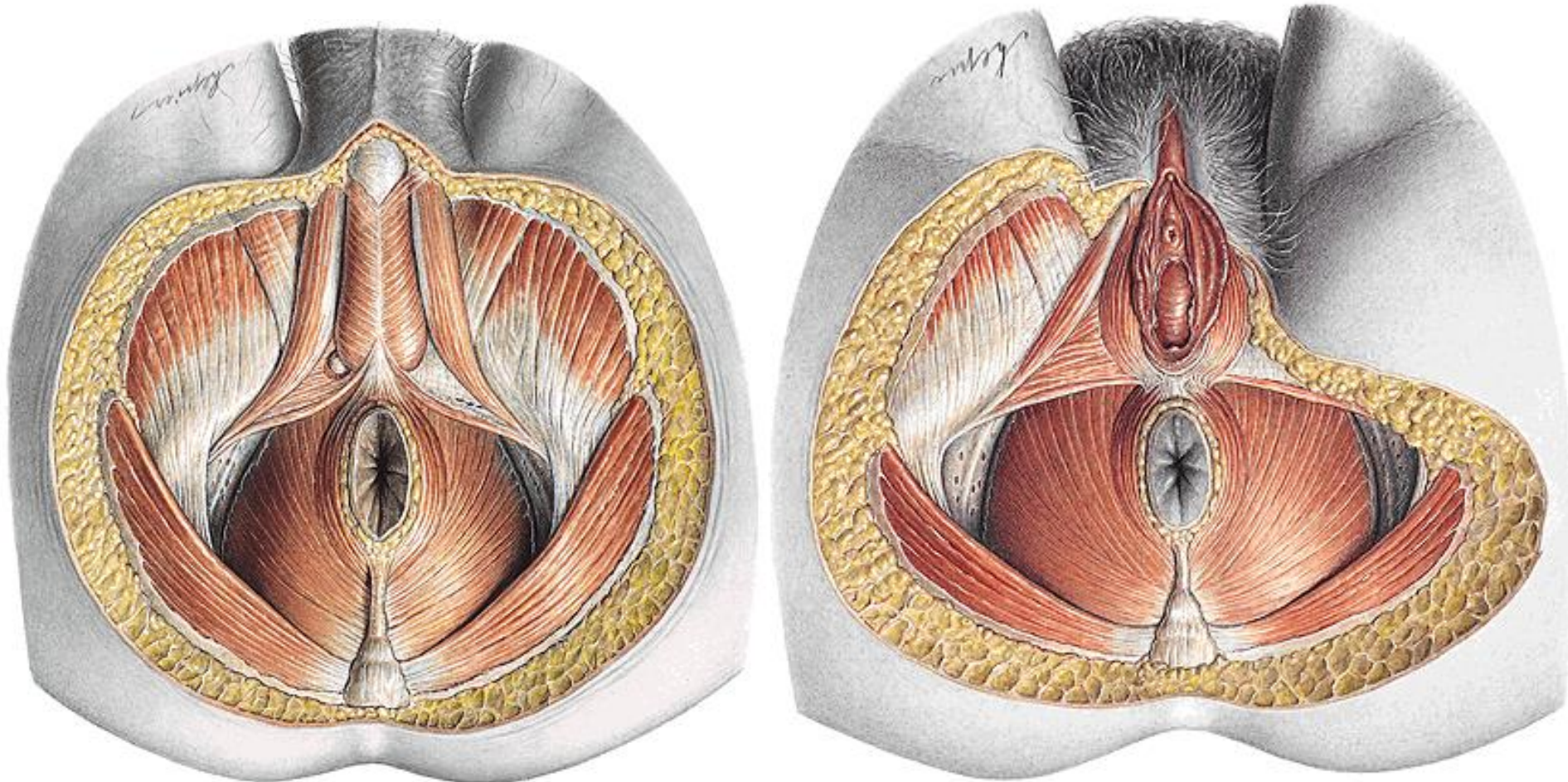
Superficial perineal pouch

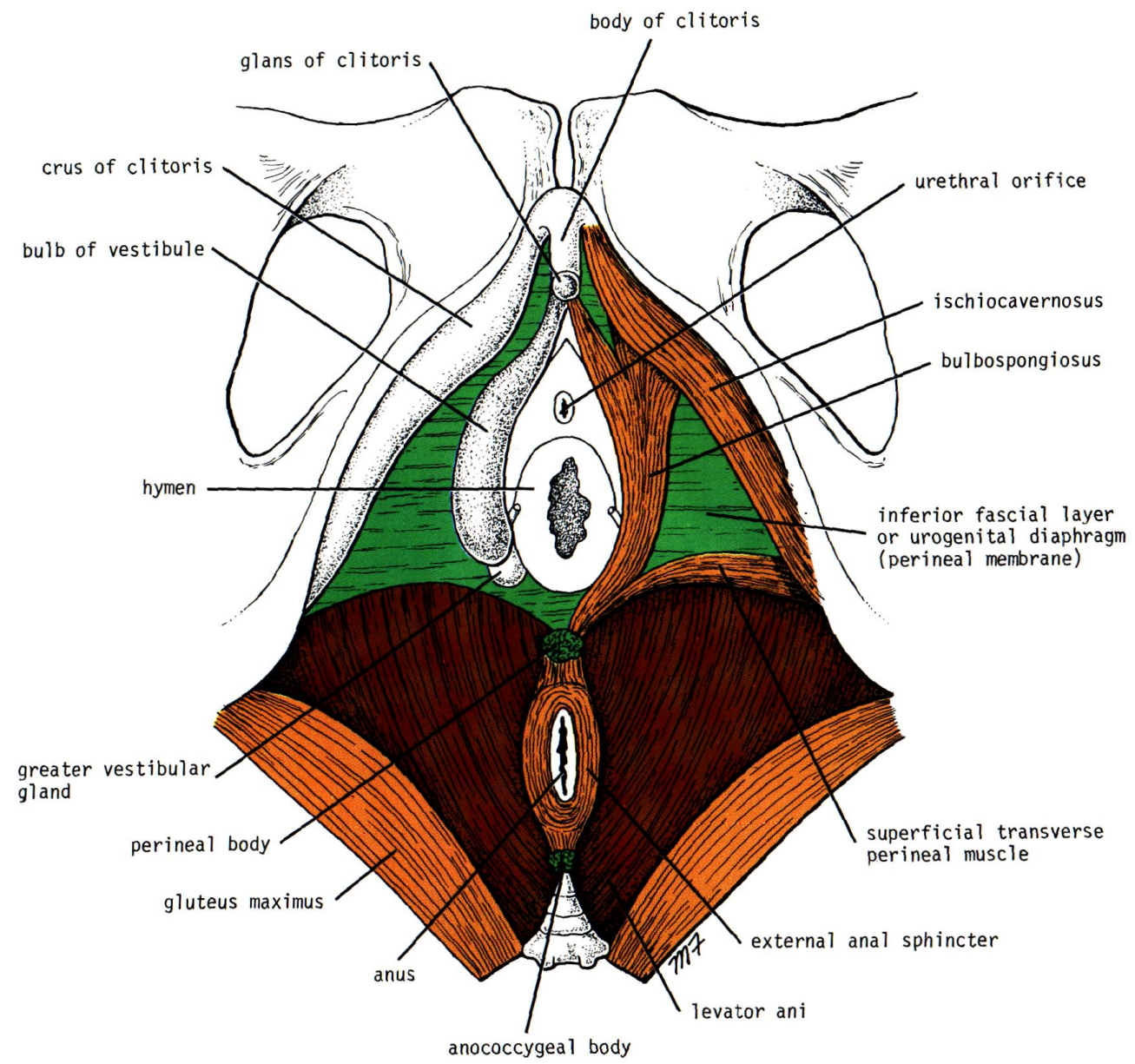
Below the perineal membrane
n. pudendus
Fascia perinei

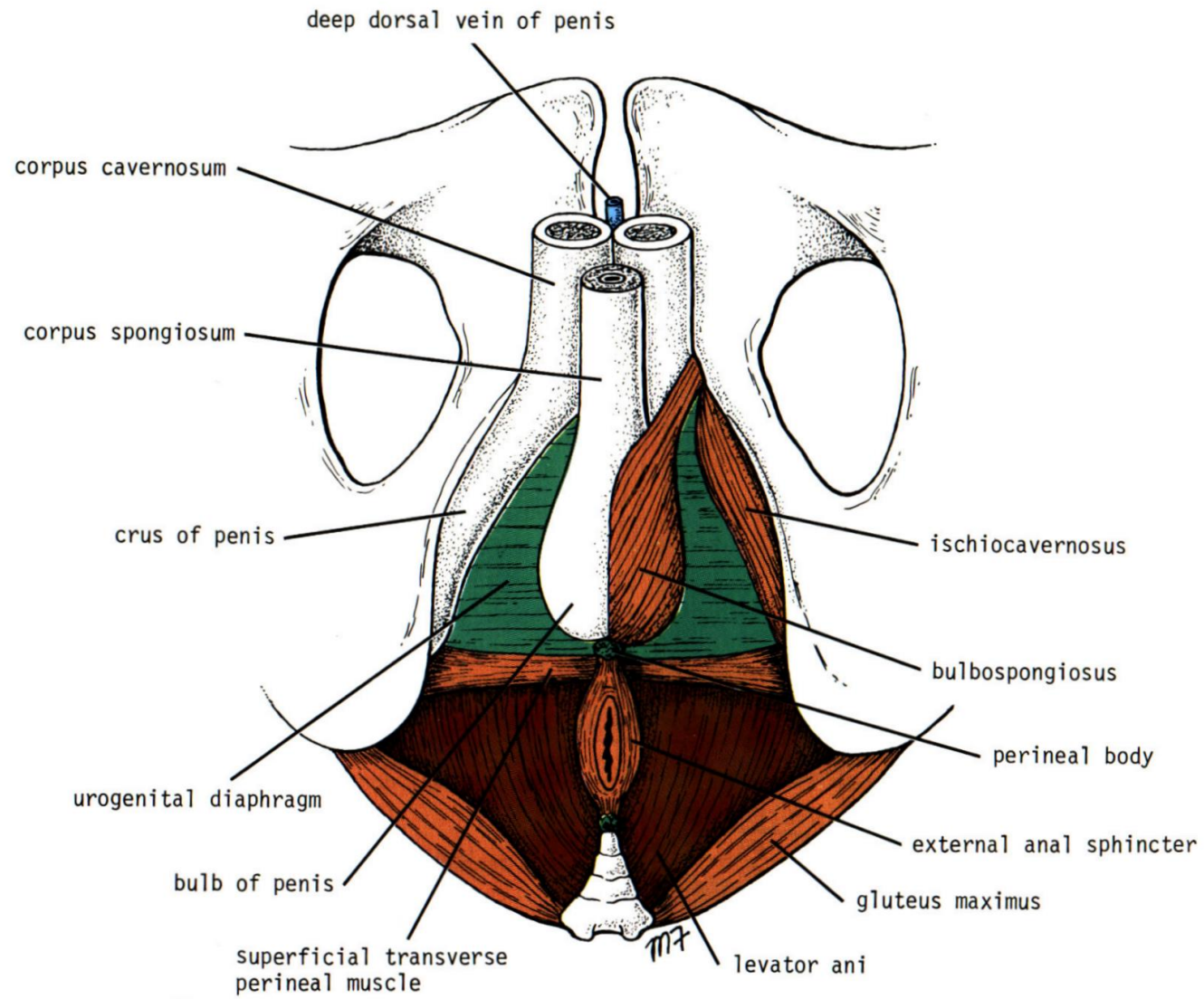
M. ischiocavernosus

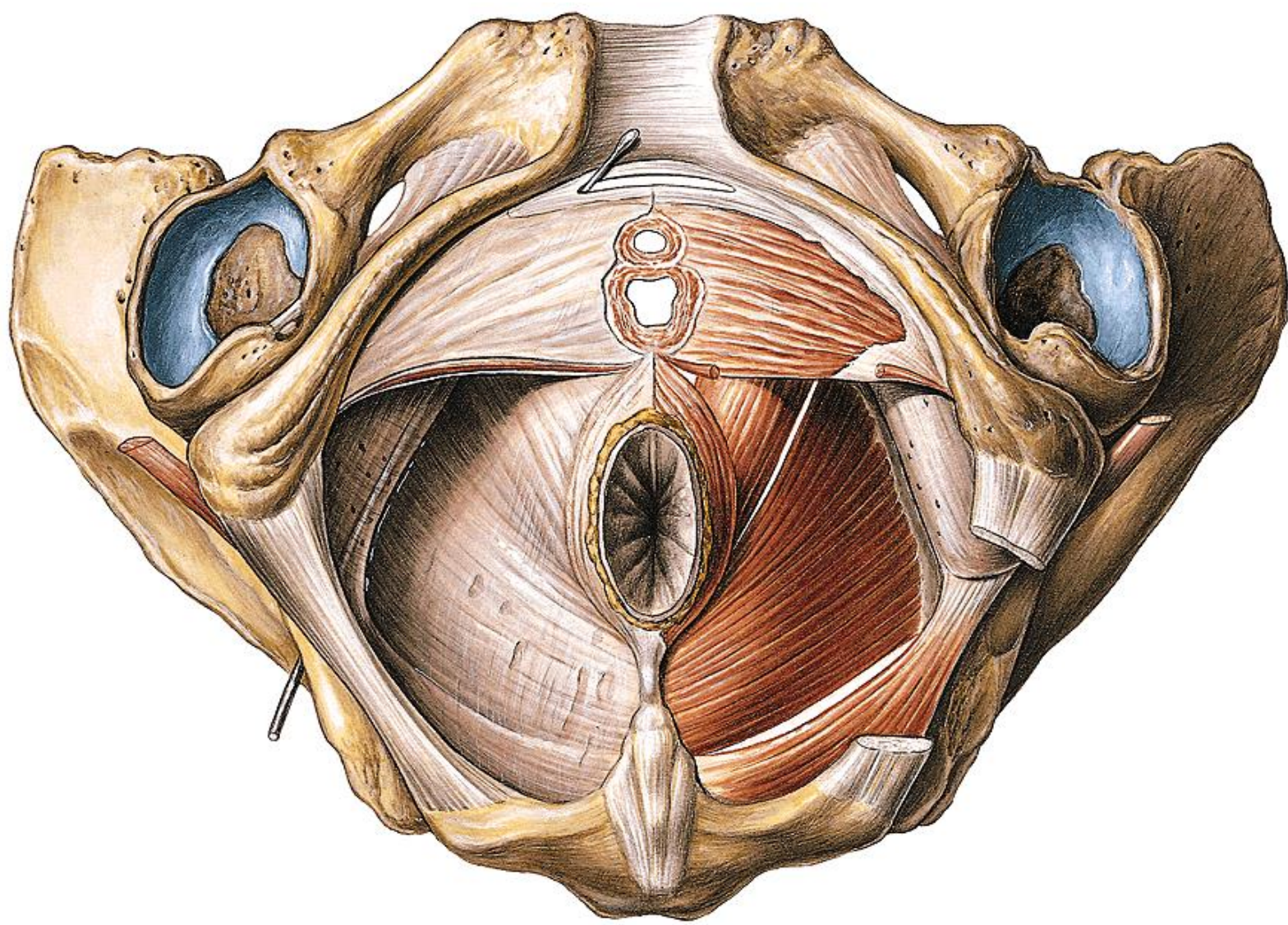
M. bulbospongiosus (M. constrictor cunni)

M. transversus perinei superf.





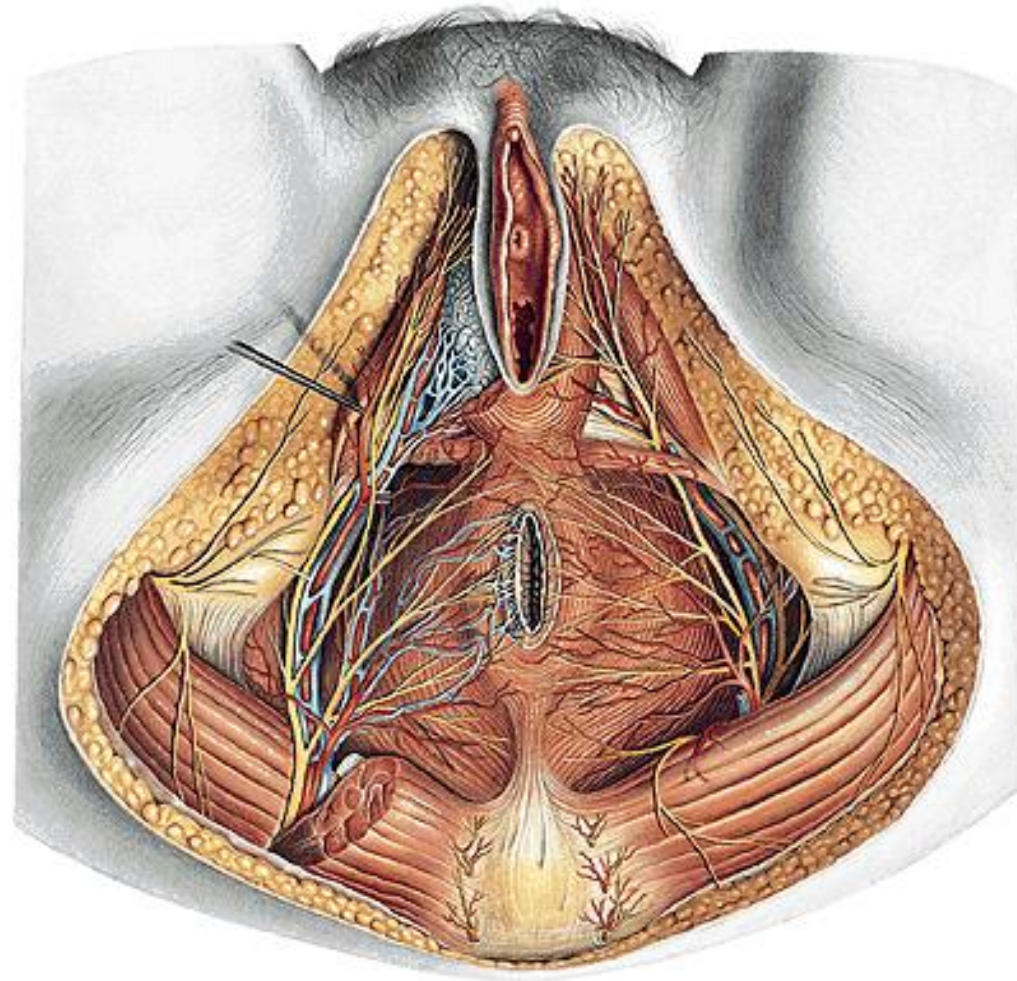
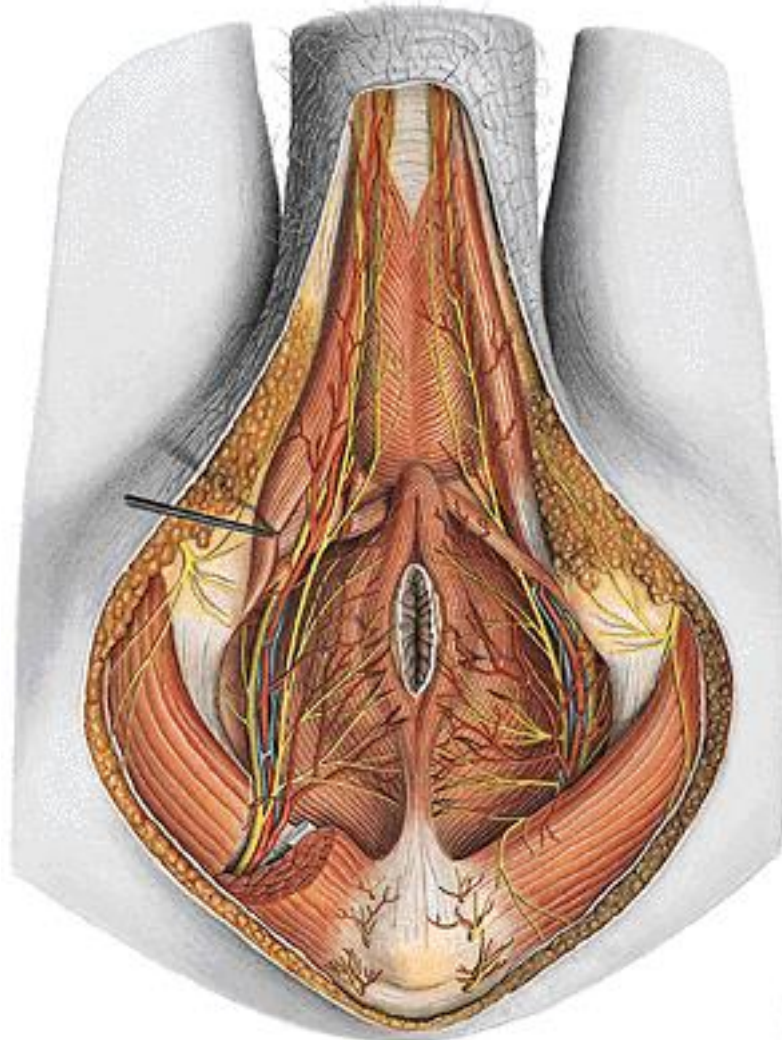




ISCHIORECTAL – ISCHIOANAL - FOSSA

FOSSA ISCHIORECTALIS – recessus pubicus

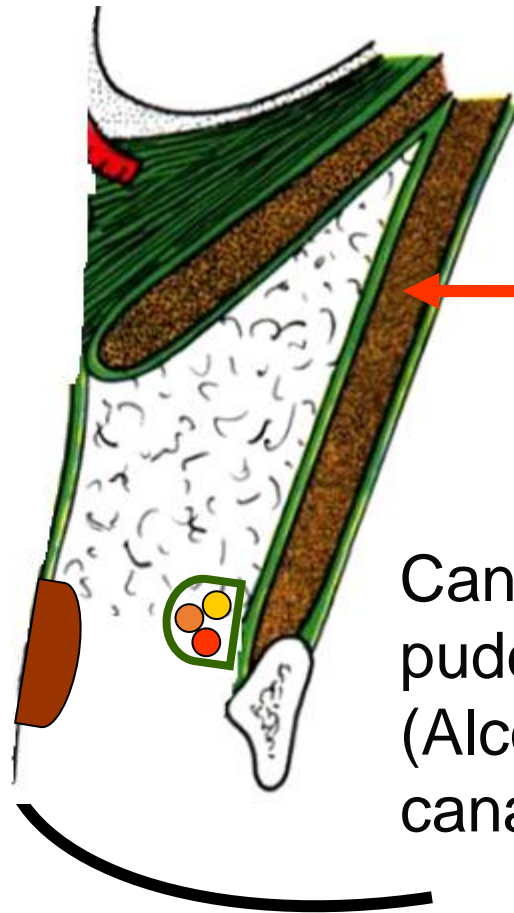
- et v. pudenda interna, n. pudendus – canalis pudendalis
Aa., vv. et nn. rectales inf.





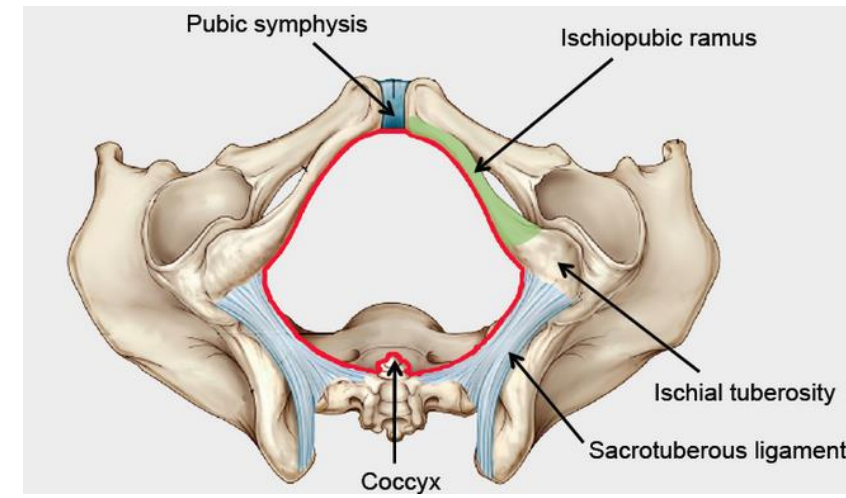
Fossa ischio-rectalis

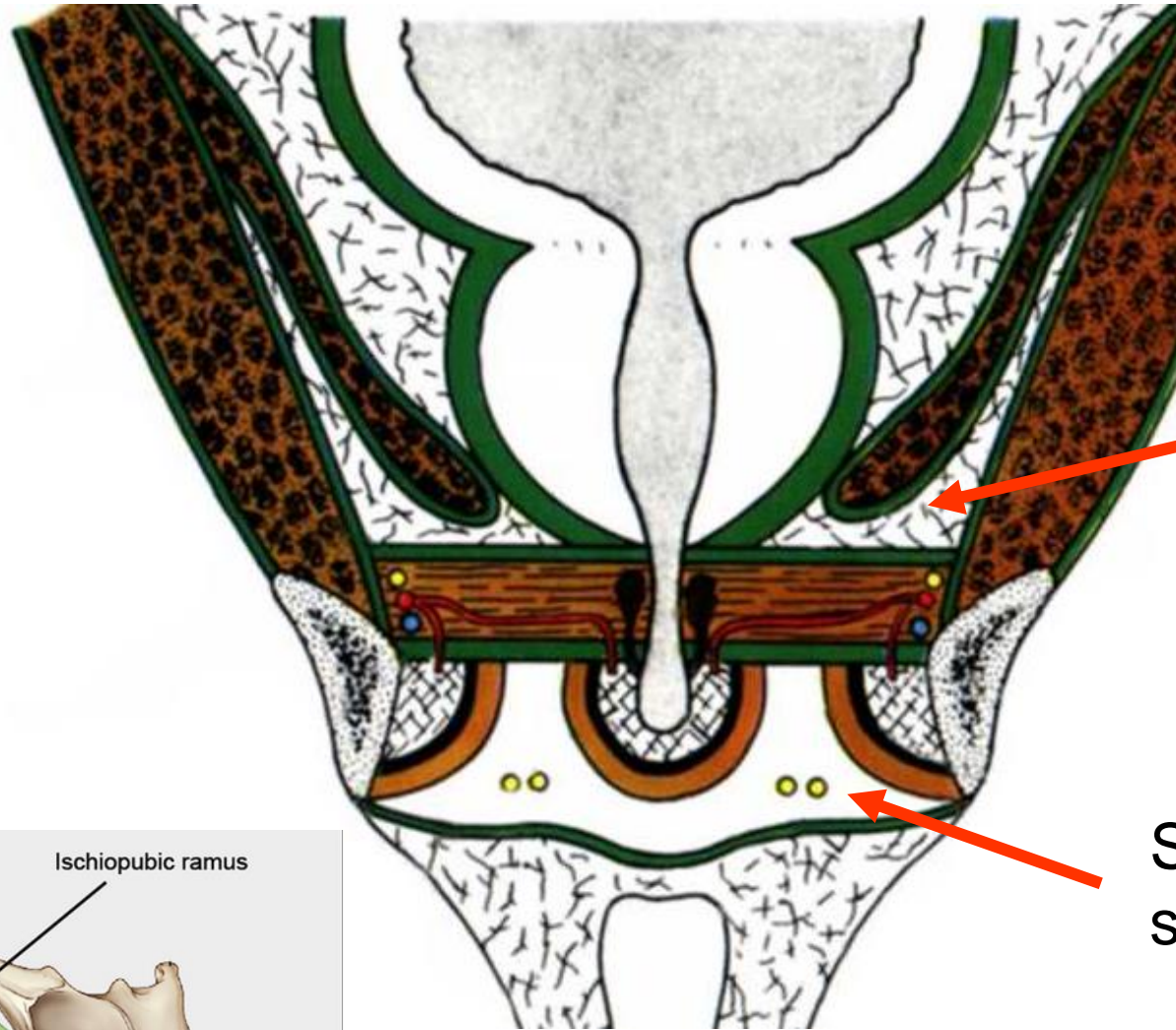
Rectum



m. obturatorius int.
Fascia obturatoria

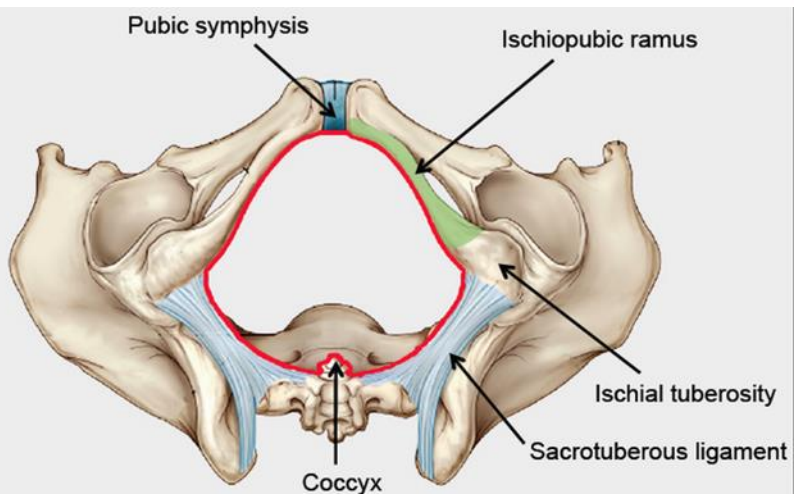
Canalis pudendalis (Alcock's canal)





Recessus
pubicus

Spatium perinei
superficiale



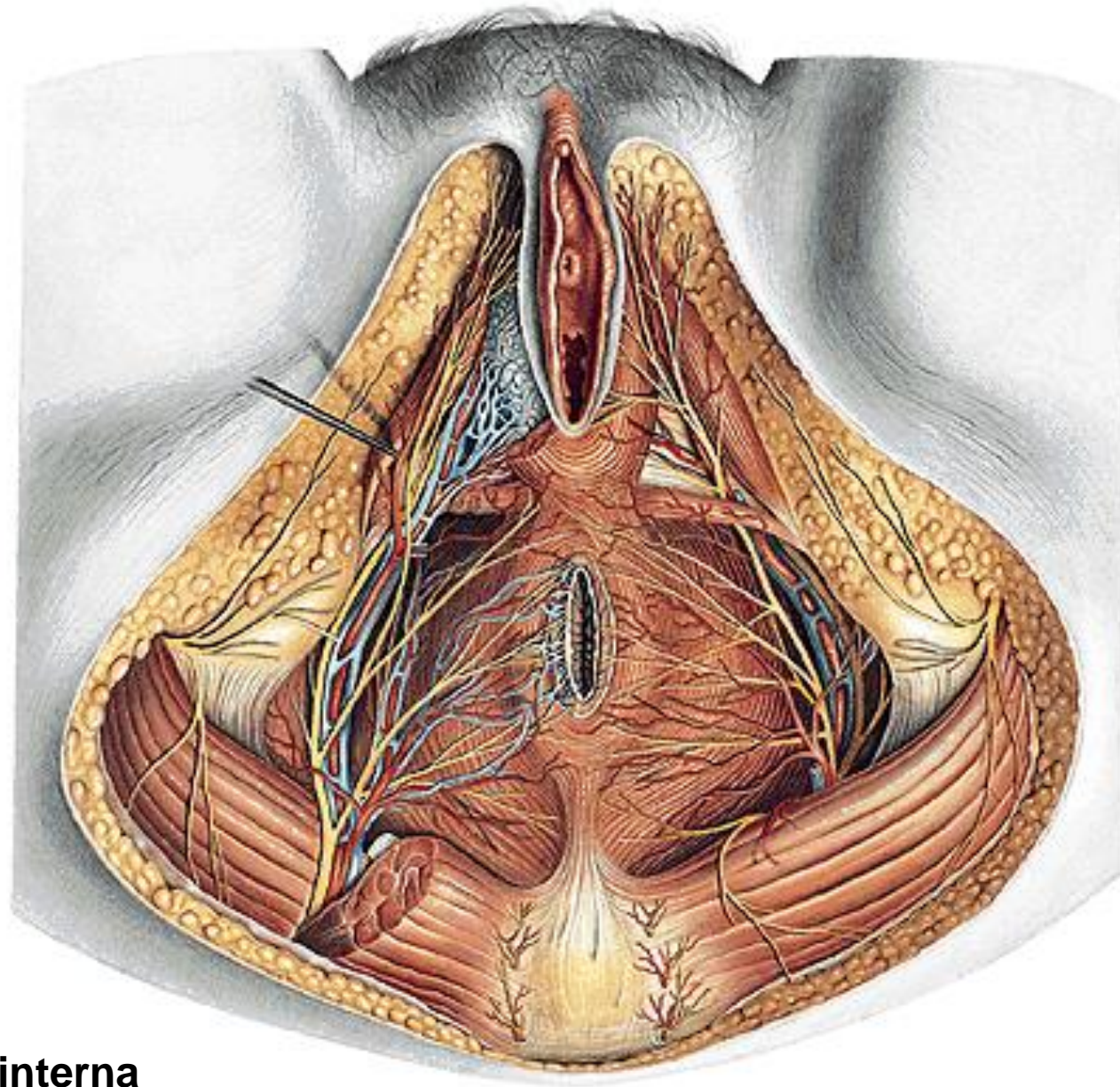
Pubic symphysis

Ischiopubic ramus

Ischial tuberosity

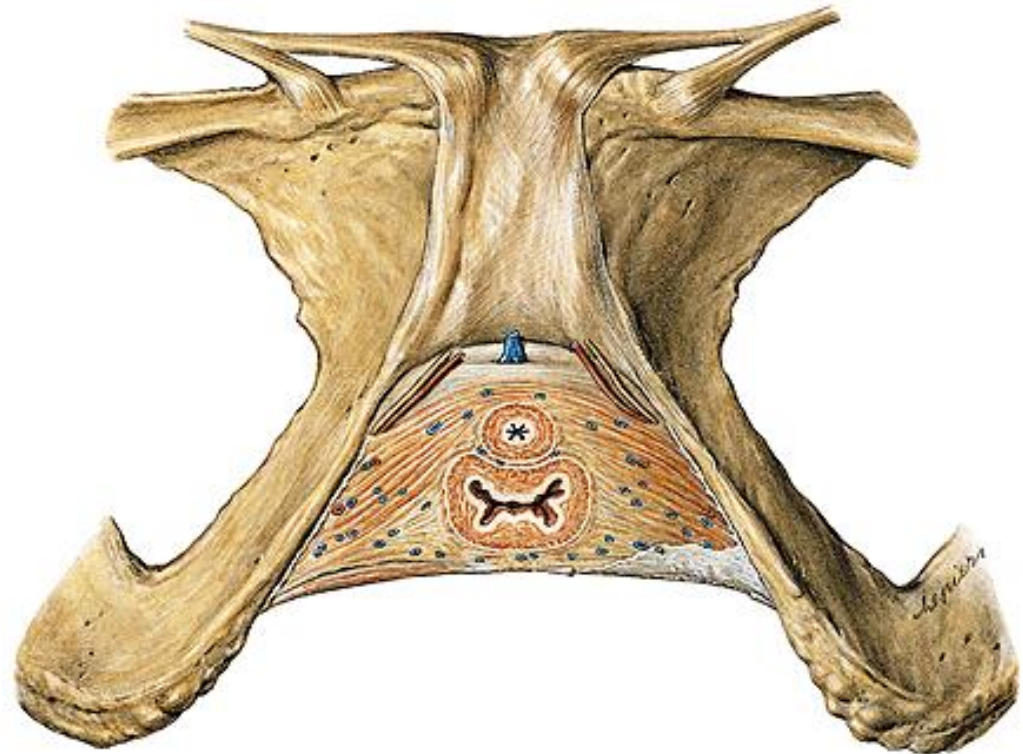
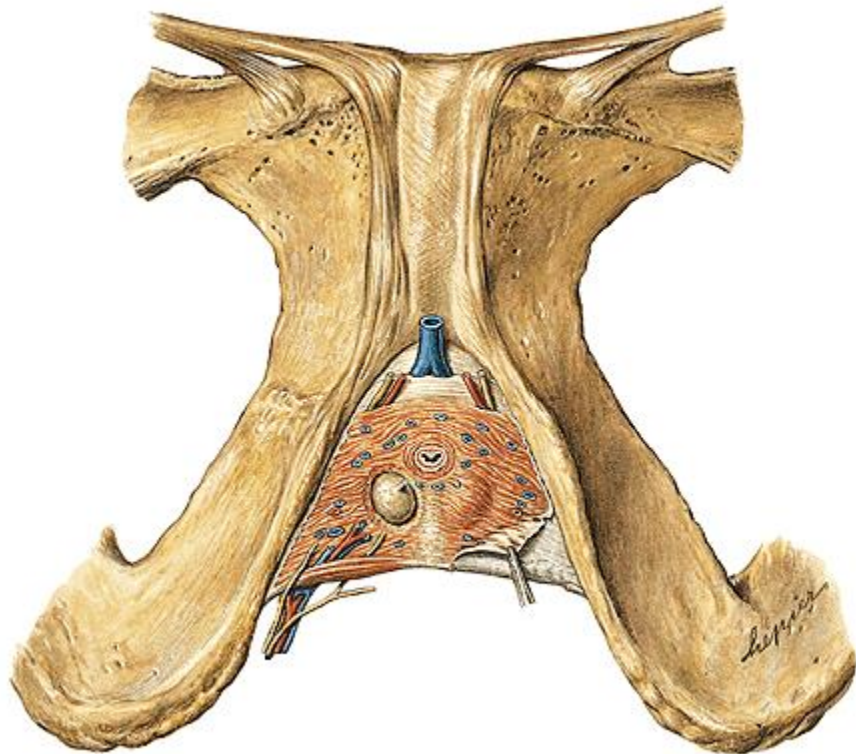
Sacrotuberous ligament

Coccyx

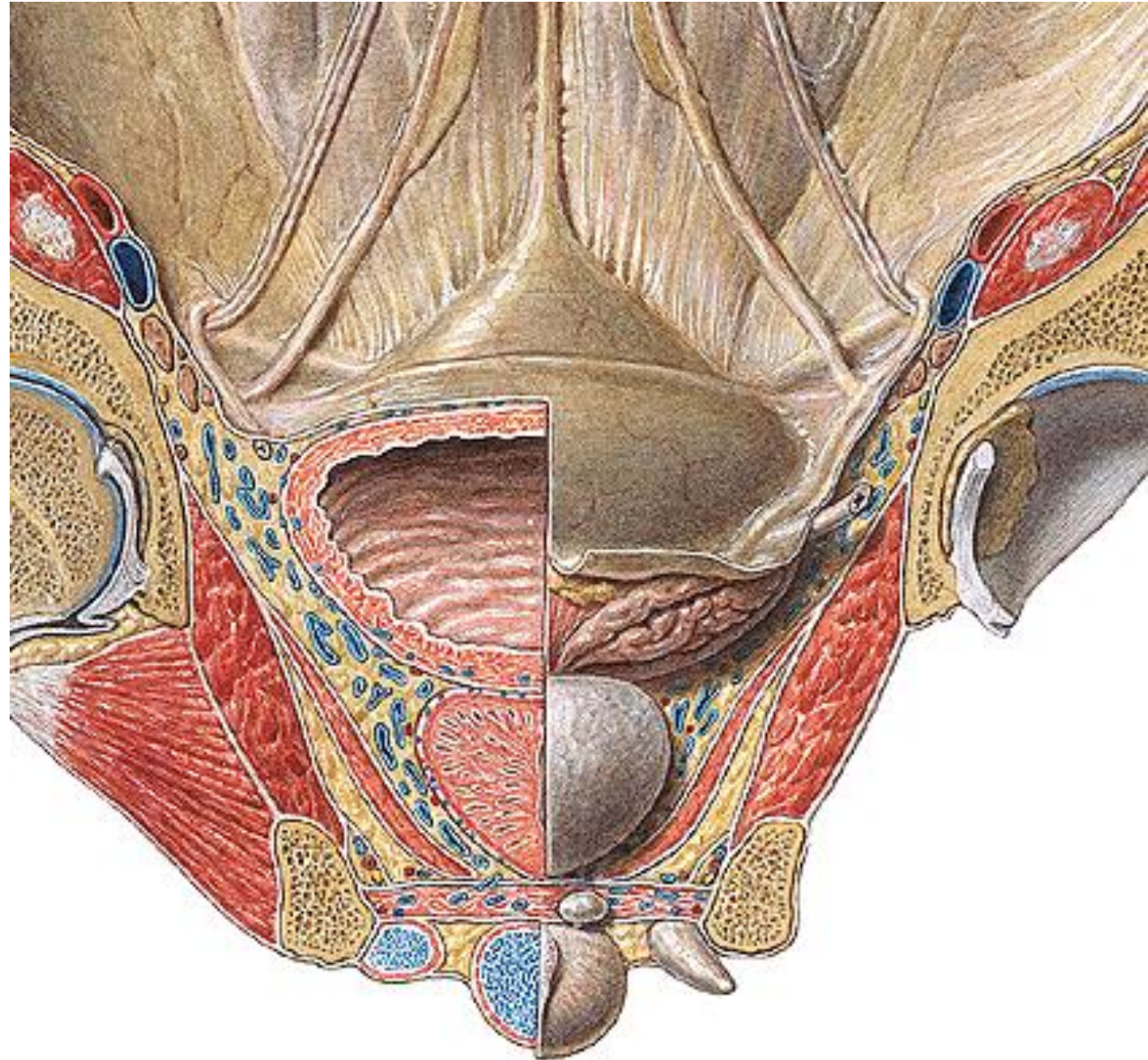


N. pudendus
A. et v. pudenda interna
N. cutaneus femoris post. (rr. perineales)

A. dorsalis penis (clitoridis)
N. dorsalis penis (clitoridis)
V. dorsalis penis (clitoridis) profunda
A.,v. et n. perinealis
Gl. bulbourethralis



Fascia diaphragmatis urogenitalis sup. et inf.
Spatium perinei profundum
Fascia perinei spf.
Spatium perinei spf.
Recessus pubicus
fossae ischio-
rectalis

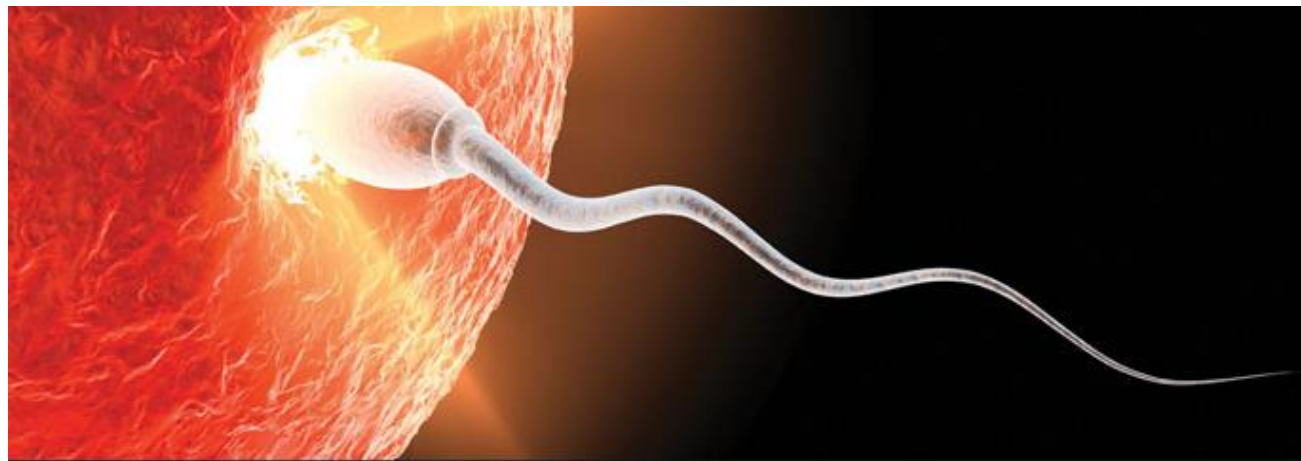

Thank you for your attention

RNDr. Michaela Račanská, Ph.D.

racanska@mail.muni.cz

Spring 2017



Department of Anatomy
MU Brno, Czech Republic



Illustrations were copied from:

Čihák R: Anatomie 2 (Splanchnologia). Avicenum, zdravotnické nakladatelství, Praha, 1988.

Sobotta, Putz, R., und Pabst, R. Atlas der Anatomie des Menschen 20. Auflage. München: Urban & Schwarzenberg, 1993

Neil A. Campbell, Jane B. Reece, Lisa Urry, Michael L. Cain et al.: Biology: A Global Approach (10th International Edition), 2014.

Pearson Education Limited (Verlag) 978-1-292-00865-3 (ISBN)