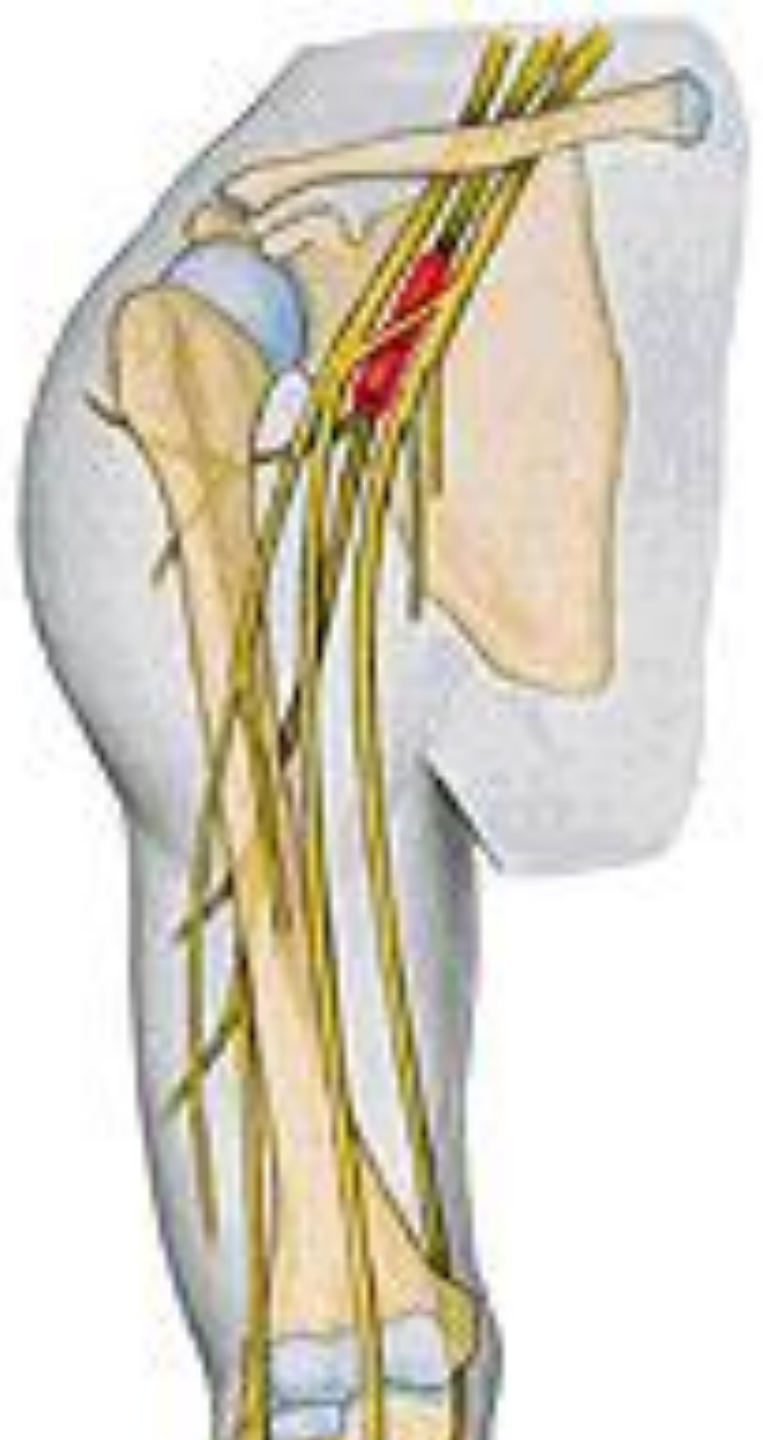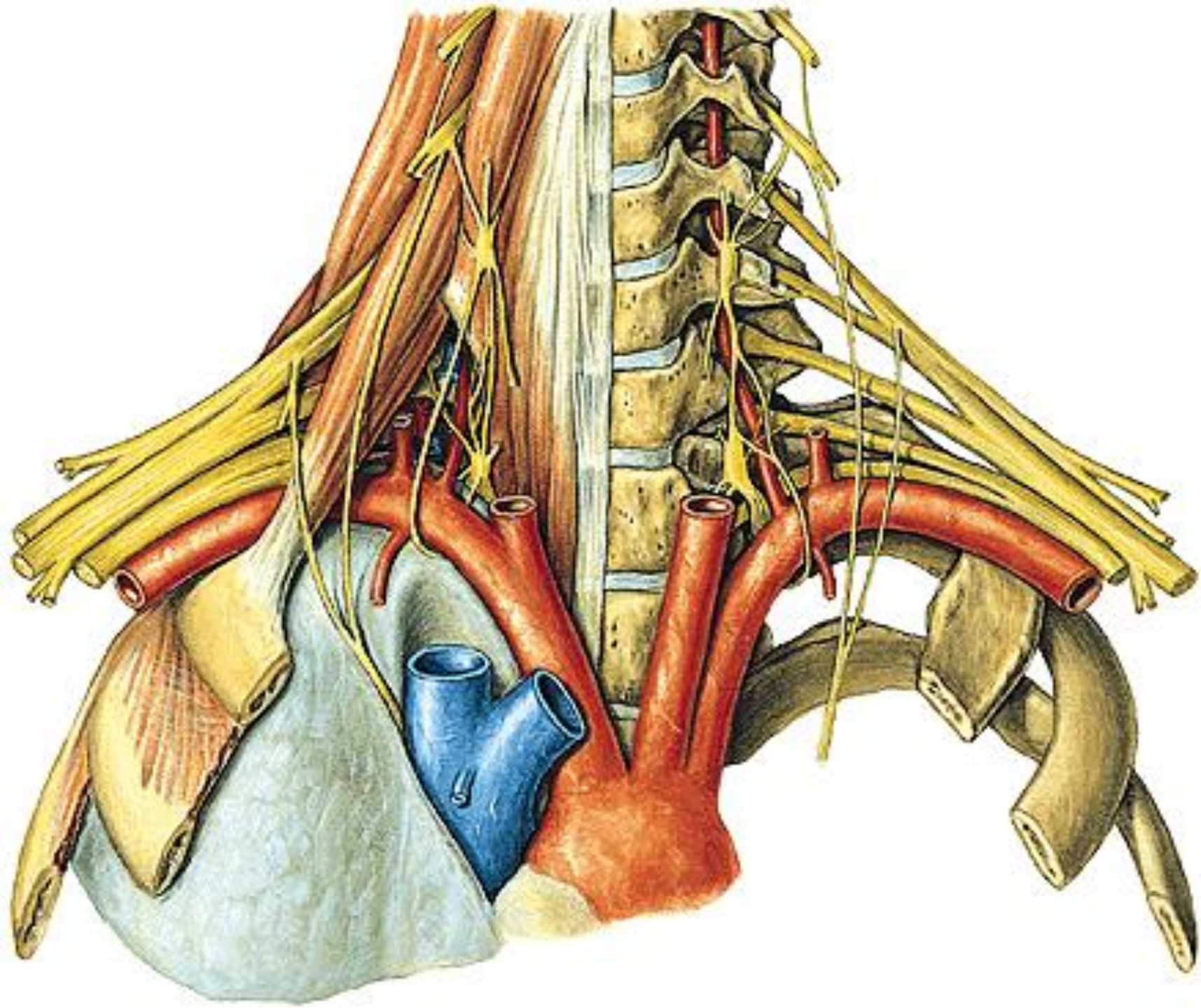


# **PLEXUS BRACHIALIS**

**PARS SUPRACLAVICULARIS**

**PARS INFRACLAVICULARIS**



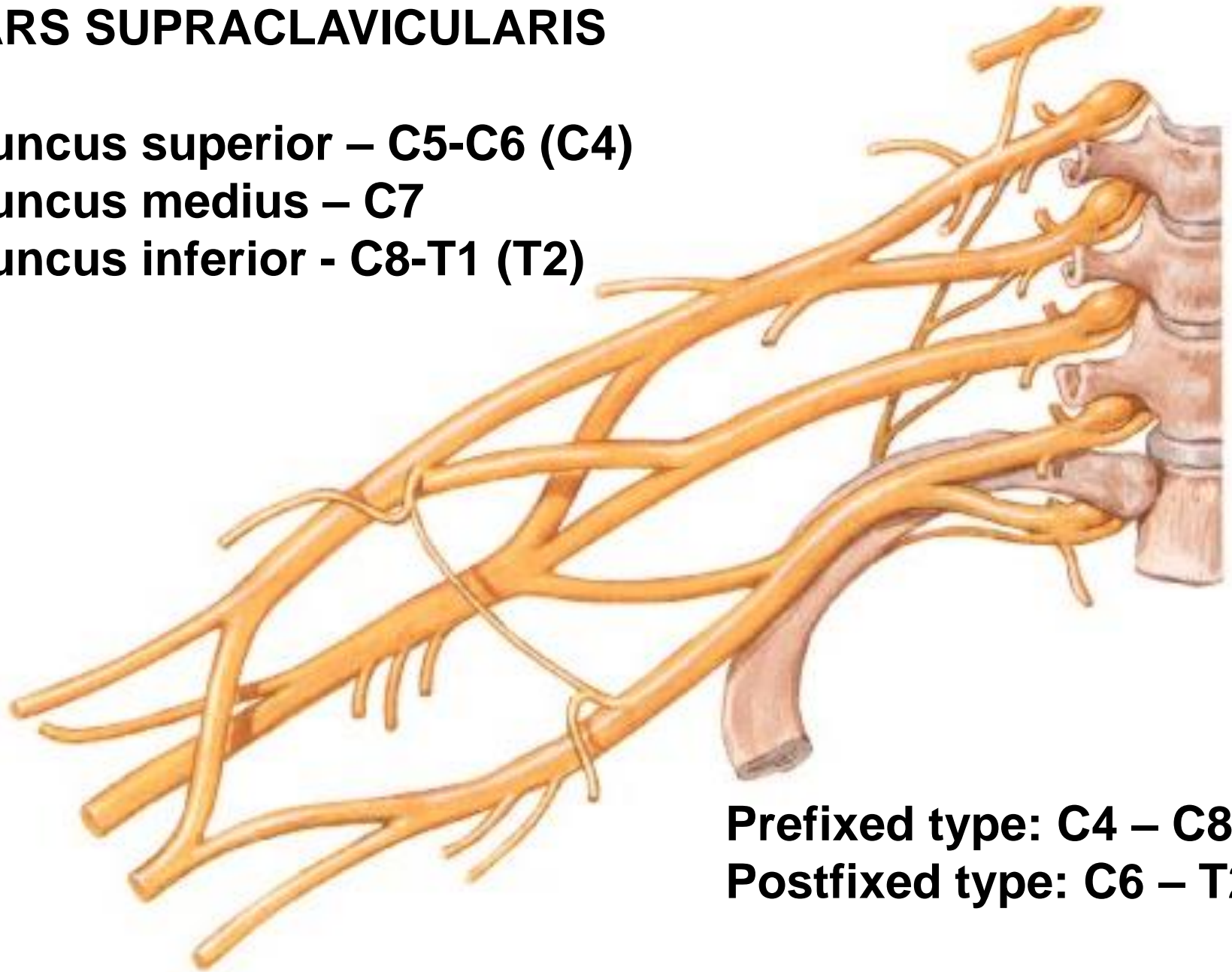


## **PARS SUPRACLAVICULARIS**

**Truncus superior – C5-C6 (C4)**

**Truncus medius – C7**

**Truncus inferior - C8-T1 (T2)**



**Prefixed type: C4 – C8**

**Postfixed type: C6 – T2**

# PARS SUPRACLAVICULARIS

## N. dorsalis scapulae (C4, C5)

- mm. rhomboidei
- m. levator scapulae

## N. thoracicus longus (C5, C6, C7)

- m. serratus ant.

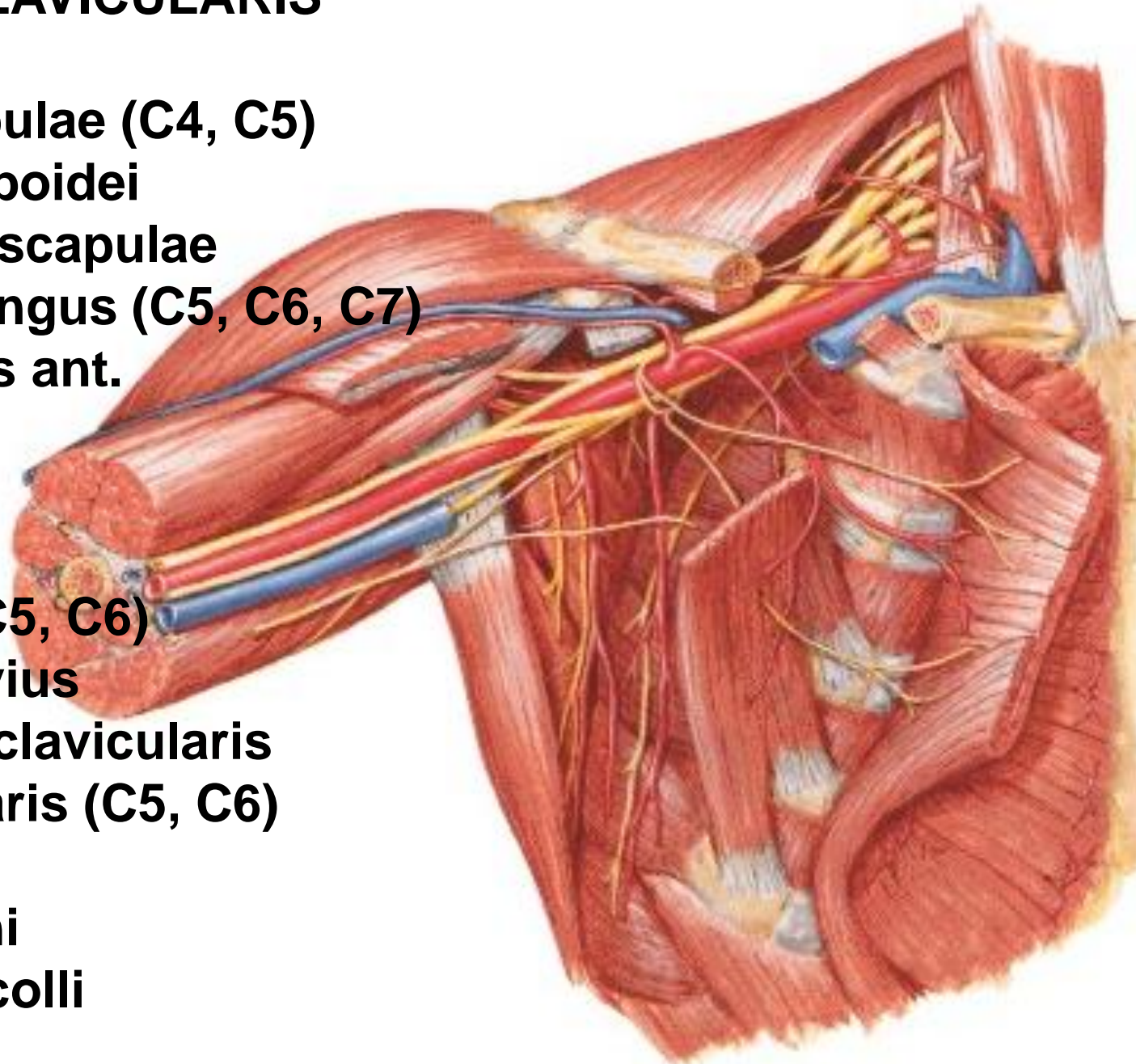
## N. subclavius (C5, C6)

- m. subclavius
- art. sternoclavicularis

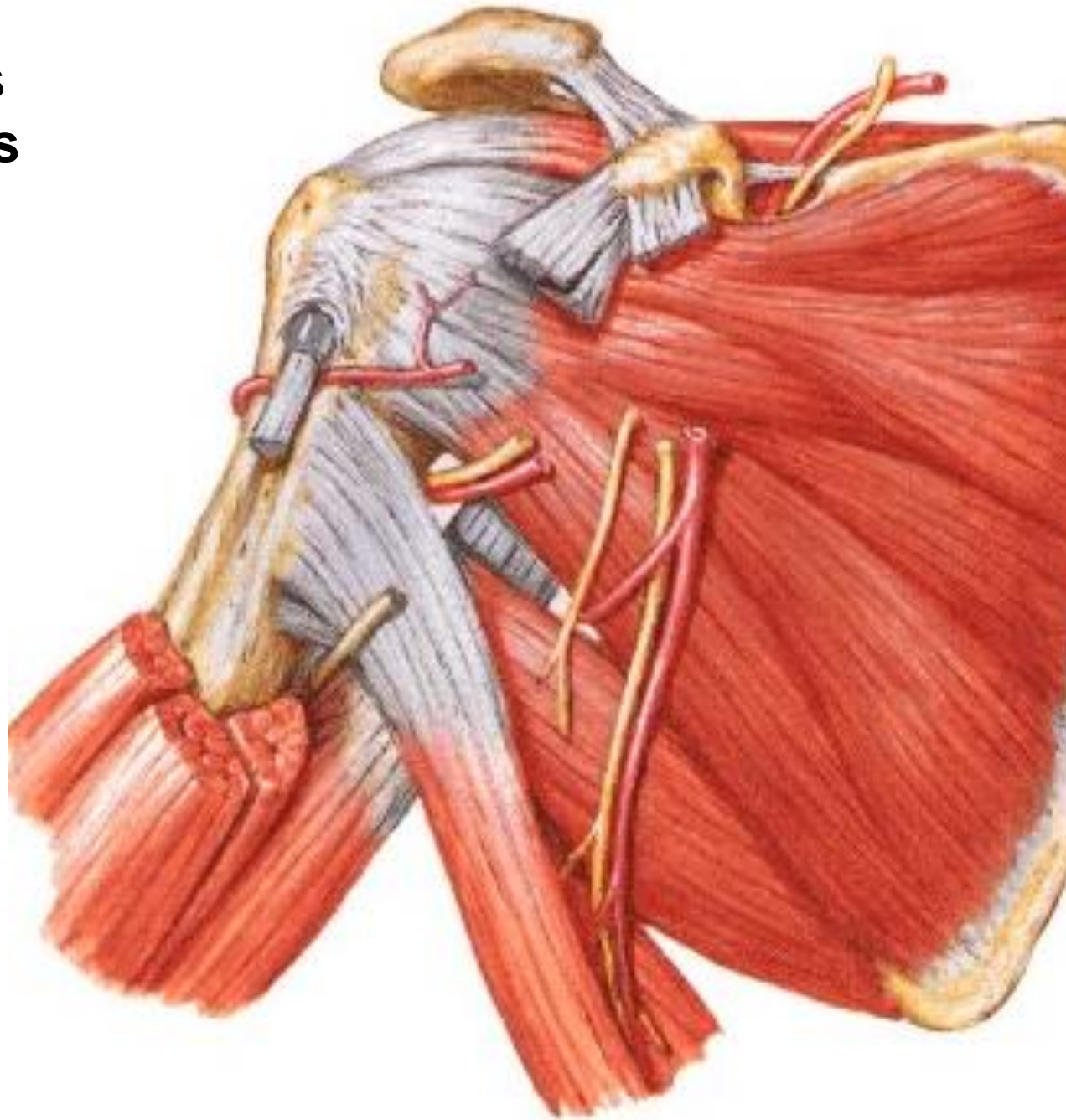
## N. suprascapularis (C5, C6)

## Rr. musculares

- mm. scaleni
- m. longus colli

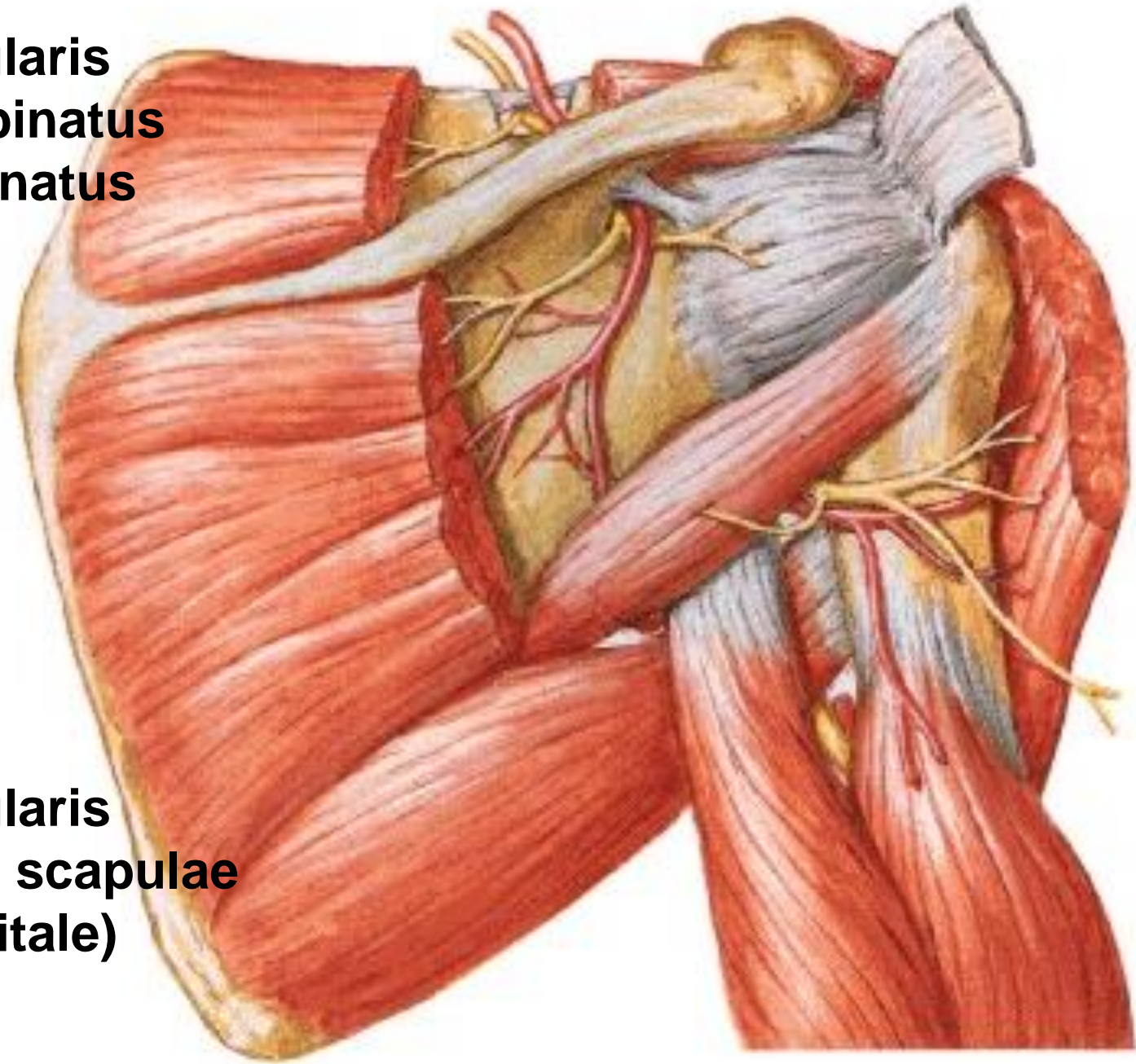


**N suprascapularis**  
**A. suprascapularis**



## **N. suprascapularis**

- m. supraspinatus
- m. infraspinatus
- art. humeri



## **A. suprascapularis**

**A. circumflexa scapulae  
(for. omotricipitale)**

**N. pectoralis lateralis (C5, C6, C7)**

- mm. pectorales

**N. pectoralis medialis (C8, T1)**

- mm. pectorales

**N. subscapularis sup. (C5)**

- m. subscapularis

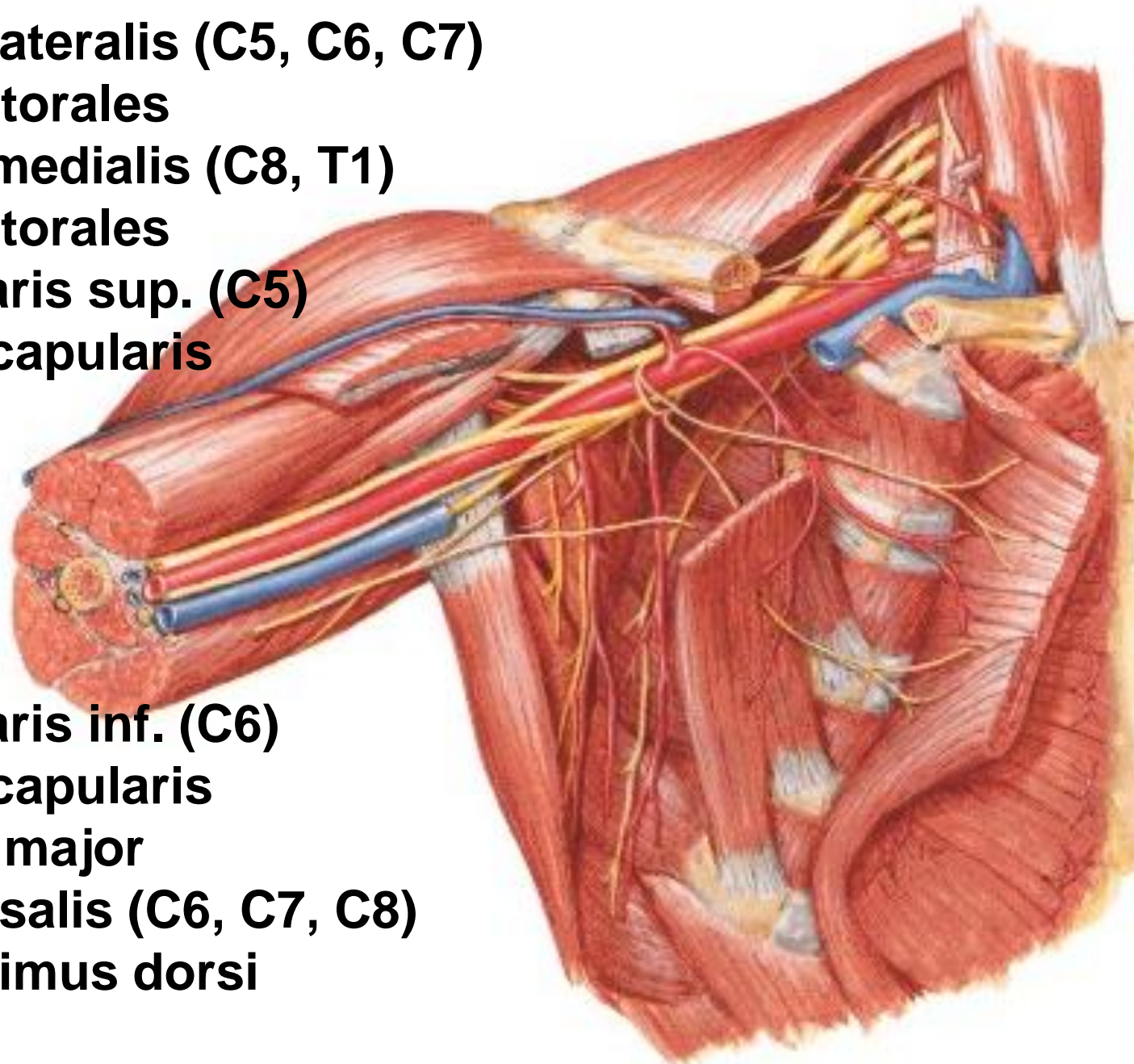
**N. subscapularis inf. (C6)**

- m. subscapularis

- m. teres major

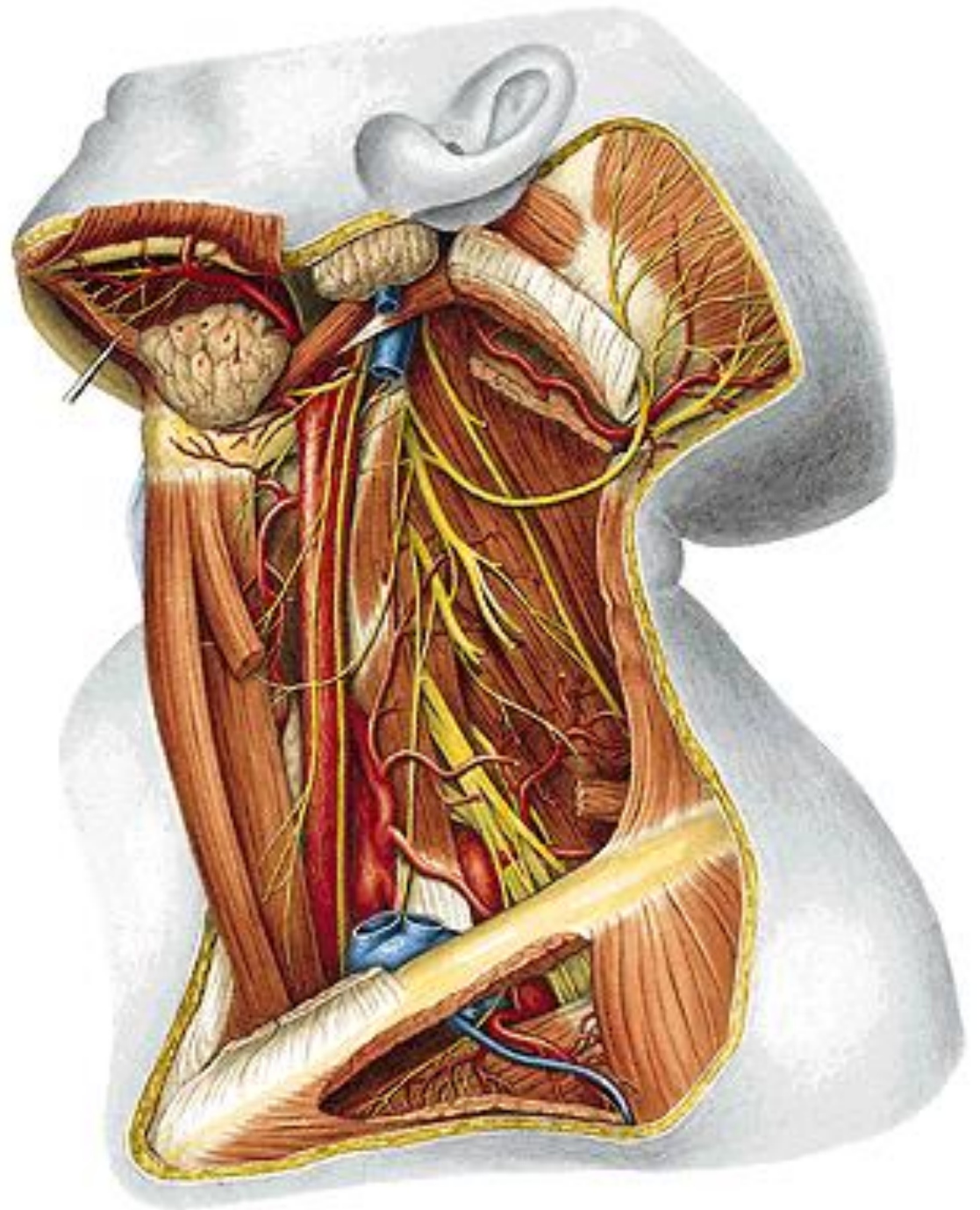
**N. thoracodorsalis (C6, C7, C8)**

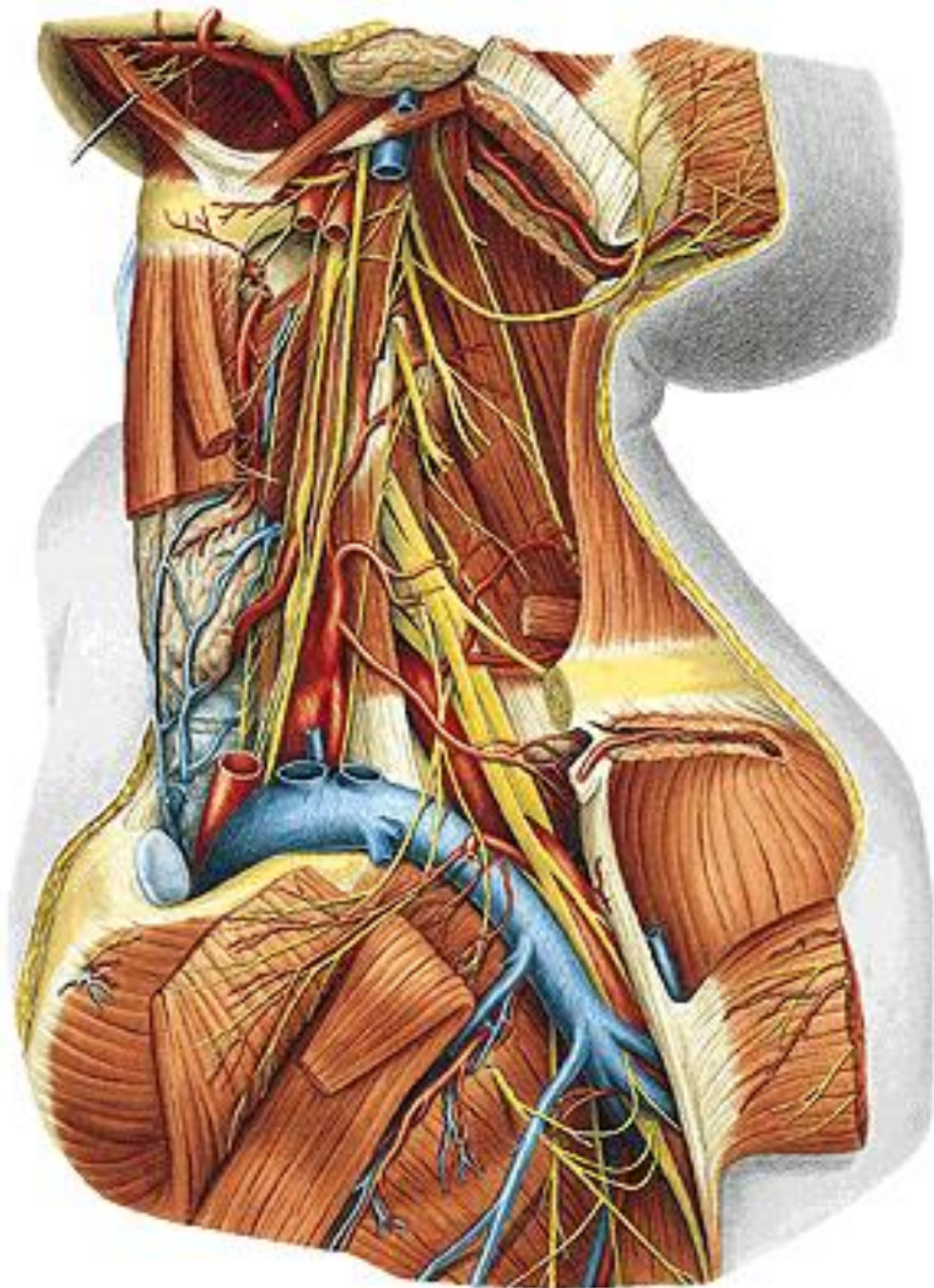
- m. latissimus dorsi





# N. phrenicus





**PARS INFRACLAVICULARIS**  
(terminal branches)

**Fasciculus lateralis**

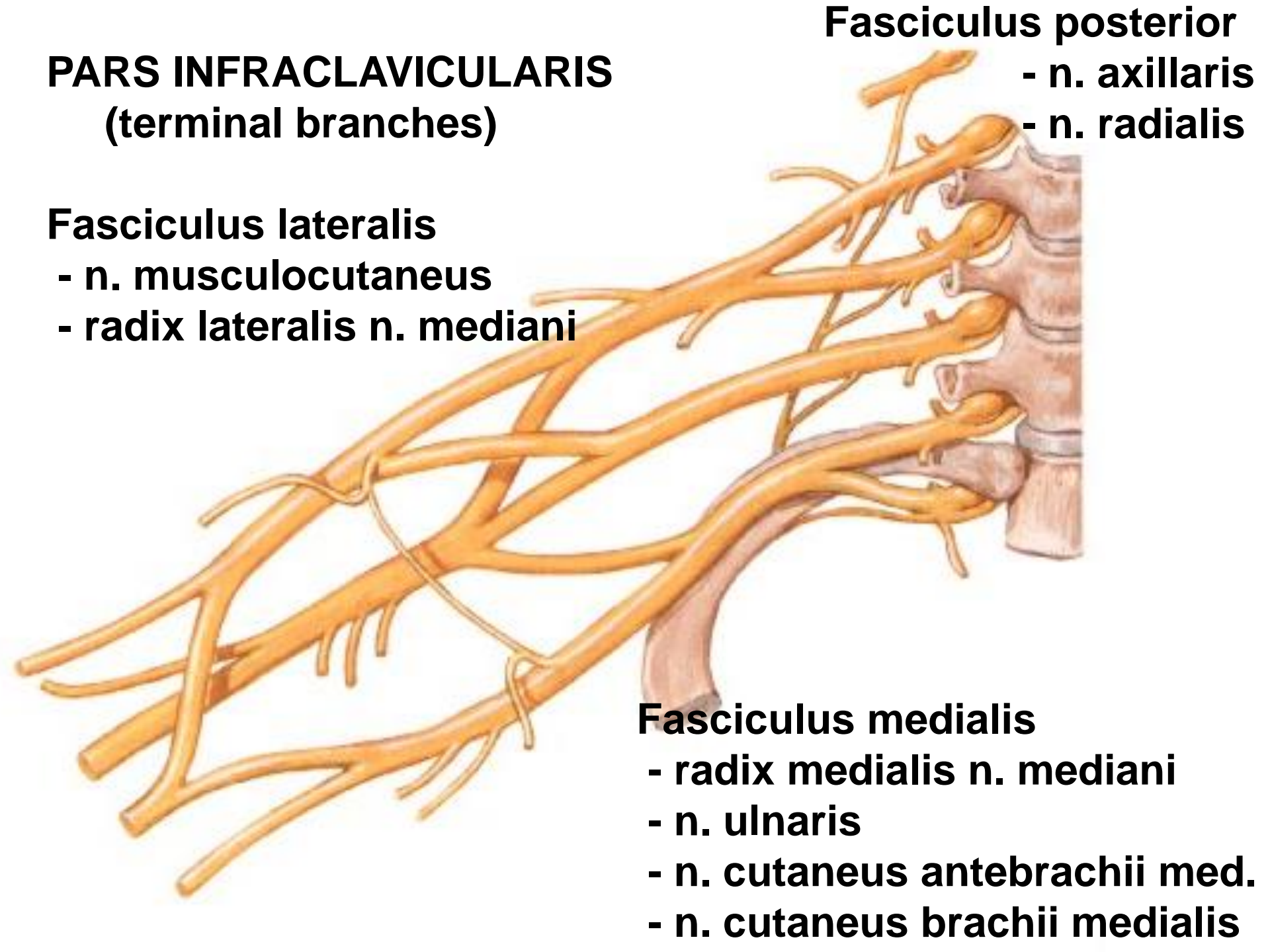
- n. musculocutaneus
- radix lateralis n. mediani

**Fasciculus posterior**

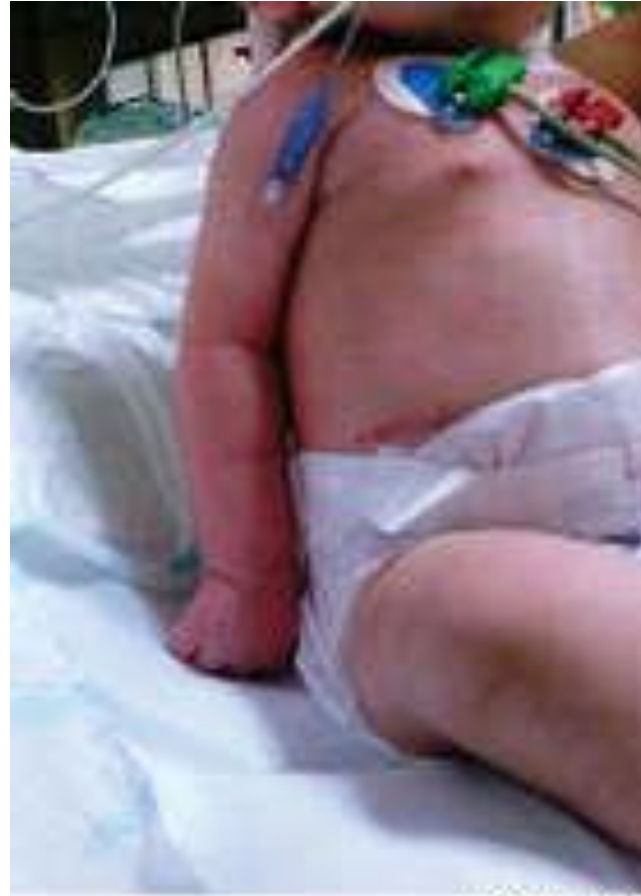- n. axillaris
- n. radialis

**Fasciculus medialis**

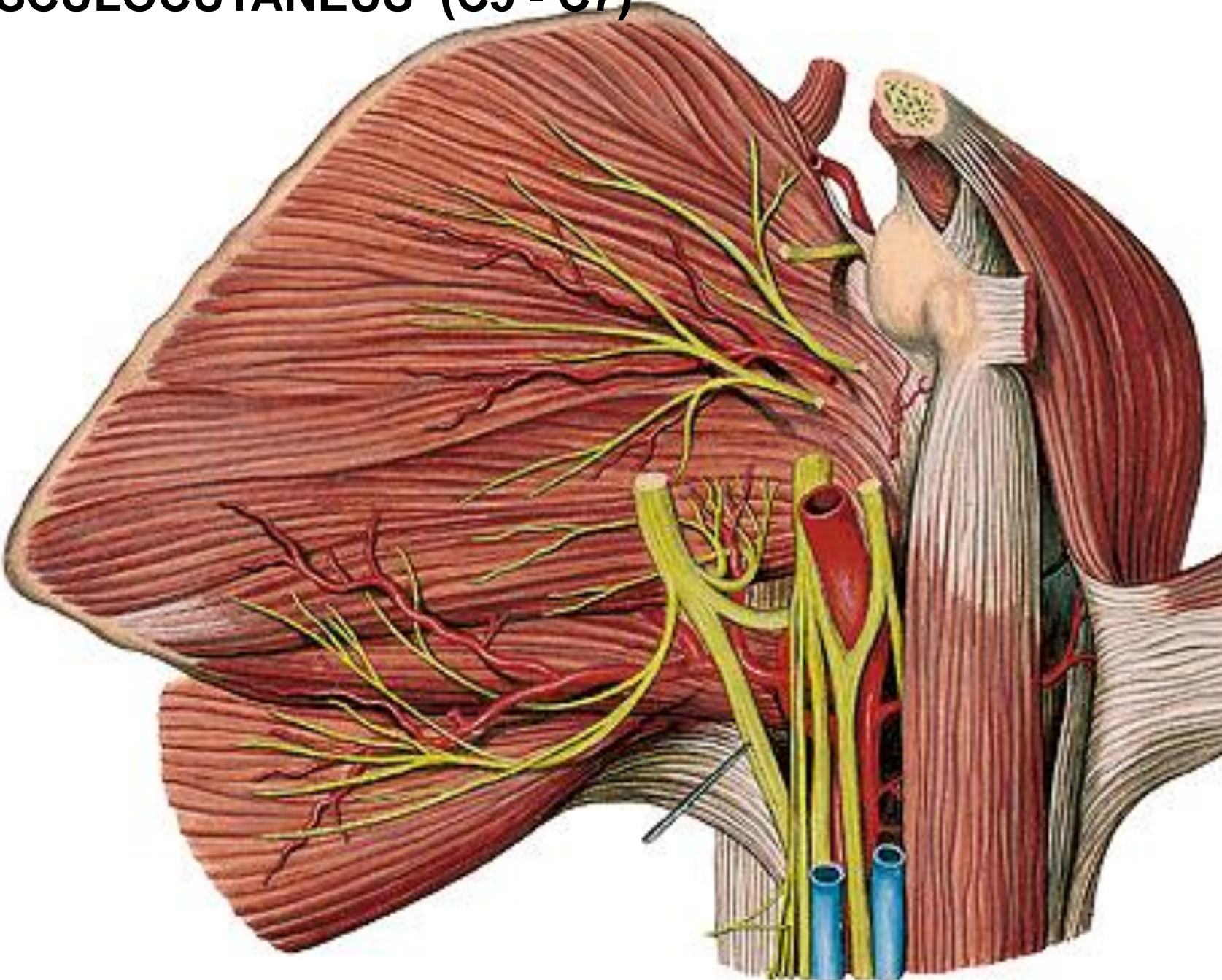
- radix medialis n. mediani
- n. ulnaris
- n. cutaneus antebrachii med.
- n. cutaneus brachii medialis



**Waiter's tip position  
(Erb's palsy):  
shoulder adduction with internal rotation  
elbow extension  
forearm pronation  
wrist flexion  
finger flexion**

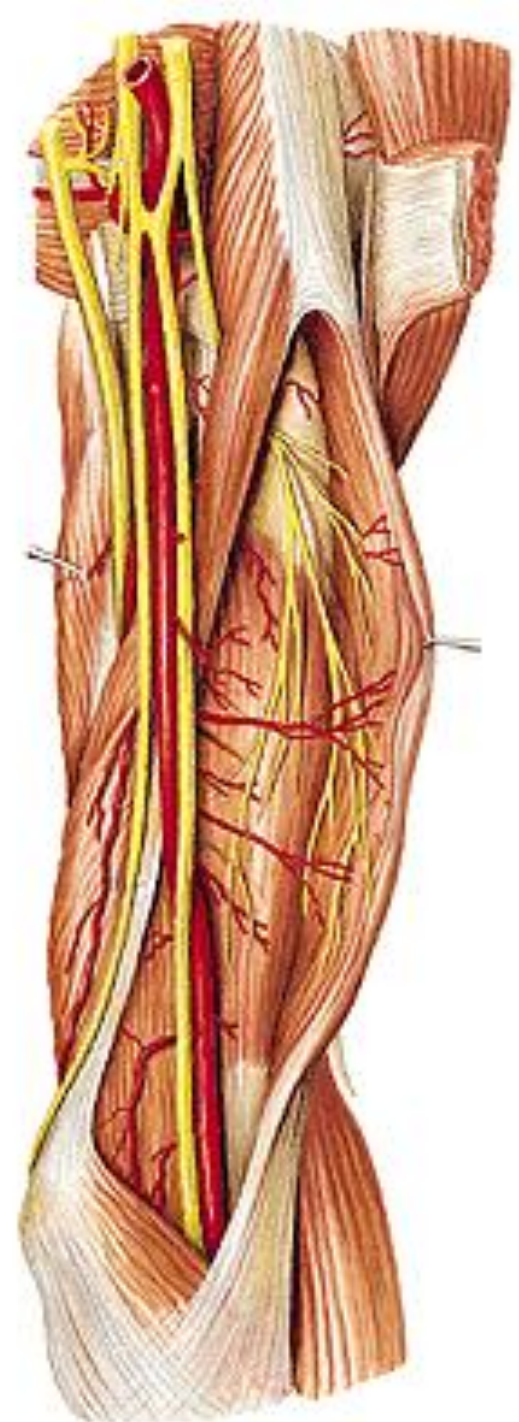
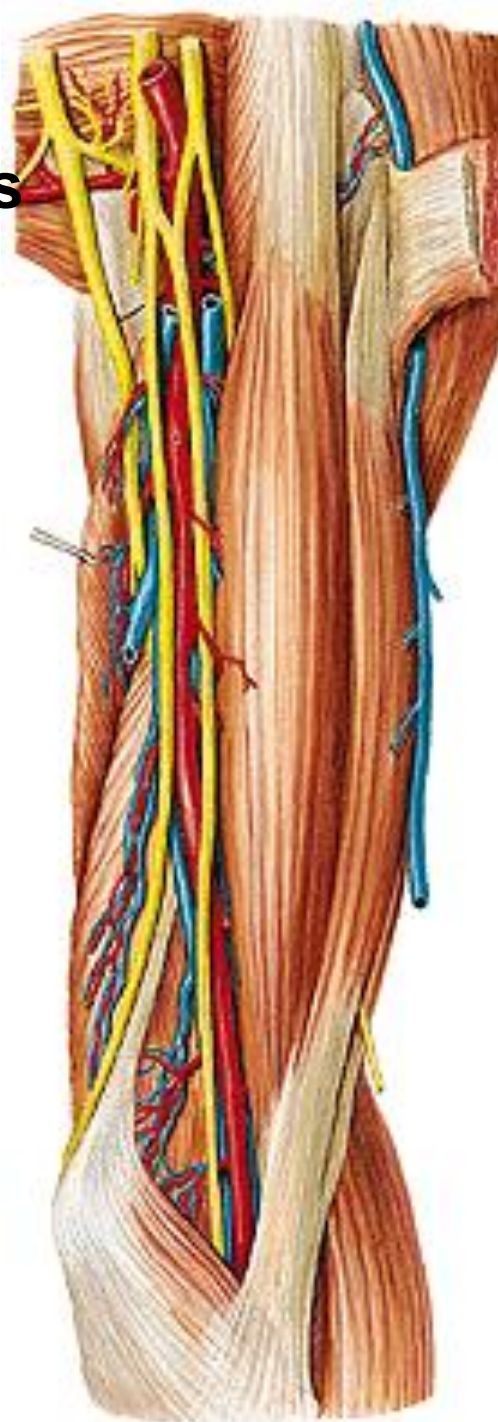


**N. MUSCULOCUTANEUS (C5 - C7)**

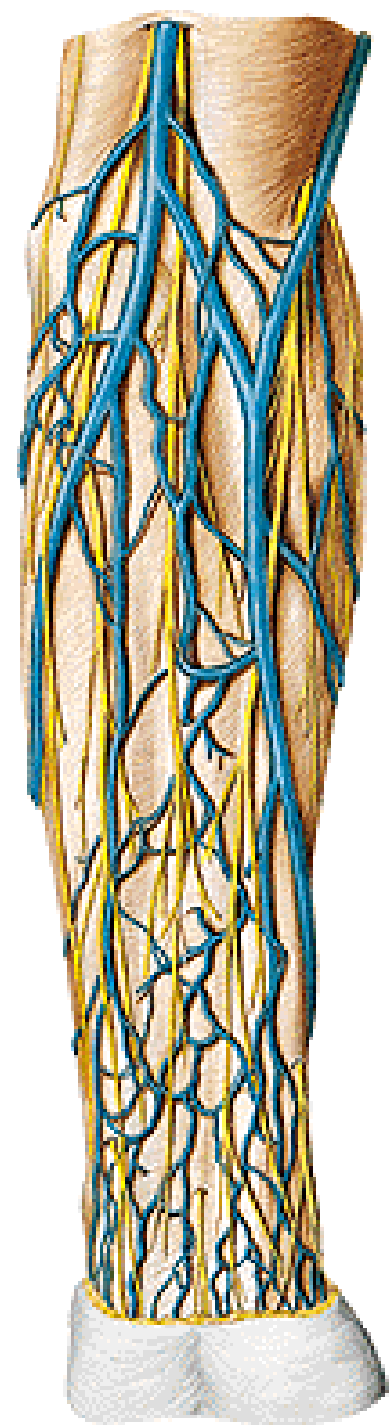


## **N. musculocutaneus**

- **m. coracobrachialis**
- **m. biceps brachii**
- **m. brachialis**

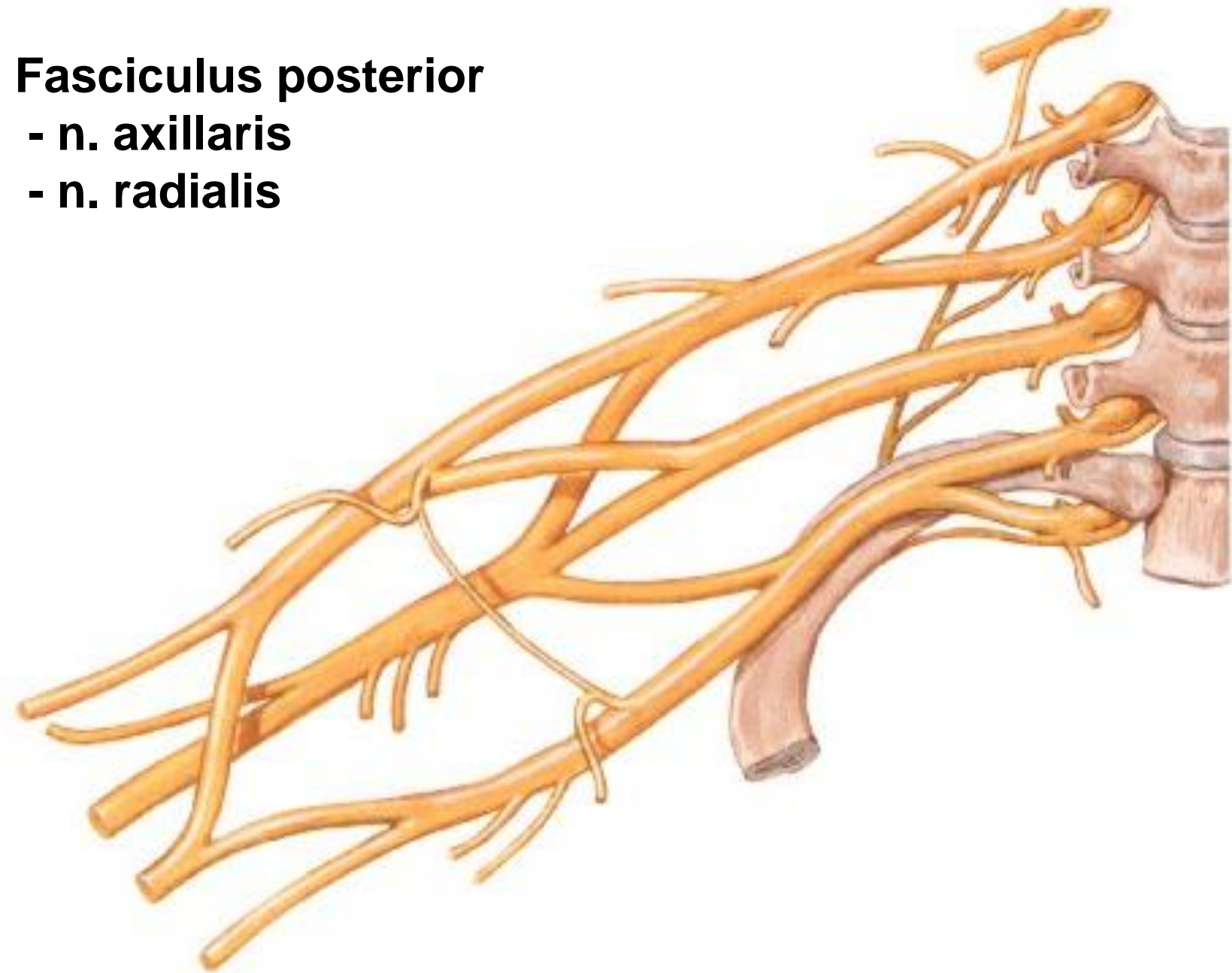


**N. cutaneus antebrachii lat.**



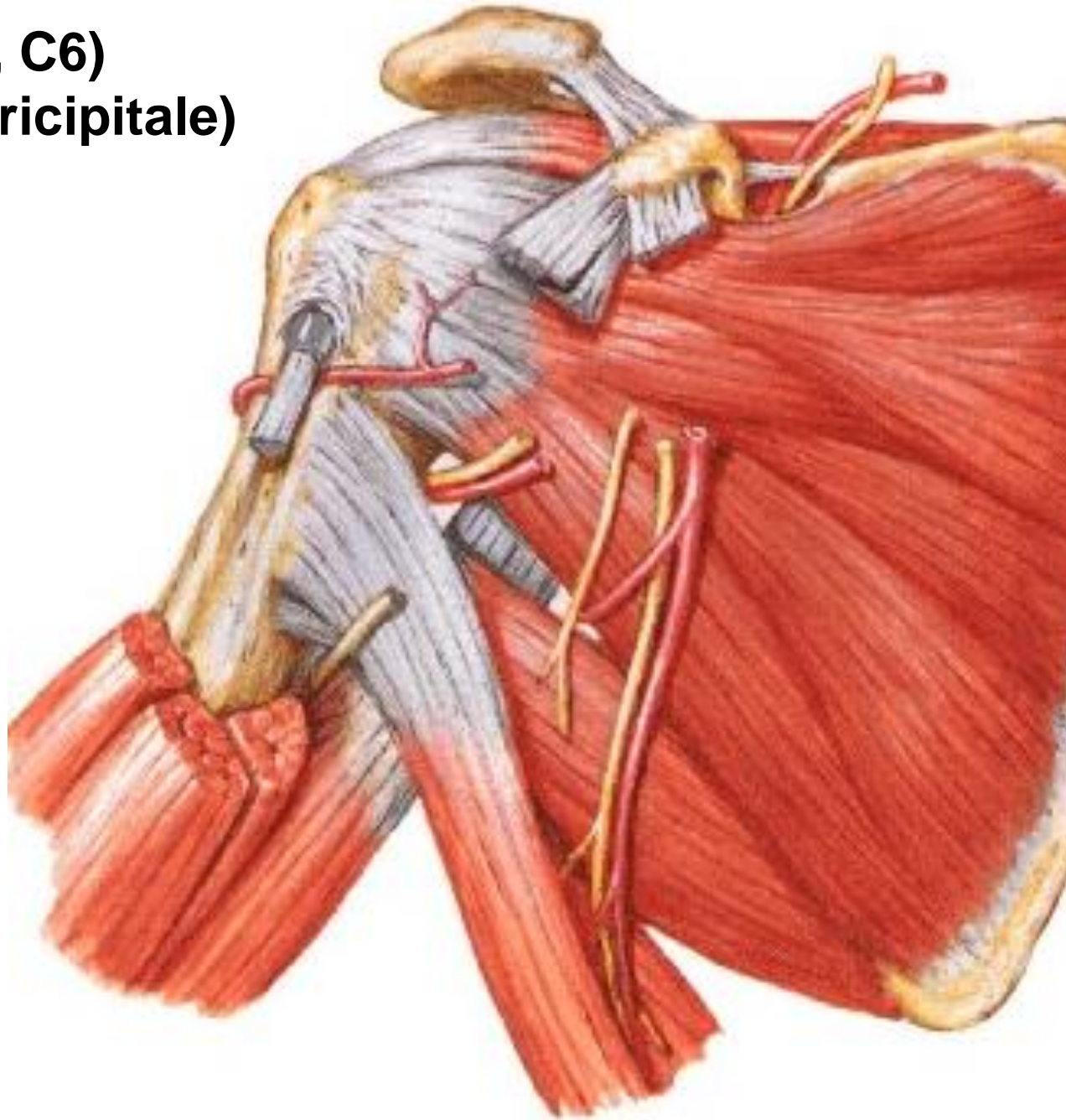
# **Fasciculus posterior**

- n. axillaris**
- n. radialis**





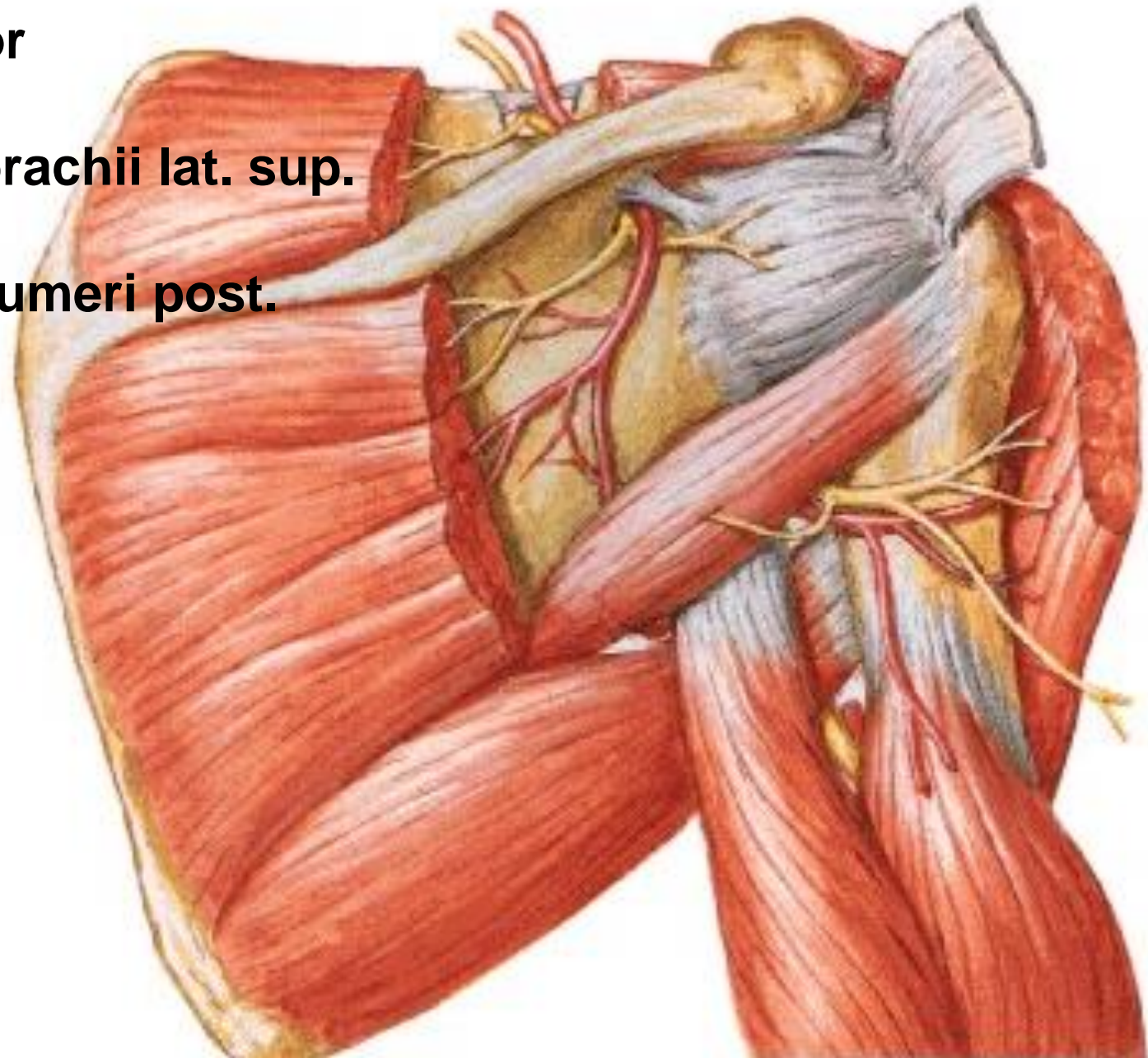
**N. AXILLARIS (C5, C6)**  
**(foramen humerotricipitale)**



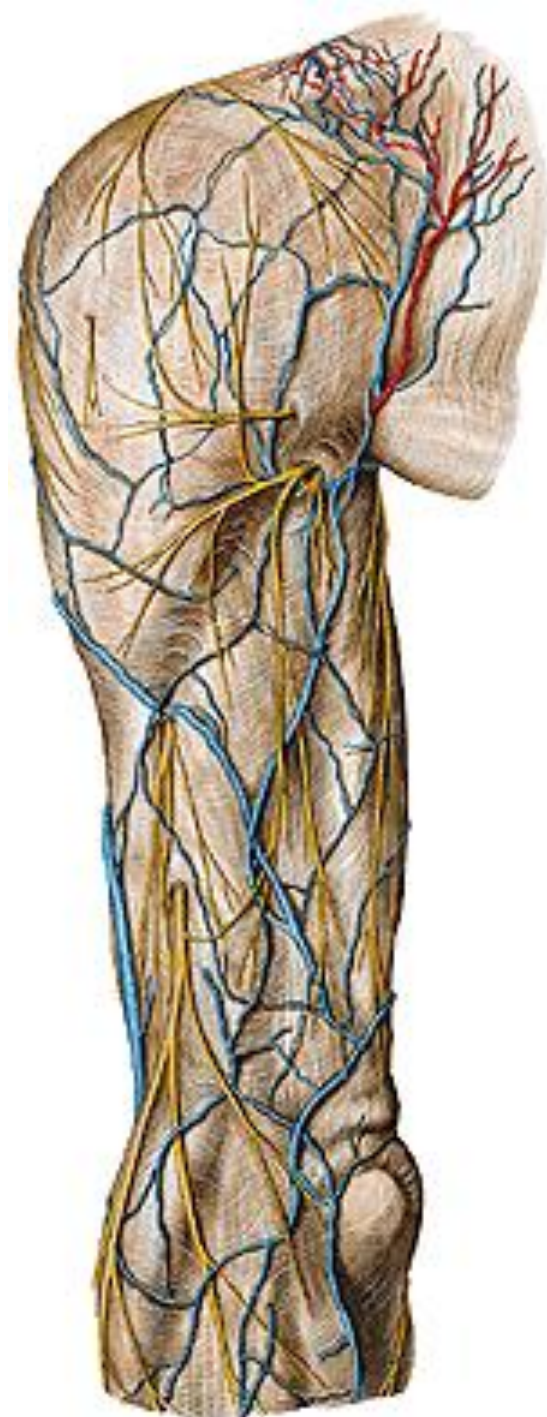## **N. axillaris**

- m. deltoideus
- m. teres minor
- art. humeri
- n. cutaneus brachii lat. sup.

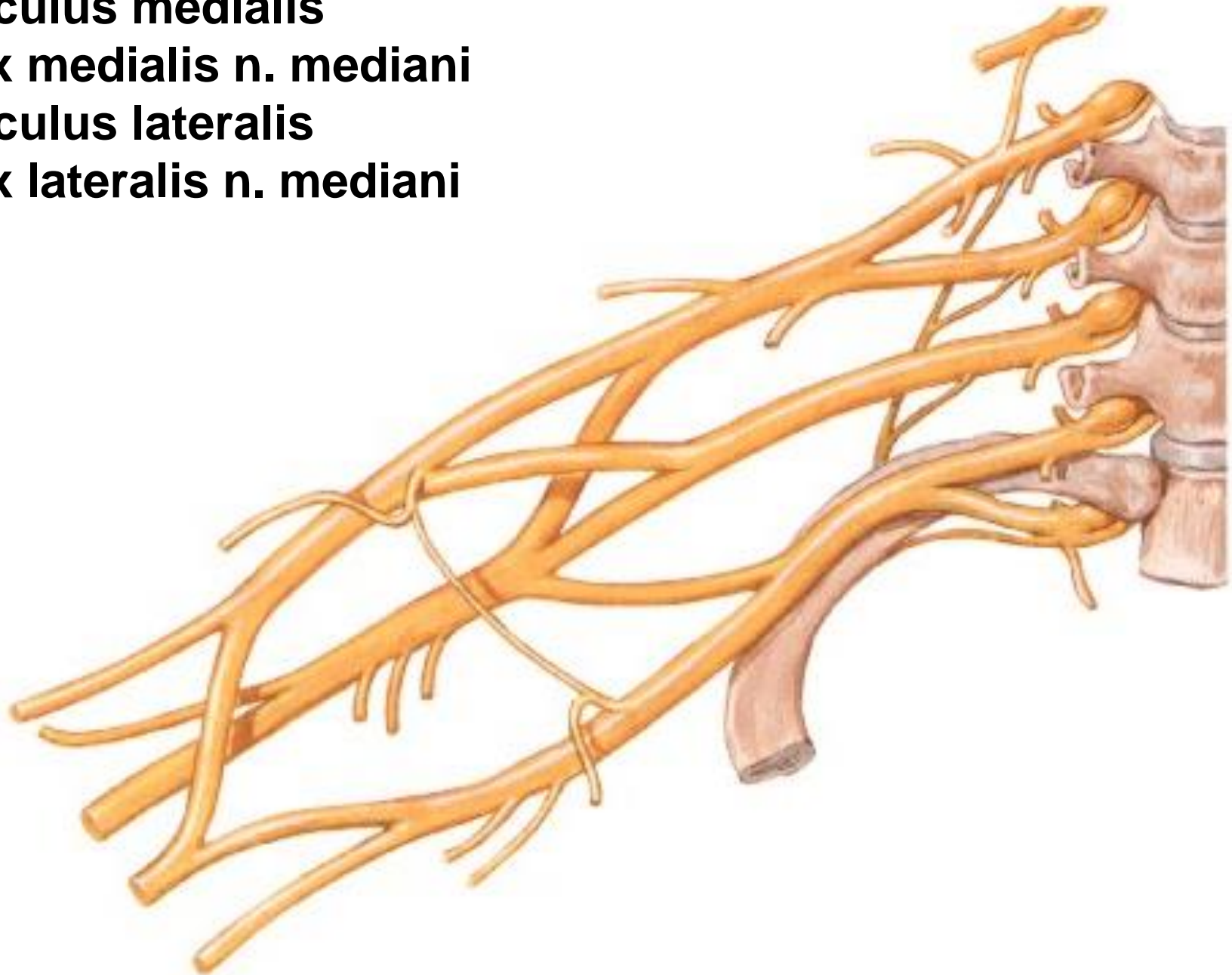
## **A. circumflexa humeri post.**



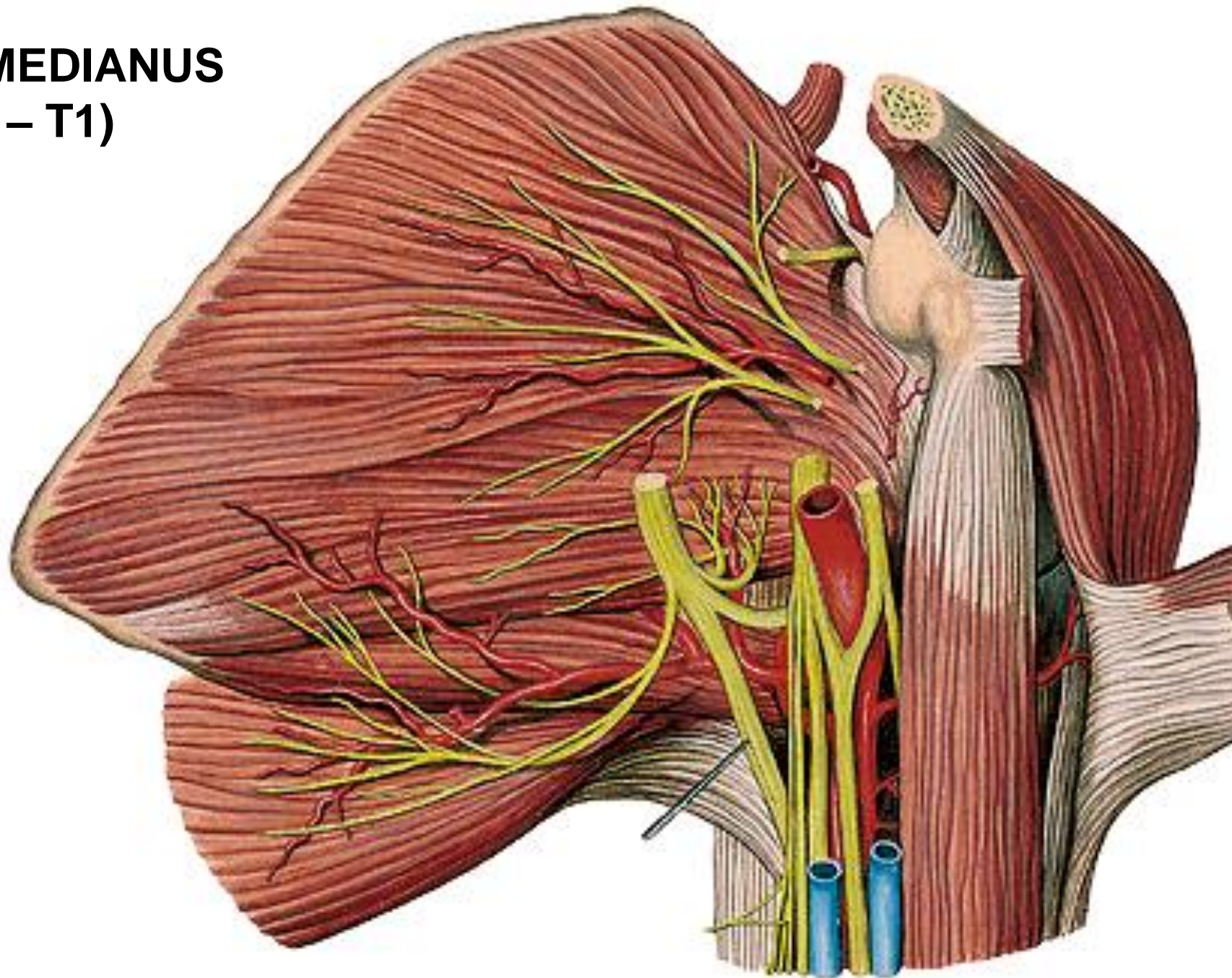
**N. cutaneus brachii lat. sup.**



**Fasciculus medialis**  
- radix medialis n. mediani  
**Fasciculus lateralis**  
- radix lateralis n. mediani

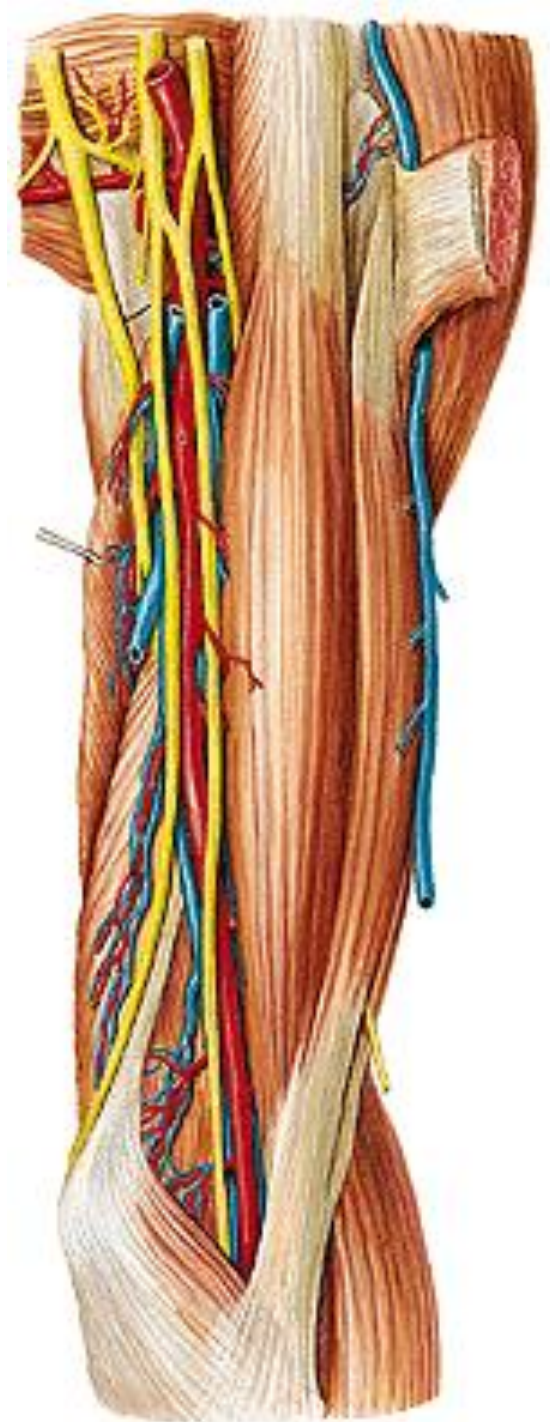


# N. MEDIANUS (C5 – T1)

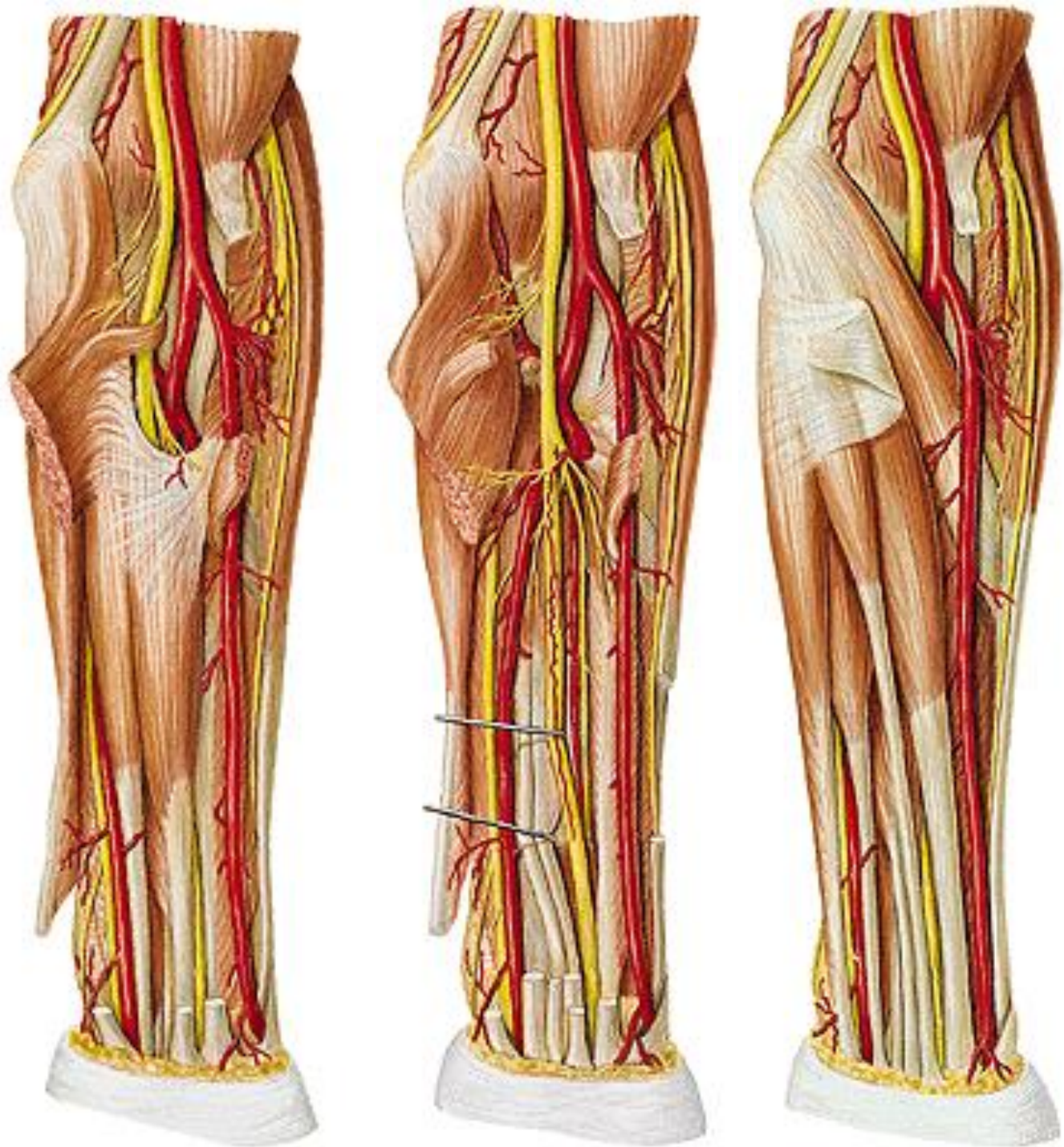

**N. medianus**

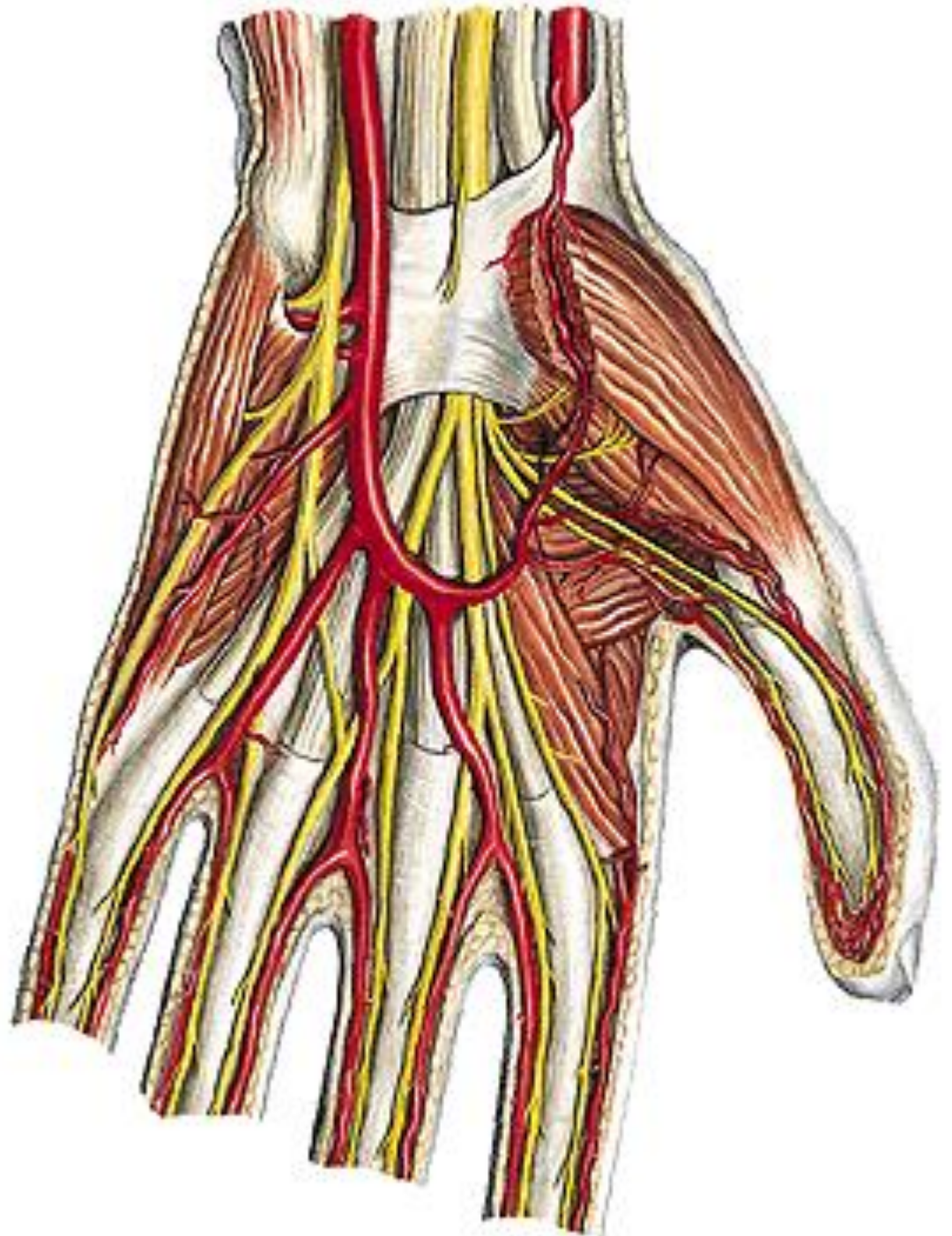
**(Sulcus bicipitalis medialis)**



# N. medianus



# N. medianus





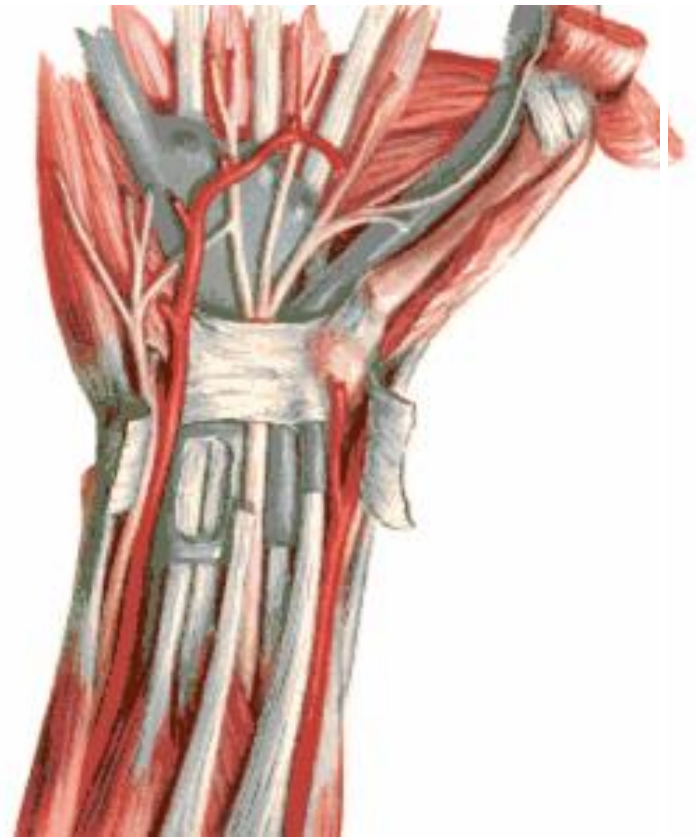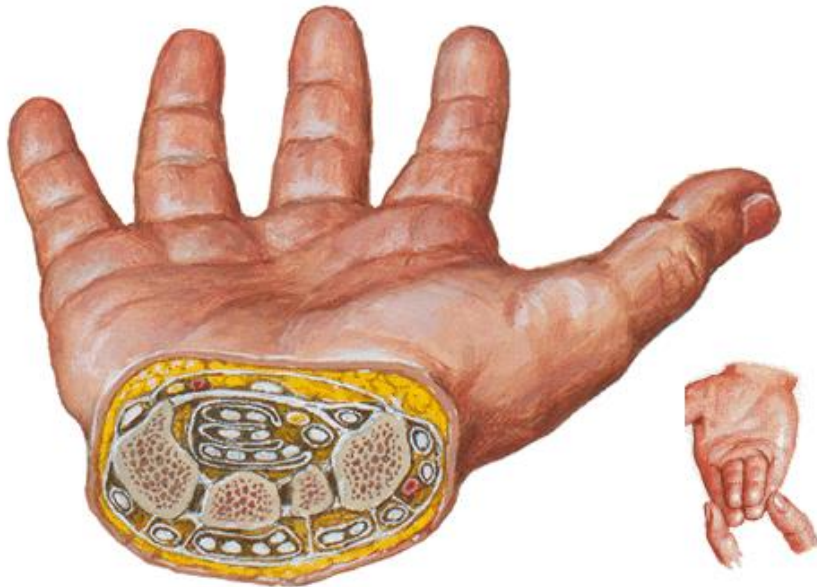**Canalis carpi: n. medianus**

**m. flexor digitorum spf. (3,4  
2,5)**

**m. flexor digitorum prof.**

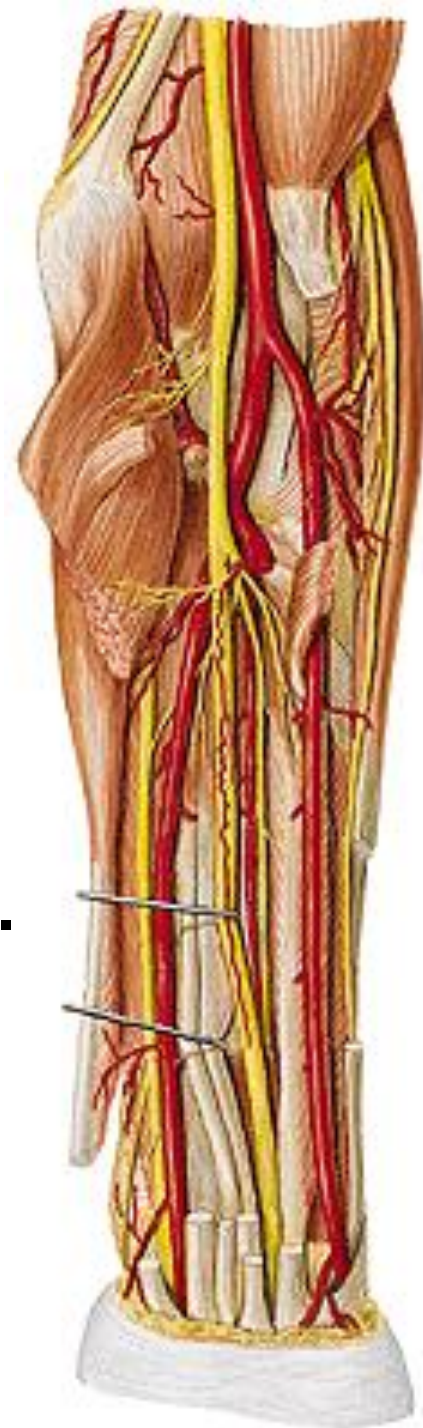**m. flexor pollicis longus**

**m. flexor carpi ulnaris**



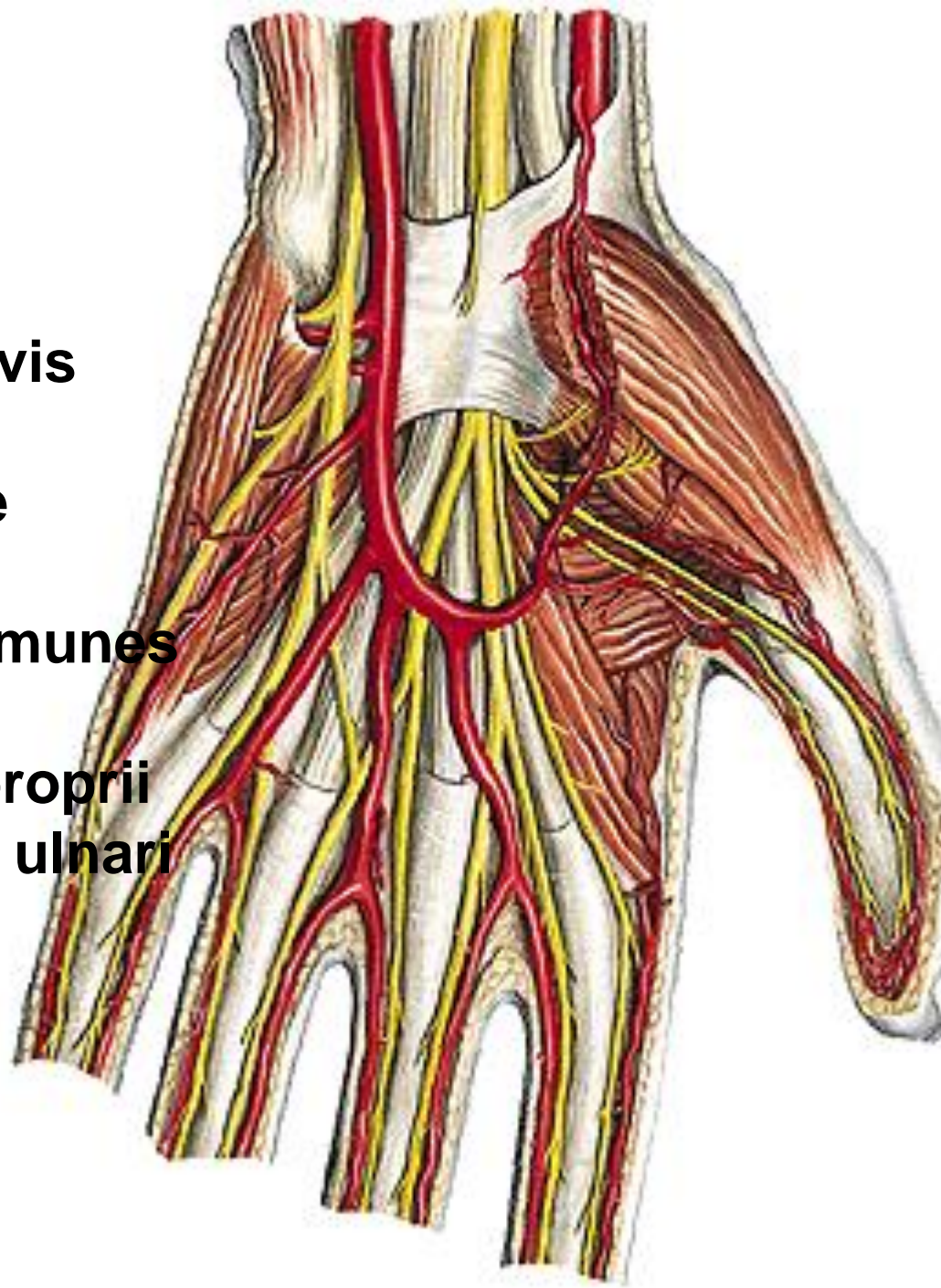
## **N. medianus**

- rr. articulares
- rr. musculares
  - m. pronator teres
  - m. flexor carpi radialis
  - m. palmaris longus
  - m. flexor digitorum spf.
- n. interosseus antebrachii ant.
  - m. flexor pollicis longus
  - radial half of m. flexor dig. prof.
  - m. pronator quadratus
- r. palmaris



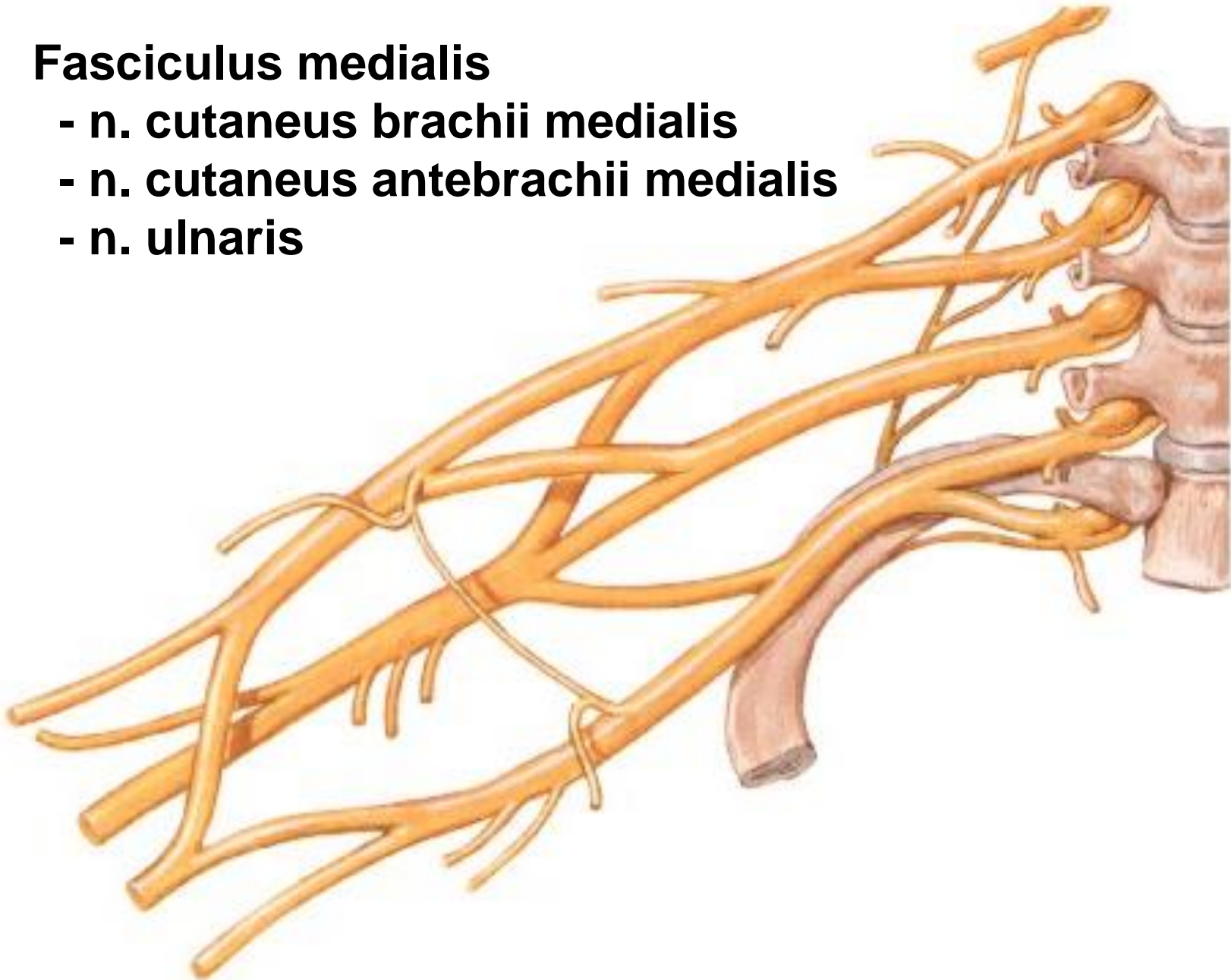
## **N. medianus**

- r. thenaris
  - m. abductor pollicis brevis
  - m. flexor pollicis brevis
    - caput superficiale
  - m. opponens pollicis
- nn. digitales palmares communes
  - mm. lumbricales (I, II)
  - nn. digitales palmares proprii
- r. communicans cum nervo ulnari



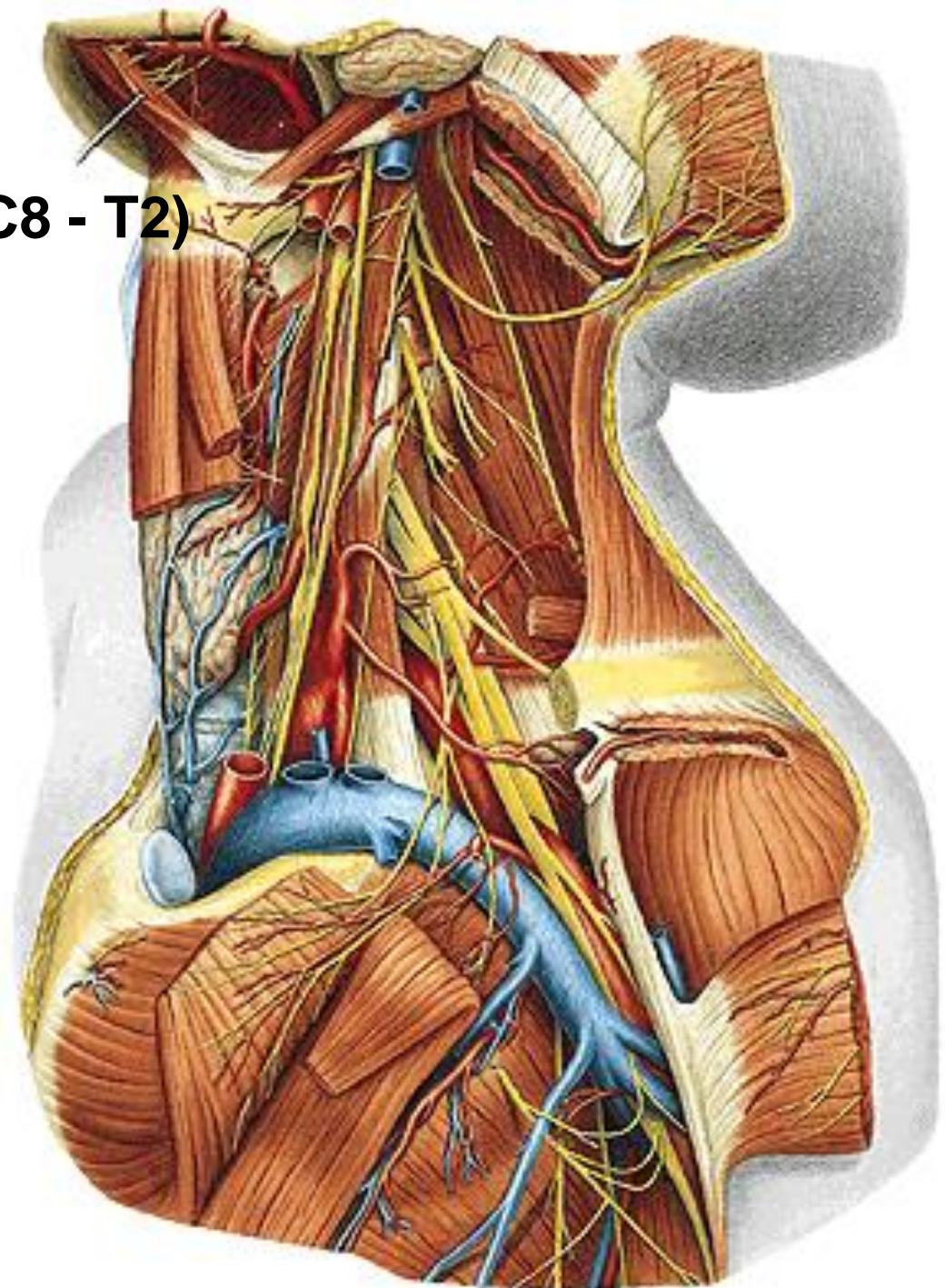
## **Fasciculus medialis**

- **n. cutaneus brachii medialis**
- **n. cutaneus antebrachii medialis**
- **n. ulnaris**

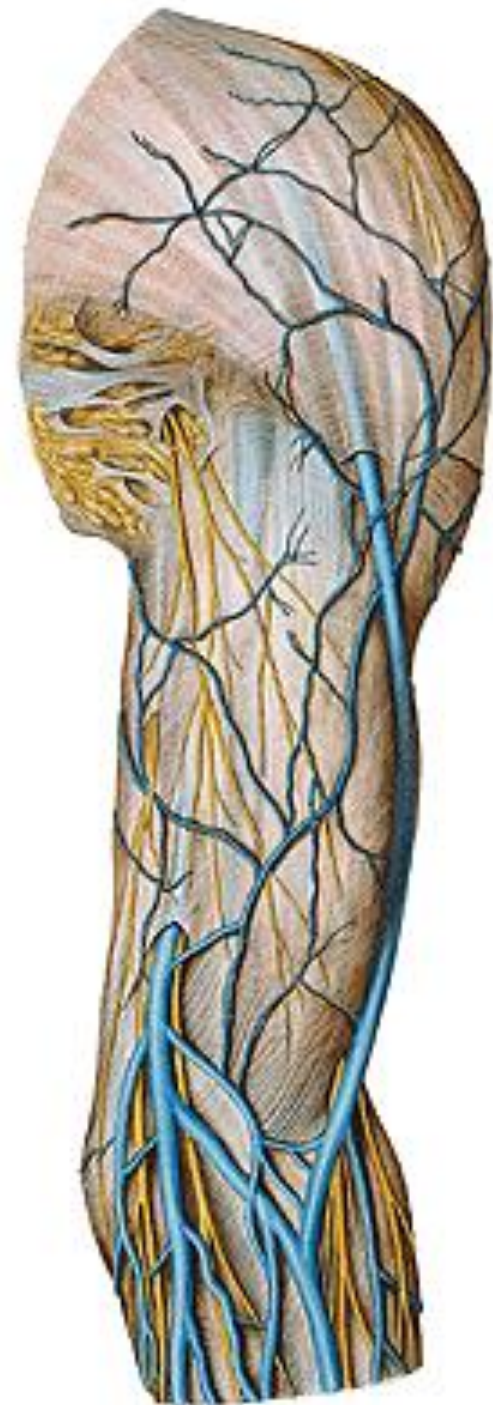


**N. cutaneus brachii med. (C8 - T2)**

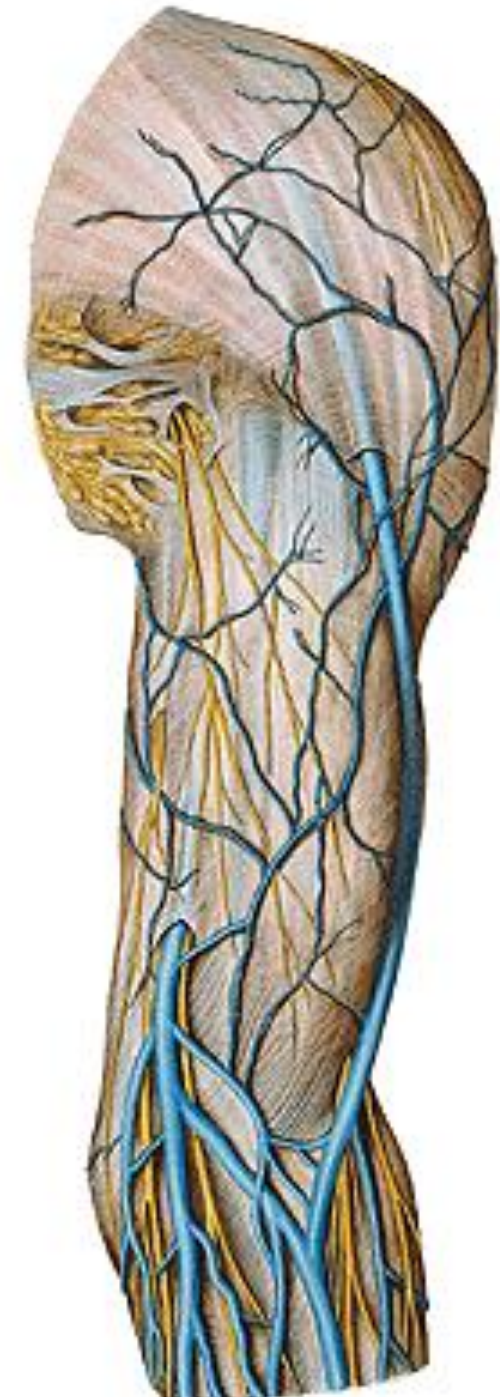
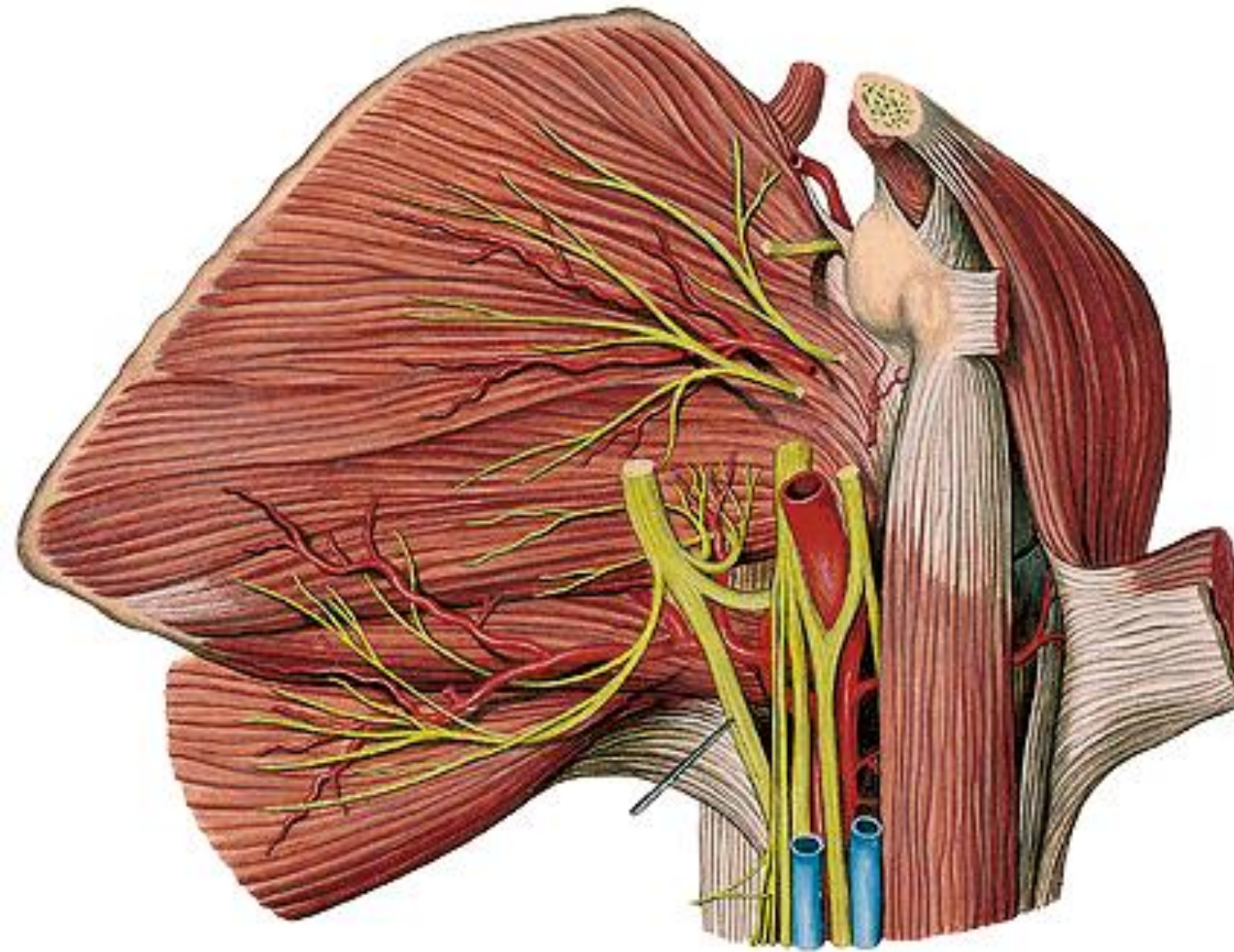
**(nn. intercostobrachiales)**



**N. cutaneus brachii med.**




# N. cutaneus antebrachii med. (C8, T1)



## **N. cutaneus antebrachii med.**

- r. anterior**
- r. posterior (ulnaris)**



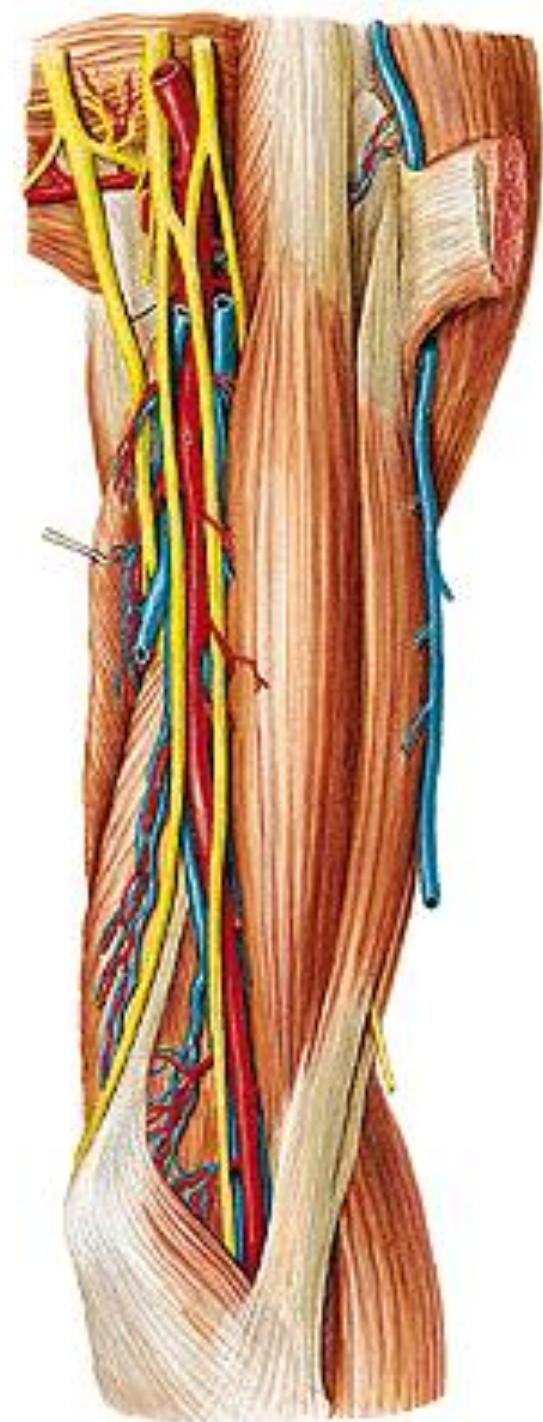
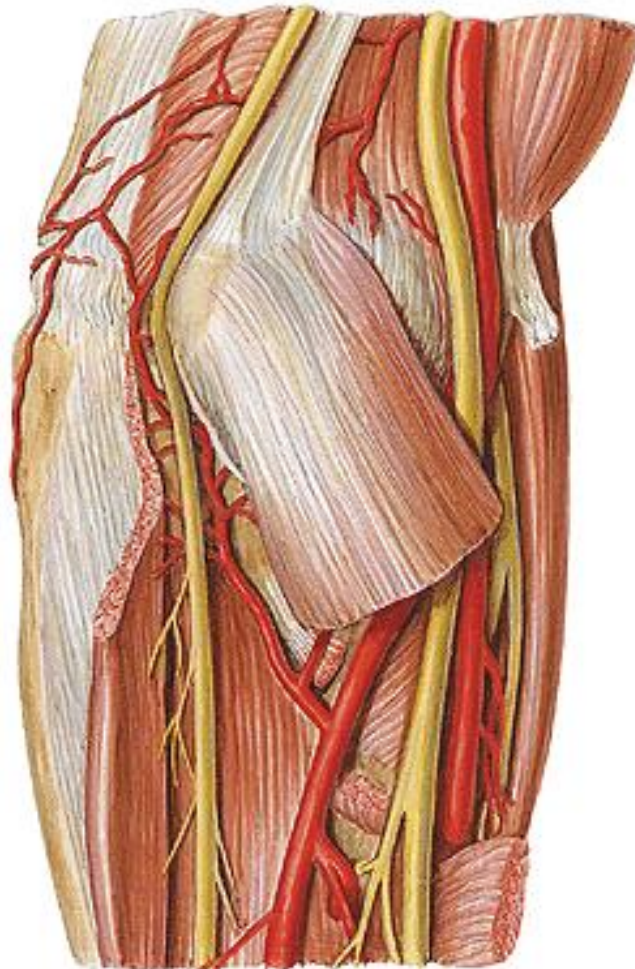


**N. ulnaris (C7 - T1)**

**sulcus bicipitalis medialis**

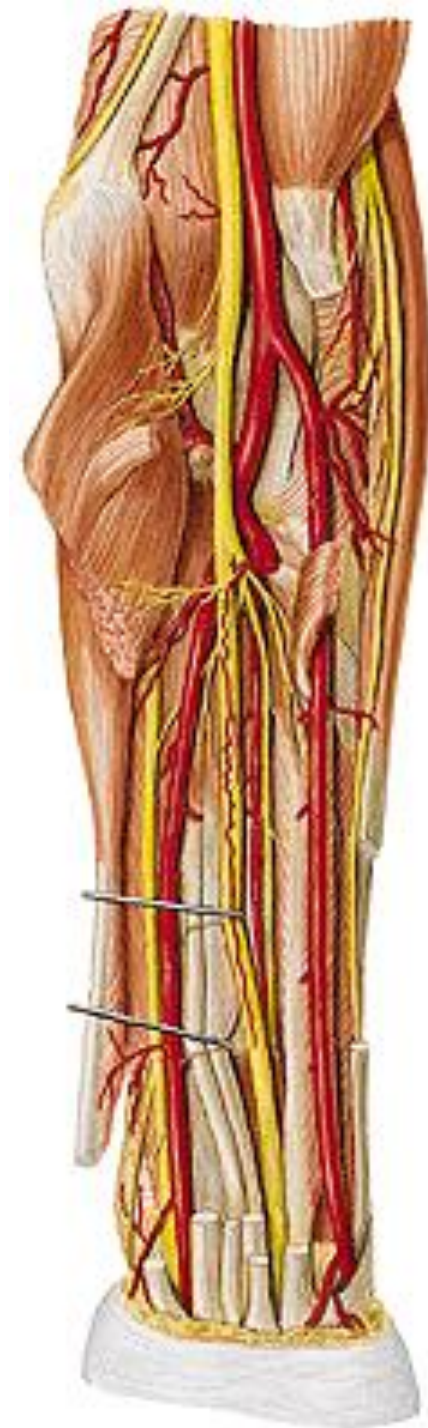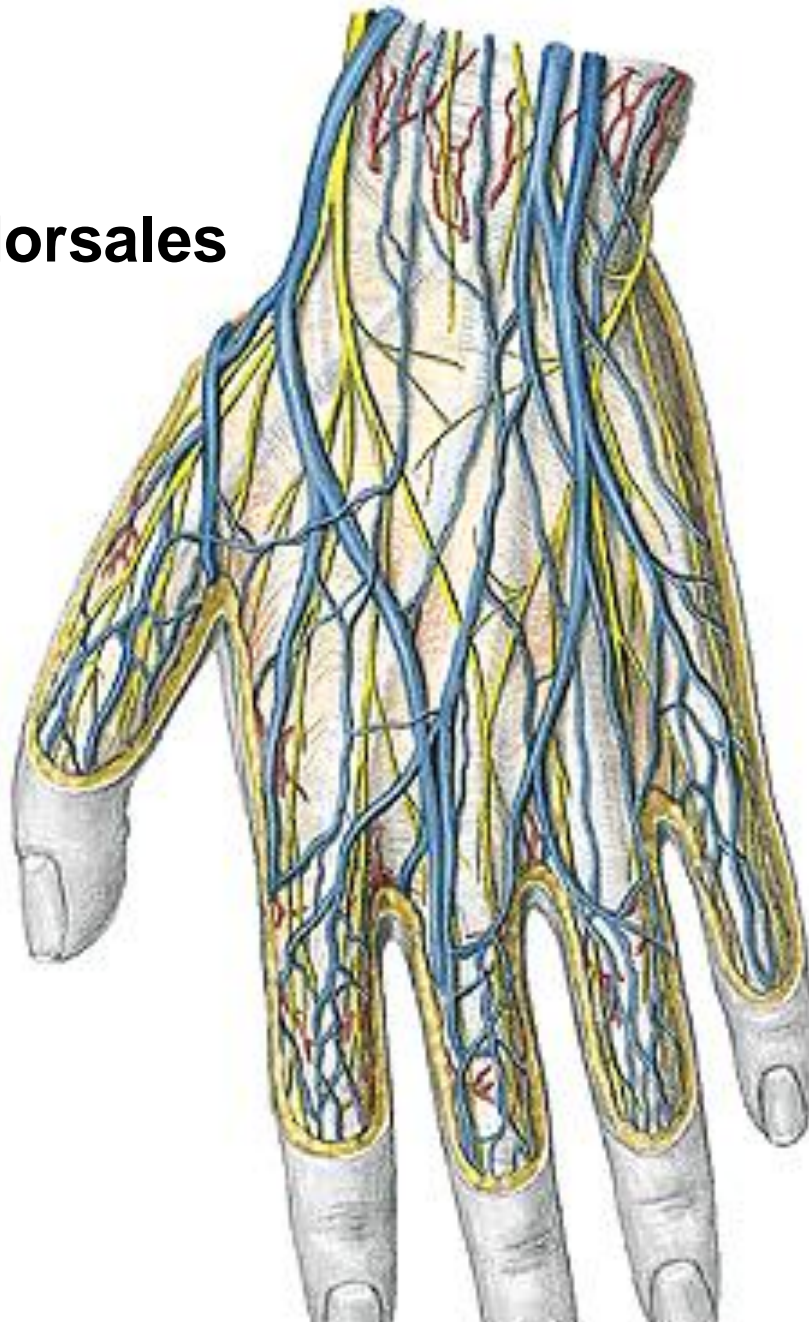
**septum intermusculare brachii mediale**

**sulcus n. ulnaris**



# N. ulnaris

- rr. articulares
- rr. musculares
- r. dorsalis
- nn. digitales dorsales

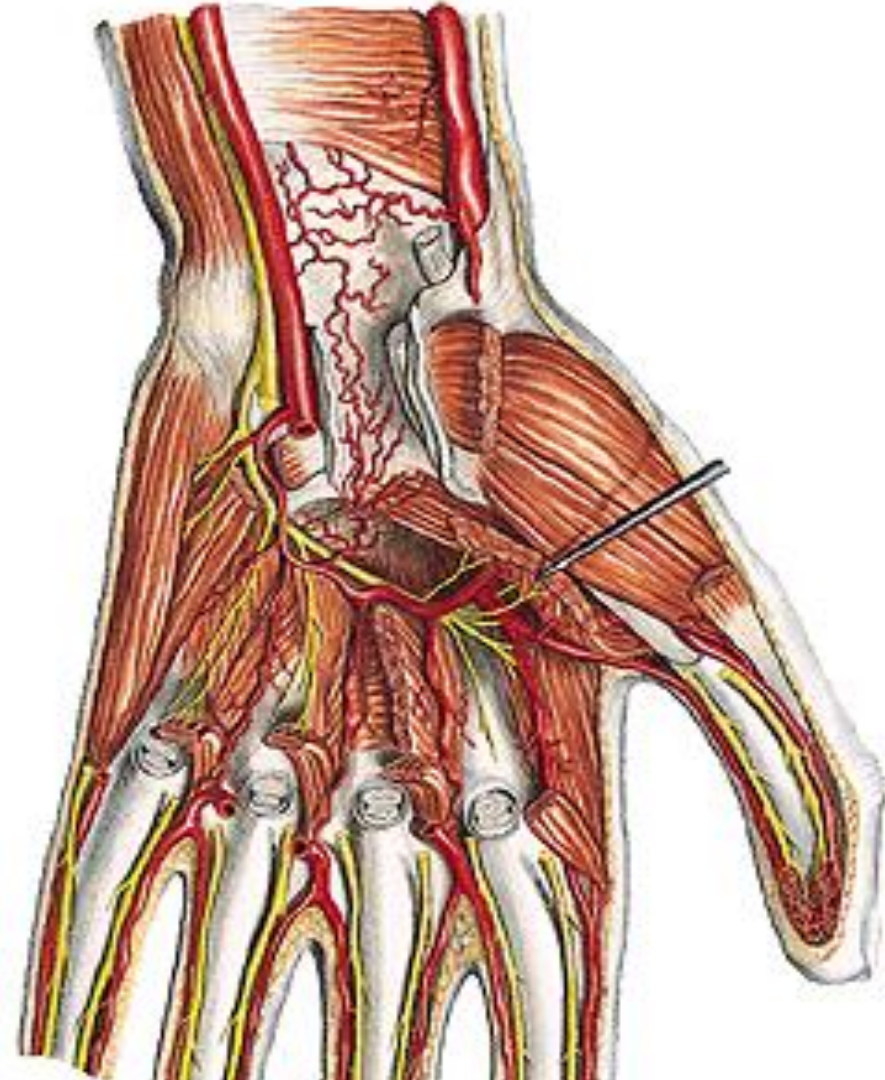
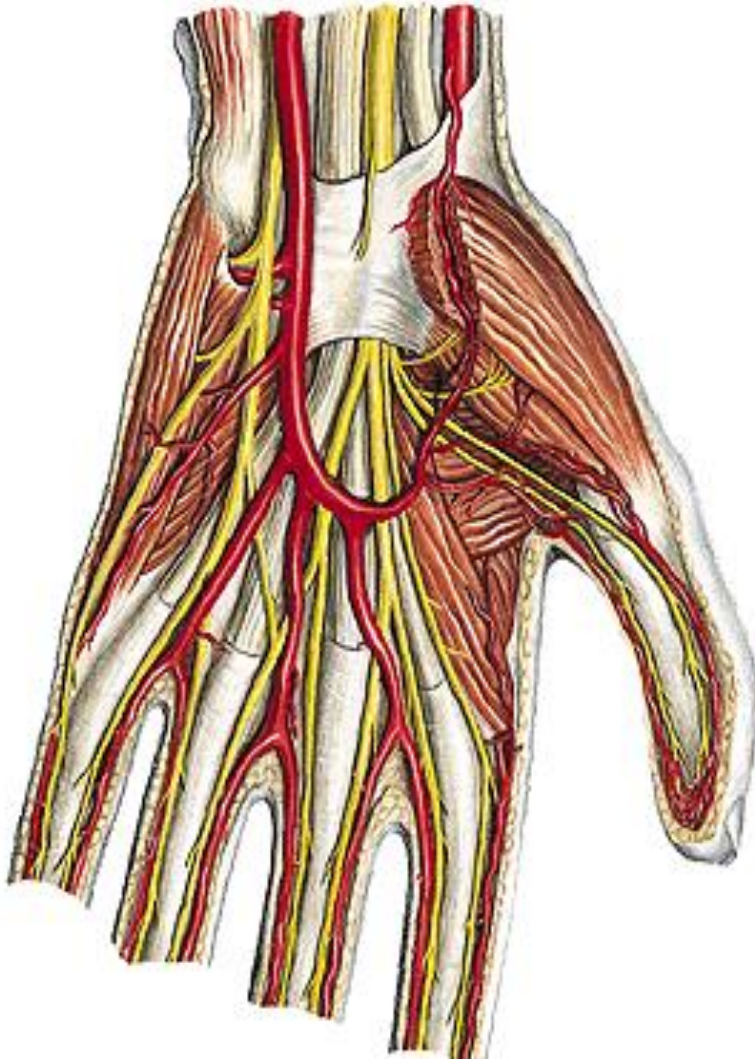


# N. ULNARIS

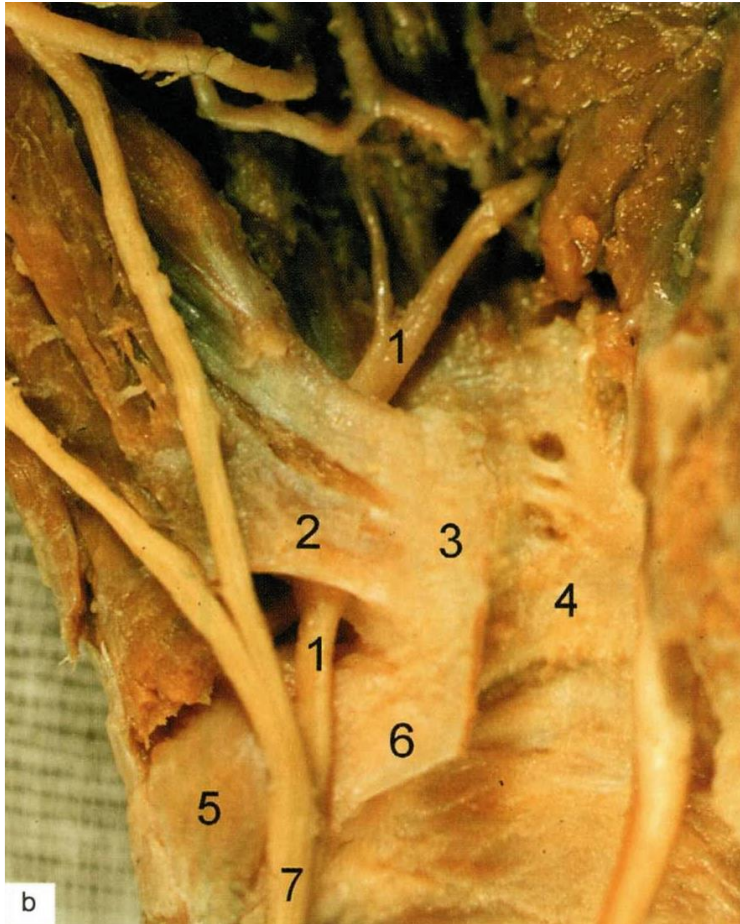
- r. palmaris

- r. superficialis - nn. dig. palmares comm. et proprii

- r. profundus - rr. musculares



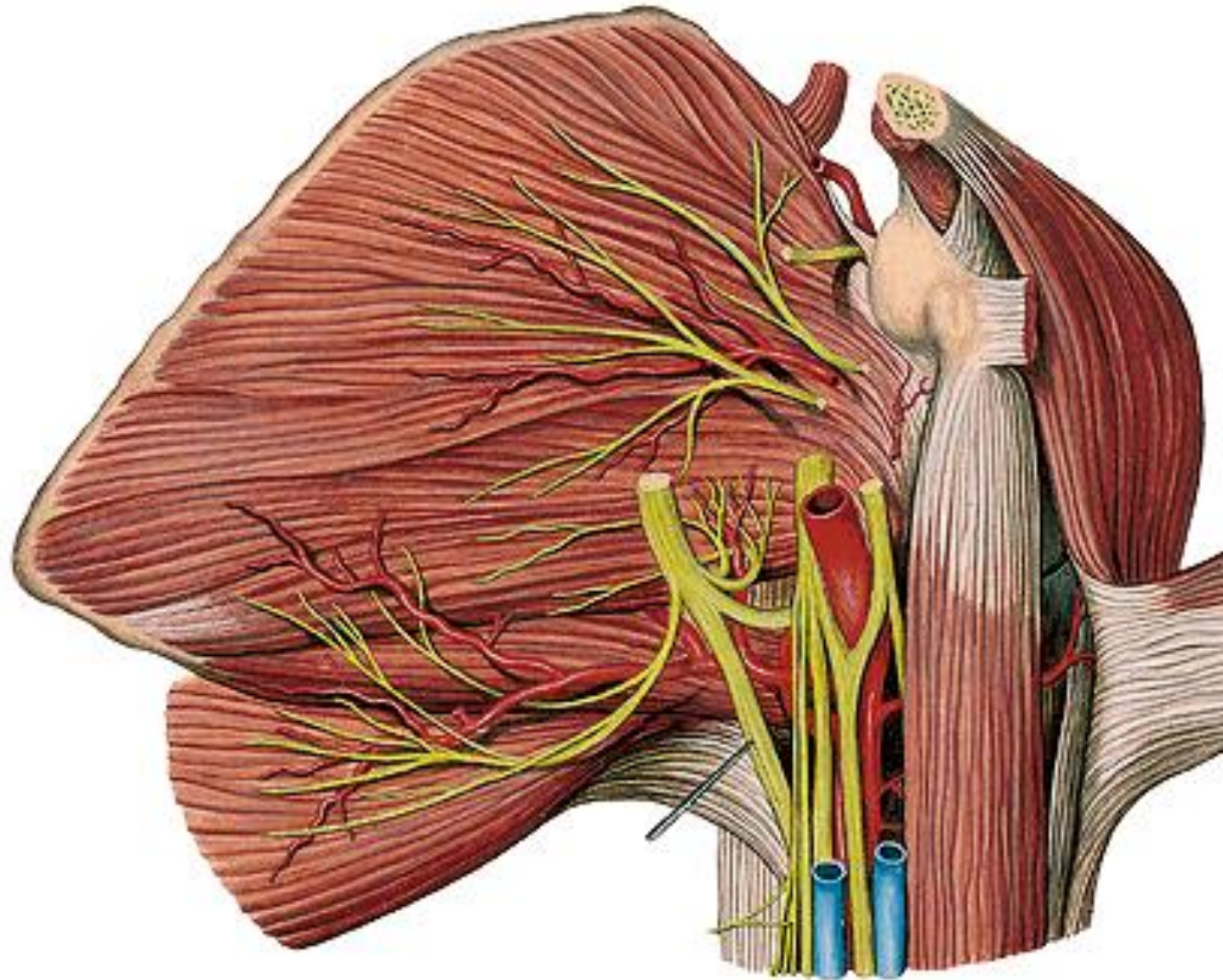
# Ulnar (Guyon) canal



1. Ramus prof. n. ulnaris
2. Hiatus distalis (pisohamate canal)
3. Hamulus ossis hamati
4. Carpal tunnel
5. Os pisiforme
6. Lig. pisohamatum
7. N. ulnaris

**Ulnar nerve entrapment - Claw hand**

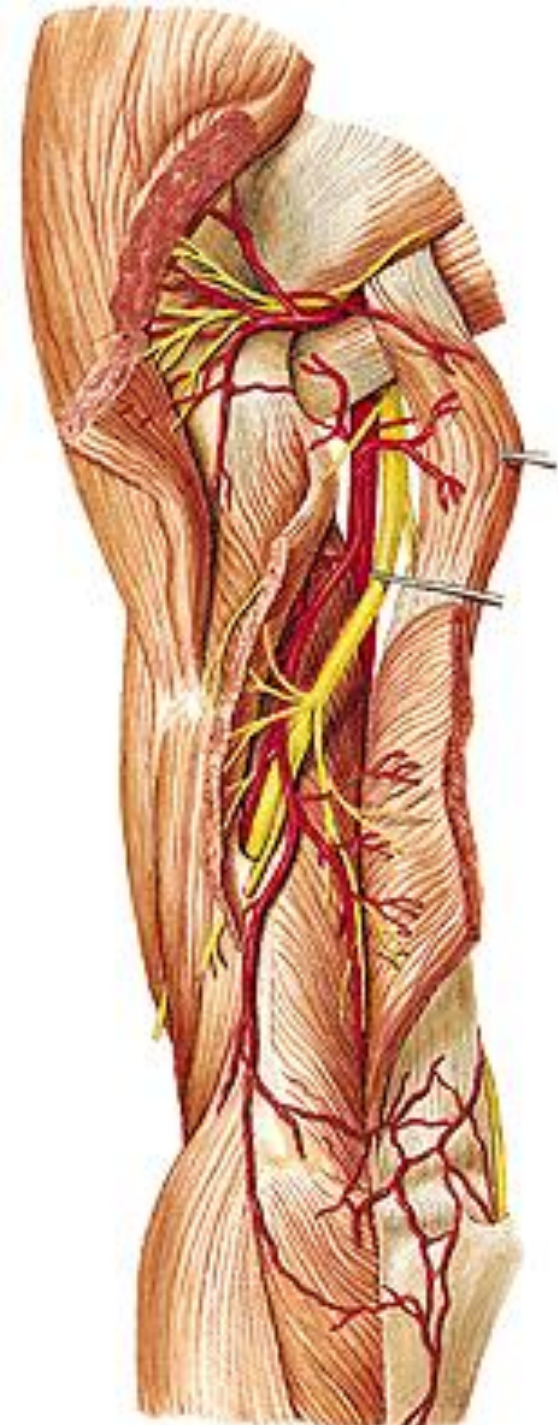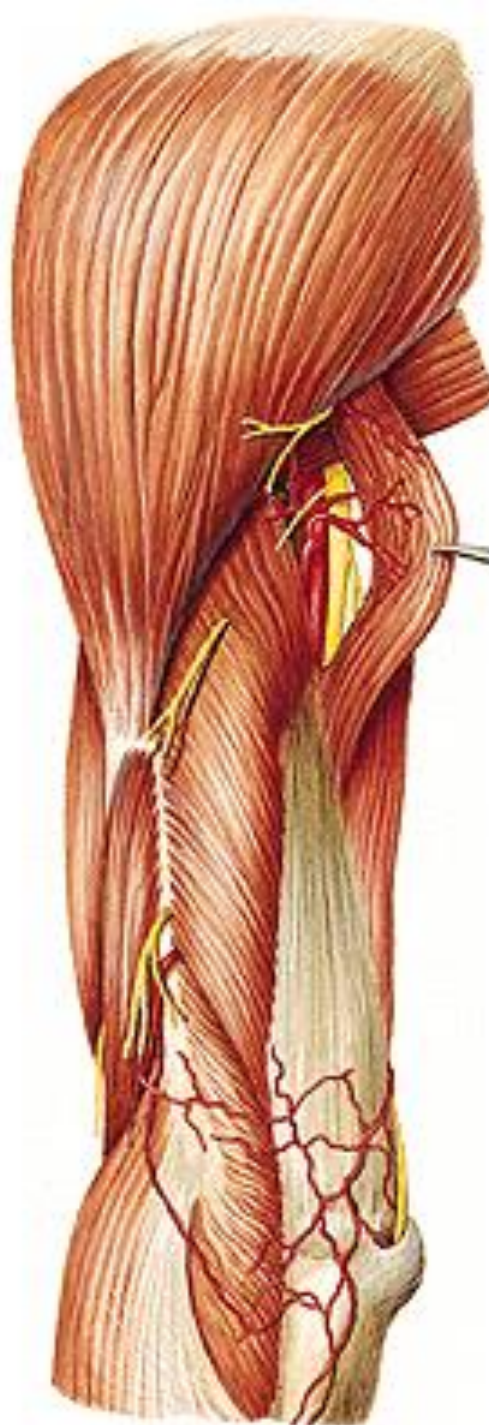# N. radialis (C5 – T1)



**N. radialis**

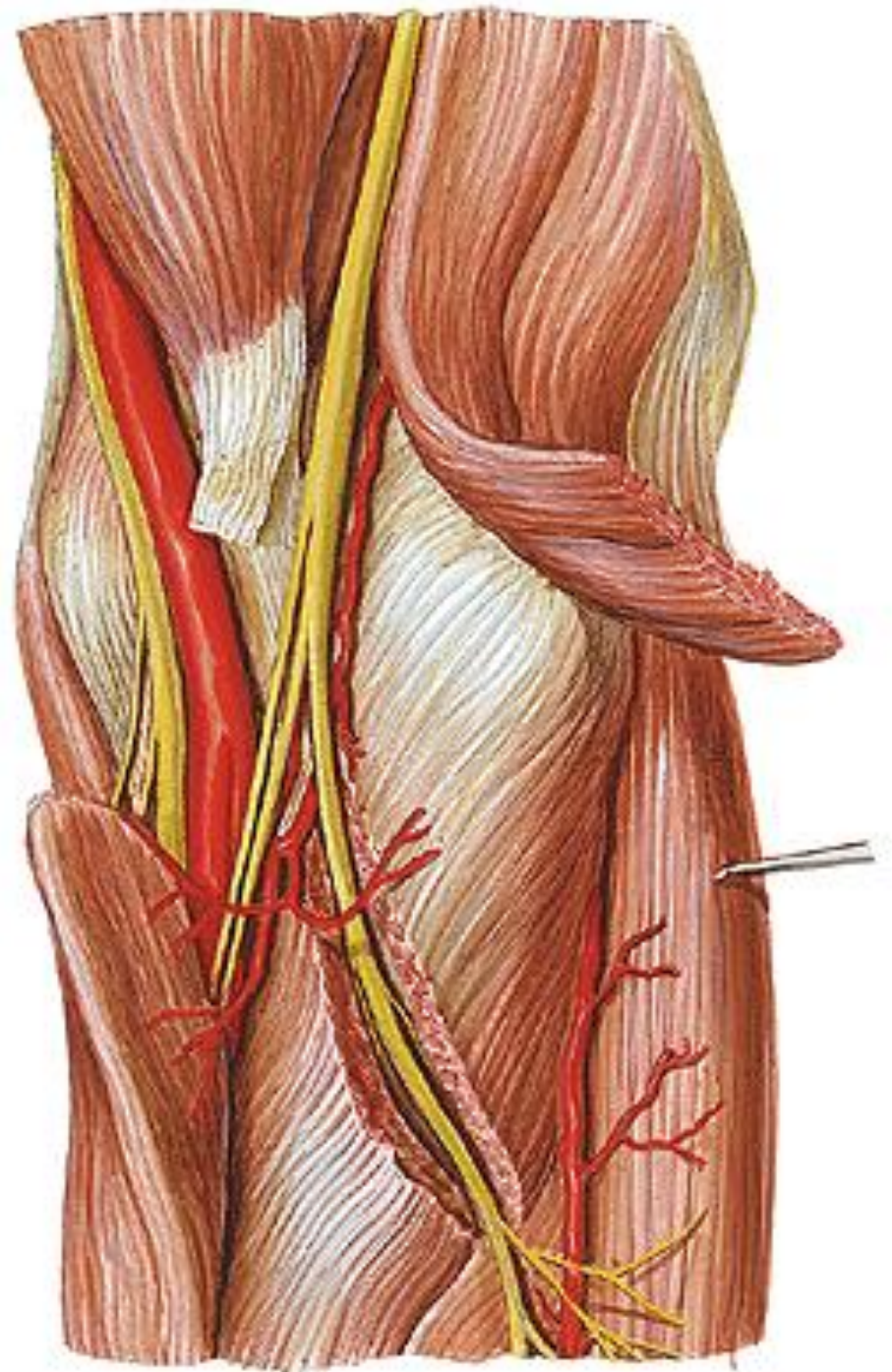
**sulcus n. radialis**

**(a. profunda brachii)**



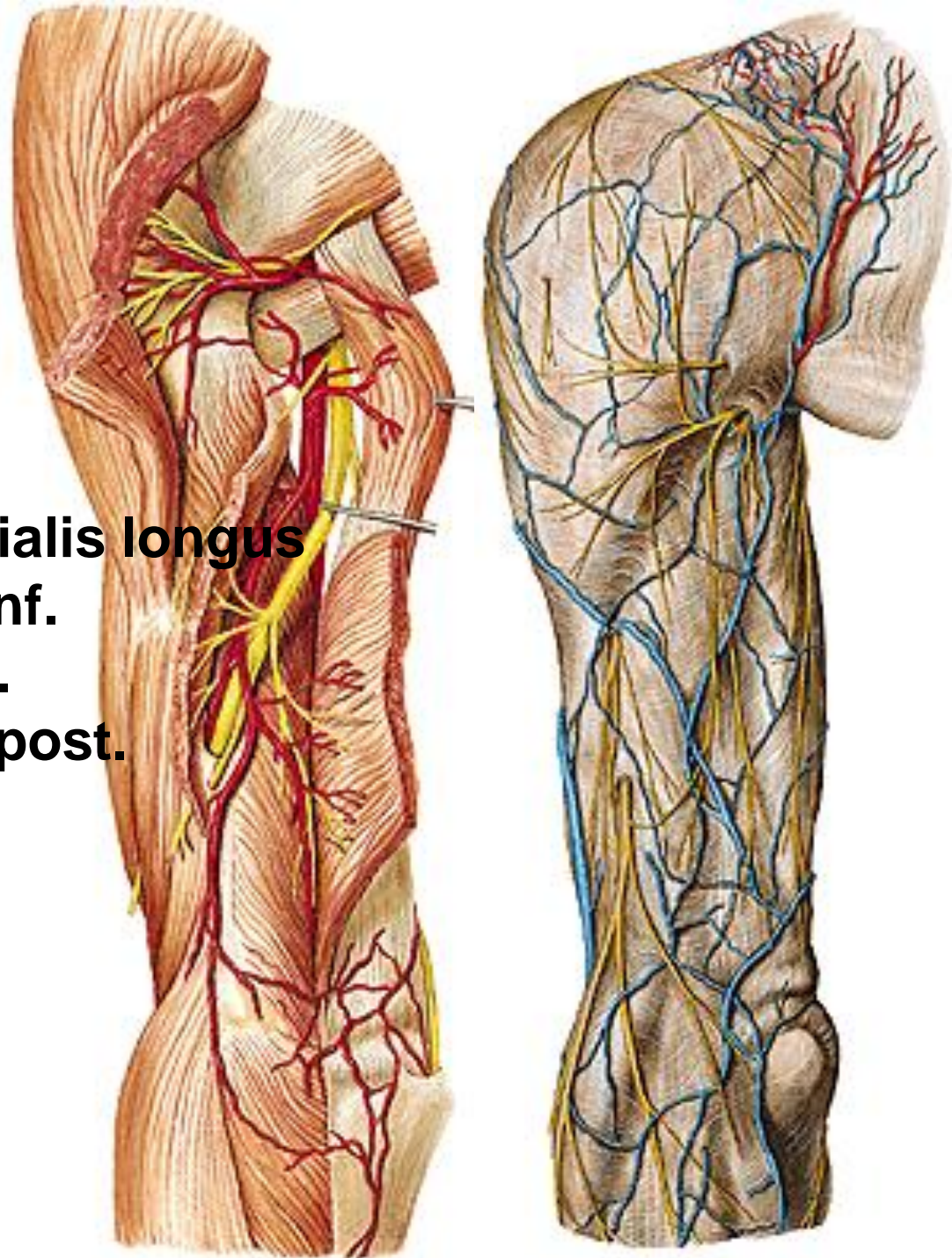
# **N. radialis**

- **r. superficialis**
- **r. profundus**



# **N. radialis**

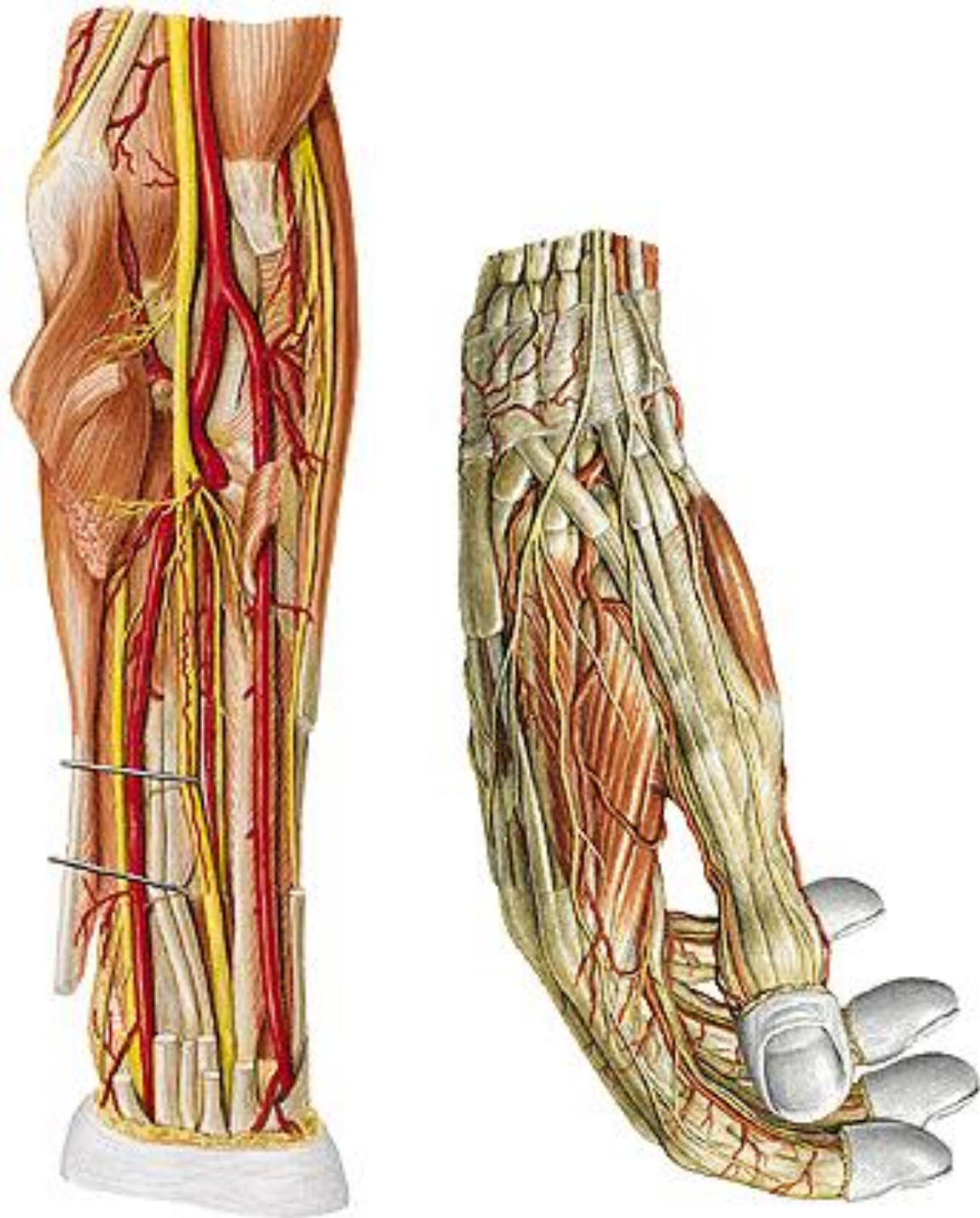
- rr. musculares
  - m. triceps brachii
  - m. anconeus
  - m. brachioradialis
  - m. extensor carpi radialis longus
- n. cutaneus brachii lat. inf.
- n. cutaneus brachii post.
- n. cutaneus antebrachii post.





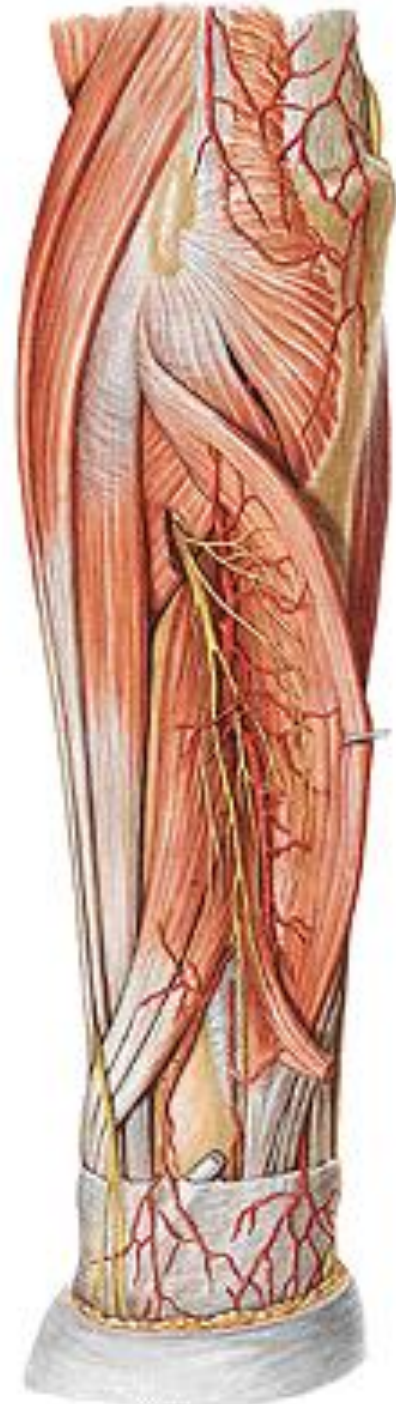
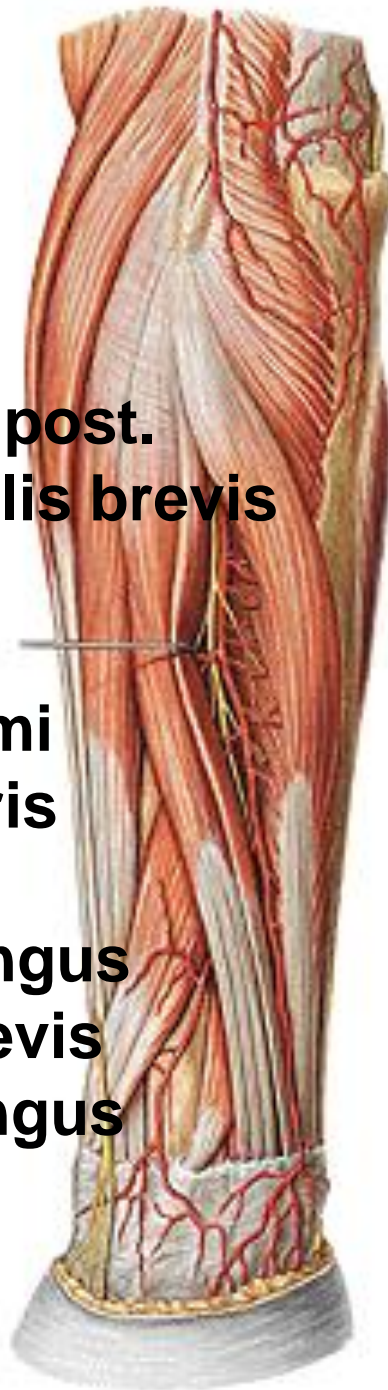# N. RADIALIS

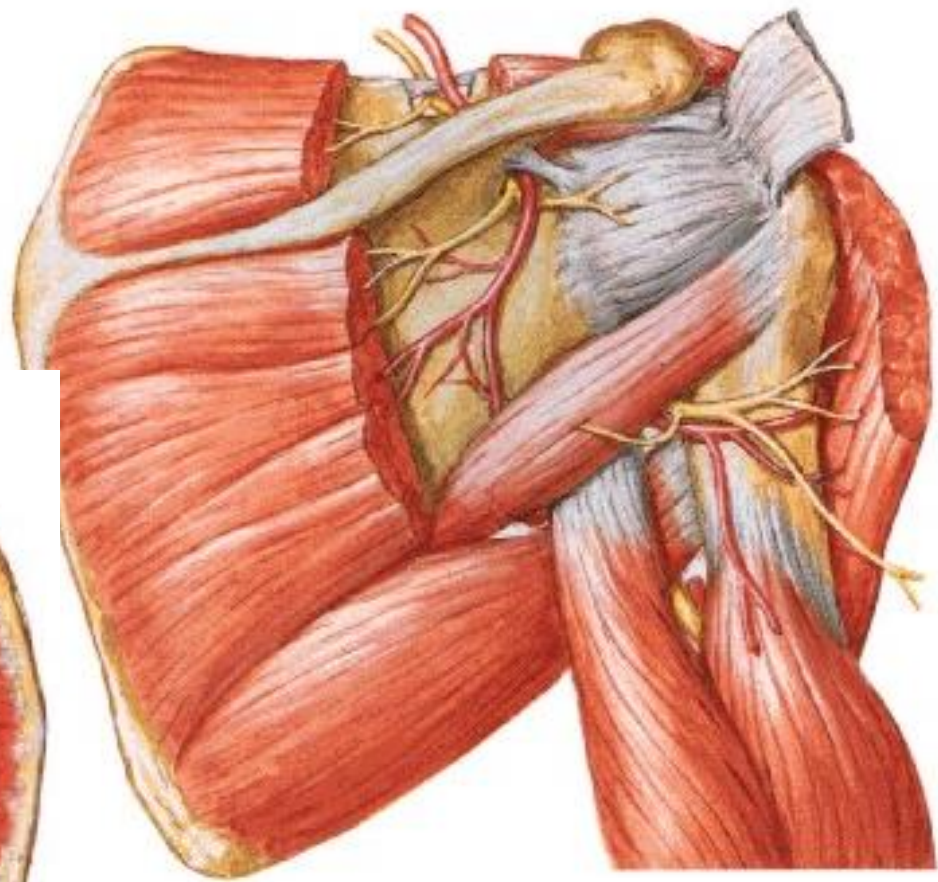
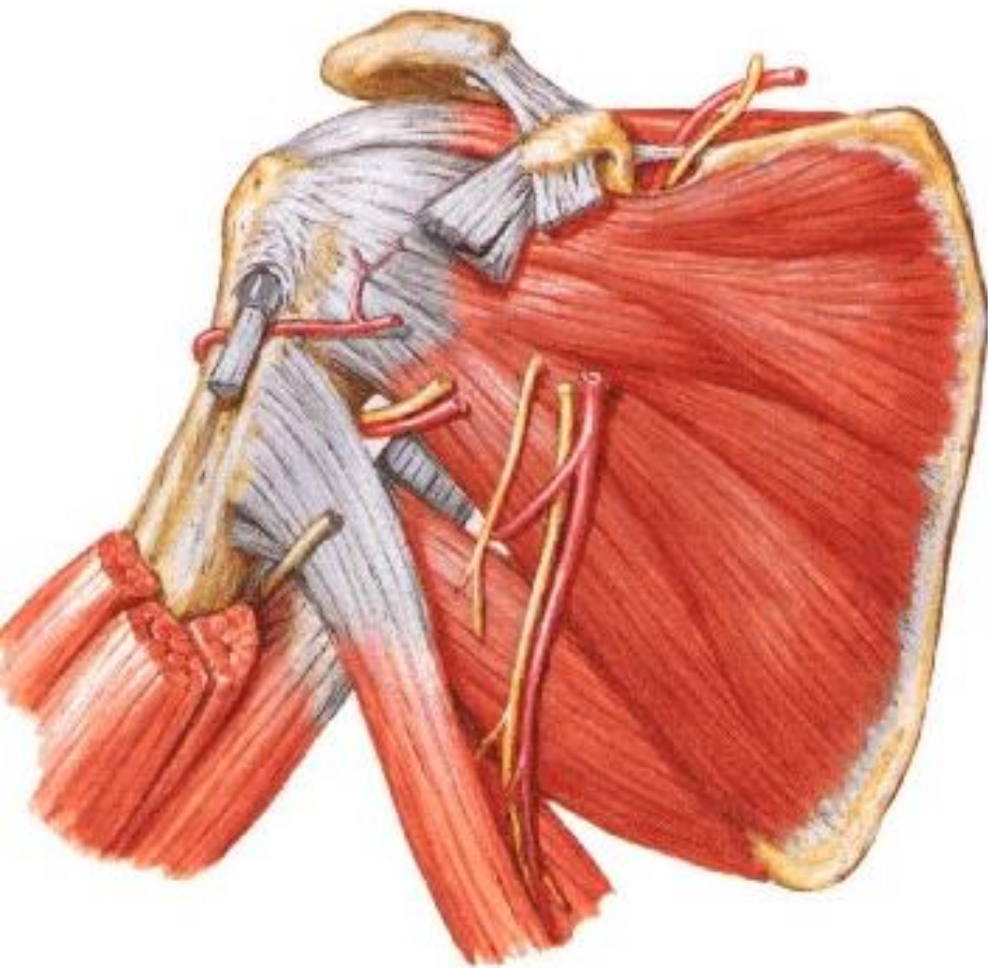
- r. superficialis
- nn. digitales dorsales

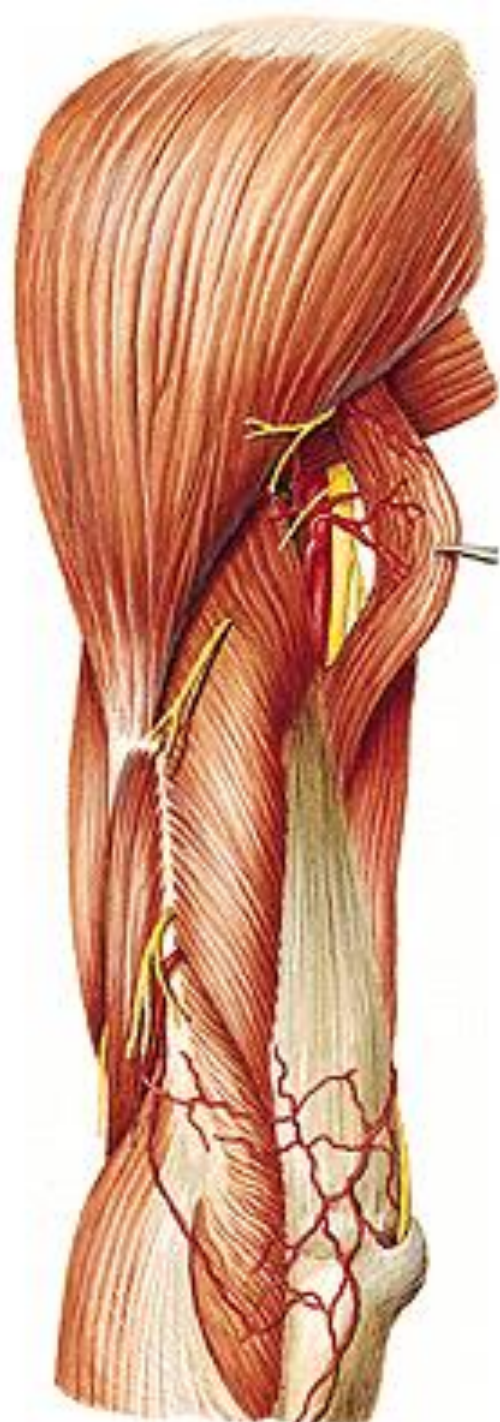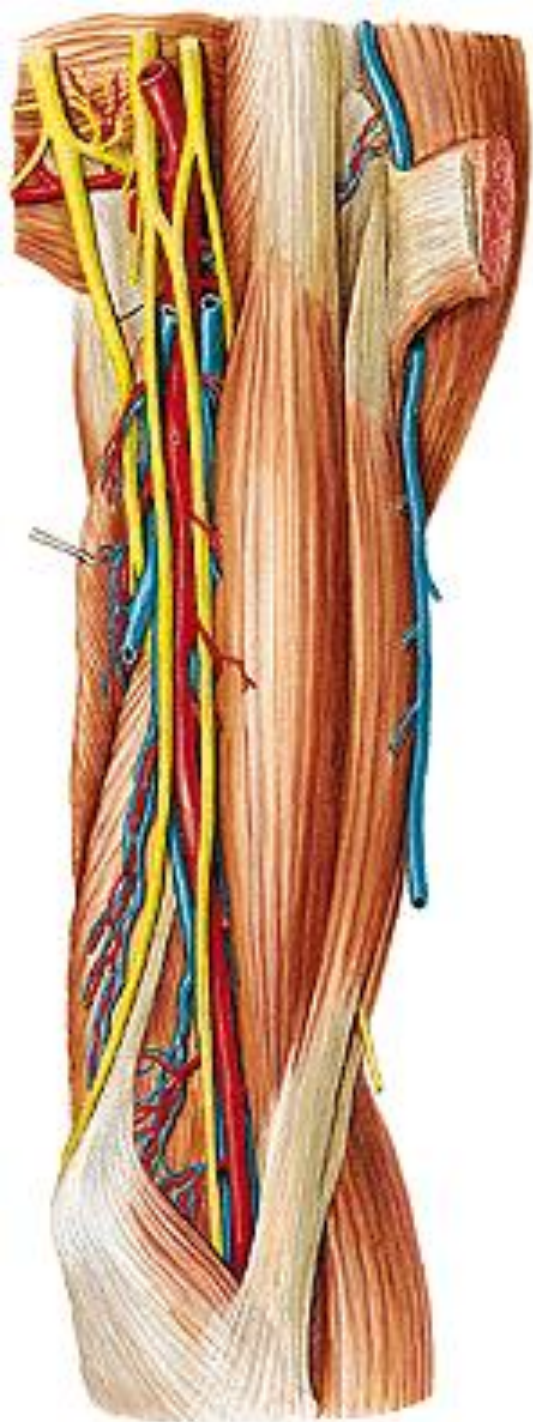


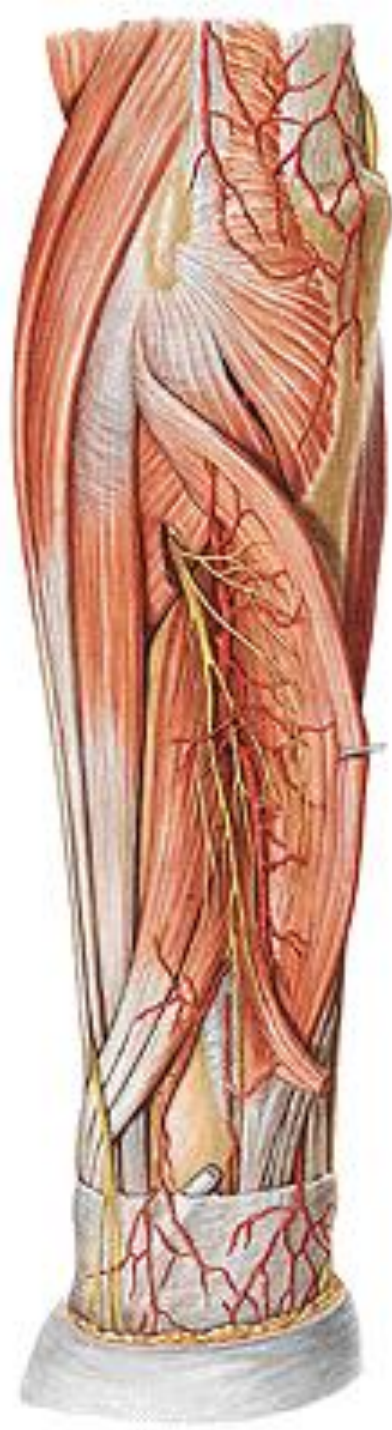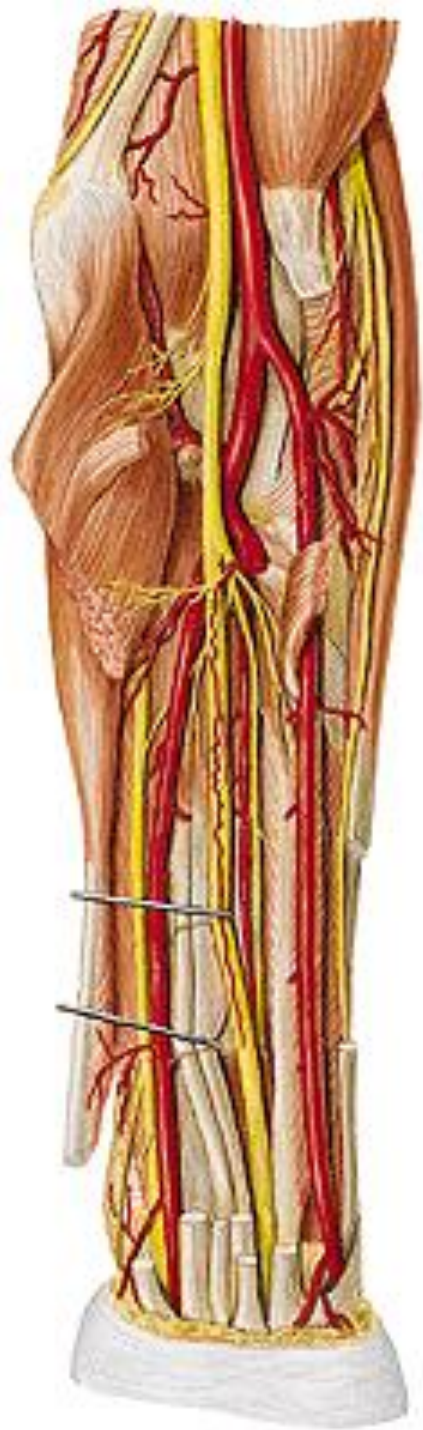# **N. RADIALIS**

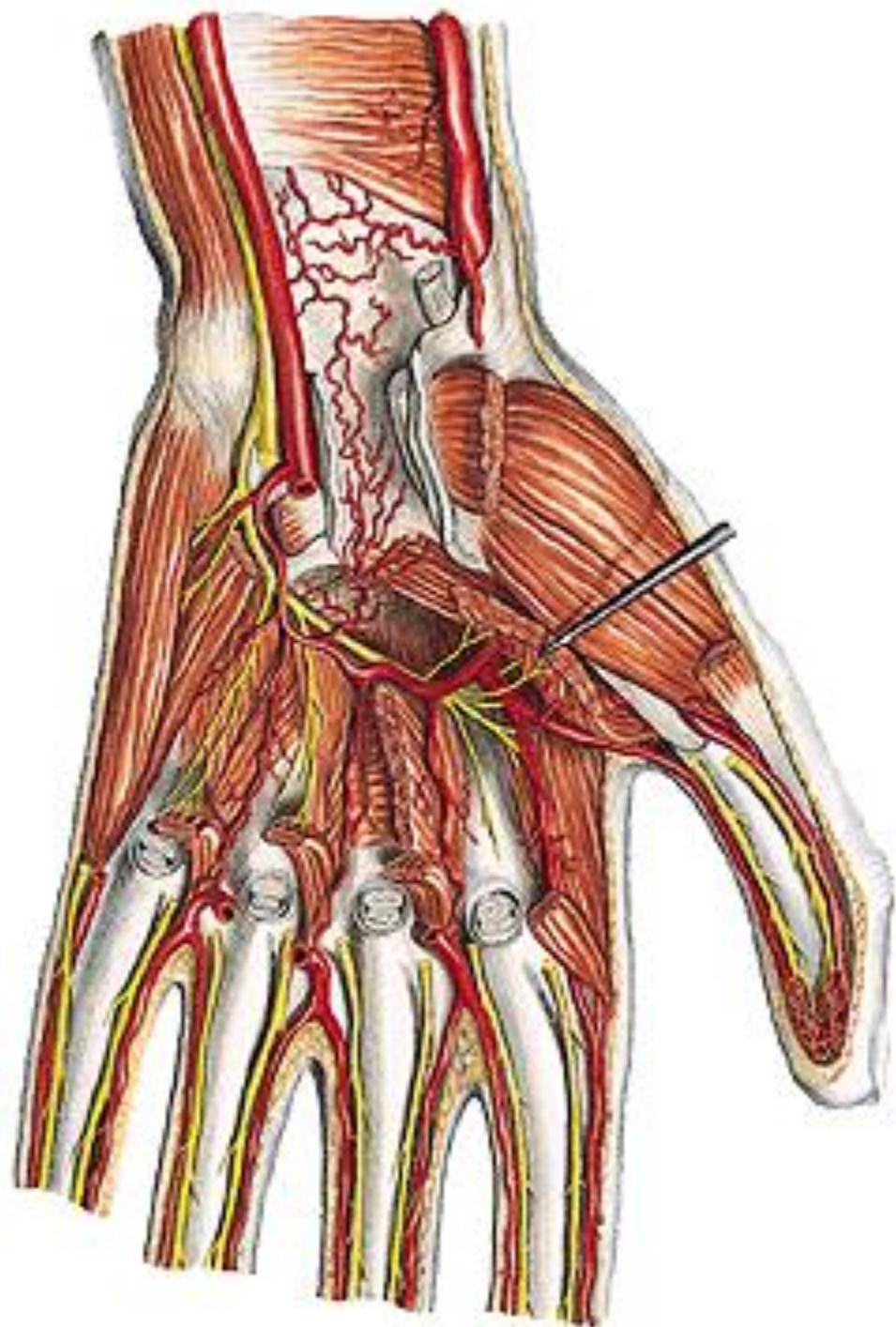
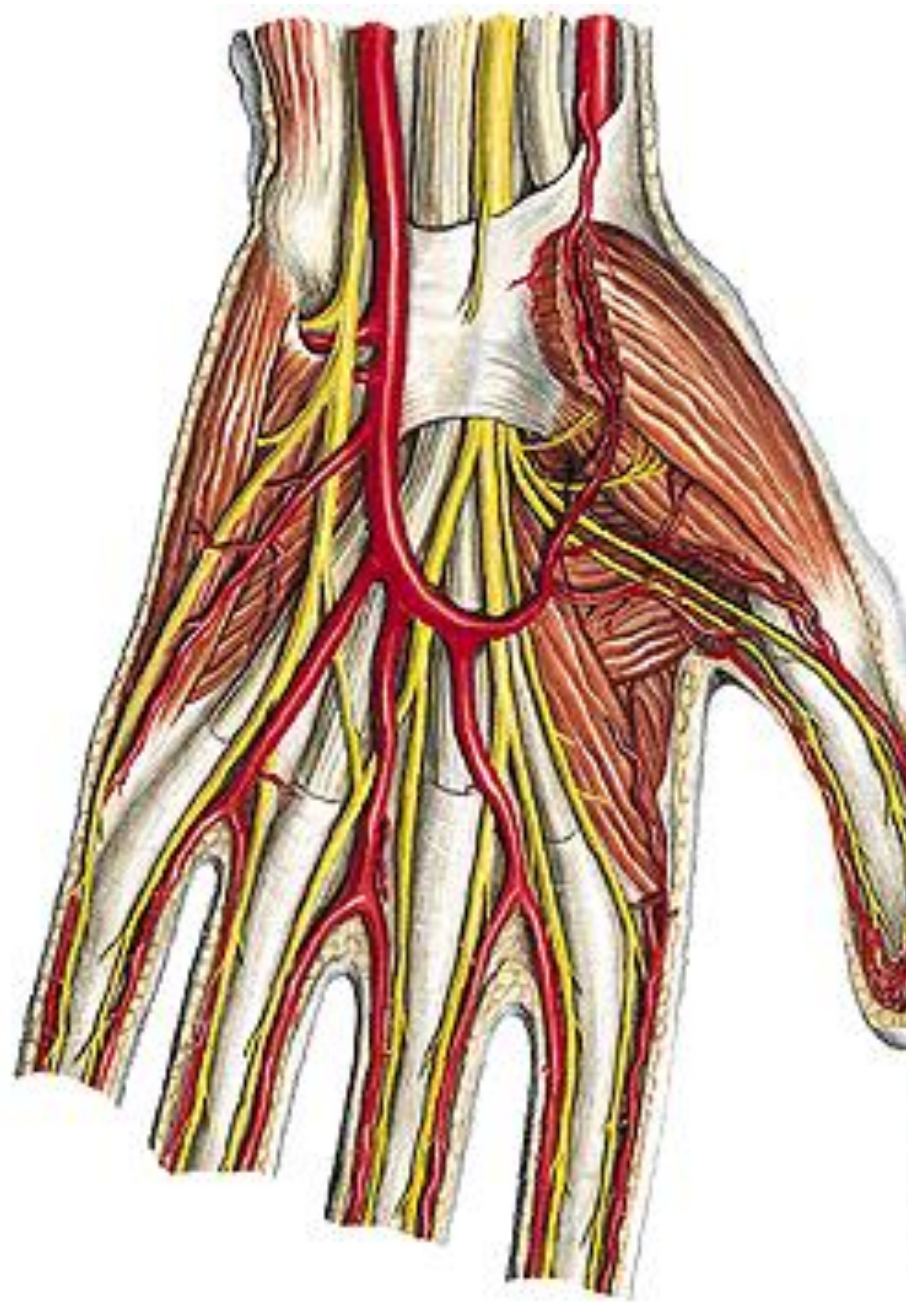
- r. profundus
- rr. musculares
- n. interosseus antebrachii post.
  - m. extensor carpi radialis brevis
  - m. supinator
  - m. extensor digitorum
  - m. extensor digiti minimi
  - m. extensor carpi ulnaris
  - m. extensor indicis
  - m. abductor pollicis longus
  - m. extensor pollicis brevis
  - m. extensor pollicis longus

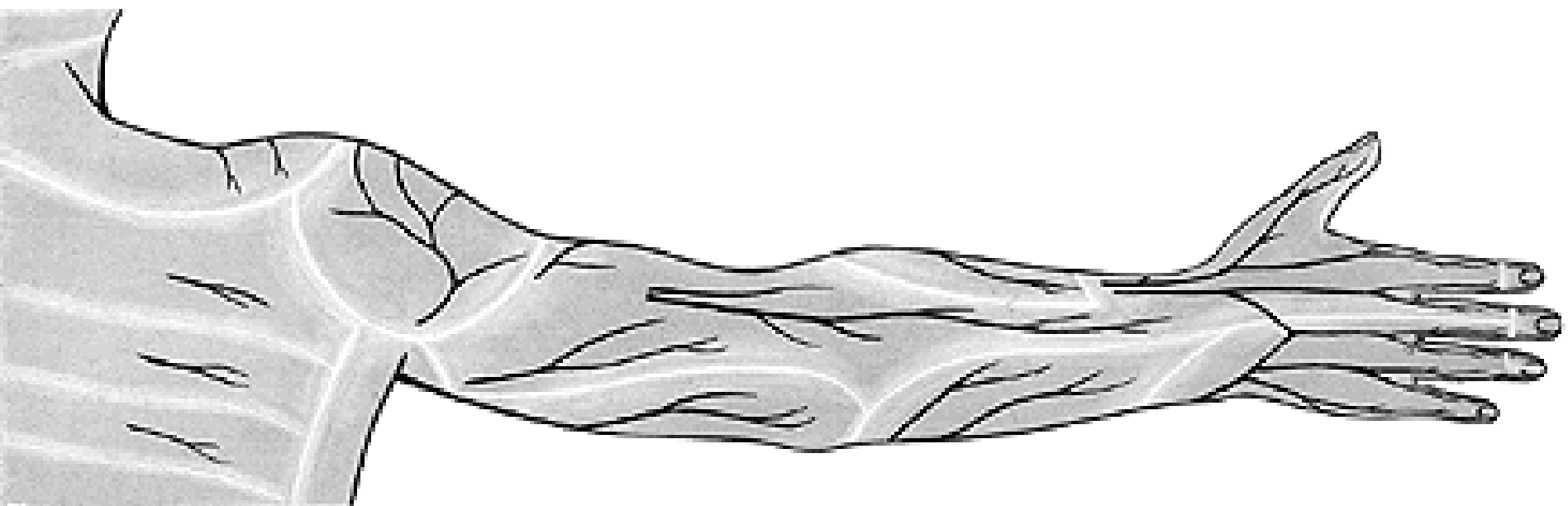
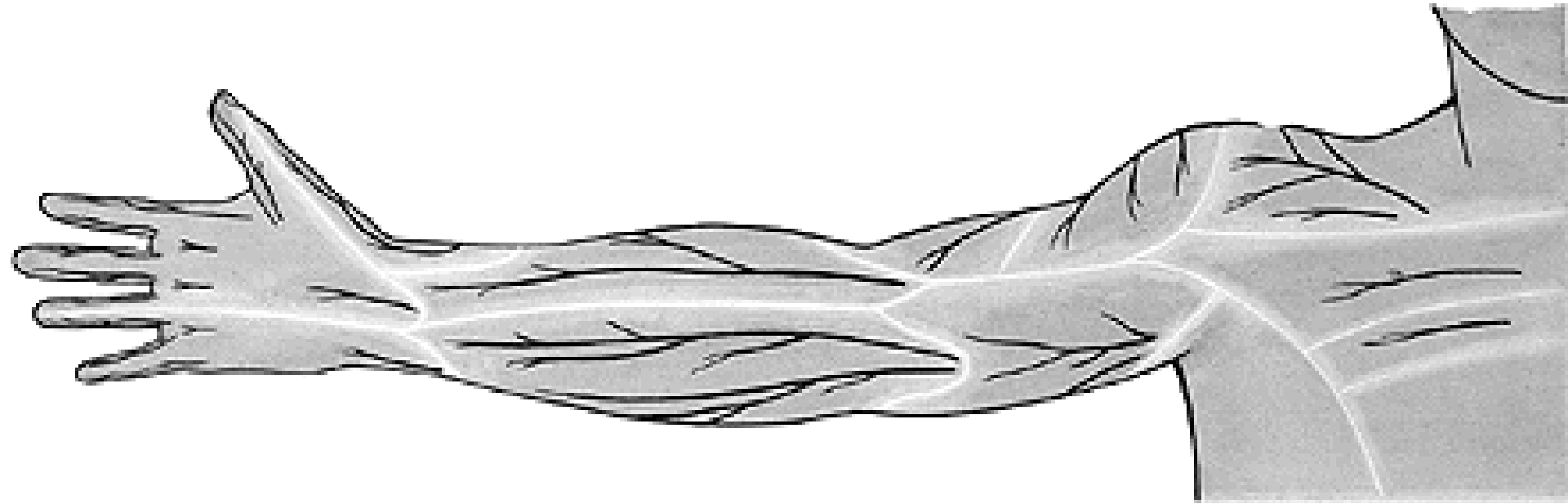


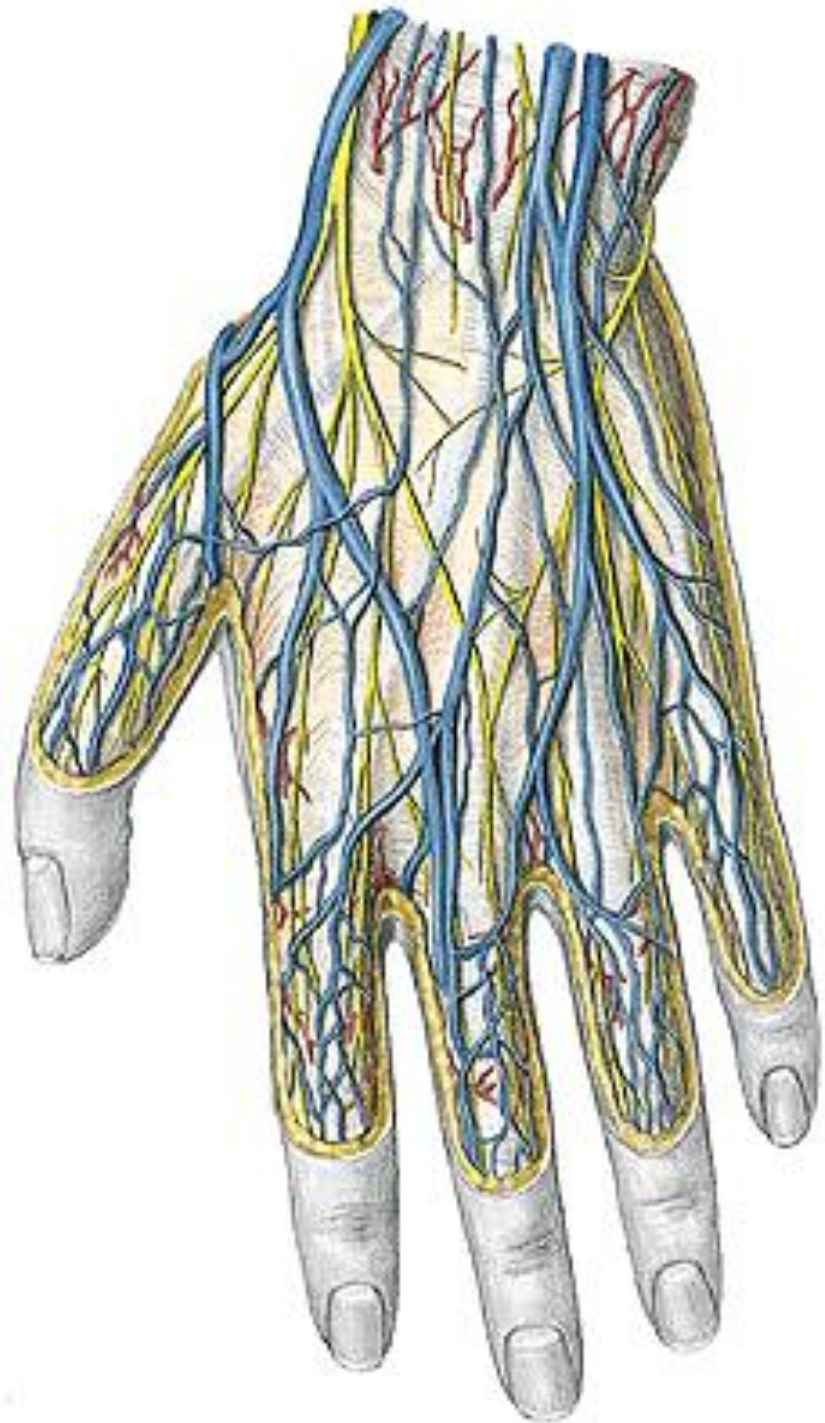
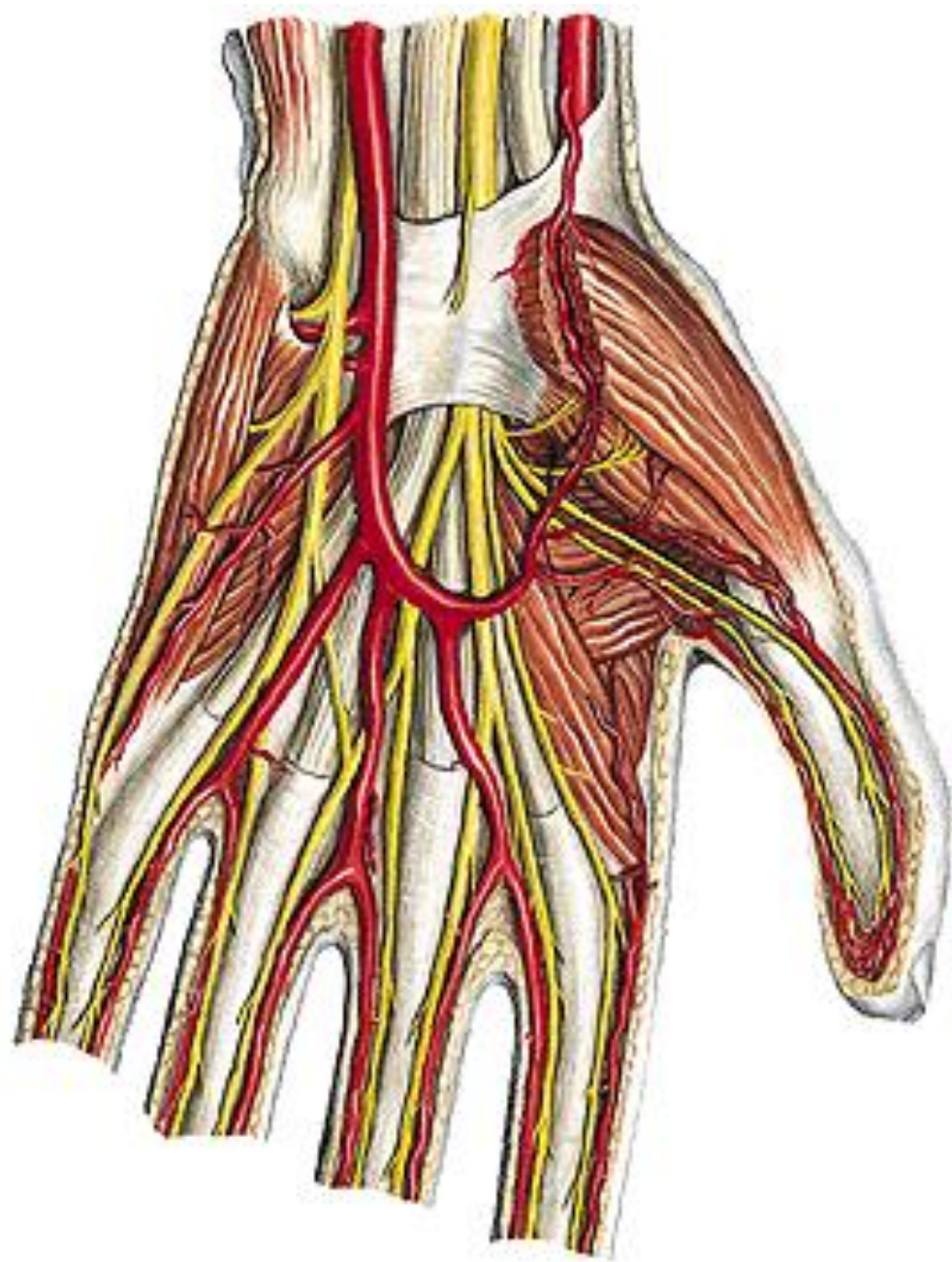














# CROSS SECTION THROUGH THE ARM

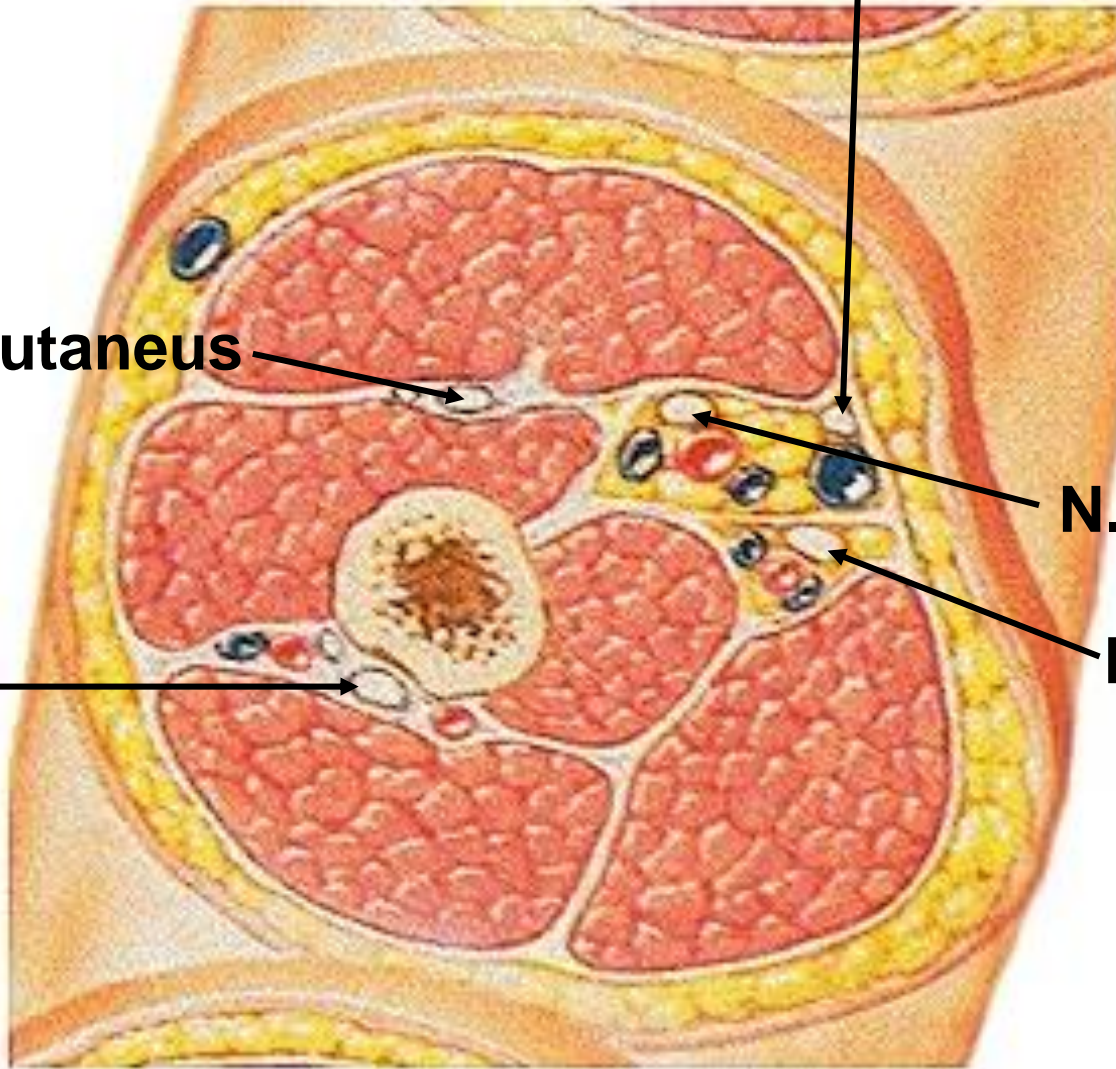
**N. cutaneus antebrachii med.**

**N. musculocutaneus**

**N. medianus**

**N. ulnaris**

**N. radialis**

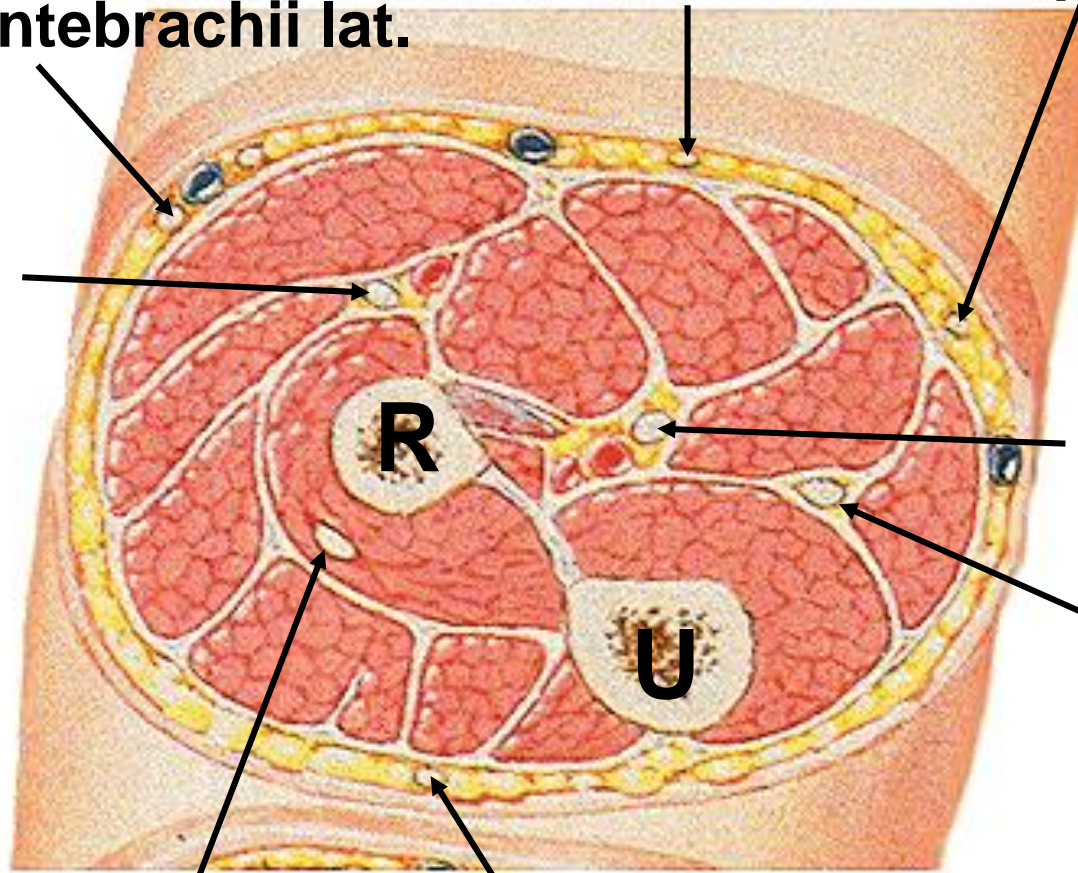


# FOREARM – PROXIMAL CROSS SECTION

N. cutaneus antebrachii med.  
- r. ant.      - r. post.

N. cutaneus antebrachii lat.

N. radialis  
- r. spf.



N. medianus

N. ulnaris

N. cutaneus antebrachii post.

N. radialis – r. prof.

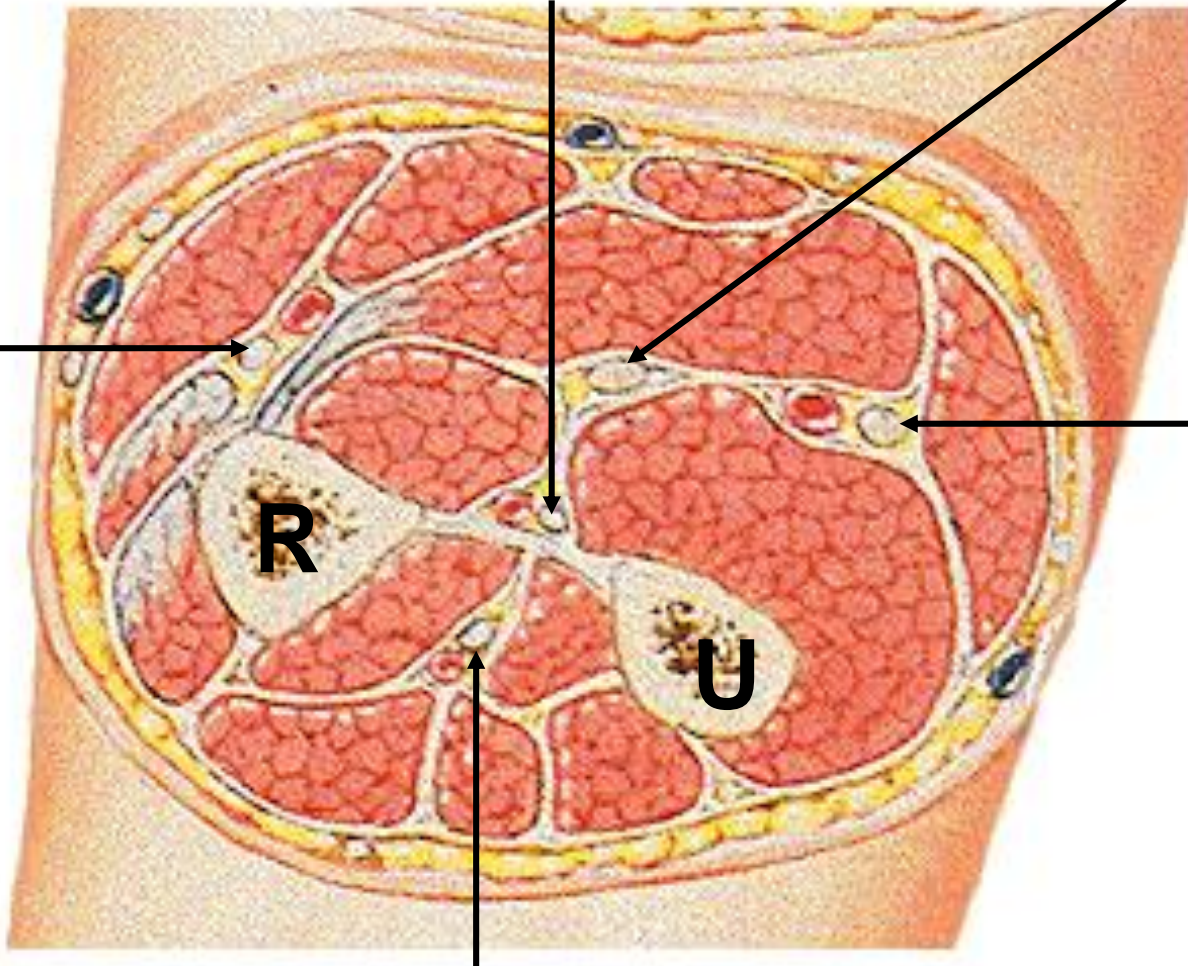
# FOREARM – MIDDLE CROSS SECTION

**N. interosseus anterior**

**N. medianus**

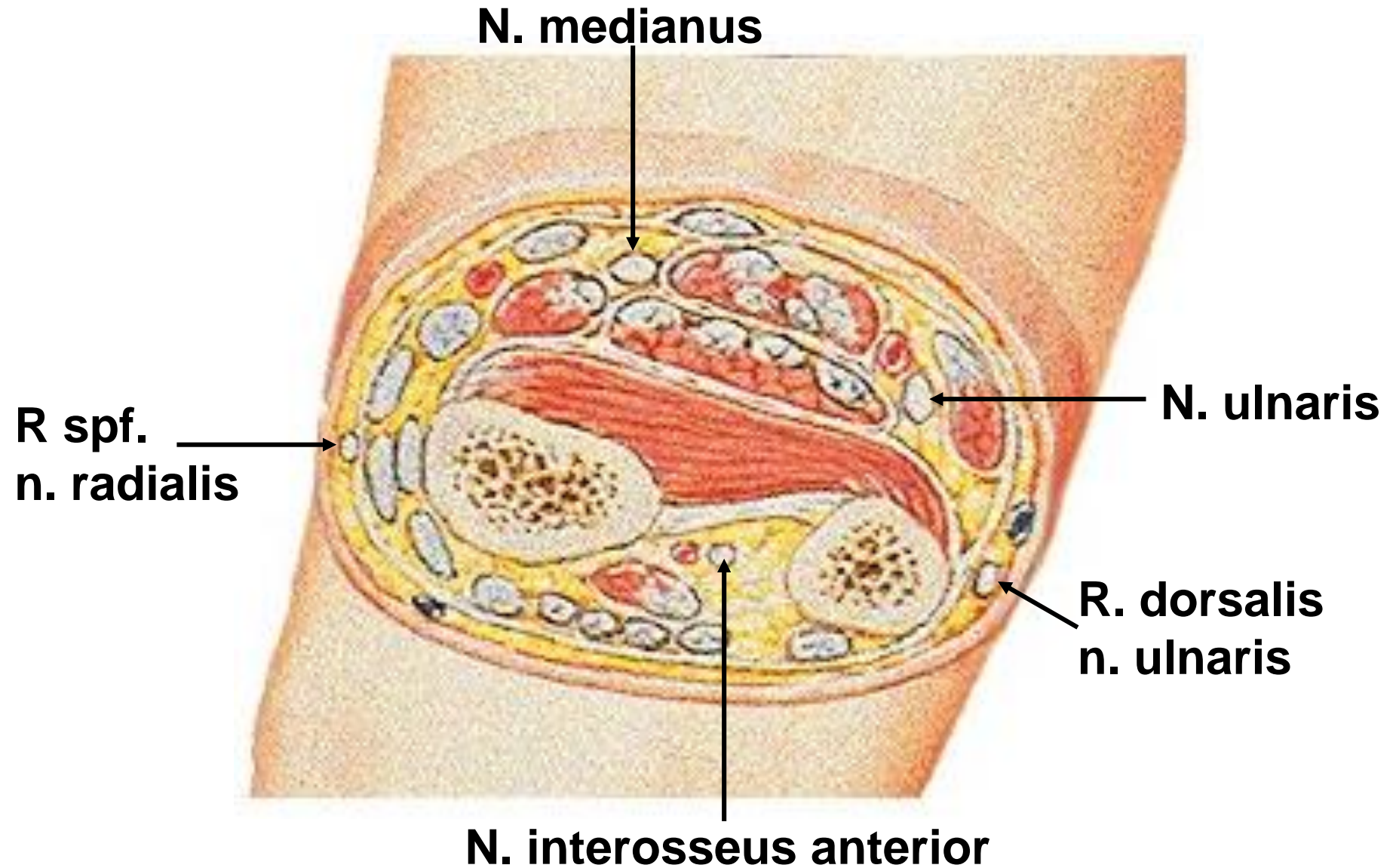
**R. spf.  
n. radialis**

**N. ulnaris**



**N. interosseus posterior**

# FOREARM – DISTAL CROSS SECTION



Illustrations and photographs were copied from:  
**Atlas der Anatomie des Menschen/Sobotta.**  
**Putz,R., und Pabst,R. 20. Auflage. München:**  
**Urban & Schwarzenberg, 1993**  
**Netter: Interactive Atlas of Human Anatomy.**  
**Windows Version 2.0**