

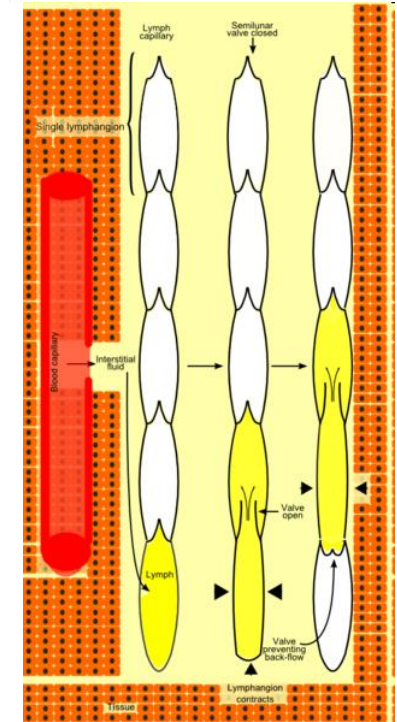
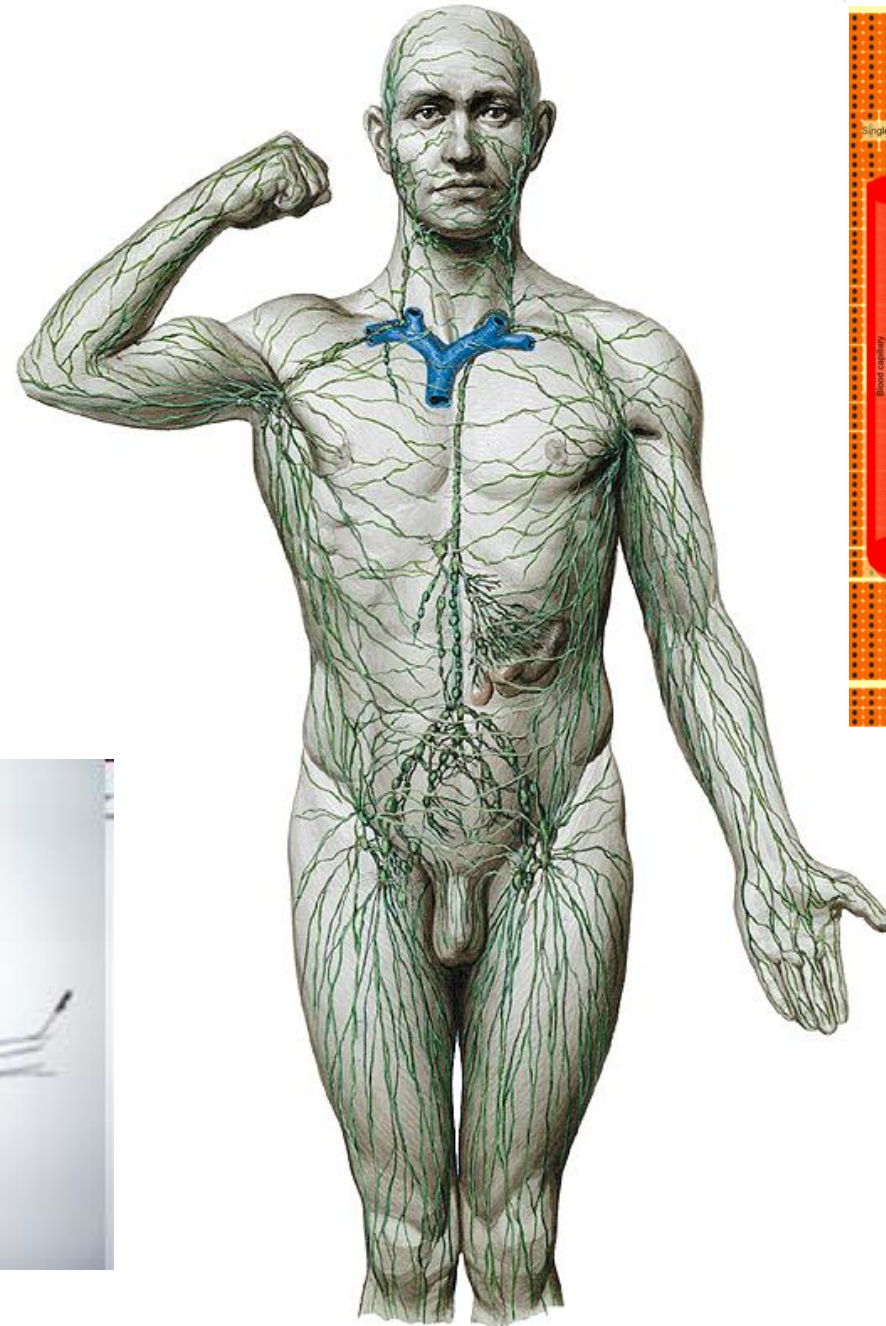# **Lymphatic system**

- lymph 1,5-2l/day
- lymphatic vessels (vasa lymphatica)

capillaries (vasa lymphocapillaria)  
 lymphatic net (rete lymphocapillare)  
 collector vessels (collectores lymphatici)  
 trunks (trunci lymphatici)

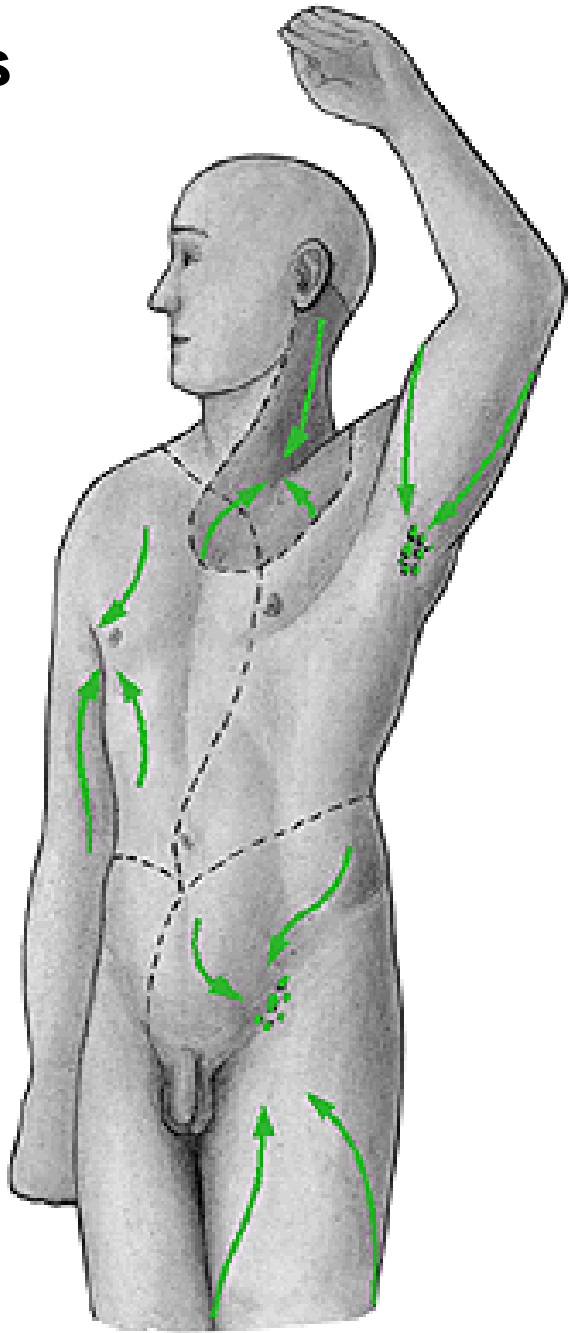
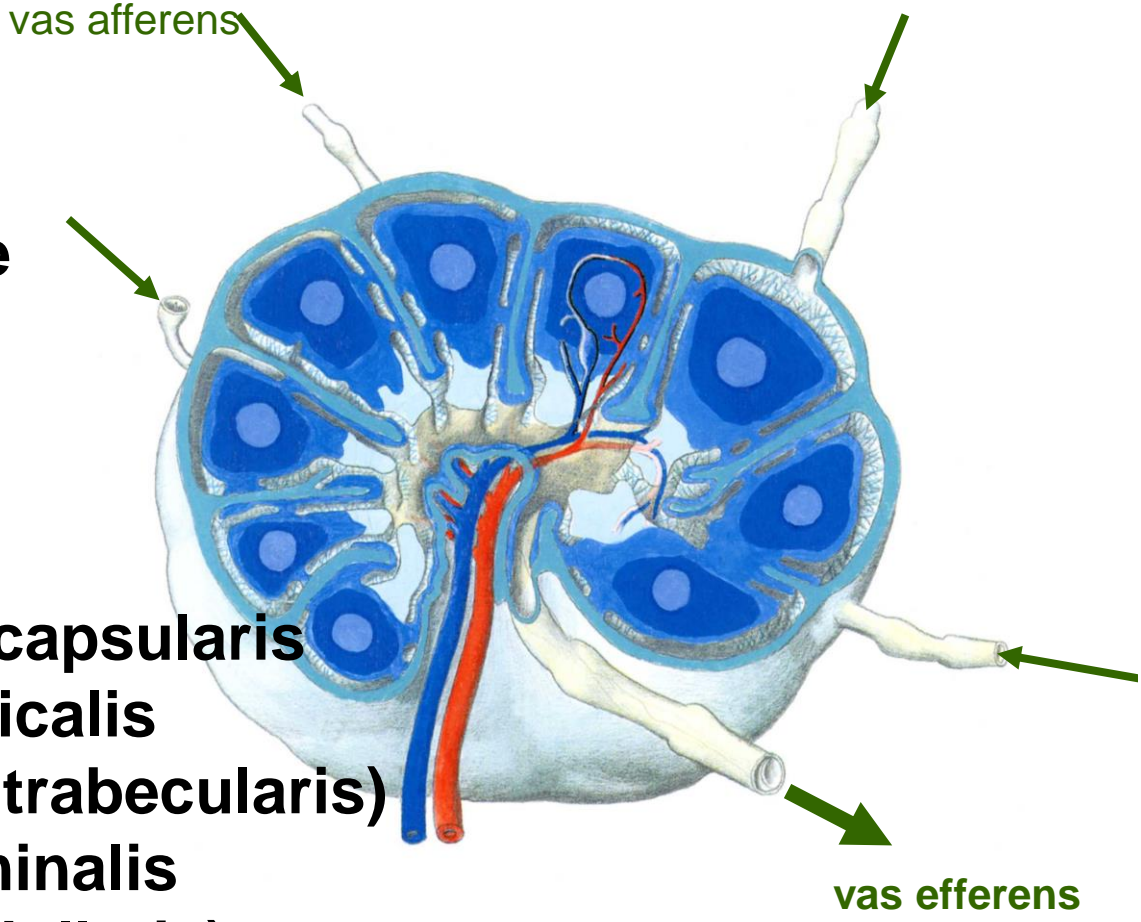
- lymphatic nodes (nodi lymphatici)
- lymphatic organs

tonsillae  
 lien  
 thymus



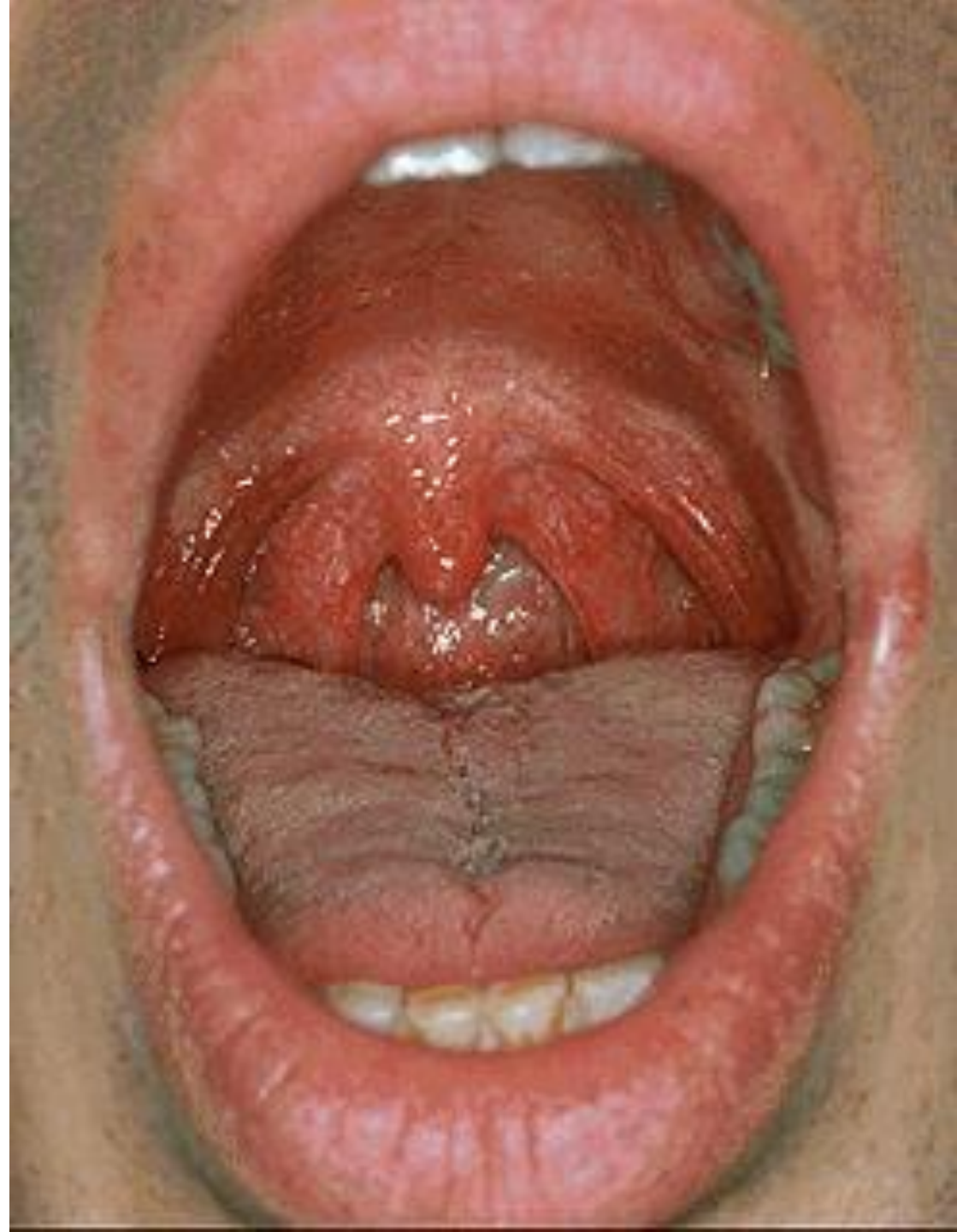# Nodus lymphaticus

- capsula
- trabeculae
- reticulum
- cortex
- medulla
- hilum
- sinus subcapsularis
- sinus corticalis (peritrabecularis)
- sinus terminalis (medullaris)

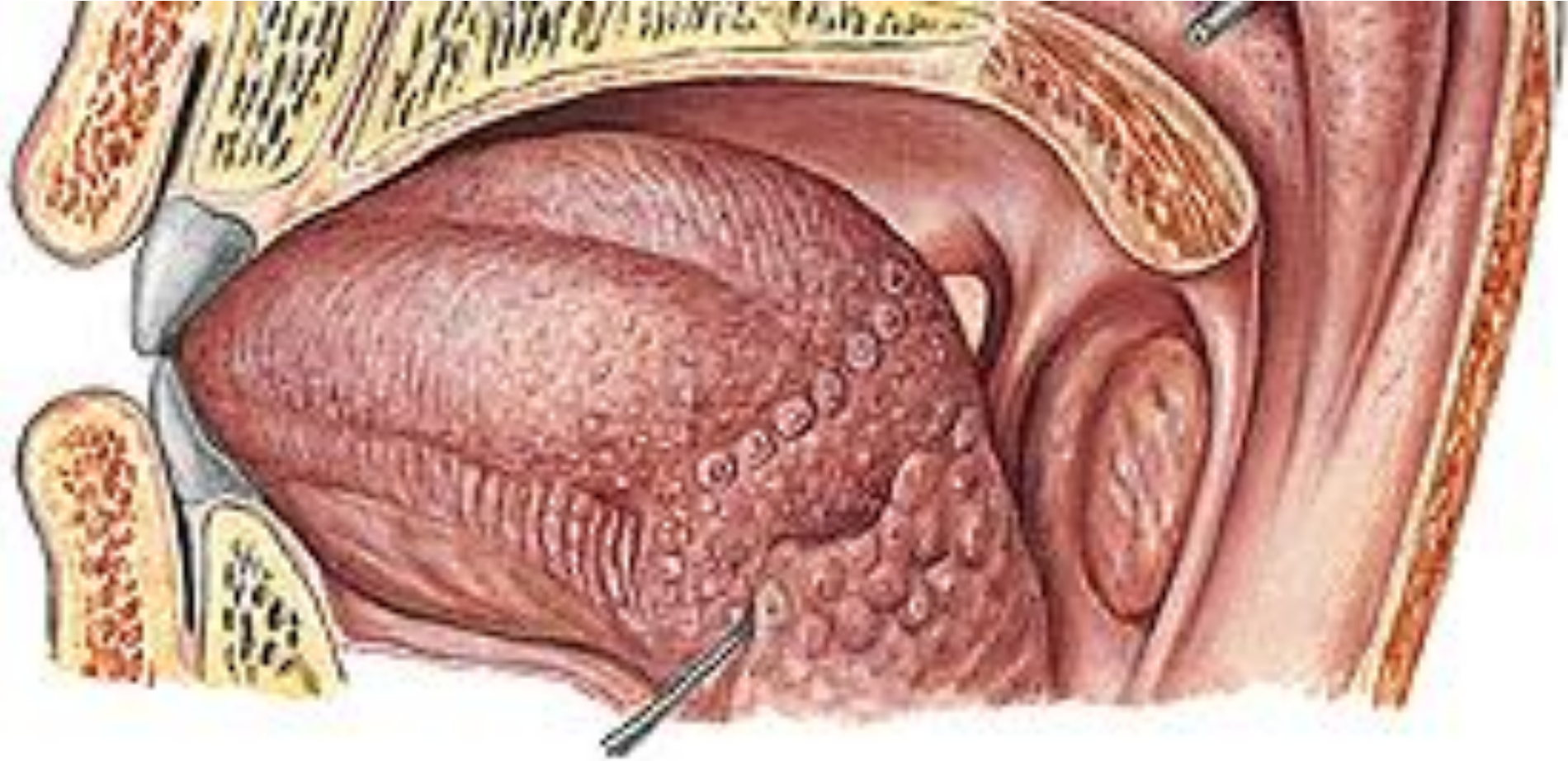

Tributary region  
Regional lymph nodes

**Tonsilla palatina**

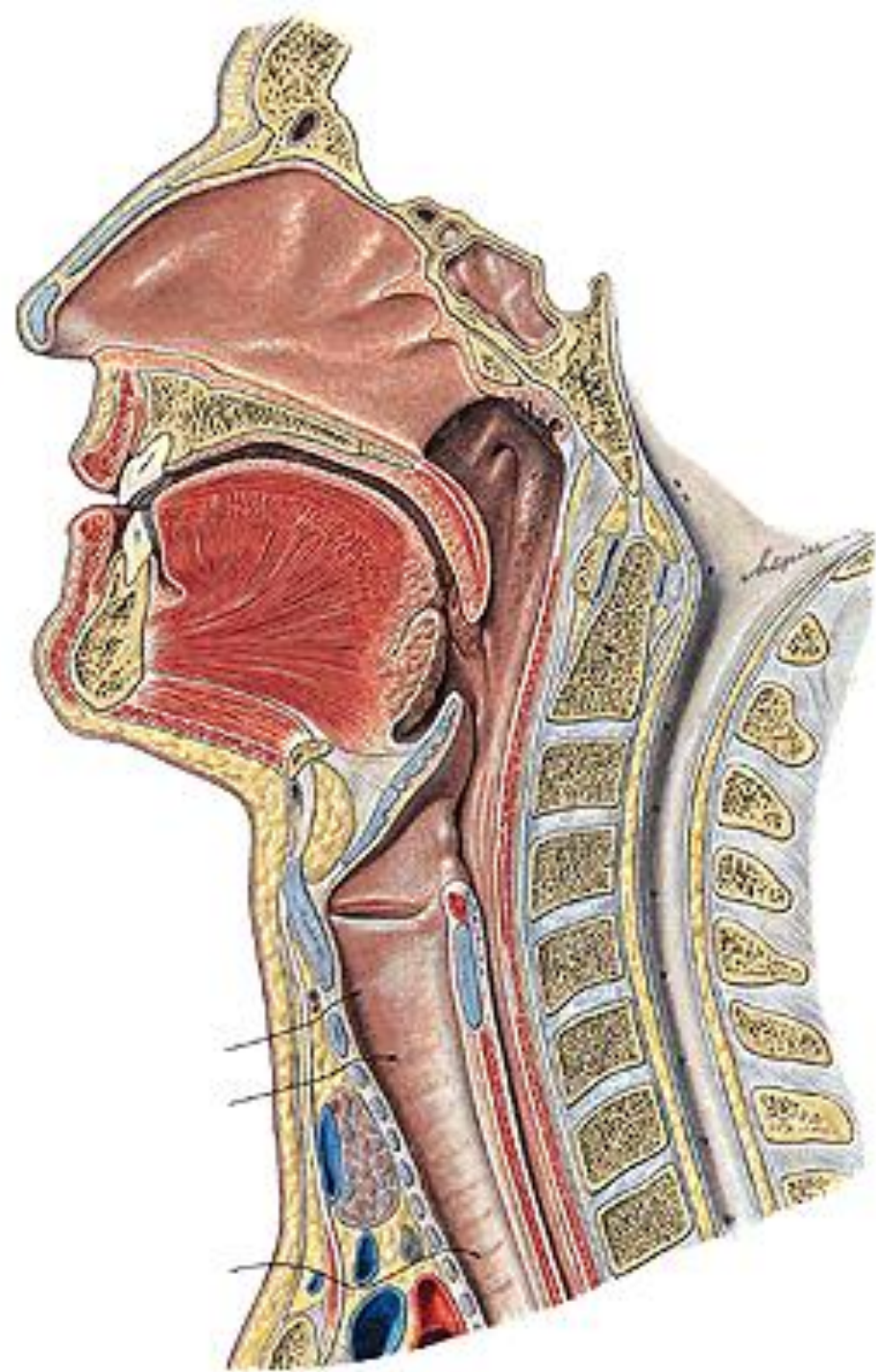


# Tonsilla lingualis

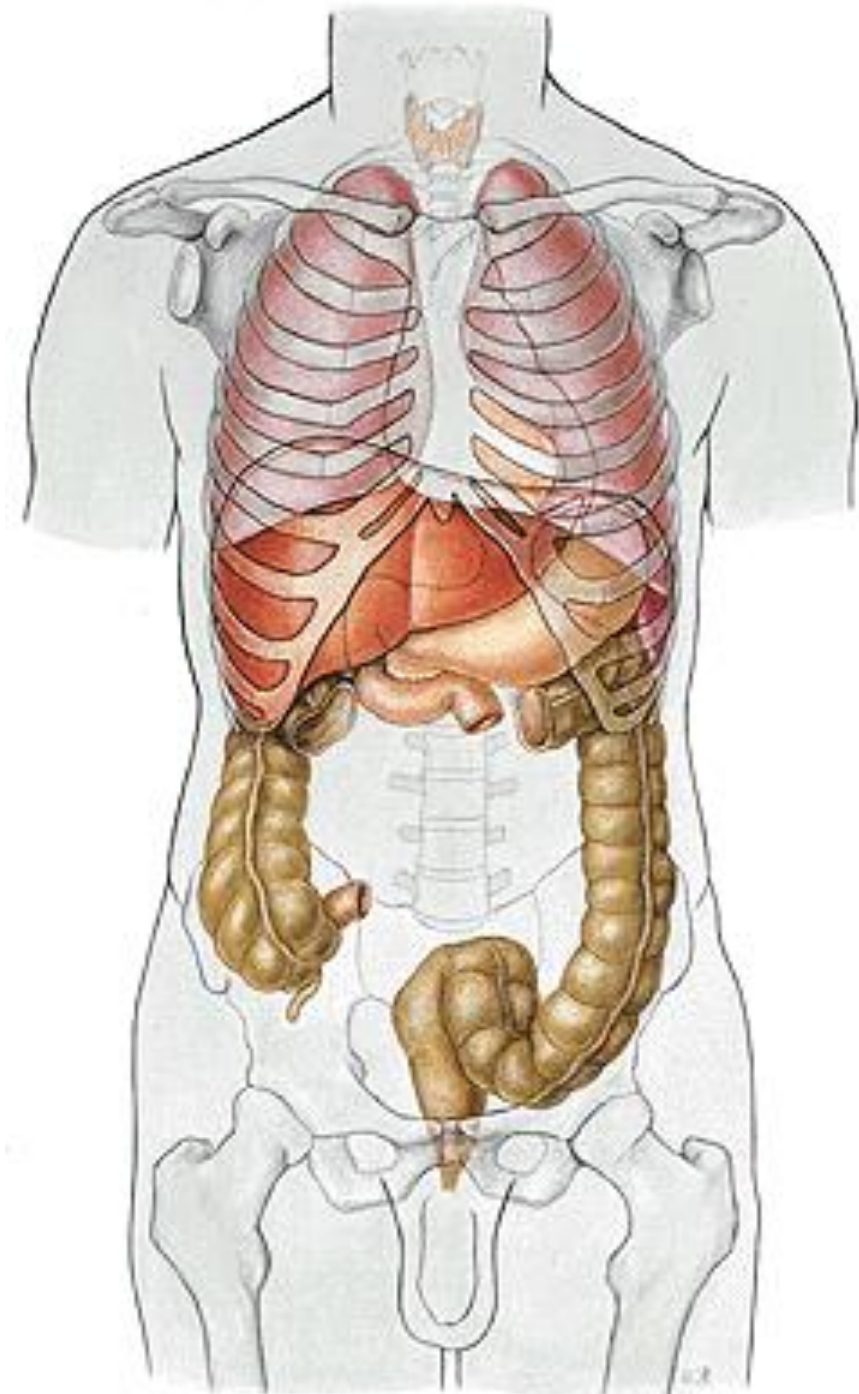


**Tonsilla pharyngea**  
**Tonsilla tubaria**

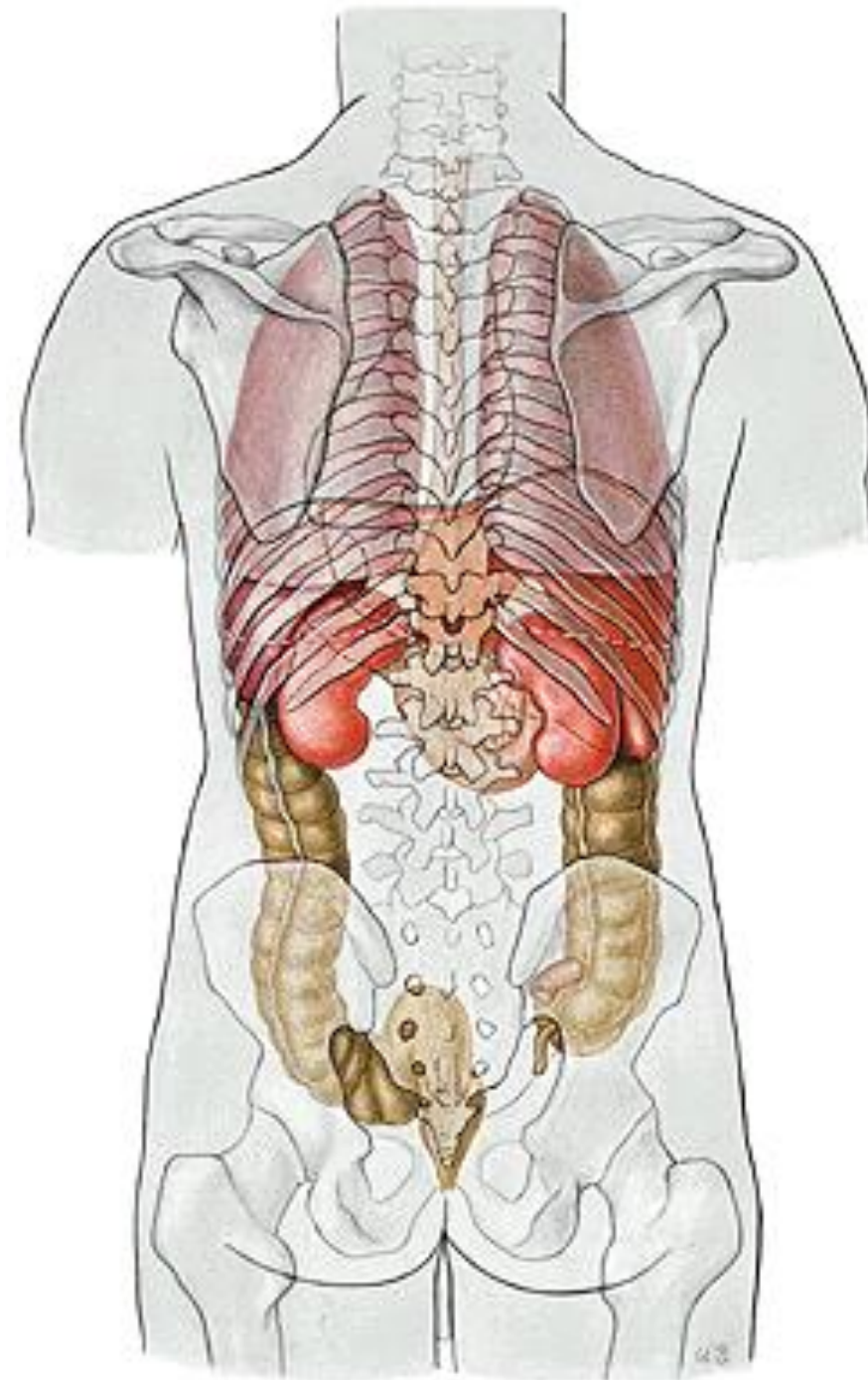
**Waldeyer's tonsillar ring**



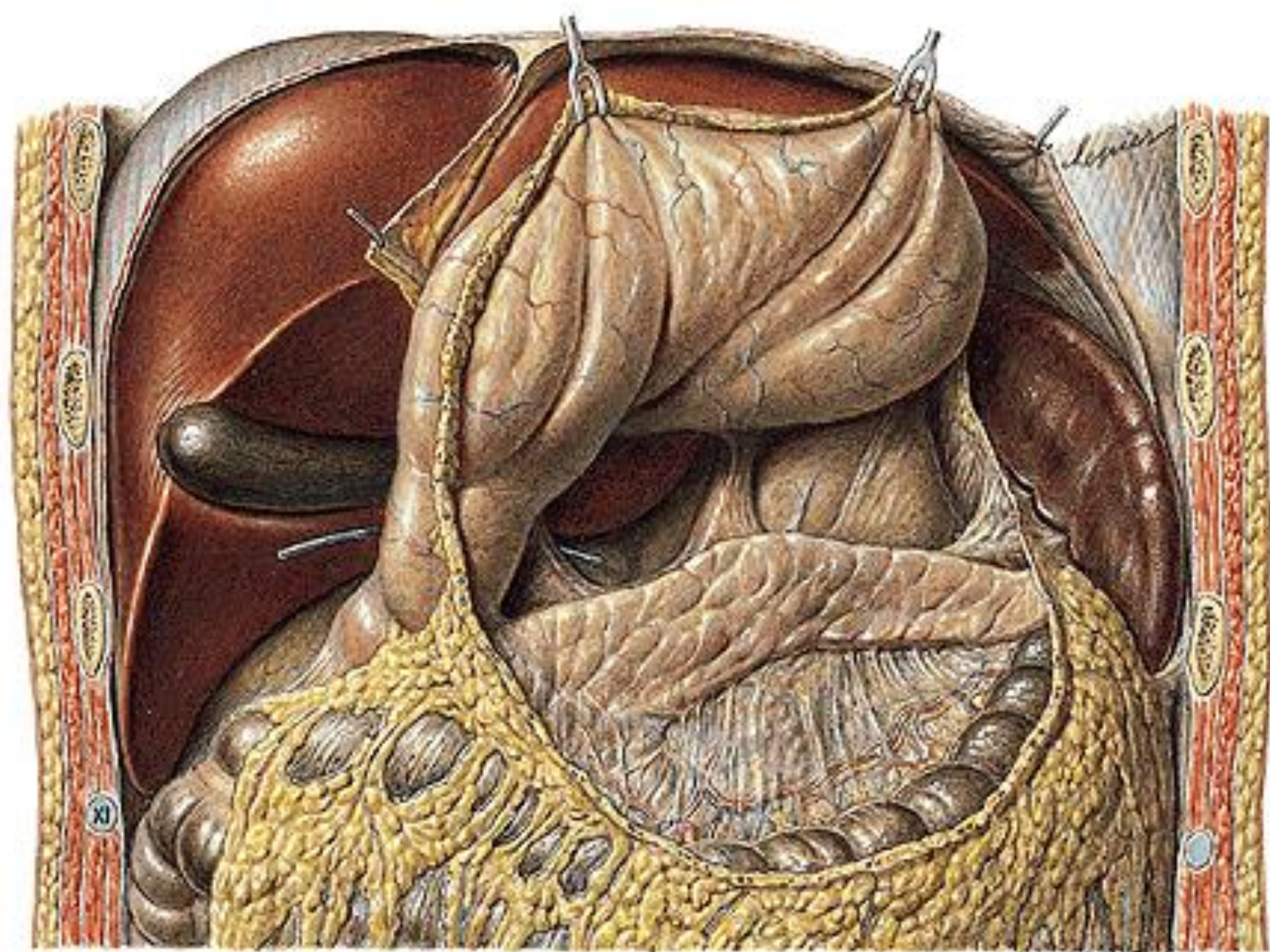
**Tonsilla abdominalis –  
appendix vermiformis**

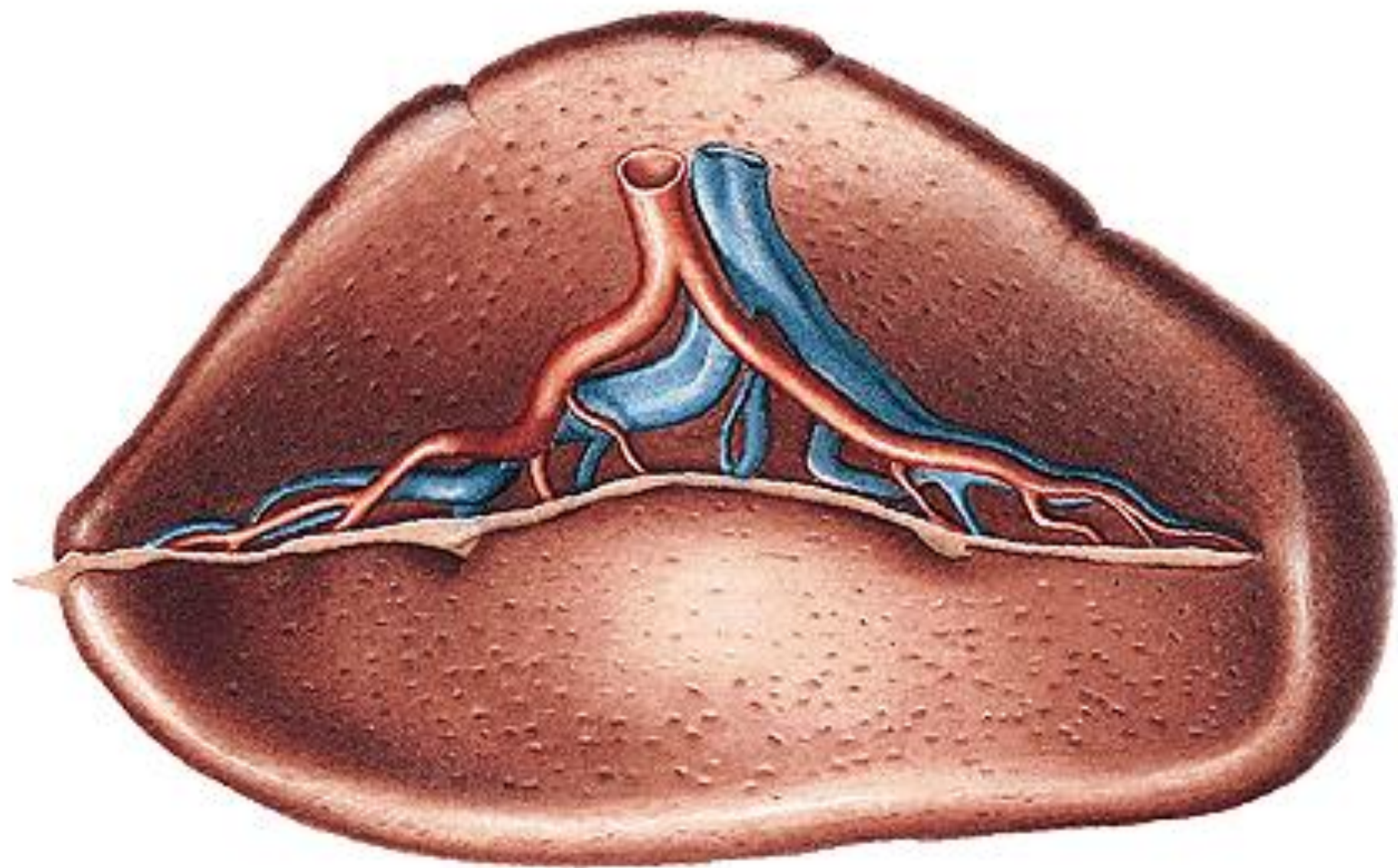


# Lien, splen



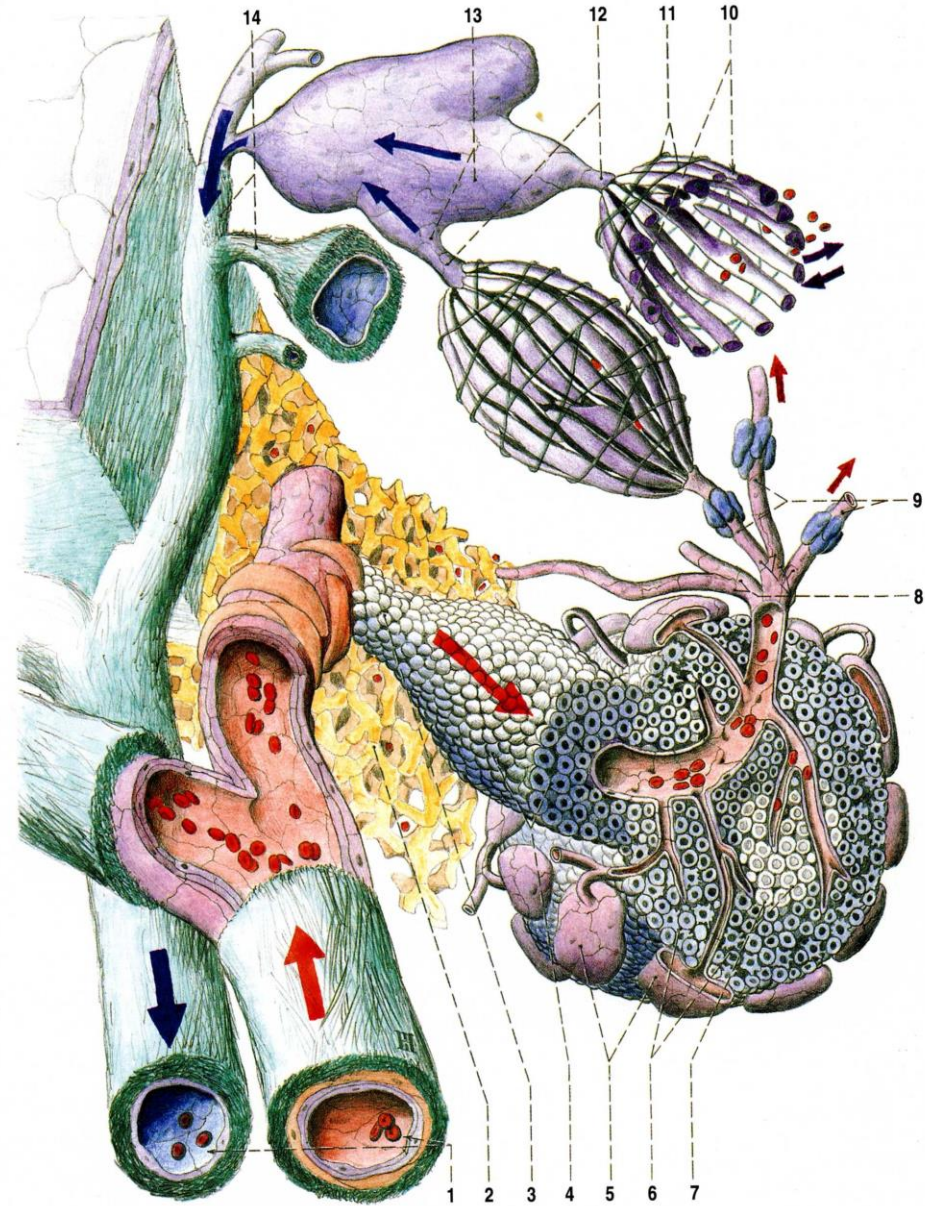








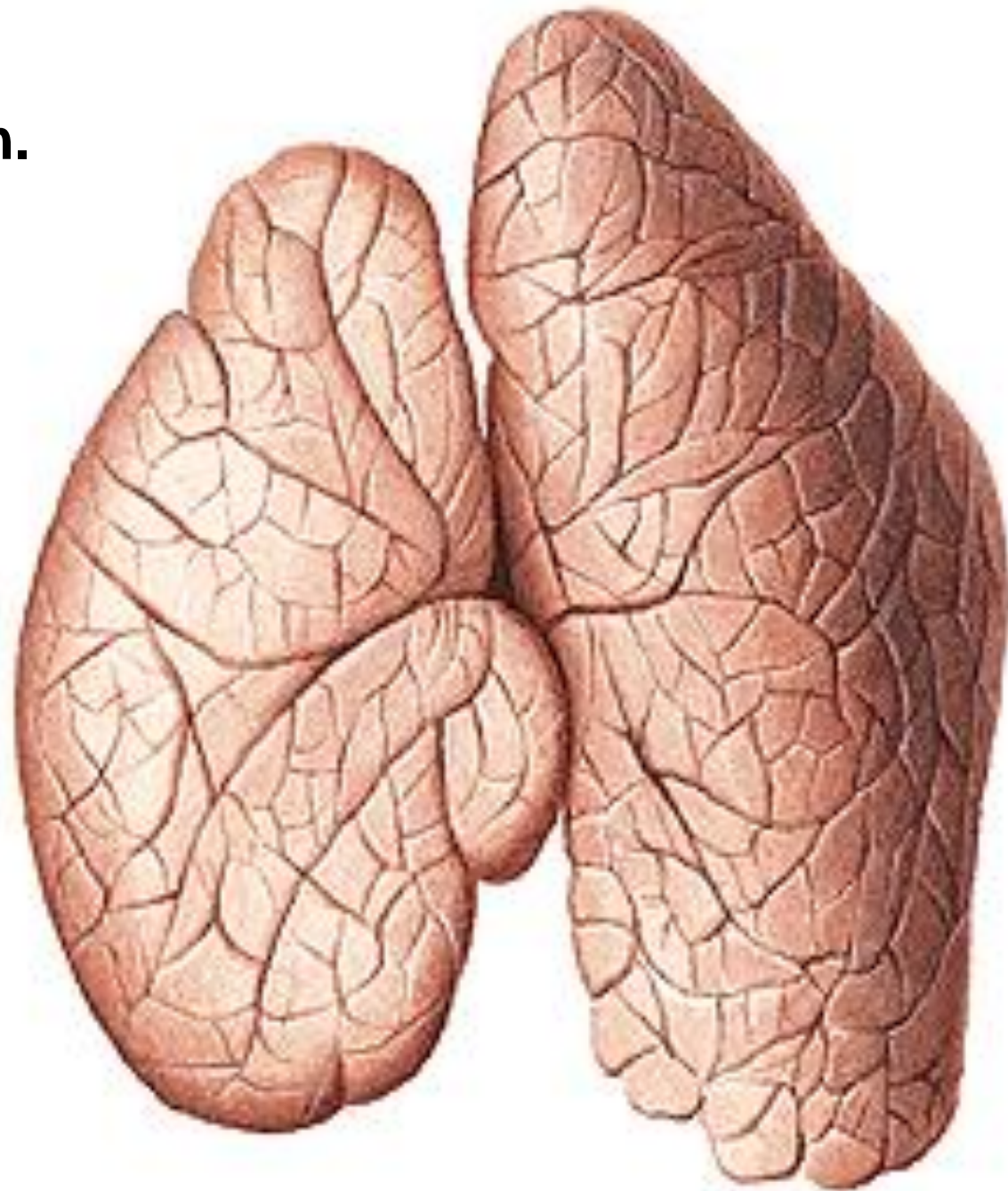
# Reticulum Pulpa rubra Pulpa alba

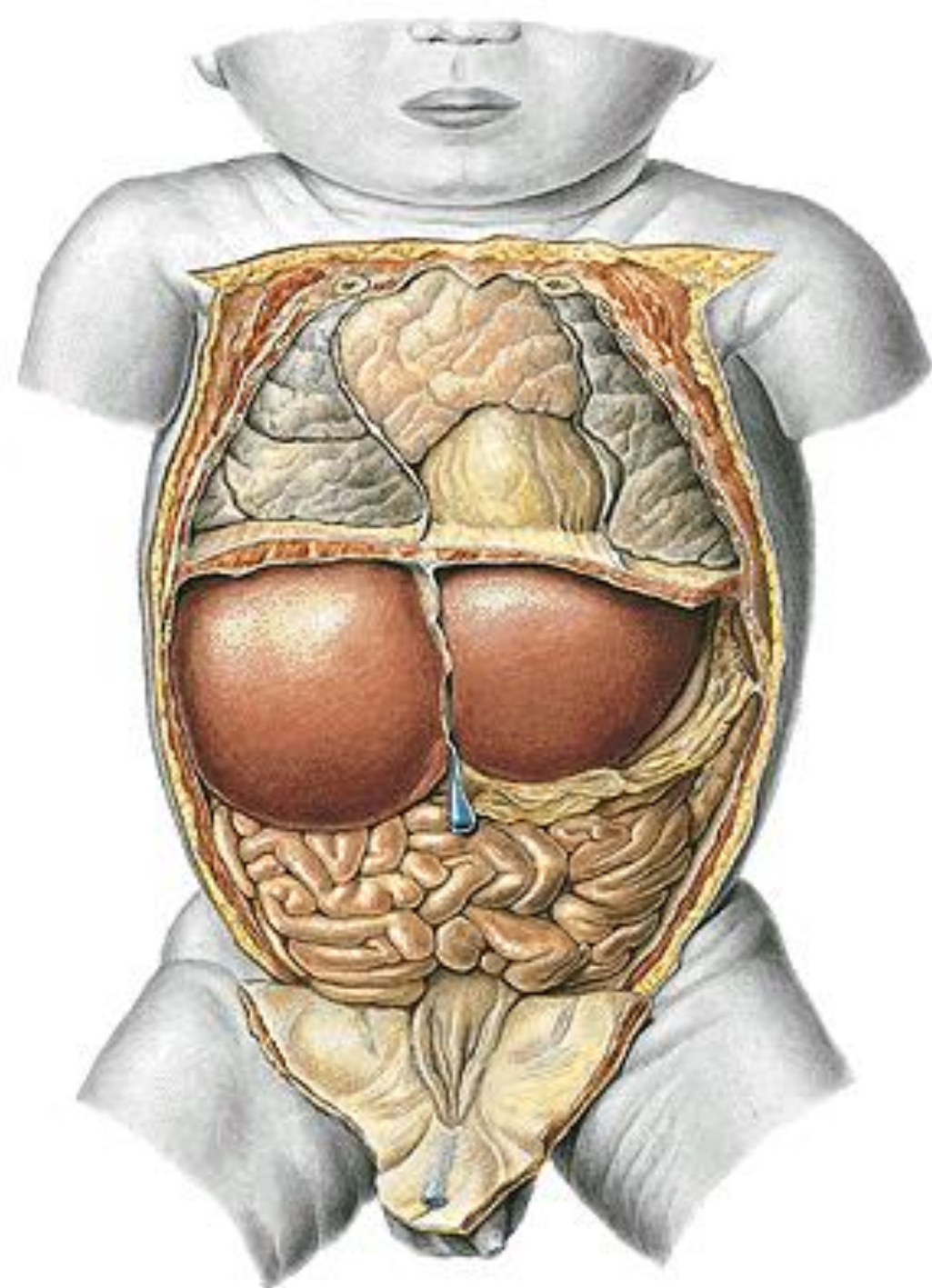


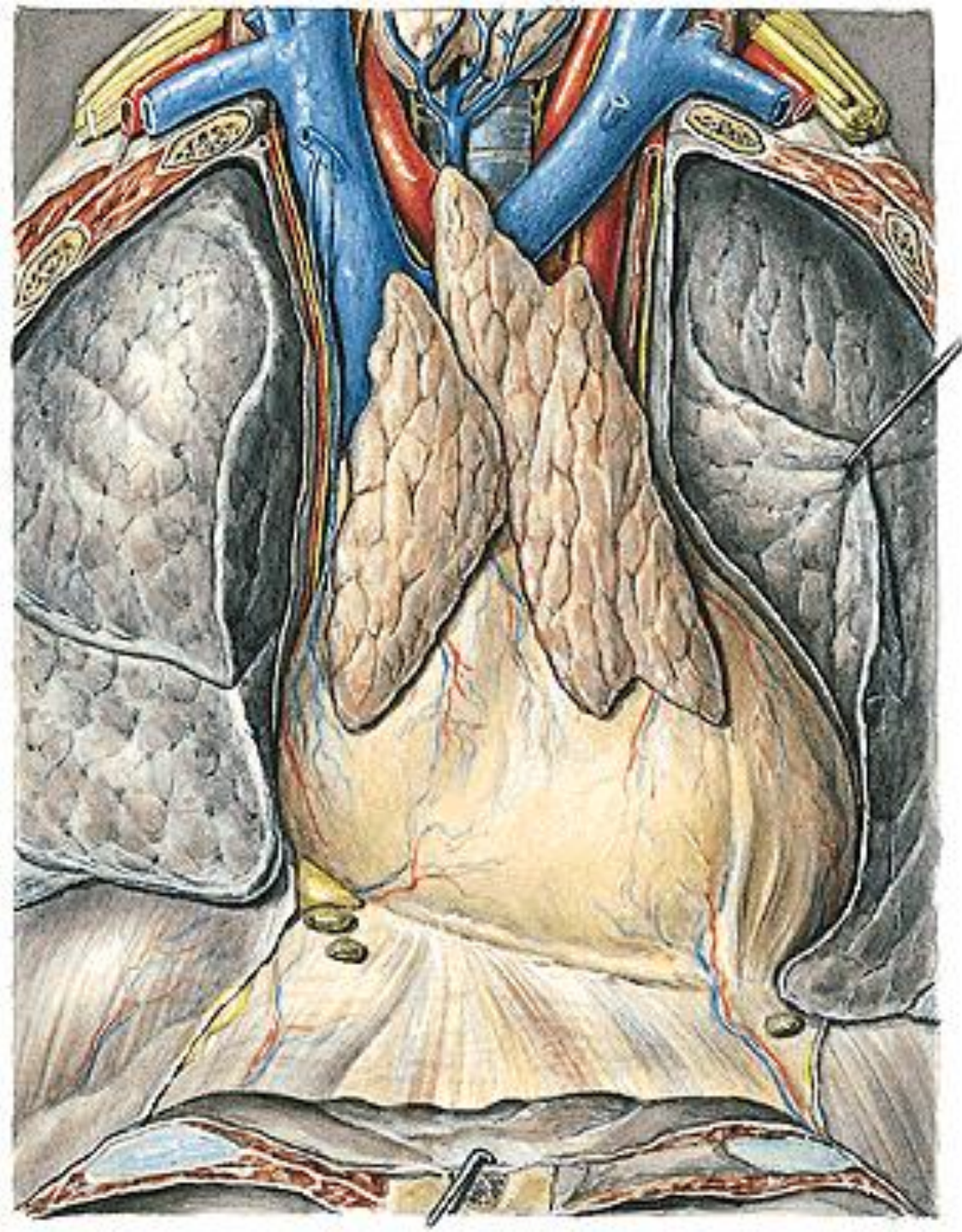
Obr. 123. STAVBA SLEZINY A PRÚTOK KRVE SLEZINOU (schéma); šipky udávají směry toku krve  
 1 trabekulární cévy sleziny  
 2 červená pulpa sleziny  
 3 periarteriální lymfatická pochva  
 4 bílá pulpa sleziny – jeden z folliculi lymphatici lienales  
 5 sinusy marginální zóny mizního uzlíku  
 6 marginální zóna uzlíku s dendritickými buňkami

- 7 zárodečné centrum uzlíku  
 8 penicillus (aa. penicillatae)  
 9 opouzdřené arterky se Schweiggerovým-Seidelovým pouzdrem  
 10 slezinové sinusy (sinus lienis)  
 11 retikulární vlákna obtáčeující sinusy  
 12 postkapilární žíly  
 13 tenkostěnné rozšířené dřeňové žíly  
 14 trabekulární žíly

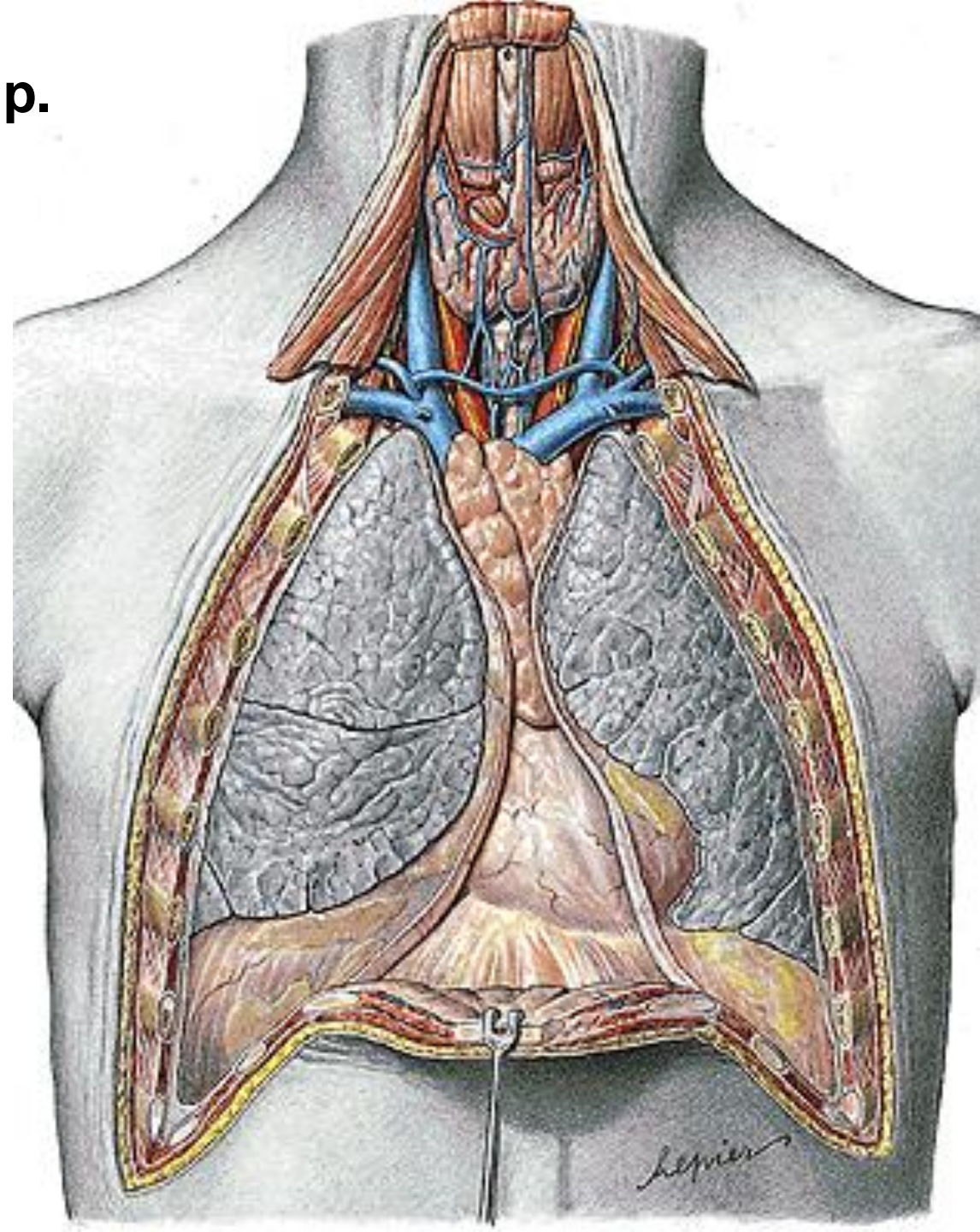
**Thymus**  
**- lobus dx. et sin.**







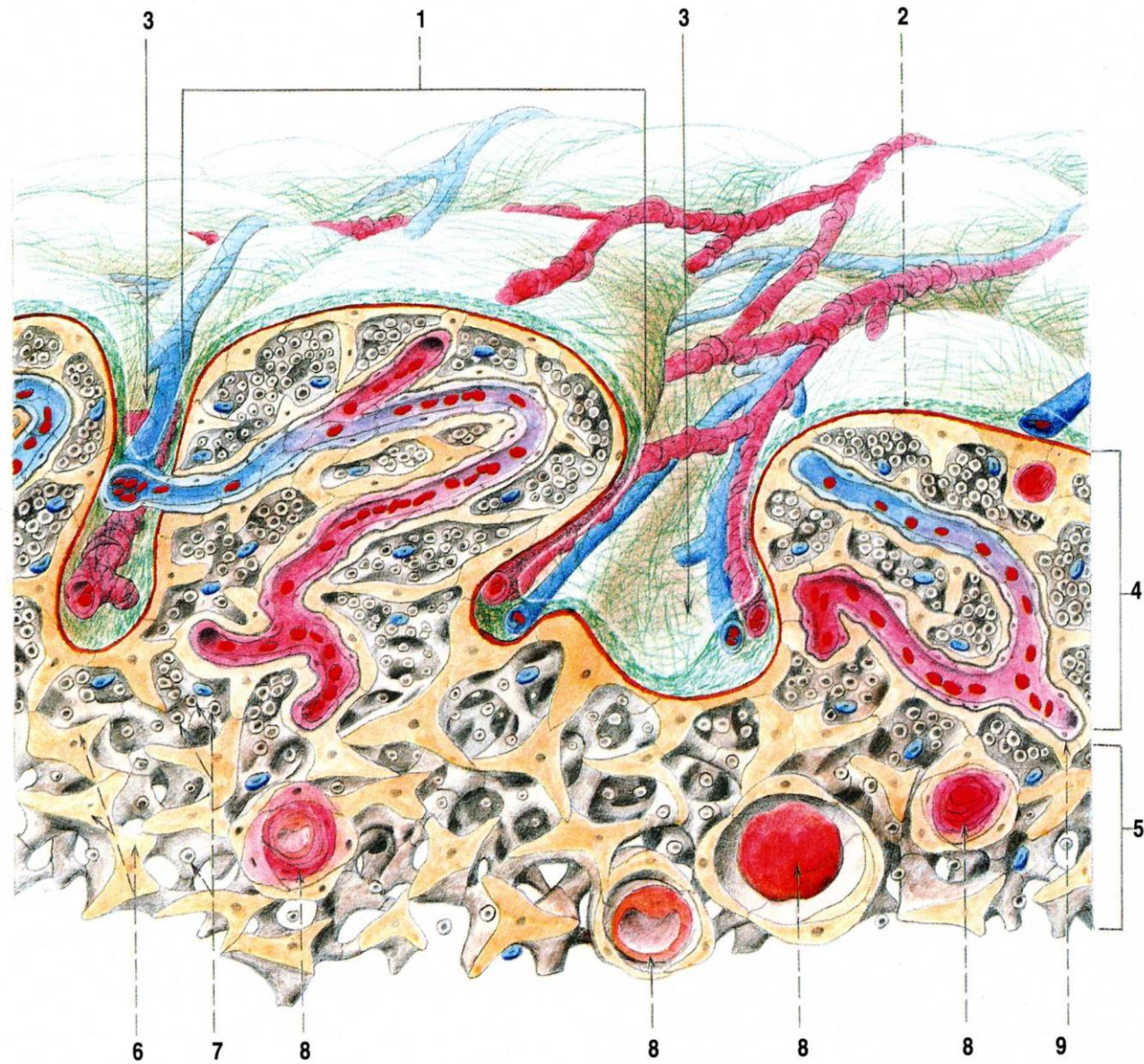
**Area interpleuralis sup.  
(thymica)**





# Thymus

- capsula
- reticulum
- lobuli
- cortex
- medulla

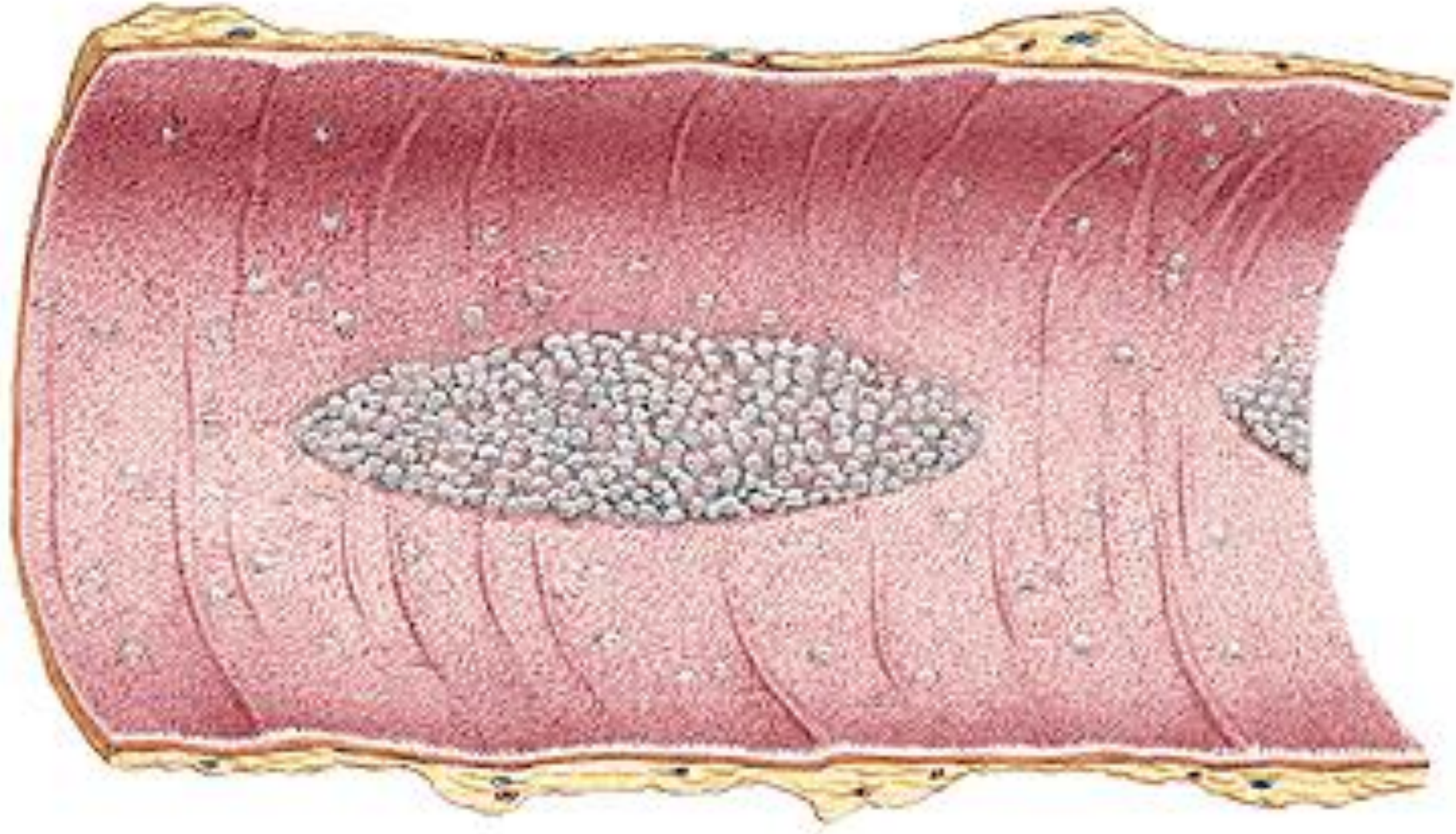


Obr. 128. STAVBA THYMU (schéma)

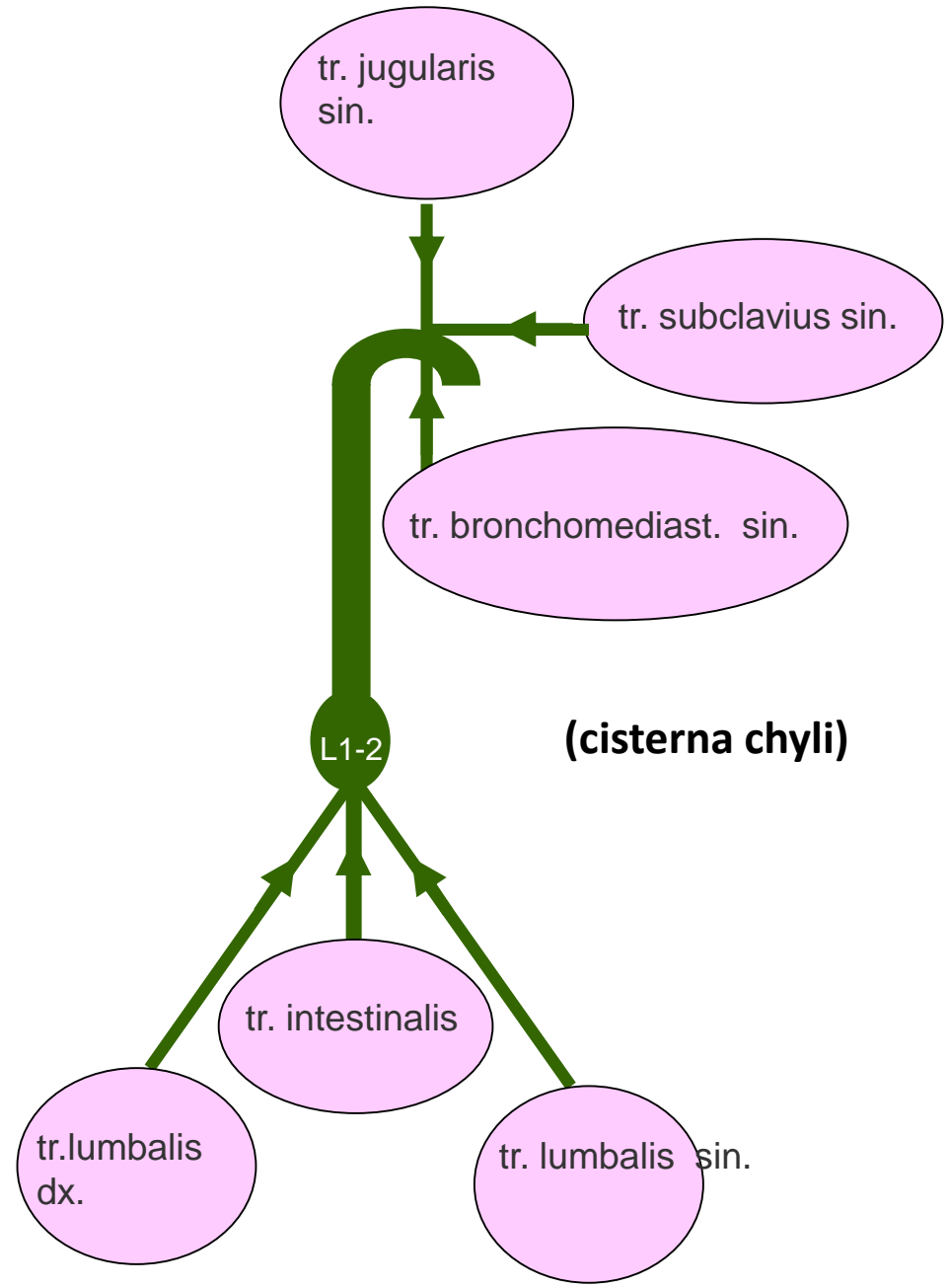
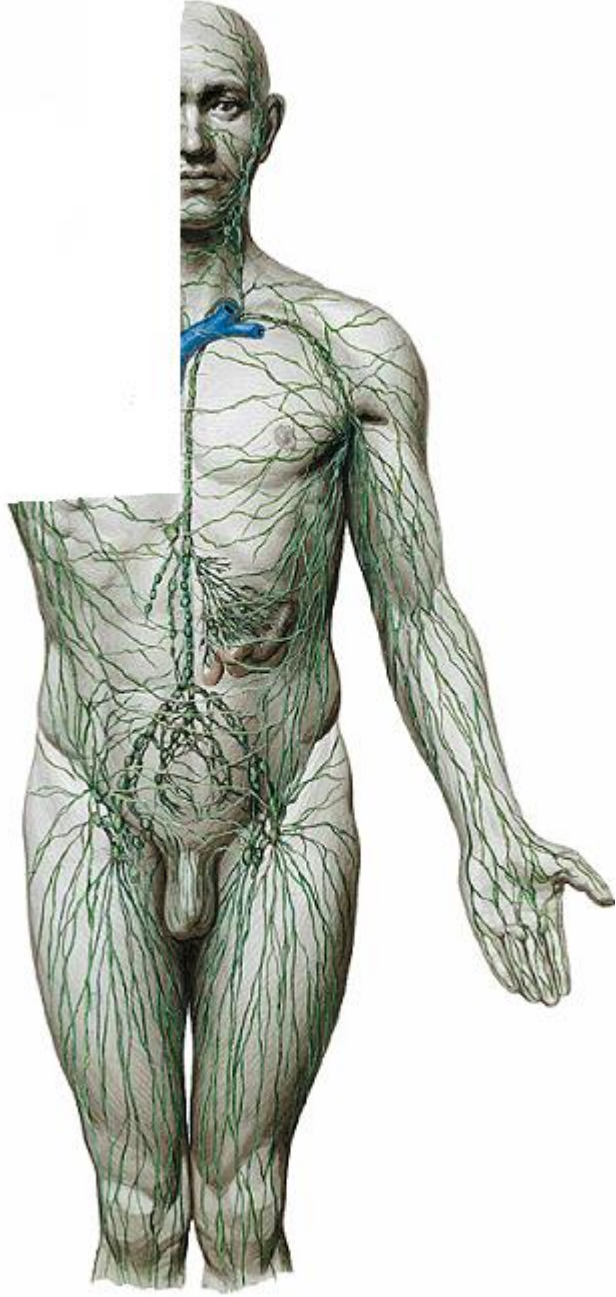
- 1 lobulus thymi
- 2 capsula thymi
- 3 vazivová septa s cévami
- 4 cortex thymi

- 5 medulla thymi
- 6 retikulum thymu
- 7 lymfocyty v okách retikula thymu
- 8 Hassalova tělíska v různých fázích svého vzniku
- 9 silná bazální membrána kapilár

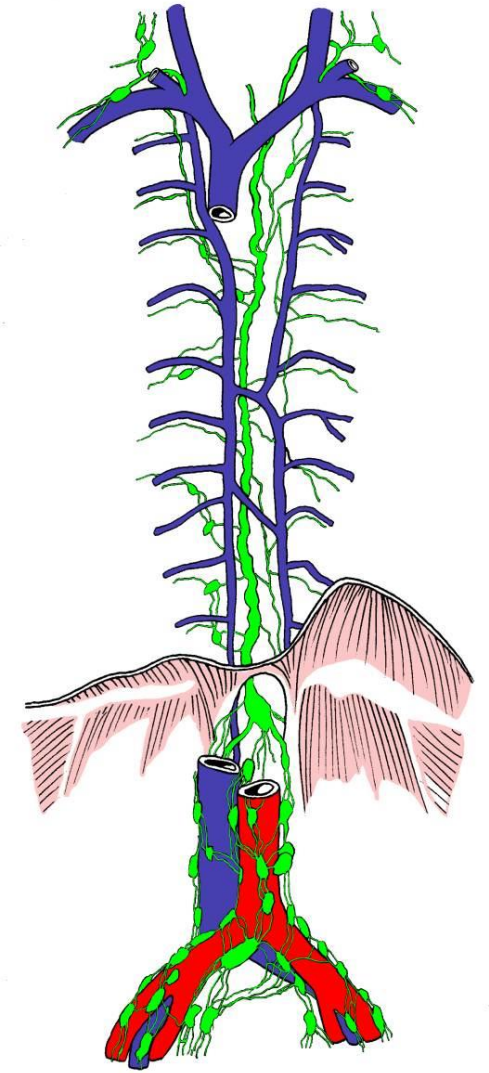
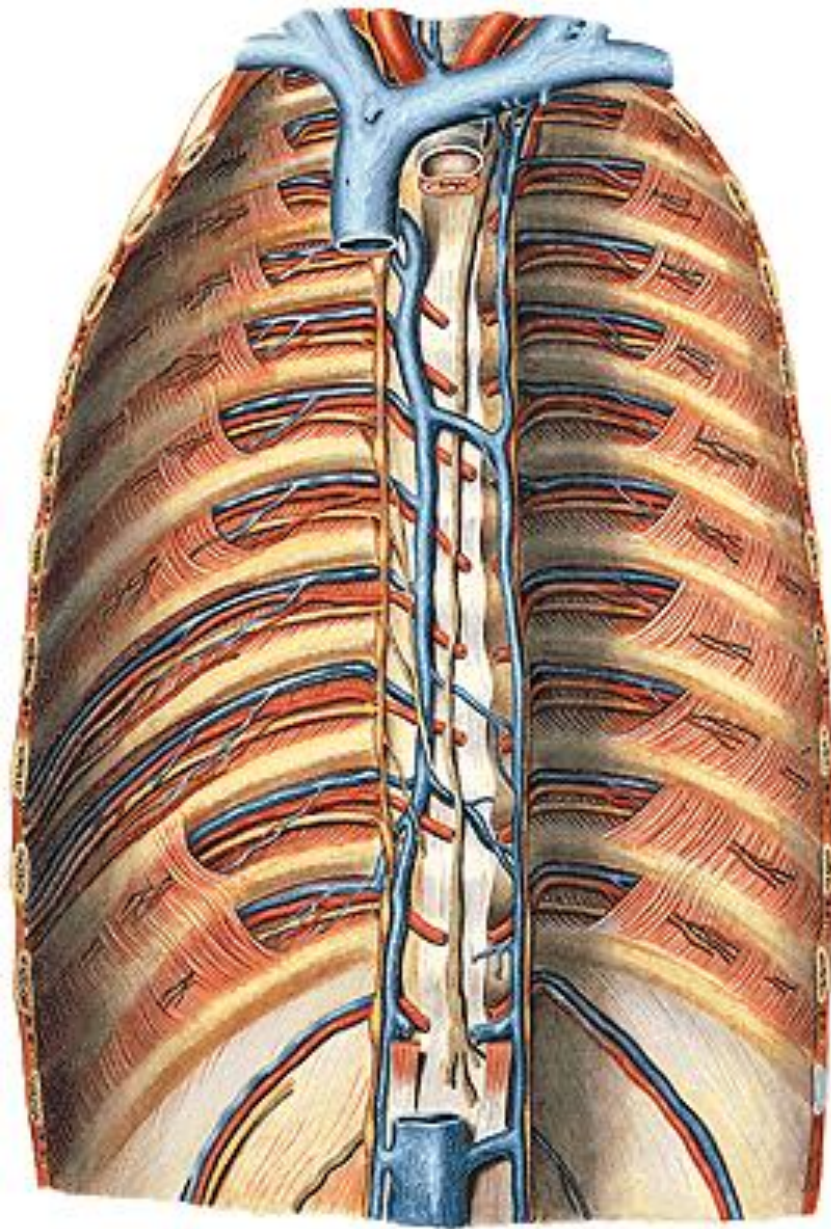
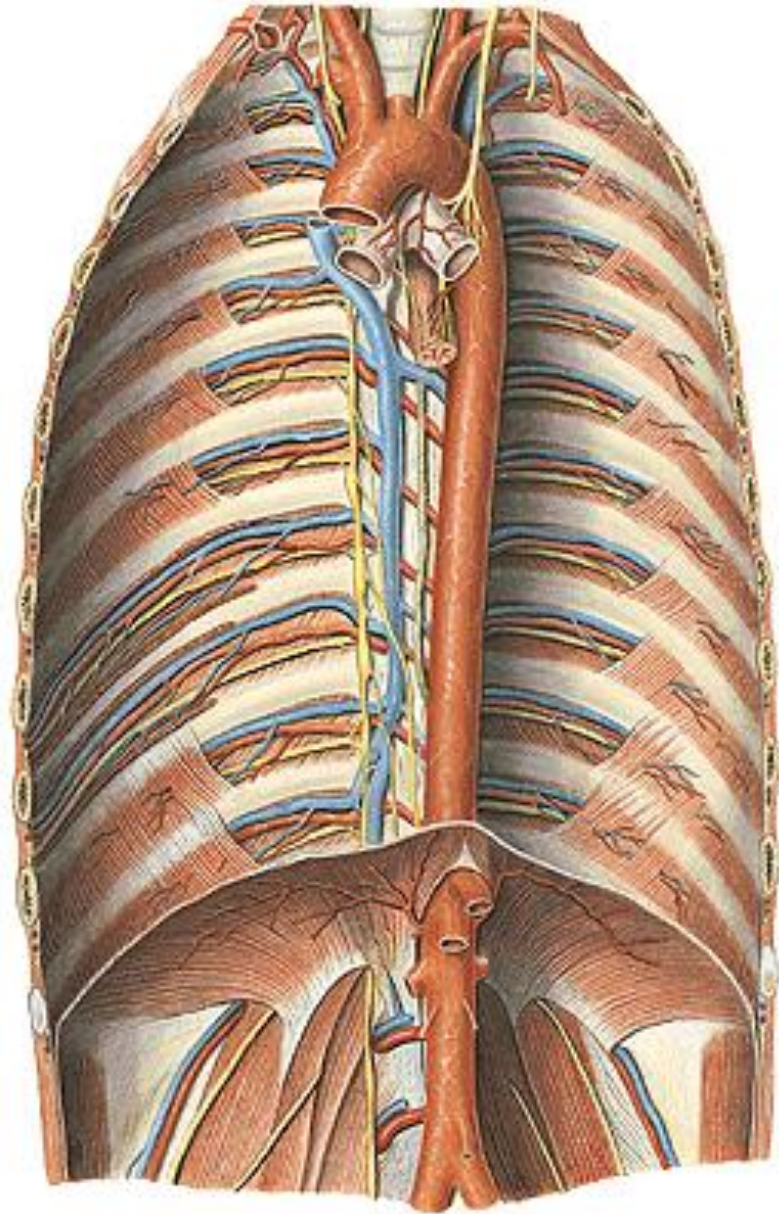
**Folliculi lymphatici solitarii**  
**Folliculi lymphatici aggregati**



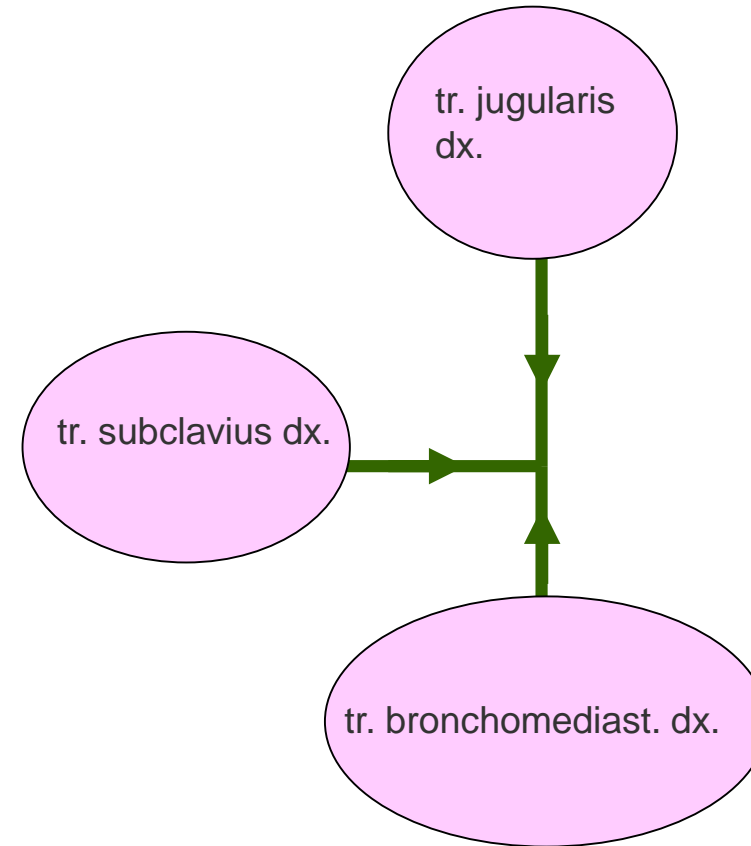
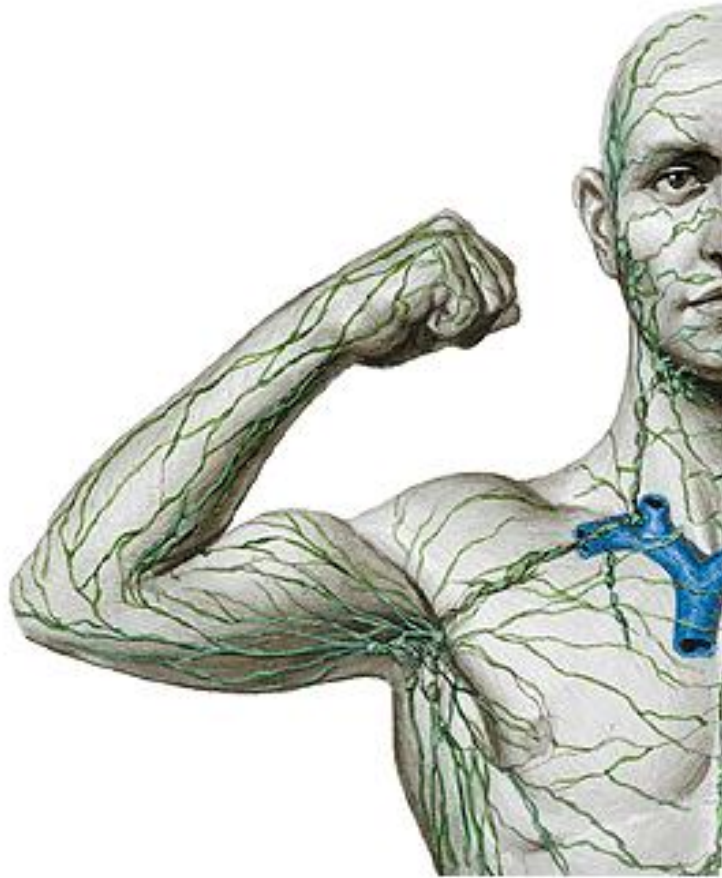# ductus thoracicus



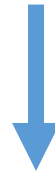# Ductus thoracicus



## ductus lymphaticus dx.



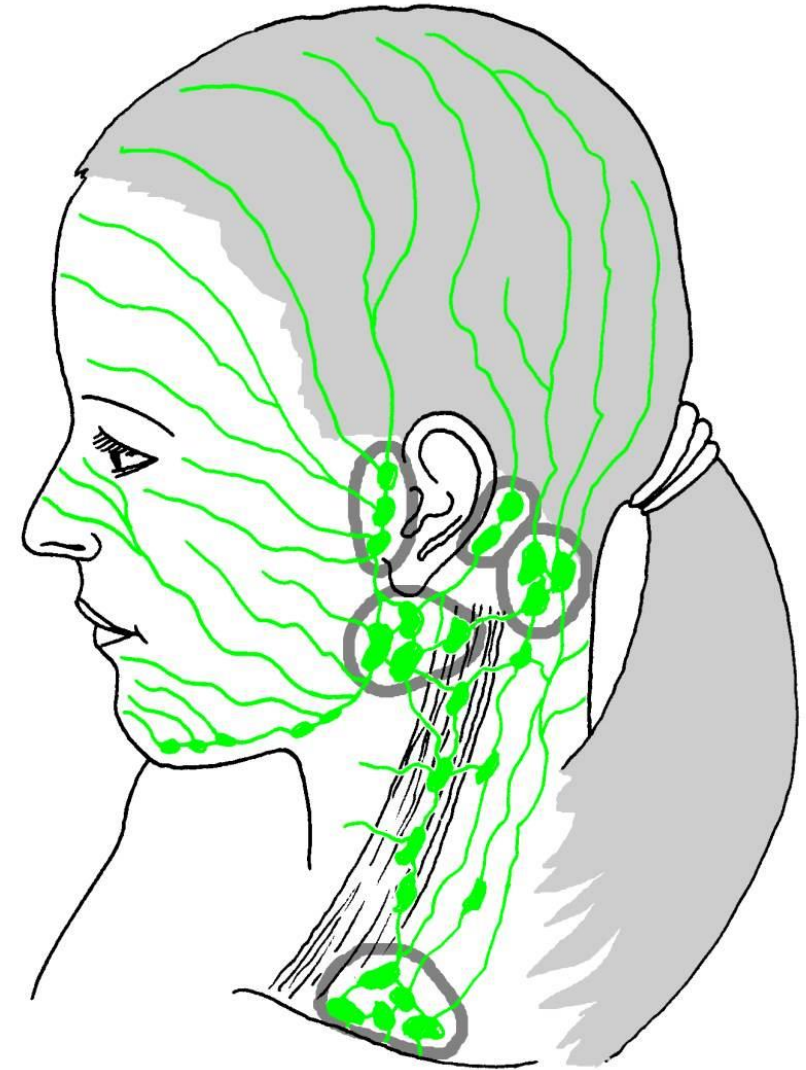
- **nodi lymphatici occipitales**
- **nodi lymphatici retroauriculares**
- **nodi lymphatici parotidei**
- **nodi lymphatici submandibulares**
- **nodi lymphatici submentales**
- **nodi lymphatici retropharyngei**



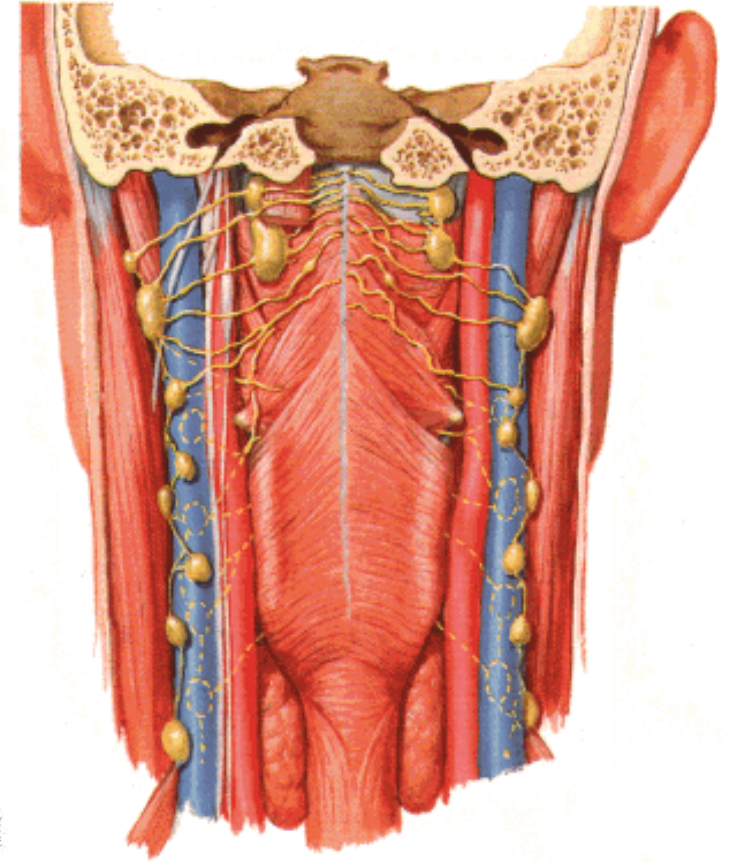
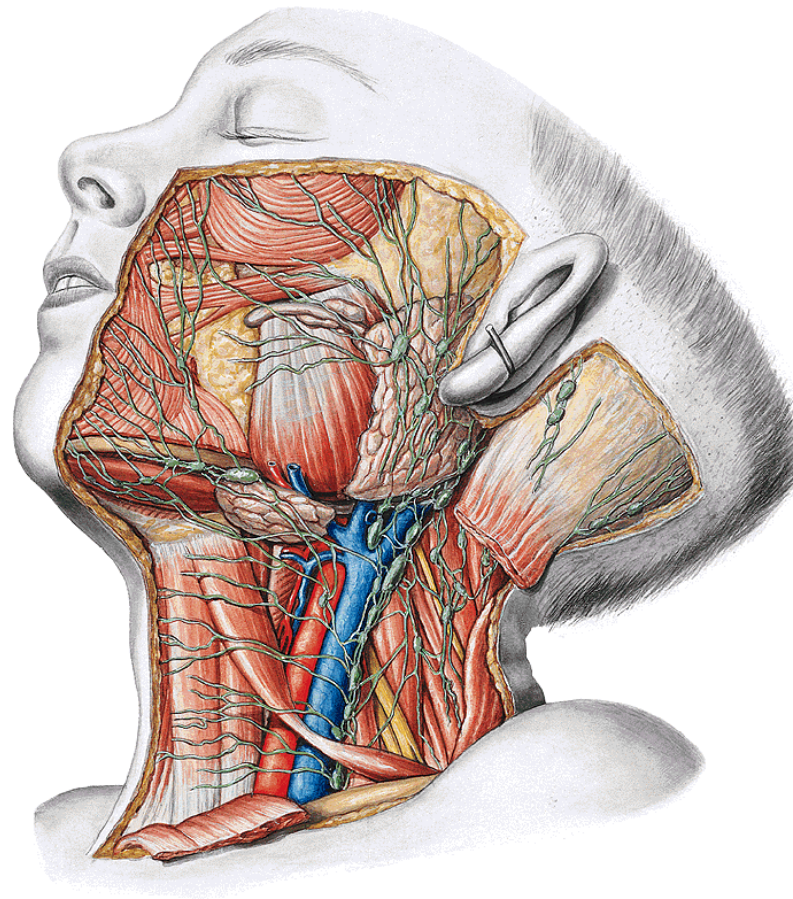
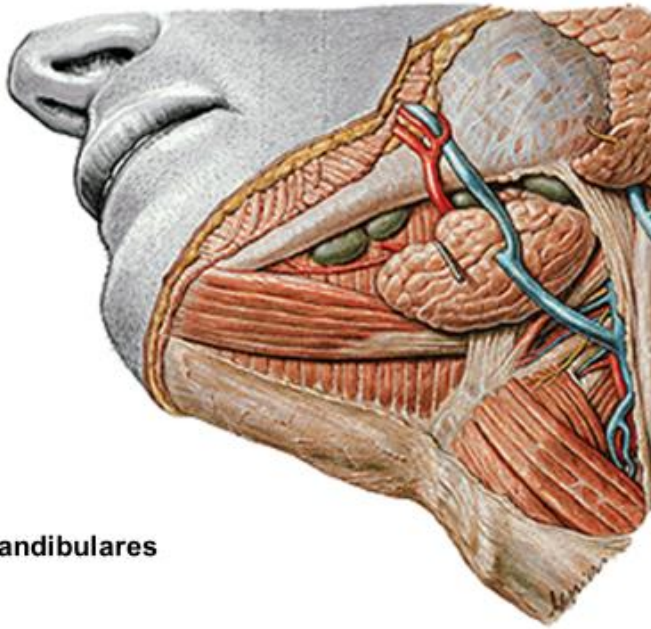
**Nll. cervicales ant.spf. et prof.**  
**Nll. cervicales lat. spf. et prof.**  
**(nll. jugulares int.**  
**nll. supraclaviculares)**

 **tr. jugularis**

## **Lymphatic drainage of the head and neck**

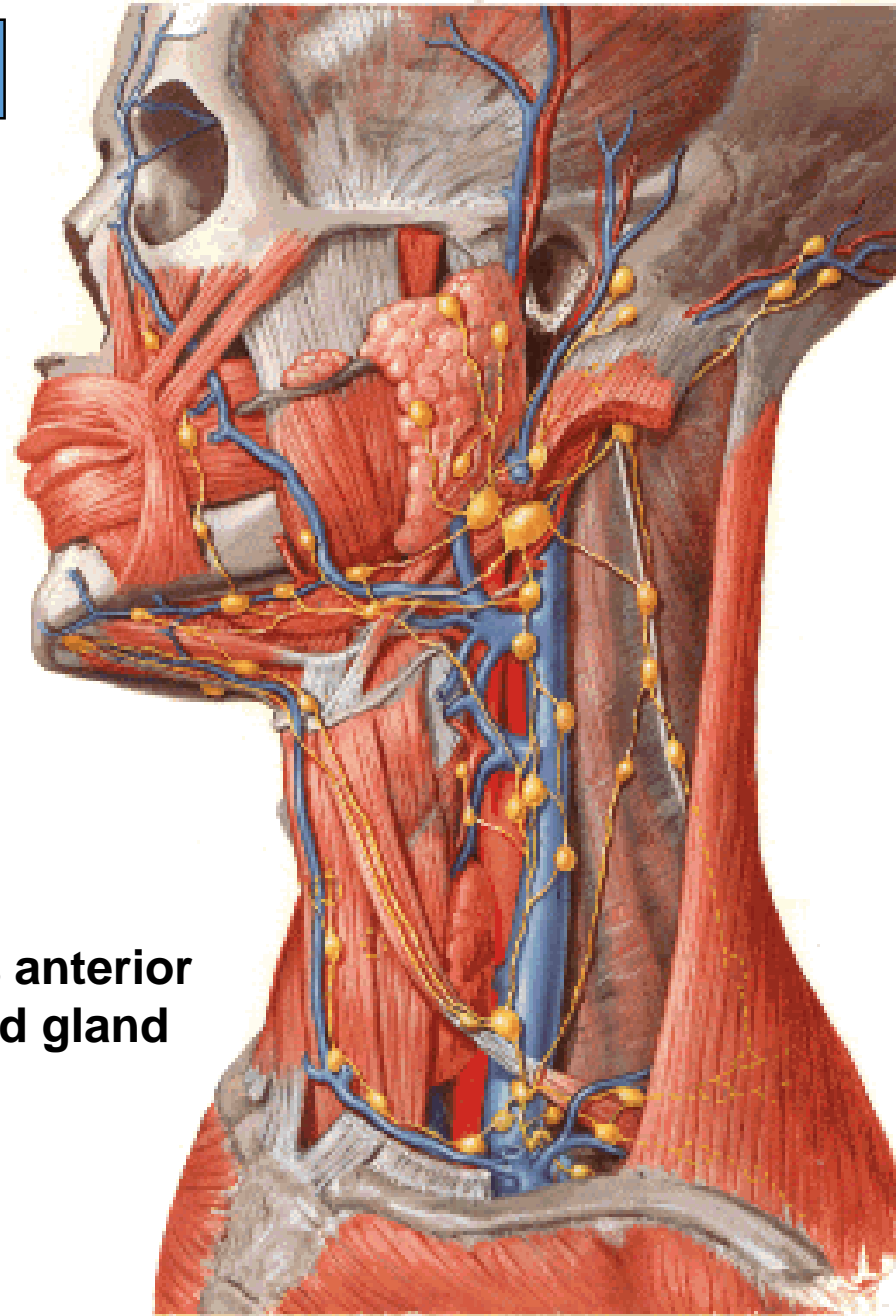


**III. submandibulares**



## Nodi lymphatici cervicales

- **superficiales**  
alongside vena jugularis externa
- **profundi**  
alongside vena jugularis interna  
alongside nervus accesorius  
alongside arteria transversa coli  
(supraclavicular)
- **anteriores**  
superficial - alongside vena jugularis anterior  
deep – around larynx, trachea, thyroid gland





# Lymphatic vessels of the upper extremity

- **superficial collectors**

anterior

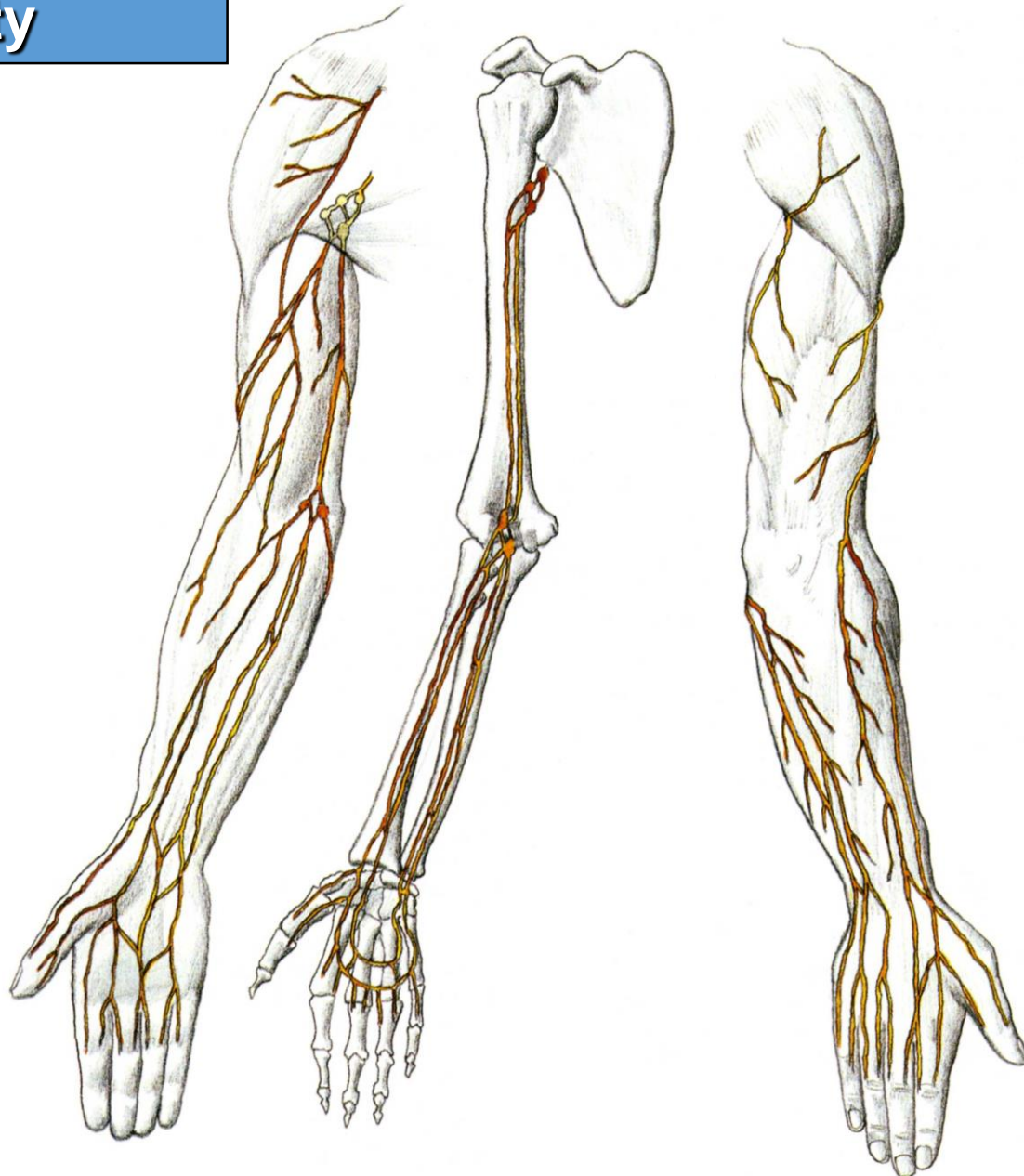
lateral

medial

n.l. cubitales superf.

- **deep collectors**

n.l. cubitales prof.  
n.l. axillares

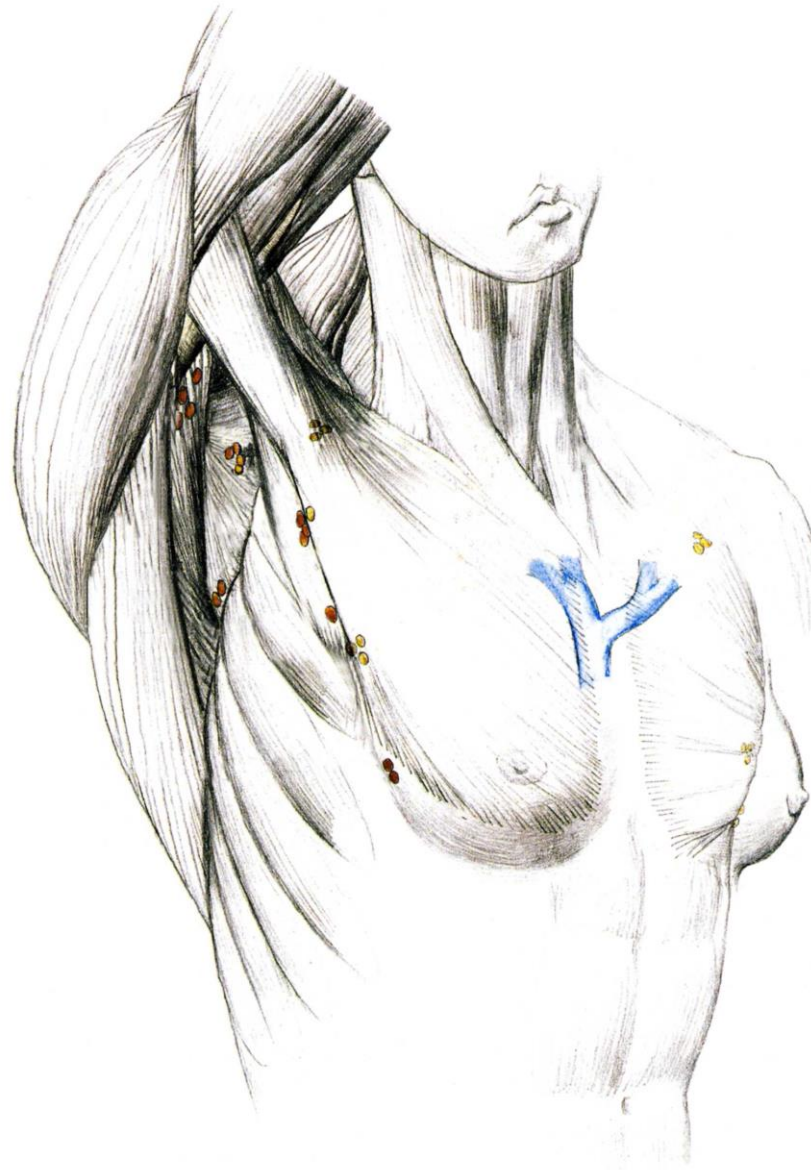


## n.l. axillares

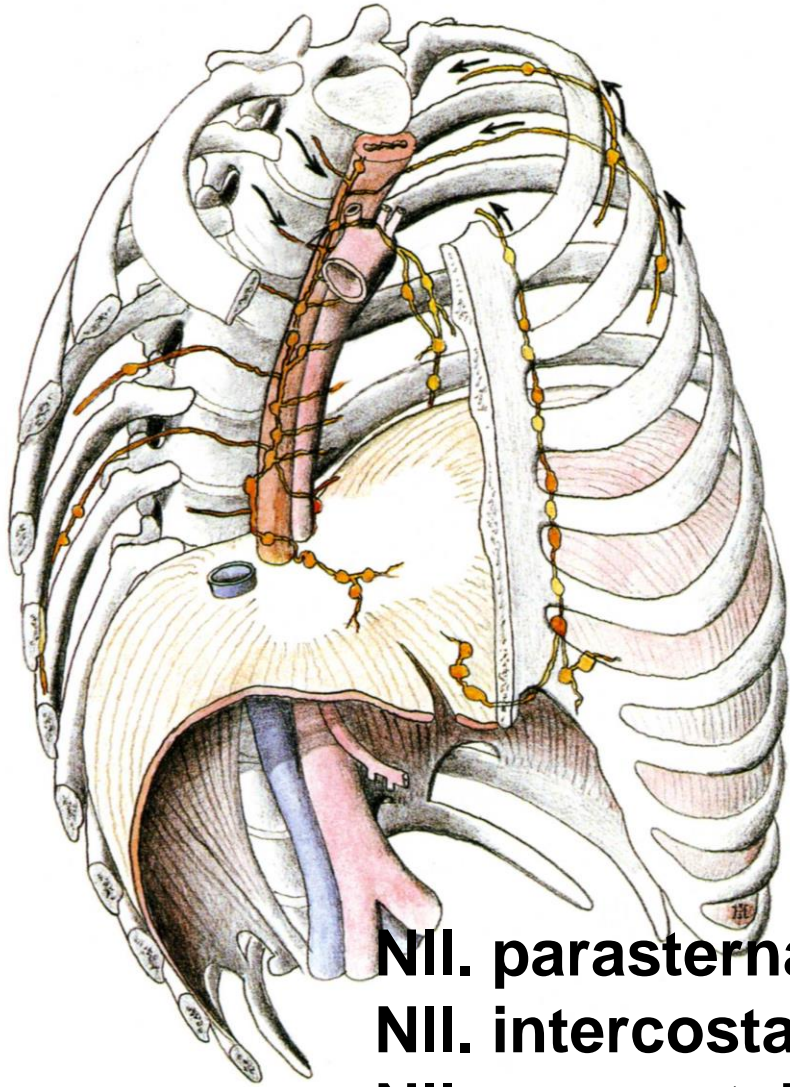
- n.l. laterales (brachiales)
- n.l. subscapulares
- n.l. pectorales  
(n.l. interpectorales)
- n.l. centrales
- n.l. apicales



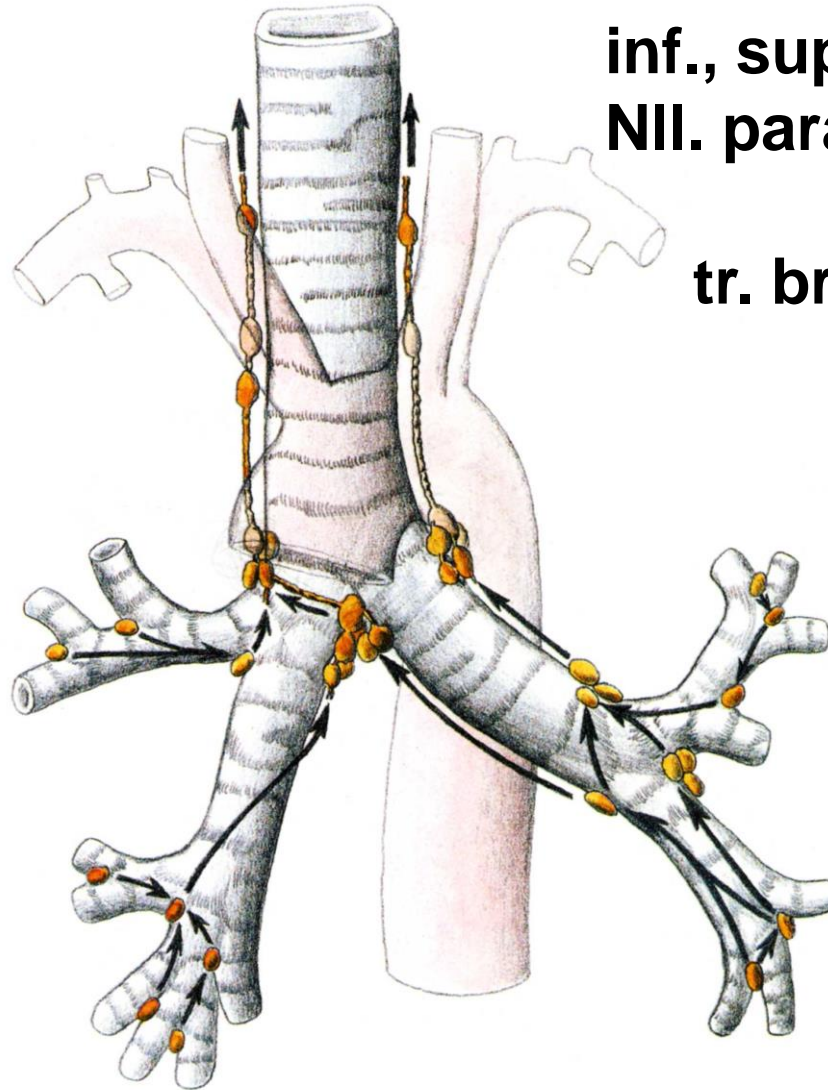
**truncus subclavius**



## Lymphatic vessels of the thorax



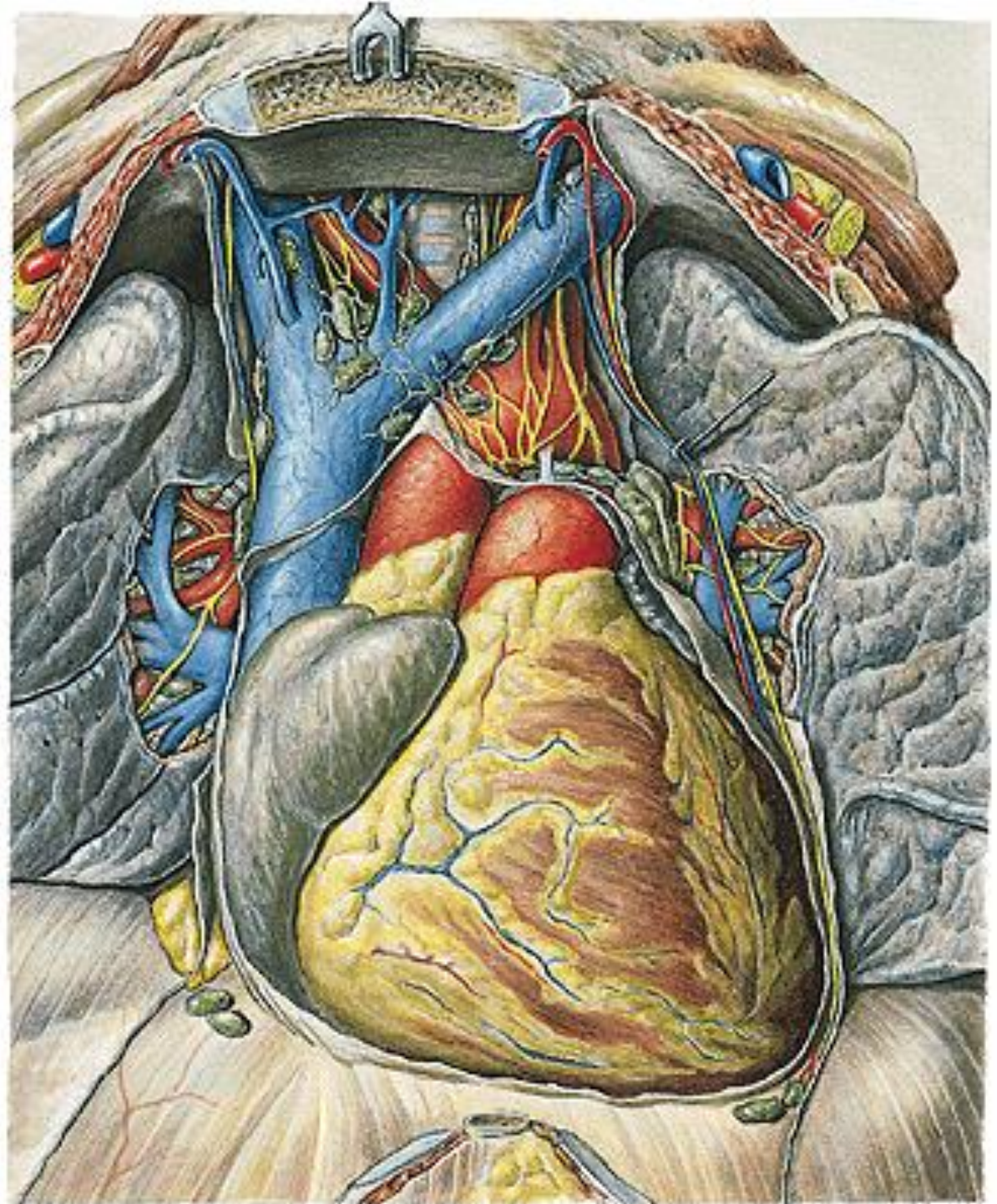
**NII. parasternales**  
**NII. intercostales**  
**NII. praevertebrales**  
**NII. phrenici sup.**



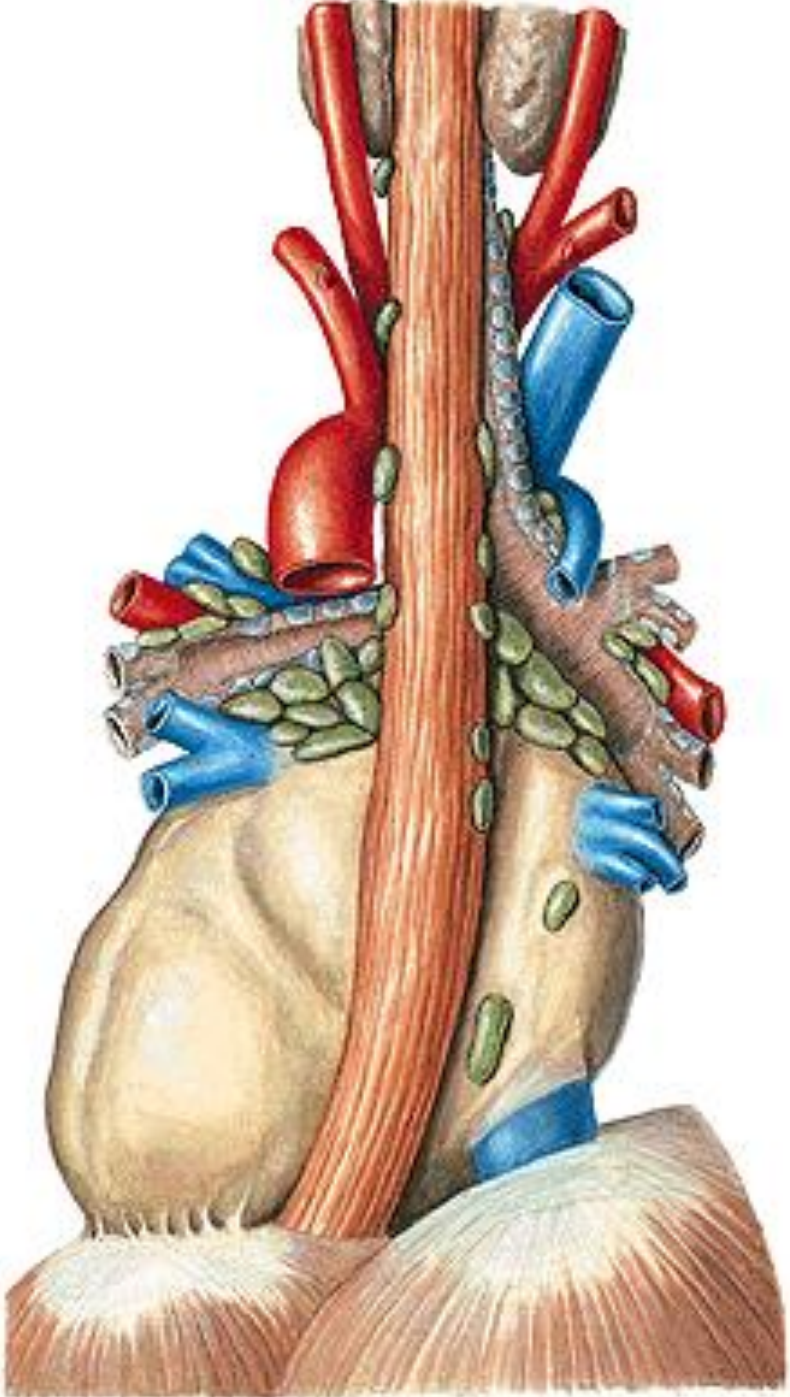
**NII. pulmonales**  
**NII. bronchopulmonales**  
**NII. tracheobronchiales**  
**inf., sup. – dx. et sin.**  
**NII. paratracheales**

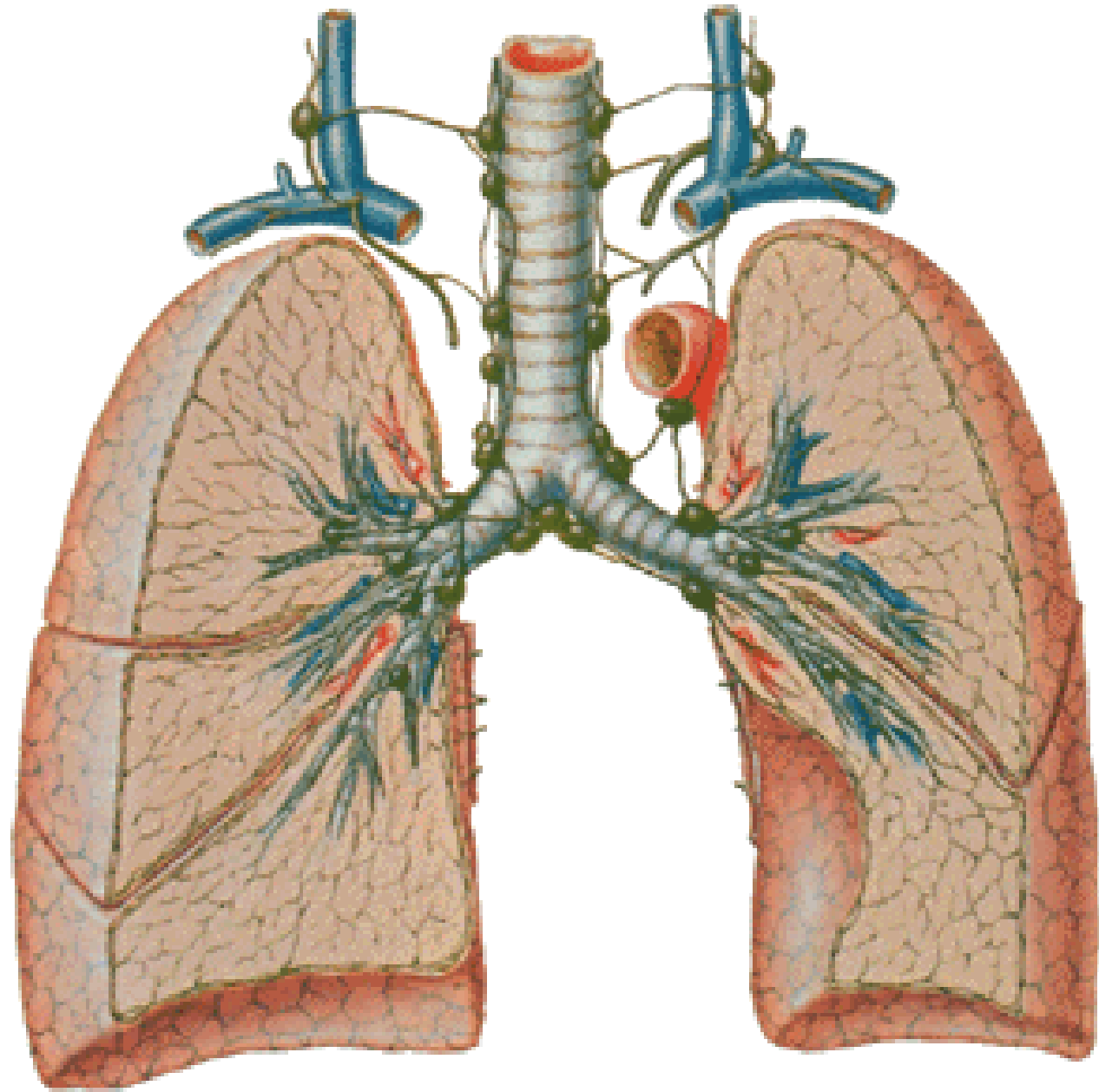
**tr. bronchomediastinalis**

## NII. mediastinales ant.

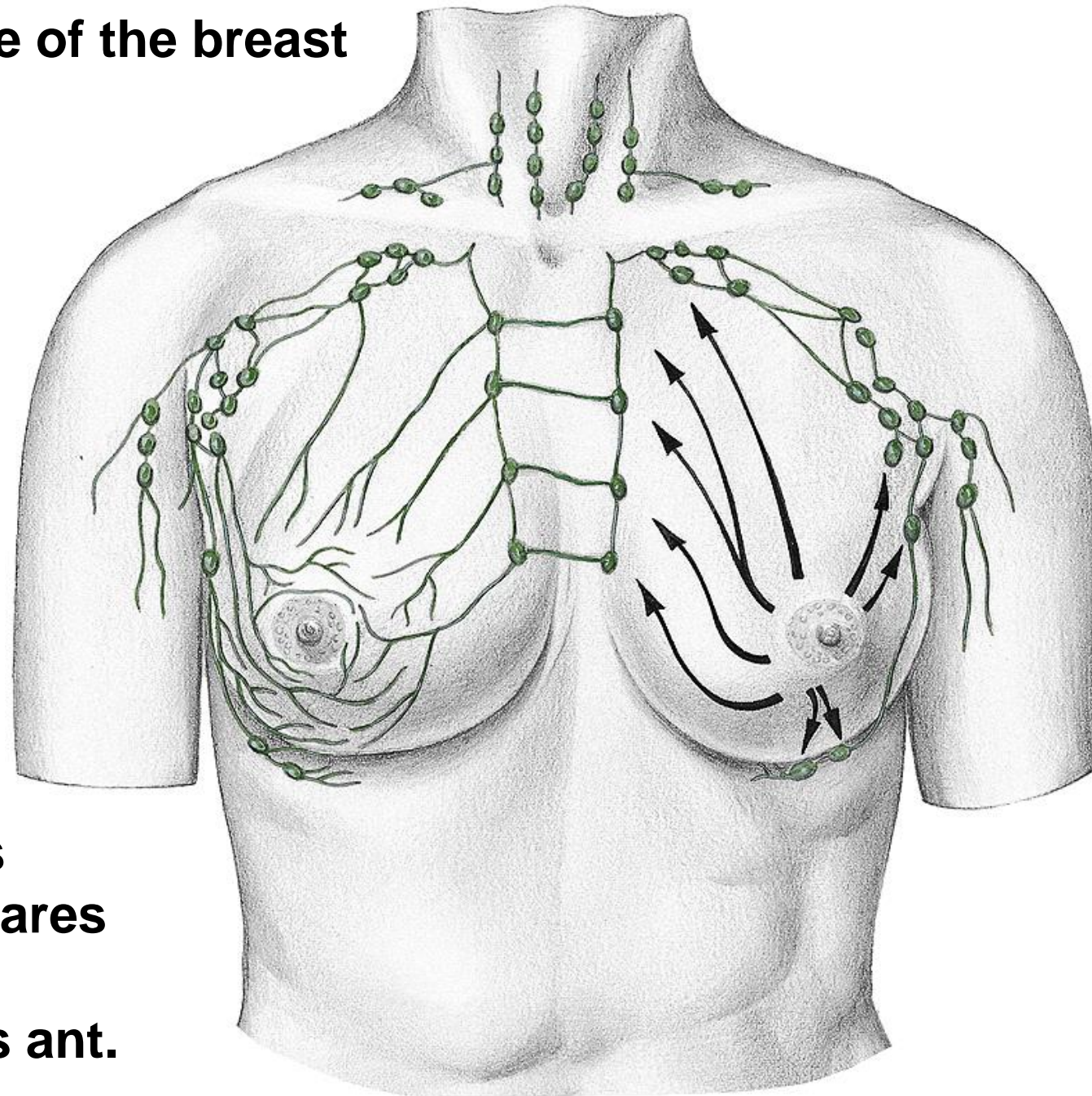


**NII. mediastinales post.**





# Lymphatic drainage of the breast



- nll. axillares
- nll. parasternales
- nll. supraclaviculares
- nll. intercostales
- nll. mediastinales ant.

# Lymphatic vessels of the lower extremity

- **superficial collectors**

posterior

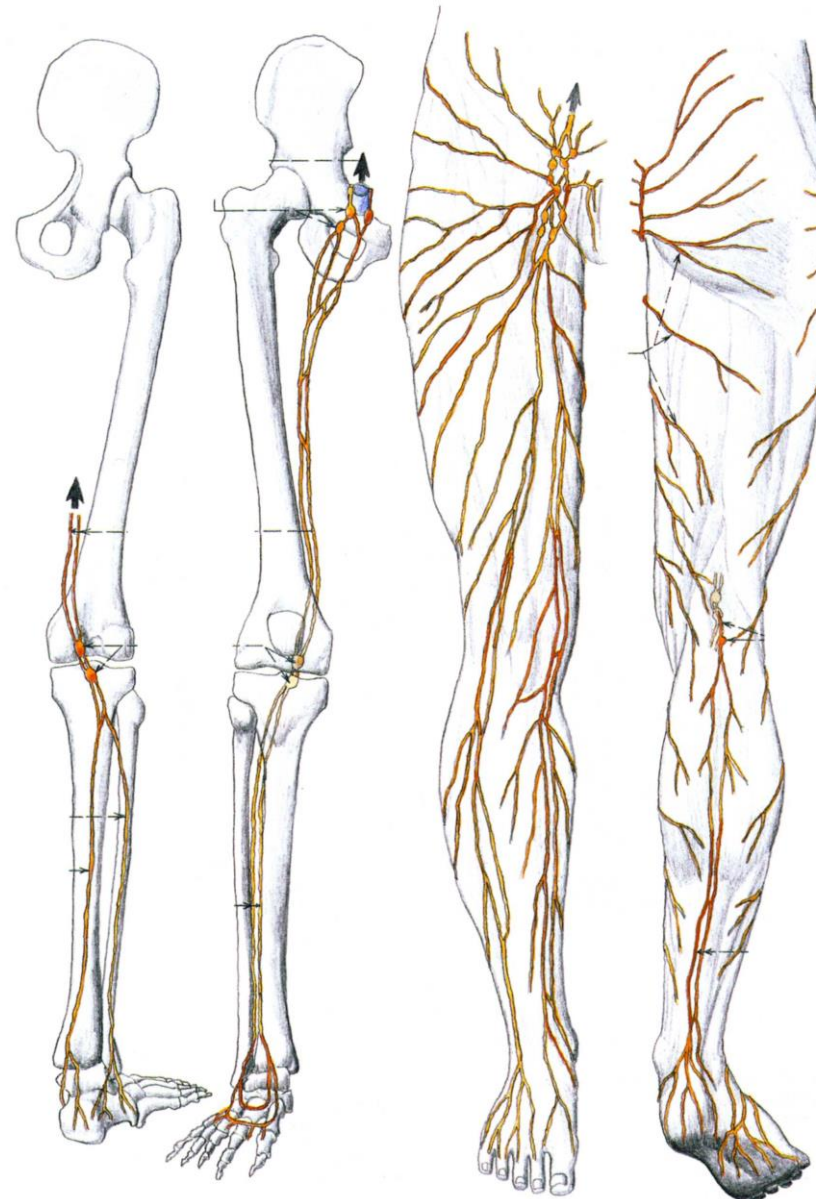
lateral

medial

n.l. poplitei superf.  
n.l. inguinales superf.

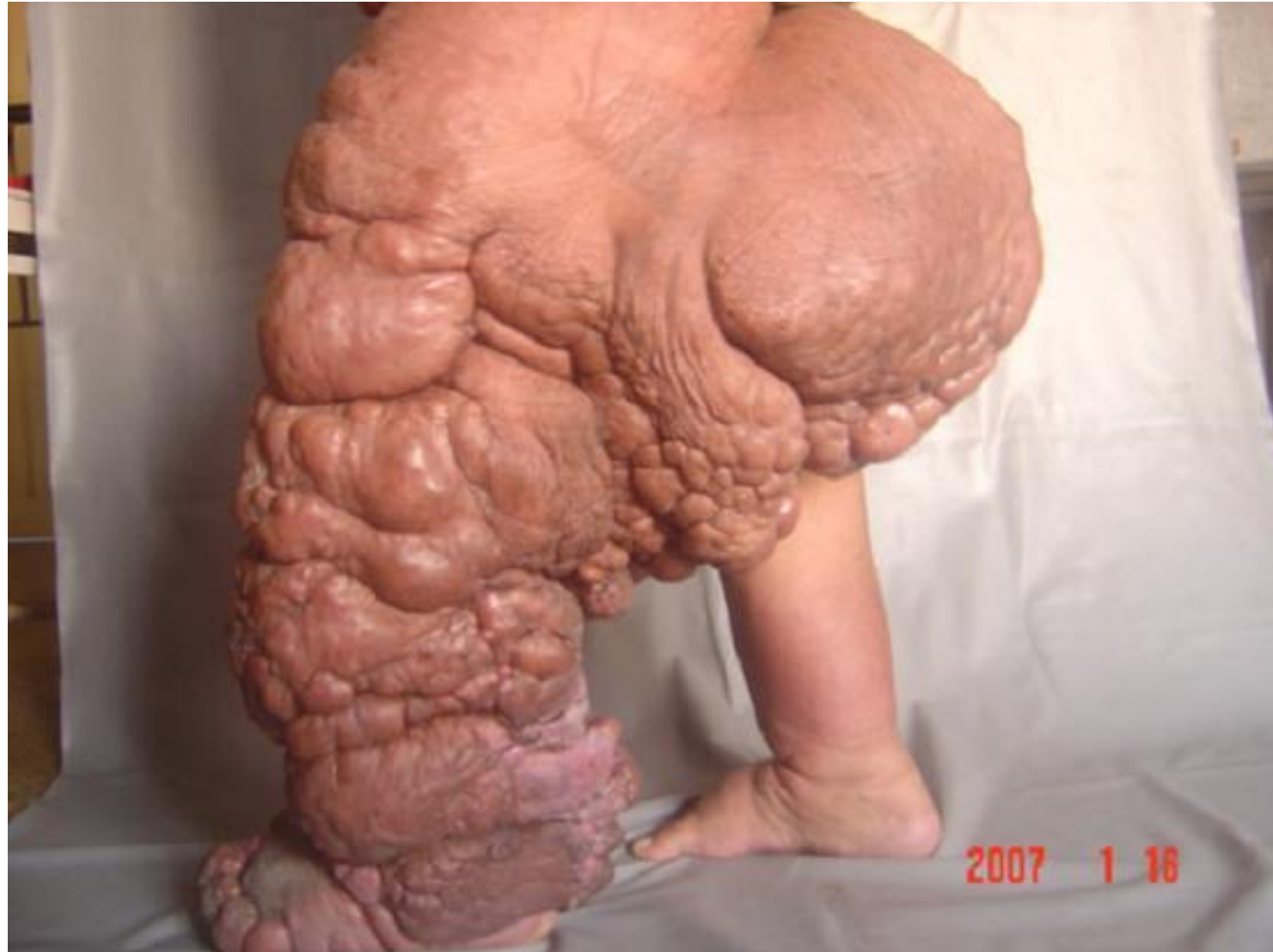- **deep collectors**

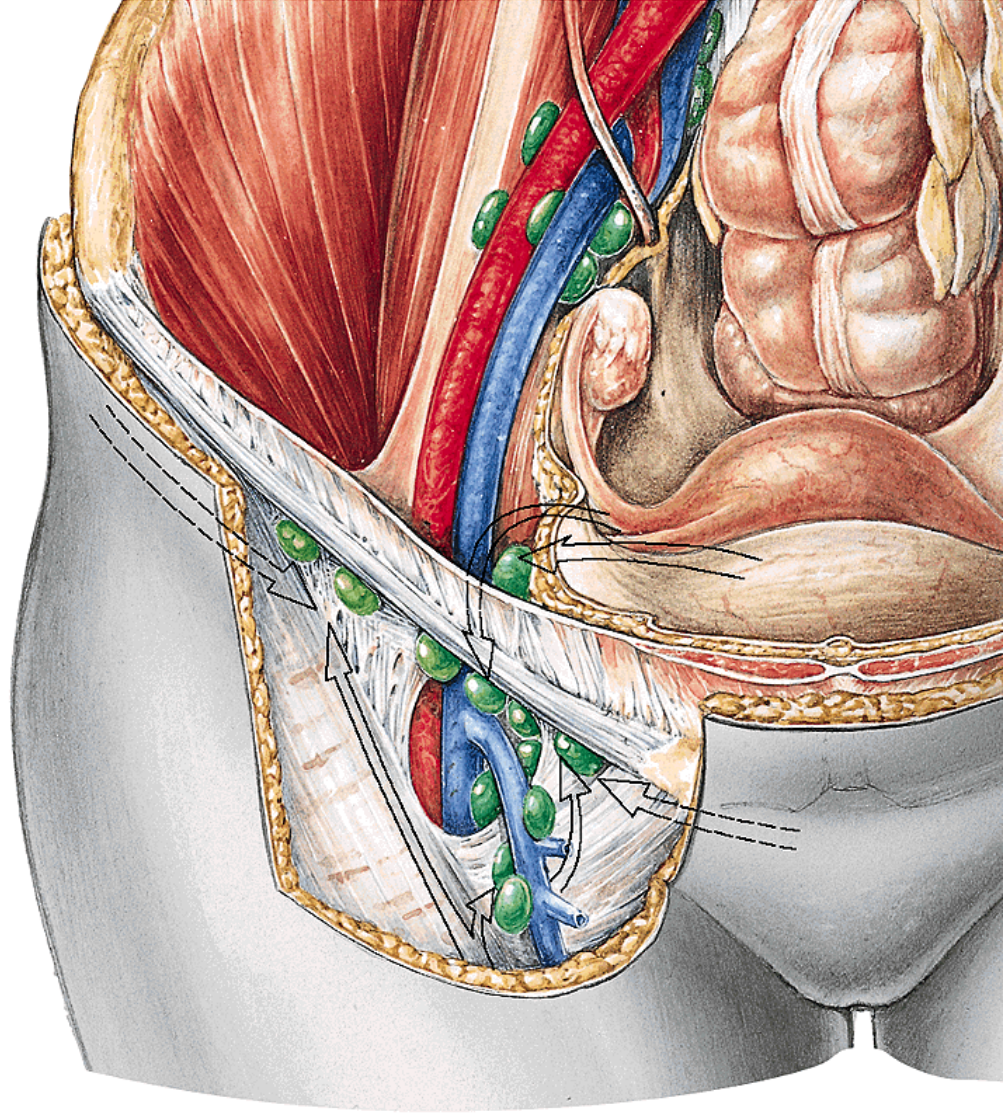
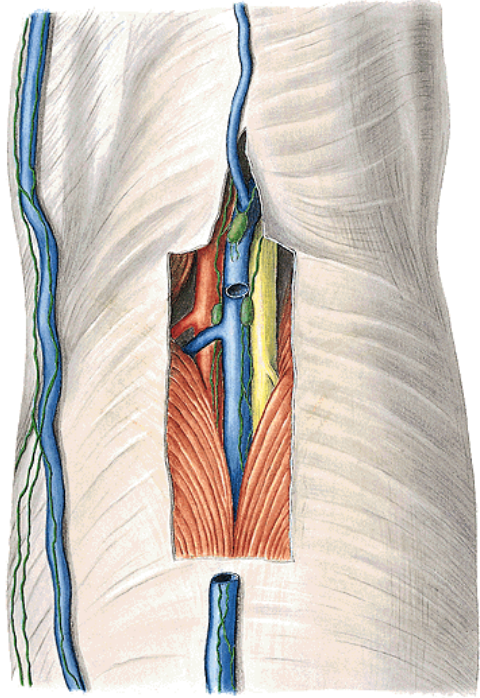
n.l. poplitei prof.  
n.l. inguinales prof.





## Elephantiasis





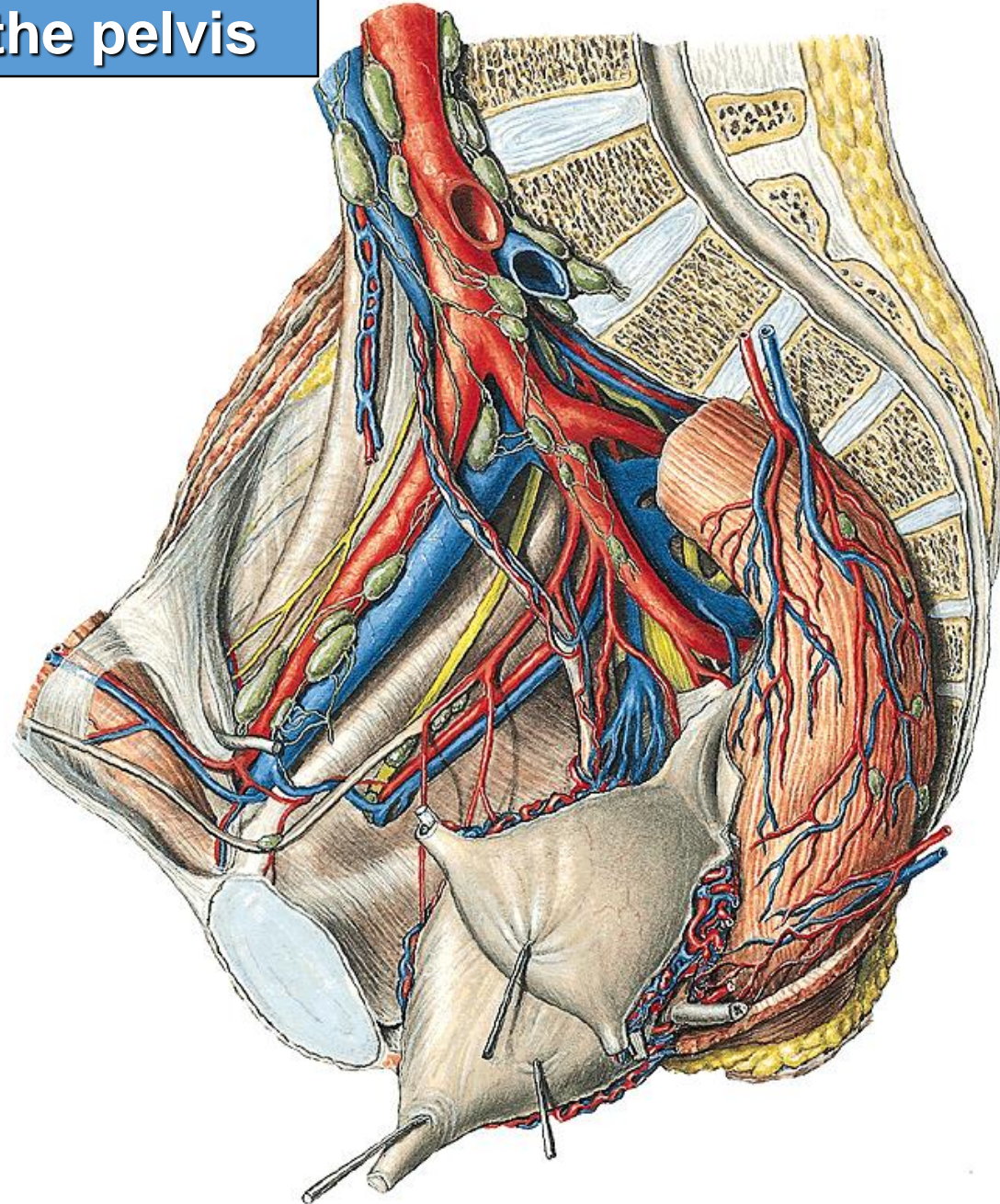
## Lymphatic vessels of the pelvis

- **nodi lymphatici iliaci externi**

- **nodi lymphatici iliaci interni**

**parietal - sacrales**

**visceral - paravesicales  
parauterini  
paravaginales  
(paraprostatici)  
pararectales**



## Lymphatic nodes of the abdominal cavity

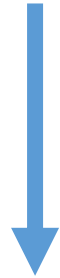nodi lymphatici iliaci comm.



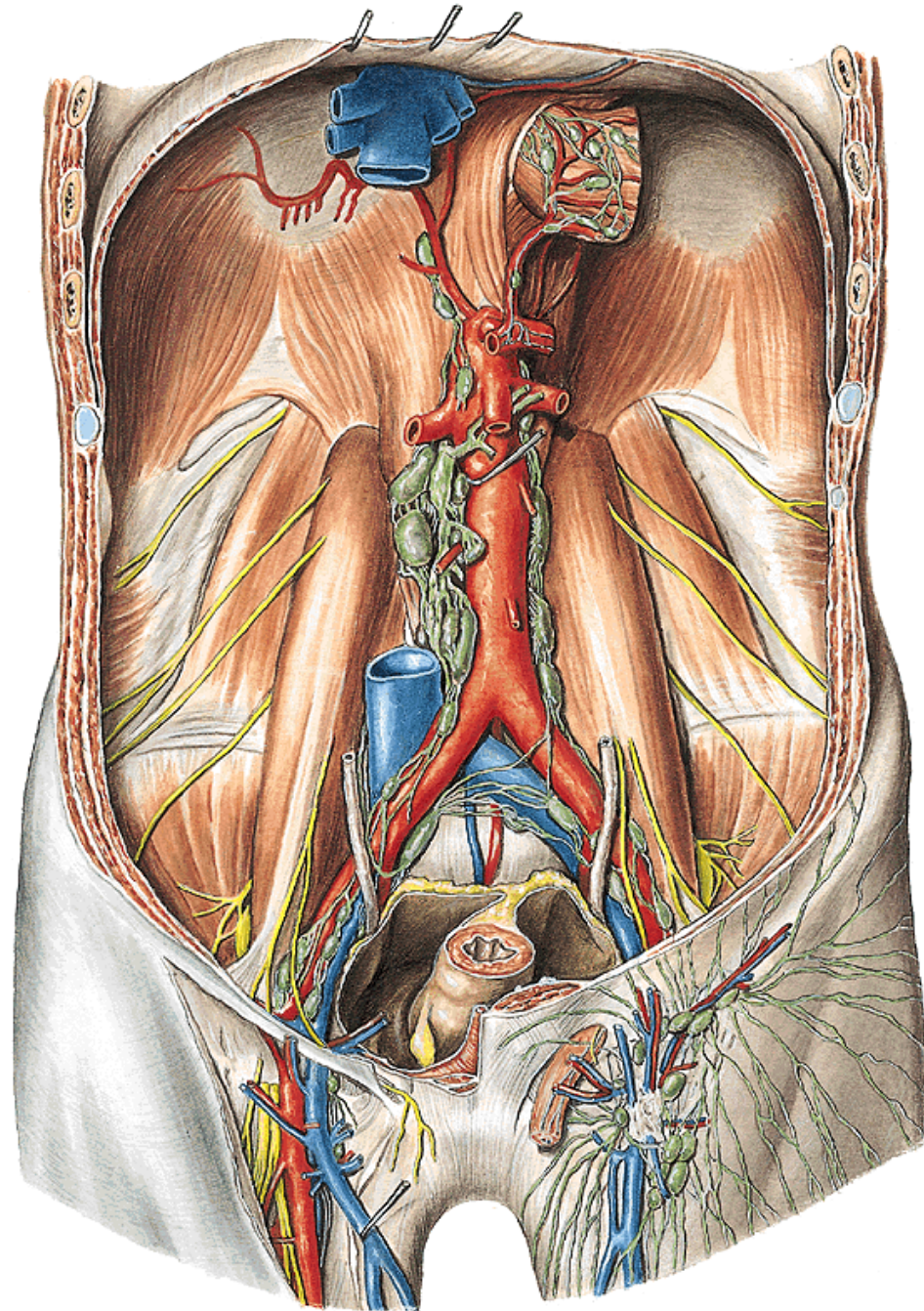
nodi lymphatici lumbales

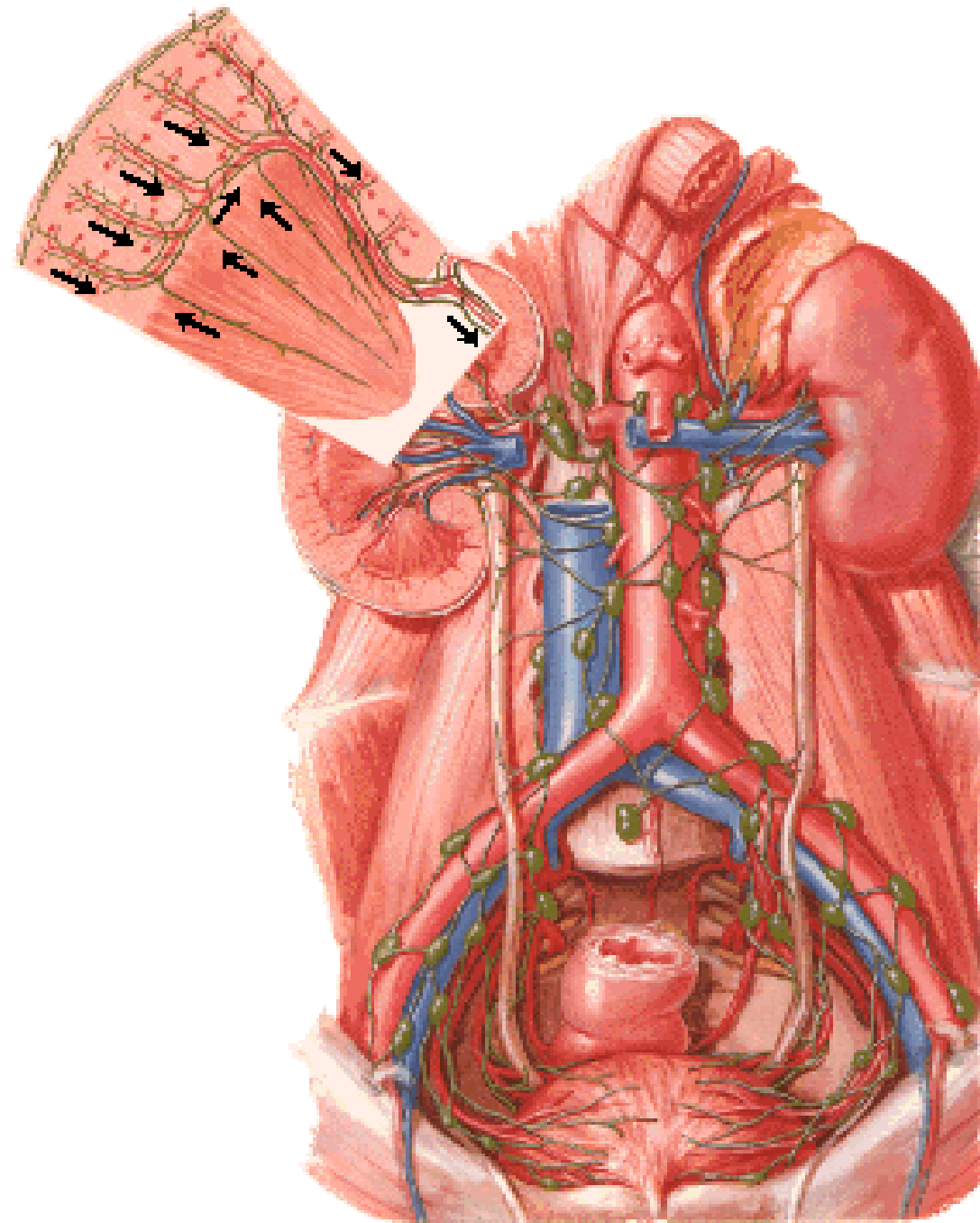
parietal

visceral from paired organs

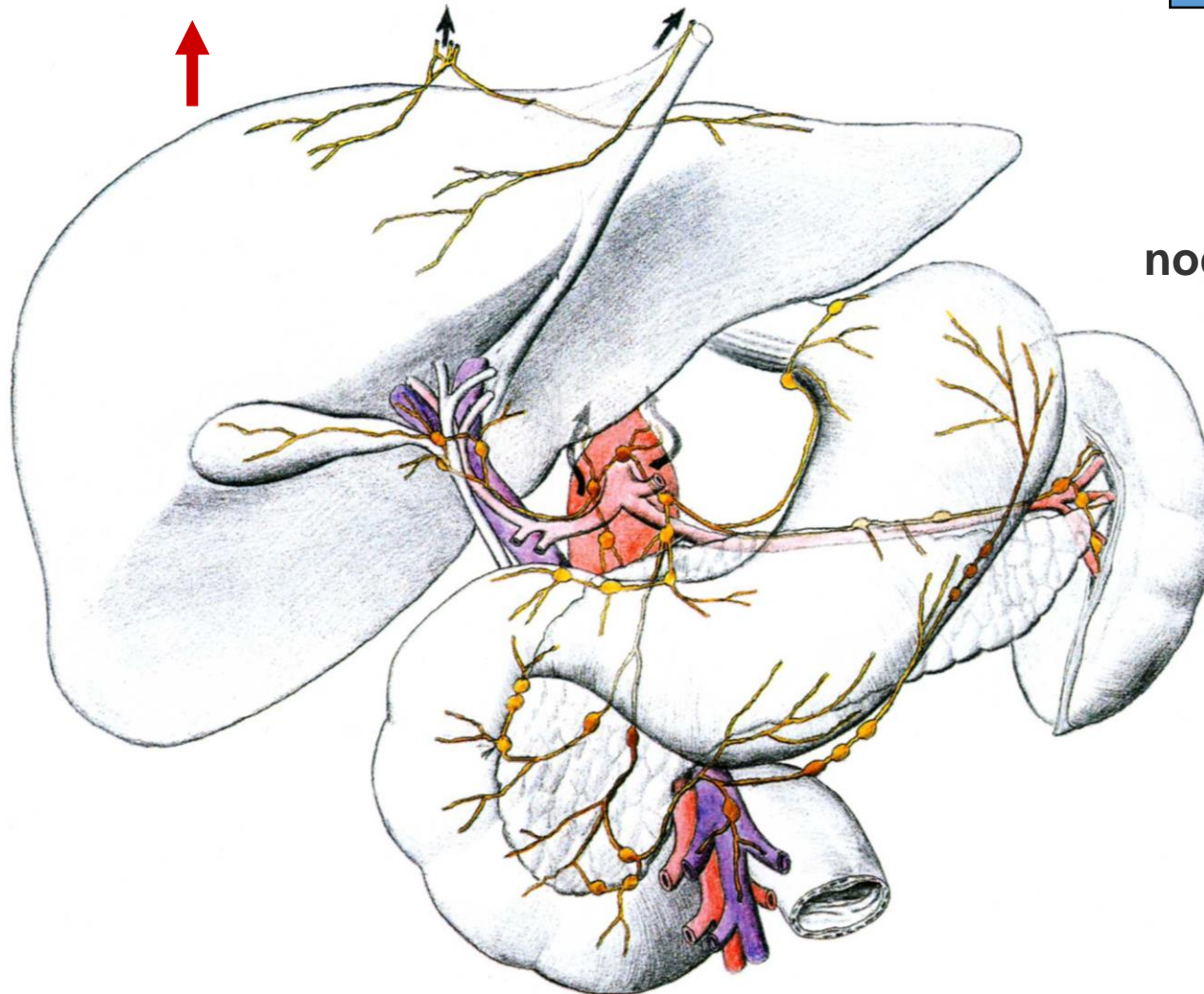


truncus lumbalis dx. et sin.





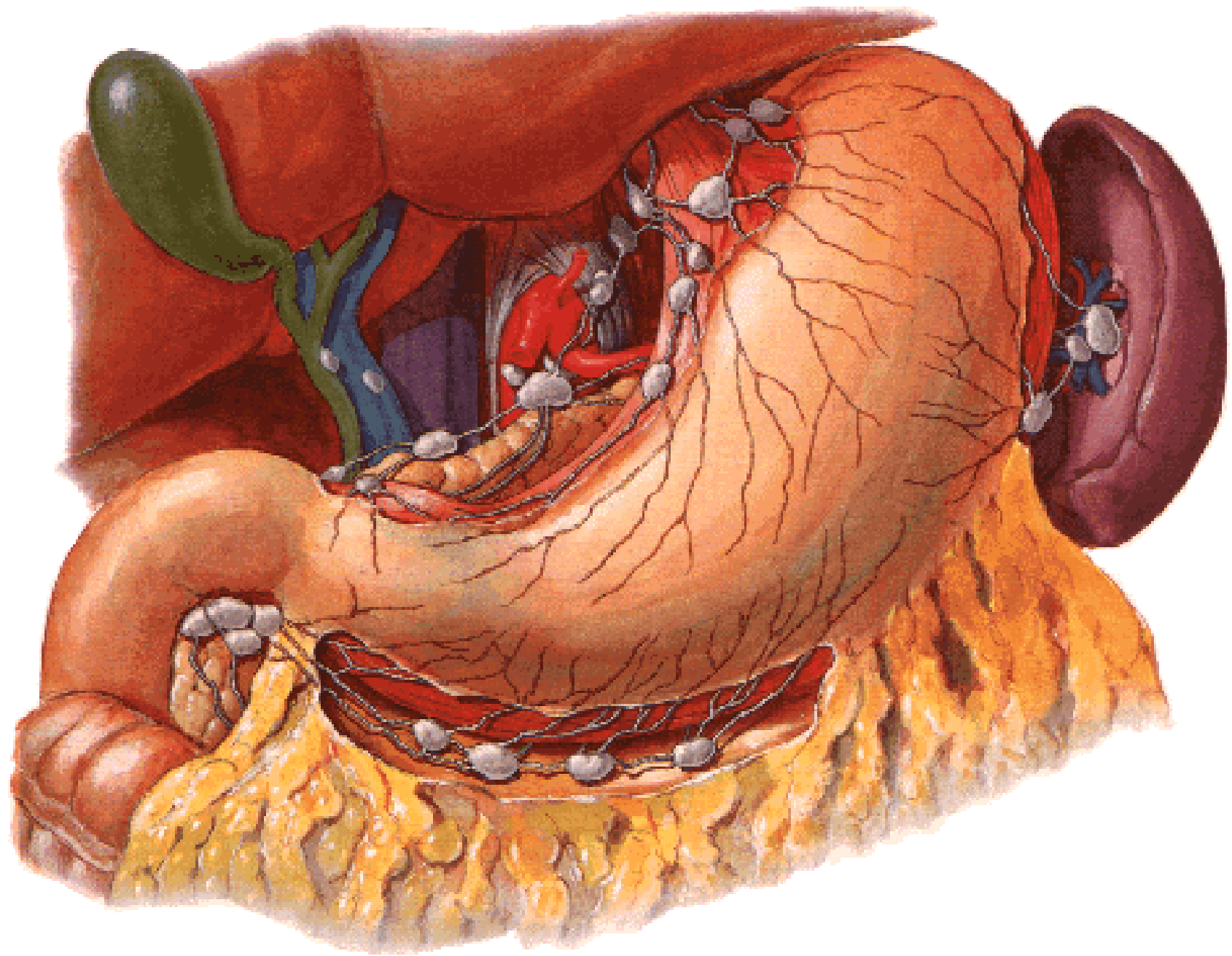# Lymphatic nodes of the unpaired organs

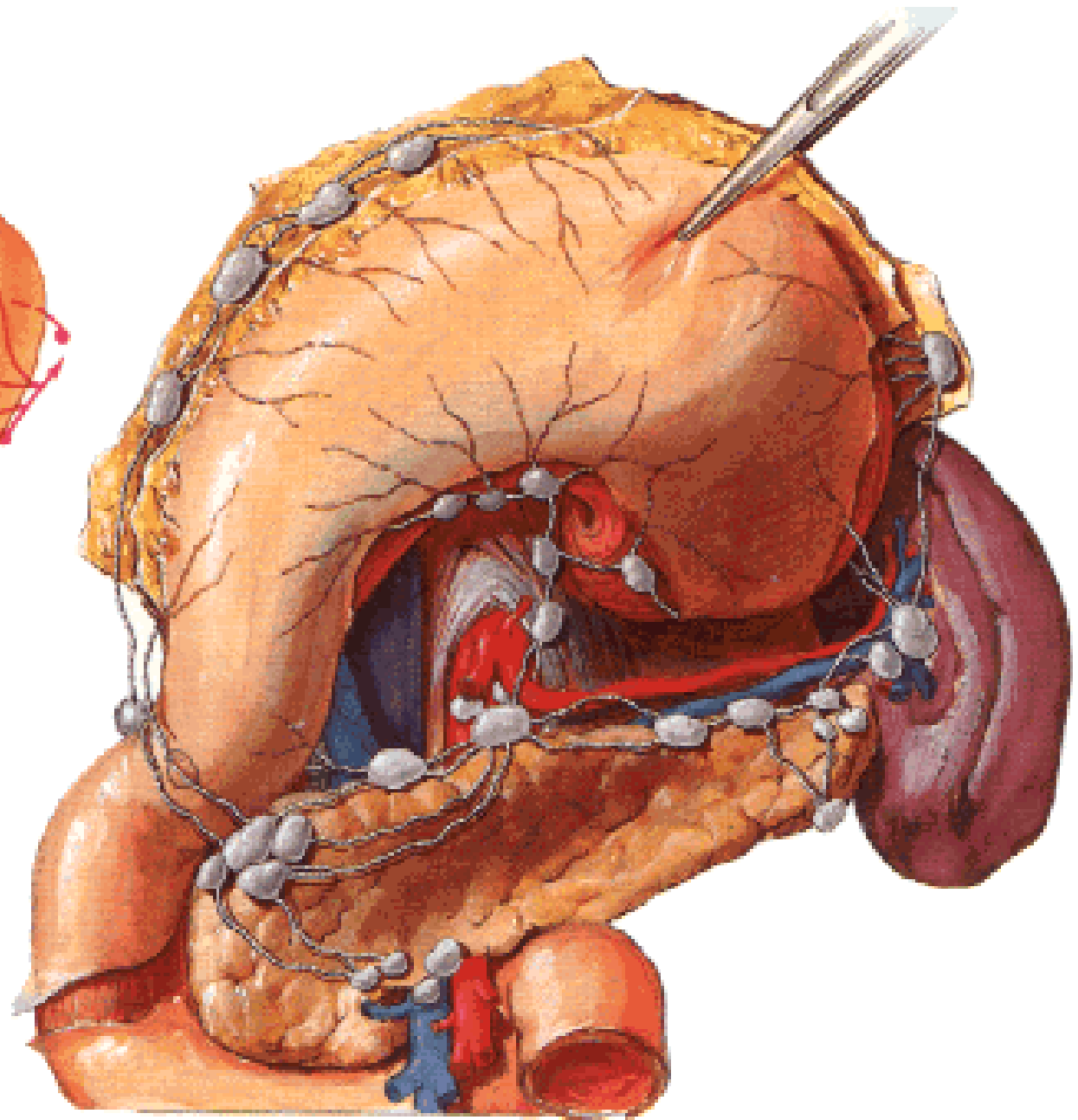
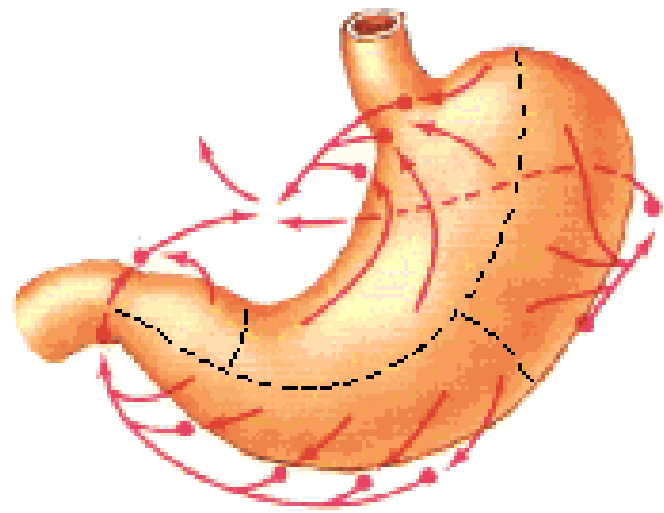


truncus intestinalis

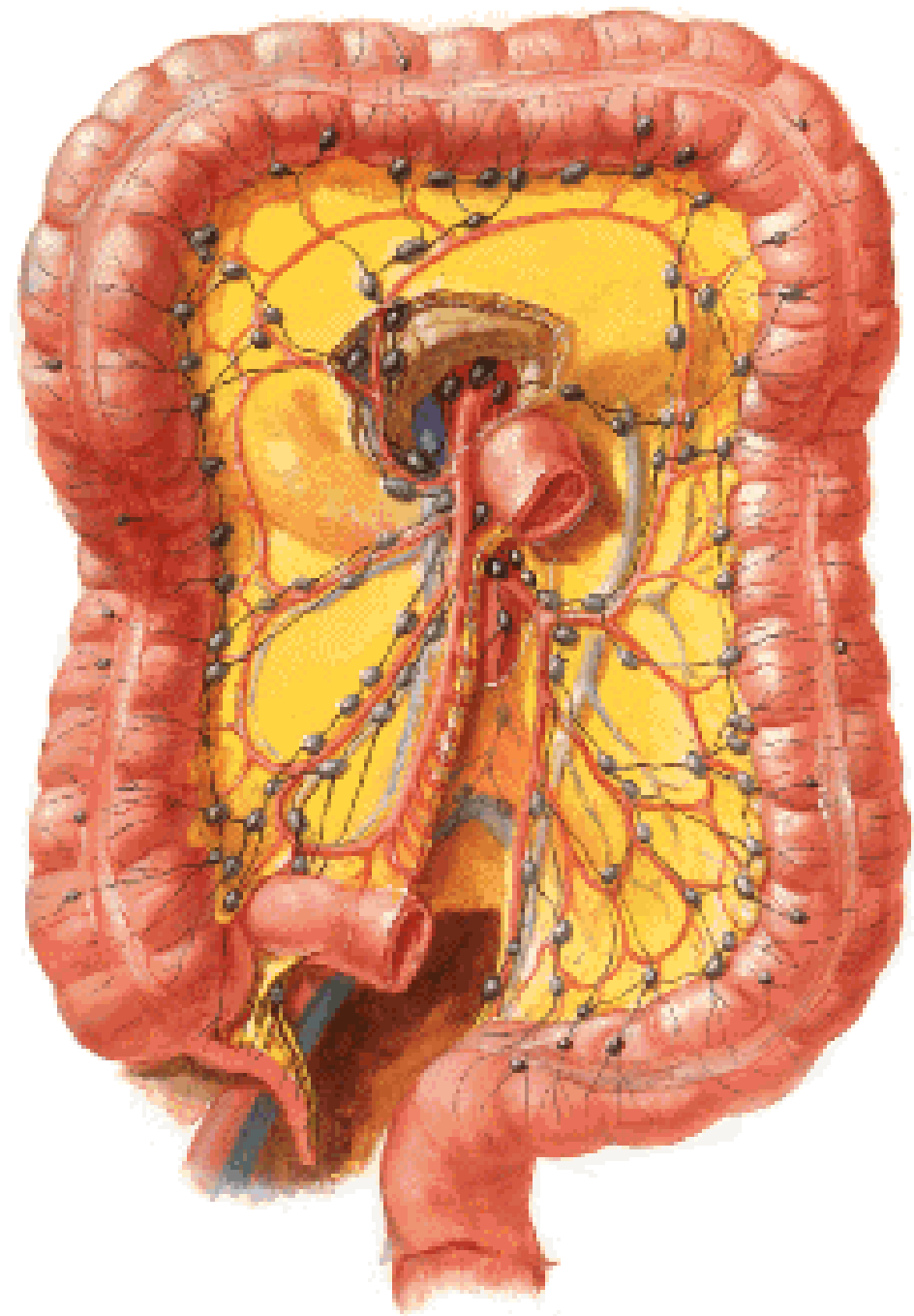
nodi lymphatici coeliaci

- gastrici
- gastroepiploici
- hepatici
- pancreaticoduodenales
- pancreatici
- lienales
- mesenterici
- ileocolici
- colici
- mesenterici inferiores

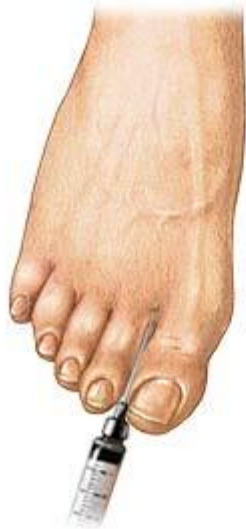







# Lymphography



Blue dye is injected  
between the toes  
into the webbing

