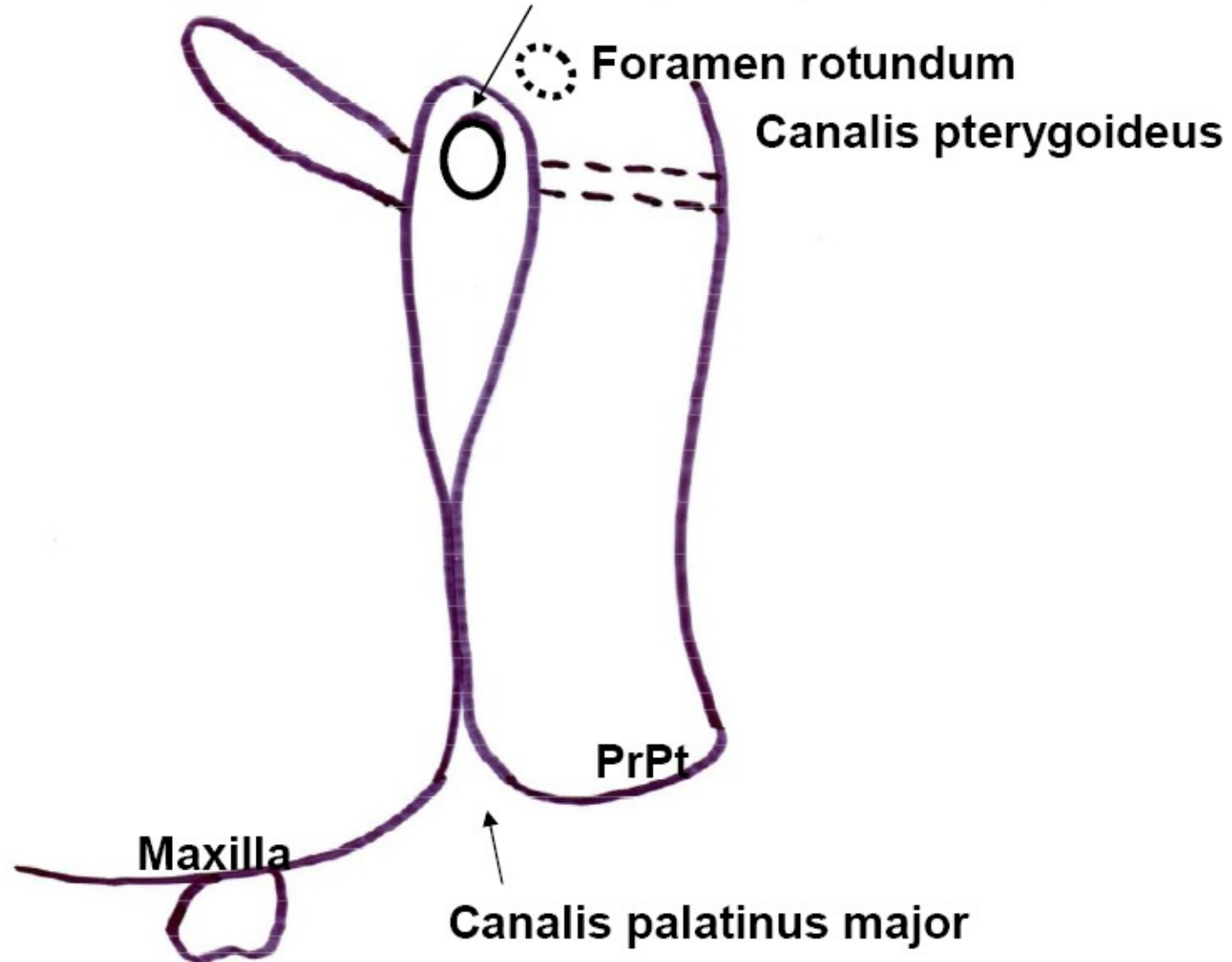


Pterygopalatine fossa from the lateral side

Fissura orbitalis inferior **Foramen sphenopalatinum**



Branches of maxillary artery in the pterygopalatine fossa

