

Fractures



Authentic medical reports



Dg:

S8220 Fr. cruris l.sin cum fr.fibulae duplex disloc.aperta TII-III
stp. OS FE 17.7. 2010
V2331 Mot.x auto,;zra.při nás.,vys.;volný čas
S730 Luxatio coxae l.sin centralis stp. repositionem 17.7.
S332 Luxatio art. SI l. sin stp. reposit. 17.7.
S3240 Fr. acetabuli l.sin transv.disloc. stp. OS 19.7.
S818 Decollement partis proximalis cruris l.sin.
S711 Vulnus lacerum reg. femoris l.sin.

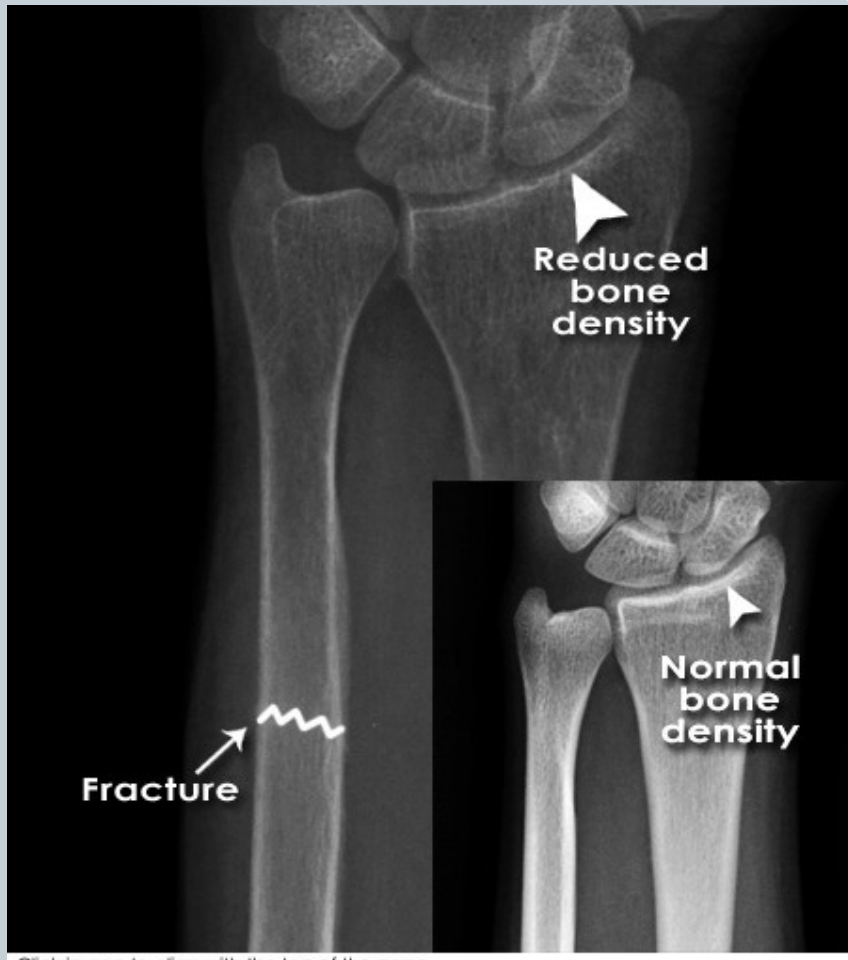OPERACE:

Datum:17.07.2010 21:00

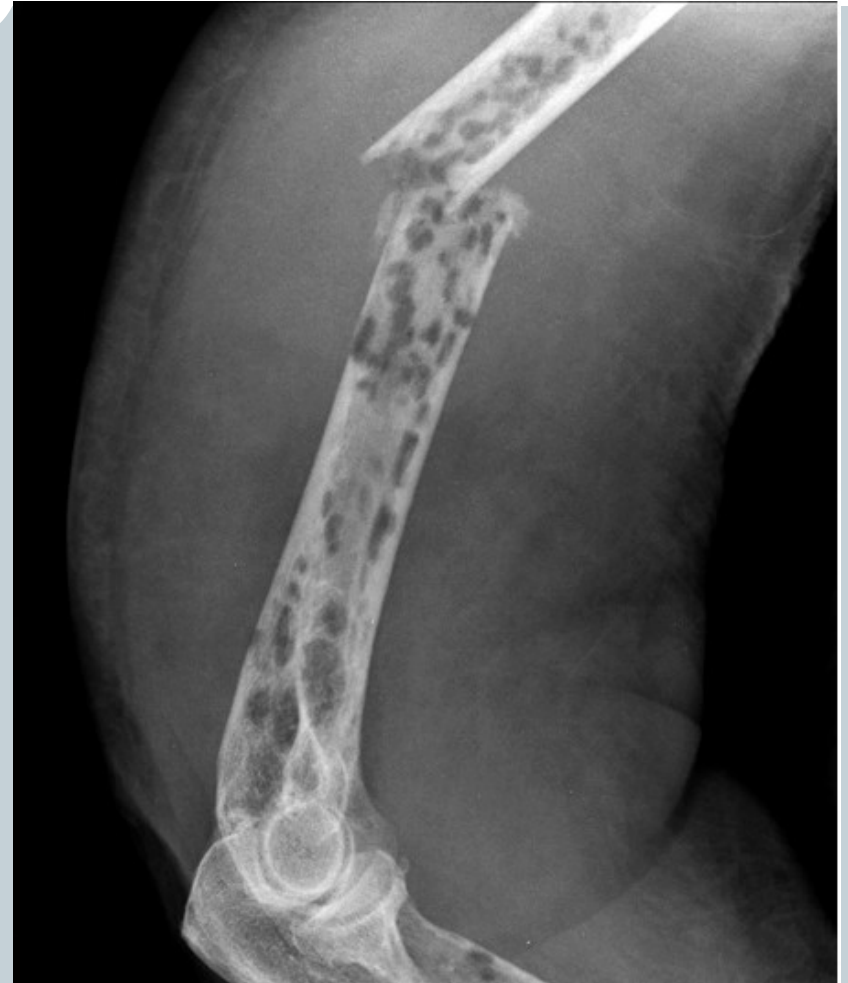Dg :S8221 Fract. cruris l.sin. aperta gr. II, Fr. acetabuli l. sin.
Debridement měkkých tkání, Zevní fixace na zlomeninu tibie, laváž,repozice
zlomeniny acetabula vlevo,Ki-extenze-za femur Pacient s otevřenou
zlomeninou levého bérce II. st., decollement
prox.poloviny bérce a kolenního kloubu, dislokovaná zlomenina acetabula
vlevo, leze SI kloubu - typ B - zadní vaz drží - vlevo
Urgentní operační výkon, pac. navezen přímo z OUP.

collement = severe damage of soft tissues

Fractura pathologica

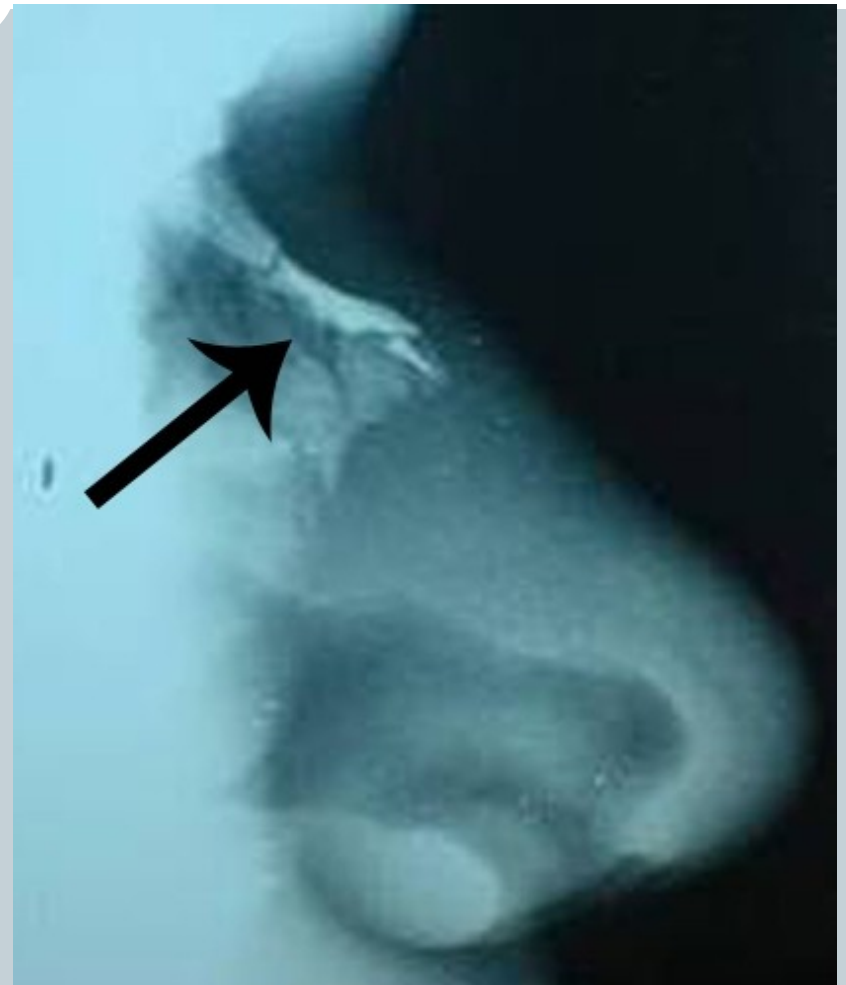
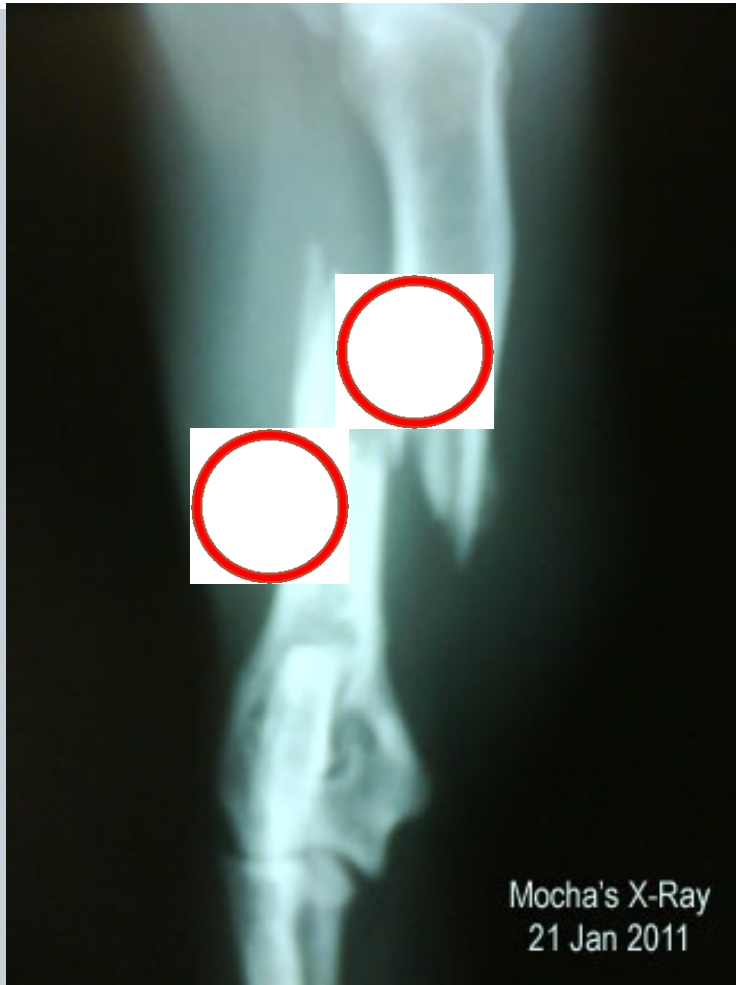

Click image to align with the top of the page

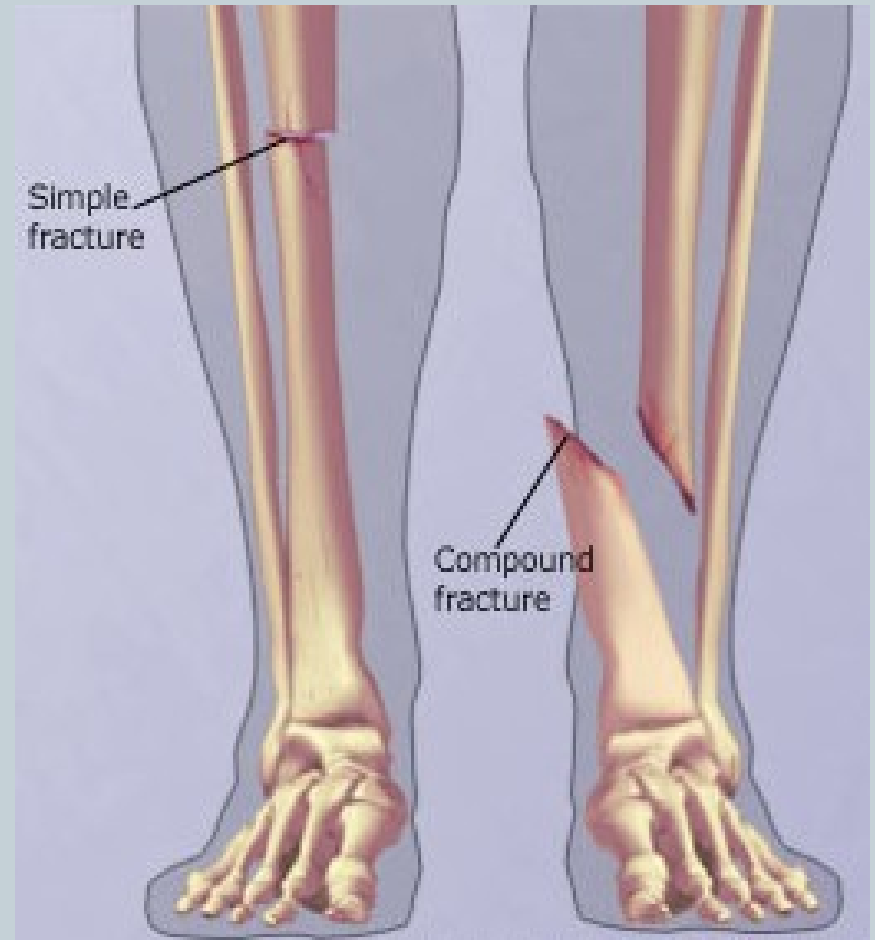
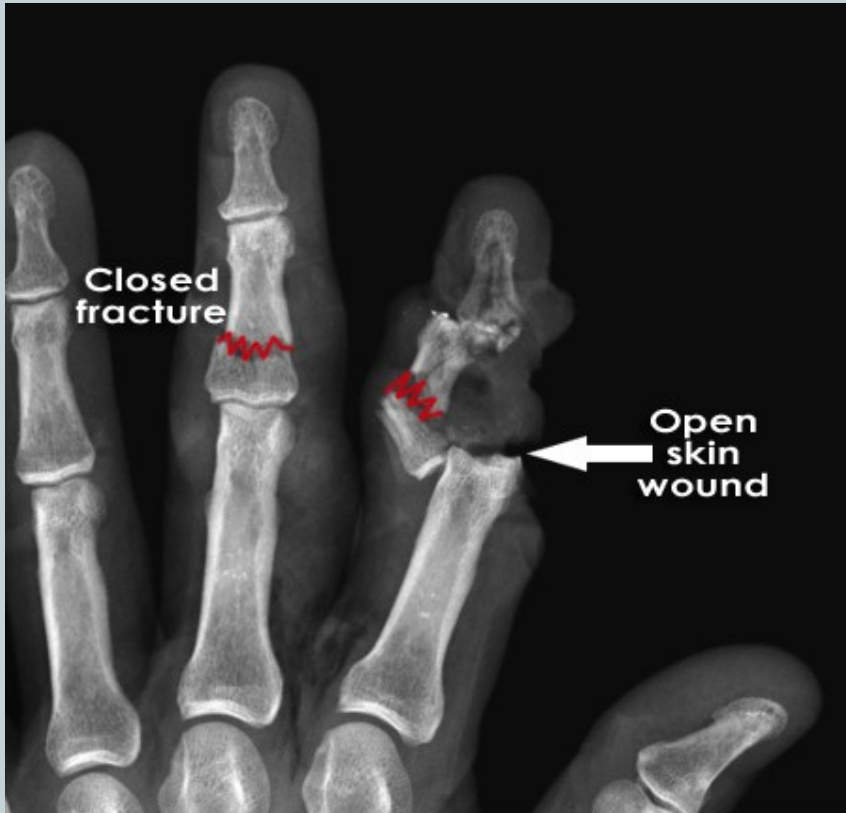

Myeloma -The plasma membrane of a muscle fiber

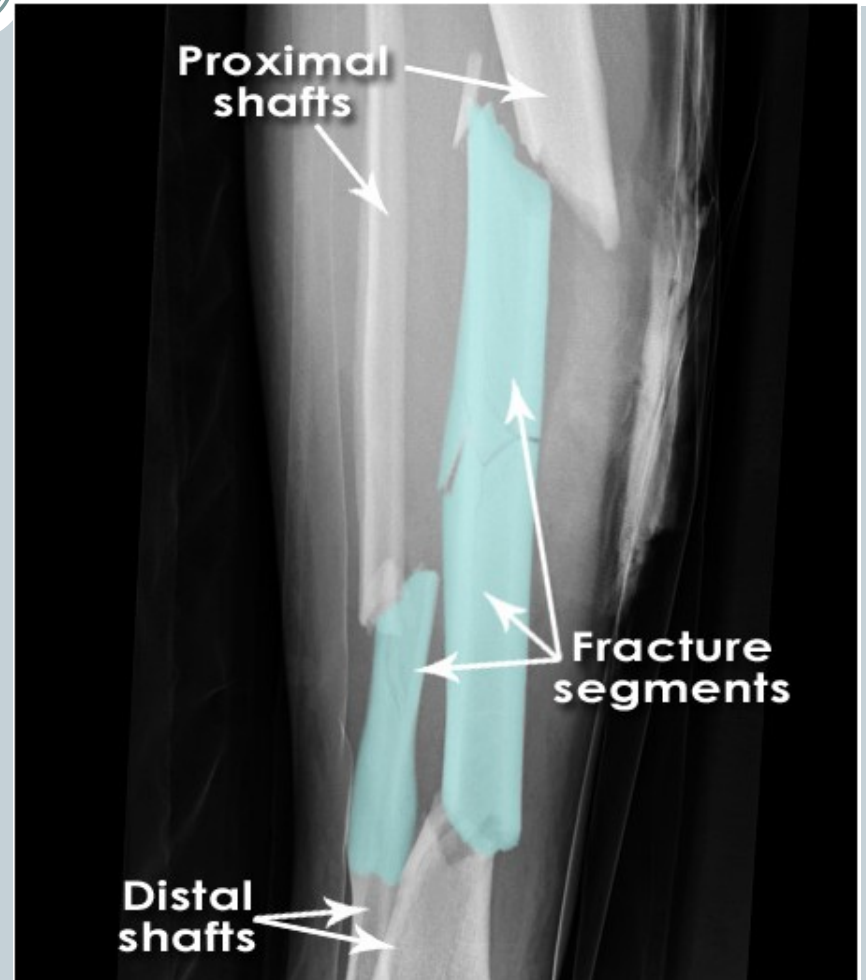
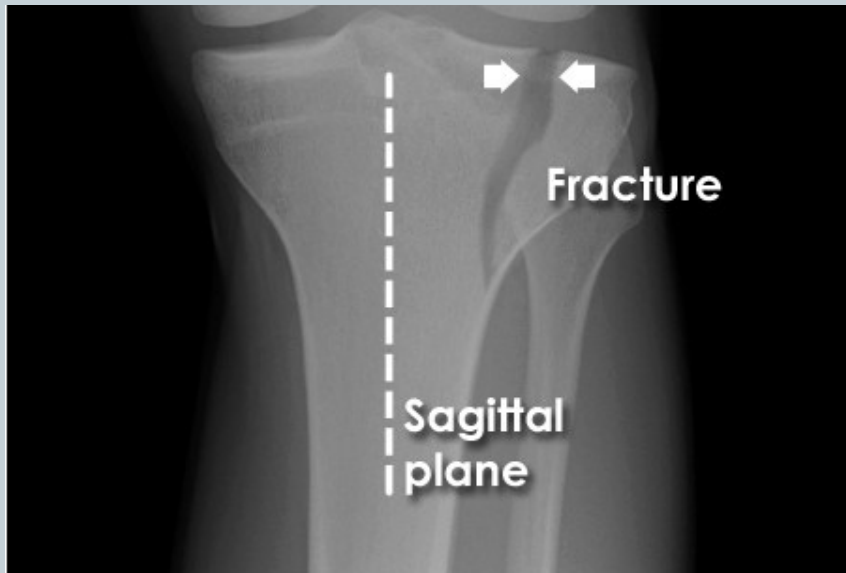
Fractura traumatica



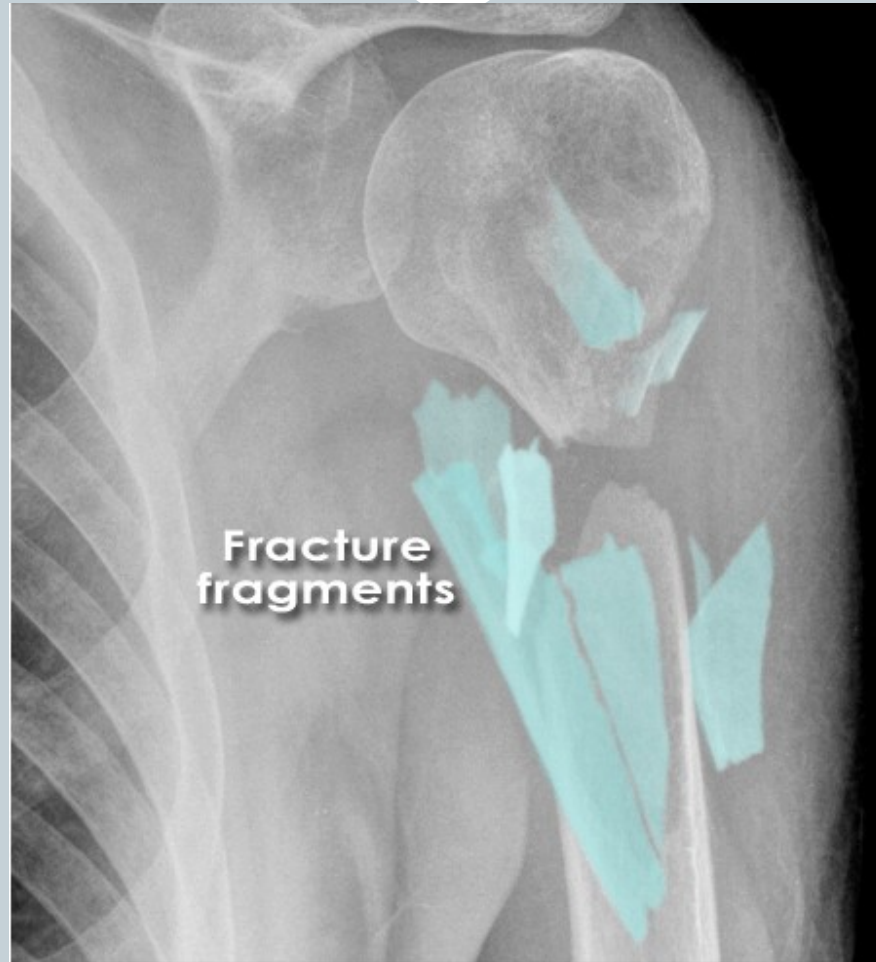
Fractura aperta/clausa



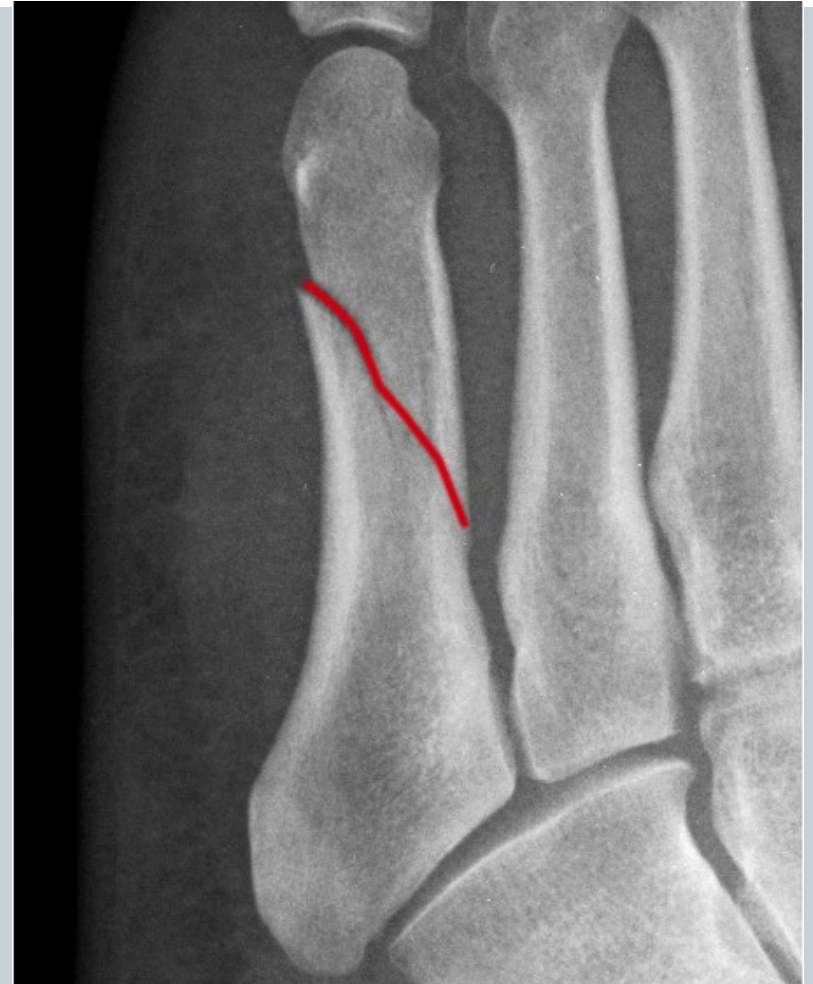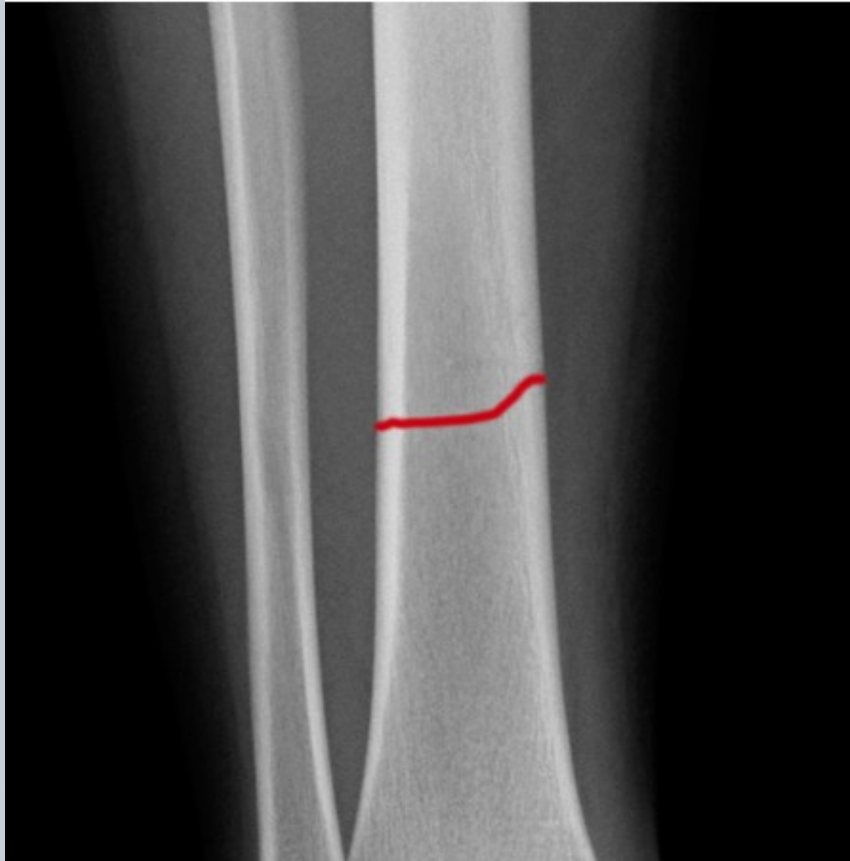Fractura simplex/multiplex



Fractura comminutiva



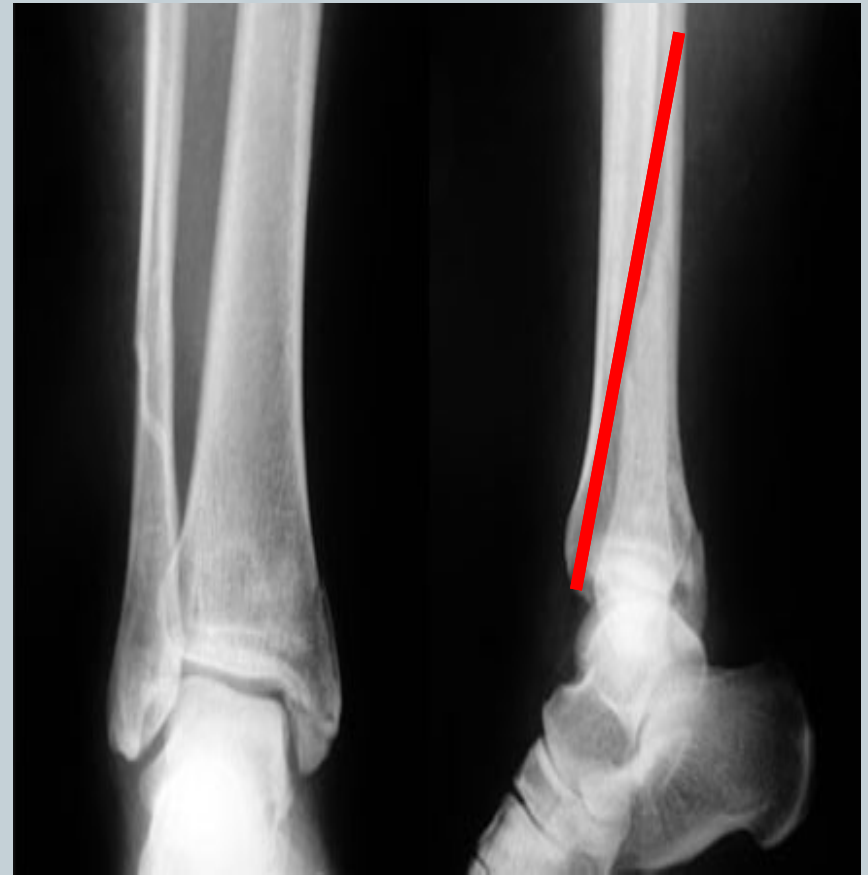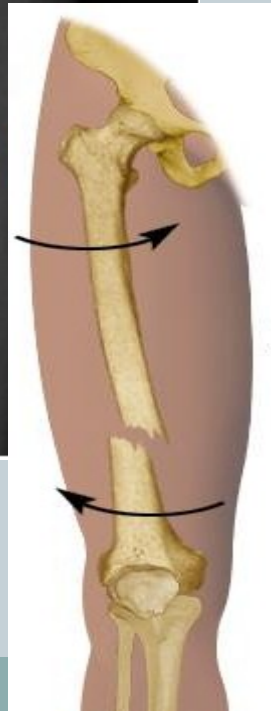
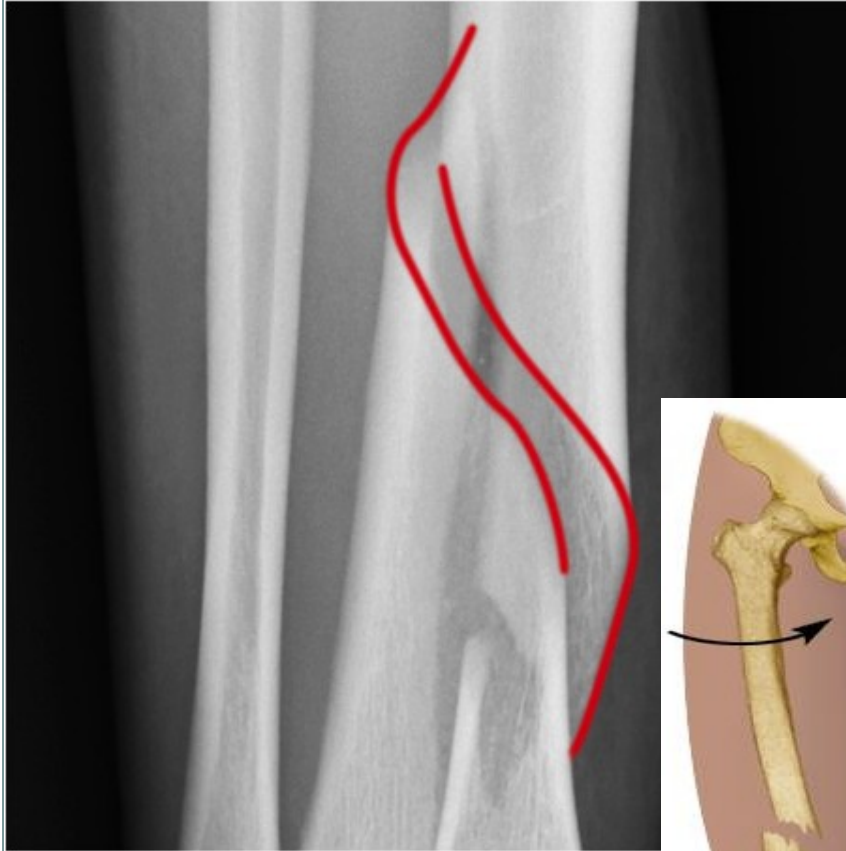
Fractura transversa/obliqua



Fractura spiralis

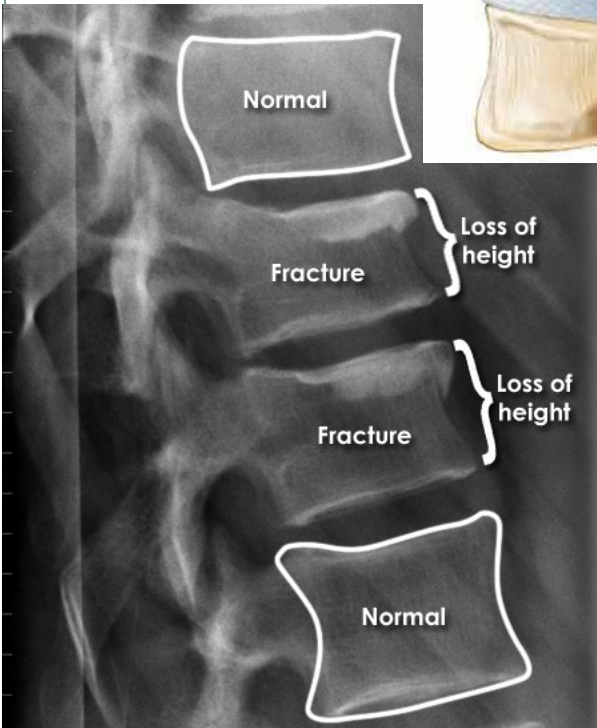
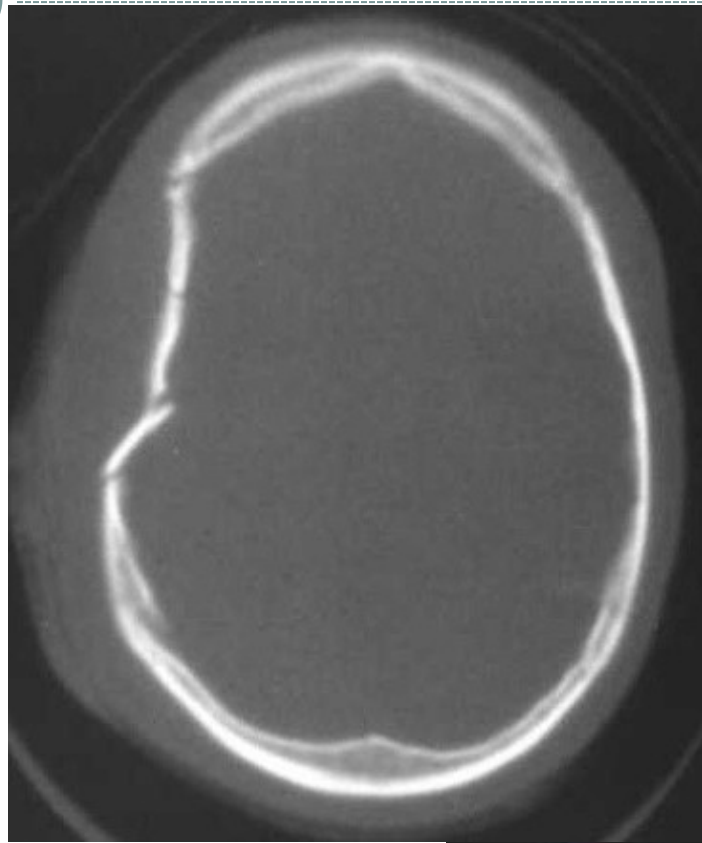
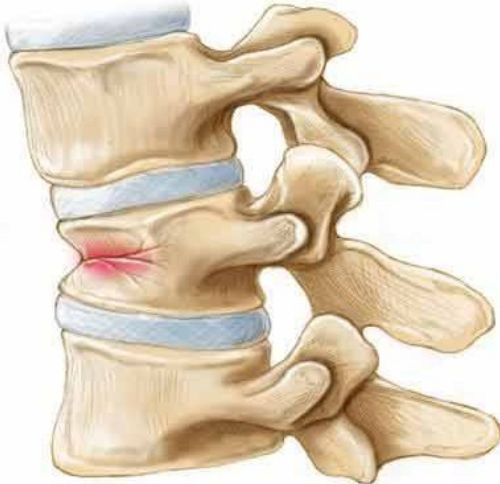/

longitudinalis

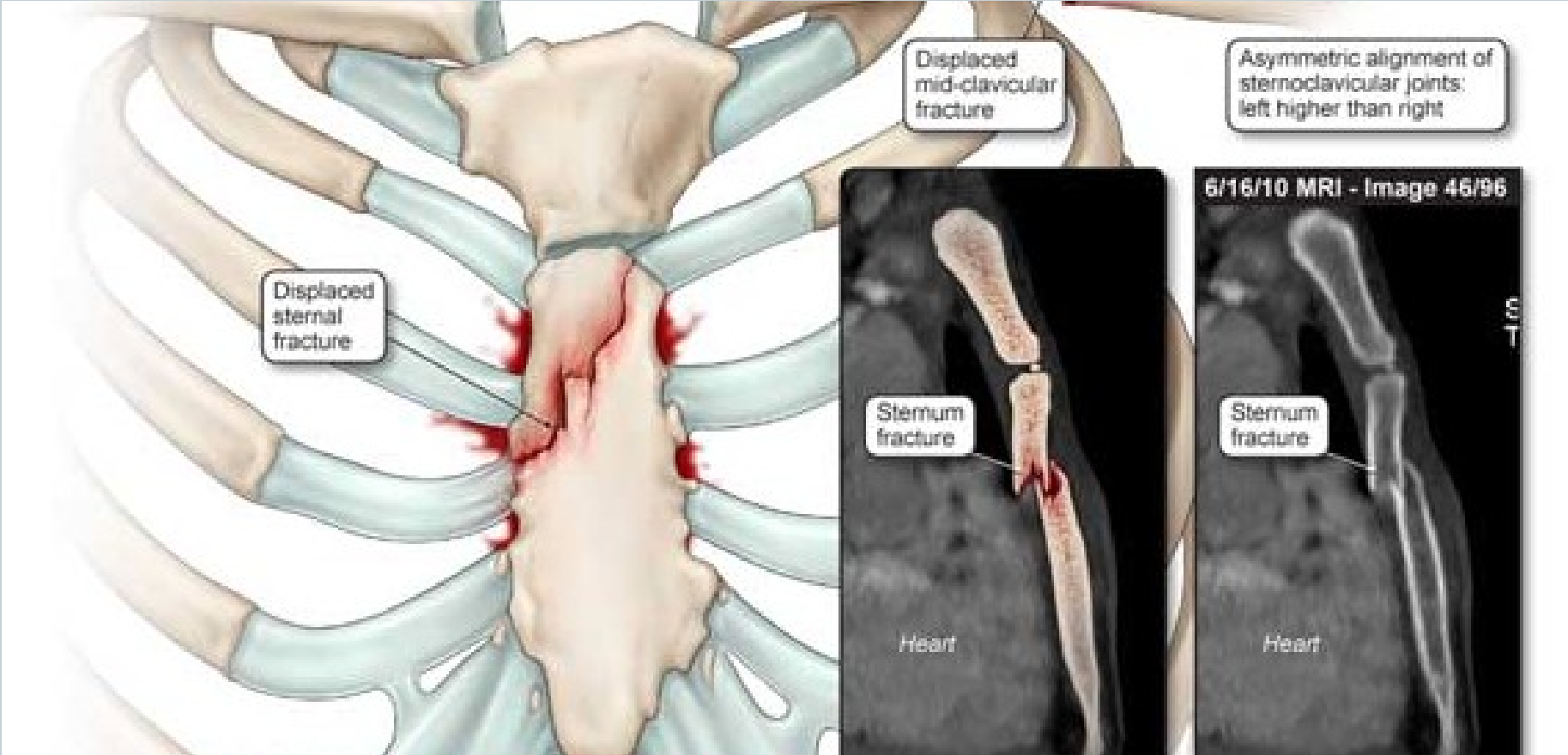


Fractura compressiva

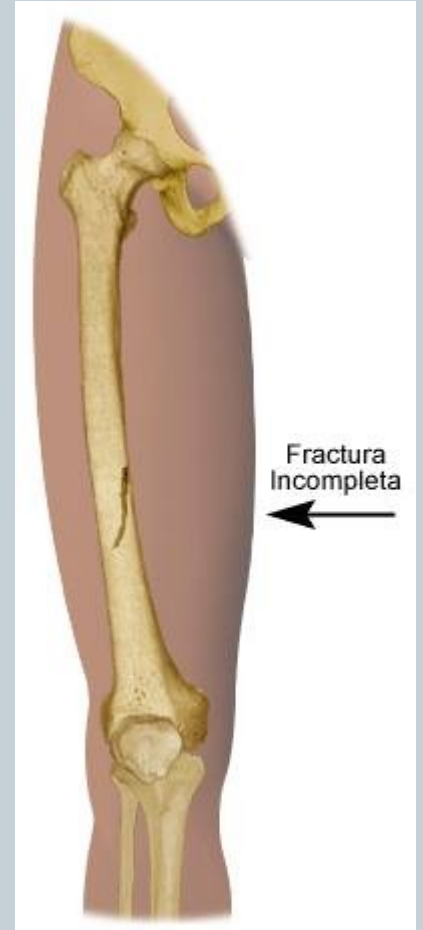
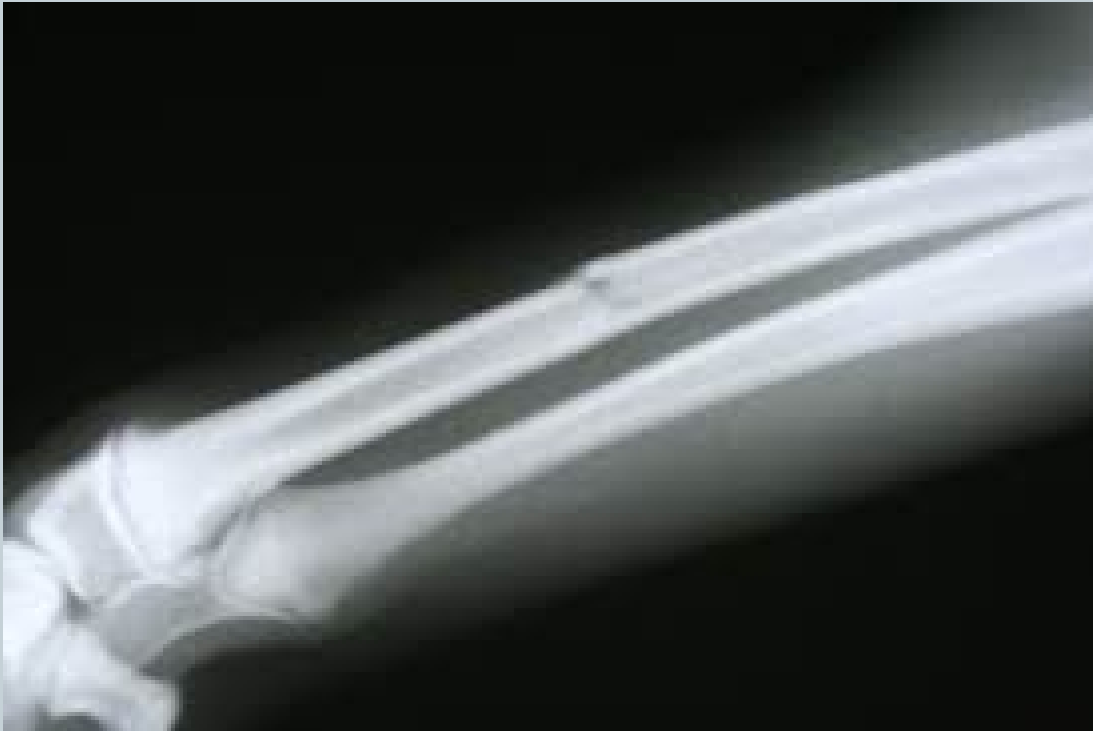/ impressiva



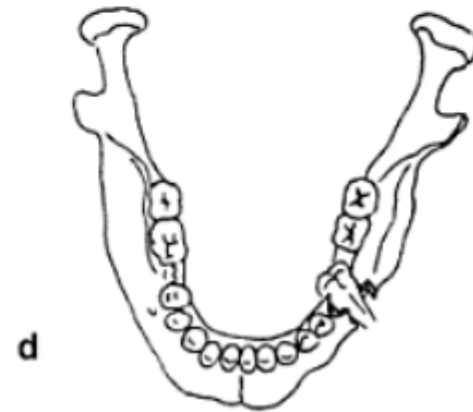
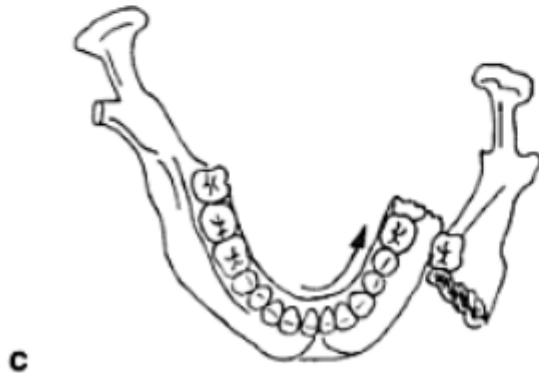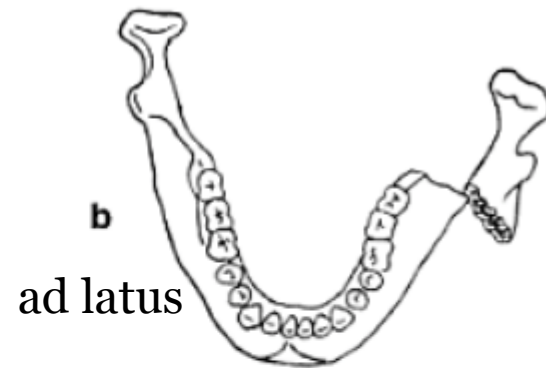
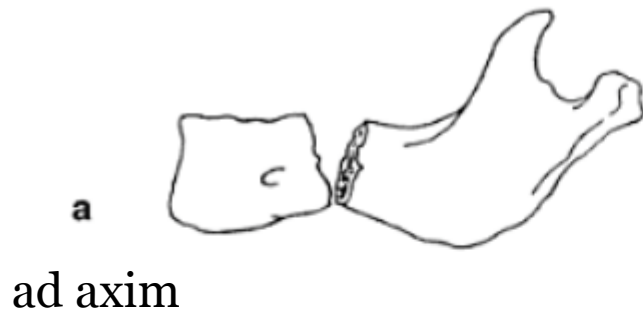
Fractura incuneata



Infractio = f. partialis = f. incompleta



Fractura cum dislocatione

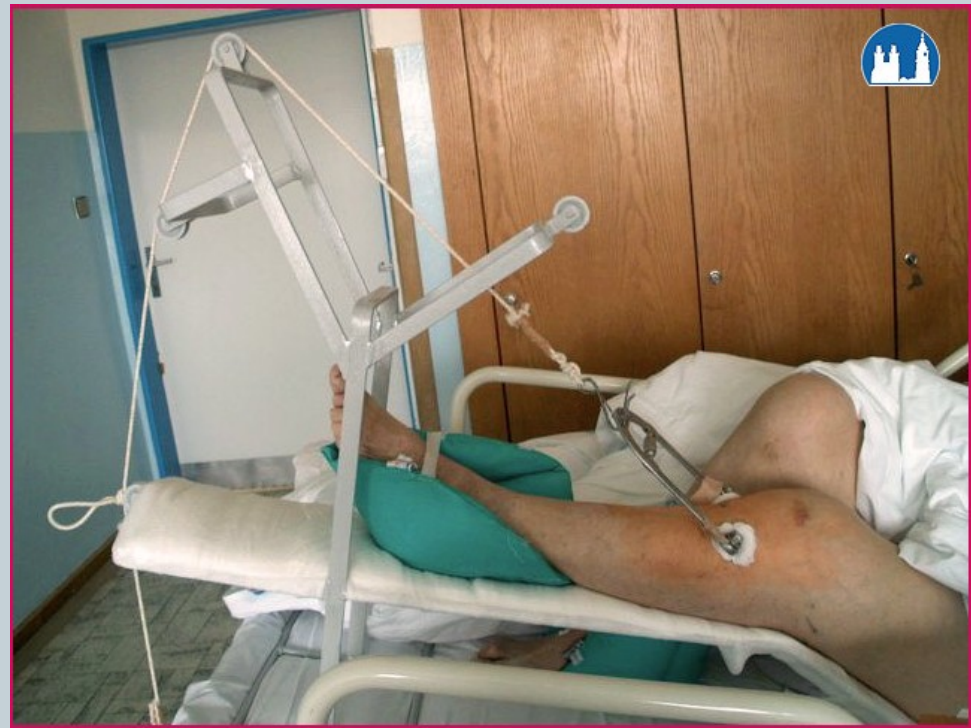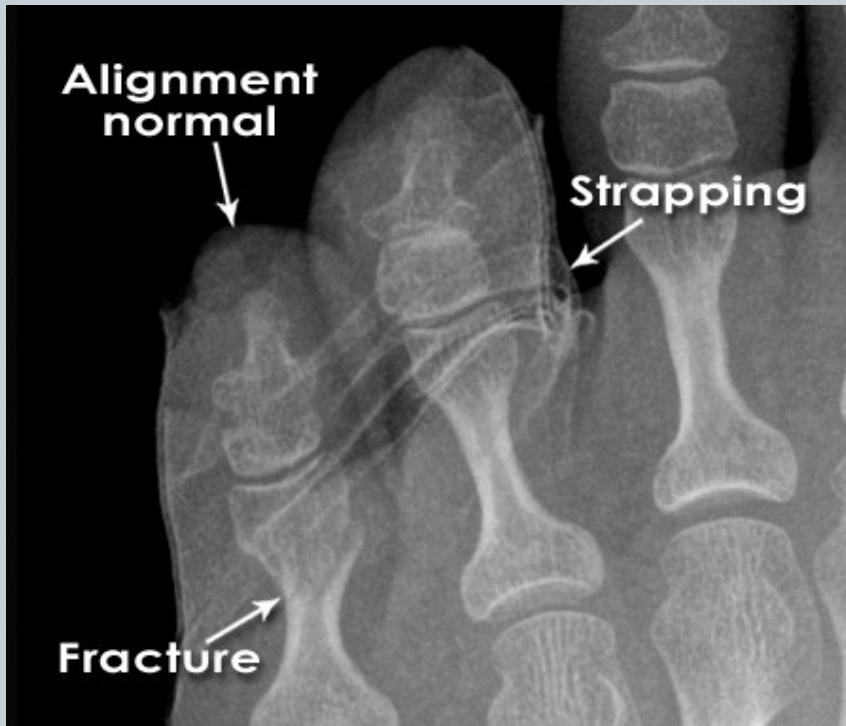


ad longitudinem cum contractione ad longitudinem cum distractione

Fracture Healing:

1: REPOSITIO = REDUCTIO fragmentorum

CLOSED (short /long term)

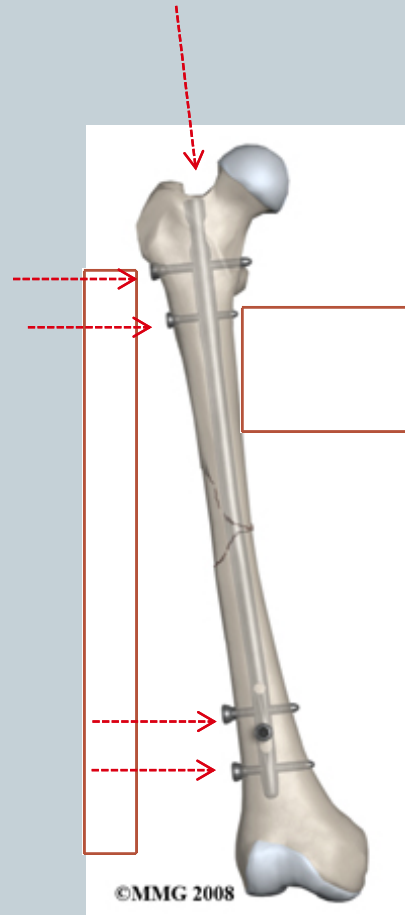
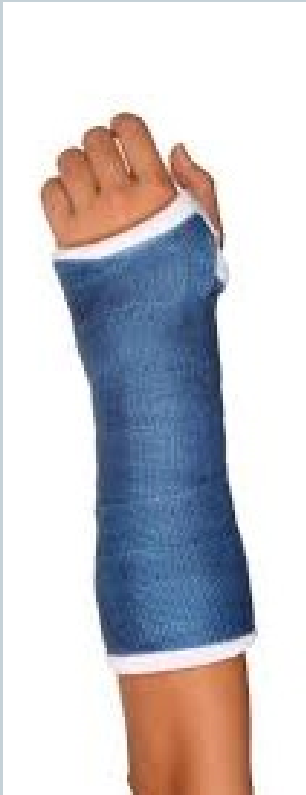

Fracture Healing:

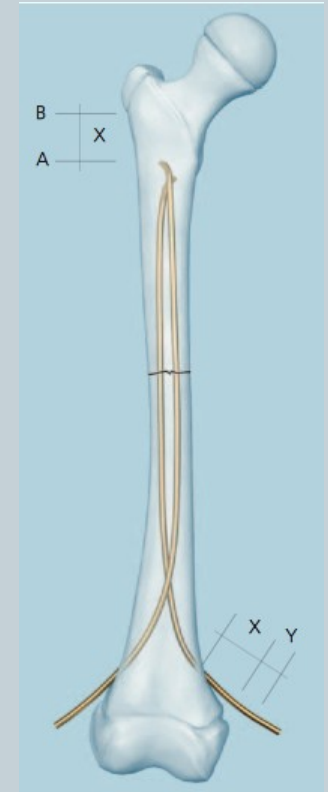
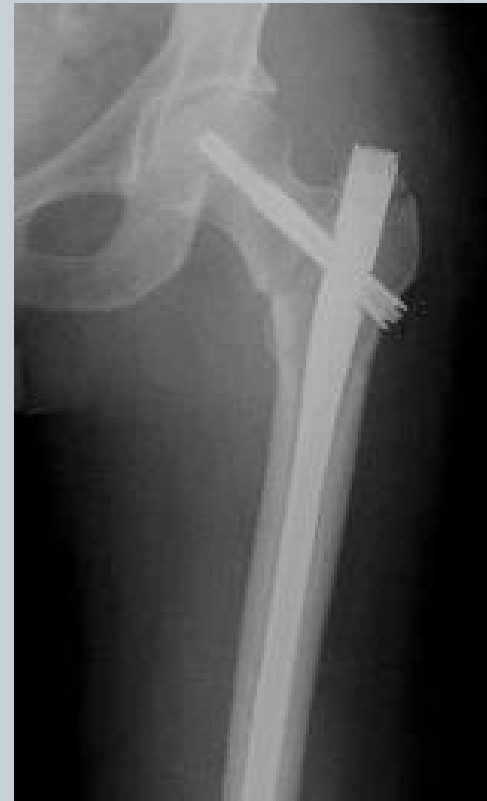2: FIXATIO = STABILISATIO fragmentorum



PLASTER CAST



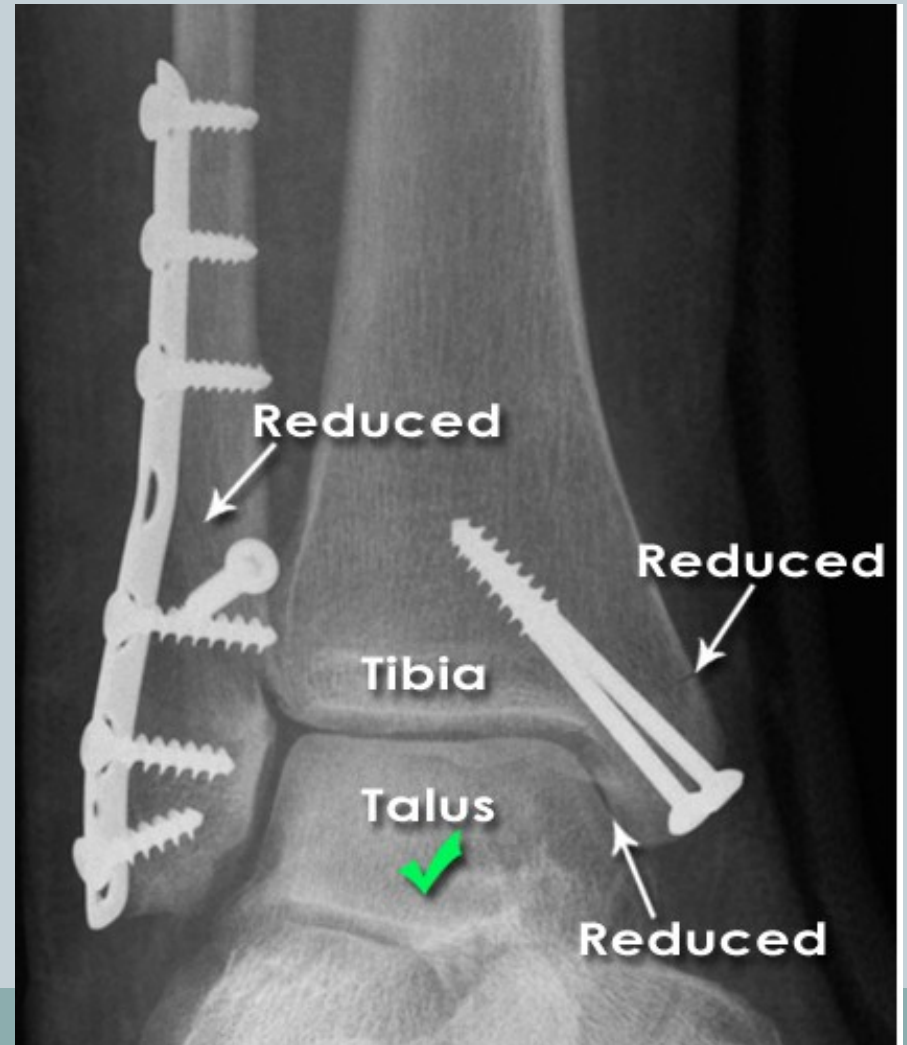

INTERNAL FIXATION



Fracture Healing:

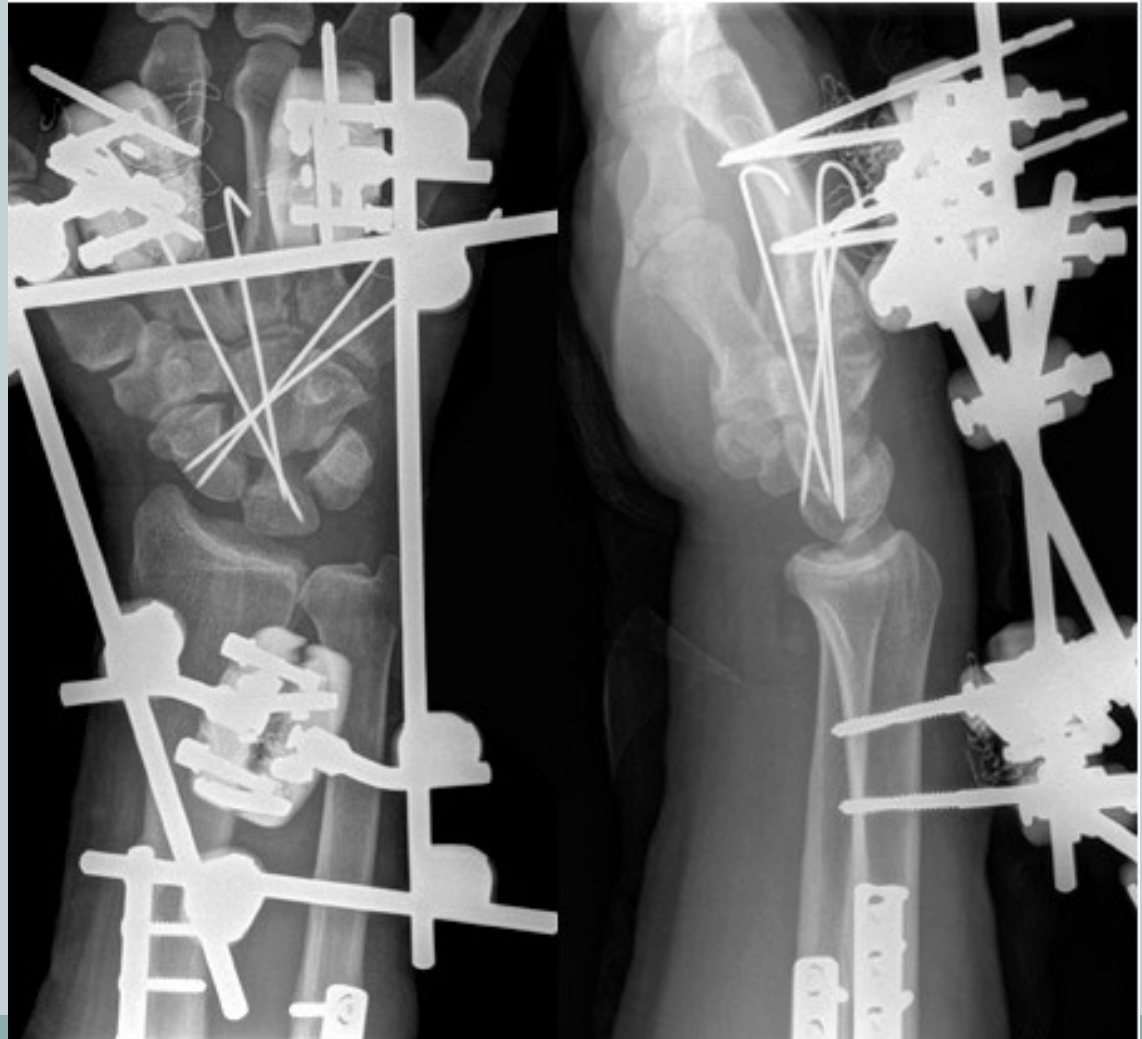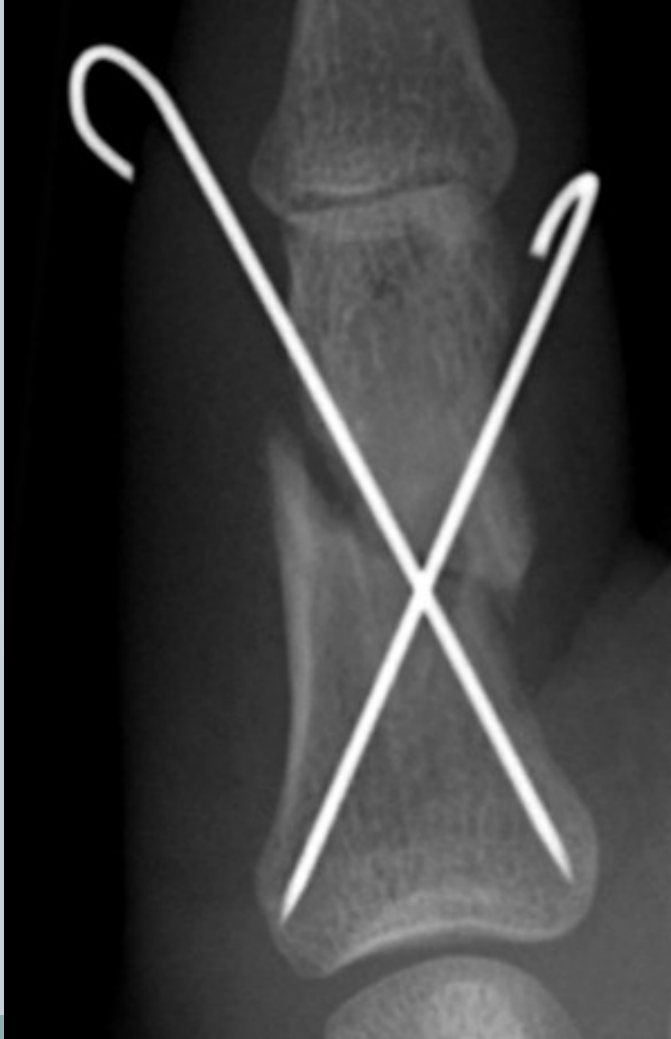2: FIXATIO = STABILISATIO fragmentorum

INTERNAL FIXATION

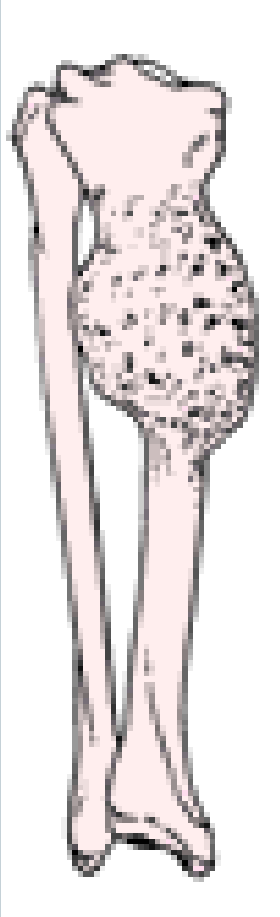


Fracture Healing:


2: FIXATIO = STABILISATIO fragmentorum




Name the type of fracture




A



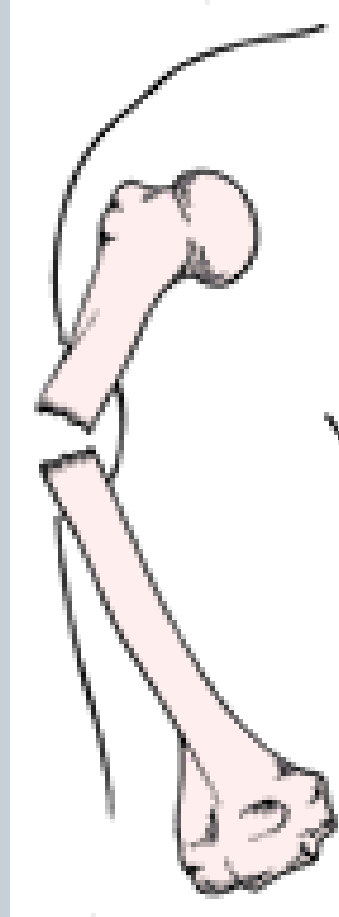B



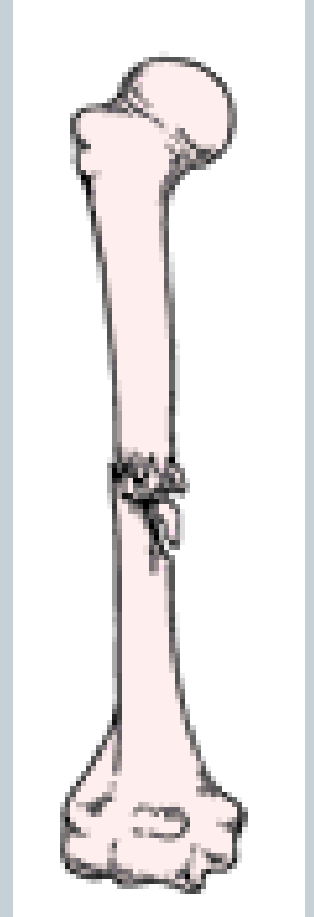
C



D



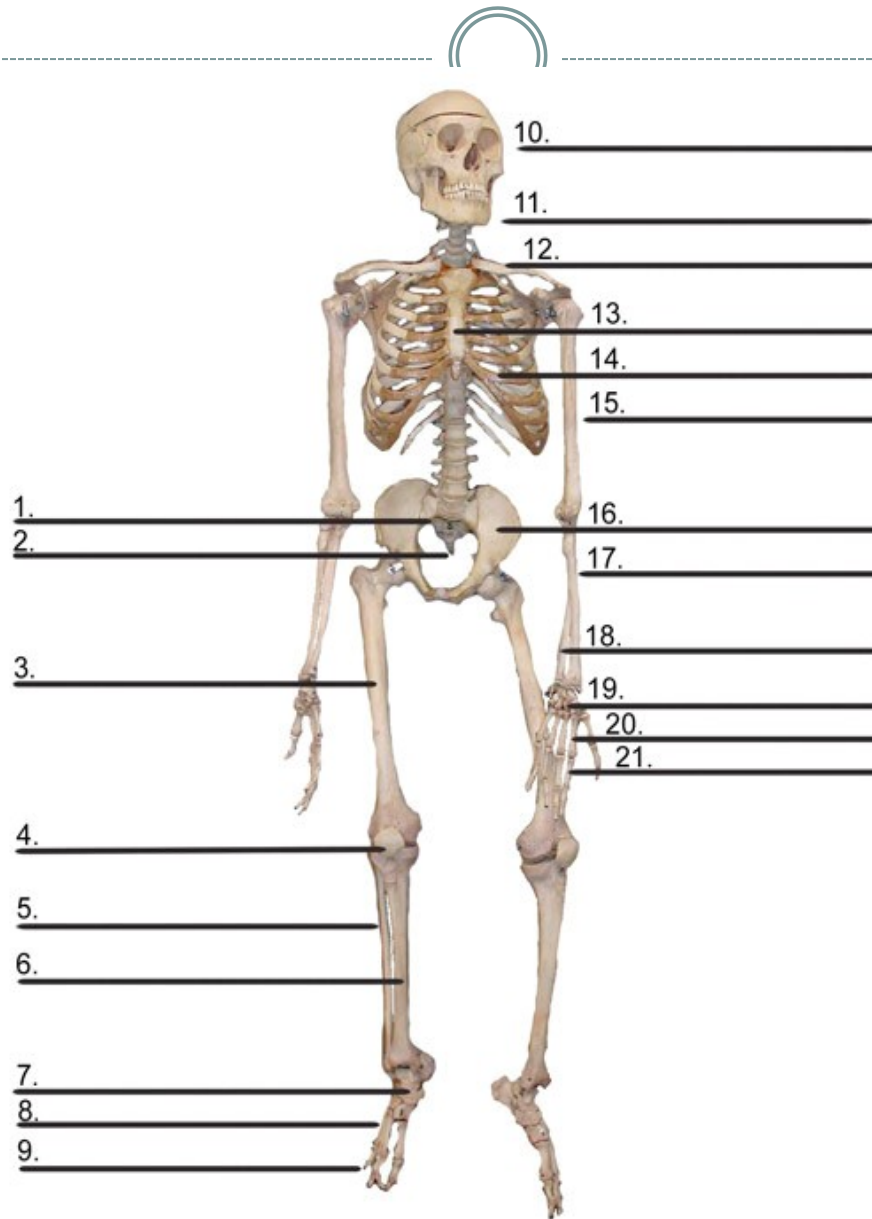
E



F

A) Name different bones of the human body

B) Write down different types of fractures of named bones

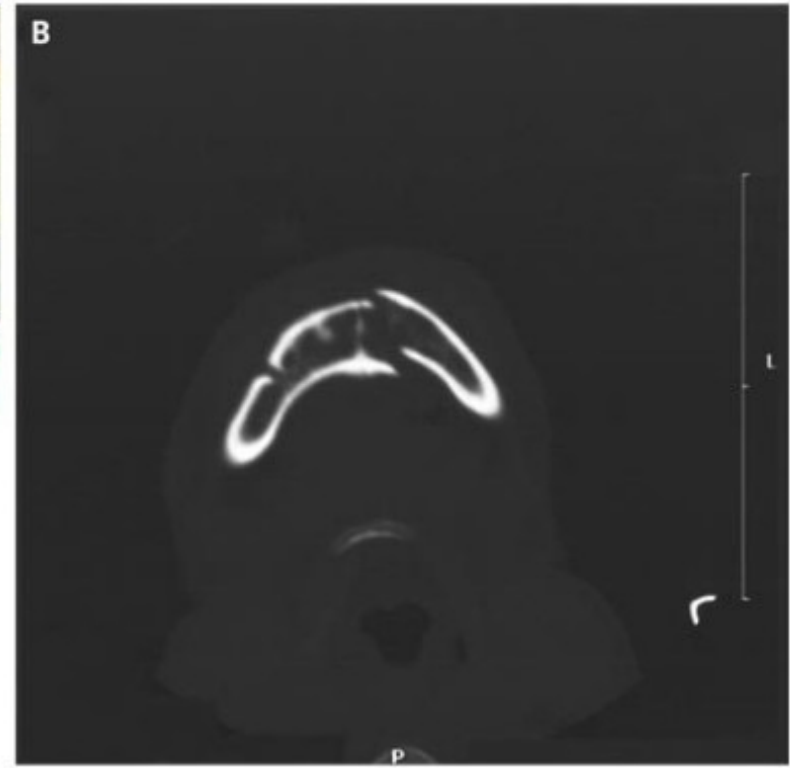
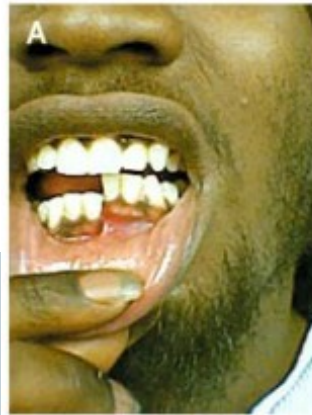

3

A 21-year-old man presented after being struck with a gun on his right lower jaw.

Examination revealed displacement of the

left half of his mandible with malocclusion on biting (Panel A). Computed tomography showed a **fracture of the left mandible and a fracture of the right mandibular body and angle** (Panel B). Given the U shape of the mandible, it is common for contralateral fractures to result from major injury. Intravenous analgesics and antibiotics were given; the patient underwent *open reduction with internal fixation of his fractures*.



Literature



- Mazánek, J.: Traumatologie orofaciální oblasti. Praha : Grada, p. 24
- <http://radiologymasterclass.co.uk>
- <http://anthropology.si.edu>
- <http://nejm.org> (The New England Journal of Medicine)