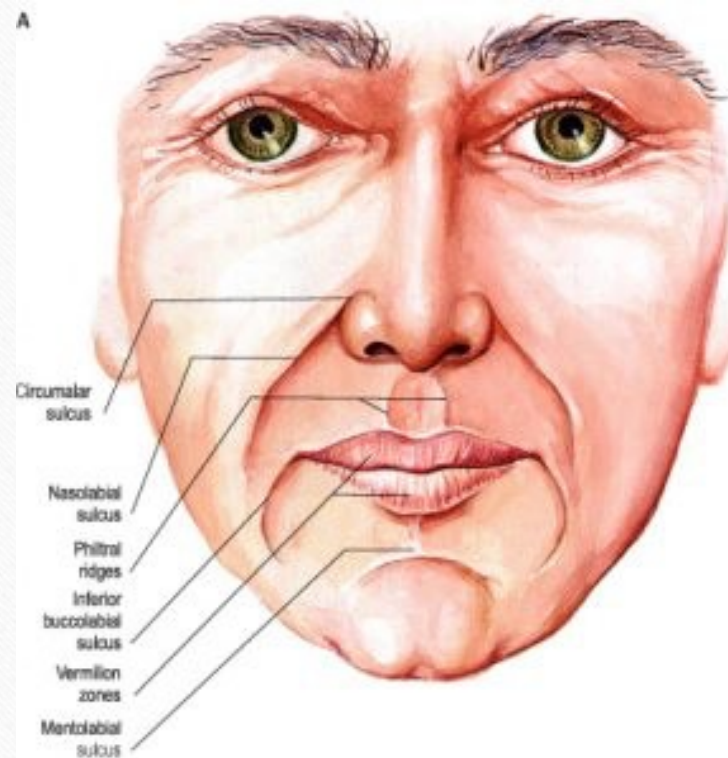


Facial Expressions

By: Loucas Hadjiconstantis

Yiannis Pistolas

- **facies, faciei, f.** - face; expression, countenance (typical of a certain disease or state)



Terms referring to healthy or pathological state:

- • **f. composita** - “normal, natural face”, i.e. composed, regular face of a healthy person
- • **f. dolorosa** - facial expression of a person suffering from pain
- • **f. febrilis** - feverous face expression, i.e. restless, discomposed characterized by shiny eyes and redness in face
- • **f. plethorica** - hyperemic face with florid, red complexion due to excessive circulation of blood

Facies composita



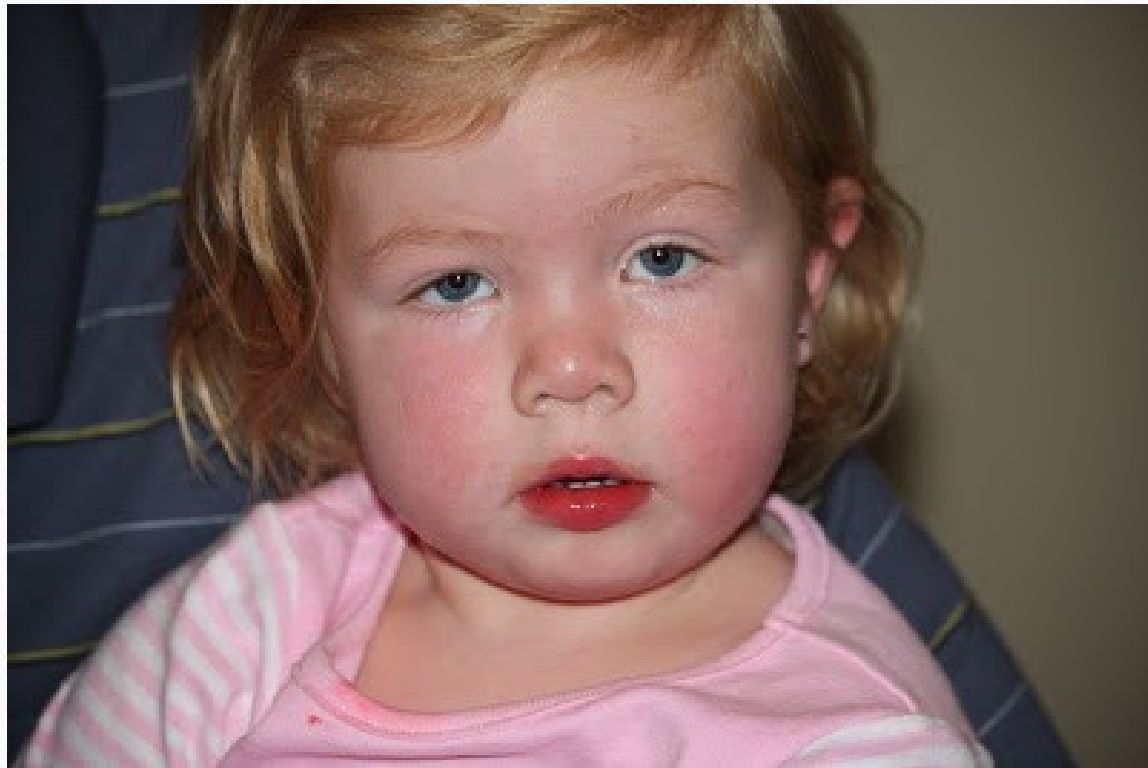Normal, natural face.

Facies dolorosa



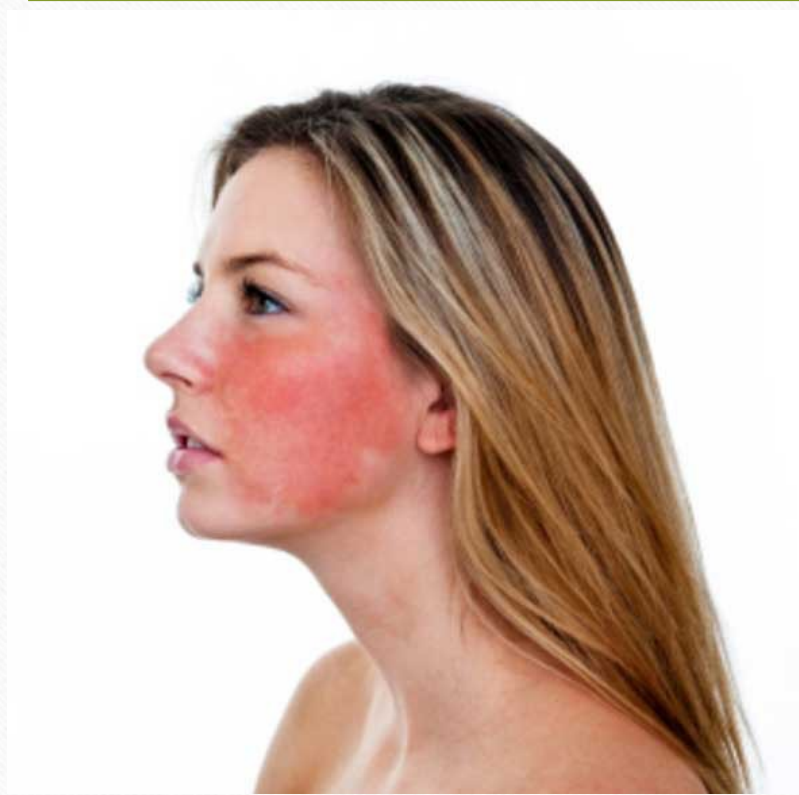Person suffering
from pain.

Facies febrilis



Feverous face
expression.

Facies plethorica



Hyperemic face
with florid, red
complexion.

Terms referring to a certain disease/ dysfunction of a certain organ:

- **f. alcoholica / aethylica** - bloated, persistently red face as a consequence of excessive drinking
- **f. pneumonica** - one-sided blush on the same cheek as the lung affected by pneumonia
- **f. nephritica** - oedematous, pale face due to the inflammation of kidneys with swelling appearing most around eyes
- **f. cardiaca** - oedematous, pale, and yellowish face with cyanotic hue; half open mouth, cyanotic lips; typically accompanies heart failure

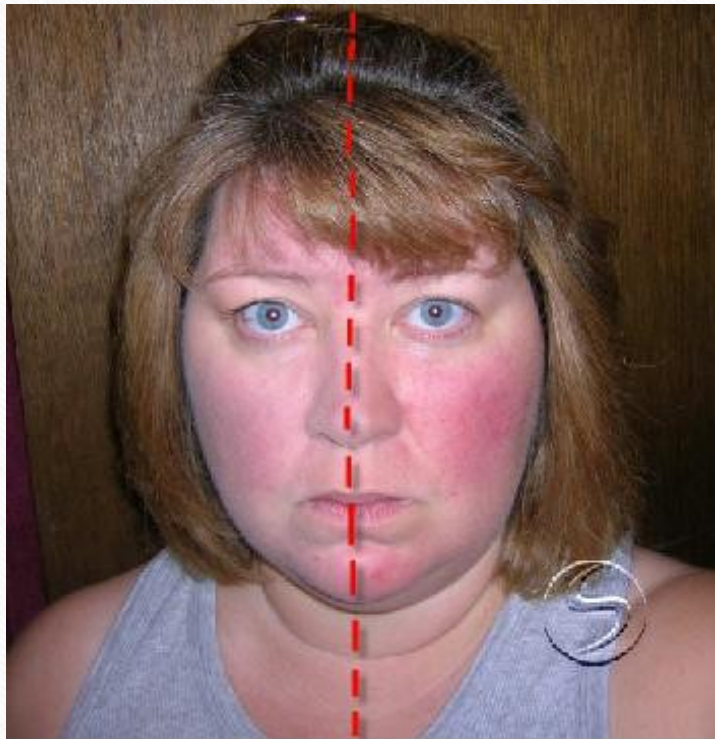- **f. anaemica** - very pale face with greenish tint in patients with iron deficiency
- **f. mitralis** - blush on cheeks, cyanotic tip of the nose and ears; the patient looks younger his/her age; typical of patients with mitral stenosis
- **f. gastrica** - facial expression typical of acute stomach problems; deep nasolabial fold
- **f. tuberculosa / hectica** - exhausted, pale face with blush on cheeks, “burning” eyes, dry lips, excited countenance, half open mouth
- **f. morbillosa** - “unhappy” facial expression with rash and reddened eyes sensitive to light; typical of children suffering from measles
- **f. syphilitica** - melancholic facial expression with saddle nose deformation; typical of the patients having the late congenital syphilis (*syphilis congenital tarda*)
- **f. tetanica / risus sardonicus** - facial expression typical of tetanus patients; mouth widened as in laughter, but the skin on forehead as if expressing grief; tonic spasm of mimic and chewing muscles
- **f. leontina** - the lion-like facial appearance occurring in patients with certain forms of leprosy

Facies alcoholica / aethylica



Bloated,
persistently
red face.

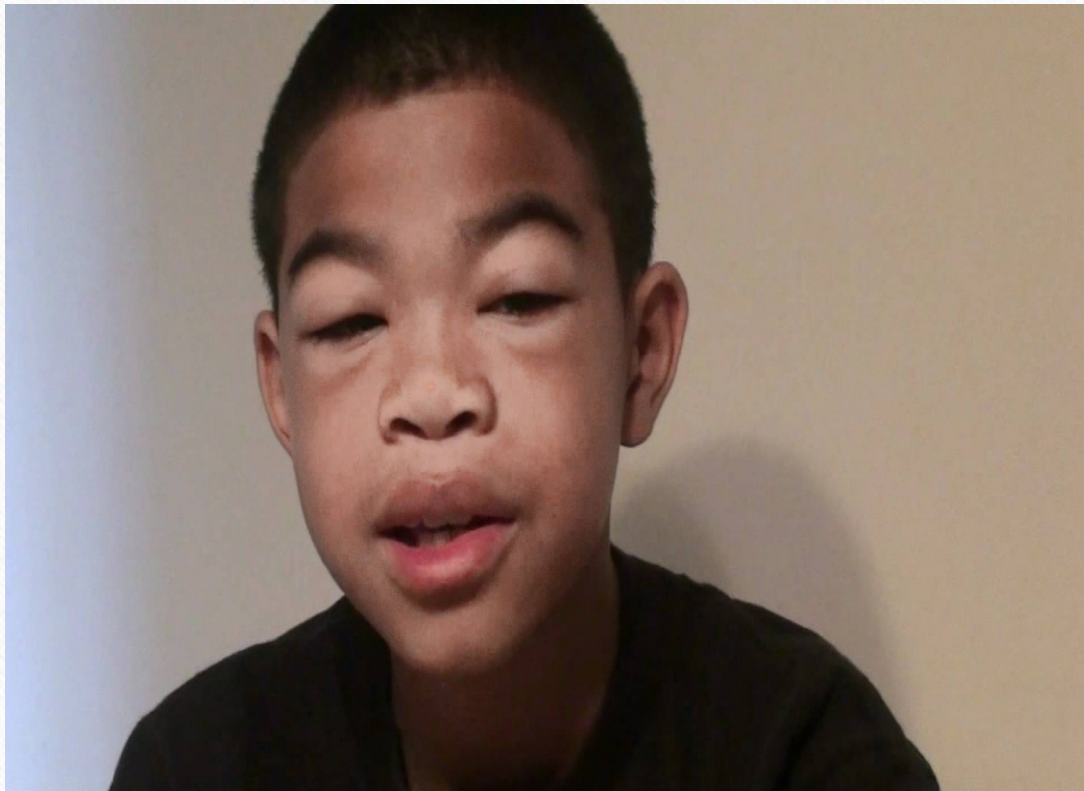Facies pneumonica



Hall - face, hair, forehead, and neck making up

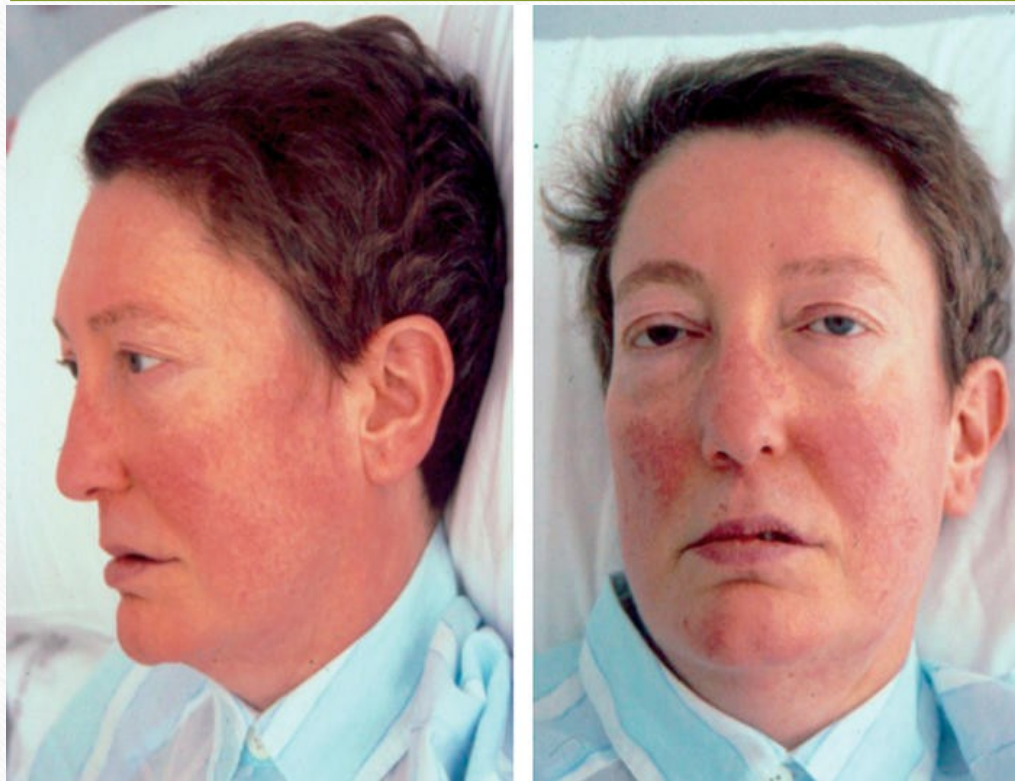One-sided blush on the same cheek as the lung affected by pneumonia.

Facies nephritica



Oedematous, pale face with swelling appearing most around eyes.

Facies cardiaca




Oedematous, pale, and yellowish face with cyanotic hue; half open mouth, cyanotic lips.

Facies anaemica



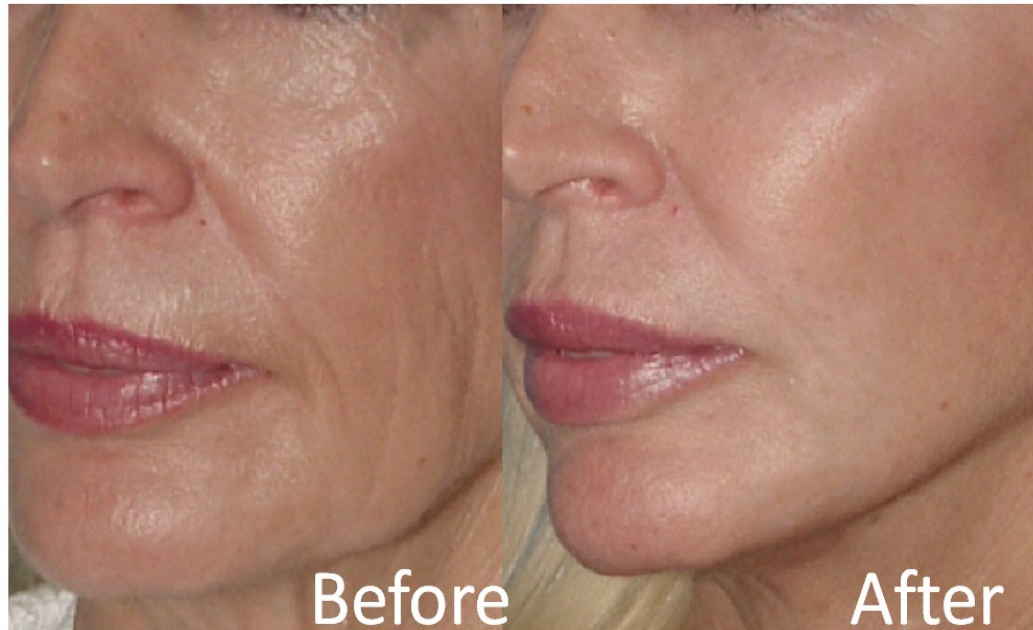Very pale face with
greenish tint in patients
with iron deficiency.

Facies mitralis



Blush on cheeks,
cyanotic tip of the
nose and ears.

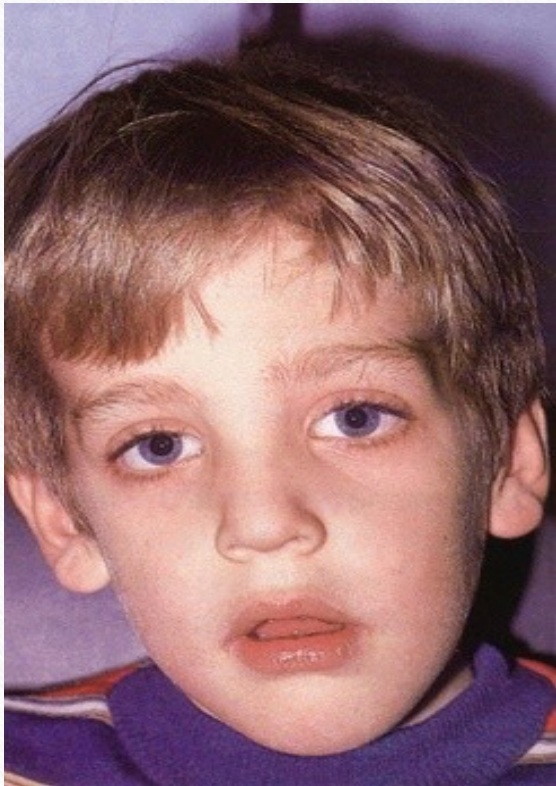Facies gastrica



Nasolabial Folds

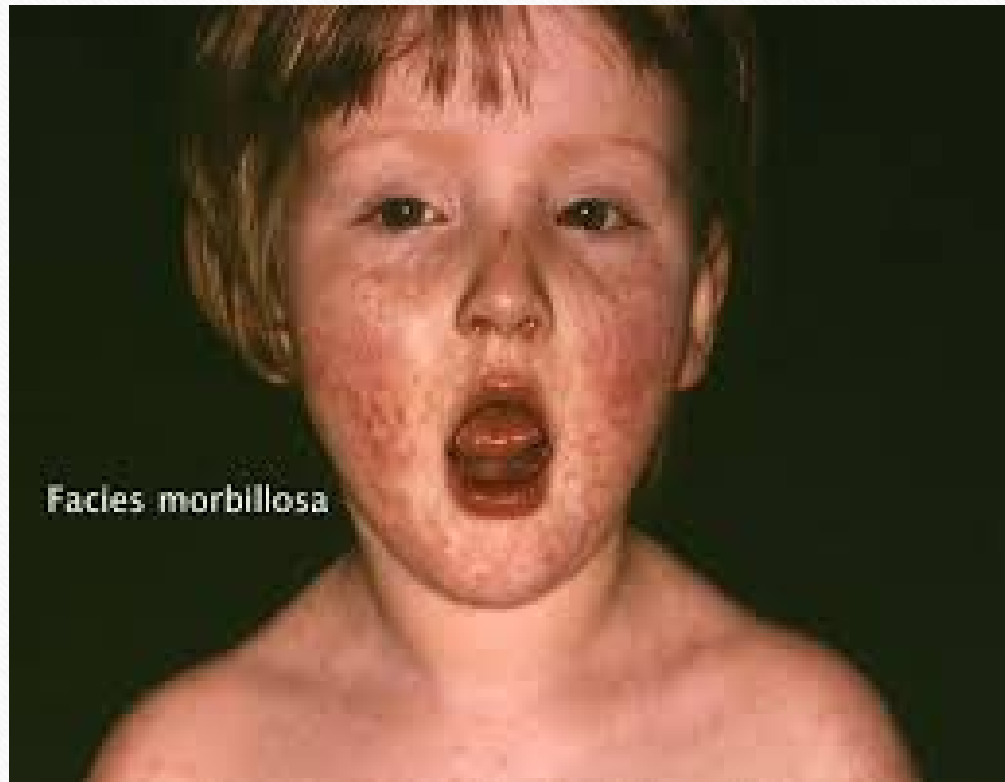Facial expression typical of acute stomach problems; deep nasolabial fold.

Facies tuberculosa / hectica



Exhausted, pale face with blush on cheeks, “burning” eyes, dry lips, excited countenance, half open mouth.

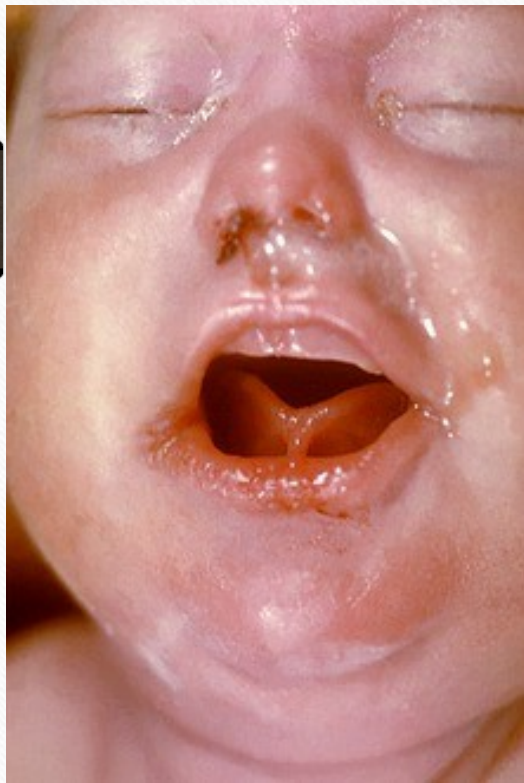Facies morbillosa





Facies morbillosa

Rash and reddened eyes sensitive to light; typical of children suffering from measles.

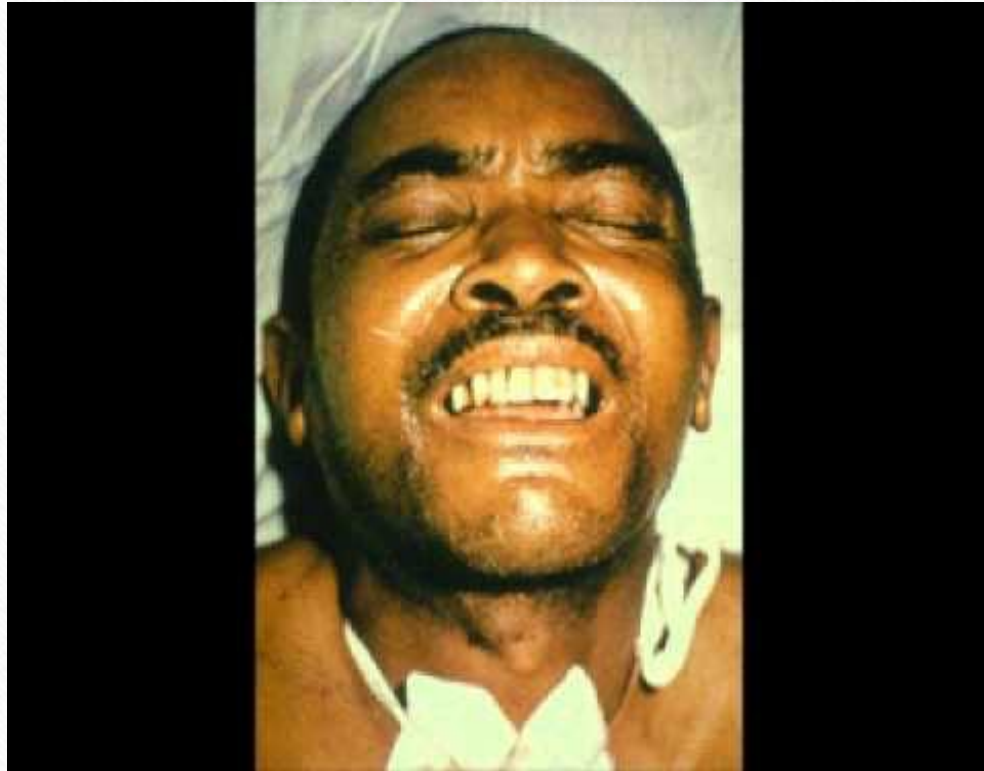Facies syphilitica



Saddle nose deformation; typical of the patients having the late congenital syphilis.

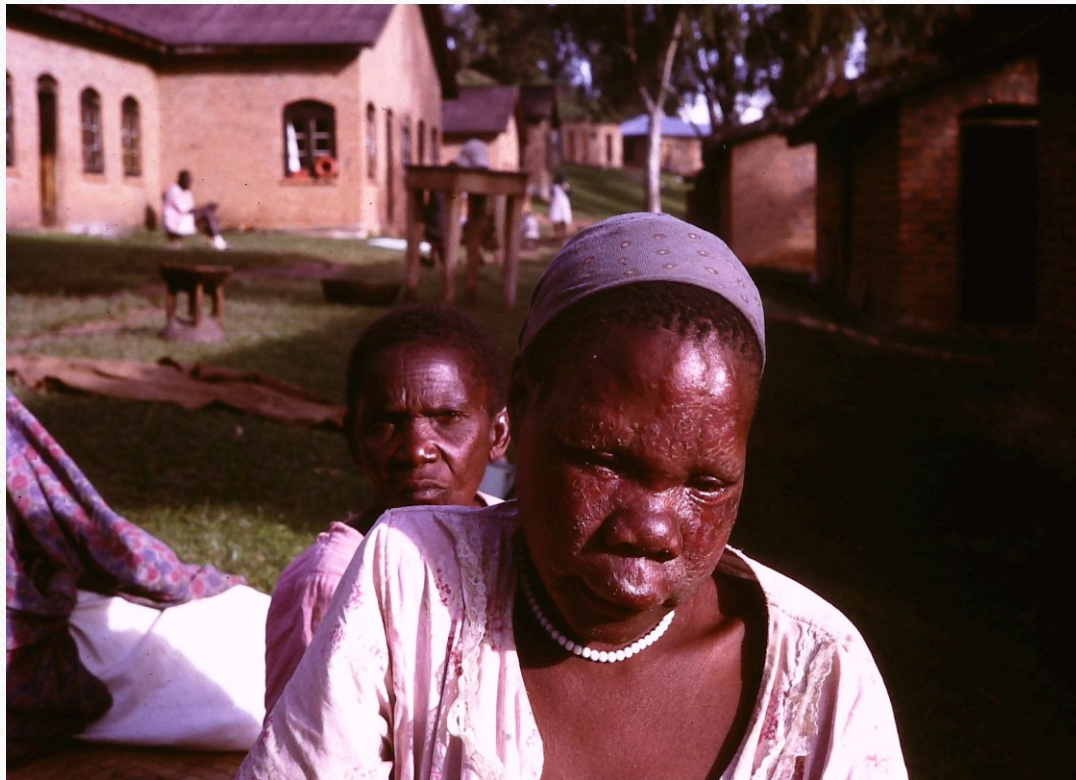

Facies tetanica / risus sardonicus



Typical of tetanus patients; mouth widened as in laughter, but the skin on forehead as if expressing grief.

Facies leontina



Lion-like facial appearance; patients with certain forms of leprosy.

Eponyms:

- **facies Hippocratica** → **facies abdominalis**

sunken eyes, pinched nose, deadly livid and cyanotic skin sometimes covered with large drops of cold sweat, specific for the collapse due to severe disease of abdominal organs accompanied by **peritonitis** (rupture of gall bladder, perforated ulcer in stomach or duodenum)

- **facies Parkinsonica / oleosa**

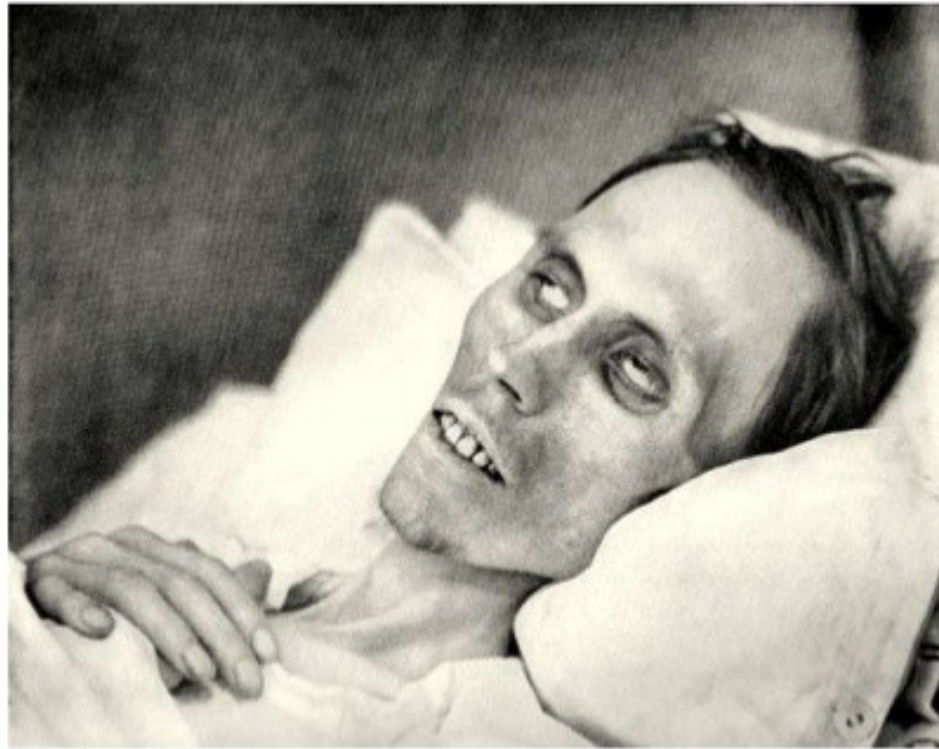amimic face with characteristic stare; the patient seems to lean forward to the observer; oily skin of face, sometimes drooling occurs; typical of patients with advanced Parkinson's disease (**morbus Parkinson**)

Facies Hippocratica → Facies abdominalis



Sunken eyes, pinched nose, deadly livid and cyanotic skin
sometimes covered with large drops of cold sweat.

facies Hippocratic



Facies Parkinsonica / oleosa




Amimic face with characteristic stare; the patient seems to lean forward to the observer; oily skin of face, sometimes drooling occurs.



Typical of patients
with advanced
Parkinson's disease
(*morbus Parkinson*)

Thank you !



“Let food be thy medicine
and medicine be thy food”
– Hippocrates

PALEOSPIRIT.COM