

EXPRESSING POSITION IN MEDICAL TERMINOLOGY

General terms

locus, i, m. / situs, us, m. (L.) = topo- (G.) = place e.g. *topophobia*

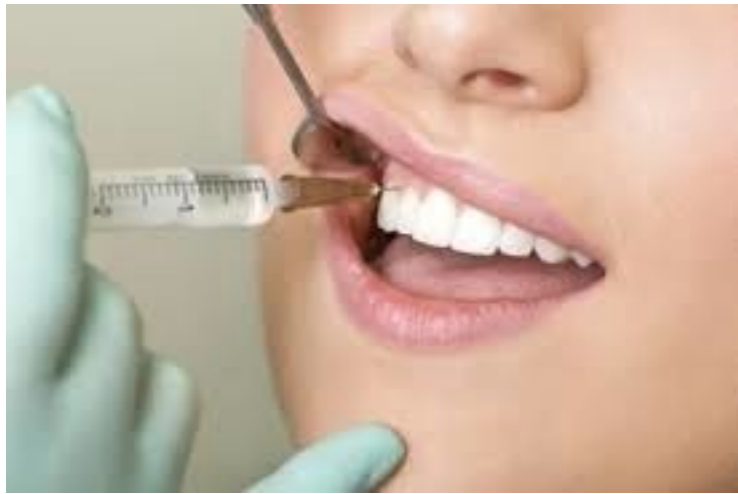in situ = in the (afore-mentioned) place

loco typico = in the typical place

loco cicatricis = in the place of the scar (*cicatrix, icis, f. = scar)

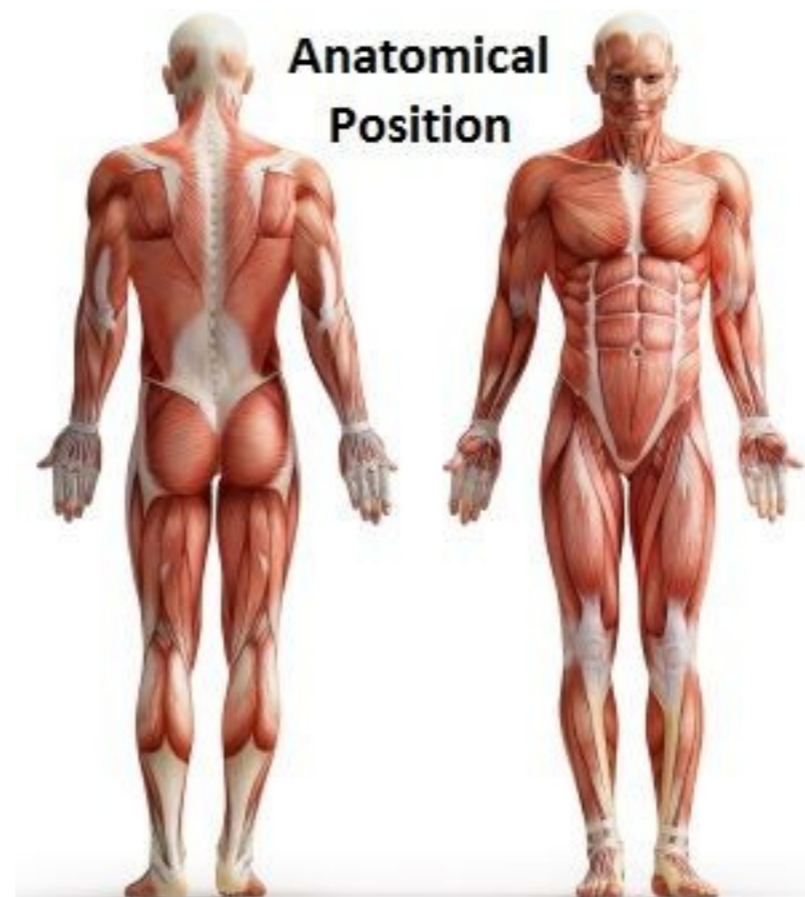
eodem loco = in the same place

localis, e = local



anaesthesia **localis**

positio, onis, f.



Lateral position

lateris *dextri* (l.dx.) = on the right side, the right one

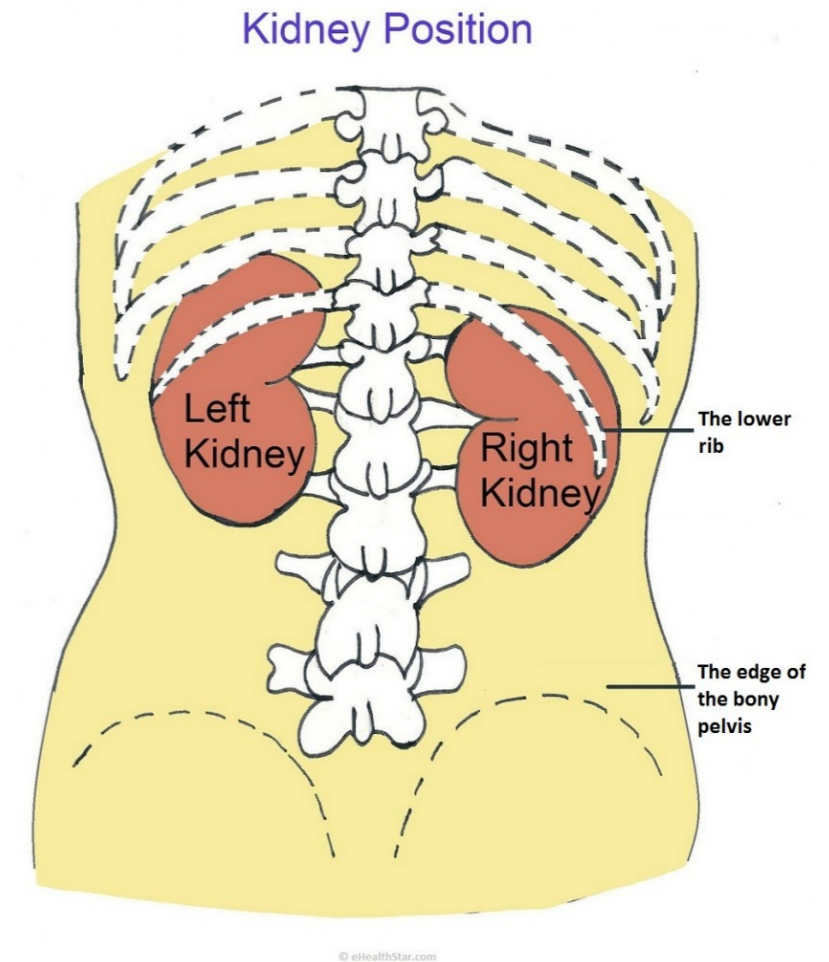
lateris *sinistri* (l.sin.) = on the left side, the left one

lateris *utriusque* (l. utr.) = on both sides, both

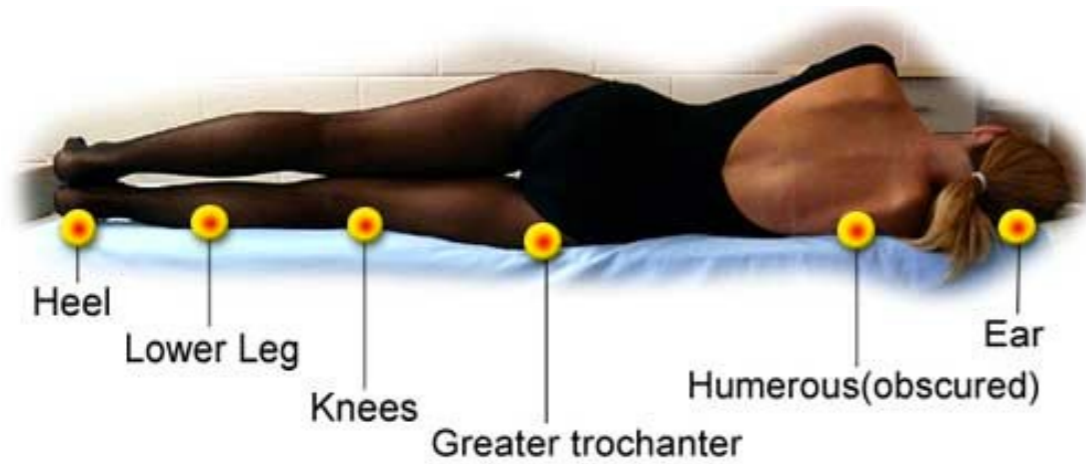
later- (L.) *(prefix) = related to side

e.g. **lateropositio uteri**

sinistro-/dextropositio = reversal of an organ to the left/right

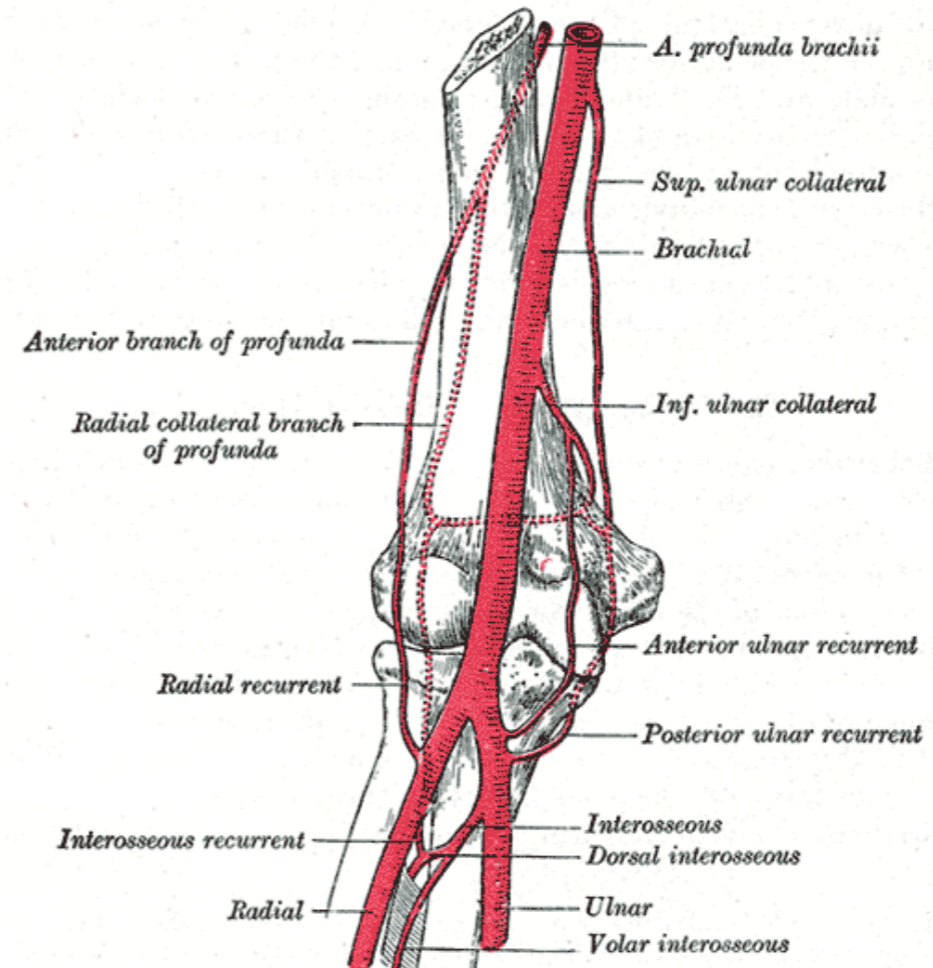


/bi/lateralis, e = /bi/lateral



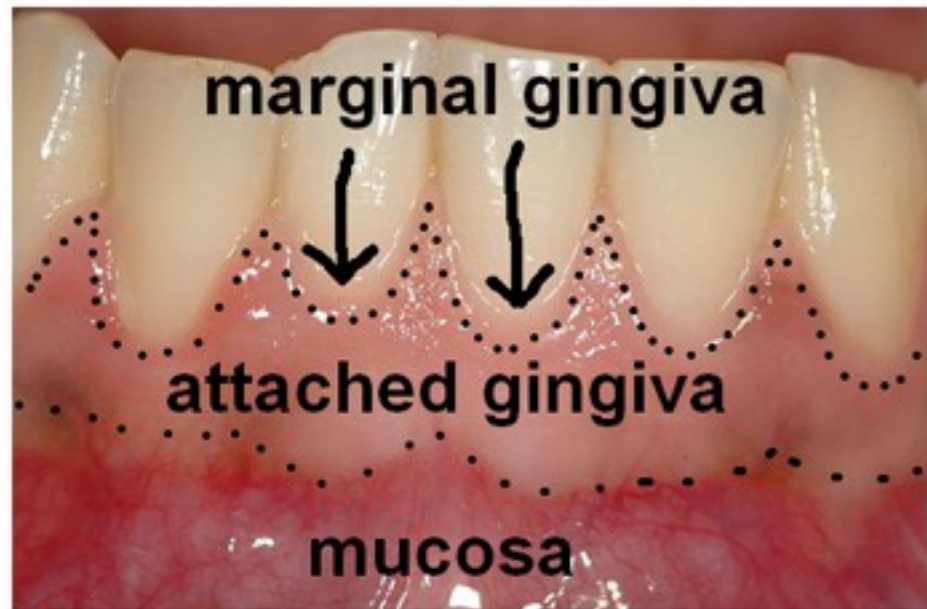decubitus **lateralis** (lateral bedsores)

collateralis, e = located on the same side



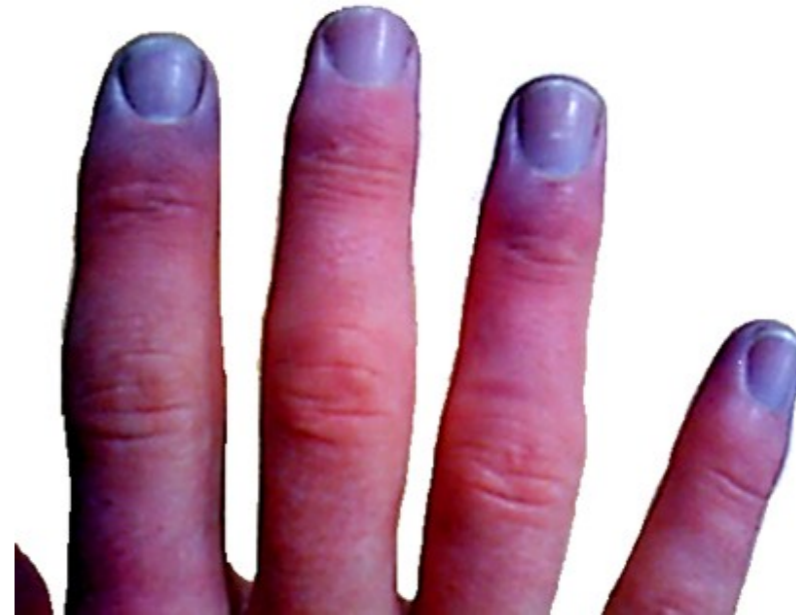arteria **collateralis** (collateral artery)

marginalis, e = marginal



gingivitis marginalis

acralis, e (G.) = referring to extremities



cyanosis acralis

Medial position

medius, a, um / medianus, a, um

medialis, e (x lateralis, e)

intermedius, a, um = located between two things

centralis, e

mes-o- (G.) *(prefix)

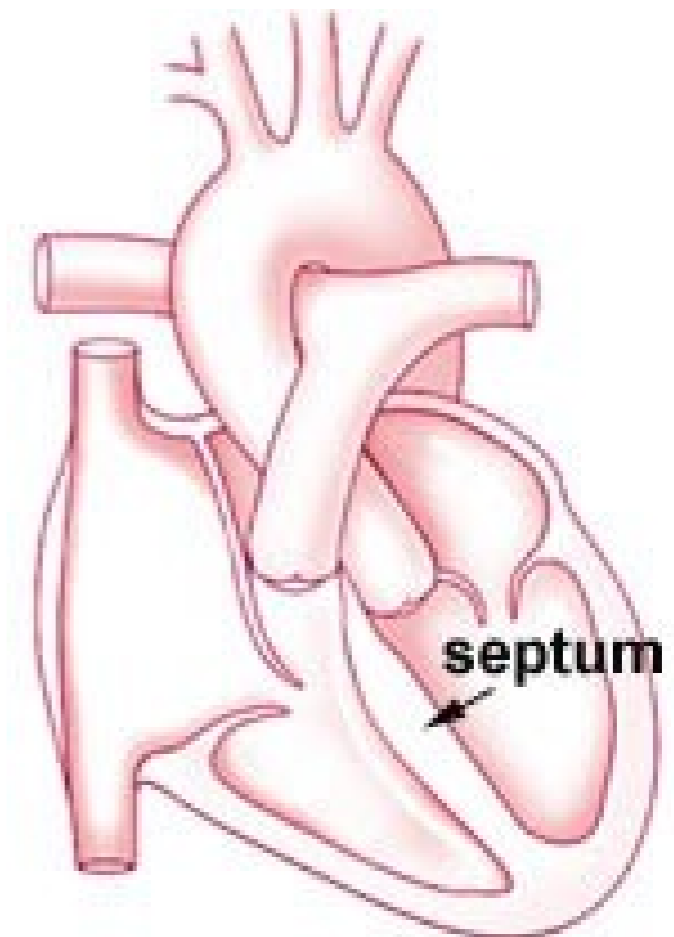
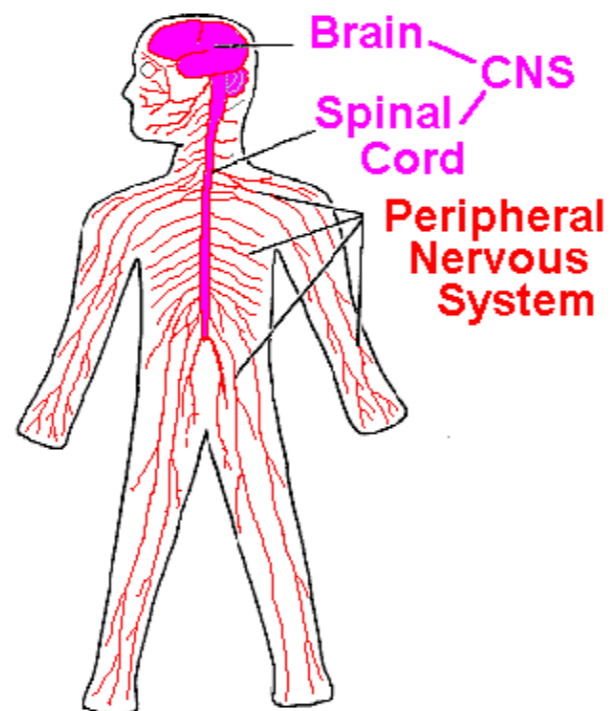
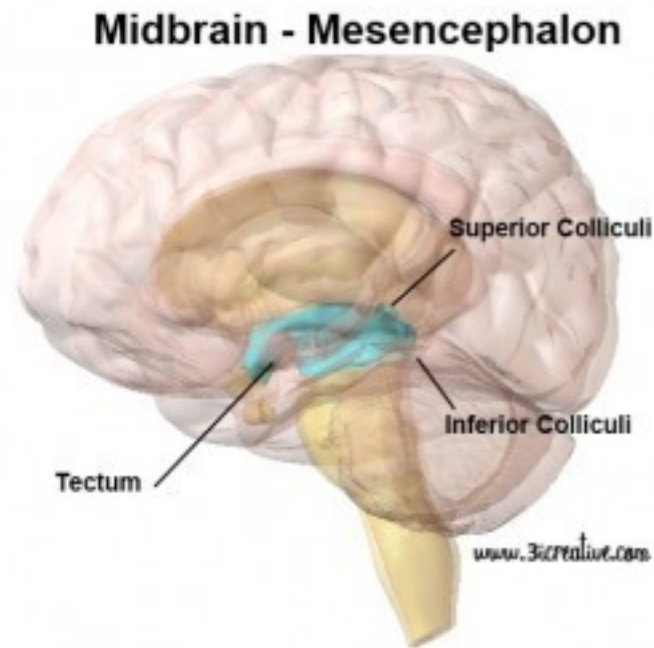
e.g. *auris media*; *linea mediana*

e.g. *nervi supraclaviculares mediales*

e.g. *septum intermedium*

e.g. *os centrale*; *systema nervosum centrale*

e.g. *mesoderma*; *mesencephalon*



Anterior position/before sth

anterior, ius *(comparative form)

antero- *(pref.)

ante- *(pref.)

prae- (L.) *(pref.)

pro- (G.) *(pref.)

e.g. *paries anterior gastris*

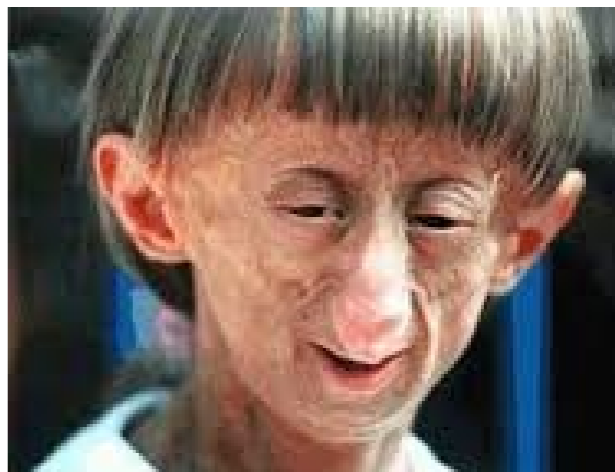e.g. *funiculus anterolateralis*

e.g. *antepositio uteri*

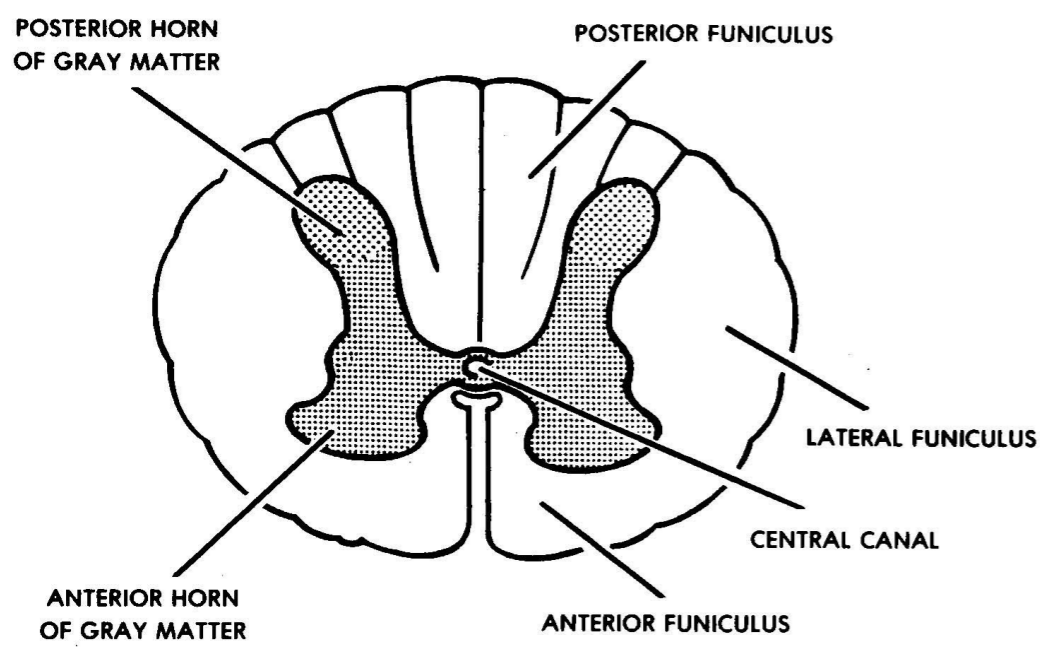
e.g. *transfusio praeoperativa*

= *transfusion before operation*

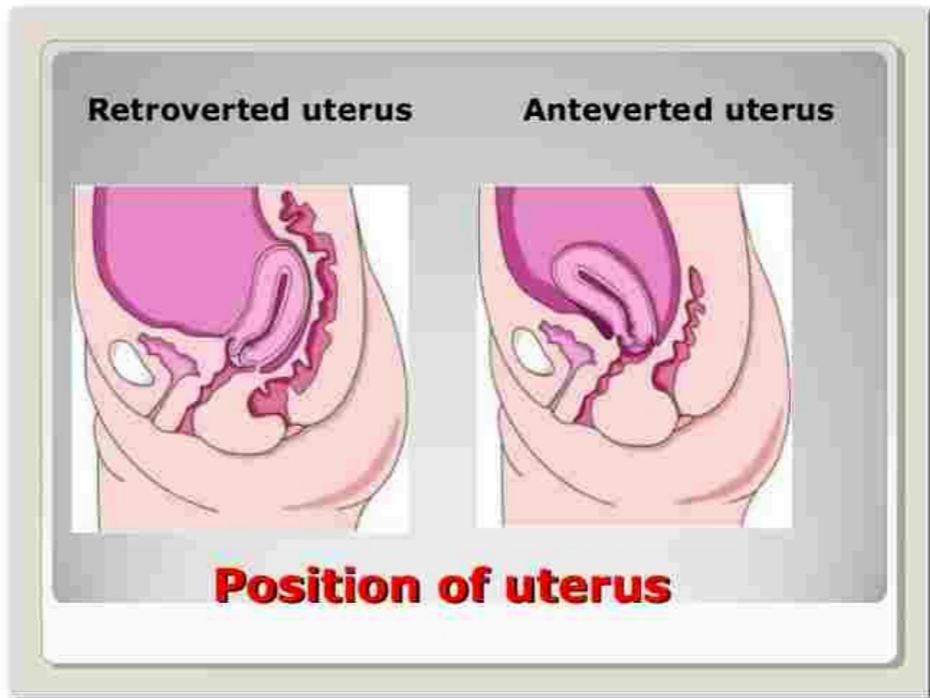
e.g. *progeria adultorum; prognathia*



progeria



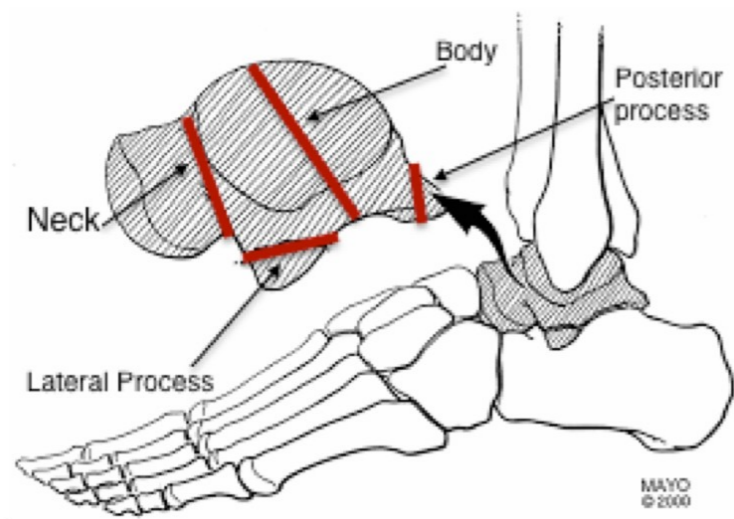
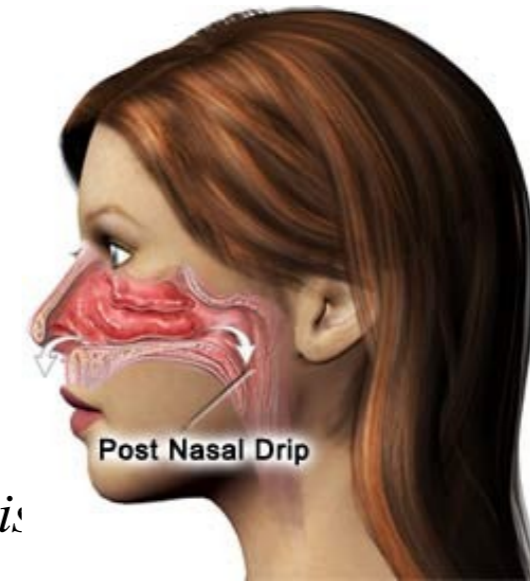
funiculus anterolateralis
(anterior and lateral white matter)



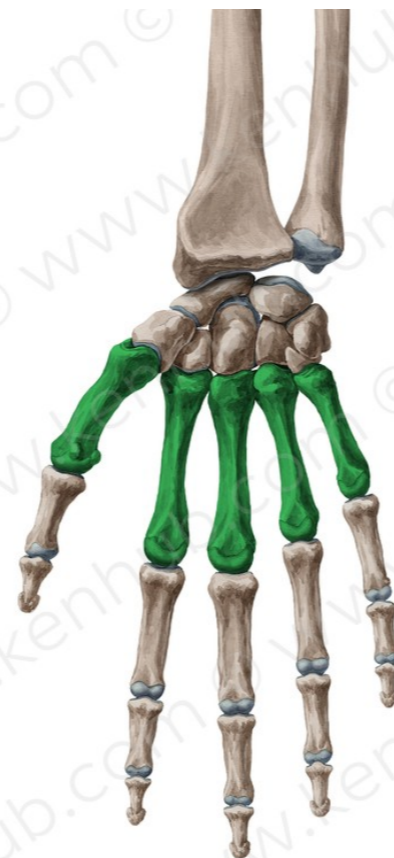
antepositio uteri

Posterior position/after sth

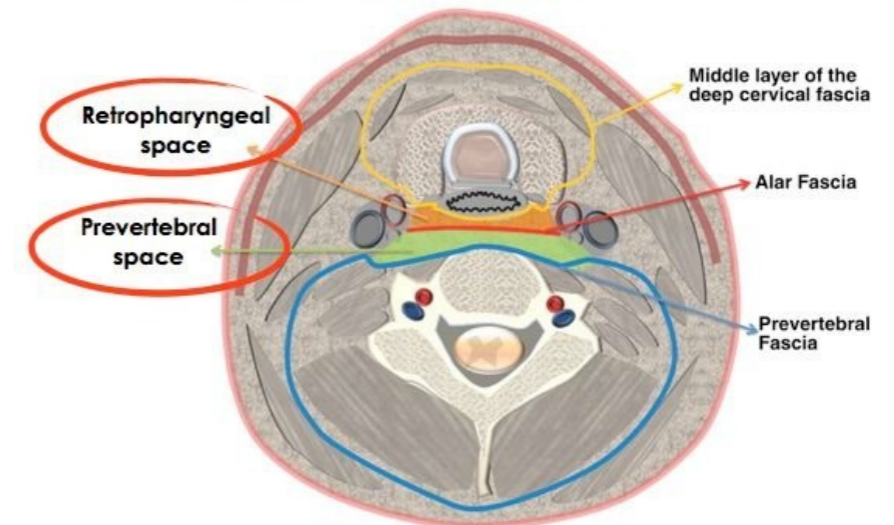
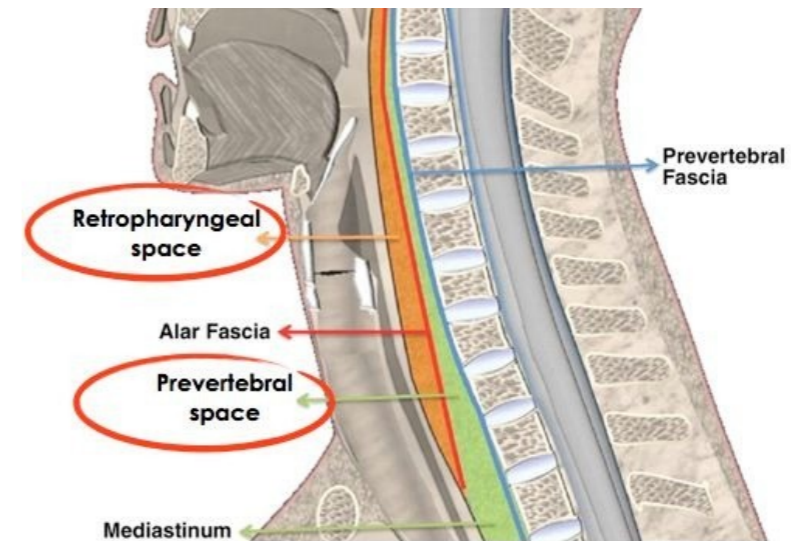
- posterior, ius *(comp. form) e.g. *processus posterior tali*
- postero- *(pref.) e.g. *infarctus posterolateralis*
- post- (L.) *(pref.) =after e.g. *regio postnasalis; status postabortalis*
- retro- (L.) *(pref.)= behind e.g. *spatium retropharyngeum*
- meta- (G.) *(pref.) = after e.g. *ossa metacarpalia*



processus posterior tali



ossa metacarpalia



regio postnasalis

Superior position

superior, ius *(comp. form)

supero- *(pref.)

supra-/super- (L.) *(pref.)

epi- (G.) *(pref.)

hyper- (g.) *(pref.) rarely

e.g. *palpebra superior*=superior eyelid

e.g. *nodi lymphatici inguinales superficiales superomediales*

e.g. *fossa **supra**vesicalis*; *venae **super**ficiales membri superioris*

e.g. *venae **epi**sclerales*= veins located above scela(*episcleral veins*)

e.g. **hyper**nephritis

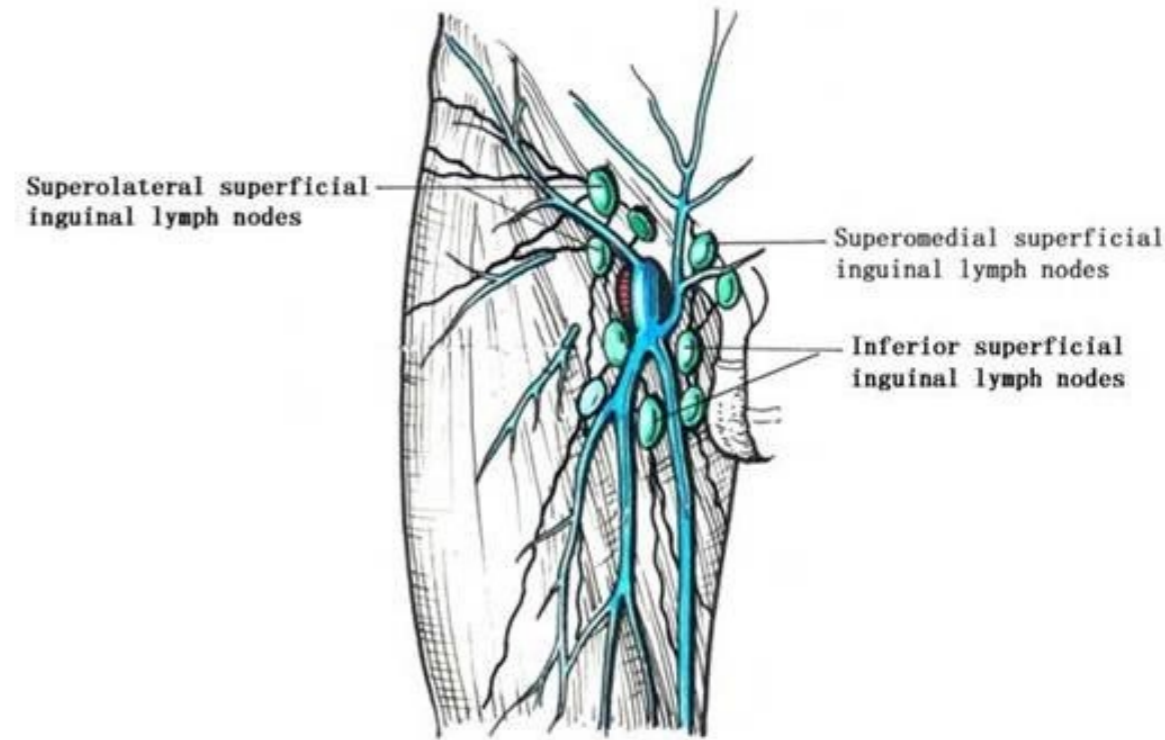
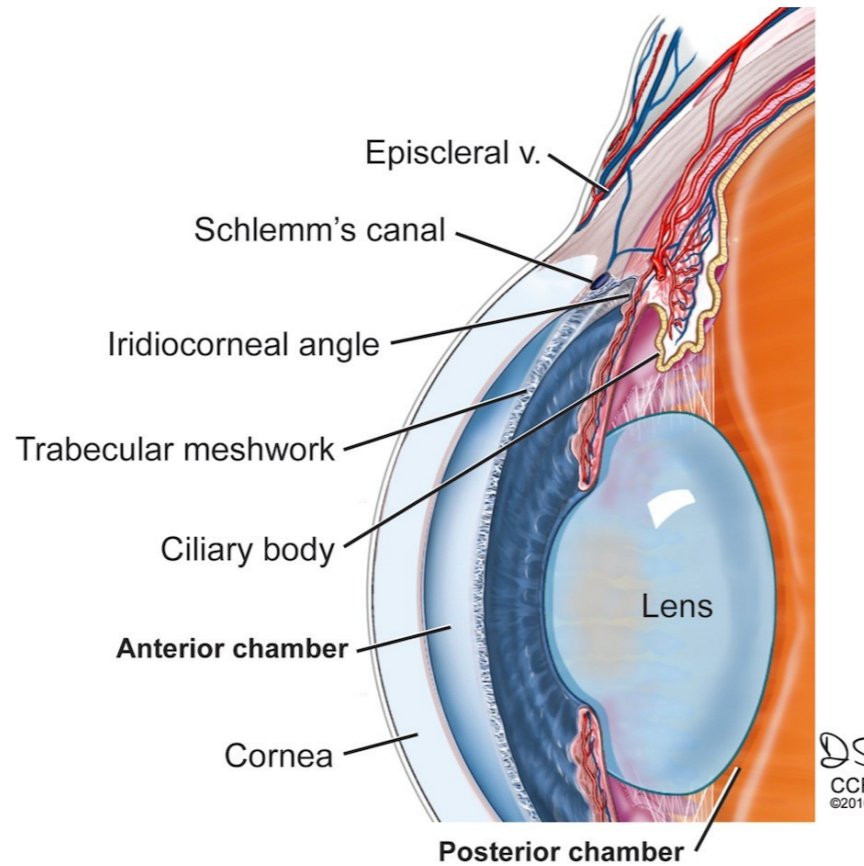
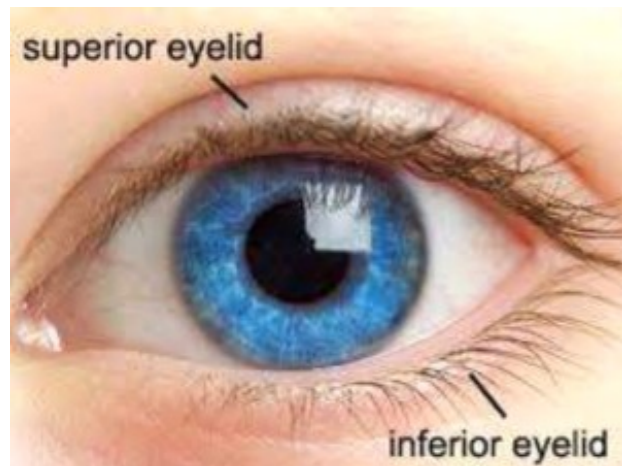


Fig. 3-2-14 The superficial inguinal lymph nodes

Inferior position

inferior, ius *(comp. form)

e.g. *membra inferiora = inferior membrane*

infero- *(pref.)

e.g. *infarctus inferoposterior*

infra- (L.) *(pref.)

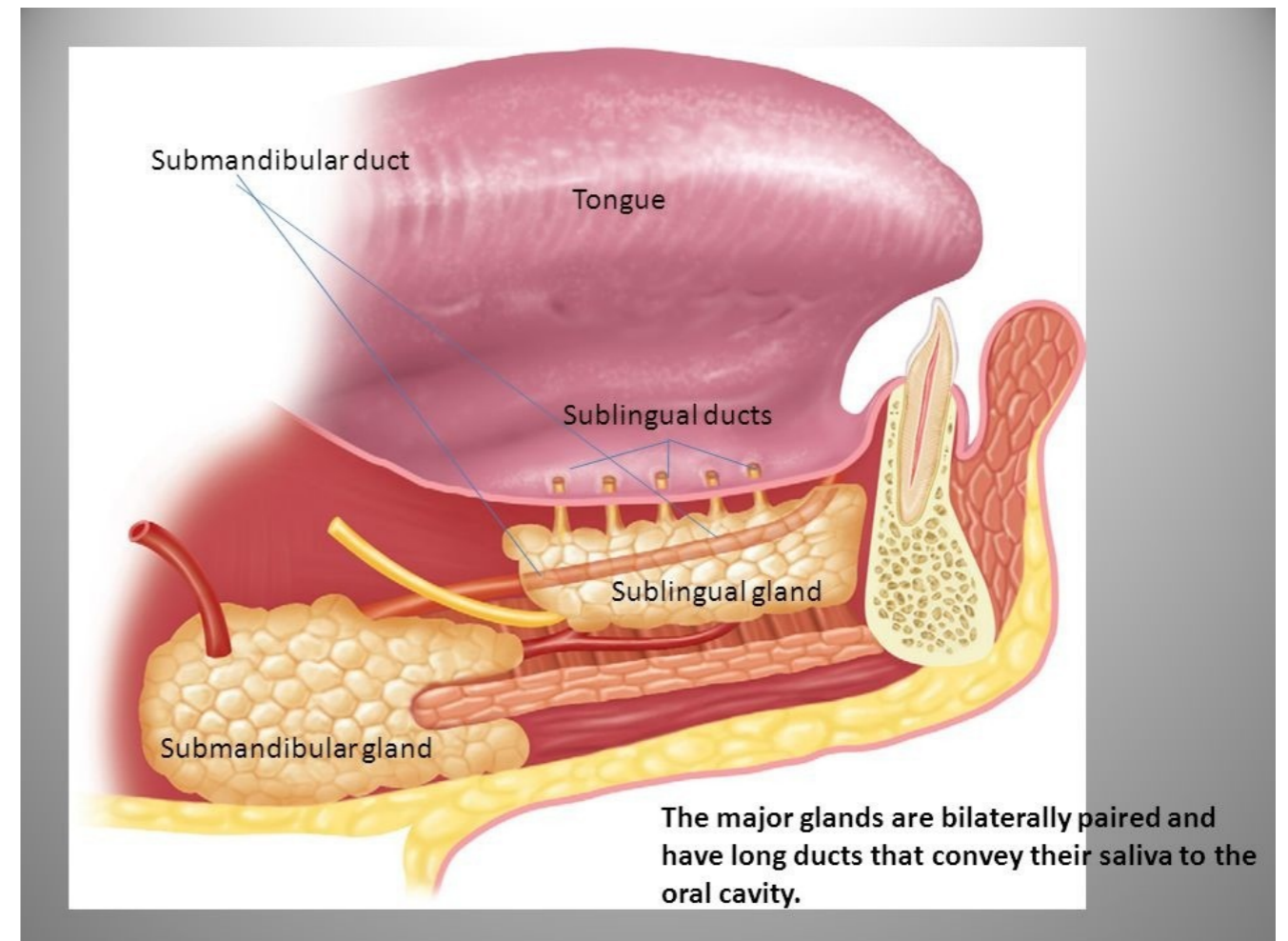
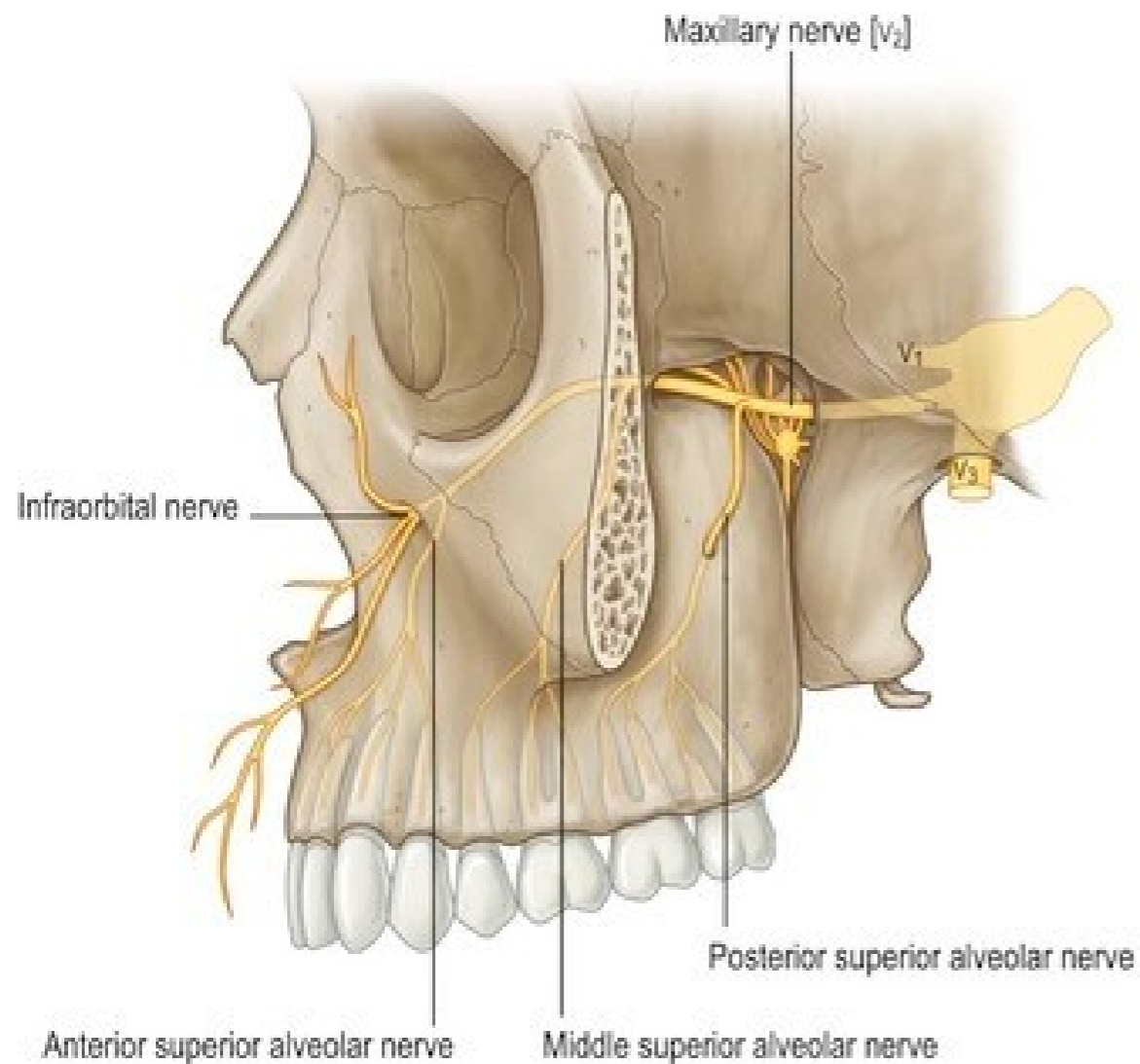
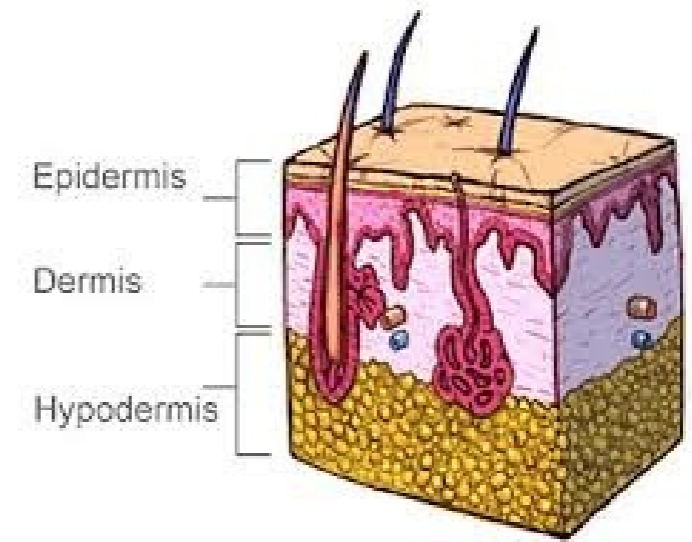
e.g. *nervus infraorbitalis = nerve under orbita.*

sub- (L.) *(pref.)

e.g. *ductus sublingualis maior = major sublingual duct*

hypo- (G.) *(pref.) rarely

e.g. *hypodermis*

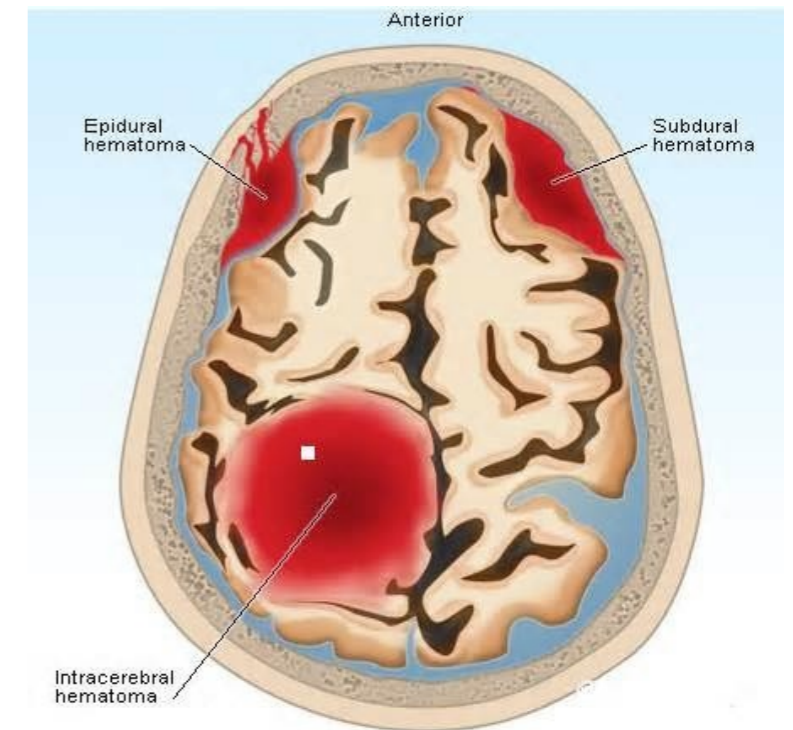
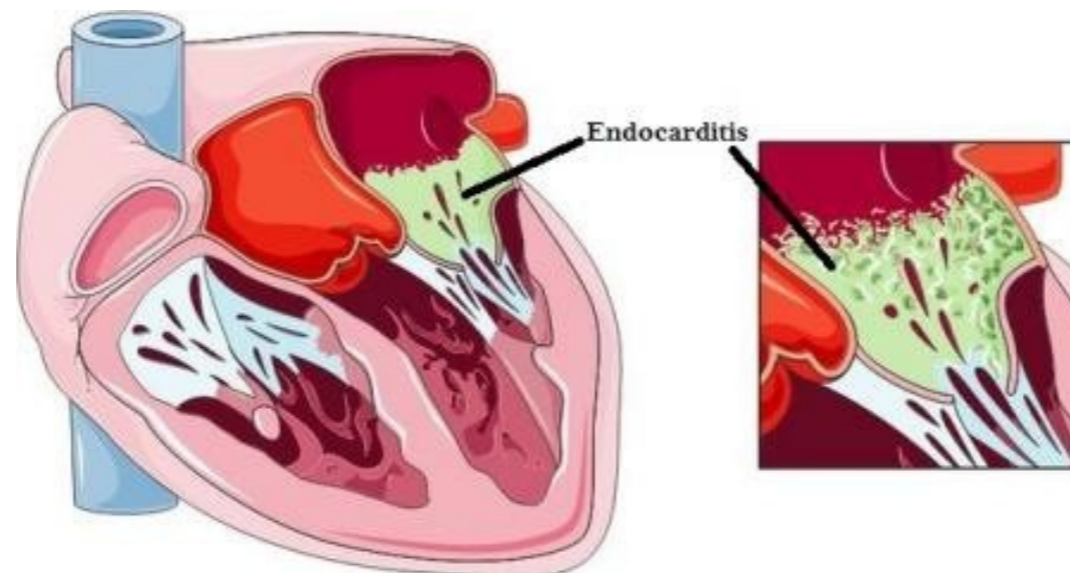
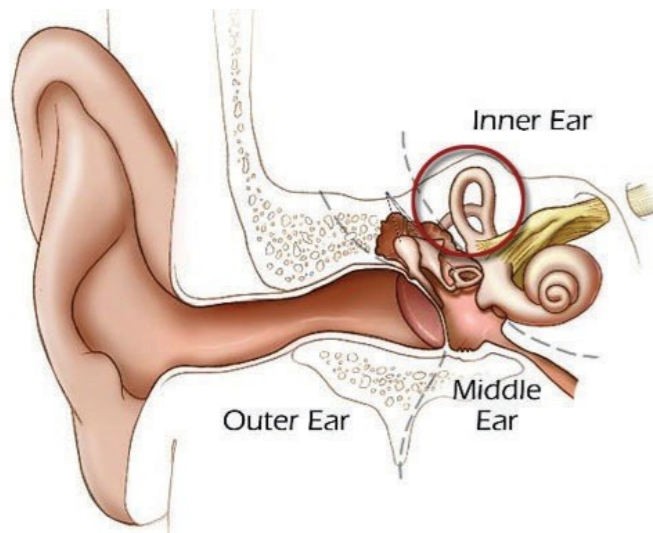


Internal position

internus, a, um *auris interna* = inner ear

intra- (L.) *(pref.) *haemorrhagia intracranialis* = intracranial bleeding

endo- (G.) *(pref.) *endocarditis* = inflammation of endocardium



haemorrhagia intracranialis

External position

externus, a, um

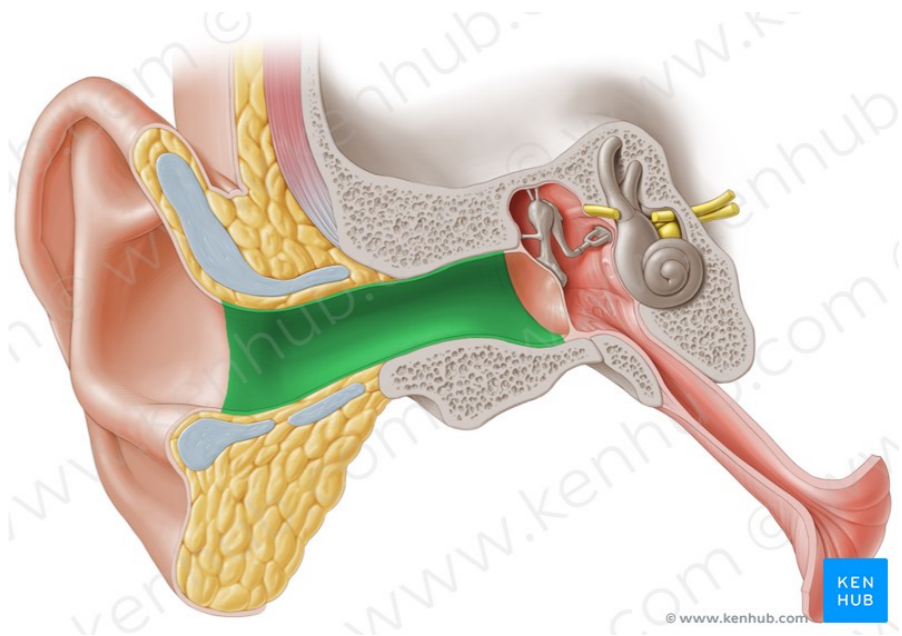
extra- (L.) *(pref.)

ecto-/exo- (G.) *(pref.)

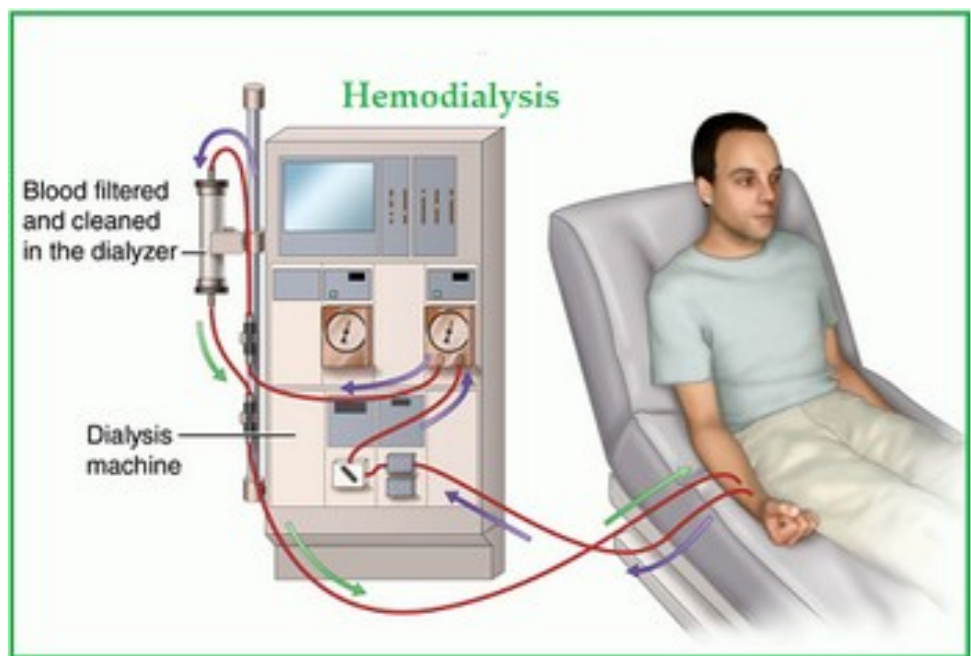
e.g. *meatus acusticus externus*

e.g. *circulatio extracorporalis*

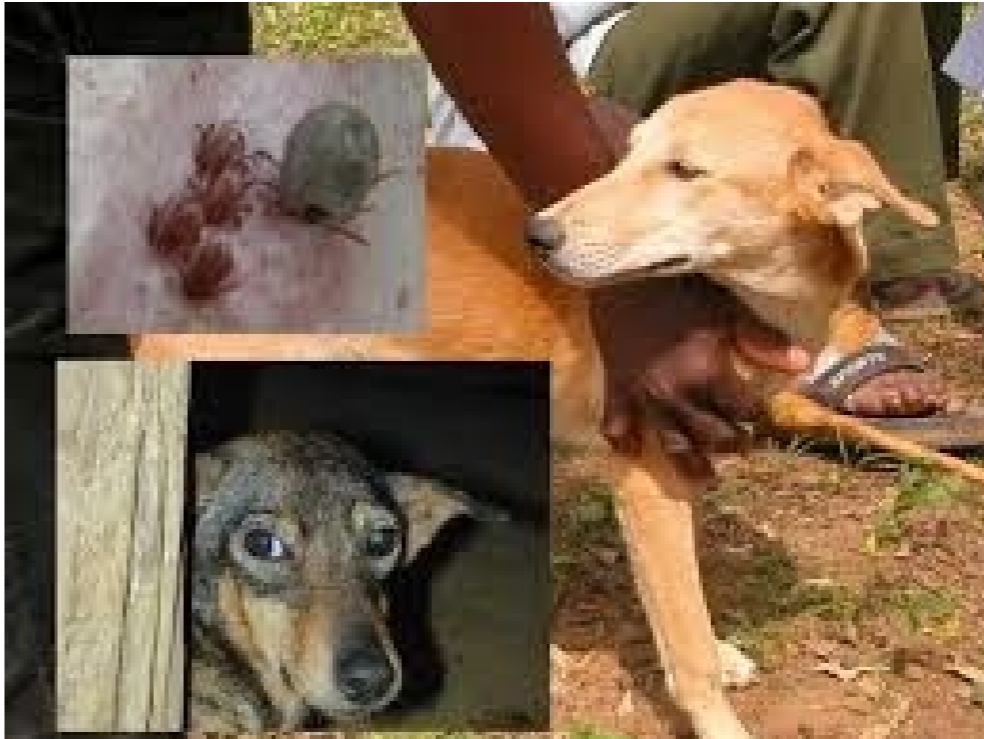e.g. *ectoparasitus; neurosis exogenes*



external caustic meatus



circulation of blood outside the body through a machine



tick