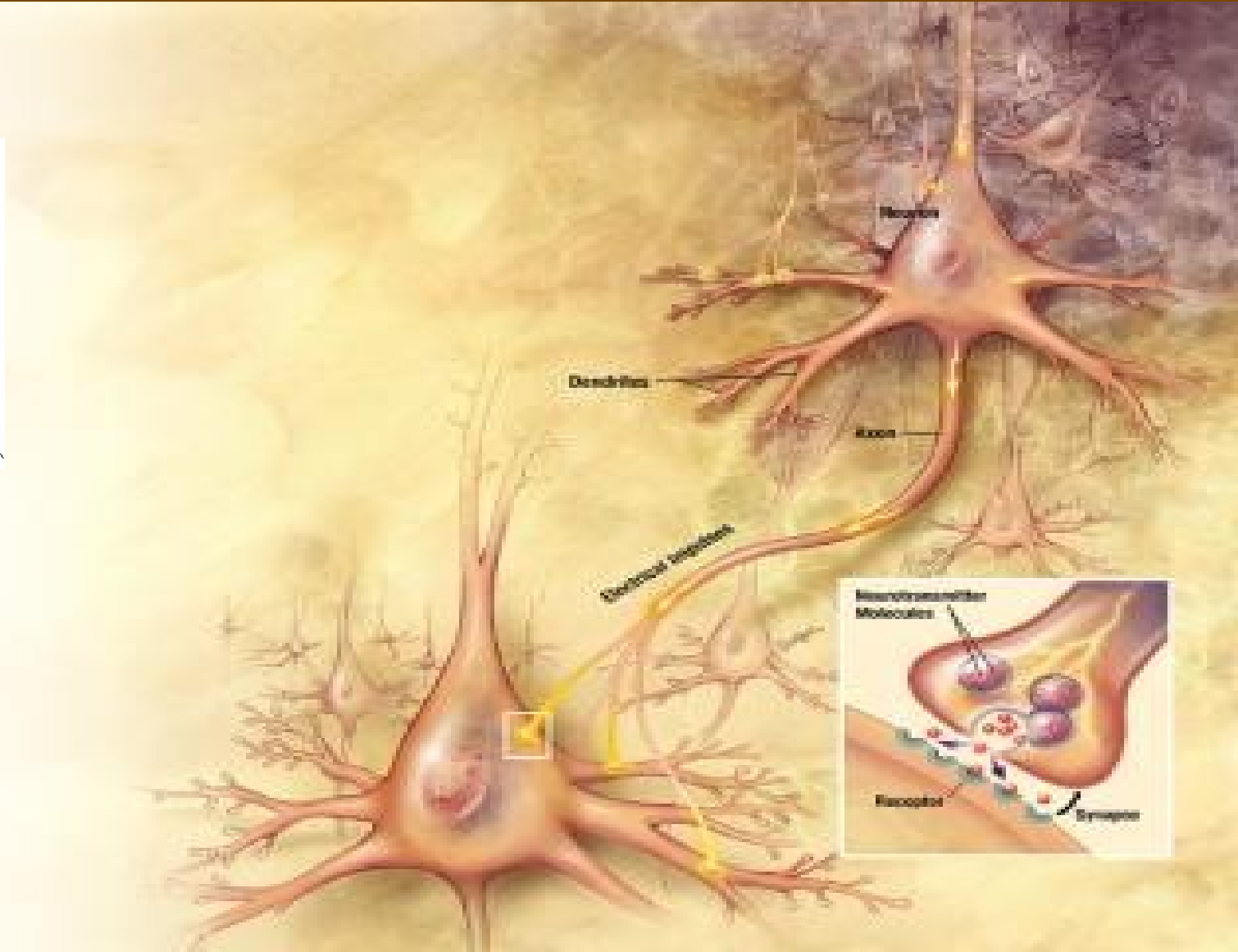
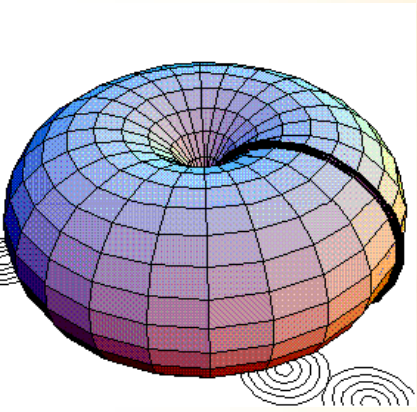


Nervová tkáň



Obecné vlastnosti nervové tkáně

dráždivost a vodivost přivedena k absolutní dokonalosti

původ: ektoderm

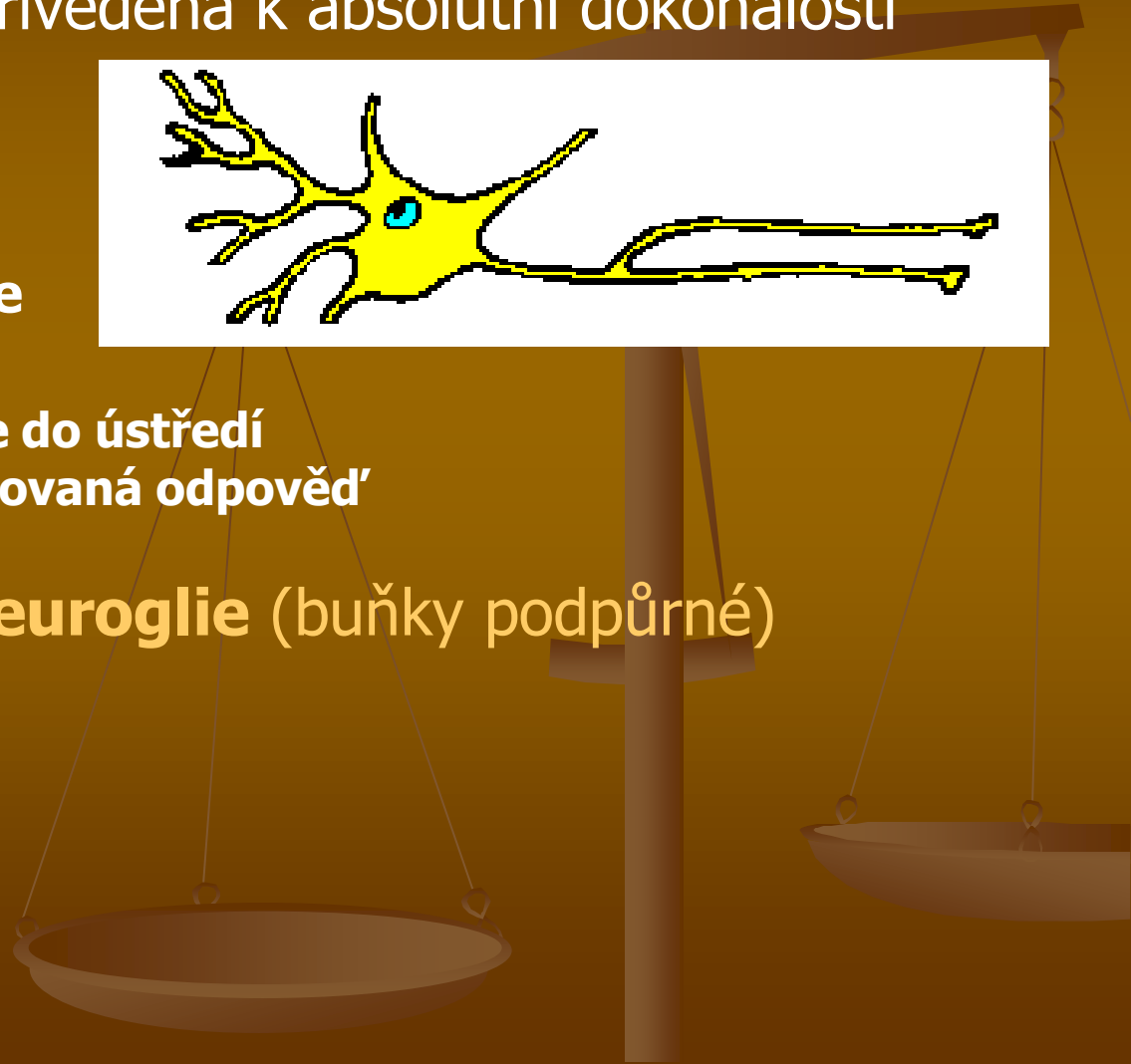
funkce: nervová regulace

- přesná analýza změn
- rychlý převod informace do ústředí
- cílená a místně diferencovaná odpověď

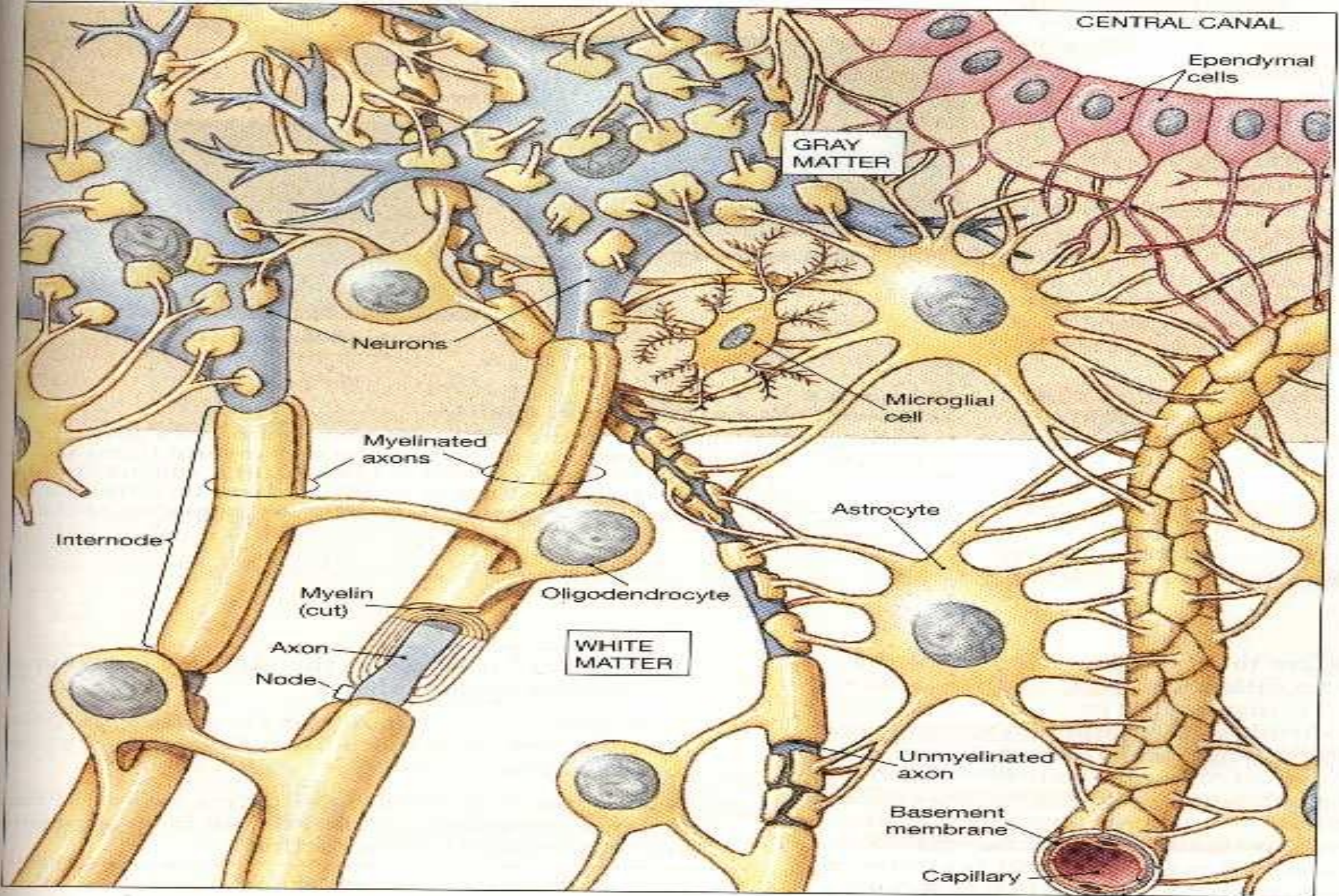
Složení: **neurony a neuroglie** (buňky podpůrné)

CNS — šedá hmota
 — bílá hmota

PNS



Neurony + gliové buňky



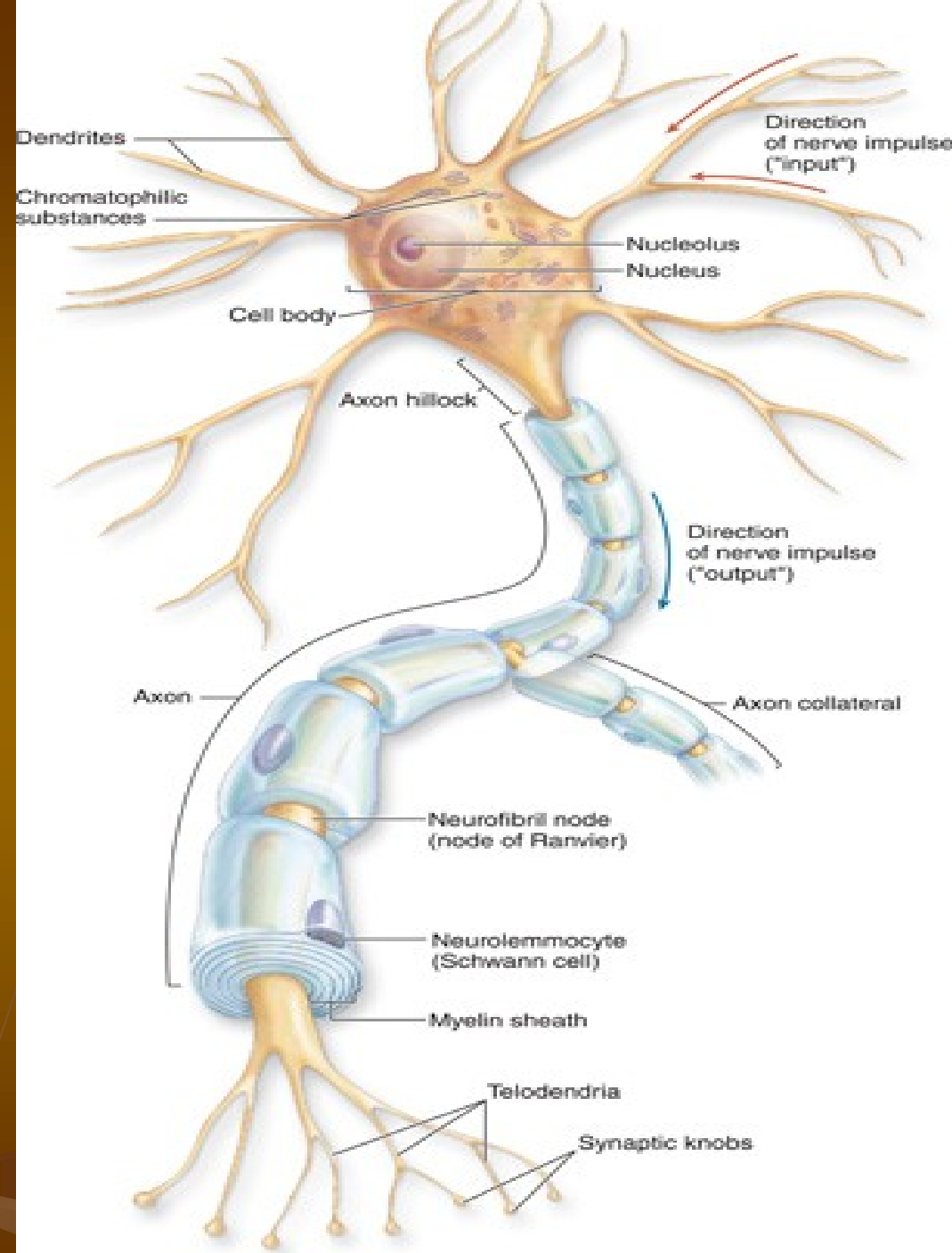
Neuron

Perikaryon (tělo)

Dendrit(y)

Axon – pouze 1
(odstupový konus
=axonový hrbol)

Telodendrie

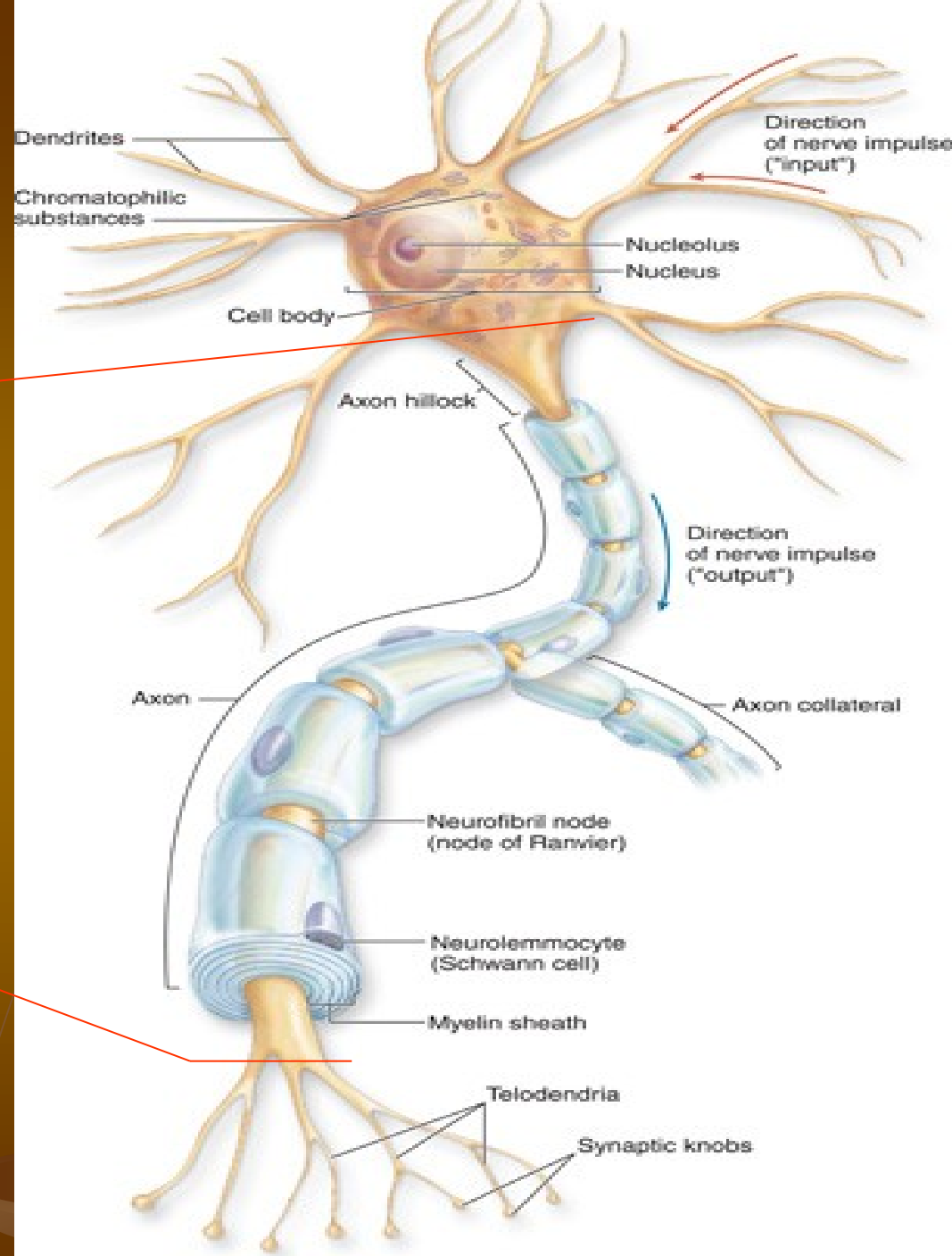


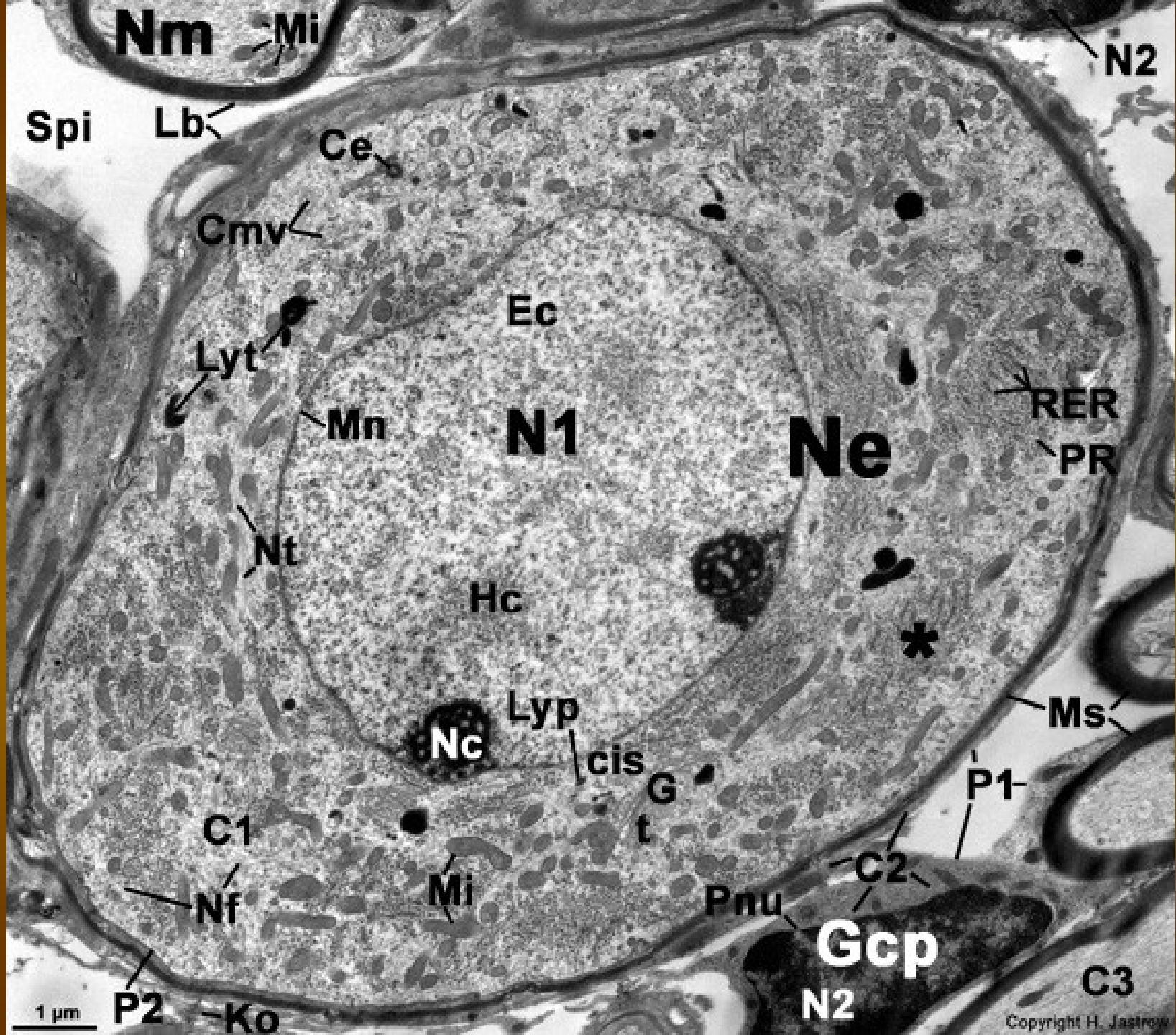
ČÁSTI NEURONU

Recepční oddíl

Transmisní oddíl

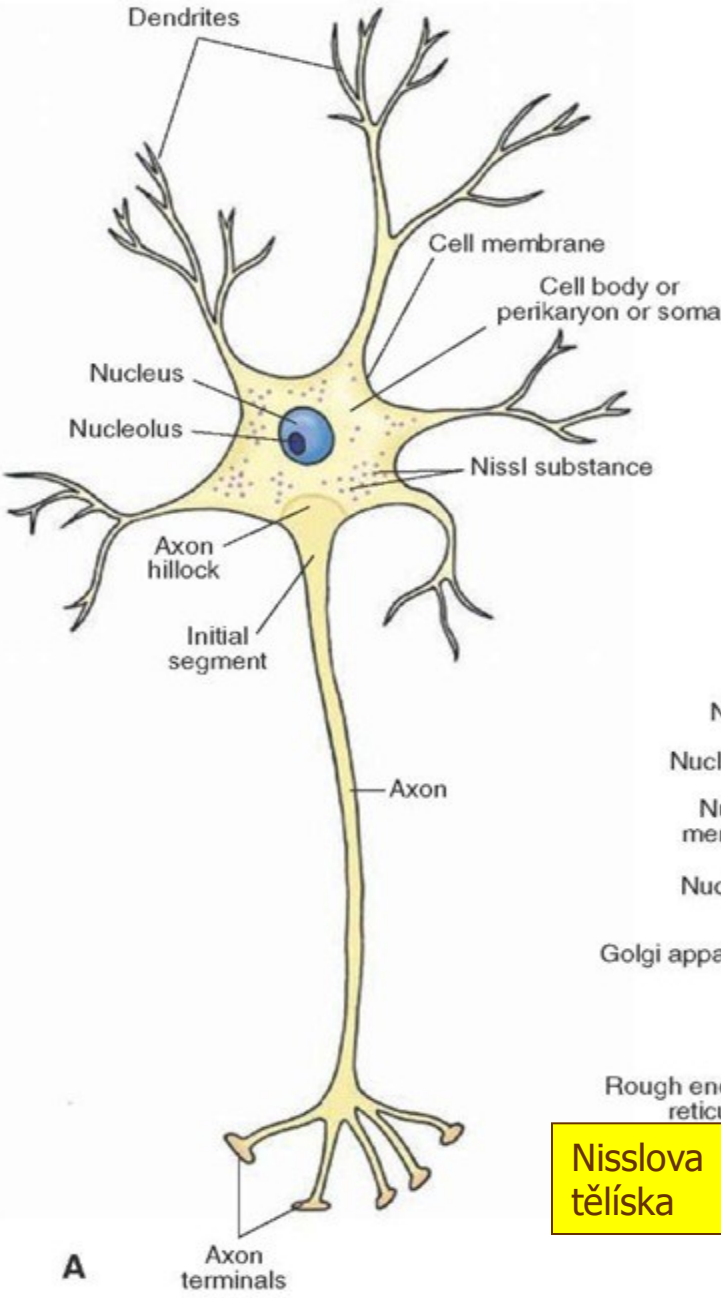
Sekreční oddíl





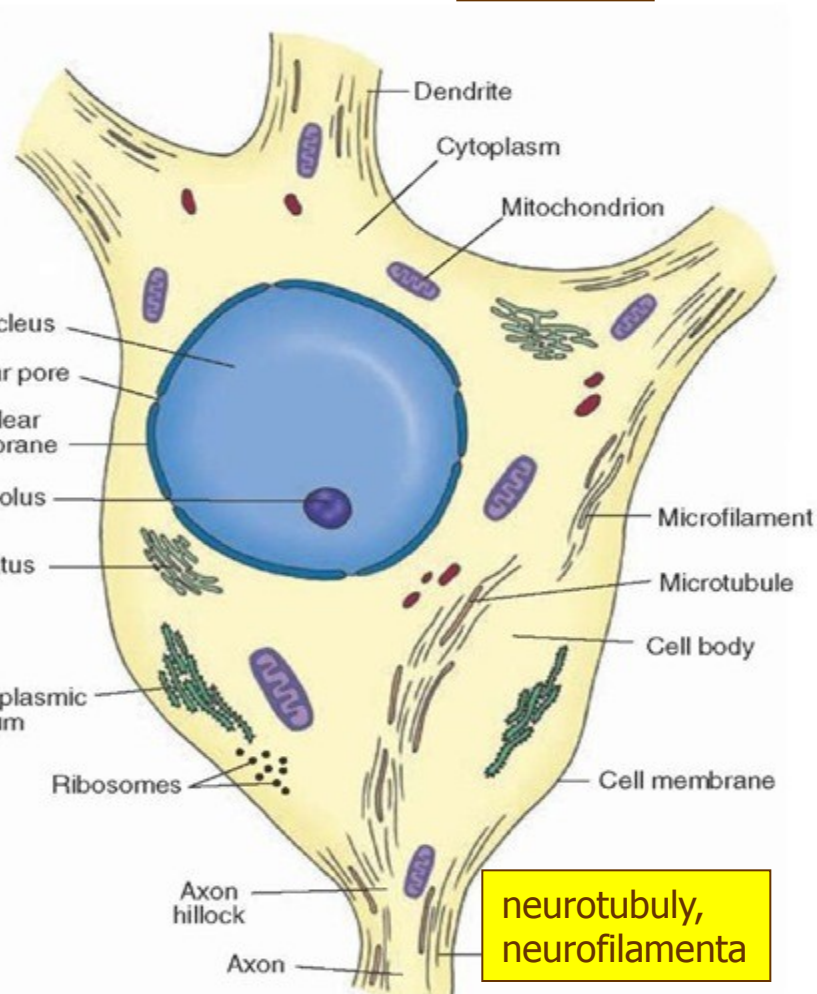
NEURON

4 – 100 μm \varnothing



lipofuscin

Nisslova tělíska

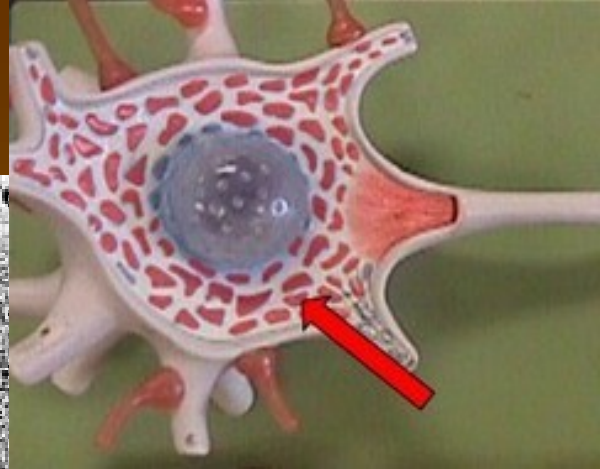
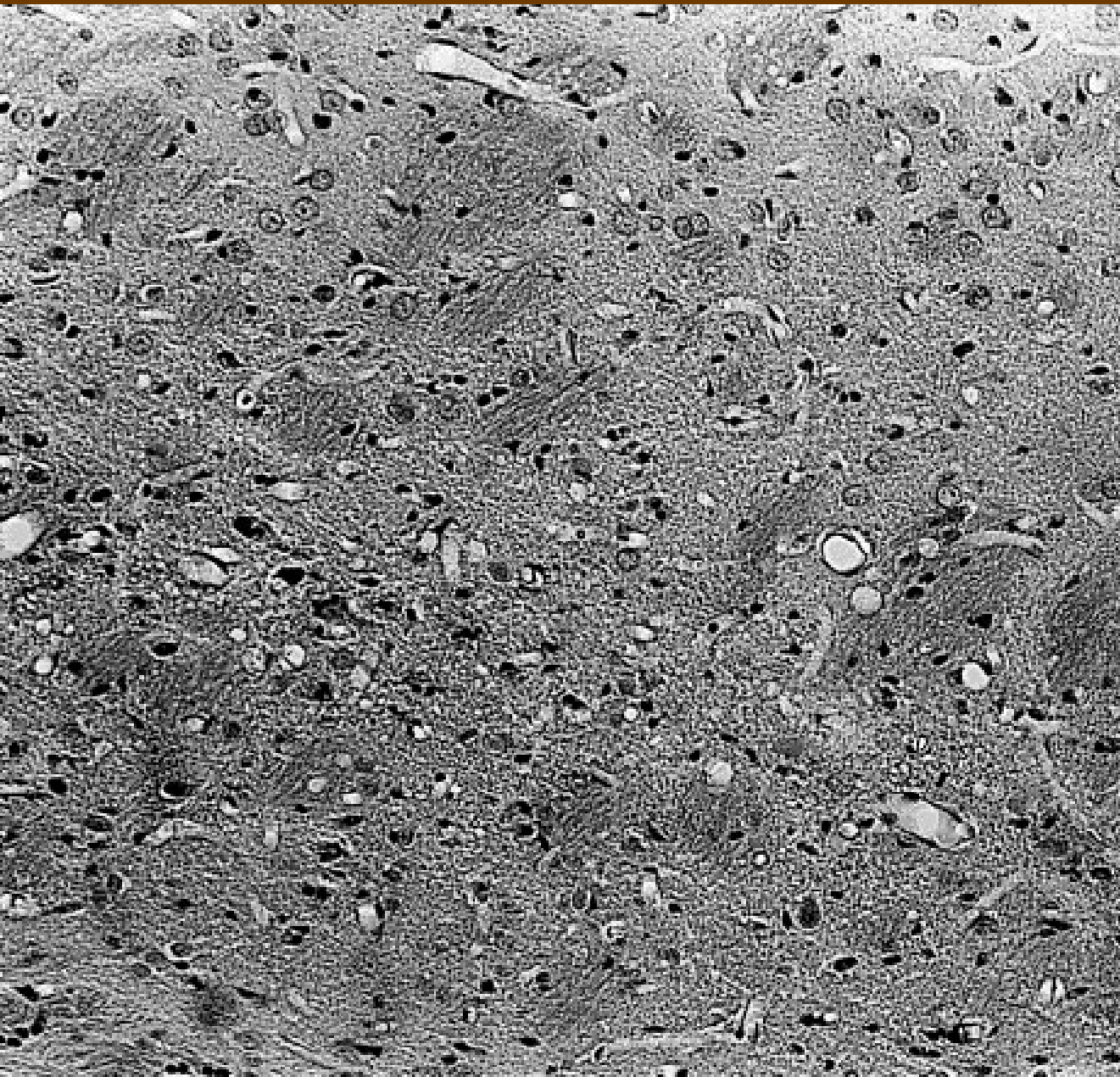


neurotubuly, neurofilamenta

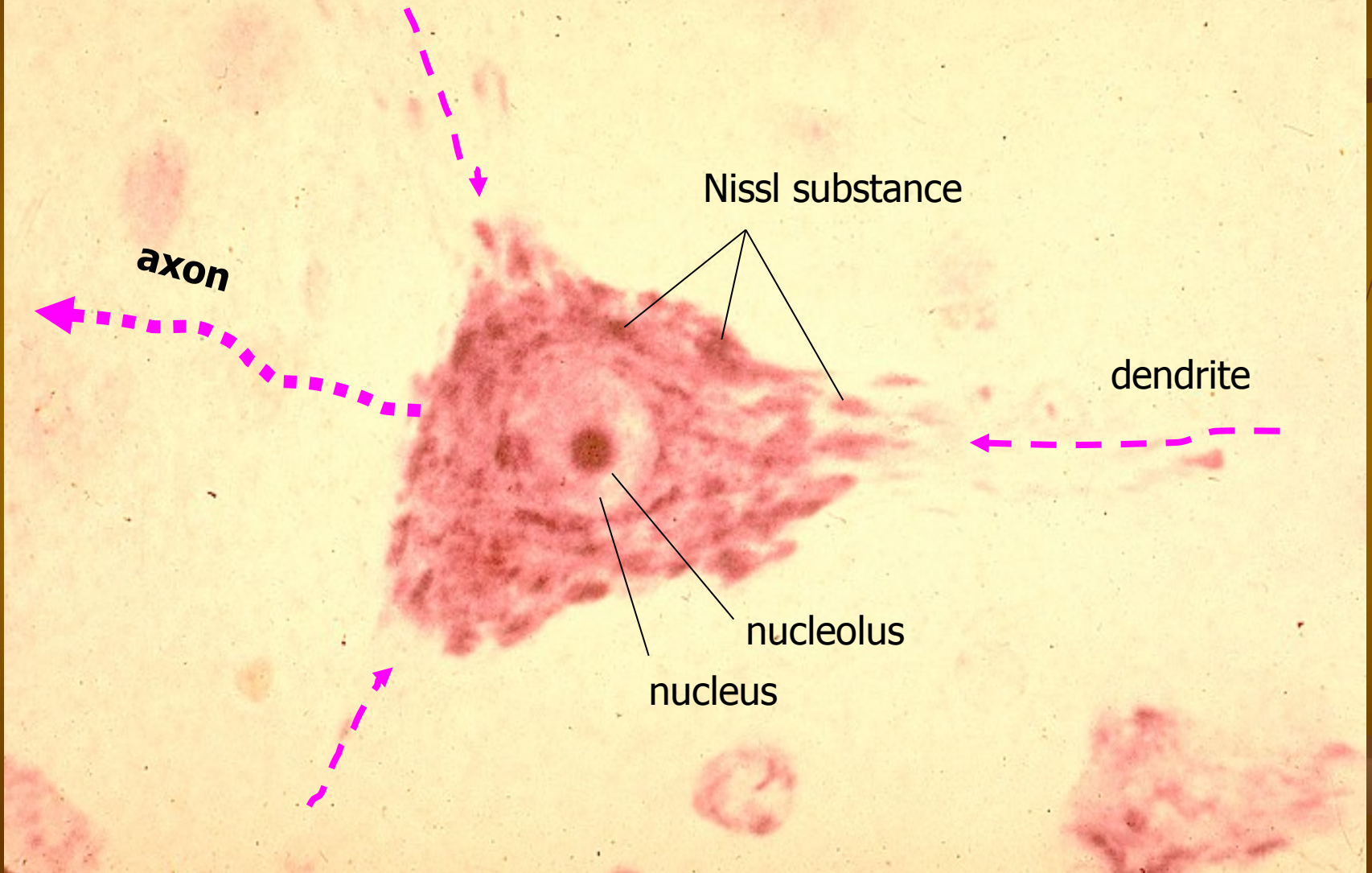
A

B

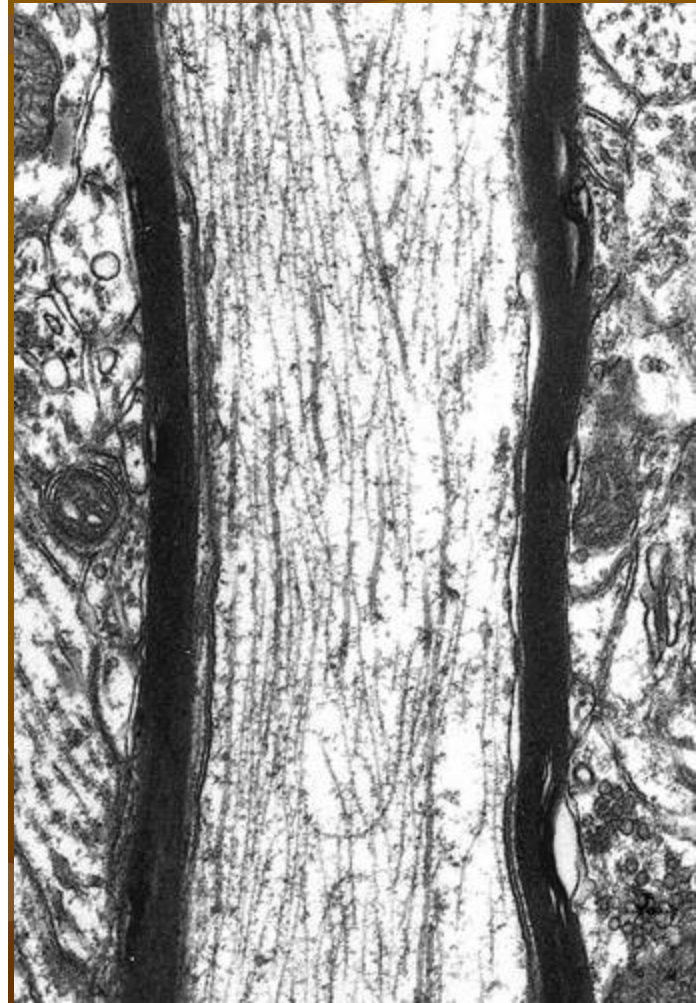
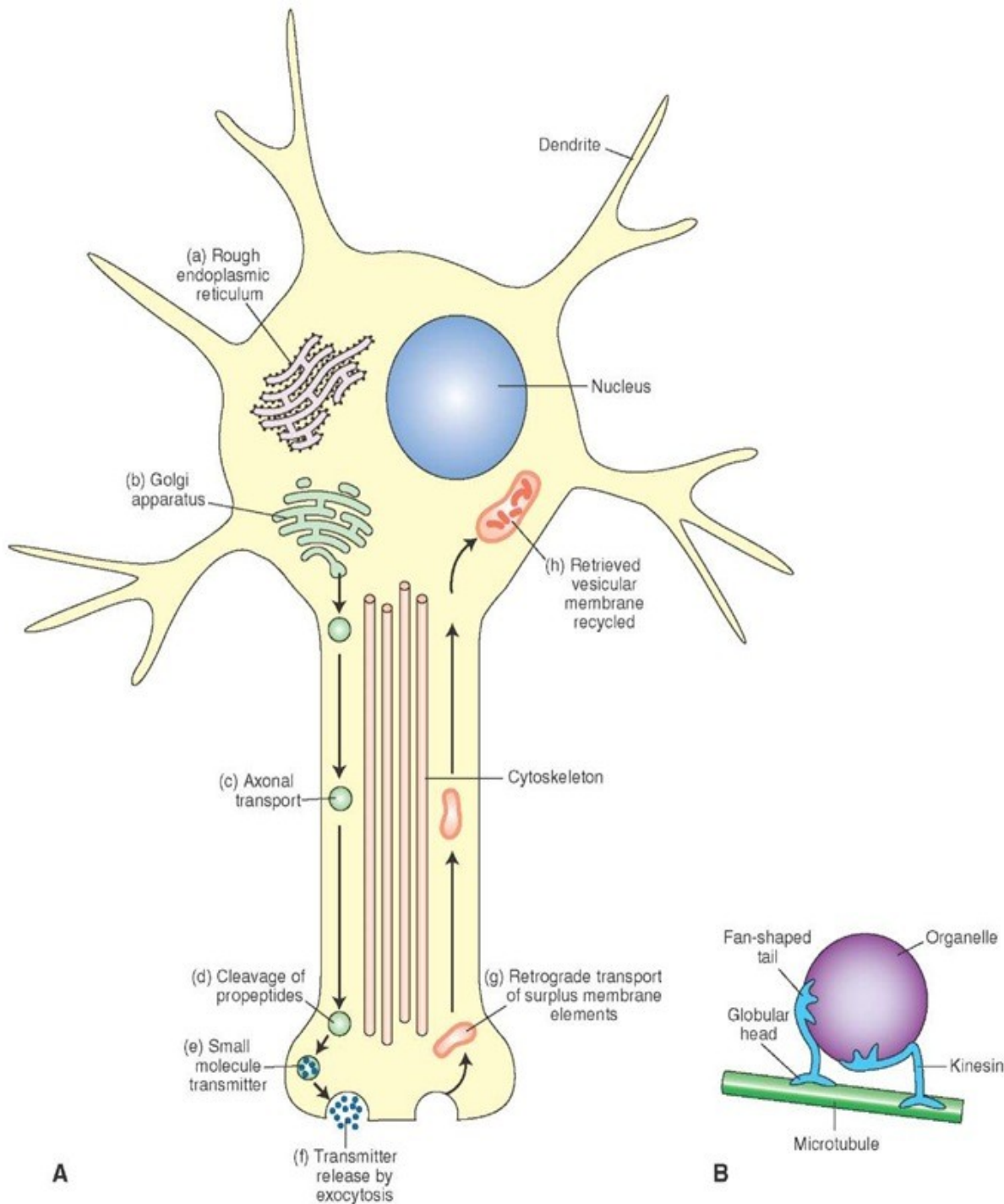
Nisslova tělíska (substance)



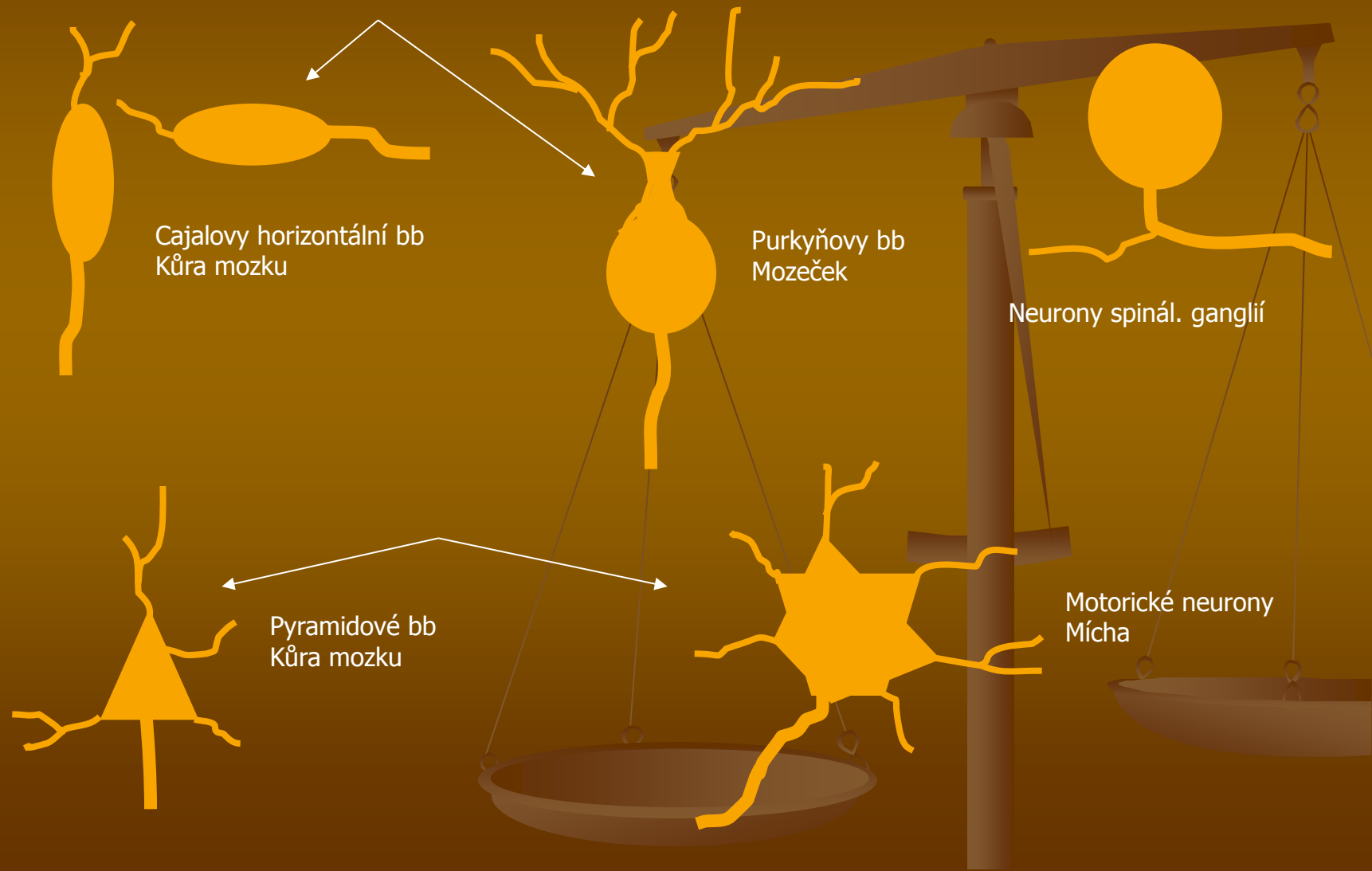
△ perikaryon (pyramidová buňka z cortex cerebri)

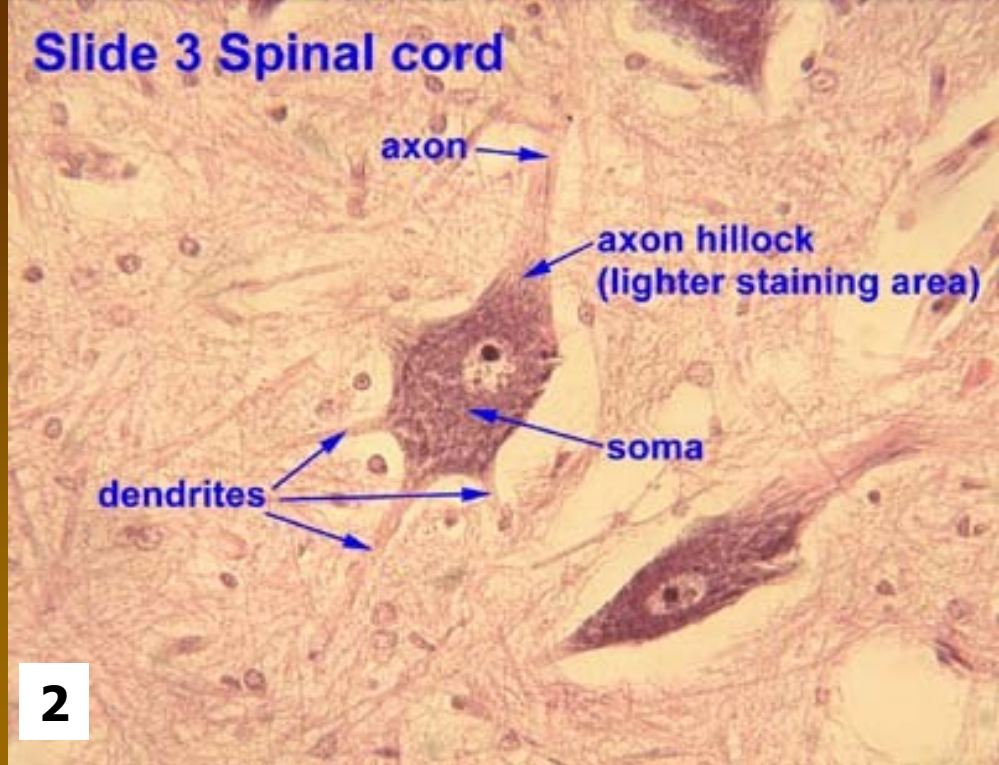
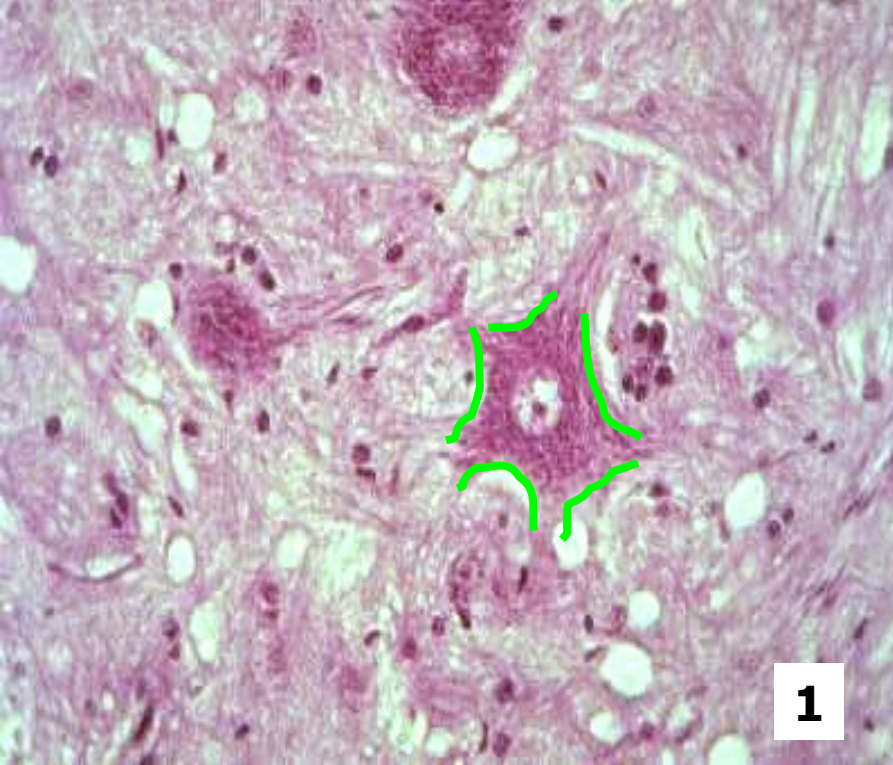


neurotubuly neurofilamenta



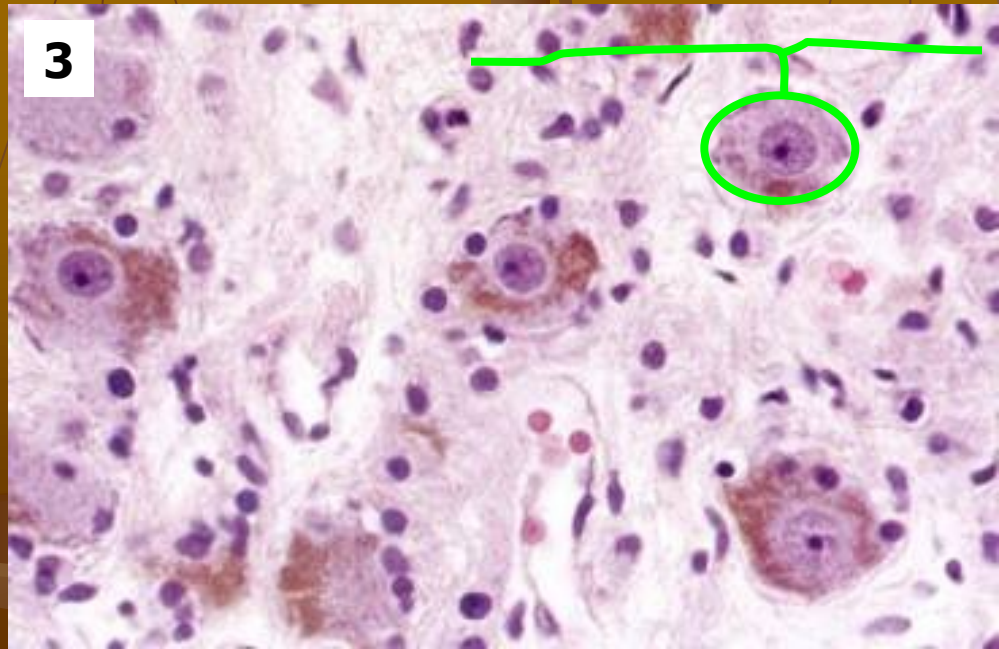
Tvar perikarya





1, 2 – multipolár. neurony: Nisslova tělíska

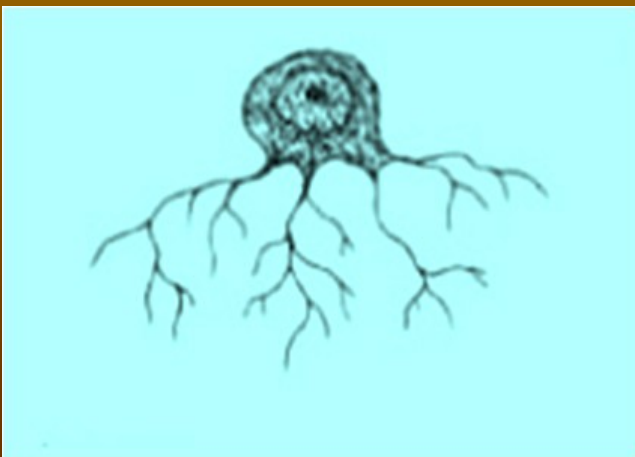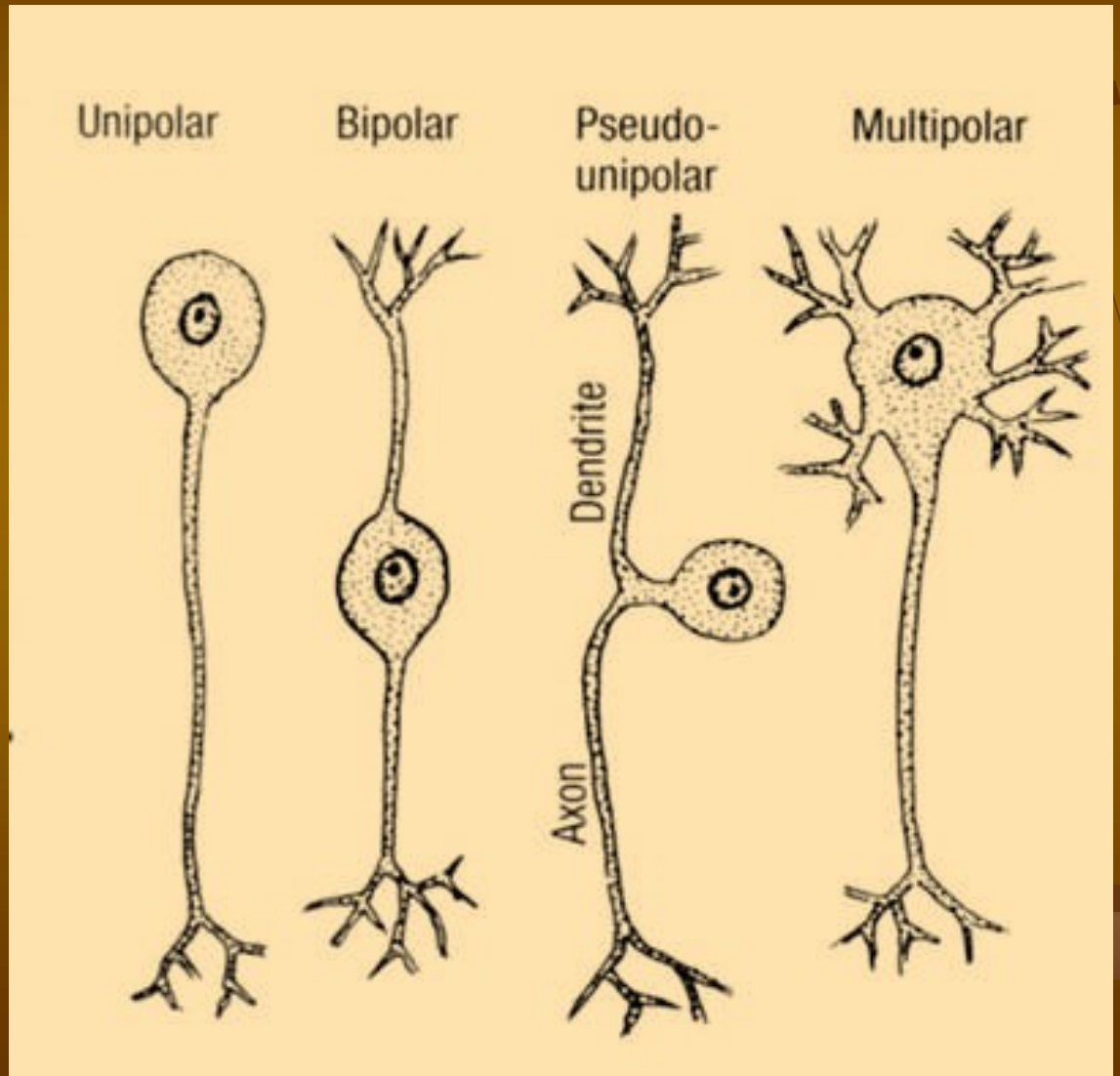
3 – pseudounipolár. neurony: lipofuscin



Klasifikace neuronů

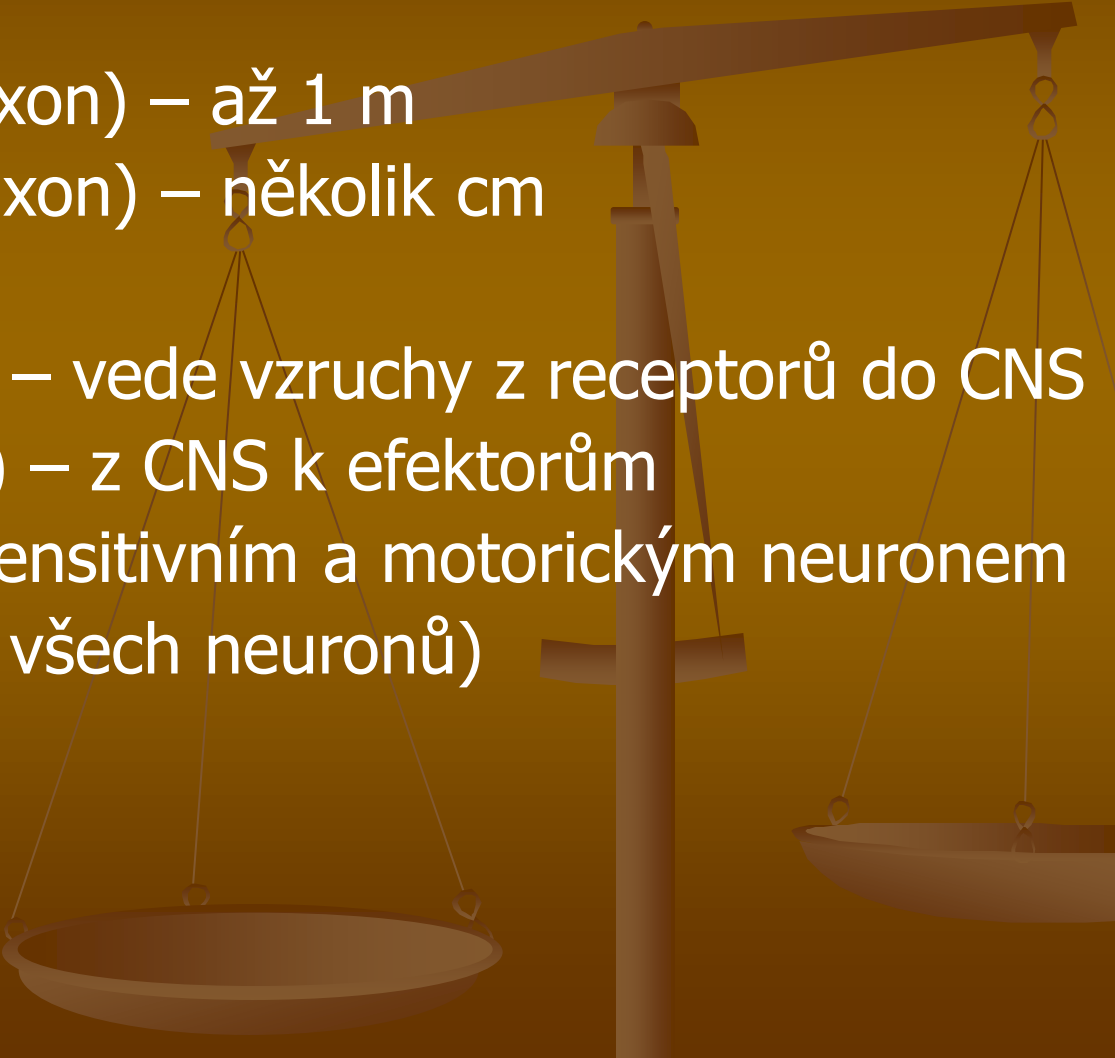
(dle počtu výběžků)

- Unipolární
- Bipolární
- Pseudounipolární
- Multipolární
- (Amakrinní)



Další dělení neuronů


(podle ...)

- délky axonu:
 - Golgi typ I (dlouhý axon) – až 1 m
 - Golgi typ II (krátký axon) – několik cm
 - funkce:
 - senzitivní (aferentní) – vede vzruchy z receptorů do CNS
 - motorický (eferentní) – z CNS k efektorům
 - interneuron – mezi senzitivním a motorickým neuronem (97 % všech neuronů)
- 

Dendrity

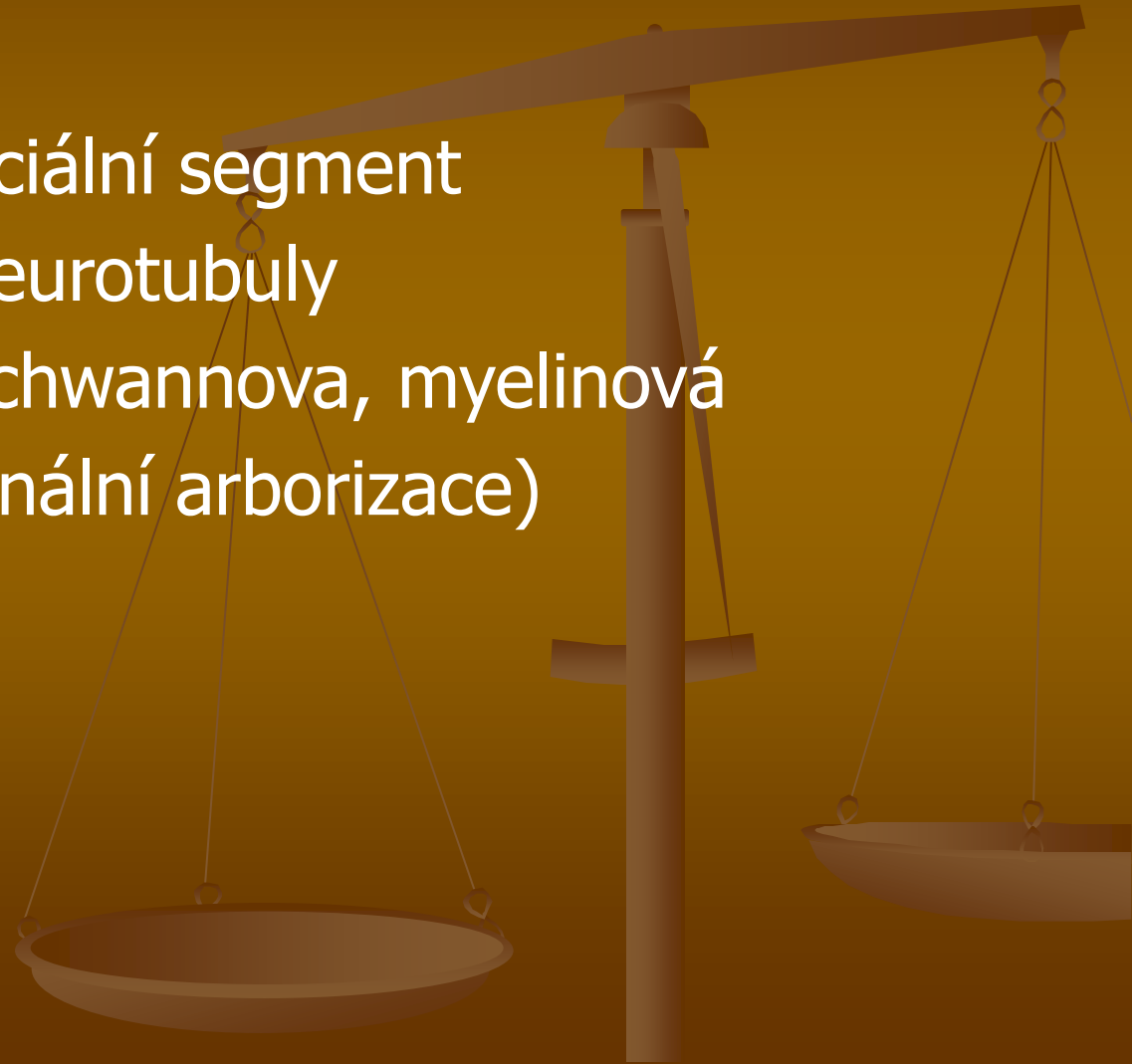
(ř. *dendron*, “strom”)

- krátké, větvené výběžky cytoplazmy,
- centripetální
- **dendritické trny** (součást synapsí)



Axon (neurit)

- dlouhý, hladký, jen oj. kolaterály
- centrifugální
- axonový hrbol, iniciální segment
- neurofilamenta, neurotubuly
- obaly (pochvy): Schwannova, myelinová
- telodendrie (terminální arborizace)



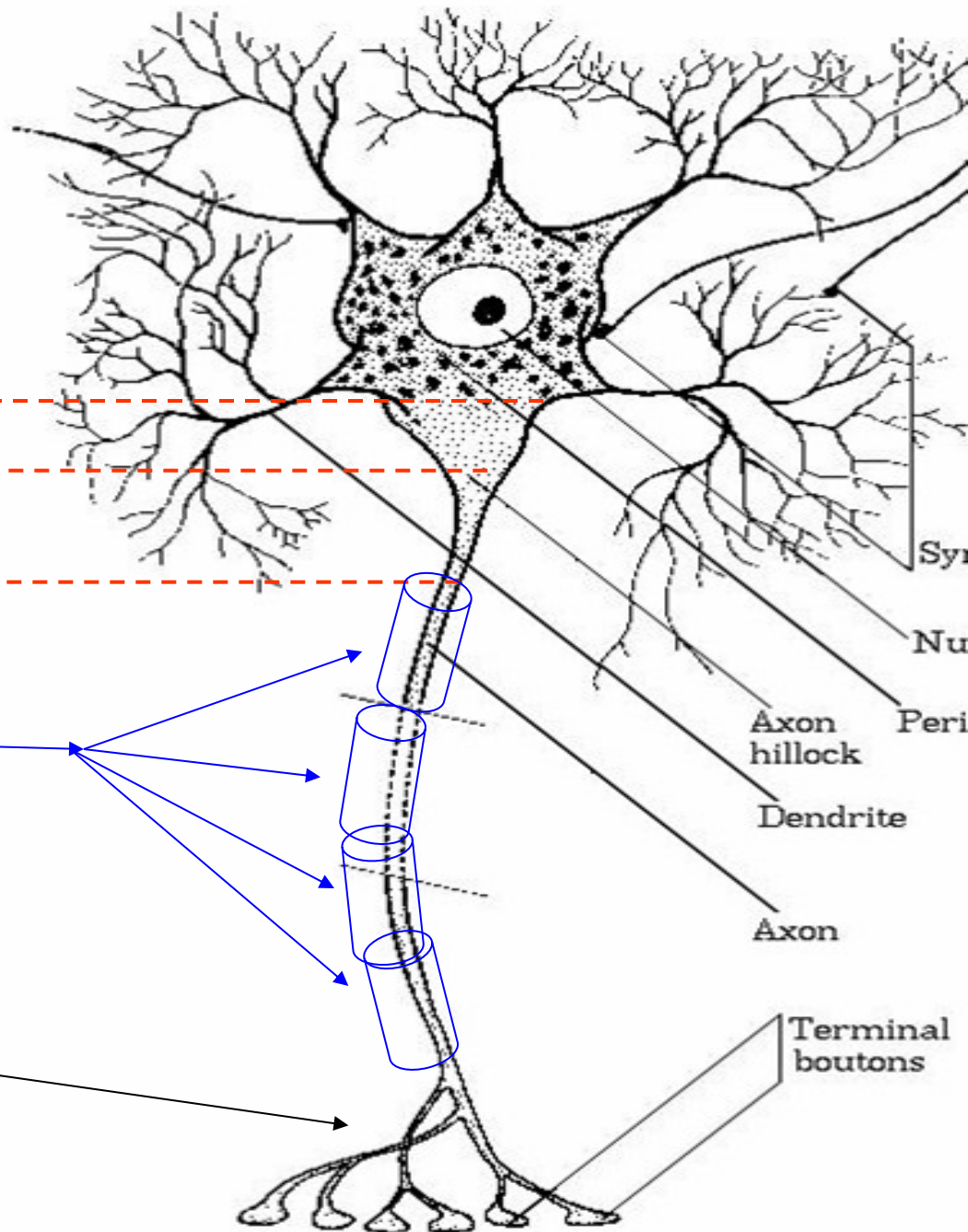
STAVBA AXONU

Axonový hrbol

Iniciální segment

Schwannovy bb

Axonterminály (telodendrion)

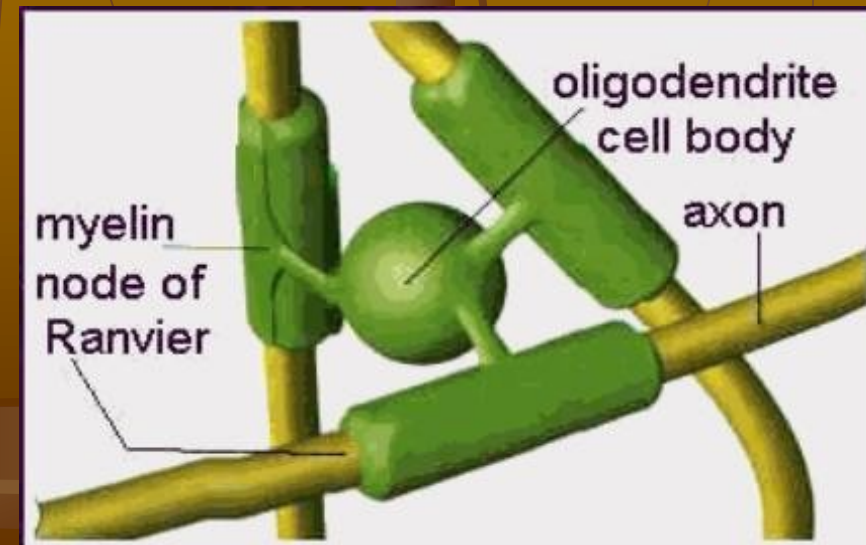
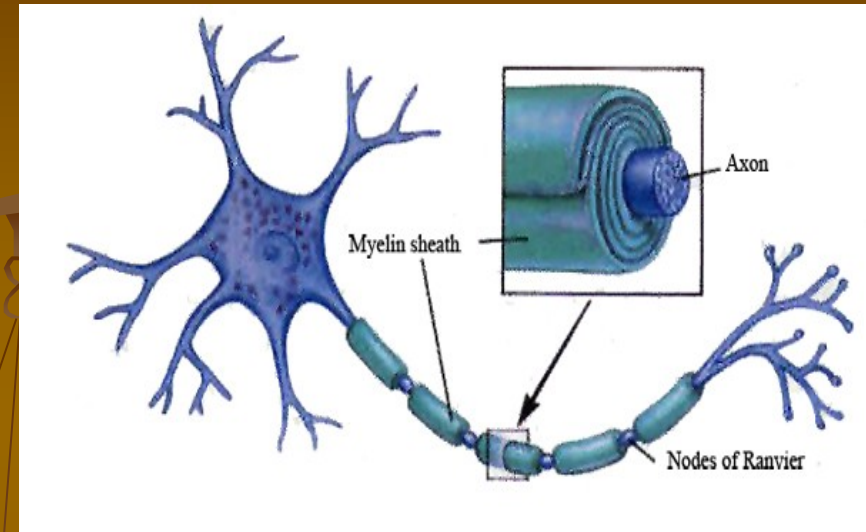


obaly axonů (neuritů)

Schwannovy b. (v PNS)

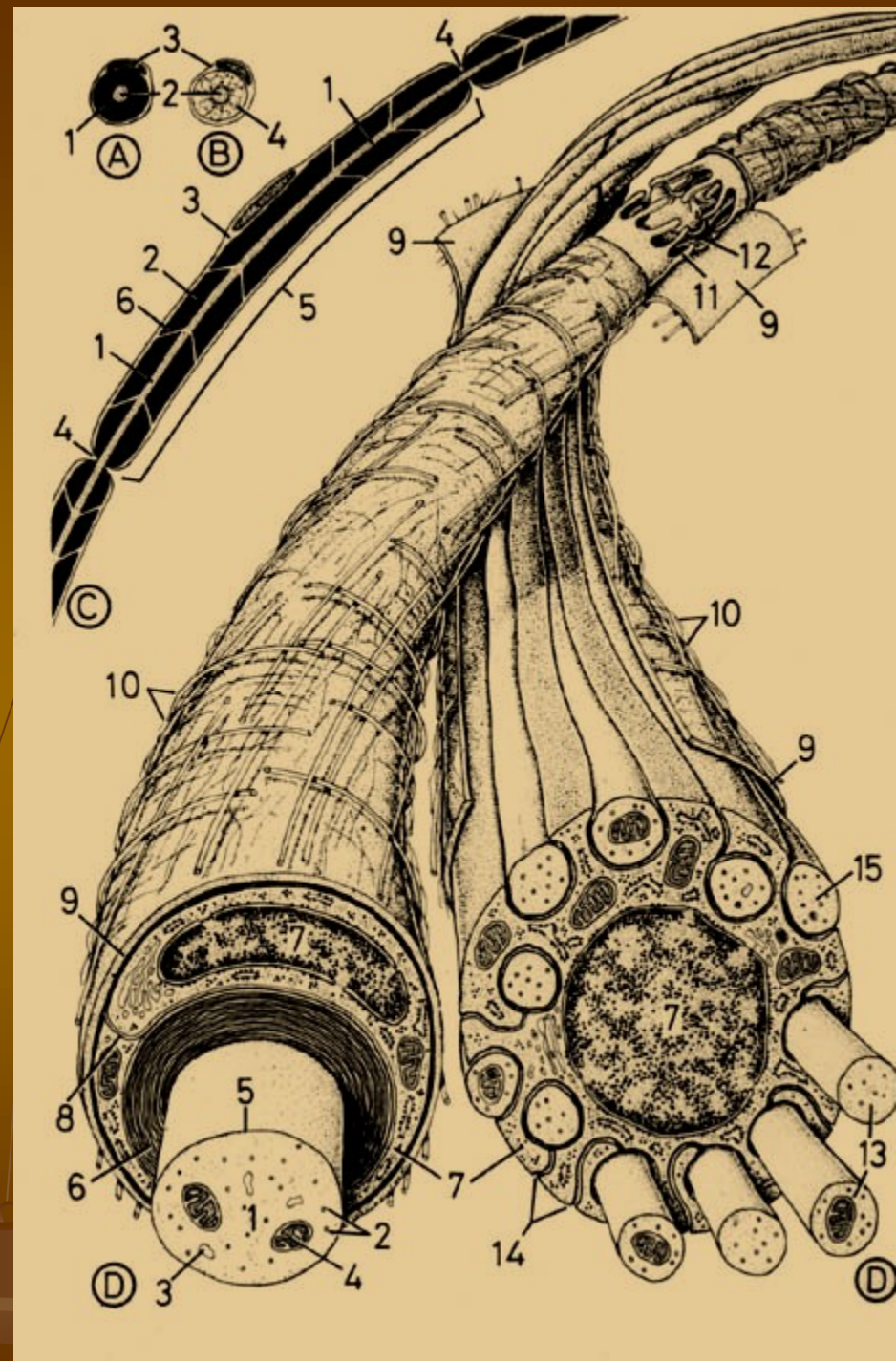
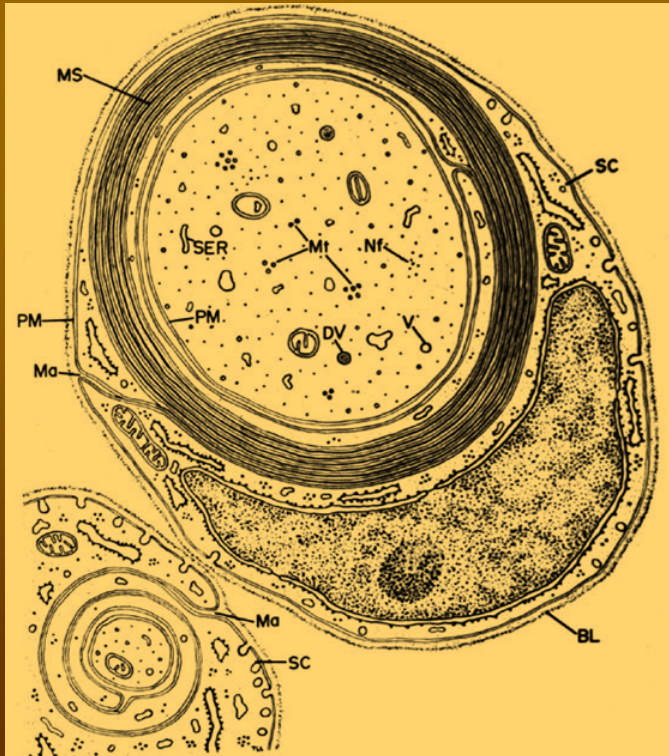
Myelin

Oligodendrocyty (v CNS)



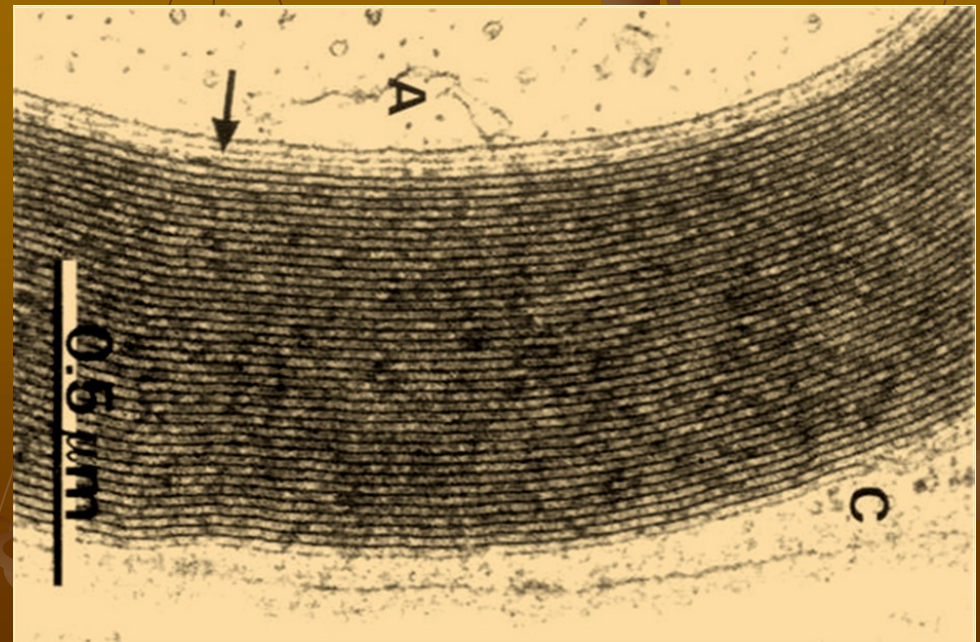
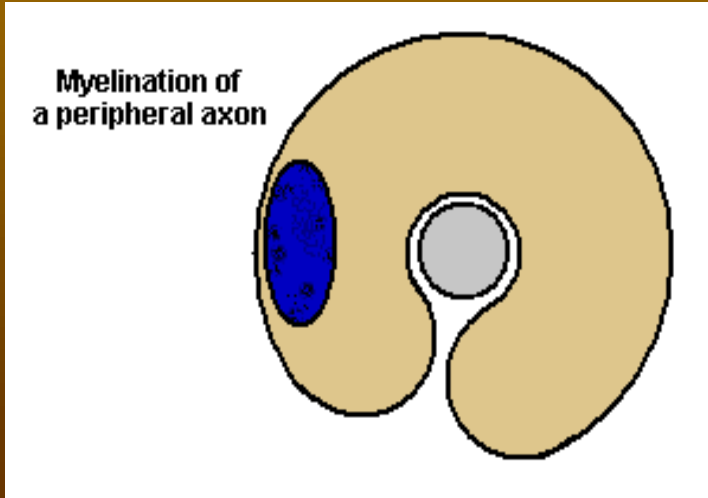
obaly

- myelinová pochva
- Schwannova pochva (v PNS)
- oligodendrocyty (v CNS)



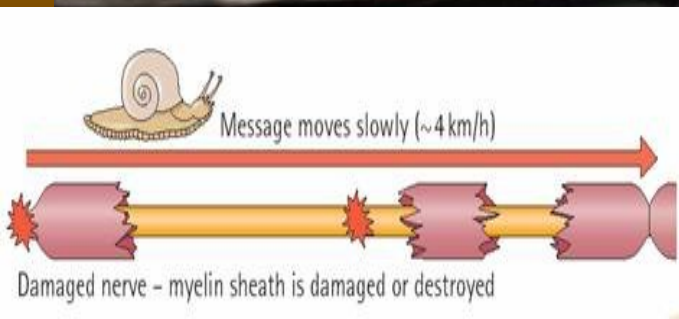
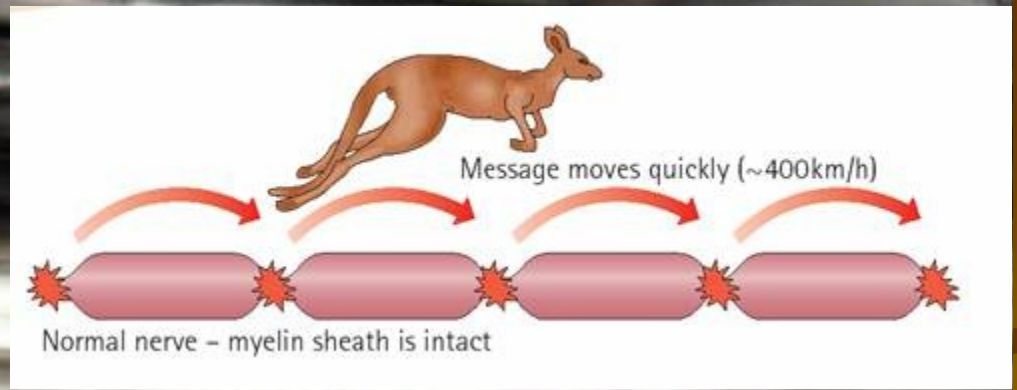
Myelinová pochva

- 1 - 20 μm \leftrightarrow
- 70 % H_2O , lipidy, proteiny
- koncentricky uspořádané lamely lipoproteinů
- Ranvierovy zářezy; internodia (Ranvier. segmenty, 0,6–2,0 mm \leftrightarrow)

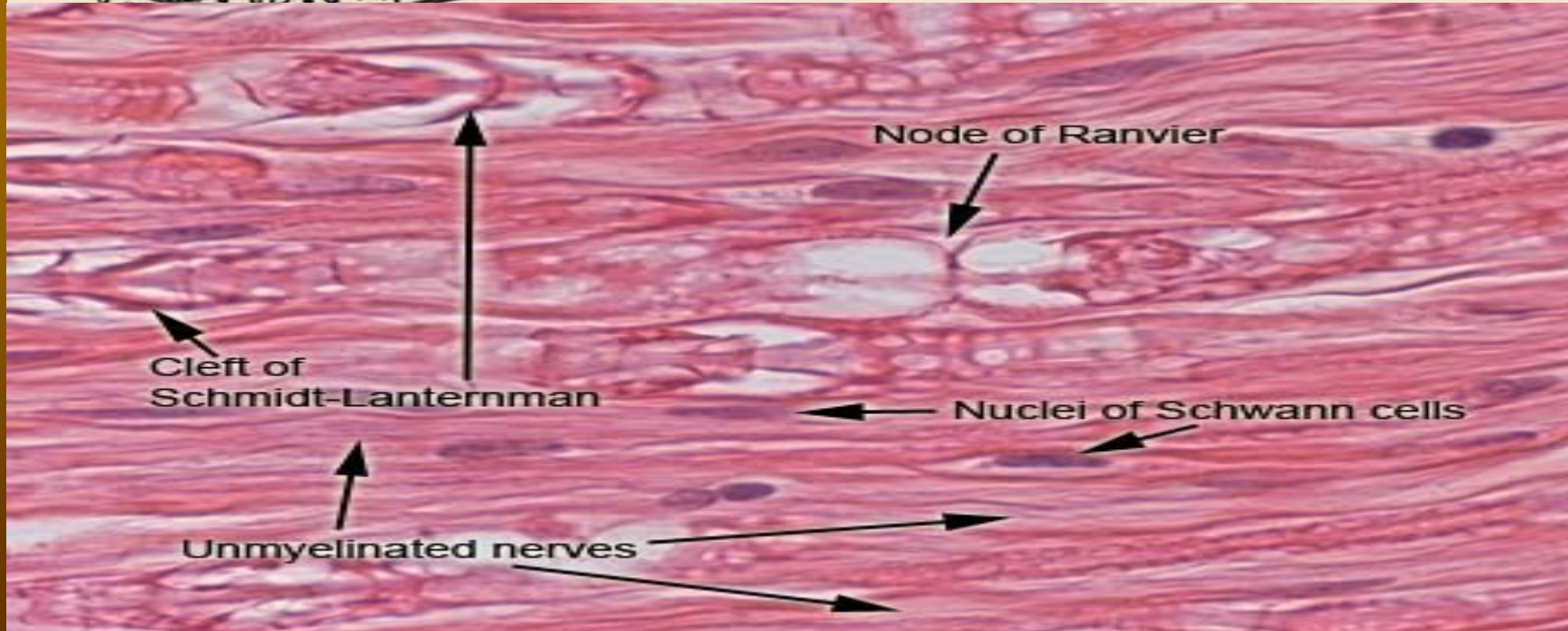
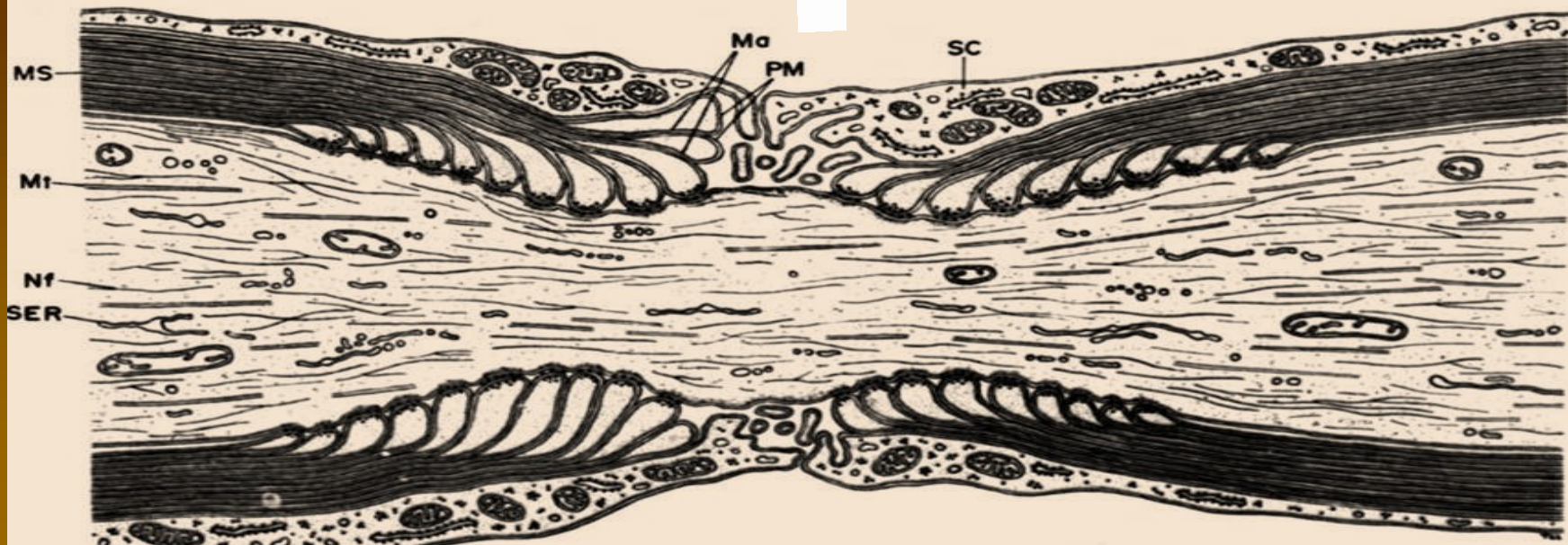


Ranvierovy zářezy

- saltatorní vedení (skokem)

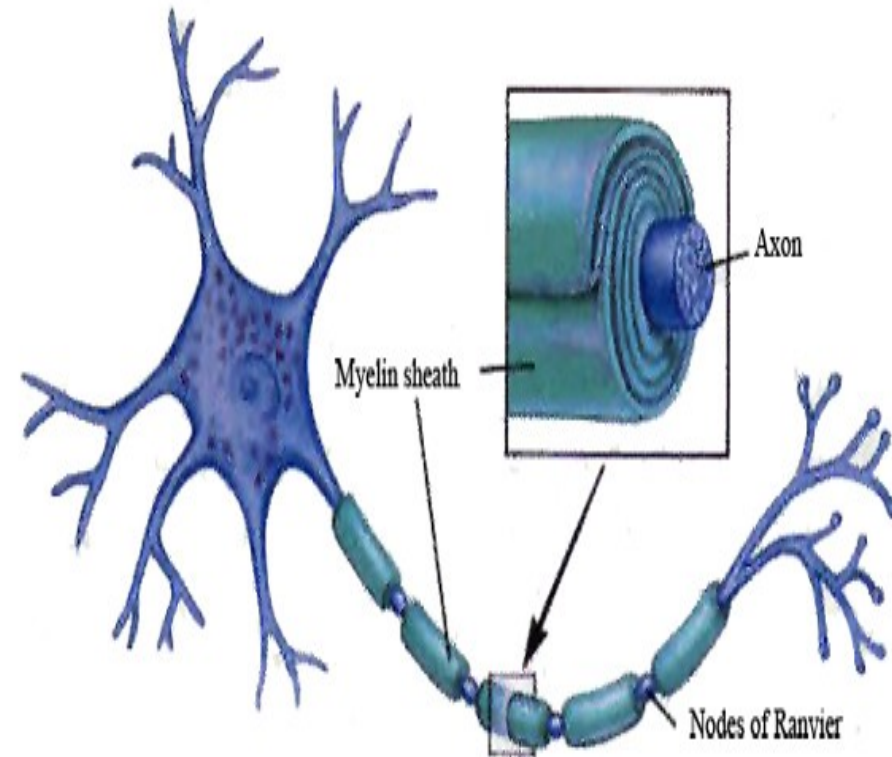
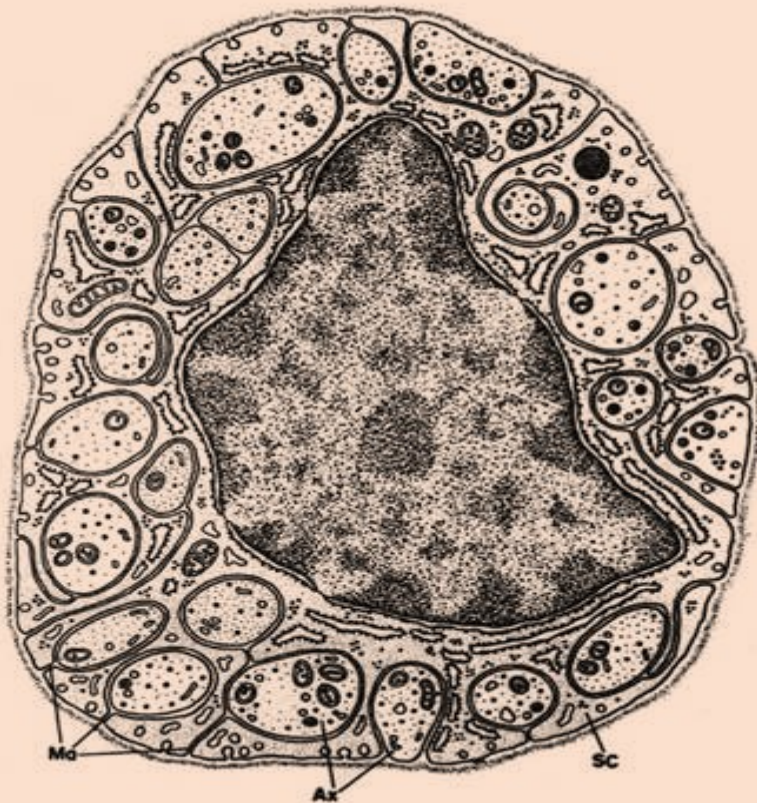

20 μ m

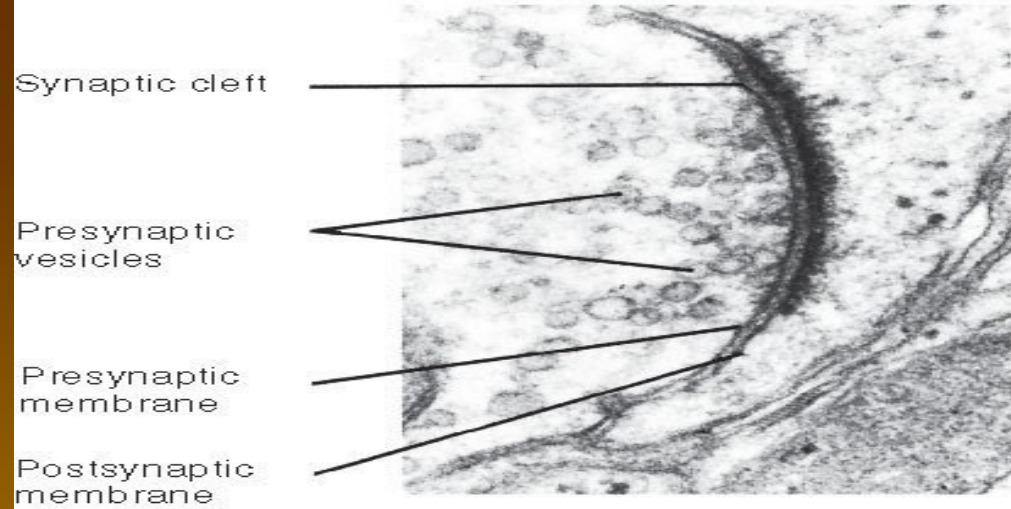


Neurilema = Schwannovy bb.

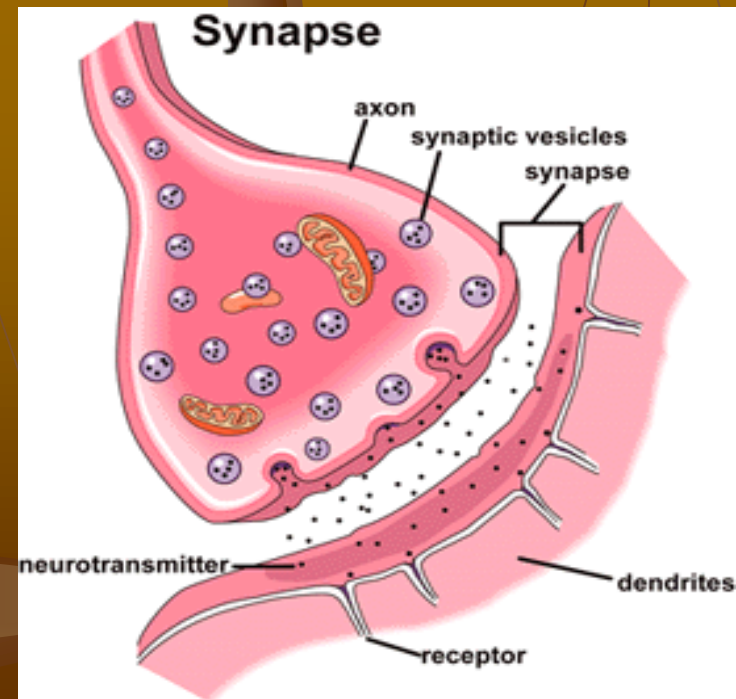
- vlákna bez myelin. pochvy – (jen Schwannovy bb. kolem axonu
- myelinizovaná vlákna – každé internodium má „svou“ Schwannovu b.



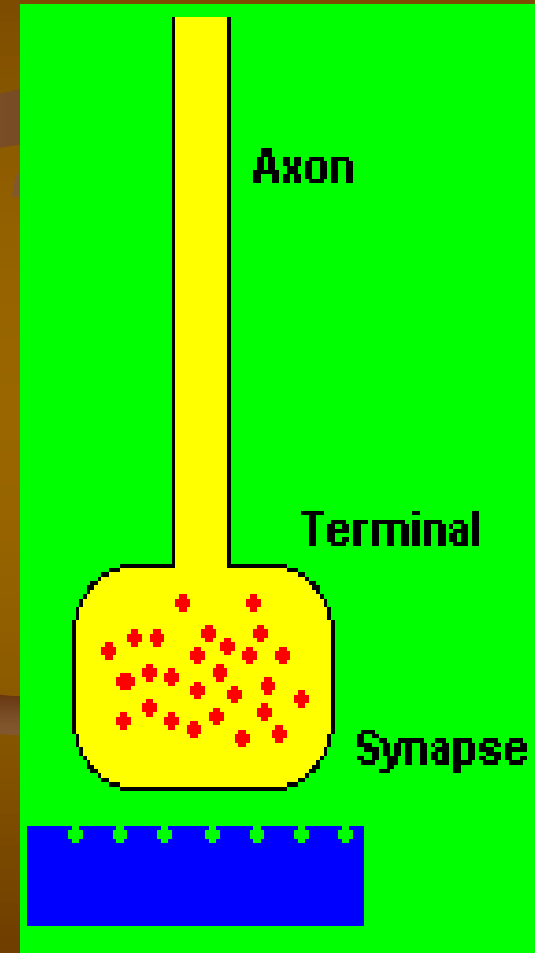
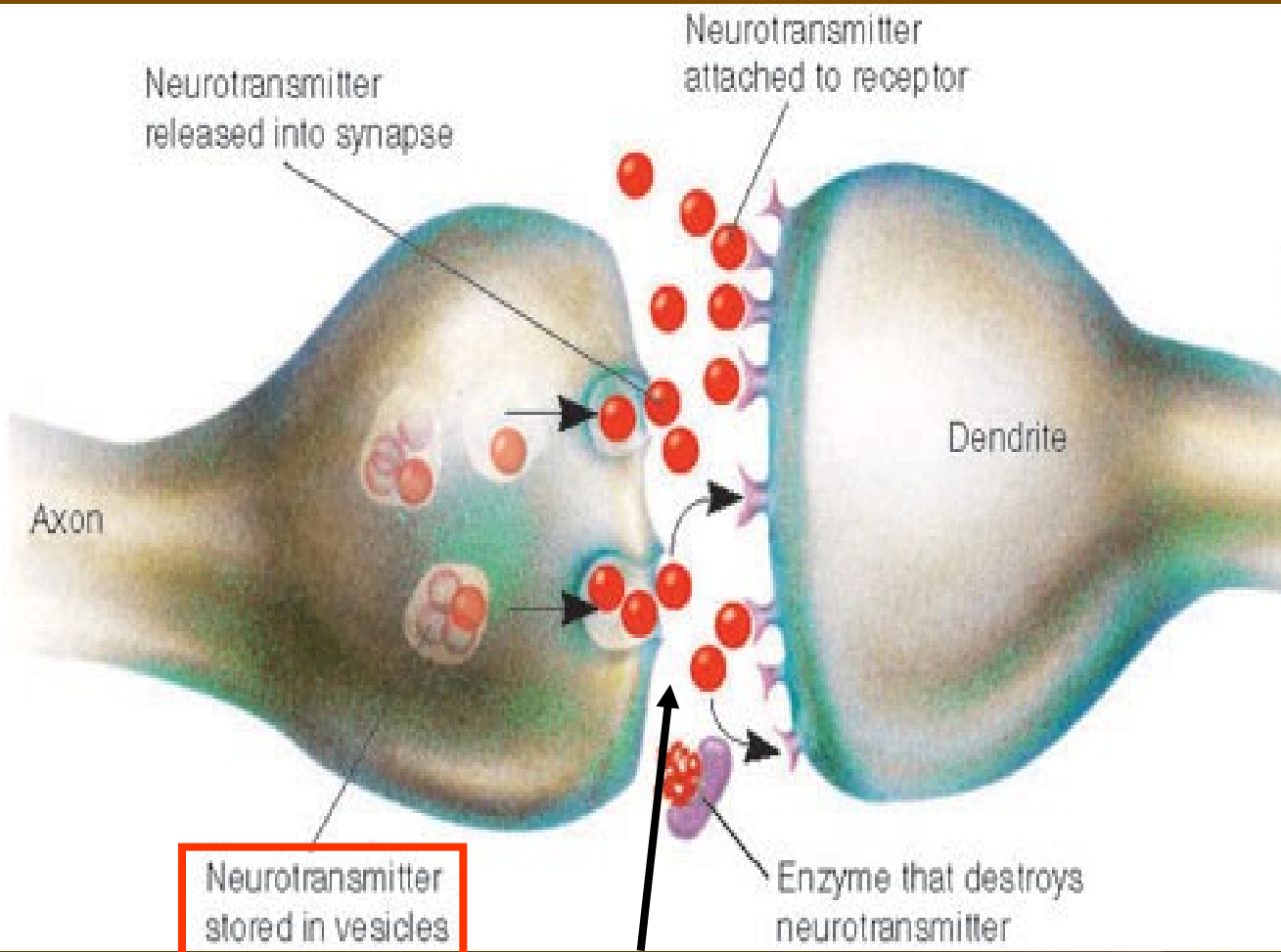
Synapse



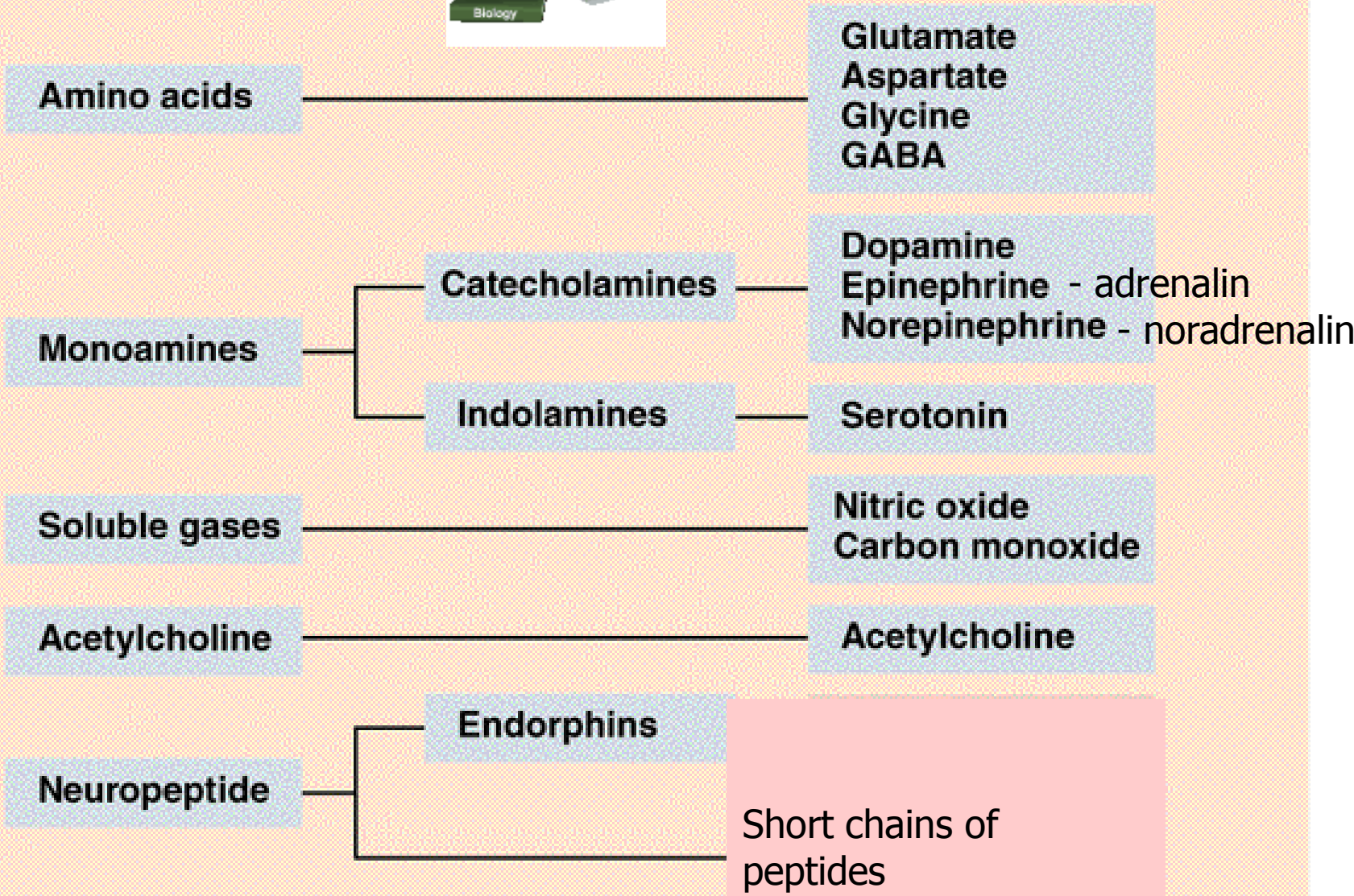

- pro převod vzruchu mezi 2 neurony nebo neuronem a efektorovou b.,
- chemická nebo elektrická synapse,
- úseky synapse:
 - 1) presynaptické zakončení
 - 2) synaptická štěrbiná
 - 3) postsynaptická membrána




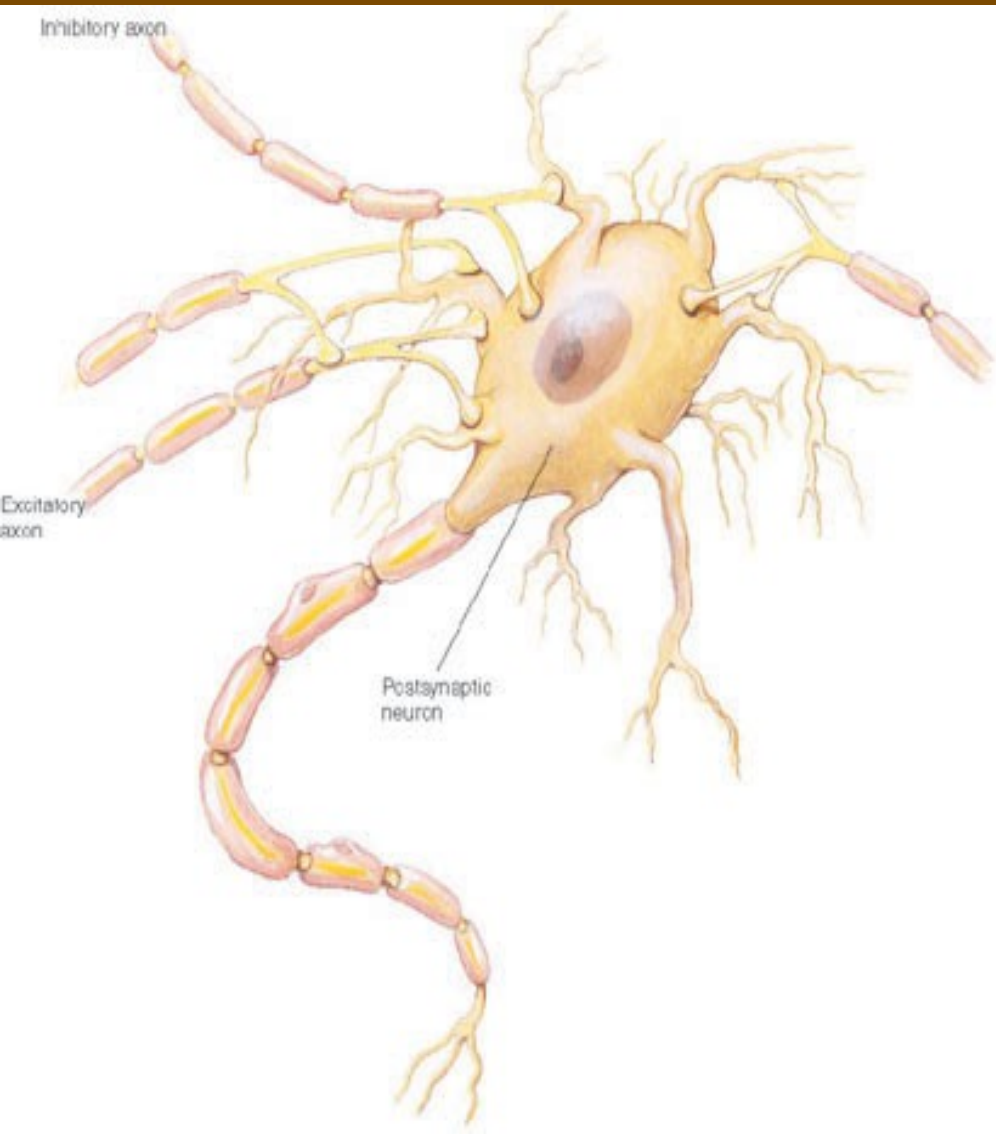
Funkce synapse



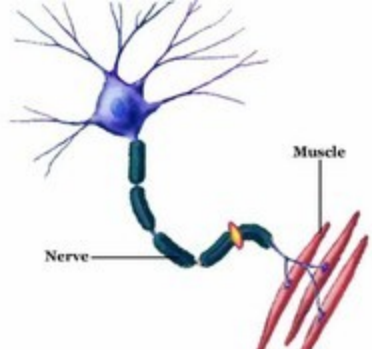
► Classes of Neurotransmitters



neuron – neuron synapse

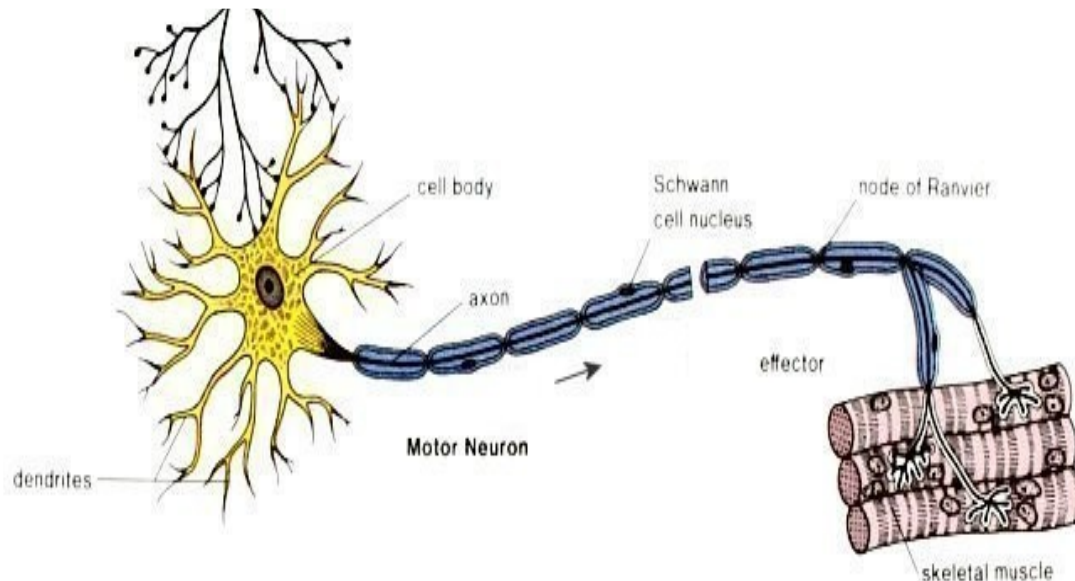
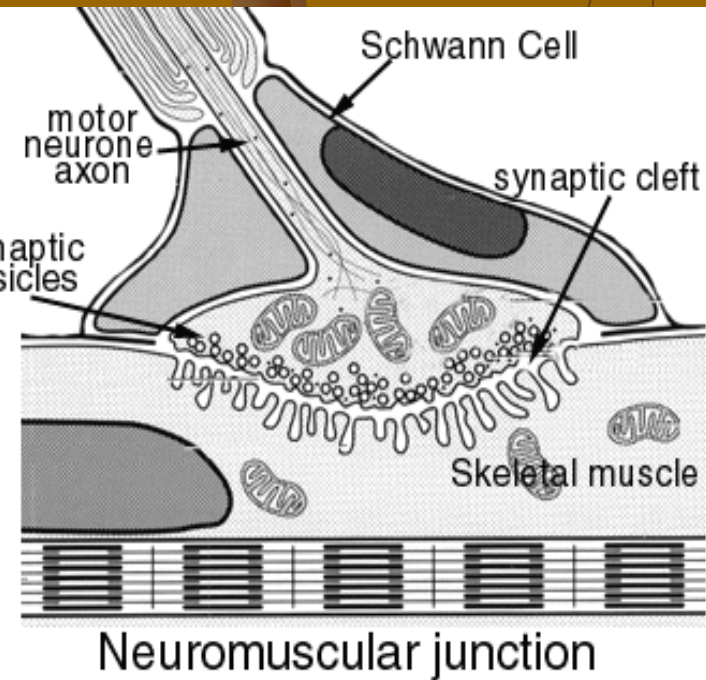
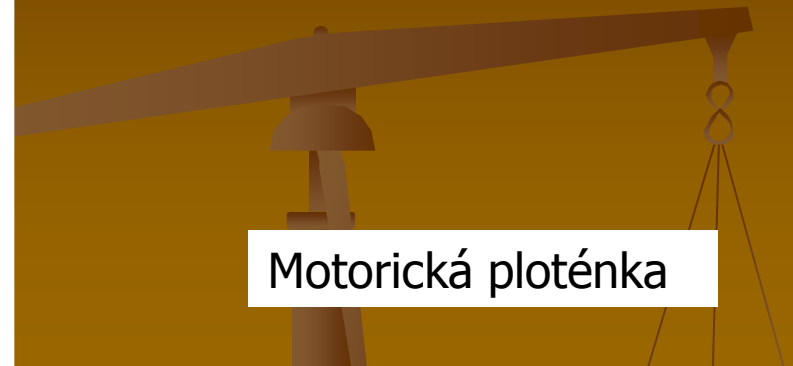

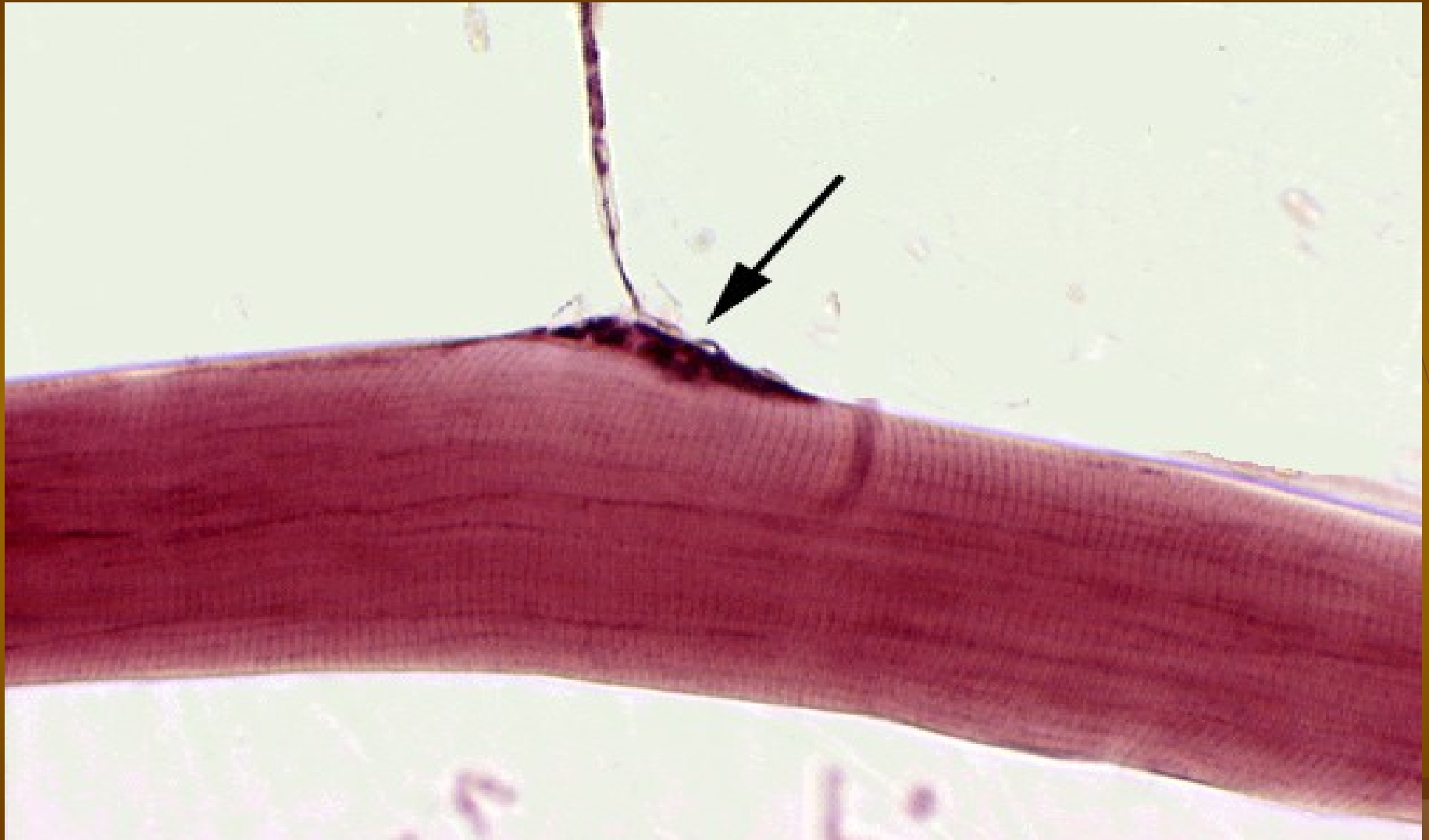Periferní synapse neuron – efektor



Efektorové buňky:

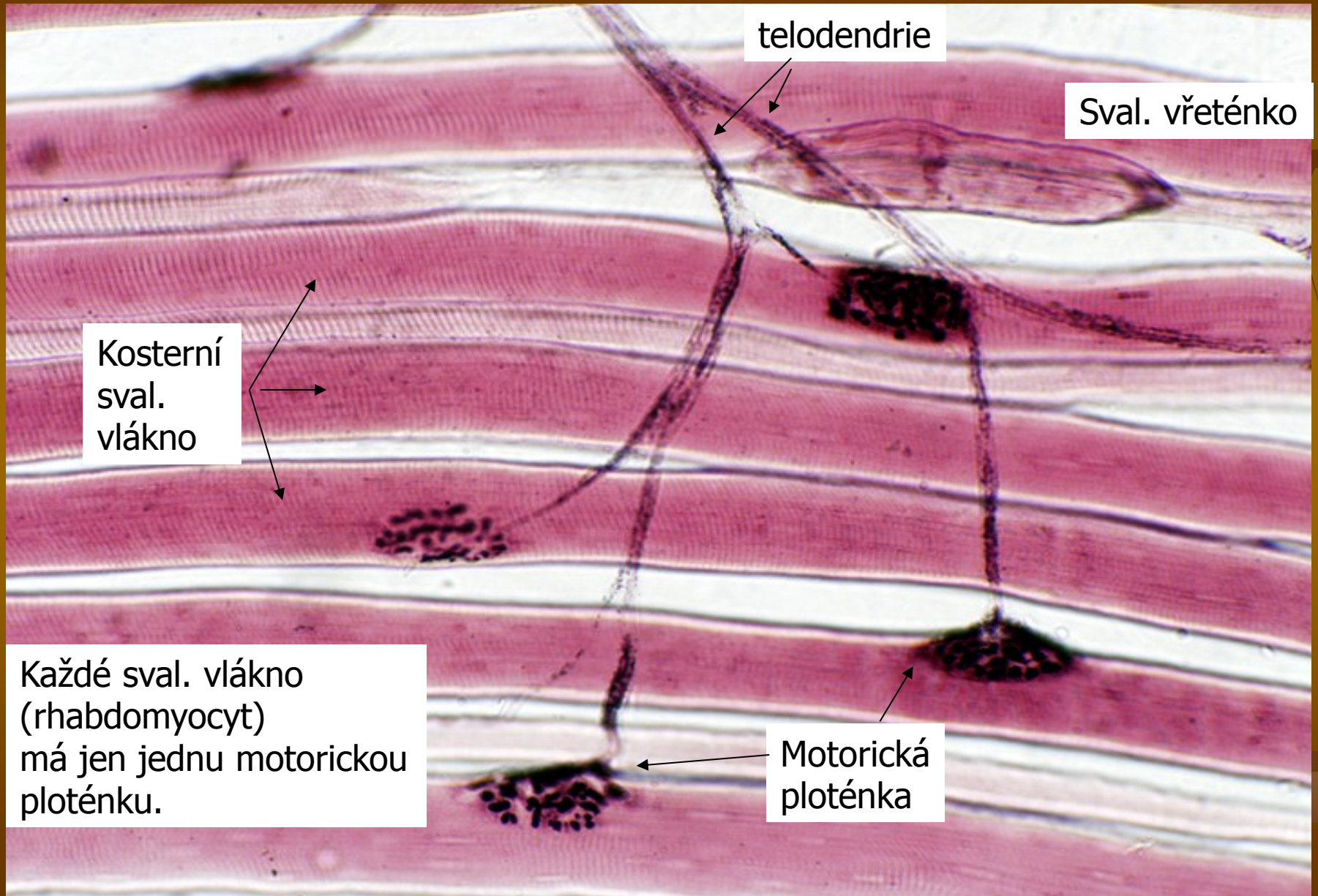
žlázové, svalové (hladká, kosterní, srdeční)
jejich plazmalema představuje postsynaptickou membránu



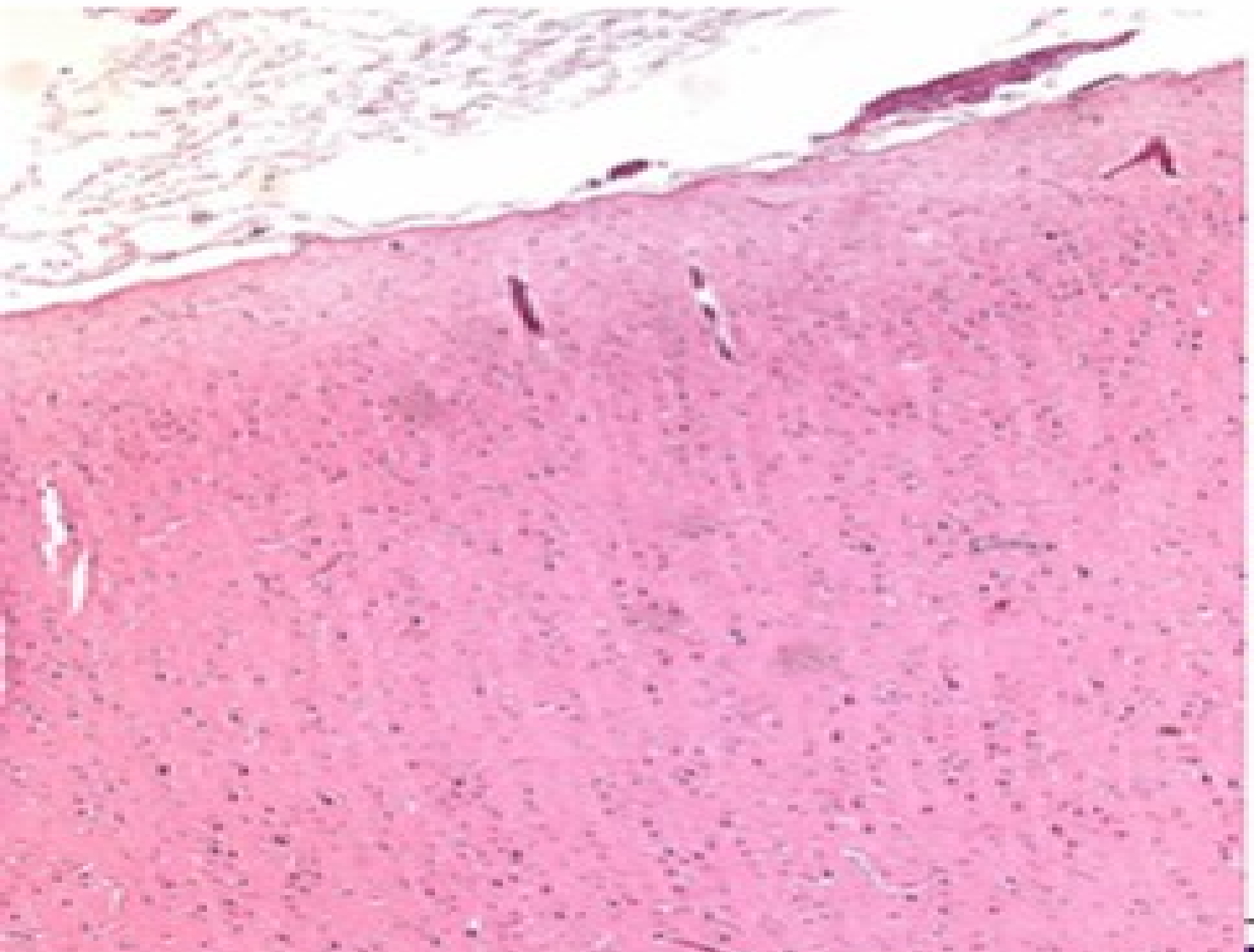


Motorické ploténky v motorické jednotce


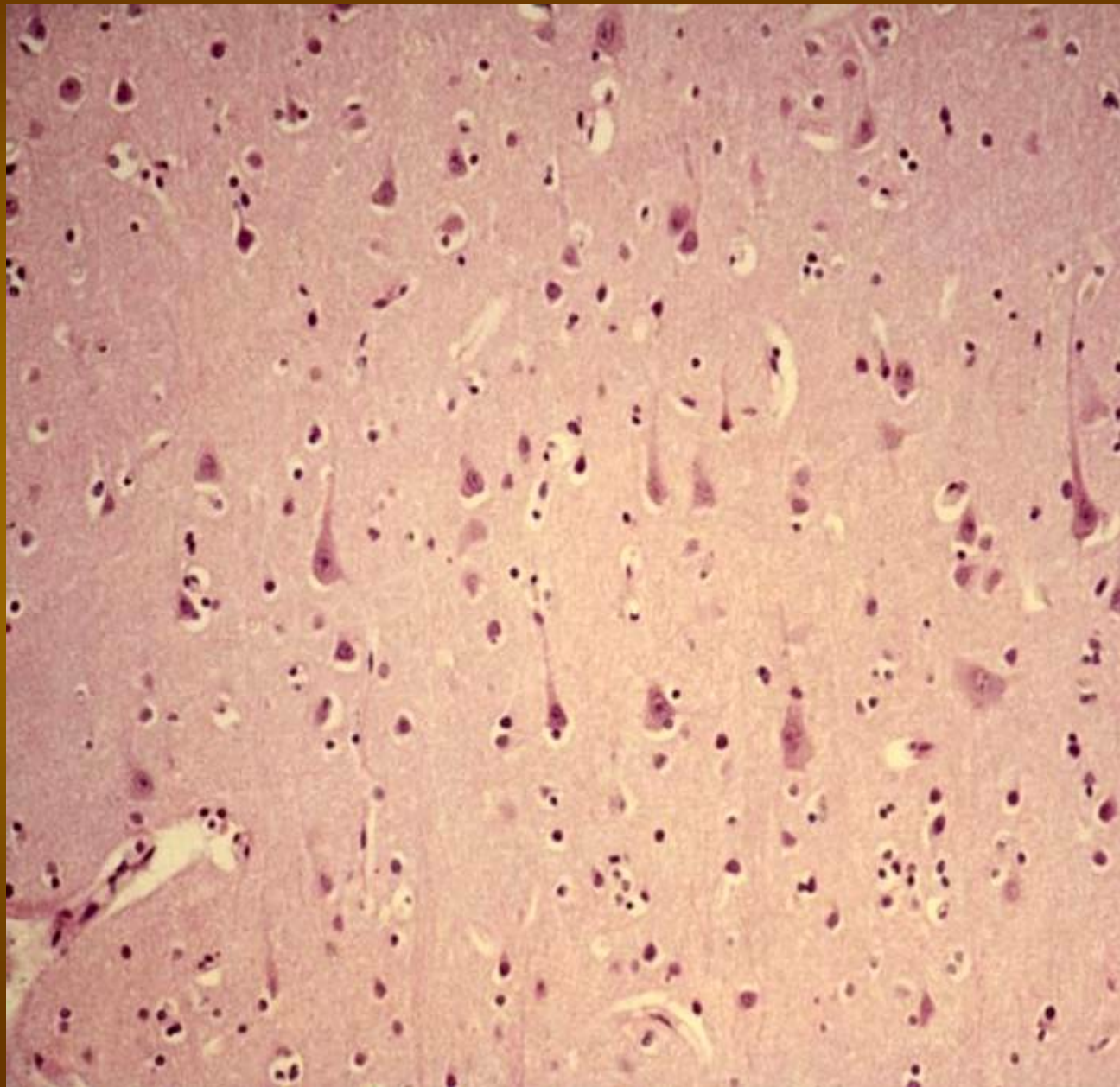
Tato svalová vlákna s kontrahují současně



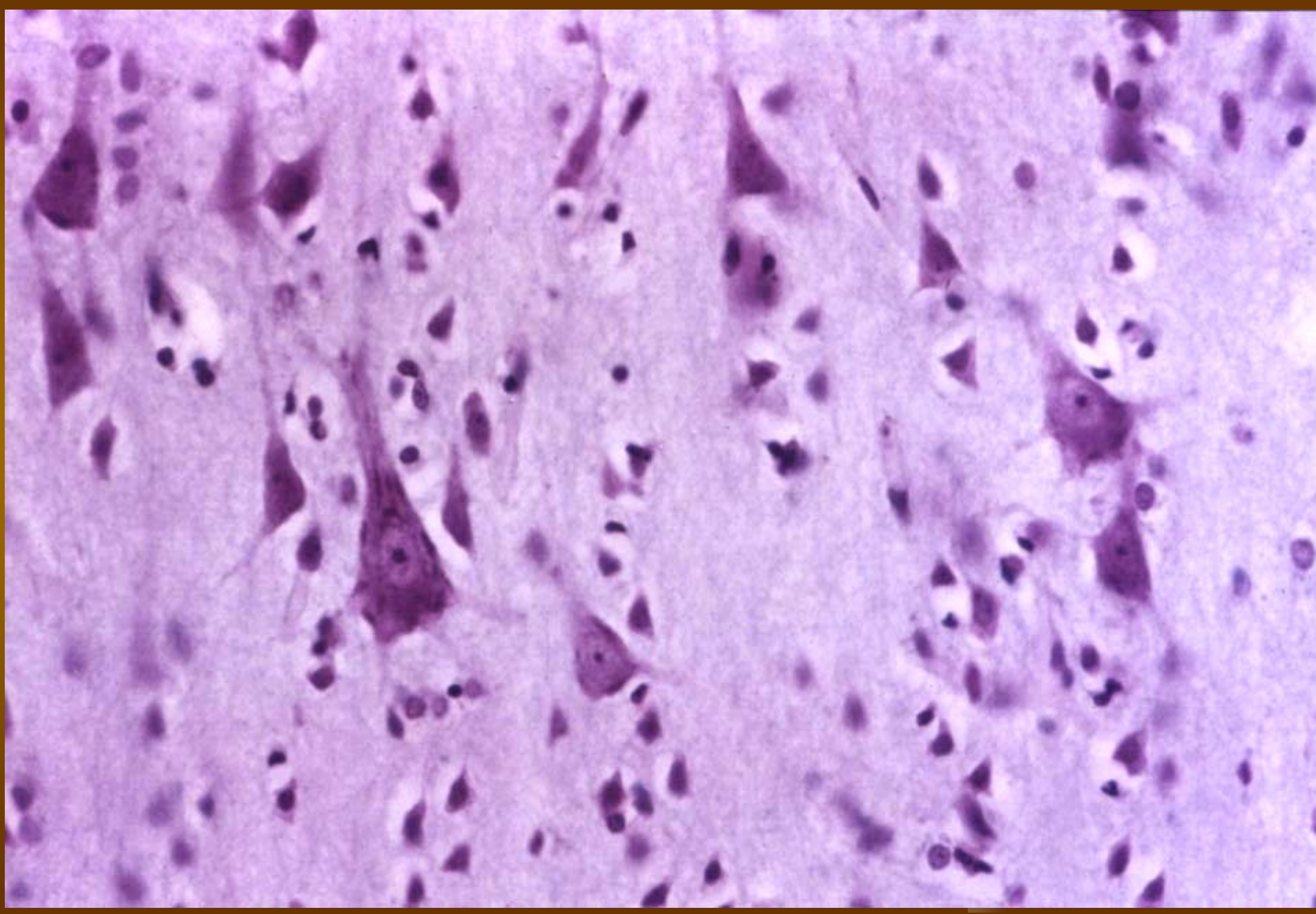
Cortex cerebri



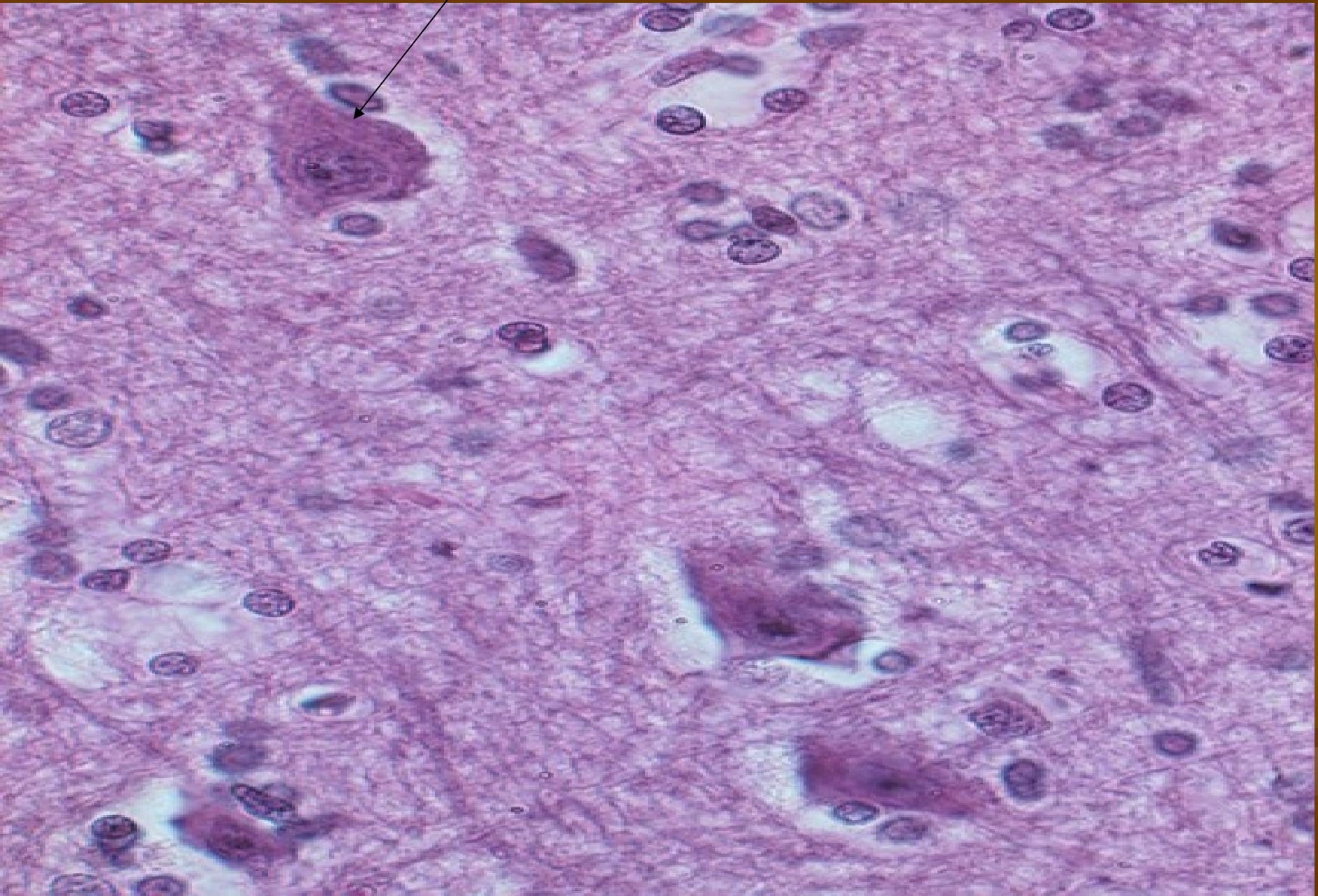
Cortex cerebri (HE) – lamina pyramidalis



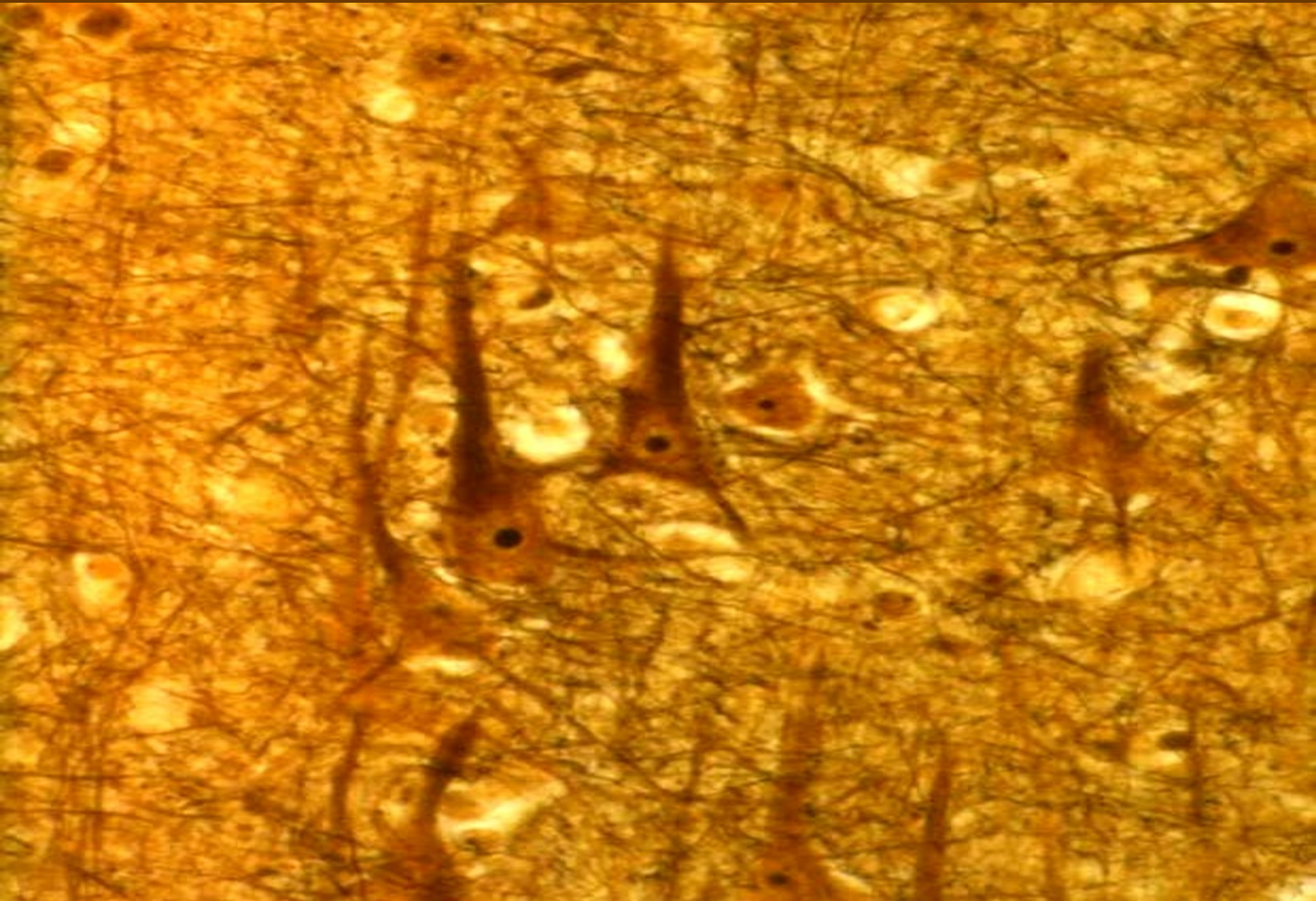
Cortex cerebri (HE) – velké pyramidové buňky = multipolární neurony



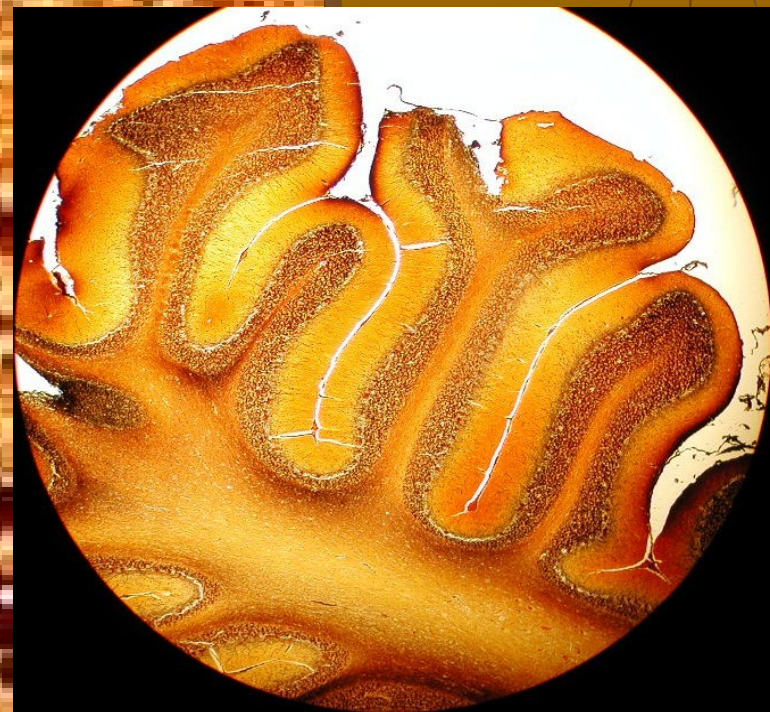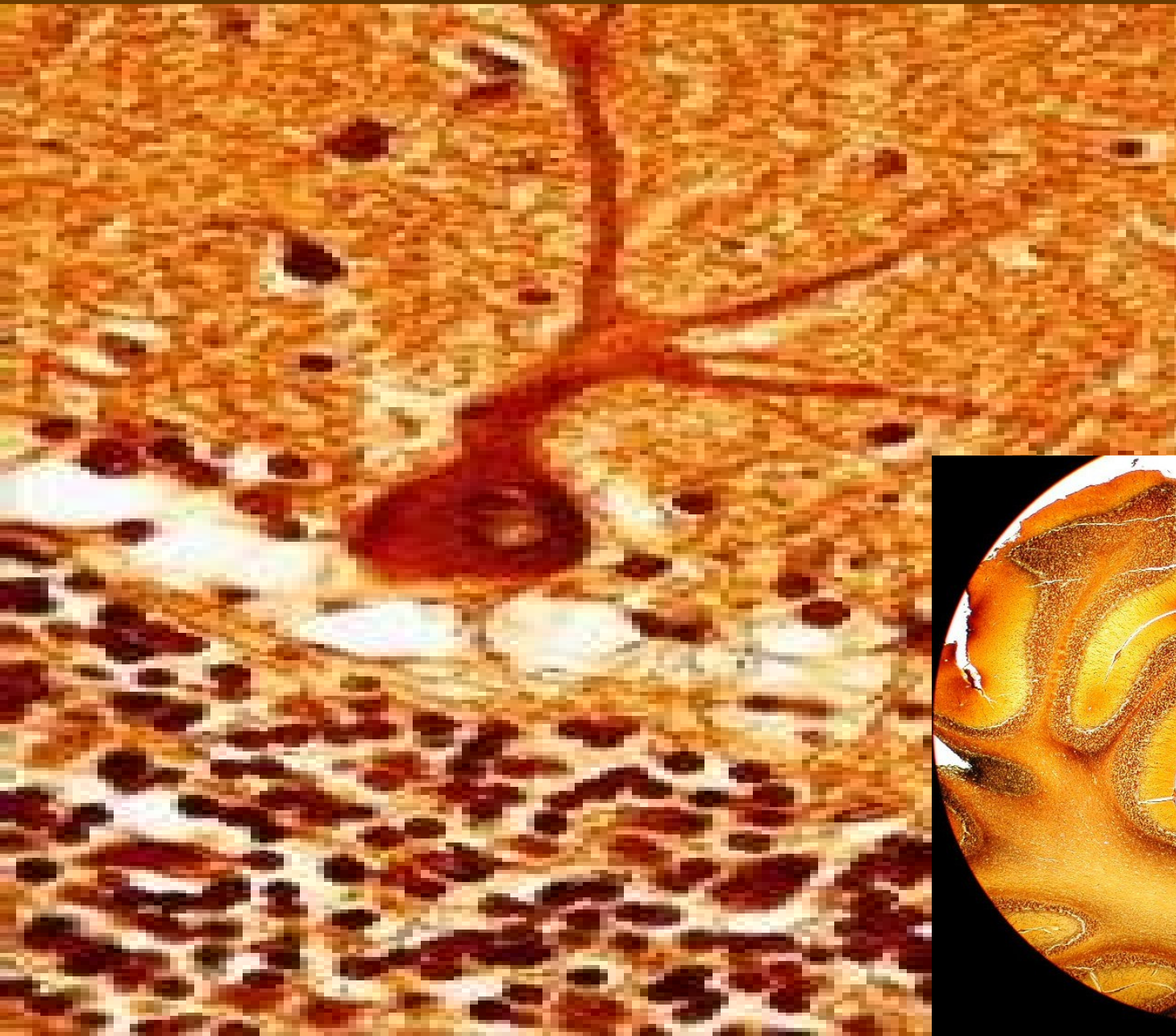
Cortex cerebri (HE) – pyramidové buňky



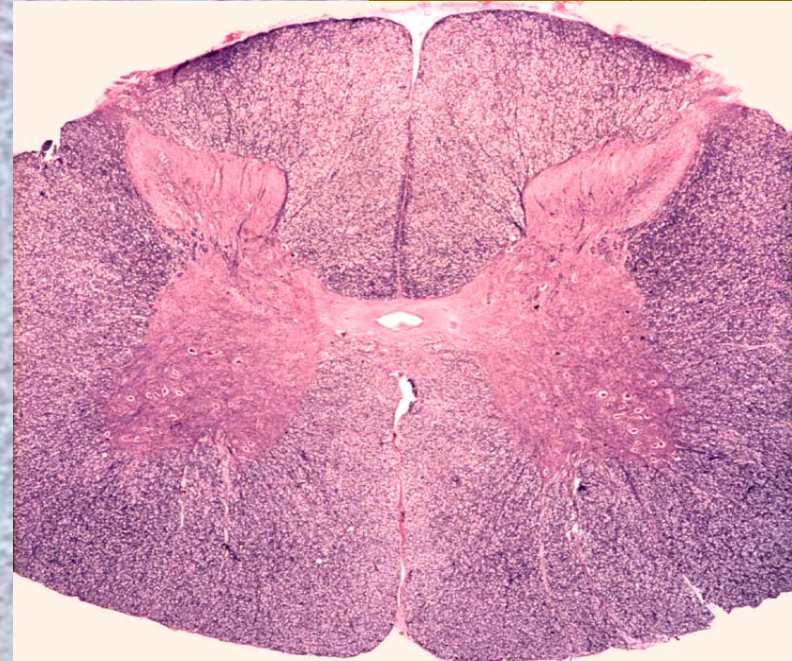
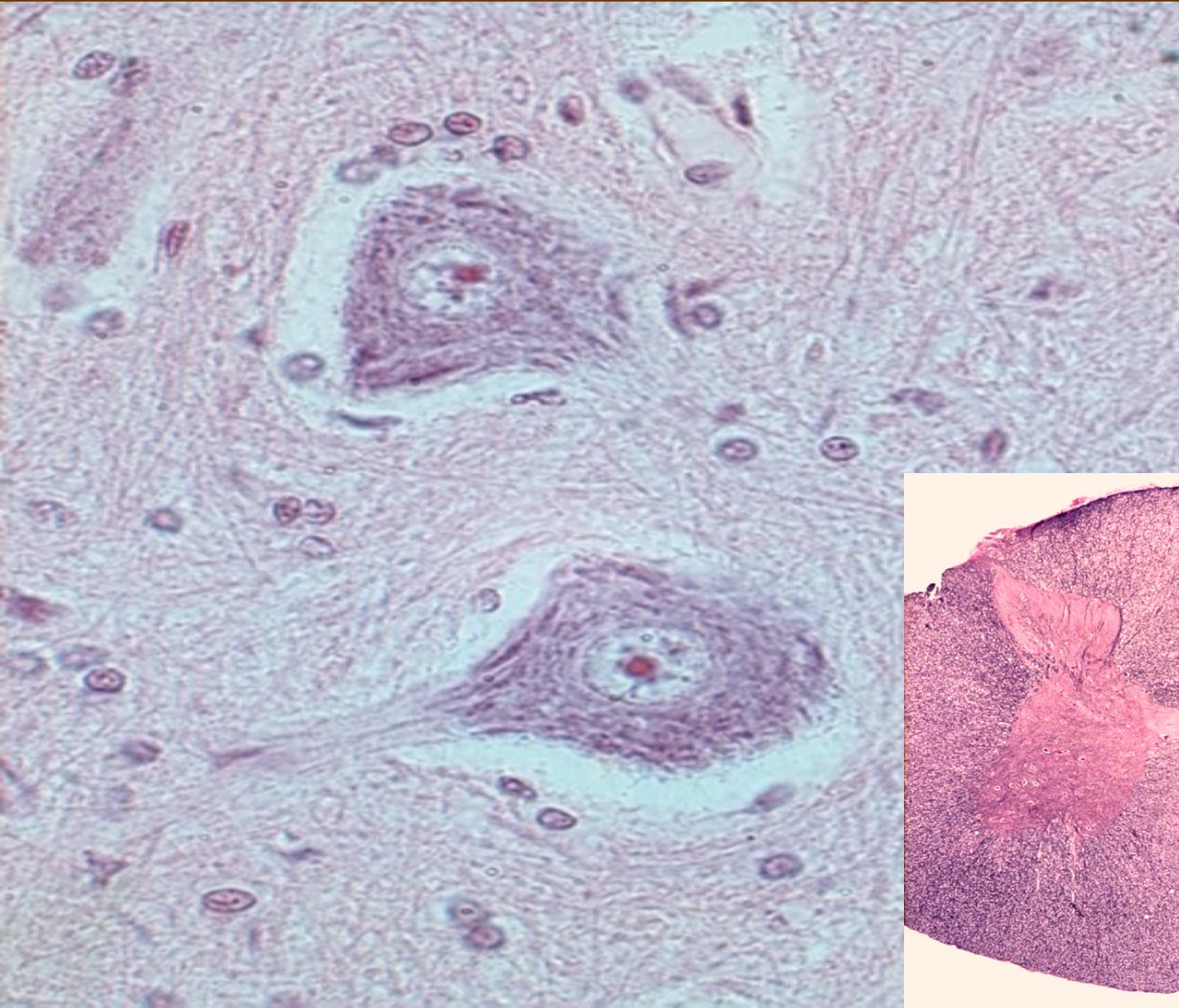
Cortex cerebri (impregnace) – pyramidové buňky



Cerebellum (impregnace) – Purkyňovy buňky = bipolární neurony

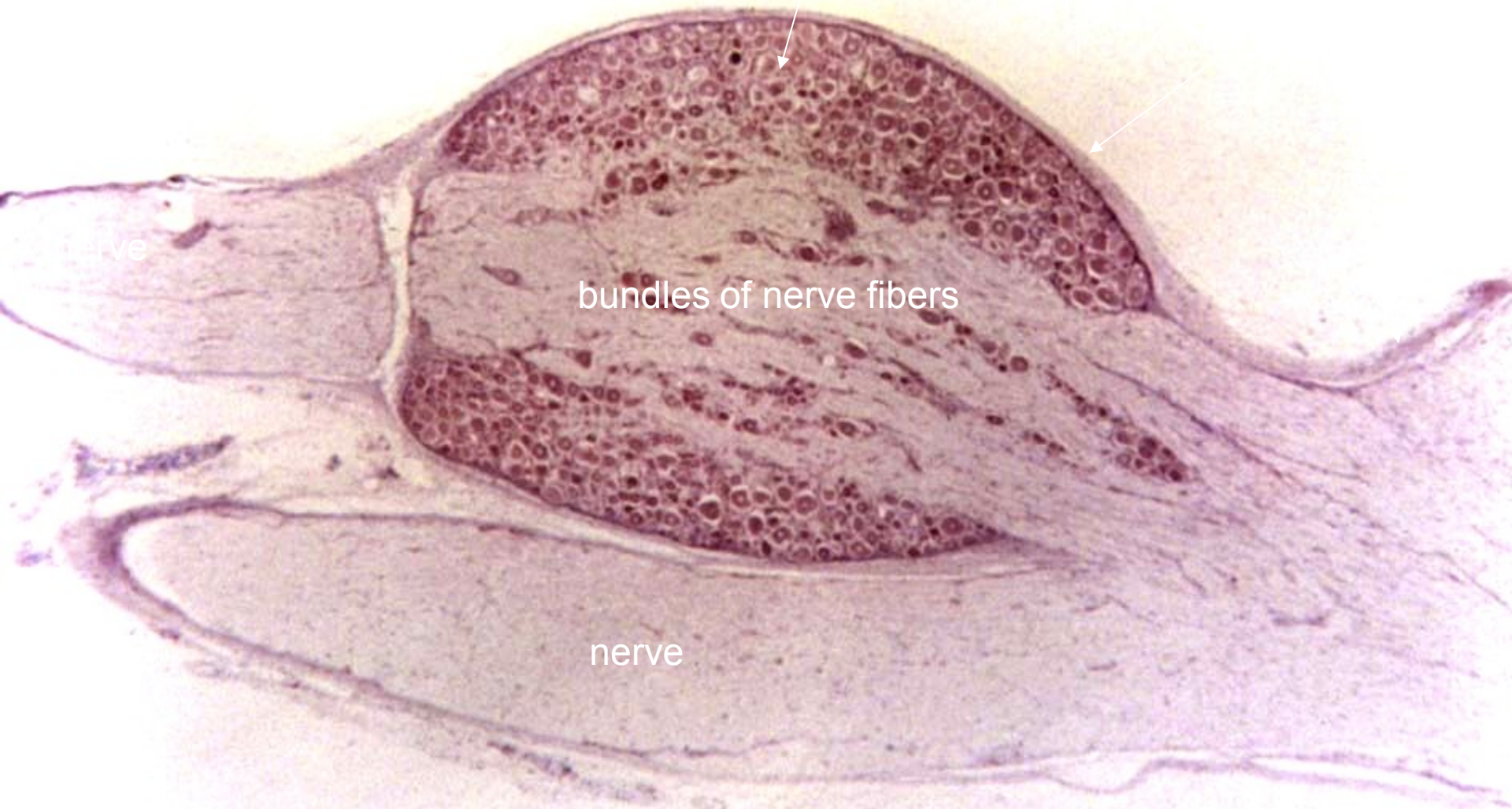


Medulla spinalis (HE) – somatomotorické neuron = multipolární



Spinalní ganglion (HE)

pseudounipolární neurony

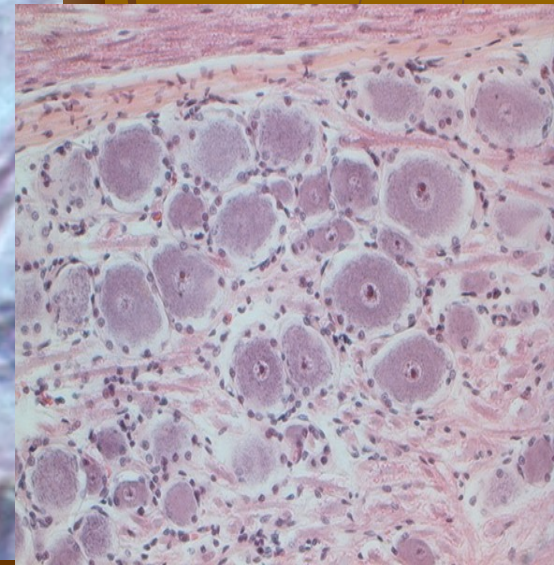
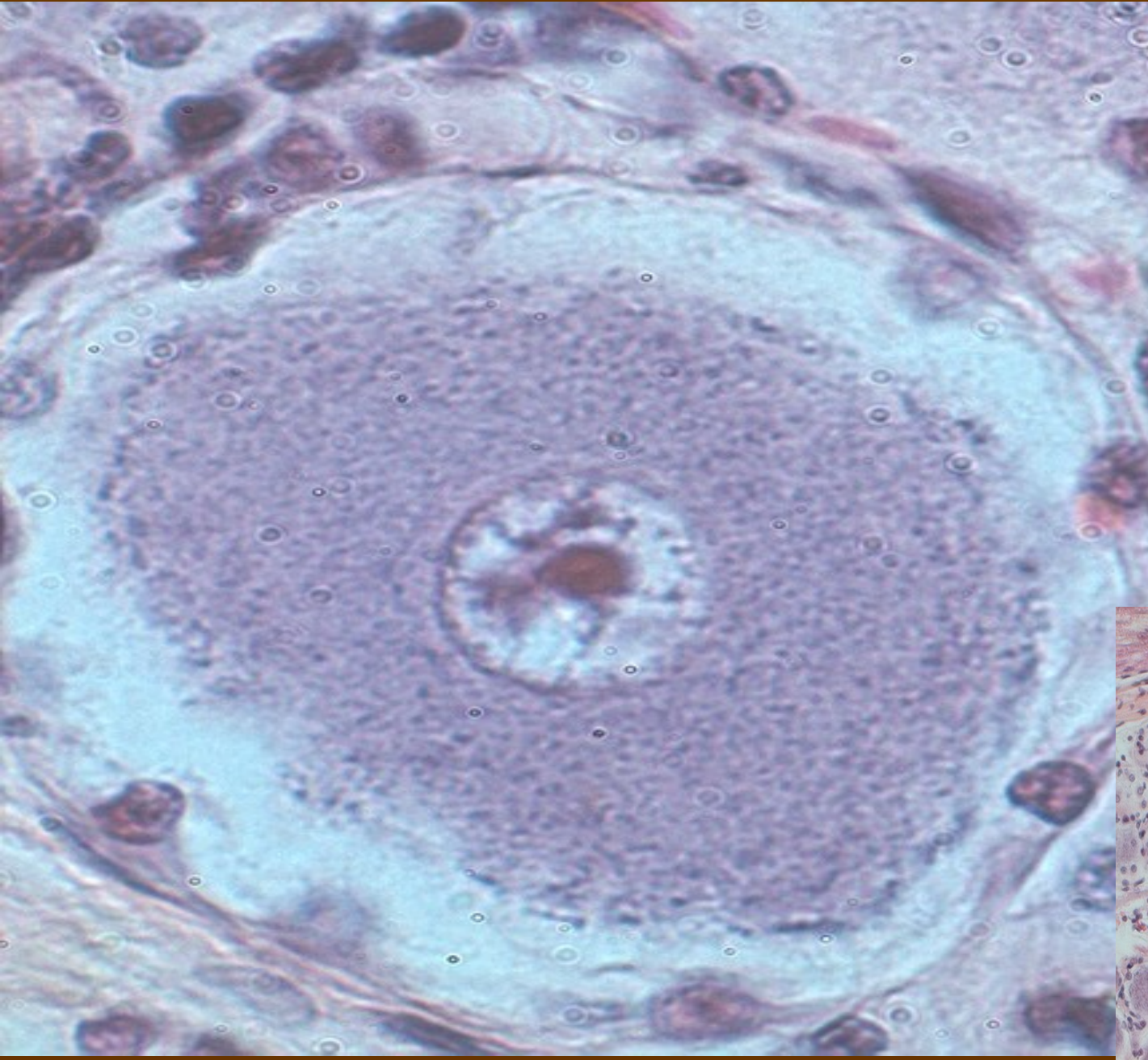


bundles of nerve fibers

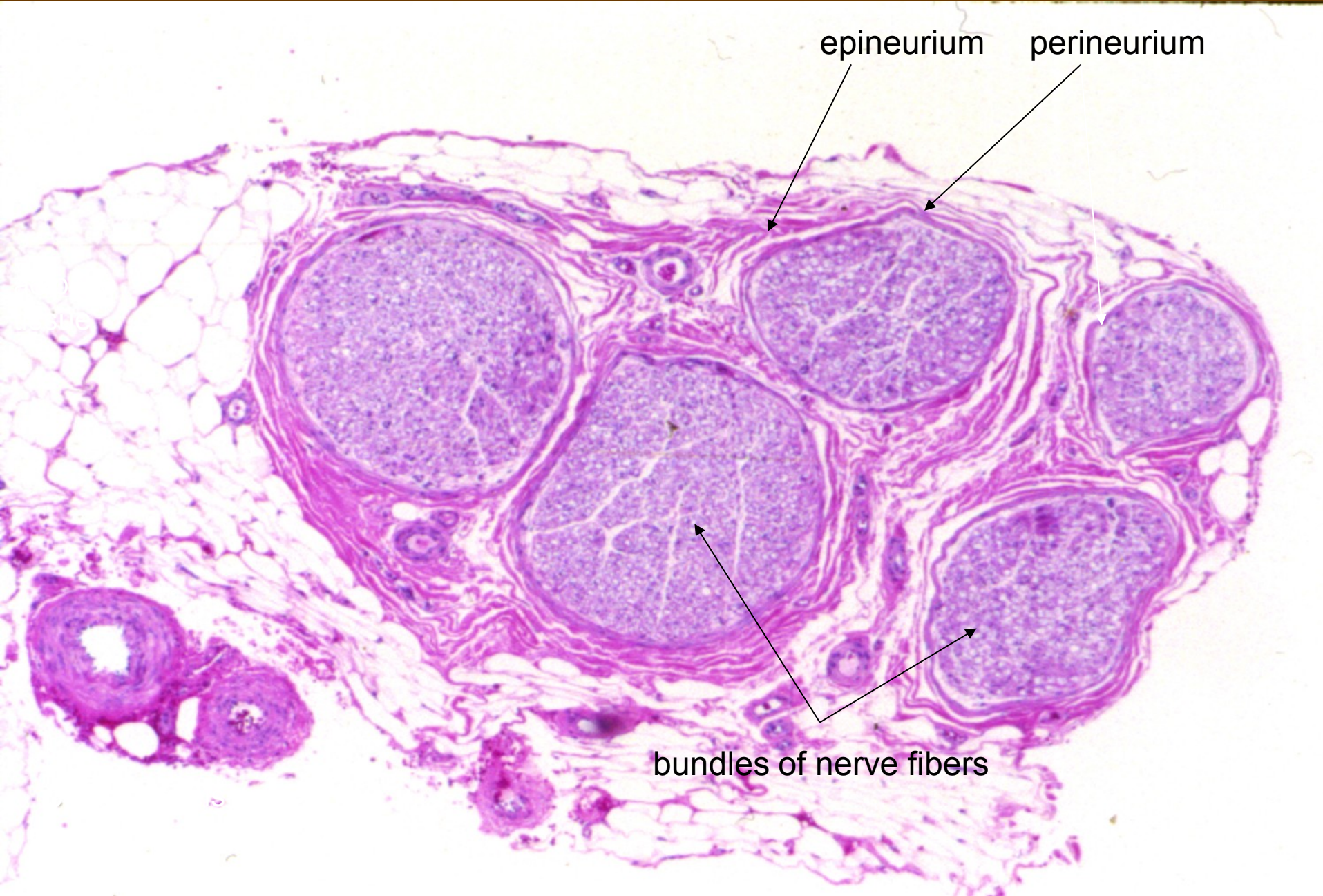
nerve

nerve

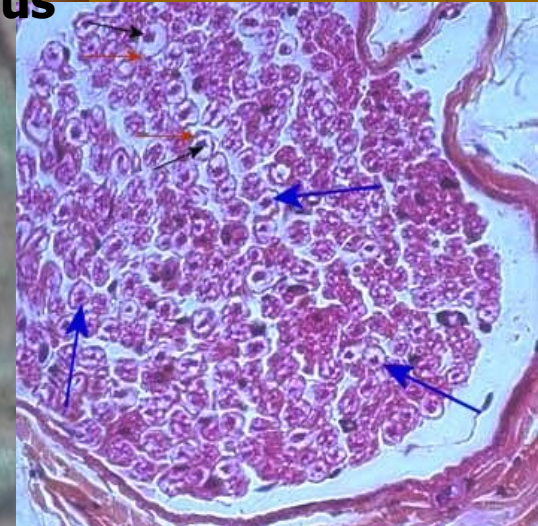
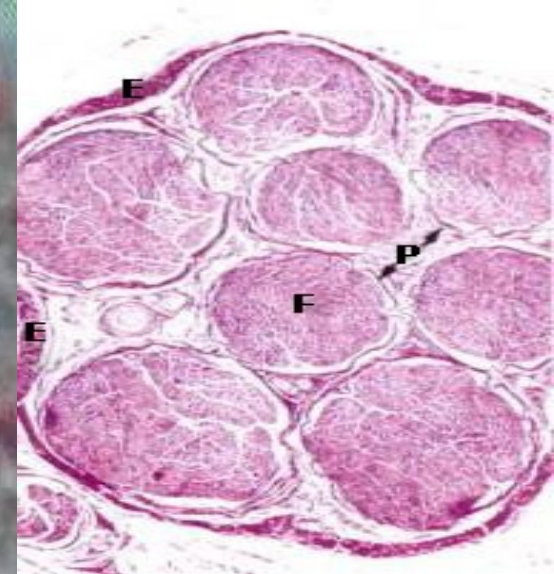
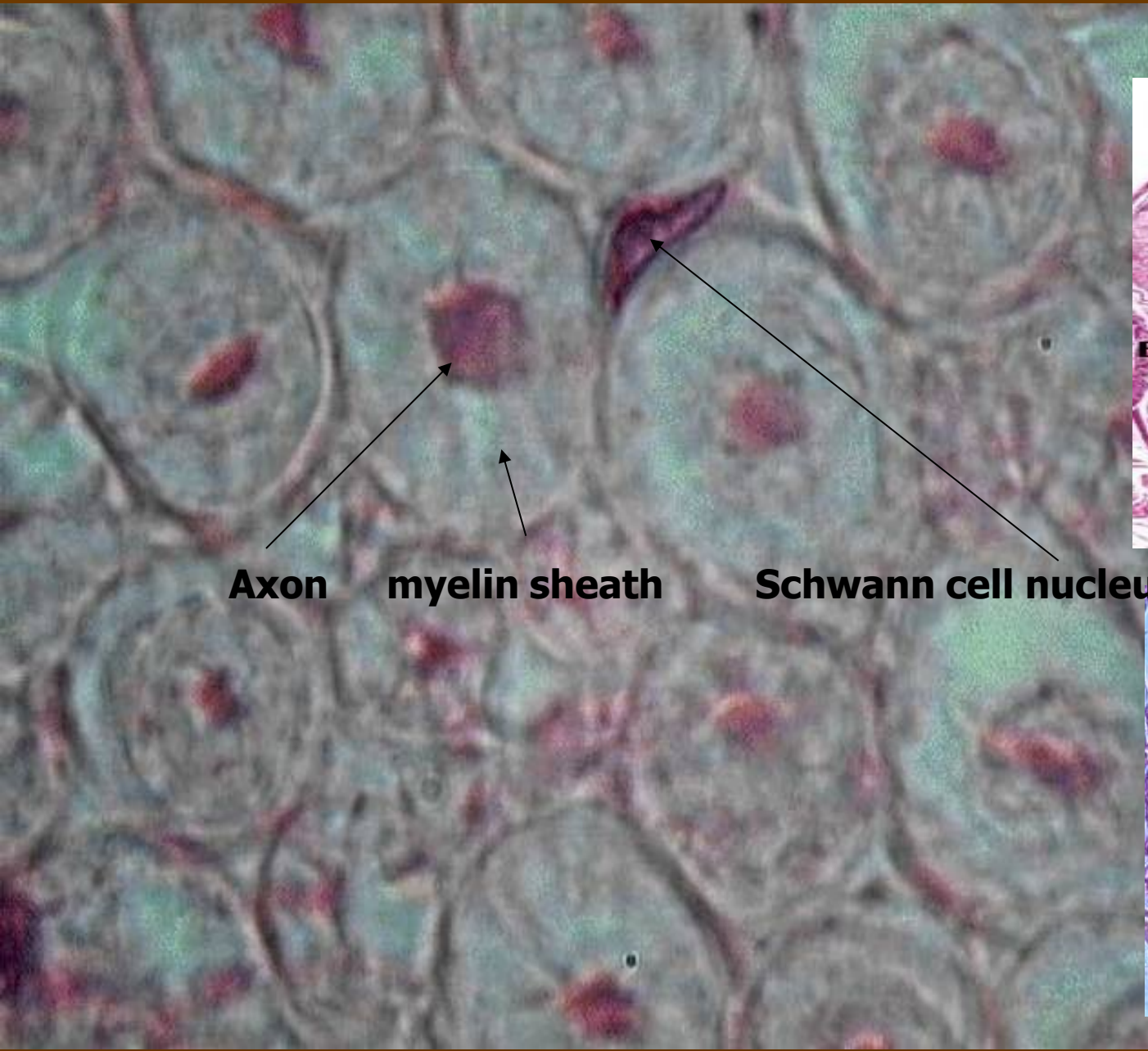Gangliové buňky = pseudounipolární neurony + satelitní bb



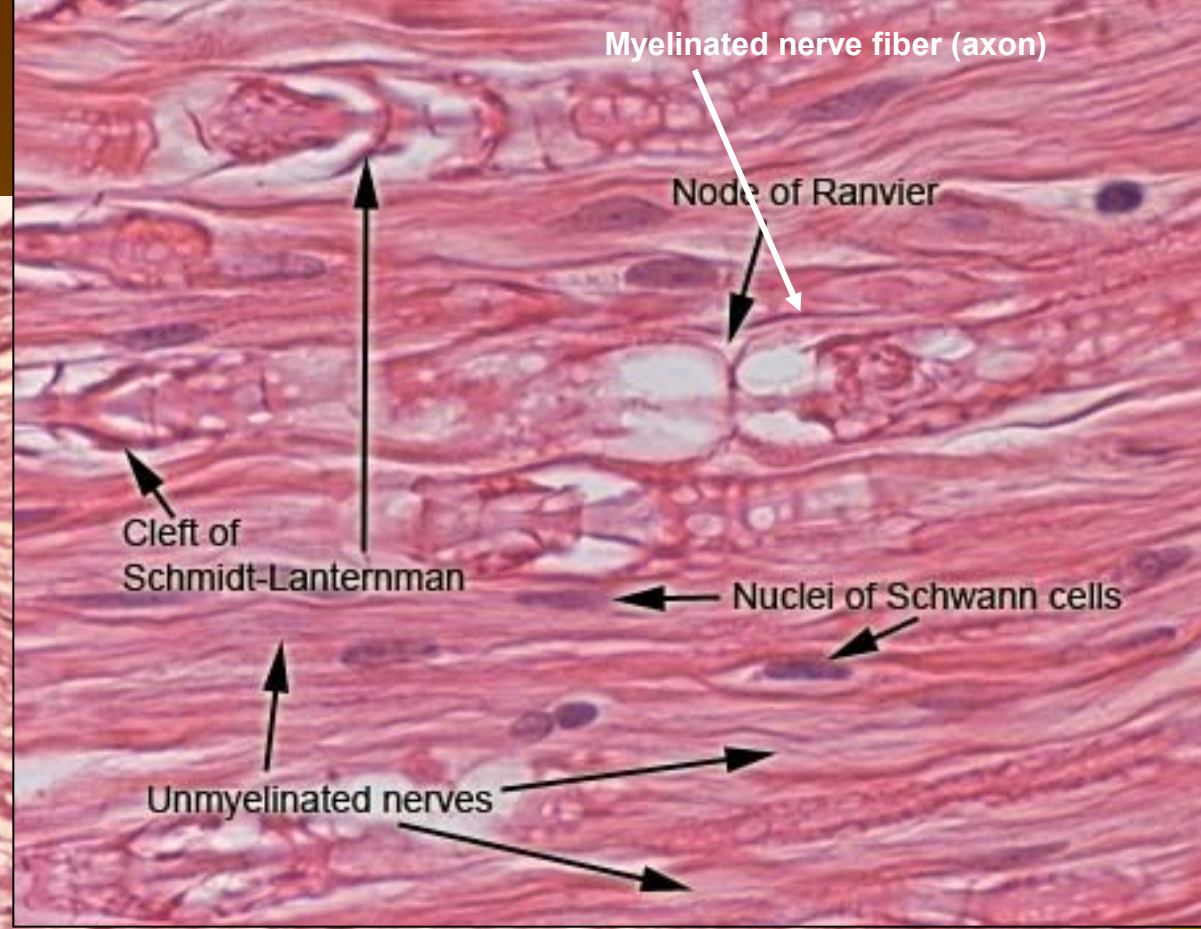
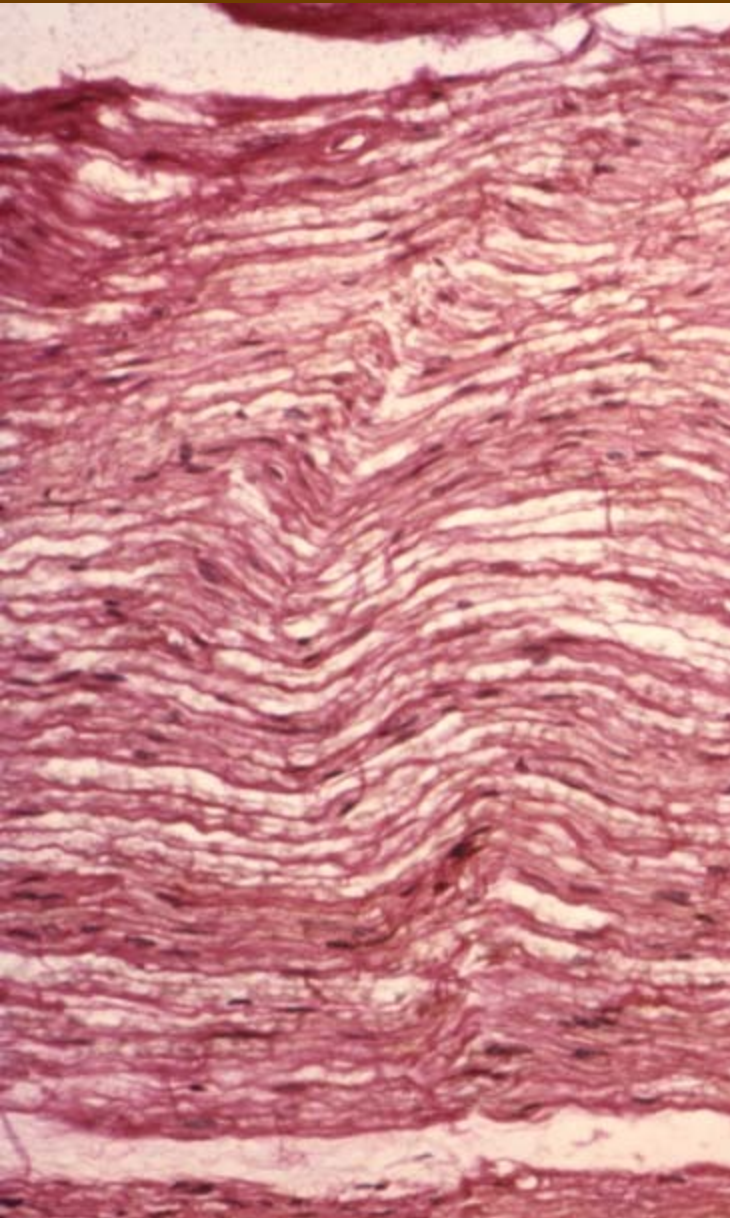
Periferní nerv (HE) – příčně



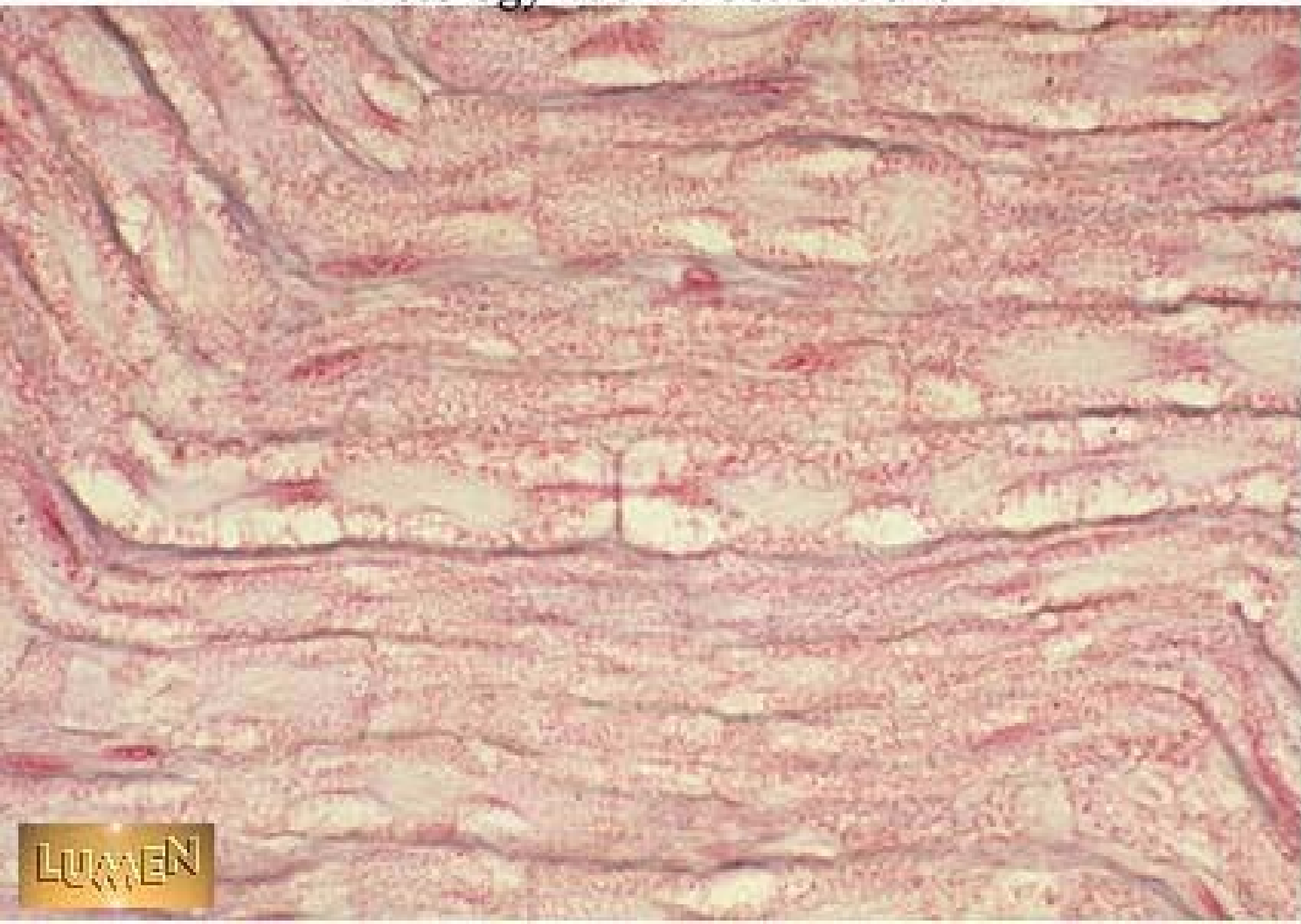
Periferní nerv (HE)



Periferní nerv (HE) podélně



Histology Lab Part 6: Slide 15



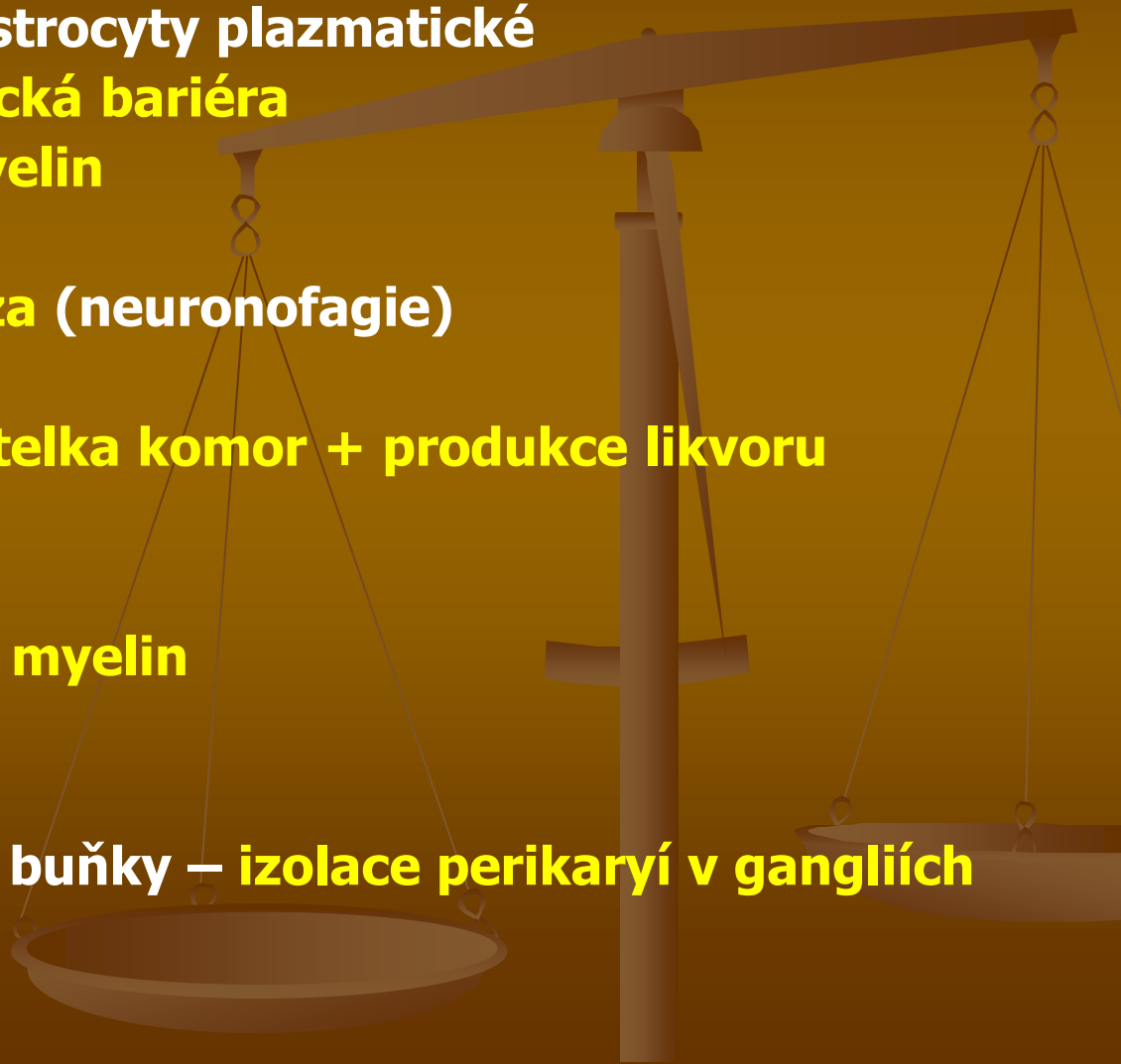
Neuroglie

Centrální glie

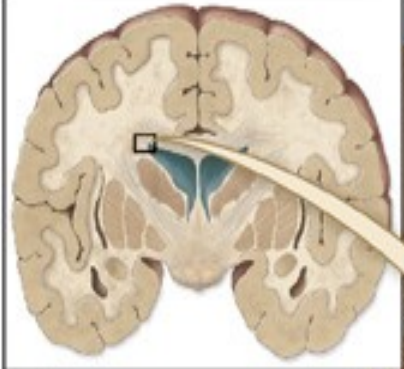- astrocyty fibrilární/astrocyty plazmatické
hematoencefalická bariéra
- oligodendrocyty – **myelin**
- mikroglie – **fagocytóza (neuronofagie)**
- ependymocyty – **výstelka komor + produkce likvoru**

Periferní glie

- Schwannovy buňky – **myelin neurilemma**
- satelitové (plášťové) buňky – **izolace perikaryí v gangliích**



CENTRAL GLIA



Microglia

Neuron

Astrocyte

Capillary

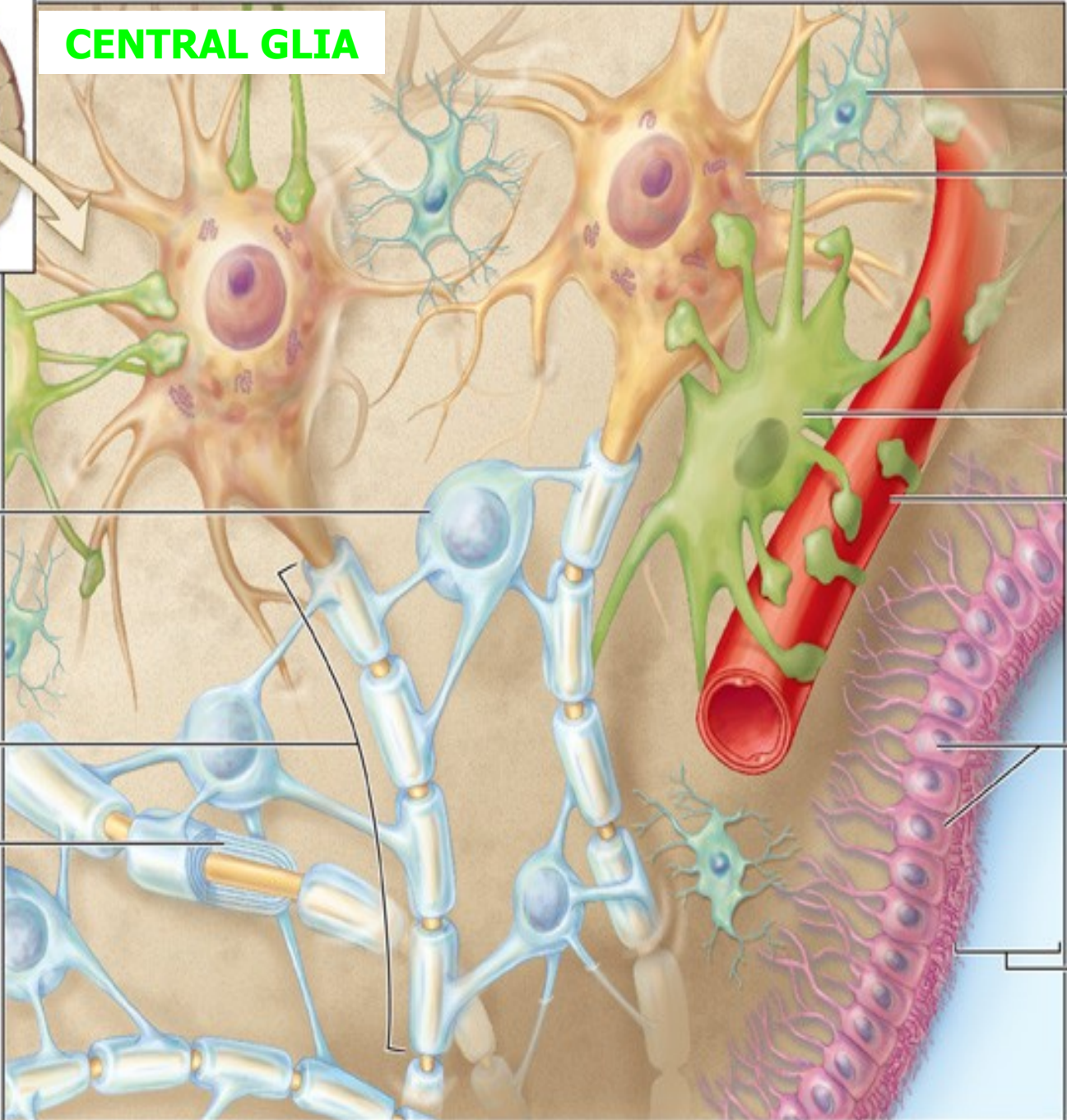
Oligodendrocyte

Ependyma cells

Myelinated axon

Myelin sheath (cut)

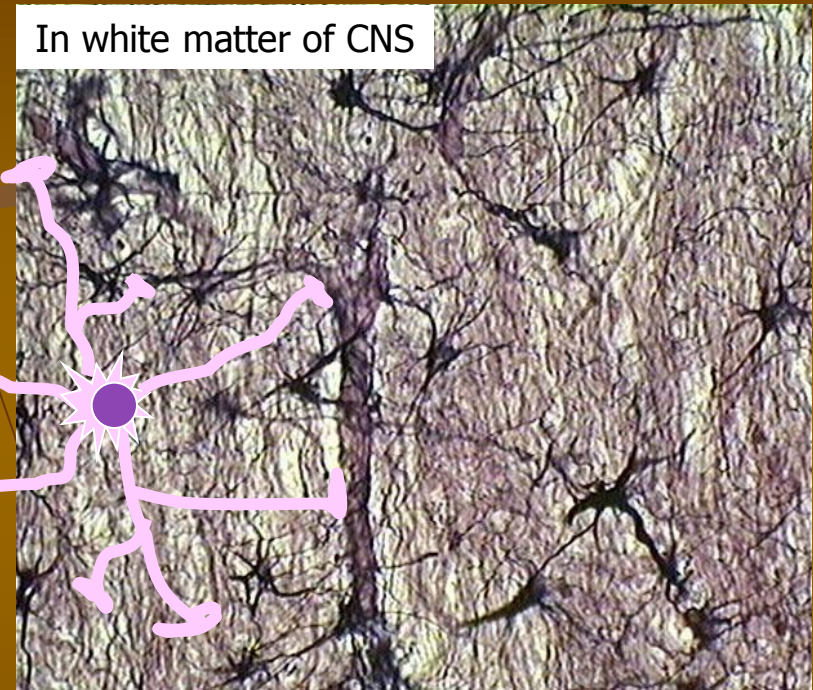
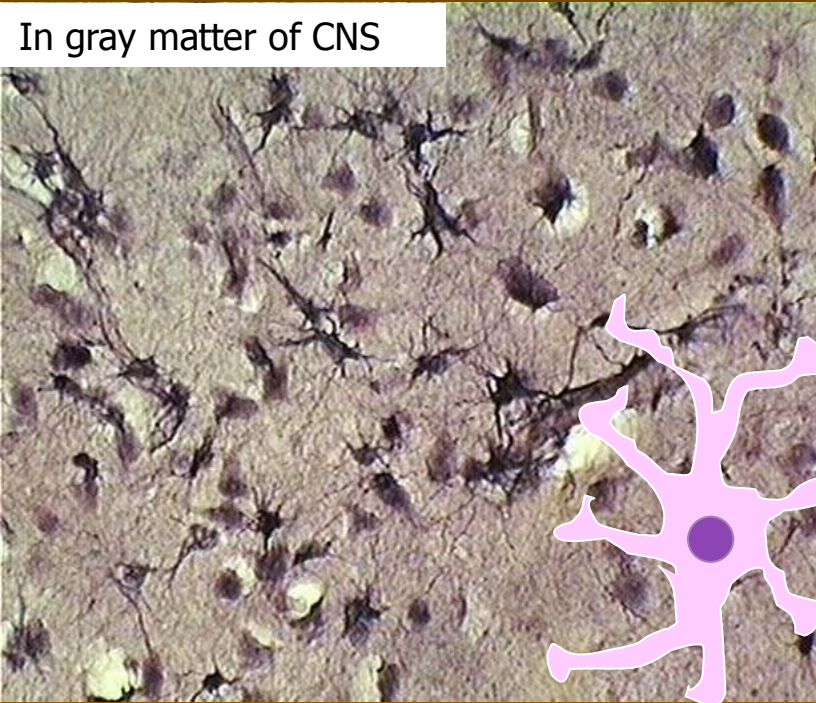
ventricle of brain



Astrocyty (macroglie)

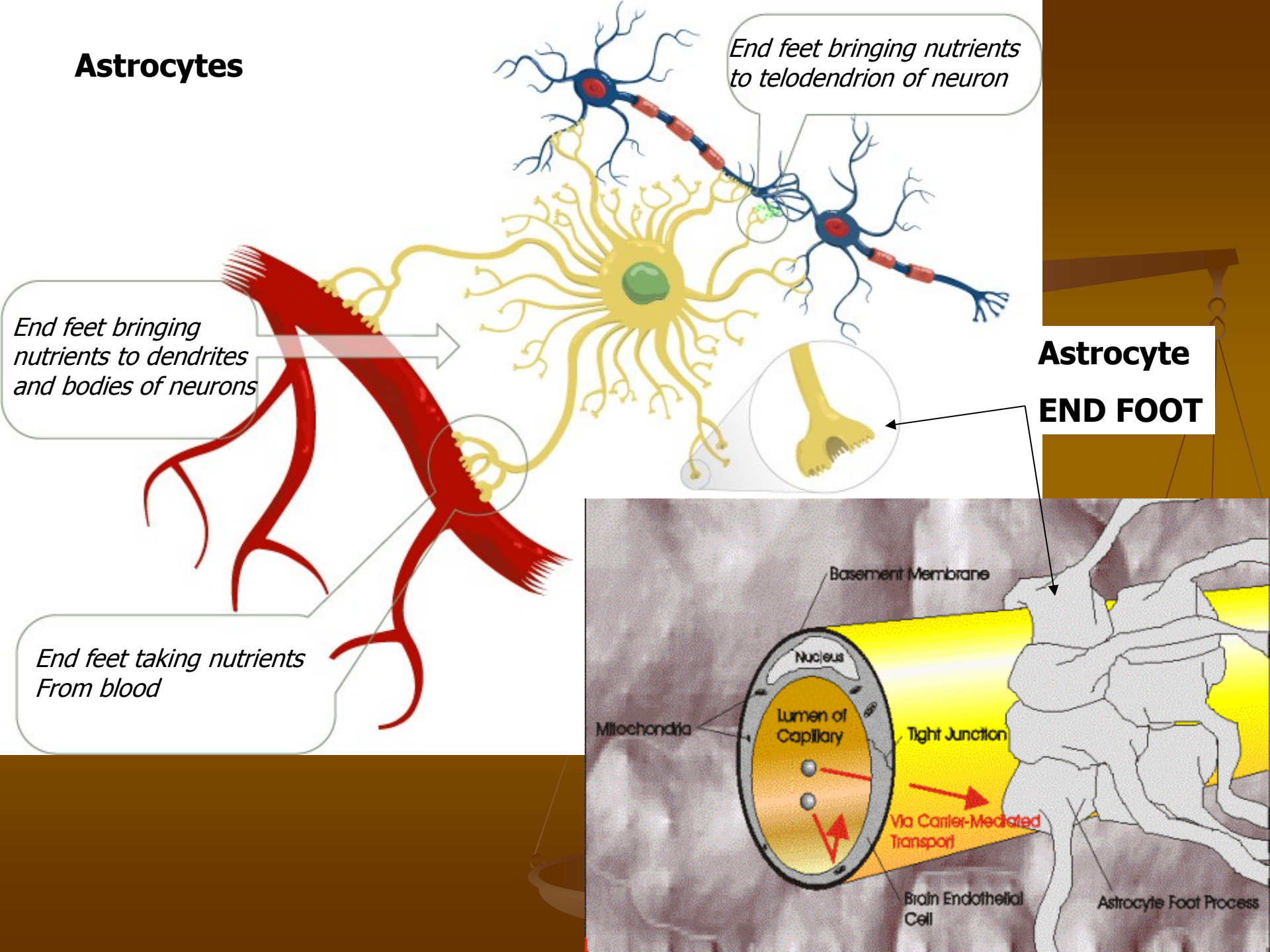
■ Plasmatické astrocyty

Vláknité astrocyty

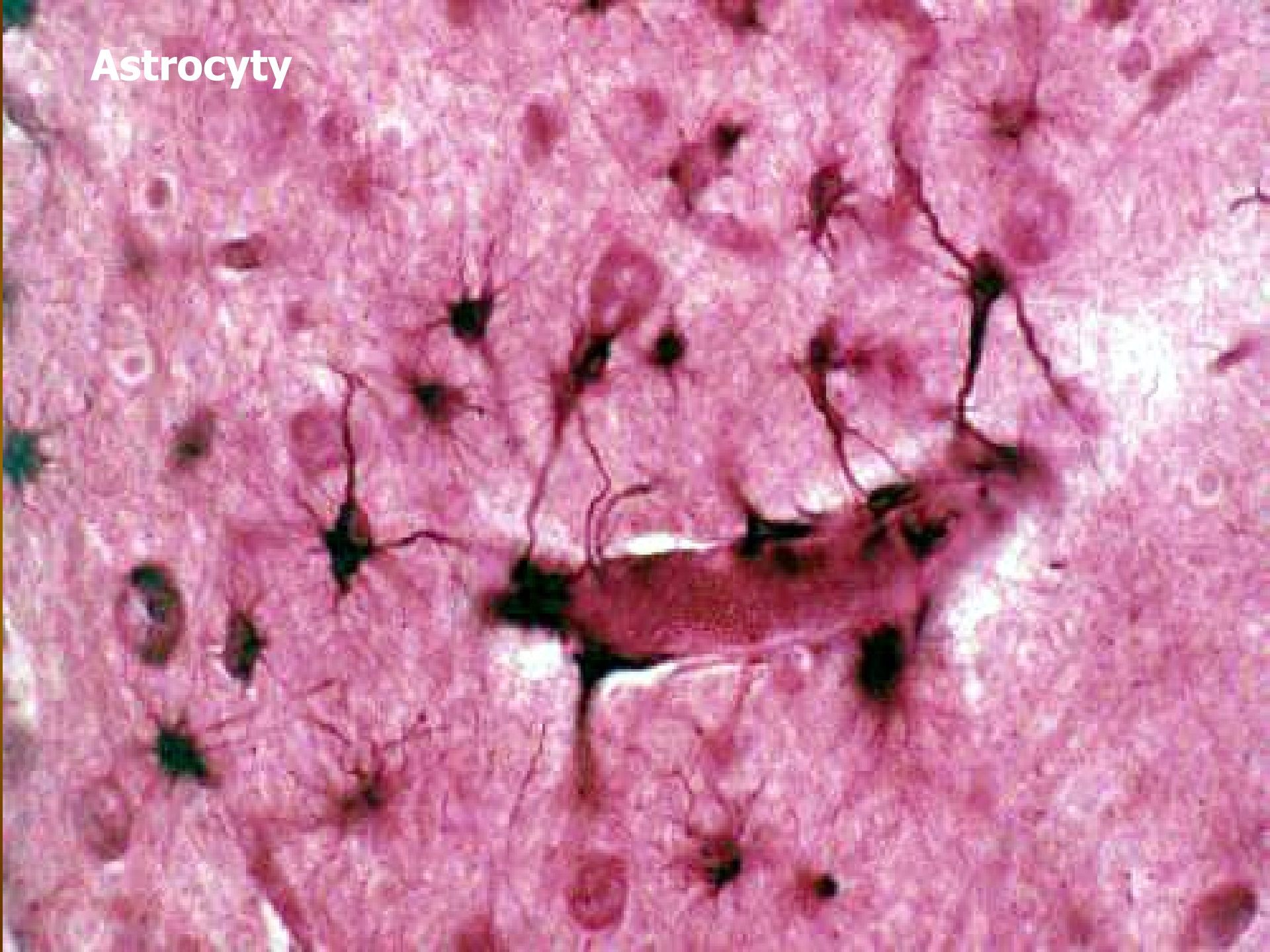


- Funkce: cytopl. výběžky mají na konci **ploténky**, ty tvoří souvislou vrstvu – membrána limitans na povrchu:
 - 1) krevních kapilár (*membrana limitans gliae perivascularis*; ta s endotelem tvoří **hematoencefalickou bariéru**,
 - 2) orgánů CNS (*membrana limitans gliae superficialis*)Astrocyty mají protektivní a nutritivní funkci

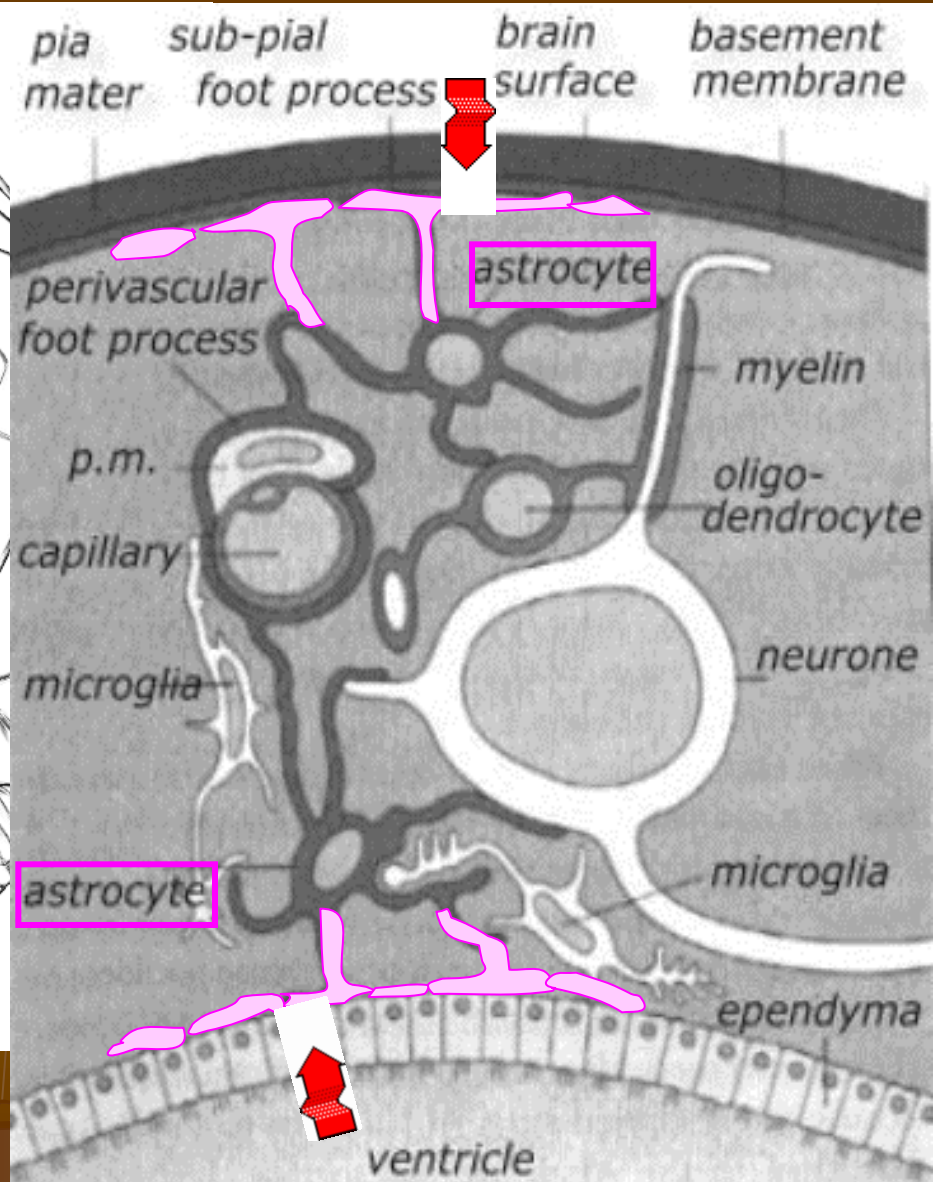
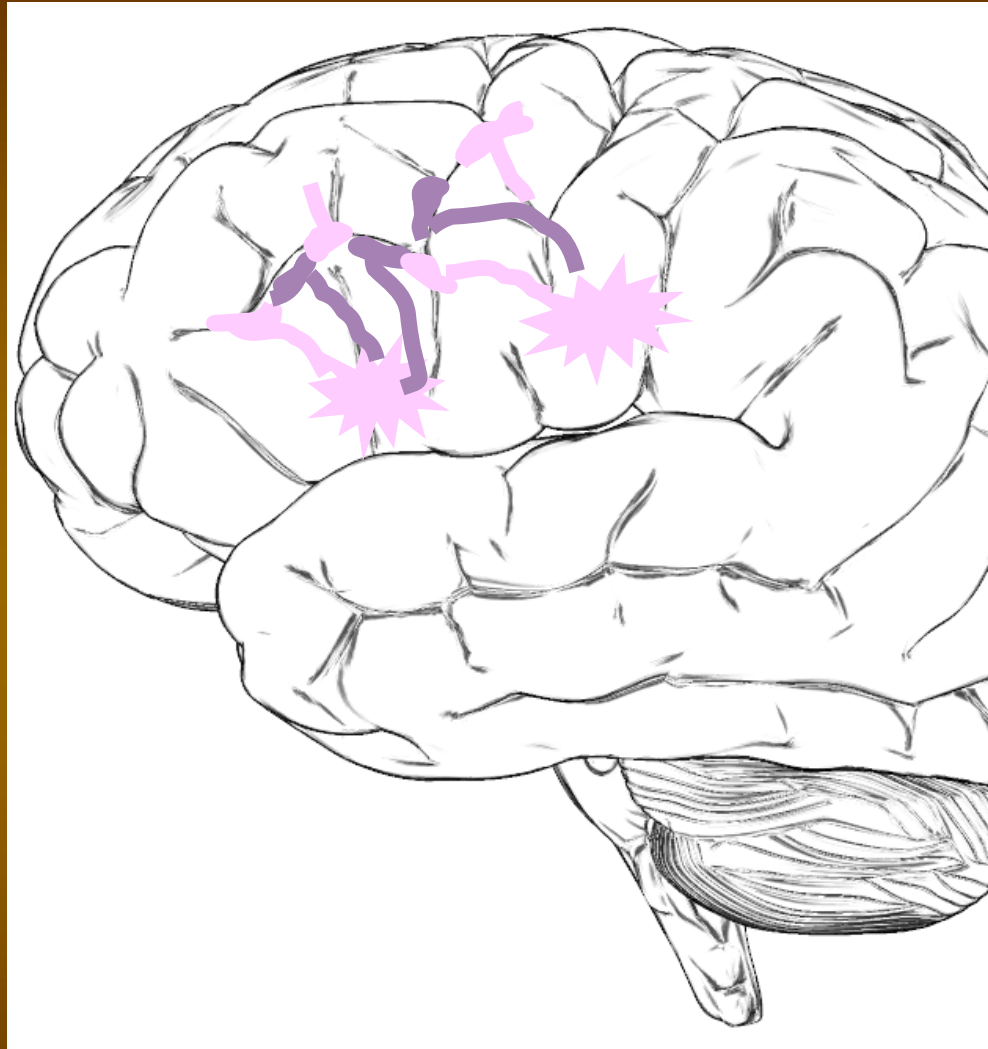
Astrocytes



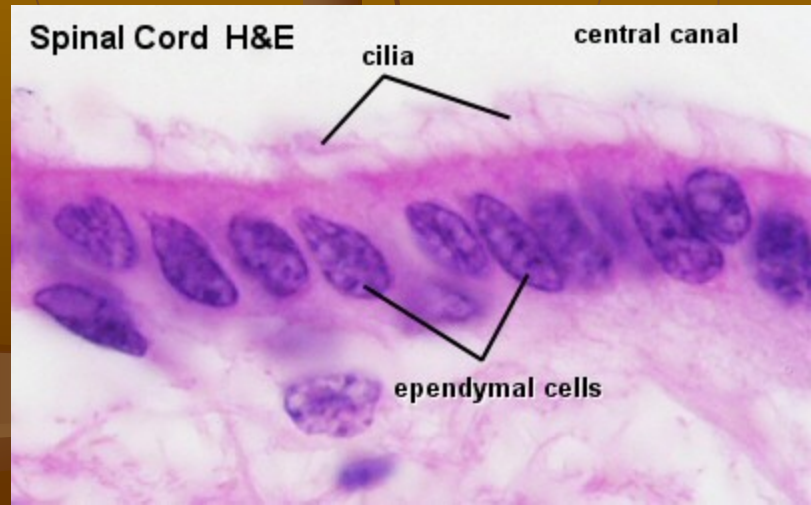
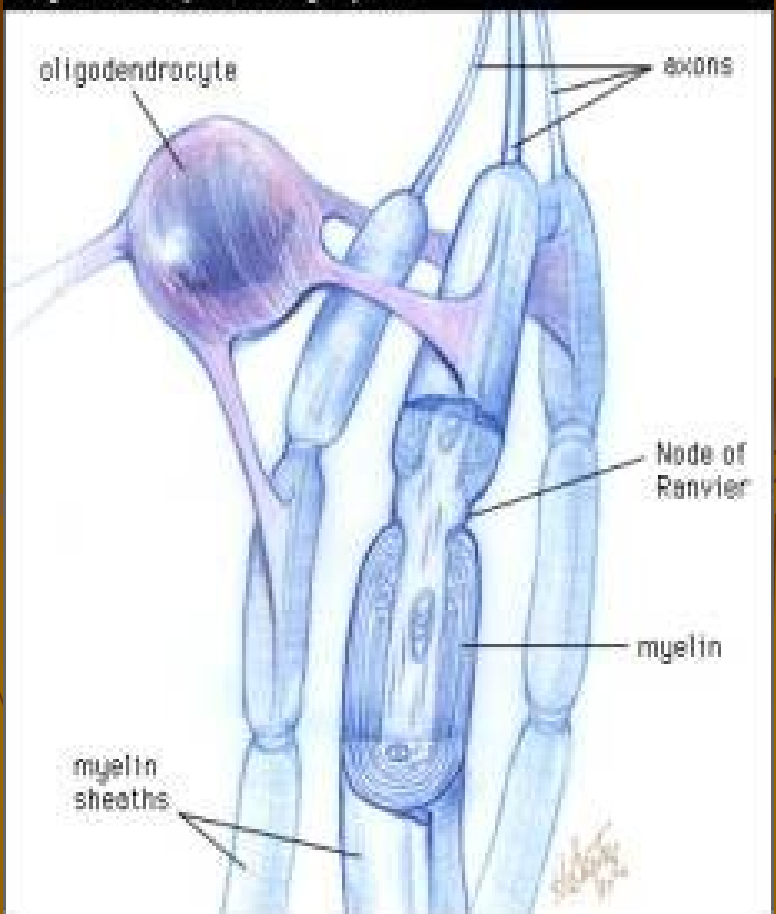
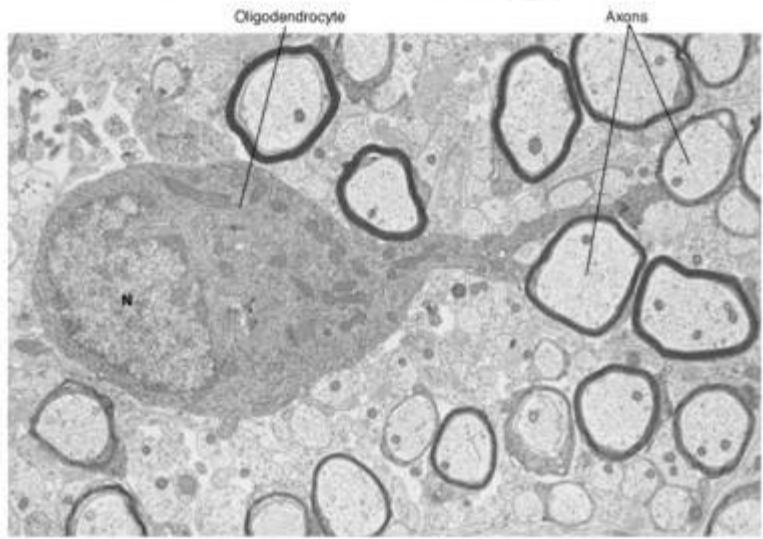
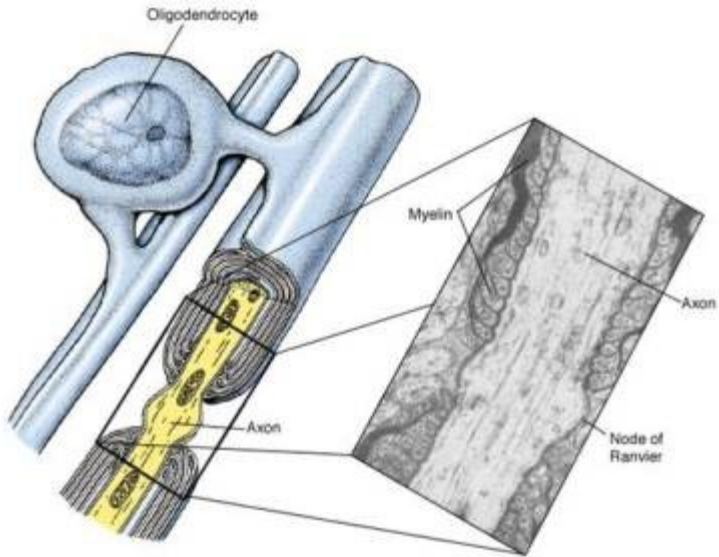
Astrocyty



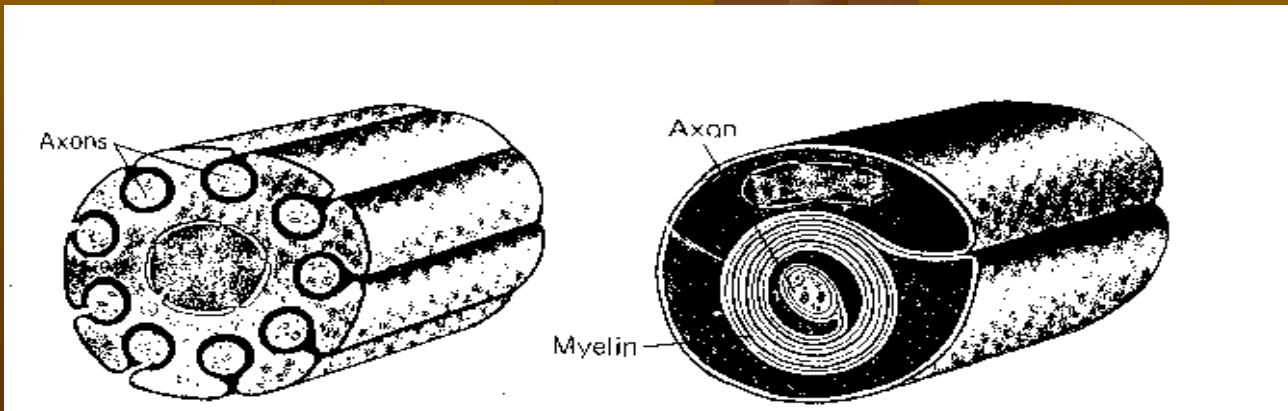
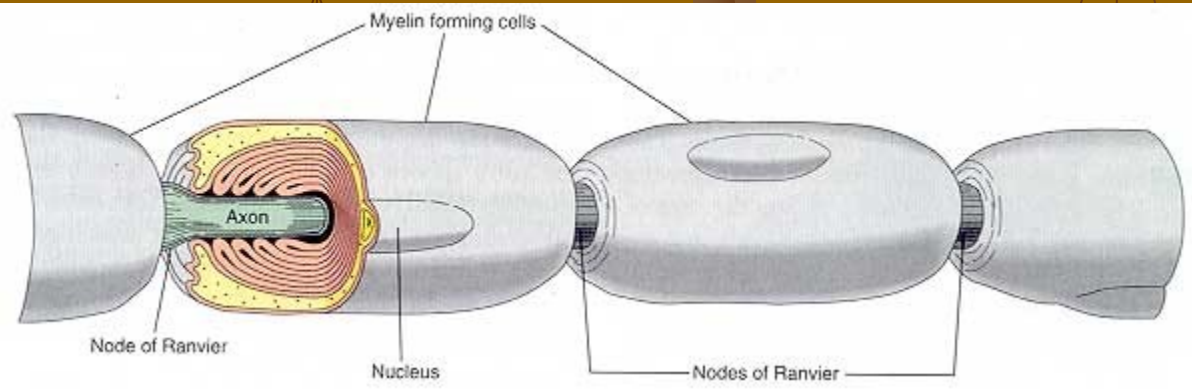
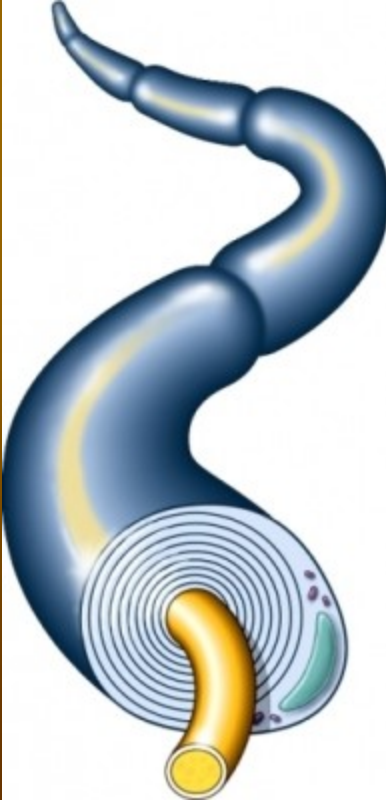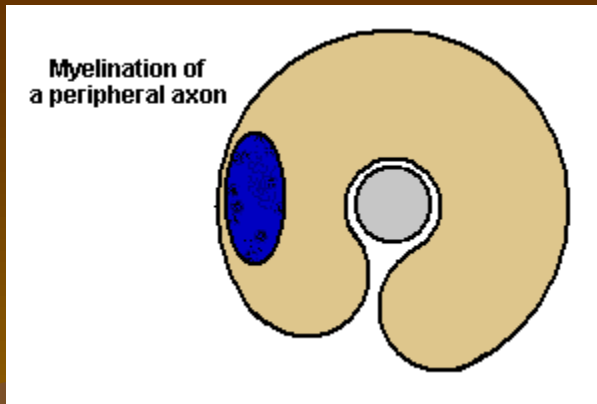
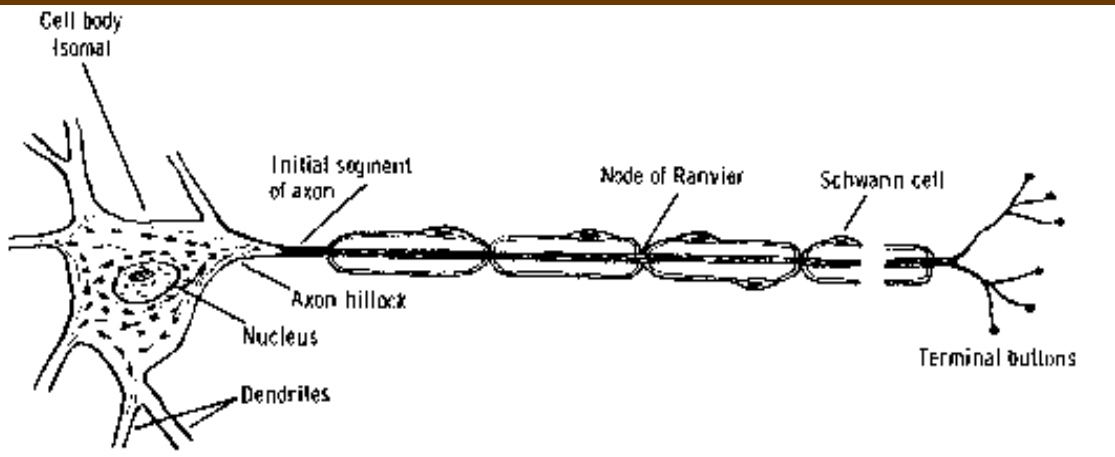
Membrana limitans gliae superficialis

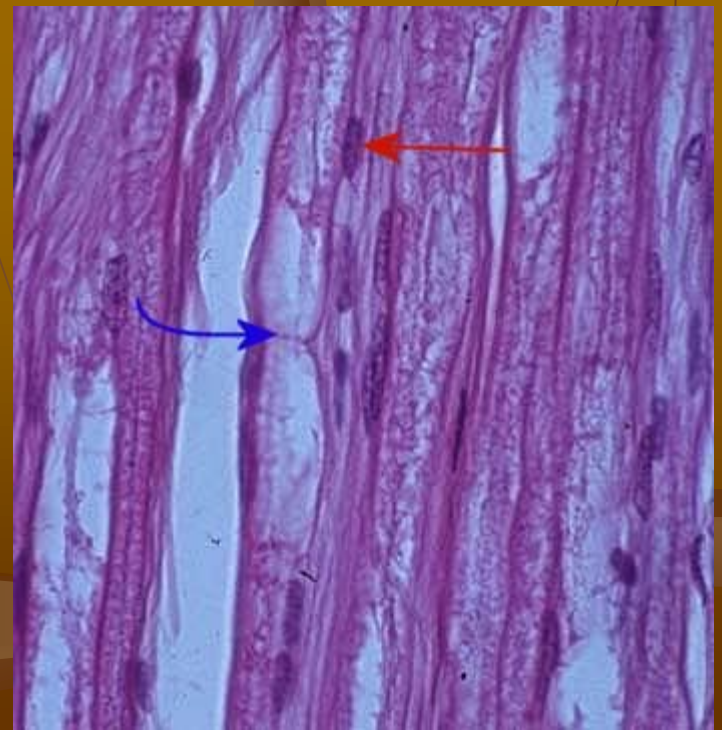
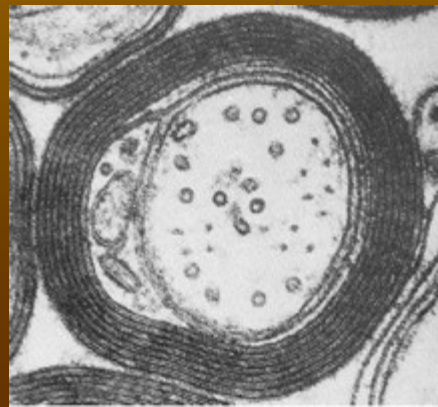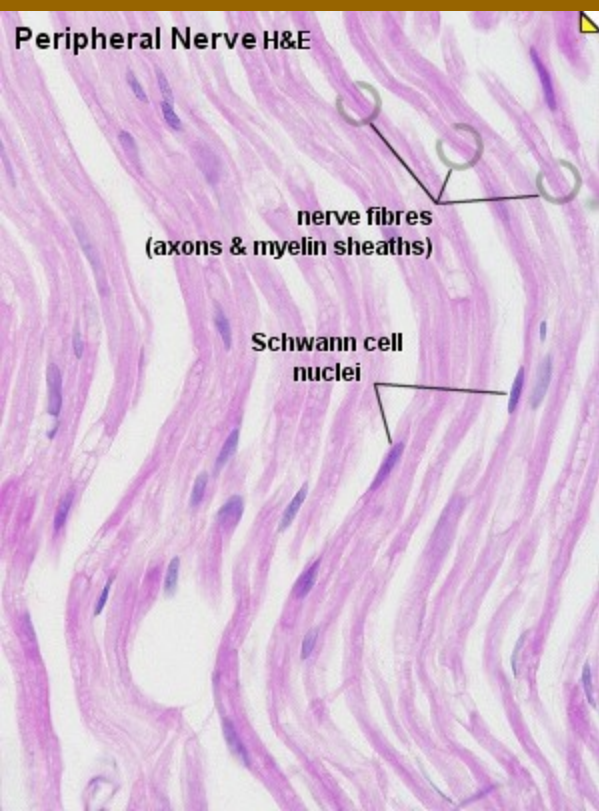
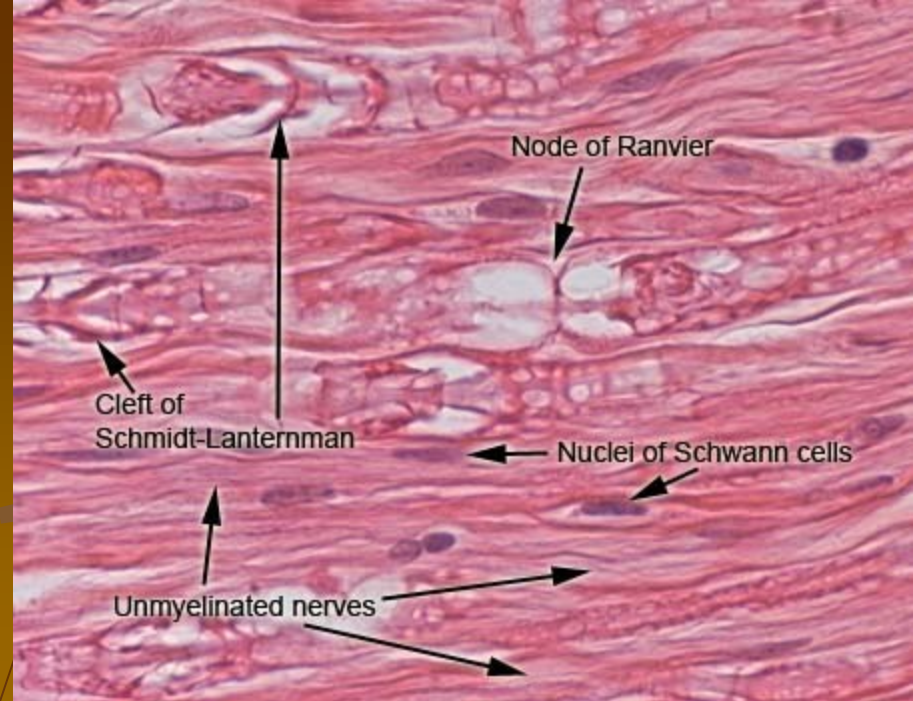
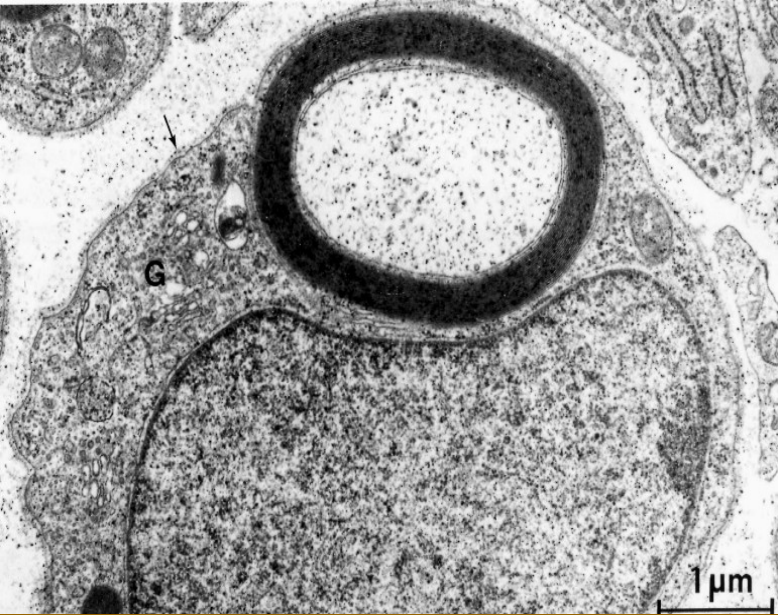


O
L
I
G
D
E
N
D
R
O
C
Y
T
E
P
E
N
D
Y
M

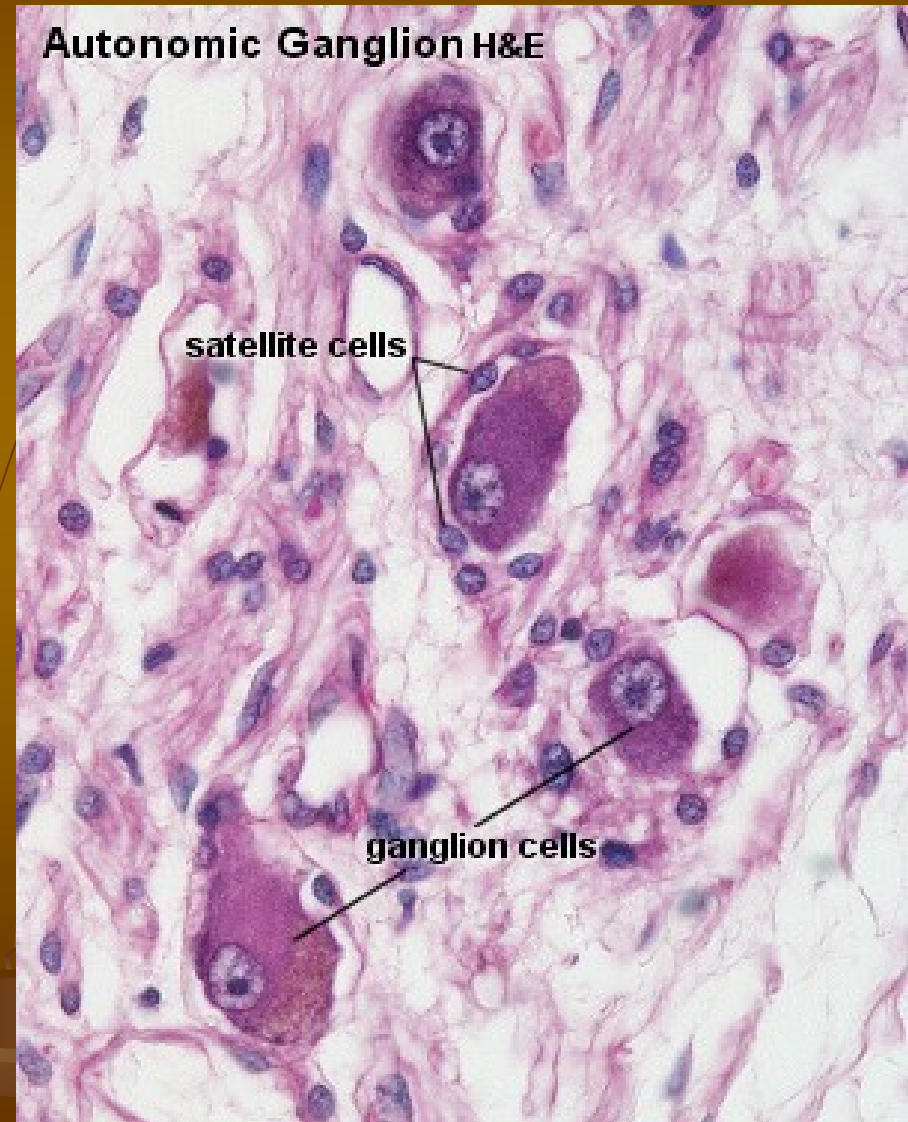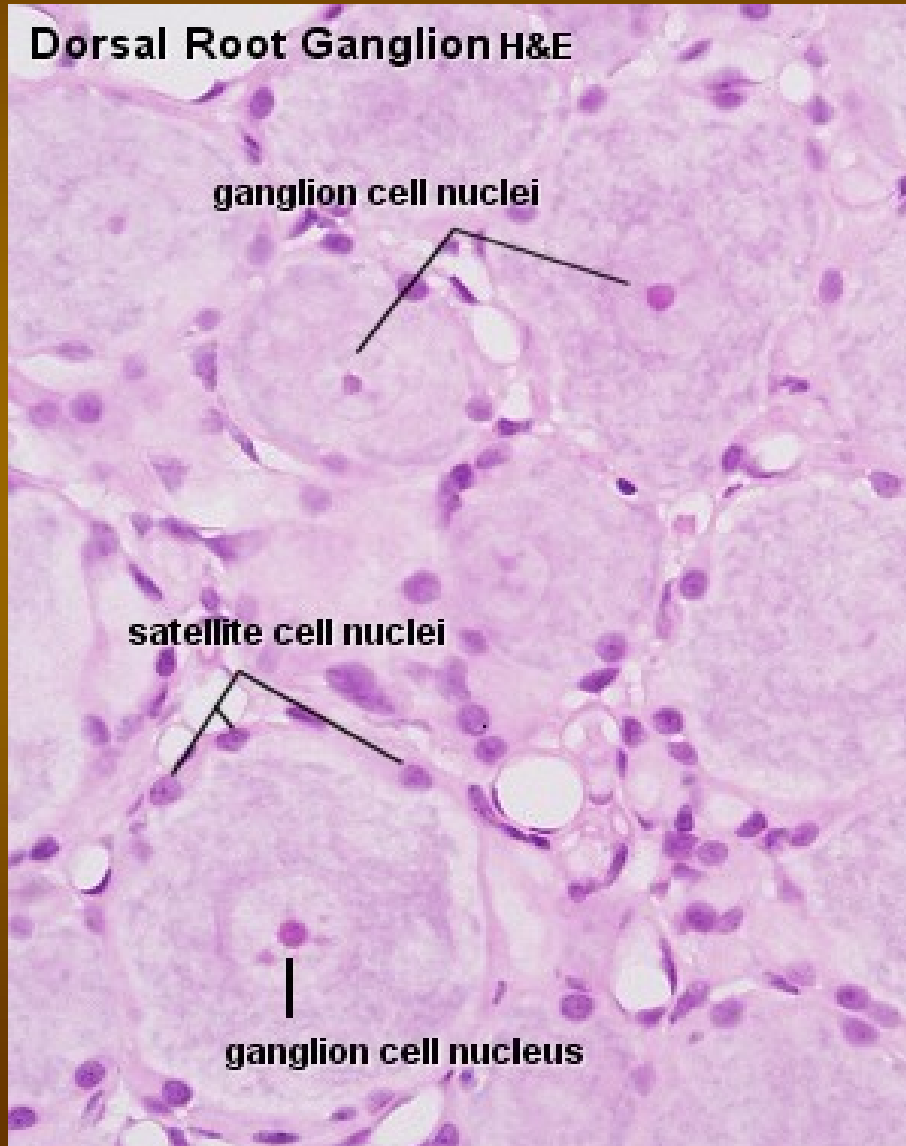


SCHWANNOVY BUŇKY





Satelitní buňky (plášťové buňky, amfocyty)
– v nervových gangliích kolem gangliových buněk





Koniklec v Brně