

## 8 Uveal Tract (Vascular Pigmented Layer)

### 8.1 Basic Knowledge

**Structure.** The uveal tract (also known as the vascular pigmented layer, vascular tunic, and uvea) takes its name from the Latin *uva* (grape) because the dark pigmentation and shape of the structure are reminiscent of a grape. The uveal tract consists of the following structures:

**Iris**

**Ciliary body**

**Choroid**

**Position.** The uveal tract lies between the sclera and retina.

**Neurovascular supply.** Arterial supply to the uveal tract is provided by the ophthalmic artery.

The *short posterior ciliary arteries* enter the eyeball with the optic nerve and supply the *choroid*.

The *long posterior ciliary arteries* pass along the interior surface of the sclera to the *ciliary body* and the *iris*. They form the major arterial circle at the root of the iris and the minor arterial circle in the collarette of the iris.

The *anterior ciliary arteries* originate from the vessels of the rectus muscles and communicate with the *posterior ciliary vessels*.

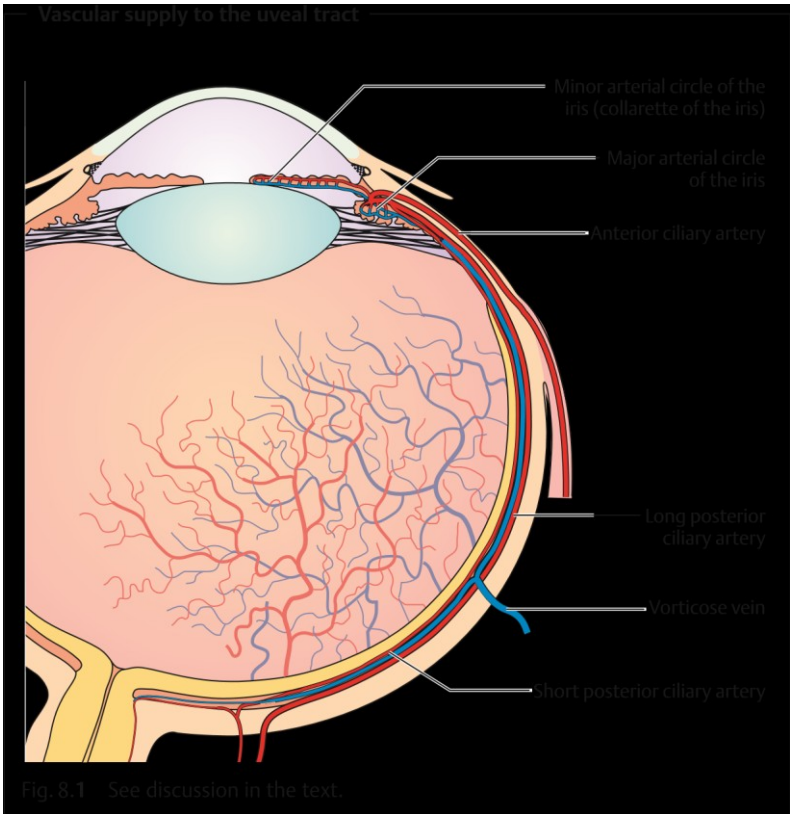
**Venous blood** drains through four to eight *vorticosae or vortex veins* that penetrate the sclera posterior to the equator and join the superior and inferior ophthalmic veins (Fig. 8.1). **Sensory supply** is provided by the *long and short ciliary nerves*.

### Iris

**Structure and function.** The iris consists of two layers: **The anterior mesodermal stromal layer**

**The posterior ectodermal pigmented epithelial layer**

The posterior layer is opaque and protects the eye against excessive incident light. The anterior surface of the lens and the pigmented layer are so close together near the pupil that they can easily form adhesions in inflammation.



The **collarette of the iris** covering the minor arterial circle of the iris divides the stroma into *pupillary* and *ciliary* portions. The pupillary portion contains the **sphincter muscle**, which is supplied by parasympathetic nerve fibers, and the **dilator pupillae muscle**, supplied by sympathetic nerve fibers. These muscles regulate the contraction and dilation of the pupil, so that the iris can be regarded as the **aperture** of the optical system of the eye.

Pupil dilation is sometimes sluggish in preterm infants and the newborn because the dilator pupillae muscle develops relatively late.

**Surface.** The normal iris has a richly textured surface structure with **crypts** (tissue gaps) and interlinked **trabeculae**. A faded surface structure *can* be a sign of inflammation (see iritis).

## 8.2 Examination Methods

**Color.** The color of the iris varies in the individual according to the **melanin content of the melanocytes (pigment cells)** in the *stroma* and *epithelial layer*. Eyes with a high melanin content are dark brown, whereas eyes with less melanin are grayish-blue. **Caucasians at birth** always have a grayish-blue iris as the *pigmented layer* only develops gradually during the first year of life. Even in **albinos** (see impaired melanin synthesis), the eyes have a grayishblue iris because of the melanin deficiency. Under slit lamp retroillumination they appear reddish due to the fundus reflex.

### Ciliary Body

**Position and structure.** The **ciliary body** extends from the root of the iris to the ora serrata, where it joins the choroid. It consists of *anterior pars plicata* and the *posterior pars plana*, which lies 3.5 mm posterior to the limbus. Numerous **ciliary processes** extend into the posterior chamber of the eye. The suspensory ligament, the zonule, extends from the pars plana and the intervals between the ciliary processes to the lens capsule.

**Function.** The *ciliary muscle* is responsible for **accommodation**. The doublelayered *epithelium covering the ciliary body* **produces the aqueous humor**.

### Choroid

**Position and structure.** The choroid is the **middle tunic of the eyeball**. It is bounded on the interior by *Bruch's membrane*. The choroid is highly vascularized, containing a vessel layer with large blood vessels and a capillary layer. The blood flow through the choroid is the *highest in the entire body*.

**Function.** The choroid **regulates temperature** and supplies **nourishment to the outer layers of the retina**.

## 8.2 Examination Methods

The *slit lamp* is used to examine the **surfaceoftheiris** under a focused beam of light. *Normally no vessels will be visible*.

Iris vessels are only visible in atrophy of the iris, inflammation, or as neovascularization in rubeosis iridis (see Fig. 8.12).

Where vessels are present, they can be visualized by *iris angiography* after intravenous injection of fluorescein sodium dye.

**Defects in the pigmented layer of the iris** appear red under retroillumination with a slit lamp (see Fig. 8.6). *Slit lamp biomicroscopy* visualizes individual cells such as melanin cells at 40-power magnification.

The *anterior chamber* is normally transparent. Inflammation can increase the permeability of the **vessels of the iris** and compromise the barrier between blood and aqueous humor. *Opacification of the aqueous humor* by proteins can be observed with the aid of a *slit lamp* when the eye is illuminated with a lateral focal beam of light (Tyndall effect). This method can also be used to diagnose *cells in the anterior chamber* in the presence of inflammation.

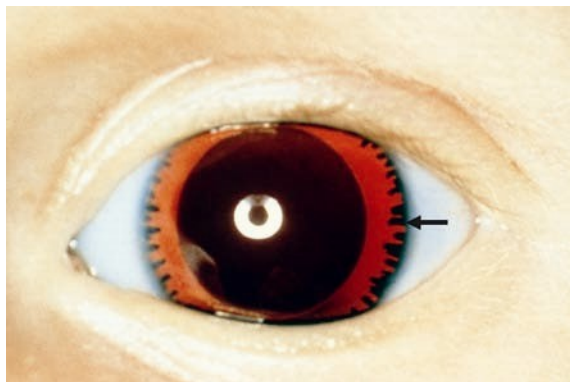
Direct inspection of the **root of the iris** is not possible because it does not lie within the line of sight. However, it can be indirectly visualized by *gonioscopy*. Inspection of the **posterior portion of the pars plana** requires a *threemirror lens*. The globe is also indented with a metal rod to permit visualization of this part of the ciliary body (for example in the presence of a suspected malignant melanoma of the ciliary body).

The pigmented epithelium of the retina permits only limited evaluation of the **choroid** by *ophthalmoscopy* and *fluorescein angiography* or indocyanine green angiography. Changes in the choroid such as tumors or hemangiomas can be visualized by ultrasound examination. Where a **tumor is suspected**, transillumination of the eye is indicated. After administration of topical anesthesia, a fiberoptic light source is placed on the eyeball to *visualize the shadow of the tumor on the red of the fundus*.

### 8.3 Developmental Anomalies

#### Aniridia

Aniridia is the **absence of the iris**. This **generally bilateral** condition is *transmitted as an autosomal-dominant trait* or occurs *sporadically*. Aniridia may

**Aniridia**

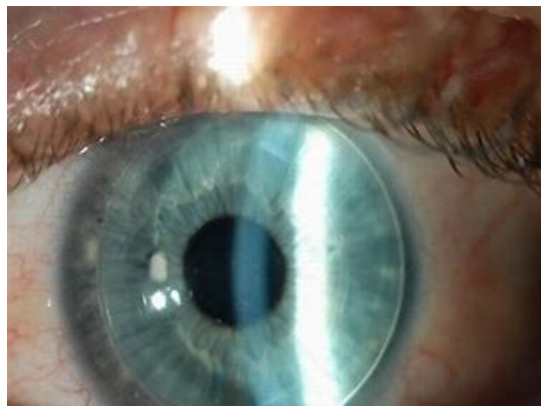
**Fig. 8.2** The ciliary villi (arrow) and the lens are visible with slit lamp retroillumination.

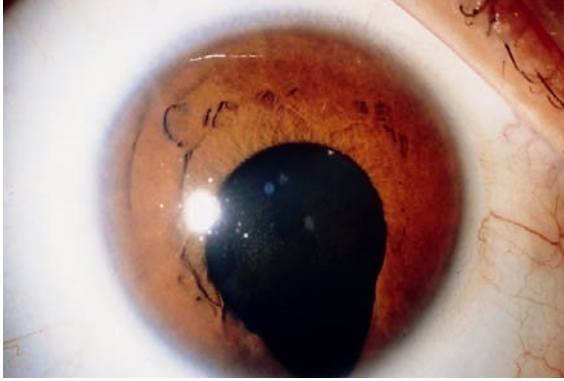
## 8.3 Developmental Anomalies

also be traumatic and can result from penetrating injuries. However, peripheral remnants of the iris are usually still present so that ciliary villi and zonule fibers will be visualized under slit lamp examination (Fig. 8.2).

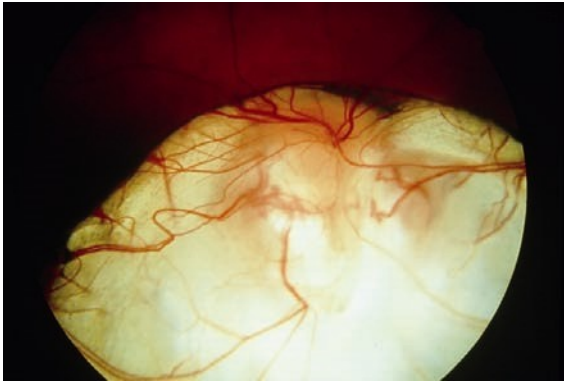
■ In sporadic aniridia, a Wilms' tumor of the kidney should be excluded.

*Vision is severely compromised* as a result of the foveal hypoplasia. The disorder is frequently associated with nystagmus, amblyopia, buphthalmos, and cataract.



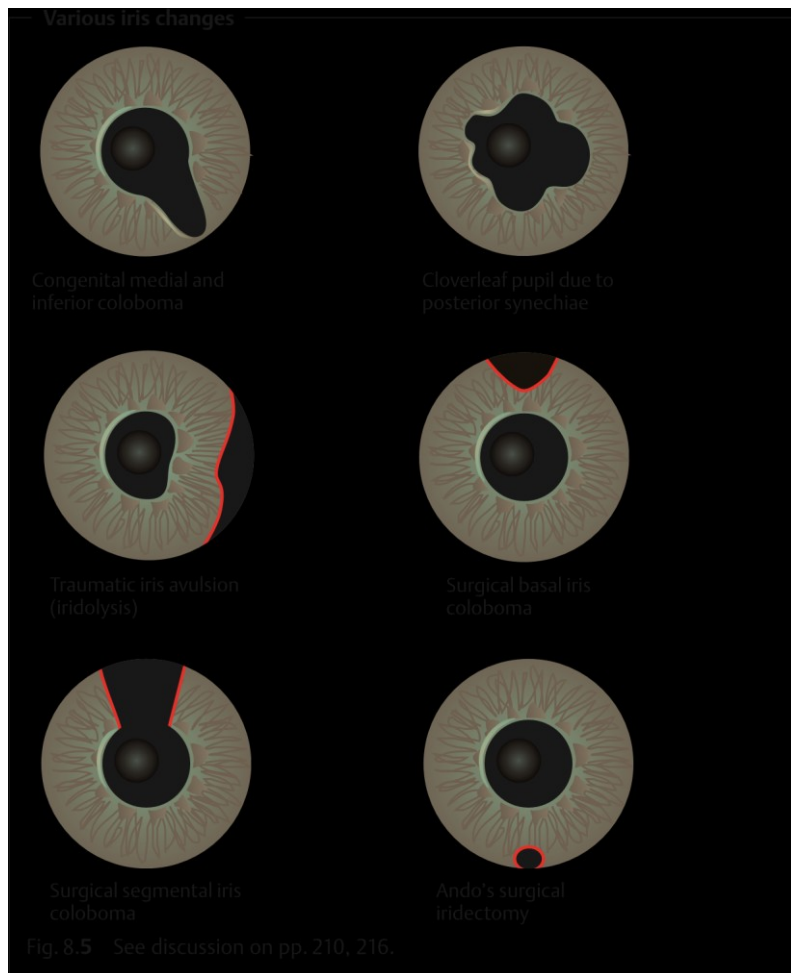
**Congenital iris coloboma**

**Fig. 8.3** The congenital iris coloboma is located medially and inferiorly. The pupil merges with the coloboma without any sharp demarcation.

**Coloboma of the retina, choroid, and optic nerve**

**Fig. 8.4** This coloboma of the retina, choroid, and optic nerve exposes the underlying white sclera.

Visual acuity will generally be reduced in the presence of nystagmus.



## Coloboma

Another congenital anomaly results from **incomplete fusion of the embryonic optic cup**, which normally occurs in about the sixth week of pregnancy. These anomalies are known as **colobomas**. They are directed medially and inferiorly and can involve the iris (Fig. 8.5), ciliary body, zonule fibers, choroid, and optic

## 8.4 Pigmentation Anomalies

nerve (Fig. 8.4). **Bridge colobomas** exhibit remnants of the iris or choroid. Involvement of the choroid and optic nerve frequently leads to *reduced visual acuity*.

**Surgical iris colobomas** in cataract and glaucoma surgery are usually opened superiorly. In this manner, they are covered by the upper eyelid so the patient will not usually experience blinding glare.

**Traumatic iris colobomas** are caused by avulsion of the iris (iridolysis; Fig. 8.5).

## 8.4 Pigmentation Anomalies

### Heterochromia

Impaired development of the pigmentation of the iris can lead to a congenital **difference in coloration between the left and right iris (heterochromia)**. One iris containing varying pigmentation is referred to as **iris bicolor**. Isolated heterochromia is not necessarily clinically significant (simple heterochromia), yet it can be a sign of abnormal changes. The following types are differentiated:

**Fuchs' heterochromic cyclitis** (etiology unclear). This refers to *recurrent iridocyclitis* (simultaneous inflammation of several portions of the uveal tract) in adults, with *precipitates on the posterior surface of the cornea* without formation of posterior synechiae (adhesions between the iris and lens). The eye is *free of external irritation*. This disorder is often associated with complicated cataract and increased intraocular pressure (glaucoma).

**Sympathetic heterochromia**. In *unilateral impairment of the sympathetic nerve supply*, the affected iris is significantly lighter. Heterochromia with unilaterally lighter pigmentation of the iris also occurs in iridocyclitis, acute glaucoma, and anterior chamber hemorrhage (hyphema).

**Melanosis of the iris**. This refers to *dark pigmentation* of one iris. Aside from the difference in coloration between the two irises, neither sympathetic heterochromia nor melanosis leads to further symptoms. The only form of heterochromia that leads to abnormal changes is Fuchs' heterochromic cyclitis. The possible complications involved require specific treatment.

### Albinism

Albinism (from the Latin *albus*, white) is a congenital **metabolic disease that leads to hypopigmentation of the eye**. The following types are differentiated:

**Ocular albinism** (involving only the eyes)

**Oculocutaneous albinism** (involving the eyes, skin, and hair)



In albinism, the iris is light blue because of the melanin deficiency resulting from impaired melanin synthesis. Under slit lamp retroillumination, the *iris*

#### Ocular albinism

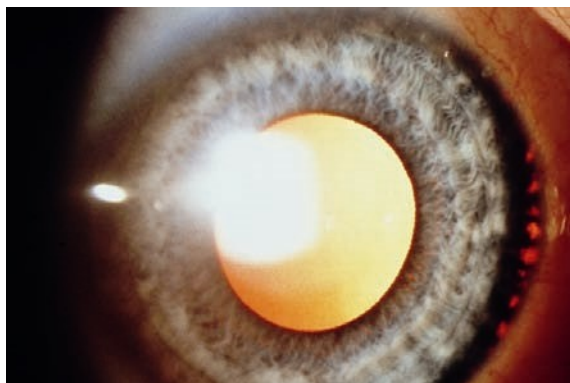


Fig. 8.6 The peripheral iris appears red with retroillumination.

#### Fundus in ocular albinism

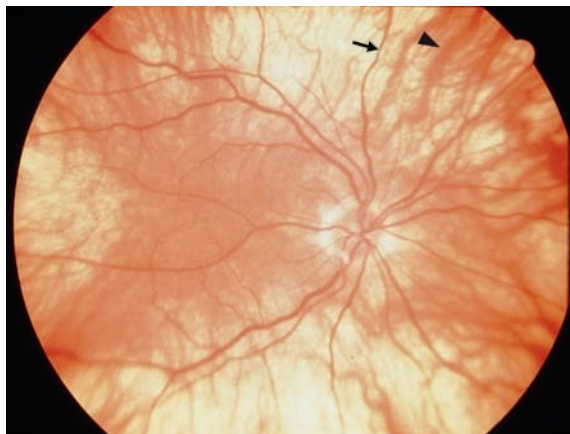


Fig. 8.7 Typical features include the choroidal vessels, which are visualized by ophthalmoscopy (thick arrowhead: choroidal vessel; arrow: retinal vessel).

*appears reddish* due to fundus reflex (Fig. 8.6). Ophthalmoscopy will detect *choroidal vessels* (Fig. 8.7). Associated foveal aplasia results in significant *reduction in visual acuity* and *nystagmus*. Most patients are also *photophobic* because of the missing filter function of the pigmented layer of the iris.

## 8.5 Inflammation

Inflammations of the uveal tract are classified according to the various portions of the globe:

Anterior uveitis (**iritis**).

Intermediate uveitis (**cyclitis**).

Posterior uveitis (**choroiditis**). However, some inflammations involve the middle portions of the uveal tract such as **iridocyclitis** (inflammation of the iris and ciliary body) or **panuveitis** (inflammation involving all segments).

### Acute Iritis and Iridocyclitis

**Epidemiology.** **Iritis** is the most frequent form of uveitis. It usually occurs in combination with cyclitis. About three-quarters of all **iridocyclitis** cases have an acute clinical course.

**Etiology.** Iridocyclitis is frequently attributable to **immunologic causes** such as allergic or hyperergic reaction to bacterial toxins. In some rheumatic disorders it is known to be frequently associated with the expression of specific human leukocyte antigens (HLA) such as HLA-B27. Iridocyclitis can also be a **symptom of systemic disease** such as ankylosing spondylitis, Reiter syndrome, sarcoidosis, etc. (Table 8.1).

**Infections** are less frequent and occur secondary to penetrating trauma or sepsis (bacteria, viruses, mycosis, or parasites). *Phacogenic inflammation*, possibly with glaucoma, can result when the lens becomes involved.

**Symptoms.** Patients report dull pain in the eye or forehead accompanied by impaired vision, photophobia, and excessive tearing (epiphora).

In contrast to choroiditis, acute iritis or iridocyclitis is painful because of the involvement of the ciliary nerves.

**Diagnostic considerations.** Typical signs include:

**Ciliary injection.** The episcleral and perilimbal vessels may appear blue and red.

**Combined injection.** The conjunctiva is also affected.

The **iris** is **hyperemic** (the iris vessels will be visible in a light-colored iris). The **structure** appears **diffuse** and **reactive miosis** is present.

Vision is impaired because of cellular infiltration of the anterior chamber and protein or fibrin accumulation (visible as a **Tyndall effect**). The precipitates accumulate on the posterior surface of the cornea in a triangular configuration known as Arlt's triangle. Exudate accumulation on the floor of the anterior chamber is referred to as **hypopyon** (Fig. 8.8). Viral infections may be accompanied by bleeding into the anterior chamber (**hyphema**; Fig. 8.9). Corneal edema can also develop in rare cases.

Tab. 8.1 Causes of uveitis according to location

Form of uveitis	Possible causes
HLA-B27-associated iridocyclitis	<ul style="list-style-type: none"> <li>Idiopathic</li> <li>Ankylosing spondylitis</li> <li>Reiter syndrome</li> <li>Regional enteritis</li> <li>Ulcerative colitis</li> <li>Psoriasis</li> </ul>
Non-HLA-B27-associated iridocyclitis	<ul style="list-style-type: none"> <li>Idiopathic</li> <li>Viral</li> <li>Tuberculosis</li> <li>Sarcoidosis</li> <li>Syphilis</li> <li>Leprosy</li> <li>Rheumatoid arthritis (Still–Chauffard syndrome)</li> <li>Heterochromic cyclitis</li> <li>Phacogenic uveitis</li> <li>Trauma</li> </ul>
Iridocyclitis and choroiditis	<ul style="list-style-type: none"> <li>Toxoplasmosis</li> <li>Sarcoidosis</li> <li>Tuberculosis</li> <li>Syphilis</li> <li>Behçet disease</li> <li>Sympathetic ophthalmia</li> <li>Borreliosis</li> </ul>

Brucellosis  
Yersiniosis  
Listeriosis  
Malignant tumors

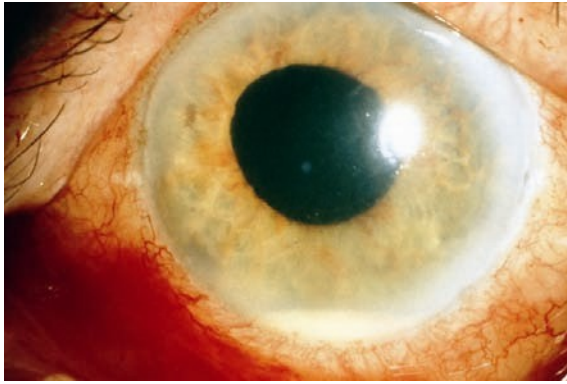---

Choroiditis

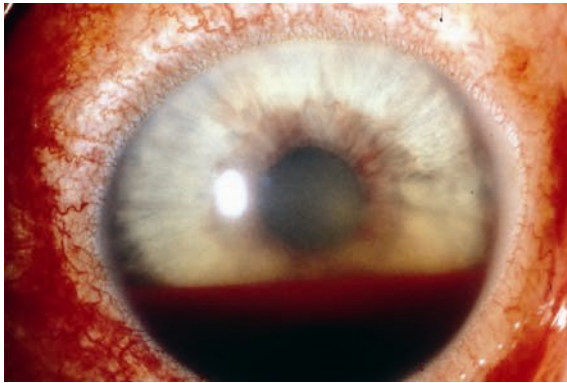Toxoplasmosis  
Sarcoidosis  
Syphilis  
Behçet disease  
Histoplasmosis  
Toxocara

Corneal edemas and Tyndall effects (accumulations of protein in the anterior chamber) can be diagnosed when the eye is illuminated with a lateral beam of light from a focused light or slit lamp.

**Differential diagnosis.** See Table 8.2.

**Hypopyon in acute iridocyclitis**

**Fig. 8.8** The purulent exudate accumulates as a pool on the floor of the anterior chamber.

**Hyphema**

**Fig. 8.9** Bleeding into the anterior chamber can occur in rubeosis iridis, trauma, or, in rare cases, iridocyclitis.

In acute iritis, the depth of the anterior chamber is normal and reactive miosis is present. In contrast, in acute glaucoma the anterior chamber is shallow and the pupil is dilated (Table 82).

**Complications.** These include:

**Secondary open angle glaucoma** with an increase in intraocular pressure

Adhesions between the iris and posterior surface of the cornea (**anterior synechiae**)

Adhesions between the iris and lens (**posterior synechiae**; Fig. 8.10)

Tab. 8.2 Differential diagnosis of iritis and acute glaucoma

Differential criteria	Acute iritis	Acute glaucoma
Symptoms	Dull pain and photophobia	Intense pain and vomiting
Conjunctiva	Combined injection	Combined injection
Cornea	Clear	Opacified, edematous
Anterior chamber	Normal depth; cells and fibrin are present	Shallow
Pupil	Narrowed (reactive miosis)	Dilatated, not round
Globe	Normal pressure	“Rock hard”

#### Posterior synechiae secondary to iridocyclitis (cloverleaf pupil)

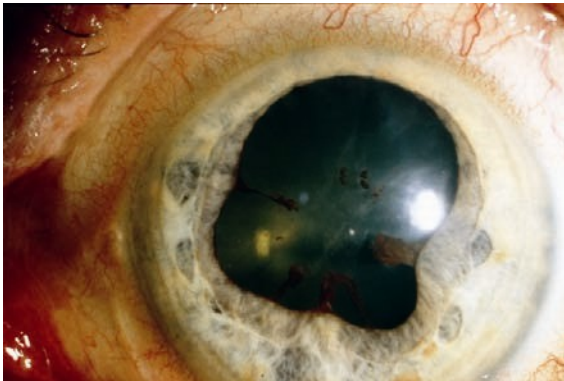


Fig. 8.10 Acute iridocyclitis produces adhesions between the iris and lens (see also Fig. 8.5).

**Treatment.** Topical and, in appropriate cases, systemic antibiotic or antiviral therapy is indicated for iridocyclitis due to a pathogen (with a corneal ulcer, penetrating trauma, or sepsis).

A conjunctival smear, or a blood culture in septic cases, is obtained to identify the pathogen. Antibiotic therapy should begin immediately as microbiological identification of the pathogen is not always successful.

Therapeutic mydriasis in combination with steroid therapy is indicated to **minimize the risk of synechiae**. Where no pathogen can be identified, high-dose topical steroid

therapy (prednisolone eyedrops every hour in combination with subconjunctival injections of soluble dexamethasone) is administered. To minimize the risk of *posterior synechiae*, the pupil must be maximally dilated (atropine, scopolamine, cyclopentolate, and possibly epinephrine eyedrops).

The mydriatic effect of dilating eyedrops may be reduced in iritis. This may necessitate the use of longer-acting medications such as atropine, which may have to be applied several times daily.

Occasionally it is possible to break off existing synechiae in this manner, and patches of iris tissue will remain on the anterior surface of the lens. **Secondary open angle glaucoma** is treated by administering beta blockers in eyedrop form and, in applicable cases, carbonic anhydrase inhibitors (acetazolamide; see Table 10.3).

**Prognosis.** Symptoms usually improve within a few days when proper therapy is initiated. The disorder can progress to a chronic stage.

### Chronic Iritis and Iridocyclitis

**Epidemiology.** About a quarter of all **iridocyclitis** cases have a chronic clinical course.

**Etiology.** See Table 8.1.

**Symptoms.** See Acute Iritis and Iridocyclitis. Chronic iridocyclitis may exhibit minimal symptoms.

**Diagnostic considerations.** See Acute Iritis and Iridocyclitis.

**Differential diagnosis.** The disorder should be distinguished from acute glaucoma, conjunctivitis, and keratitis.

**Complications.** Total obliteration of the pupil by posterior synechiae is referred to a **pupillary block**. Because the aqueous humor can no longer circulate, **secondary angle closure glaucoma with iris bombé** occurs. **Occlusion of the pupil** also results in fibrous scarring in the pupil. This can lead to the development of posterior subcapsular opacities in the lens (**secondary cataract**). Recurrent iridocyclitis can also lead to calcific band keratopathy.

**Treatment.** In **pupillary block** with a secondary angle closure glaucoma, a *Nd:YAG laser iridotomy* can be performed to create a shunt to allow the aqueous humor from the posterior chamber to circulate into the anterior chamber. In the presence of a **secondary cataract**, a cataract *extraction* can be performed when the inflammation has abated.

**Prognosis.** Because of the chronic recurrent course of the disorder, it frequently involves complications such as synechiae or cataract that may progress to blindness from shrinkage of the eyeball.

## Choroiditis

**Epidemiology.** There are few epidemiologic studies of choroiditis. The annual incidence is assumed to be four cases per 100 000 people.

**Etiology.** See Table 8.1.

**Symptoms.** Patients are free of pain, although they report blurred vision and floaters.

■ Choroiditis is painless, as the choroid is devoid of sensory nerve fibers.

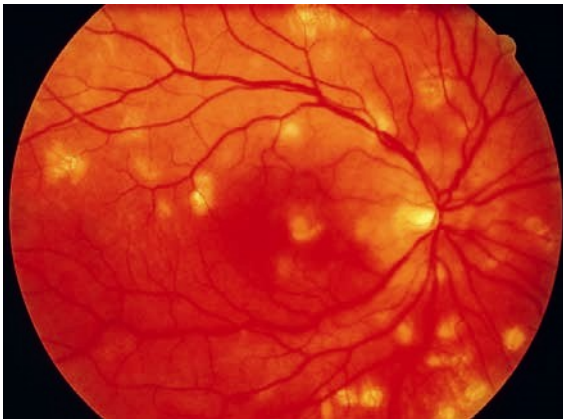**Diagnostic considerations.** Ophthalmoscopy reveals isolated or multiple choroiditis foci. In *acute disease* they appear as ill-defined white dots (Fig. 8.11). *Once scarring has occurred* the foci are sharply demarcated with a yellowish-brown color. Occasionally the major choroidal vessels will be visible through the atrophic scars.

*No cells will be found in the vitreous body* in a **primary choroidal process**. However, inflammation proceeding from the retina (**retinochoroiditis**) will exhibit *cellular infiltration of the vitreous body*.

**Differential diagnosis.** This disorder should be distinguished from retinal inflammations, which are accompanied by cellular infiltration of the vitreous body and are most frequently caused by viruses or *Toxoplasma gondii*.

**Treatment.** Choroiditis is treated either with antibiotics or steroids, depending on its etiology.

### Multifocal choroiditis



**Fig. 8.11** The foci of acute inflammation are yellowish and ill-defined; older lesions are yellowish-brown and sharply demarcated.



**Prognosis.** The inflammatory foci will heal within 2–6 weeks and form chorioretinal scars. The scars will result in localized scotomas that will reduce visual acuity if the macula is affected.

## Sympathetic Ophthalmia

**Definition:** Specific bilateral inflammation of the uveal tract due to chronic irritation of one eye, caused by a perforating wound to the eye or intraocular surgery, produces transferred uveitis in the fellow eye.

**Epidemiology.** Sympathetic ophthalmia is very rare.

**Etiology.** Sympathetic uveitis can occur in an *otherwise unaffected eye* even years after penetrating injuries or intraocular surgery in the fellow eye, especially where there was chronic irritation. Tissues in the injured eye (uveal tract, lens, and retina) act as antigens and provoke an autoimmune disorder in the unaffected eye.

**Symptoms.** The earliest symptoms include limited range of accommodation and photophobia. Later there is diminished visual acuity and pain.

**Diagnostic considerations.** Clinical symptoms include combined injections, cells and protein in the anterior chamber and vitreous body, papillary and retinal edema, and granulomatous inflammation of the choroid.

**Differential diagnosis.** The disorder should be distinguished from iridocyclitis and choroiditis from other causes (see Table 8.1).

**Treatment.** The injured eye, which is usually blind, must be enucleated to eliminate the antigen. High-dose topical and systemic steroid therapy is indicated. Concurrent treatment with immunosuppressives (cyclophosphamide and azathioprine) may be necessary.

**Clinical course and complications.** The disorder has a chronic clinical course and may involve severe complications of uveitis such as secondary glaucoma, secondary cataract, retinal detachment, and shrinkage of the eyeball. Sympathetic ophthalmia can lead to blindness in particularly severe cases.

When the injured eye is blind, prophylactic enucleation is indicated before the onset of sympathetic ophthalmia in the fellow eye. An early sign of sympathetic ophthalmia is a limited range of accommodation with photophobia.

## 8.6 Neovascularization in the Iris: Rubeosis Iridis

**Definition:** Rubeosis iridis is neovascularization in the iris that occurs in various retinal disorders.

**Etiology.** The most frequent causes of rubeosis iridis (Fig. 8.12) are *proliferative diabetic retinopathy* and *retinal vein occlusion*. Retinal periphlebitis is a less frequent cause of neovascularization in the iris.

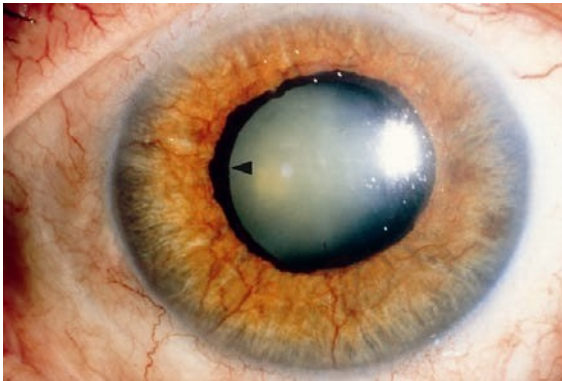
**Symptoms and diagnostic considerations.** Neovascularization in the stroma of the iris is *asymptomatic* for the patient. Neovascularization in the angle of the anterior chamber is irreversible and produces secondary angle closure glaucoma with the typical *symptoms of acute glaucoma*: loss of visual acuity, intense pain, conjunctival and ciliary injection, and a “rock hard” eyeball upon palpation (see Fig. 10.21).

**Differential diagnosis.** Acute glaucoma due to other causes such as acute angle closure glaucoma should be excluded.

**Treatment, prognosis, and prophylaxis.** Rubeosis iridis is tantamount to the loss of an eye. Usually it leads to irreversible blindness. Prompt laser treatment of retinal disorders is crucial to prevent rubeosis iridis. Secondary angle closure glaucoma is treated by transscleral freezing of the ciliary body (cyclocryotherapy) or laser treatment (cyclophotocoagulation) to reduce intraocular pressure. Where this fails or the eye shrinks (phthisis bulbi) and the patient experiences intense pain, enucleation of the eye is indicated.

Prompt laser treatment is important in high-risk proliferative diabetic reti-

#### Neovascularization in the iris: rubeosis iridis



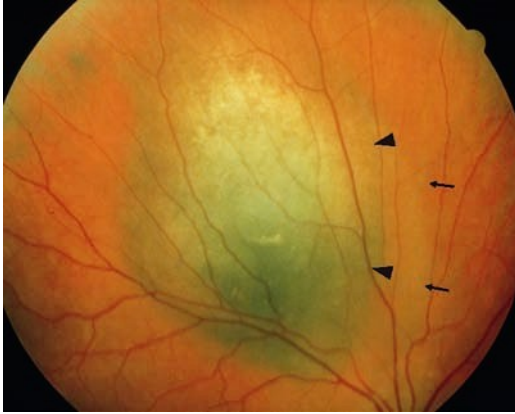**Fig. 8.12** Protrusion of the pigmented layer (arrowhead) indicates that the rubeosis iridis has been present for at least several weeks.

nopathy to prevent rubeosis iridis.

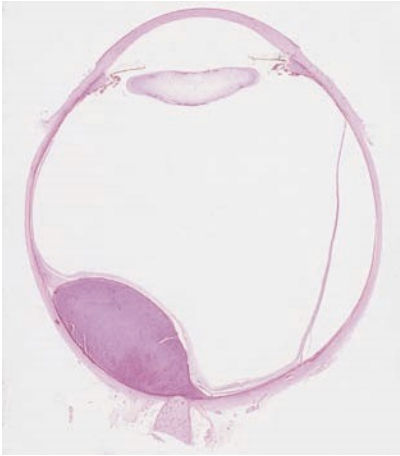## 8.7 Tumors

### Malignant Tumors (Uveal Melanoma)

With an incidence of one in 10 000, malignant uveal melanoma is the most common primary intraocular tumor. It usually occurs as a choroidal melanoma, and is almost always unilateral. *Tumors in the iris* are detected earlier than tumors located in the *ciliary body* and *choroid* (Fig. 8.13).

**Choroidal melanoma**

**Fig. 8.13 a** A prominent yellowish-brown choroidal tumor (thick arrowheads) accompanied by serous retinal detachment (arrows). Compare the ultrasound findings shown in Fig. 126.



**b** This histological image (from another eye, but with identical findings) shows tumor growth into the eye in direction of the retina, causing visual problems at an advanced stage.

### Choroidal metastases

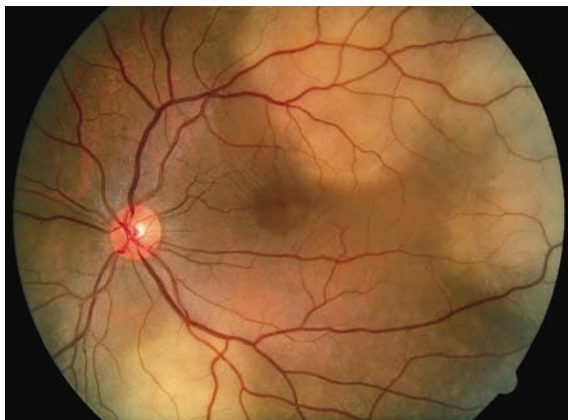


Fig. 8.14 Flat, grayish-brown choroidal tumors.

**Iris melanomas.** These tumors are *often initially asymptomatic*. However, metastatic melanoma cells in the angle of the anterior chamber can lead to *secondary glaucoma*. Circumscribed iris melanomas are removed by *segmental iridectomy*.

**Ciliary body melanomas.** Symptoms include changes in accommodation and refraction resulting from displacement of the lens. Ciliary body melanomas are resected en bloc.

**Choroidal melanomas.** These tumors become clinically symptomatic when involvement of the macula *reduces visual acuity* or the patient notices a shadow in his or her field of vision as a result of the tumor and the accompanying *retinal detachment*. The diagnosis is confirmed with the aid of transillumination, ultrasound, and fluorescein angiography. Choroidal tumors are treated with radioactive isotopes delivered by plaques of radioactive material (*brachytherapy*). *Enucleation* is indicated for tumors whose diameter exceeds 8 mm and whose prominence exceeds 5 mm.

**Uveal metastases** most frequently develop from carcinomas of the breast or lung. They are usually flat, with little pigmentation. (Fig. 8.14)

### Benign Choroidal Tumors

Choroidal nevi (Fig. 8.15) occur in 11% of the population. They can lead to secondary neovascularization with retinal edema. In very rare cases in which the macula is

involved, choroidal nevi can lead to impaired vision. However, benign choroidal tumors are normally asymptomatic.

### 8.7 Tumors

#### Benign choroidal tumor (nevus)

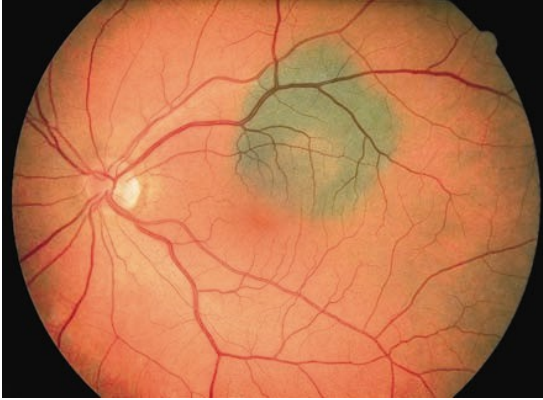


Fig. 8.15 In contrast to uveal melanoma (Fig. 8.13), the nevus is flat, has more pigment, is

stable, and does not change in size. As it is located underneath the retina, it does not cause any visual problems.

