

## 7 čočka

### Vrozená

### Získaná

### Stacionární

### Progredující

#### 7.1 Basic Knowledge

**Function of the lens.** The lens is one of the essential refractive media of the eye and focuses incident rays of light on the retina. It adds a variable element to the eye's total refractive power (10–20 diopters, depending on individual accommodation) to the fixed refractive power of the cornea (approximately 43 diopters).

**Shape.** The fully developed lens is a **biconvex, transparent structure**. The curvature of the posterior surface, which has a radius of 6 mm, is greater than that of the anterior surface, which has a radius of 10 mm.

**Weight.** The lens is approximately 4 mm thick, and its weight increases with age to five times its weight at birth. An adult lens weighs about 220 mg.

**Position and suspension.** The lens lies in the posterior chamber of the eye between the posterior surface of the iris and the vitreous body in a **saucershaped depression of the vitreous body** known as the hyaloid fossa. Together with the iris it forms an optical diaphragm that separates the anterior and posterior chambers of the eye. Radially arranged **zonule fibers** that insert into the lens around its equator connect the lens to the ciliary body. These fibers hold the lens in position (Fig. 7.1) and transfer the tensile force of the ciliary muscle (see Accommodation, p. 437).

**Embryology and growth.** The lens is a **purely epithelial structure** without any nerves or blood vessels. It moves into its intraocular position in the first month of fetal development as surface ectoderm invaginates into the primitive optic vesicle, which consists of neuroectoderm. *A purely ectodermal structure*, the lens differentiates during gestation into central geometric lens fibers, an anterior layer of epithelial cells, and an acellular hyaline capsule (Fig. 7.2). The normal **direction of growth** of epithelial structures is centrifugal; fully developed epithelial cells migrate to the surface and are peeled off. However, the lens grows in the *opposite* direction. The

— youngest cells are always on the surface and the oldest cells in the center of the lens. The growth of primary lens fibers forms the **embryonic nucleus**. At the **equator**, the epithelial cells further differentiate into lens fiber cells (Fig. 7. 2). These new secondary fibers displace the primary fibers toward the center of the lens.

### Shape of the lens and its position in the eye

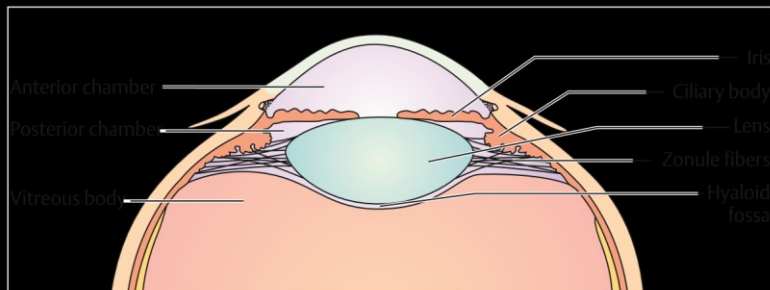


Fig. 7.1 The lens is a biconvex structure suspended on the zonule fibers. It lies in the hyaloid fossa and separates the anterior and posterior chambers of the eye.

### Embryology of the lens

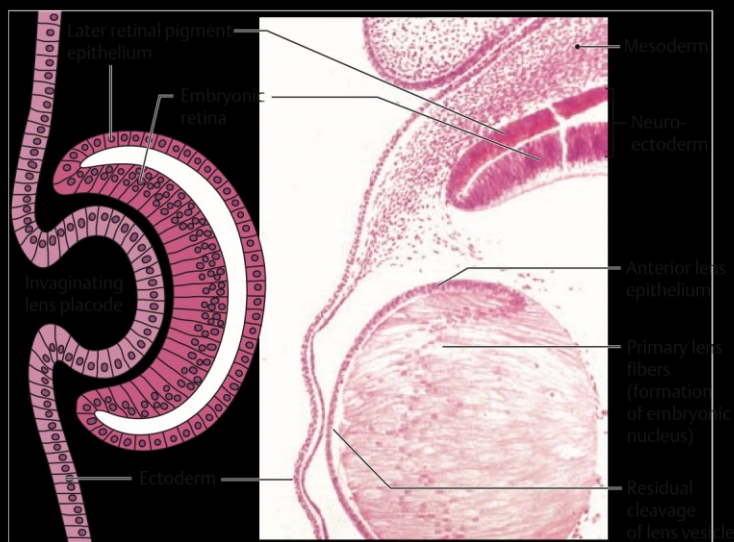


Fig. 7.2 a First month of fetal development. The ectoderm invaginates and is isolated in what becomes the optic cup. b The lens vesicle is completely invaginated. The primary lens fibers grow and begin to form the embryonic nucleus.

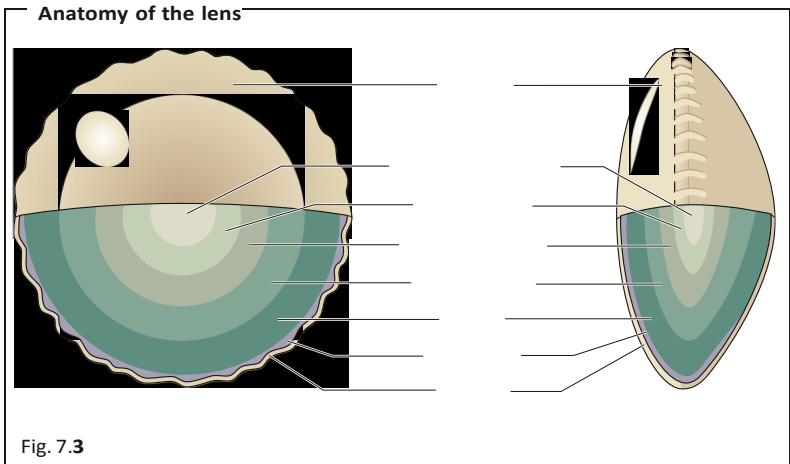
### 7.1 Basic Knowledge

Formation of a **fetal nucleus** that encloses the embryonic nucleus is complete at birth. Fiber formation at the equator, which continues throughout life, produces the **infantile nucleus** during the first and second decades of life, and the **adult nucleus** during the third decade. Completely enclosed by the lens capsule, the lens never loses any cells so that its tissue is continuously compressed throughout life (Fig. 7.3). The various density zones created as the lens develops are readily discernible as discontinuity zones (Fig. 7.4).

**Metabolism and aging of the lens.** The lens is nourished by **diffusion from the aqueous humor**. In this respect it resembles a tissue culture, with the aqueous humor as its substrate and the eyeball as the container that provides a constant temperature.

The metabolism and detailed biochemical processes involved in aging are complex and not completely understood. Because of this, it has not been possible to influence cataract development (see Cataract, p. 174) with medications.

The metabolism and growth of the lens cells are self-regulating. Metabolic activity is essential for the preservation of the integrity, transparency, and optical function of the lens. The epithelium of the lens helps to maintain the ion equilibrium and permit **transportation of nutrients, minerals, and water into the lens**. This type of transportation, referred to as a “pump-leak system,” permits active transfer of sodium, potassium, calcium, and amino acids from the aqueous humor into the lens as well as passive diffusion through the posterior lens capsule. Maintaining this equilibrium (homeostasis) is essential



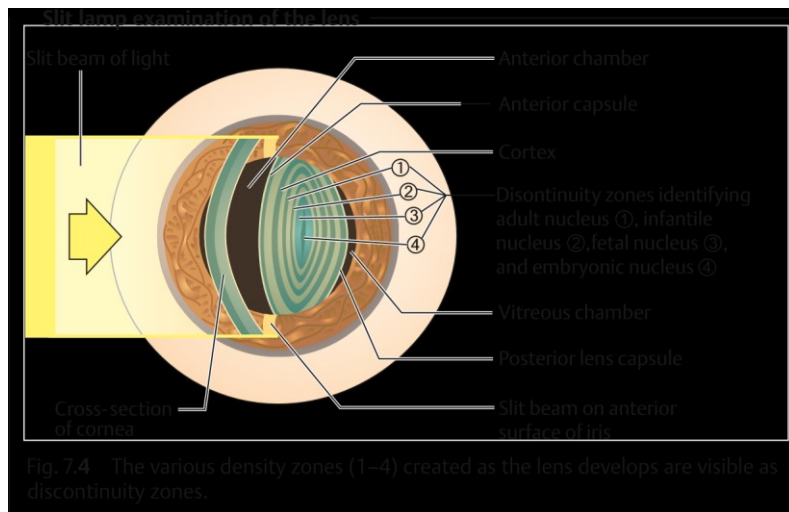


Fig. 7.4 The various density zones (1–4) created as the lens develops are visible as discontinuity zones.

for the transparency of the lens and is closely related to the water balance. The **water content of the lens** is normally stable and in equilibrium with the surrounding aqueous humor. The water content of the lens decreases with age, whereas the content of insoluble lens proteins (albuminoid) increases. The lens becomes harder, less elastic (see Loss of accommodation), and less transparent. A **decrease in the transparency of the lens with age** is as unavoidable as wrinkles in the skin or gray hair. Manifestly reduced transparency is present in 95% of persons over the age of 65, although individual exceptions are not uncommon. The central portion or nucleus of the lens becomes sclerosed and slightly yellowish with age.

## 7.2 Examination Methods

**Cataracts.** Retroillumination of the lens (Brückner's test) is the *quickest preliminary examination method* for lens opacities (Cataracts, see section 7.4). Under a light source or ophthalmoscope (set to 10 diopters), opacities will appear black in the red pupil (Fig. 7.5). The lens can be examined *in greater detail and in three dimensions* under focal illumination with a slit lamp with the pupil maximally dilated. The extent, type, location, and density of opacities and their relation to the visual axis can be evaluated. Mature lens opacities can be diagnosed with the unaided eye by the presence of a white pupil (leukocoria).

### 7.3 Developmental Anomalies of the Lens

#### Retroillumination of the lens (Brückner's test)

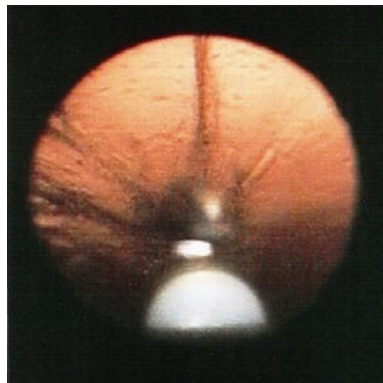


Fig. 7.5 Opacities appear black in the red pupil.

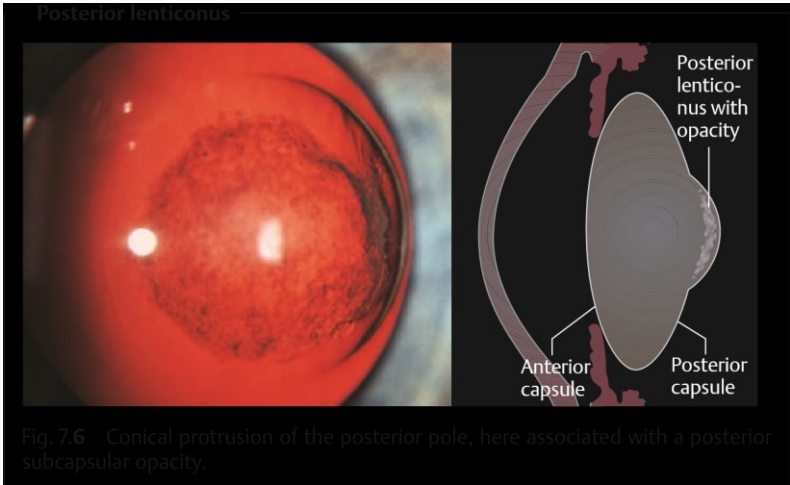
Where the fundus is not visible in the presence of a mature lens opacity, ultrasound studies (one-dimensional A-scan and two-dimensional B-scan studies) are indicated to exclude involvement of the deeper structures of the eye.

**Iridodonesis and phacodonesis.** Tremulous motion of the iris and lens observed during slit lamp examination suggests subluxation of the lens (see p. 202).

### 7.3 Developmental Anomalies of the Lens

Anomalies of lens shape are very rare. Lenticonus is a circumscribed conical protrusion of the anterior pole (anterior lenticonus) or posterior pole (posterior lenticonus). A hemispherical protrusion is referred to as lentiglobus. Symptoms include myopia and reduced visual acuity. Some patients with Alport syndrome (kidney disease accompanied by sensorineural hearing loss and anomalies of lens shape) have *anterior* lenticonus. *Posterior lenticonus* may be associated with a lens opacity (Fig. 7.6). Treatment is the same as for congenital or juvenile cataract.

**Microphakia** refers to a lens of abnormally small diameter. Any interruption of the development of the eye generally leads to microphakia. This can occur for example in Weill–Marchesani syndrome (see Table 7.5).



## 7.4 Cataract

**Definition:** A cataract is present when the transparency of the lens is reduced to the point that the patient's vision is impaired. The term **cataract** comes from the Greek word *katarraktes* (down-rushing; waterfall), because earlier it was thought that the cataract was a congealed fluid from the brain that had flowed in front of the lens.

**General symptoms.** Development of the cataract and its symptoms is generally an *ocult process*. Patients experience the various symptoms such as seeing only shades of gray, visual impairment, blurred vision, distorted vision, glare or star bursts, monocular diplopia, altered color perception, etc. to varying degrees, and these symptoms will vary with the specific type of cataract (see Table 7.3 and Fig. 7.7).

Diagnosis of a cataract is generally very unsettling for patients, who immediately associate it with surgery. One should therefore refer only to a cataract when it has been established that surgery is indicated. If the cataract has not progressed to an advanced stage or the patient can cope well with the visual impairment, one should refer instead to a “lens opacity.”

### Cataract symptoms



**Fig. 7.7 a** Visual image without a cataract.



**b** Visual image with a cataract: there are gray areas and partial loss of image perception. Color perception is different.



**Classification.** Cataracts can be classified according to several different criteria.

Time of occurrence (acquired or congenital cataracts).

Maturity.

Morphology.

No one classification system is completely satisfactory. We prefer the system shown in Table 7.1.

Tab. 7.1 Classification of cataracts according to time of occurrence

<b>Acquired cataracts (over 99% of cataracts)</b>	<p>Senile cataract (over 90% of cataracts) Cataract with systemic disease</p> <ul style="list-style-type: none"> <li>– Diabetes mellitus</li> <li>– Galactosemia</li> <li>– Renal insufficiency</li> <li>– Mannosidosis</li> <li>– Fabry disease</li> <li>– Lowe syndrome</li> <li>– Wilson disease</li> <li>– Myotonic dystrophy</li> <li>– Tetany</li> <li>– Skin disorders</li> </ul> <p>Complicated cataracts</p> <ul style="list-style-type: none"> <li>– Cataract with heterochromia</li> <li>– Cataract with chronic iridocyclitis</li> <li>– Cataract with retinal vasculitis</li> <li>– Cataract with retinitis pigmentosa</li> </ul> <p>Postoperative cataracts</p> <ul style="list-style-type: none"> <li>– Most frequently following vitrectomy and silicone oil retinal tamponade</li> <li>– Following filtering operations</li> </ul> <p>Traumatic cataracts</p> <ul style="list-style-type: none"> <li>– Contusion or perforation rosette</li> <li>– Infrared radiation (glassblower's cataract)</li> <li>– Electrical injury</li> <li>– Ionizing radiation</li> </ul> <p>Toxic cataract</p> <ul style="list-style-type: none"> <li>– Corticosteroid-induced cataract (most frequent)</li> <li>– Less frequently from chlorpromazine, mitotic agents, or busulfan</li> </ul>
<b>Congenital cataracts (fewer than 1% of cataracts)</b>	<p>Hereditary cataracts</p> <ul style="list-style-type: none"> <li>– Autosomal-dominant</li> <li>– Autosomal-recessive</li> <li>– Sporadic</li> <li>– X-linked</li> </ul> <p>Cataracts due to early embryonic (transplacental) damage</p> <ul style="list-style-type: none"> <li>– Rubella (40–60%)</li> <li>– Mumps (10–22%)</li> <li>– Hepatitis (16%)</li> </ul>

- Toxoplasmosis (5%)

## Acquired Cataract

### Senile Cataract

**Epidemiology.** Senile cataract is by far the most frequent form of cataract, accounting for 90% of cataracts. About 5% of 70-year-olds and 10% of 80-year-olds suffer from a cataract requiring surgery.

■ Ninety percent of cataracts are senile cataracts.

**Etiology.** The precise causes of senile cataract have not been identified. As occurrence is often familial, it is important to obtain a detailed family history.

**Classification and forms of senile cataracts.** The classification according to **maturity** (Table 7.2) follows the degree of visual impairment and the maturity, which earlier was important to determine the time of surgery. We follow a **morphologic classification** as morphologic aspects such as the hardness and thickness of the nucleus now influence the surgical procedure (Table 7.3):

**Nuclear cataract.** In the fourth decade of life, the pressure of peripheral lens fiber production causes hardening of the entire lens, especially the nucleus. The nucleus takes on a *yellowish-brown color (brunescens nuclear cataract)*. This may range from reddish-brown to nearly black discoloration of the entire lens (black cataract). Because they increase the refractive power of the lens, nuclear cataracts lead to lenticular myopia and occasionally produce a second focal point in the lens with resulting monocular diplopia (Fig. 7.8).

■ Nuclear cataracts develop very slowly. Due to the lenticular myopia, near vision (even without eyeglasses) remains good for a long time.


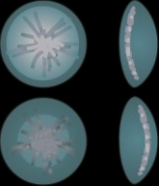

**Cortical cataract.** Nuclear cataracts are often associated with changes in the lens

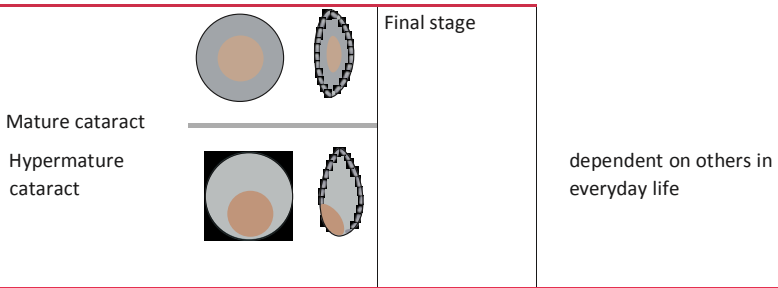
Cataract form	Visual acuity
Developing cataract	Still full (0.8–1.0)
Immature cataract	Reduced (0.4–0.5)
Developed cataract	Severely reduced (1/50–0.1)
Mature cataract, hypermature cataract	Light and dark perception, perception of hand movements in front of the eye

cortex. It is interesting to note that patients with cortical cataracts tend to have acquired hyperopia in contrast to patients with nuclear cataracts, who tend to be myopic (see above).

Tab. 7.2 Classification of cataracts in relation to maturity

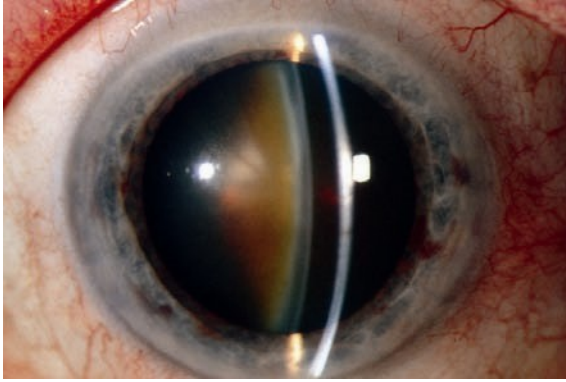
Tab 7.3 Overview of forms of senile cataract

Cataract form	Morphology	Incidence	Symptoms
Nuclear cataract		About 30%, particularly in more severe myopia	<ul style="list-style-type: none"> <li>- Shades of gray (like looking through frosted glass)</li> <li>- Blurred vision</li> <li>- Distorted vision</li> <li>- Intense glare in bright light</li> <li>- Diminished contrast</li> </ul>
<p>Anterior subcapsular cataract</p> <p>Posterior</p>		About 50%	<ul style="list-style-type: none"> <li>- Changes in color perception (rare)</li> <li>- Frequent change of refraction</li> </ul>
Posterior subcapsular cataract		About 20%	<ul style="list-style-type: none"> <li>- Objects no longer discernible</li> <li>- Patients with bilateral cataracts are practically blind and</li> </ul>



Visual acuity	Progression	Peculiarities, glare, eyesight in twilight	Diagnosis and prognosis for vision
<ul style="list-style-type: none"> <li>- Impairment is relatively <i>late</i></li> <li>- Increasing <i>poor distance vision</i></li> <li>- <i>Near vision</i> remains due to myopic effect of cataract</li> </ul>	Slow	<ul style="list-style-type: none"> <li>- Eyesight in twilight often better than in daylight because the mydriasis in darkness allows light past the opacity</li> <li>- Glare is less pronounced</li> <li>- Monocular diplopia due to two focal points in the lens</li> </ul>	<ul style="list-style-type: none"> <li>- Morphology by transillumination (Brückner's test)</li> </ul>
<ul style="list-style-type: none"> <li>- <i>Early loss of visual acuity</i></li> <li>- Hyperopic effect of cataract compromises <i>distance vision</i> less than near vision</li> </ul>	Rapid (temporary improvement in visual acuity due to stenopeic effect)	<ul style="list-style-type: none"> <li>- Patient is severely hampered by glare (sun, snow, headlights). Patients typically prefer dark glasses and wide-brimmed hats.</li> <li>- Marked improvement of vision <i>in twilight</i> and <i>at night</i> (nyctalopia)</li> </ul>	<ul style="list-style-type: none"> <li>- Detailed diagnosis in slit-lamp examination</li> <li>- Prediction of expected postoperative visual acuity: <i>laser interference visual acuity testing</i></li> </ul>

<ul style="list-style-type: none"> <li>- Early loss of visual acuity</li> <li>- Near vision particularly affected, <i>distance vision</i> less so</li> </ul>	Rapid		
<p>Visual acuity reduced to perception of light and dark; perception of hand movements in front of the eye at best</p>	<p>All cataract forms will progress to a mature or hypermature form given enough time</p>	<p>In intense light, patient will perceive gross movements and persons as silhouettes</p>	<ul style="list-style-type: none"> <li>- Leukocoria (white pupil) detectable with unaided eye</li> <li>- Slit lamp permits differentiation</li> <li>- Retinoscopy to determine visual acuity is often ineffective with dense opacities</li> </ul>

**Nuclear cataract**

**Fig. 7.8** The nucleus of the lens has a yellowish brown color due to the pressure of peripheral lens fiber production.

Whereas changes in *nuclear* cataracts are due to hardening, *cortical* changes are characterized by *increased water content*. Several morphologic changes will be apparent upon slit lamp examination with maximum mydriasis:

*Vacuoles*. Fluid accumulations will be present in the form of small narrow cortical vesicles. The vacuoles remain small and increase in number.

*Water fissures*. Radial patterns of fluid-filled fissures will be seen between the fibers.

*Separation of the lamellae*. Not as frequent as water fissures, these consist of a zone of fluid between the lamellae (often between the clear lamellae and the cortical fibers).

*Cuneiform cataract*. This is a frequent finding in which the opacities radiate from the periphery of the lens like spokes of a wheel.

Cortical cataracts progress more rapidly than nuclear cataracts. Visual acuity may temporarily improve during the course of the disease. This is due to a stenopeic effect as light passes through a clear area between two radial opacities.

**Posterior subcapsular cataract.** This is a *special form of cortical cataract* that begins in the visual axis. Beginning as a small cluster of granular opacities, this form of cataract expands peripherally in a disc-like pattern. As opacity increases, the rest of the cortex and the nucleus become involved (the usual spectrum of senile cataract).

Posterior subcapsular cataract leads to early, rapid, and severe loss of visual acuity. Near vision is usually significantly worse than distance vision (near-field miosis). Dilating eyedrops can improve visual acuity in this form of cataract.

**Mature cataract.** The lens is diffusely white due to *complete opacification of the cortex*. A brownish lens nucleus is often faintly discernible (Fig. 7.9). Where water

content is increased, a lens with a mature cataract can swell and acquire a silky luster (intumescent cataract in which the capsule is under pressure). The increasing thickness of the lens increases the resistance of the pupil and with it the risk of angle closure glaucoma.

Vision is reduced to perception of light and dark, and the interior of the eye is no longer visible. Cataract surgery is indicated to restore visual acuity.

**Hypermaturation cataract.** If a mature cataract progresses to the point of complete liquefaction of the cortex, the dense brown nucleus will subside within the capsule. Its superior margin will then be visible in the pupil as a dark brown silhouette against the surrounding grayish white cortex. The pressure in the lens capsule decreases. The contents of the limp and wrinkled capsular bag gravitate within the capsule. This condition, referred to as *Morgagni's cataract*, is the final stage in a cataract that has usually developed over the course of two decades. The approximate onset of the cataract can usually be inferred from such findings (Fig. 7.10).

Mature cataract

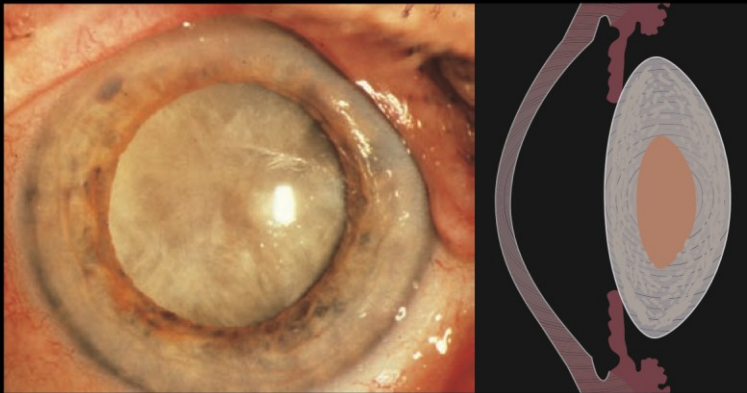
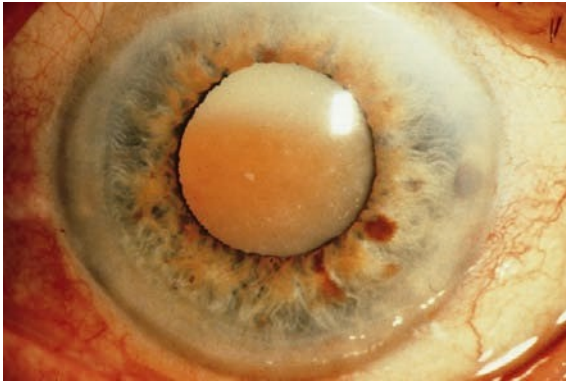


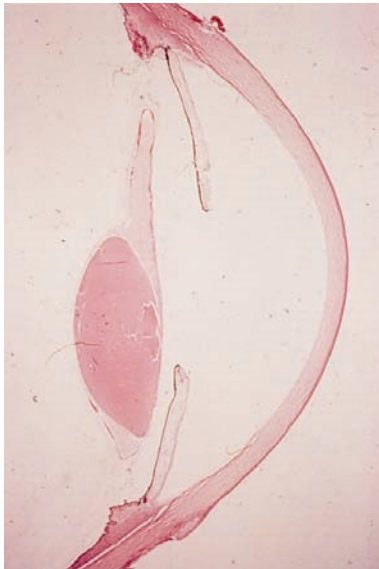Fig. 7.9

- There is diffuse, complete opacification of the lens. A brownish nucleus is faintly visible posterior to the cortical layer.
- Interior of the eye is no longer visible.
- Visual acuity is reduced to perception of light and dark.



**Hypermature cataract**

**Fig. 7.10 a** The brown nucleus has subsided in the liquefied cortex.



**b** The histologic image obtained at autopsy shows the position of the subsided nucleus and the shrunken capsular bag.

Prompt cataract extraction not only restores visual acuity but also prevents development of phacolytic glaucoma.

When the lens capsule becomes permeable for liquefied lens substances, it will lose volume due to leakage. The capsule will become wrinkled. The escaping lens proteins will cause intraocular irritation and attract macrophages that then cause congestion of the trabecular network (*phacolytic glaucoma*: see Secondary open angle glaucoma).

Emergency extraction of the hypermature cataract is indicated in phacolytic glaucoma to save the eye.

## Cataract in Systemic Disease

**Epidemiology.** Lens opacities can occasionally occur as a sign of systemic disease.

### Types of cataract in systemic disease:

**Diabetic cataract.** The typical diabetic cataract is rare in young diabetic patients. Transient metabolic decompensation promotes the occurrence of a typical radial snowflake pattern of cortical opacities (snowflake cataract). Transient hyperopia and myopia can occur.

Diabetic cataract progresses rapidly. Senile cataracts are observed about five times as often in older diabetics as in patients the same age with normal metabolism. These cataracts usually also occur 2–3 years earlier.

**Galactosemic cataract.** This *deep posterior cortical opacity* begins after birth. Galactosemia is a rare cause of early cataract in children lacking an enzyme required to metabolize galactose. The newborn receives ample amounts of galactose in the mother's milk. Due a lack of uridylyl transferase, or less frequently galactokinase, galactose cannot be metabolized to glucose, and the body becomes inundated with galactose or with galactose and galactose-1-phosphate. If the disorder is diagnosed promptly and the child is maintained on a galactose-free diet, the opacities of the first few weeks of life will be reversible.

Galactosemic cataract is the only form of cataract that responds to conservative therapy.

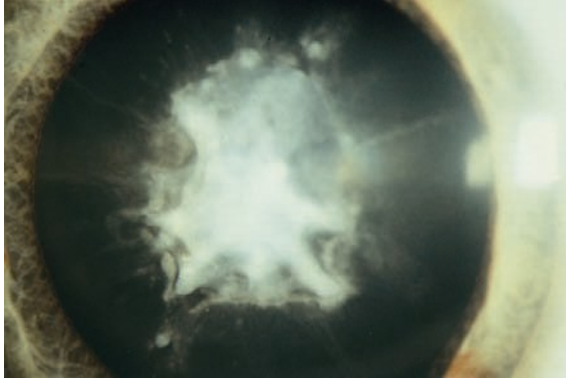
**Dialysis cataract.** Hemodialysis to eliminate metabolic acidosis in renal insufficiency can disturb the osmotic equilibrium of lens metabolism and cause swelling of the cortex of the lens.

Other *rare metabolic diseases* that can cause cataract include mannosidosis, Fabry disease, Lowe syndrome (oculocerebrorenal syndrome), and Wilson disease (hepatolenticular degeneration).

**Cataract with myotonic dystrophy.** Opacities first occur between the ages of 30 and 50, initially in a thin layer of the anterior cortex and later also in the subcapsular posterior cortex in the form of rosettes. Detecting these opacities is important for *differential*

*diagnosis* as cataracts do not occur in Thomsen disease (myotonia congenita) or Erb progressive muscular dystrophy.

#### Dermatogenous cataract



**Fig. 7.11** Typical symptoms include a crest-shaped whitish opacity beneath the anterior lens capsule along the visual axis.

Symptoms that *confirm the diagnosis* include cataract, active signs of myotonia (delayed opening of the fist), and passive signs of myotonia (decreased relaxation of muscles in the extremities following direct percussion of the muscle and absence of reflexes).

**Tetany cataract.** The opacity lies within a broad zone inferior to the anterior lens capsule and consists of a series of gray punctate lesions. Symptoms that *confirm the diagnosis* include low blood calcium levels, a positive hyperventilation test, and signs of tetany: positive Chvostek, Trousseau, and Erb signs.

**Dermatogenous cataract.** This may occur with chronic neurodermatitis and less frequently with other skin disorders such as scleroderma, poikiloderma, and chronic eczema. Characteristic signs include an anterior crest-shaped thickening of the protruding center of the capsule (Fig. 7.11).

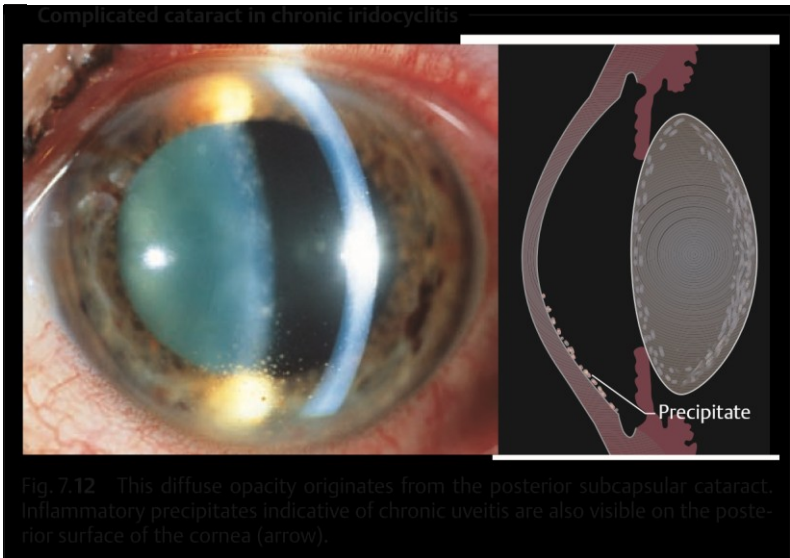
#### Complicated Cataracts

This form of cataract can occur as a complication of any protracted intraocular inflammation, especially heterochromia, chronic iridocyclitis, retinal vasculitis, and retinitis pigmentosa. The result is a pumice-like posterior subcapsular cataract that progresses axially toward the nucleus. This form of cataract produces extreme light scattering (Fig. 7.12).

---

### Cataract after Intraocular Surgery

Cataracts usually develop earlier in the operated eye as compared to the opposite, unoperated eye after intraocular surgery. This applies especially to



filtering operations. A secondary cataract will generally occur following vitrectomy and silicone oil tamponade.

### Traumatic Cataract

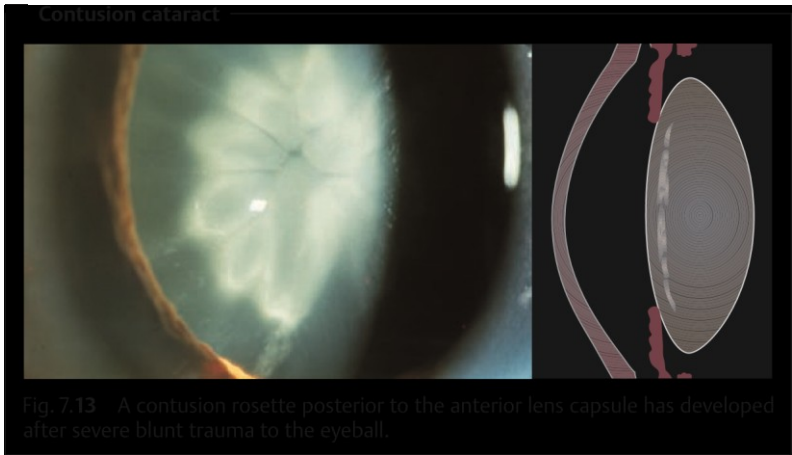
The incidence of these lens opacities is higher in men than in women due to occupational and sports injuries. The following types of traumatic cataracts are differentiated.

#### Frequent traumatic cataract:

**Contusion cataract.** Contusion of the eyeball will produce a rosette-shaped subcapsular opacity on the anterior surface of the lens. It will normally remain unchanged but will migrate into the deeper cortex over time due to the apposition of new fibers (Fig. 7.13).

#### Rarer traumatic cataracts:

**Infrared radiation cataract** (glassblower's cataract): This type of cataract occurs after decades of prolonged exposure to the infrared radiation of fire without eye protection. Characteristic findings include splitting of the anterior lens capsule, whose edges will be observed to curl up and float in the anterior chamber. Occupational safety regulations have drastically reduced the incidence of this type of cataract.

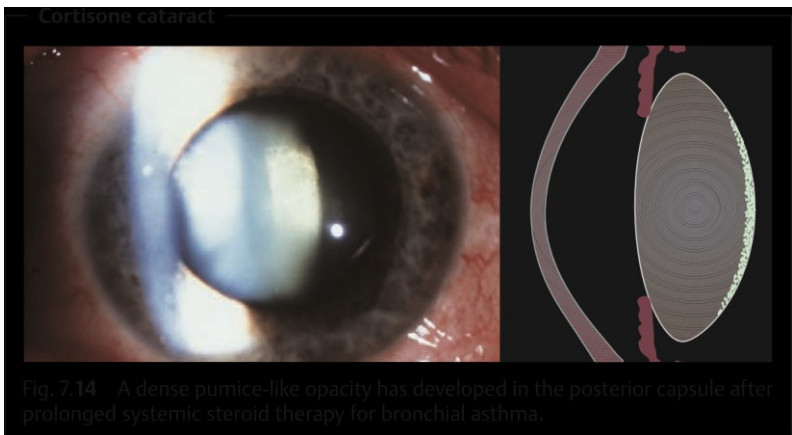


**Electrical injury.** This dense subcapsular cataract can be caused by lightning or high-voltage electrical shock.

**Cataract from ionizing radiation.** See Chapter 18.

### Toxic Cataract

**Steroid cataract.** Prolonged topical or systemic therapy with corticosteroids can result in a posterior subcapsular opacity. The exact dose–response relationship is not known (Fig. 7.14).



**Other toxic cataracts can result from** chlorpromazine, mitotic agents (especially cholinesterase inhibitors), and busulfan (Myleran) used in the treatment of chronic myelocytic leukemia.

## Congenital Cataract

There are many congenital cataracts. They are either hereditary or acquired through the placenta.

### Hereditary Congenital Cataracts

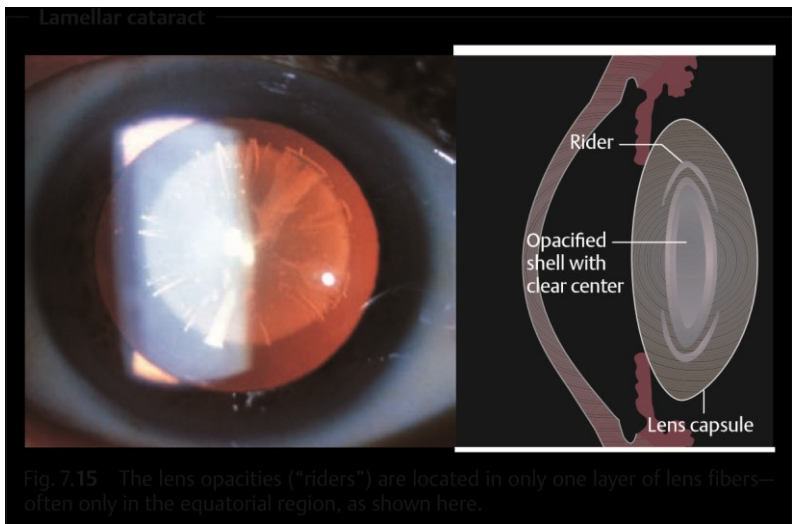
Familial forms of congenital cataracts may be autosomal-dominant, autosomal-recessive, sporadic, or X-linked. They are easily diagnosed on the basis of their characteristic symmetric morphology.

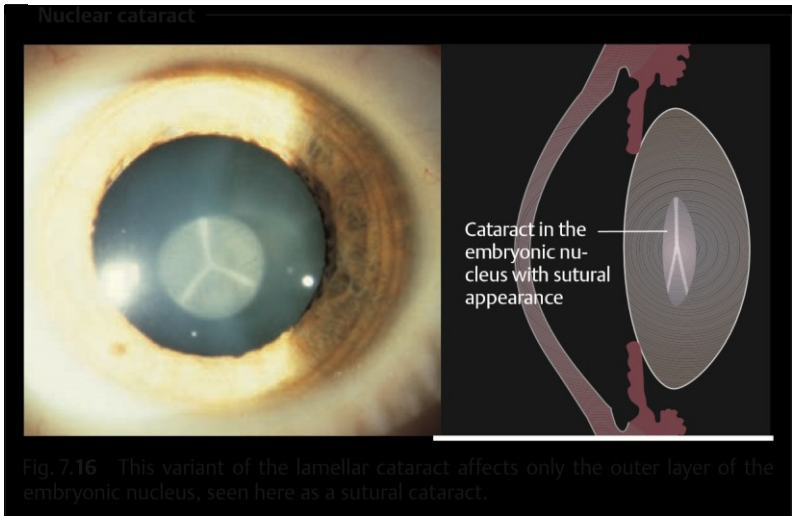
#### Forms of hereditary congenital cataract:

**Lamellar or zonular cataract.** Opacities are located in one layer of lens fibers, often as “riders” only in the equatorial region (Fig. 7.15).

**Nuclear cataract.** This is a variant of the lamellar cataract in which initially only the outer layer of the embryonic nucleus is affected (Fig. 7.16).

**Coronary cataract.** This is characterized by fine radial opacities in the equatorial region.





**Cerulean cataract.** This is characterized by fine round or club-shaped blue peripheral lens opacities.

■ Most familial lens opacities do not impair vision and are not progressive.

This also applies to rare lens opacities involving the capsule such as anterior and posterior polar cataracts, anterior pyramidal cataract, and Mittendorf's dot (remnant of the embryonic hyaloid artery on the posterior capsule of the lens; see Chapter 11).

#### Cataract from Transplacental Infection in the First Trimester of Pregnancy

A statistical study by Pau (1986) cites the following incidences of congenital cataract with respect to systemic disease contracted by the mother during the first trimester of pregnancy:

Rubella 40–60%.

Mumps 10–22%.

Hepatitis 16%.

Toxoplasmosis 5%.

Most of these cases involved *total cataracts* due to virus infection contracted by the mother during early pregnancy. This infection occurred during the fifth to eighth week of pregnancy, the phase in which the lens develops. Because the protective lens capsule has not yet been formed at this time, viruses can invade and opacify the lens tissue.



The most frequent cause of cataract is a rubella infection contracted by the mother, which also produces other developmental anomalies (Gregg syndrome involving lens opacity, an open ductus arteriosus, and sensorineural hearing loss). The cataract is bilateral and total and can be diagnosed by the presence of leukocoria (white pupil) and chorioretinal scarring secondary to choroiditis.

## Treatment of Cataracts

### Medical Treatment

In spite of theoretical approaches in animal research, the effectiveness of conservative cataract treatment in humans has not been demonstrated.

At present, no conservative methods are available to prevent, delay, or reverse the development of a cataract. Galactosemic cataracts (see p. 183) are the only exception to this rule.

### Surgical Treatment

Cataract surgery is the most frequently performed procedure in ophthalmology.

#### *When Is Surgery Indicated?*

Earlier surgical techniques were dependent upon the maturity of the cataract. This is no longer the case in modern cataract surgery.

**Optical indications.** Restoration of visual acuity is by far the most frequent indication for cataract surgery.

In the presence of **bilateral cataracts**, the eye with the worse visual acuity should undergo surgery when the patient feels visually handicapped. However, this threshold will vary depending on the patient's occupational requirements.

In the presence of a **unilateral cataract**, the patient is often inclined to postpone surgery as long as vision in the healthy eye is sufficient.

#### **Medical indications.**

In the presence of a **mature cataract**, it is important to advise the patient to undergo **surgery as soon as possible to prevent a phacolytic glaucoma.**

In the case of retinal disease (e.g., diabetic retinopathy) a cataract extraction may be necessary to clear the optical axis for retinal diagnosis and laser treatment.

#### *Will the Operation Be Successful?*

The prospect of a successful outcome is important for the patient. Most patients define a successful outcome in terms of a significant improvement in vision. Therefore, it is important that the patient undergoes a thorough pre-

operative eye examination to exclude any ocular disorders, aside from the cataract, that may worsen visual acuity and compromise the success of the cataract operation. Such disorders include uncontrolled glaucoma, uveitis, macular degeneration, retinal detachment, atrophy of the optic nerve, and amblyopia.

A detailed history of the patient's other ocular disorders and vision prior to development of the cataract should be obtained before surgery.

Several methods are helpful for assessing the **prognosis with respect to expected visual acuity** (retinal resolution) following cataract surgery. These include:

*Laser interference visual acuity testing* (see p. 443).

*Evaluation of the choroid figure* (in severe opacifications such as a mature cataract).

### **Reliability of Cataract Surgery**

Cataract surgery is now performed as a microsurgical technique under an operating microscope. Modern standardized techniques such as extracapsular cataract extraction (ECCE), phacoemulsification, and microincision cataract surgery (MICS), microsurgical instruments, atraumatic suture material (30-  $\mu\text{m}$  thin nylon suture thread), and specially trained surgeons performing many cataract operations (high-volume surgeons) have made it possible to successfully perform cataract surgery *without serious complications in 99% of patients*. The procedure lasts about 30 minutes and, like the postoperative phase, is painless.

The risk of losing vision or the entire eye during a cataract extraction, with hemorrhage during surgery or endophthalmitis after surgery, is about 0.05%.

It is mandatory to discuss the risks of the cataract surgery with the patient before the operation.

### **In-Patient or Outpatient Surgery?**

Usually cataract surgery is carried out on an outpatient basis. The patient can be *hospitalized for 3 days*, depending on the adequacy of postoperative care at home. Older patients who live alone may be unable to care for themselves adequately and maintain the regimen of prescribed medications for the operated eye in the immediate postoperative phase. The operation *can be performed as an outpatient procedure* if the ophthalmologist's practice is able to ensure adequate care.

### **Possible Types of Anesthesia**

Cataract extraction can be performed under *local anesthesia* or *general anesthesia*. Today, most operations are performed under local anesthesia. Aside from the patient's wishes, there are medical reasons for preferring one form of anesthesia over another.

**General anesthesia.** This is recommended for patients who are extremely apprehensive and nervous, deaf, or mentally retarded; it is also indicated for patients with Parkinson disease or rheumatism, who are unable to lie still without pain.

**Localanesthesia** (retrobulbar, peribulbar, or topical anesthesia). This is recommended for patients with increased anesthesia risks, and is the preferred approach in outpatient surgery.

#### **Preoperative Consultation on Options for Refractive Correction** (Table 7.4)

**Intraocular lens.** In almost all cataract extractions, an intraocular lens (IOL) is implanted, preferably in the place of the natural lens (*posterior chamber lens, PC-IOL*). If for intraoperative reasons PC-IOL placement is not possible, an IOL is implanted in the *anterior chamber (AC-IOL)*. An eye with an artificial lens is referred to as a *pseudophakia*. The different kinds of IOLs are discussed in the section on IOL technology.

**Biometry.** The refractive power of the lens required is determined preoperatively by biometry to reach the targeted refractive result. In a simplified fashion, IOL refractive power is determined by the refractive power of the cornea, IOL refraction constants, and the axial length, determined by ultrasonic measurement. More recent devices (e.g., the Zeiss IOL-Master) carry out noncontact biometry calculations with numerous additional parameters.

**Postoperative refractive status.** The usual recommendation is to target emmetropia or mild myopia ( $-0.25$  to  $-0.5$  D). The patient will then only need glasses for reading. Postoperative hyperopia (need for glasses at far and near distances) is not satisfactory for the patient. If the patient's fellow eye does not need cataract extraction within a short period of time, the refractive difference between the two eyes should be not more than 2 to 2.5 D, to avoid anisometric problems in binocular vision.

#### **Intraocular Lens (IOL)** (Fig. 7.17)

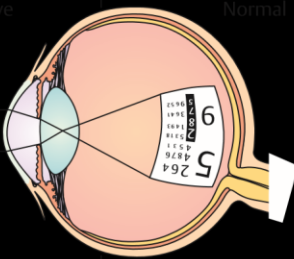
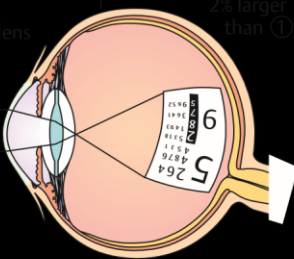
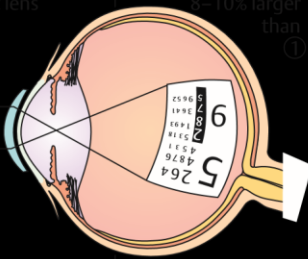
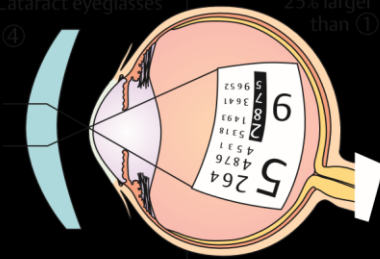
**IOL.** Every IOL consists of a central optical part (refractive element) and two haptics, to stabilize the IOL in the capsular bag, ciliary sulcus, or chamber angle. A distinction is made between:

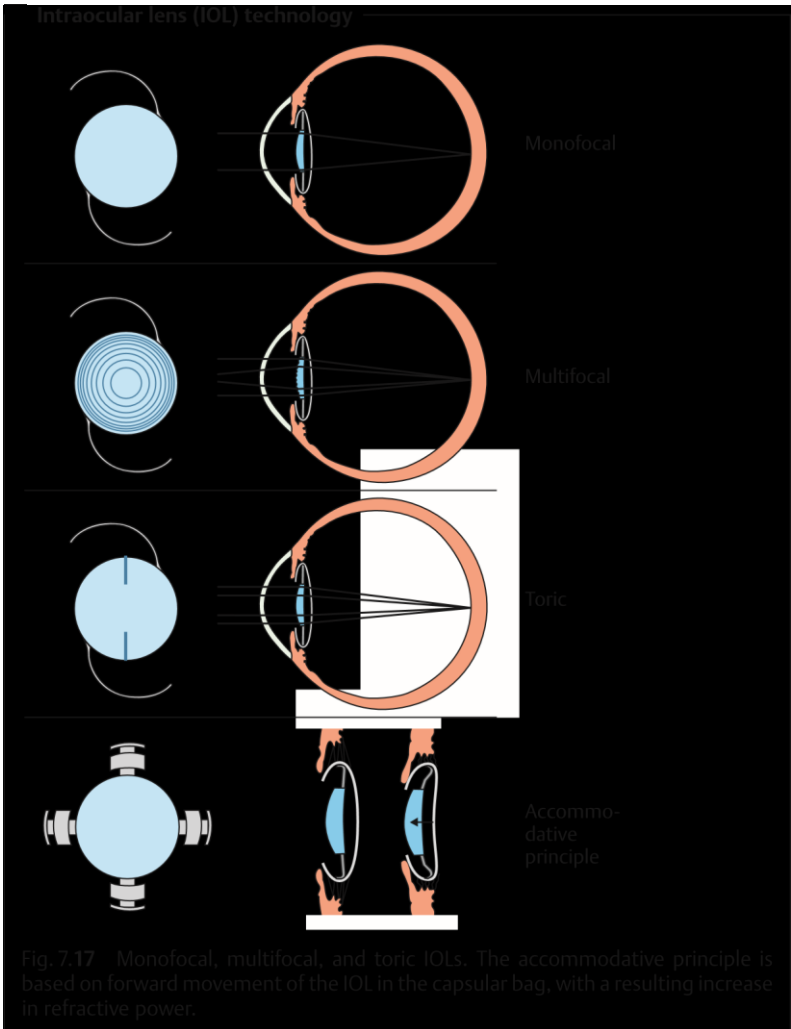
**Monofocal IOLs**, with only one specific focus (far or near).

**Multifocal IOLs**, with a focus for far and near objects. Multifocal IOLs do not yet match the optical quality standards of monofocal IOLs and may create problems due to reduced contrast vision, glare, and halos at night. Patient selection is crucial, and about 5% of multifocal IOLs need to be explanted due to patient dissatisfaction.

**Toric IOLs** correct not only spherical ametropia but also up to 3 D of astigmatism. The correct orientation of the IOL (orientation marks) is crucial.

Tab. 7.4 Comparison of a normal eye (1) and correction of cataract with a posterior chamber intraocular lens (2), contact lens (3), and cataract eyeglasses (4)

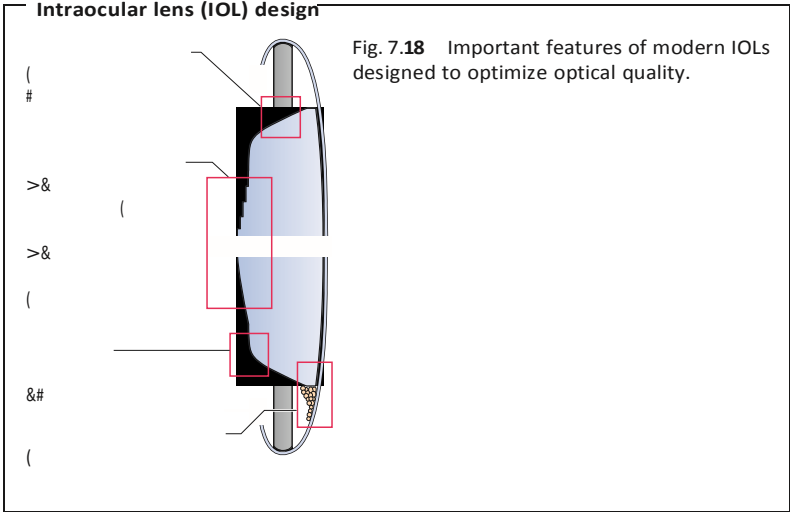
Correction	Monocular image size	Binocular vision: combination	advantages/ disadvantages
Normal eye ①	Normal 	① can be combined with ② and ③  Difference in image size is small enough for the brain to fuse the images	Visual field: full  Normal vision
Posterior chamber lens ②	2% larger than ① 	② can be combined with ①, ② and ③	Visual field: full IOL: no care necessary Vision (even without glasses): good vision, good orientation
Contact lens ③	8–10% larger than ① 	③ can be combined with ①, ②, and ③	Visual field: full Older patients often find it difficult to look after and manage lenses Vision: good with contact lenses, poor orientation without contact lenses Injury due to wearing of contact lenses possible Contact lenses not possible with dry eyes
Cataract eyeglasses ④	25% larger than ① 	④ can only be combined with ④	Visual Field: Limited (peripheral scotoma) Cataract eyeglasses: Simple to use, heavy, unsatisfactory cosmetic appearance Vision: good with eyeglasses, poor orientation without eyeglasses



**Accommodative IOLs** are designed to move forward and backward in the eye to allow accommodation. However, with less than 0.75 D of accommodative power, this approach does not currently meet expectations.

**IOL design** (Fig. 7.18). The geometrical configuration of IOLs has been subject to constant development. The sharp posterior edge of the optical part serves as a barrier

Lang, *Ophthalmology: A Pocket Textbook Atlas*, 2nd Ed. (ISBN 978-1-58890-555-0), copyright © 2007 Thieme Medical Publishers. All rights reserved. Usage subject to terms and conditions of license.



to lens epithelial cells migrating from the equator of the capsule toward the center, preventing secondary cataract. The sloping side part and the rounded anterior edge of the optic minimize glare and internal light reflections. Additional enhancements of the optical quality include multifocal steps and an aberration-optimized anterior IOL surface.

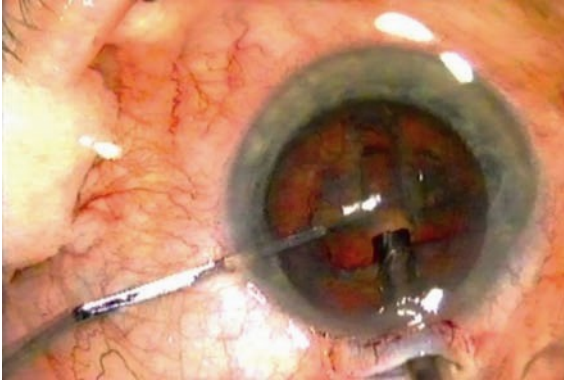
**IOL material.** Basically, IOLs can be divided into **nonflexible** and **flexible types**, as well as **one-piece IOLs** (in which the haptics and optic are made of a single material with no connecting points) and **three-piece IOLs** (in which the optic and haptics are made of different materials such as PMMA, polypropylene, and polyamide and connected to each other).

**Nonflexible IOLs.** These are mostly made of polymethylmethacrylate (PMMA). To implant a nonflexible IOL, the incision needs to be larger than the diameter of the IOL (5.5–6.5 mm). Modern nonflexible IOLs are one-piece IOLs.

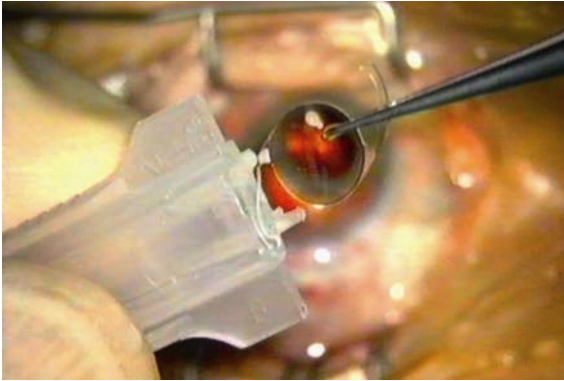
**Flexible IOLs** are folded with a forceps or an injector system and are therefore implantable through 2.0–3.0 mm incisions with the same optic size as nonflexible IOLs (Fig. 7.19). Flexible IOLs are made of silicone, acrylic, hydrogel, or Collamer.

The development and modification of modern IOLs is a constantly ongoing process.

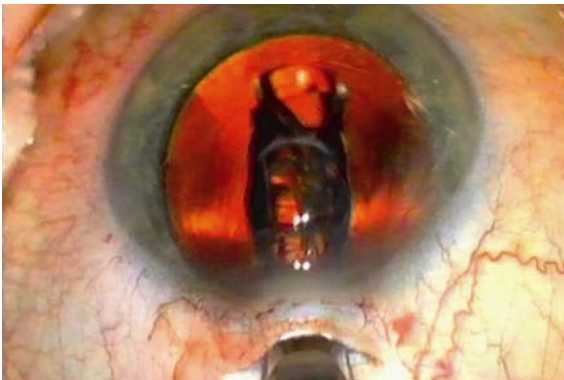
**Phacoemulsification and shooter implantation of a flexible intraocular lens (IOL)**



**Fig. 7.19 a** Removal of the lens nucleus with the phacoemulsification tip.



**b** A one-piece acrylic IOL is placed in the shooter.



**c** Injection of the folded acrylic IOL, just being delivered through the shooter, through a 2.5-mm incision.

### Alternative Methods of Correcting Refractive Errors

**Cataract eyeglasses.** The development of the intraocular lens has largely replaced the correction of postoperative aphakia with cataract lenses. Long the standard, this method is *now only necessary in exceptional cases*. Cataract eyeglasses cannot be used to correct *unilateral aphakia*, because the difference in the size of the retinal images is too great (aniseikonia). Therefore, cataract eyeglasses are only suitable for correcting *bilateral aphakia*. Cataract eyeglasses have the disadvantage of limiting the field of vision (*peripheral and ring scotoma*).

**Contact lenses** (soft, rigid, and oxygen-permeable). These lenses provide a near-normal field of vision and are *suitable for postoperative correction of unilateral cataracts*, as the difference in image size is negligible. However, many older patients have difficulty in learning how to cope with contact lenses.

### Surgical Techniques

The operation is performed on only one eye at a time. The procedure on the fellow eye is performed after about a week once the first eye has stabilized.

### Historical milestones.

**Couching** (reclination). Up until the 19th century, a pointed instrument was used to displace the lens into the vitreous body out of the visual axis.

**1746.** J. Daviel carried out the **first extracapsular cataract extraction** by removing the contents of the lens through an inferior approach.

**1866.** A. von Graefe carried out the first removal of a cataract through a **superior limbal incision with capsulotomy**.

**Intracapsular cataract extraction.** *Until the mid-1980s, this was the method of choice.* Today, intracapsular cataract extraction is used only with subluxation or dislocation of the lens. The entire lens is frozen in its capsule with a cryoprobe and removed from the eye through a large superior corneal incision

### Extracapsular cataract extraction.

*Procedure* (Fig. 7.20). The anterior capsule is opened (capsulorrhexis). Then only the cortex and nucleus of the lens are removed (extracapsular extraction); the posterior capsule and zonule suspension remain intact. This provides a stable base for implantation of the posterior chamber intraocular lens.

Extracapsular cataract extraction with implantation of a posterior chamber intraocular lens is now the method of choice.

Today, *phacoemulsification* (emulsifying and aspirating the nucleus of the lens with a high-frequency ultrasonic needle) is the preferred technique for removing the nucleus. Where the nucleus is very hard, the entire nucleus is expressed or aspirated. Then the softer portions of the cortex are removed by suction with an aspirator/irrigator attachment in an aspiration/irrigation maneuver. The posterior capsule is then polished, and an intraocular lens



Extracapsular cataract extraction with implantation of a nonflexible one-piece IOL into the capsular bag

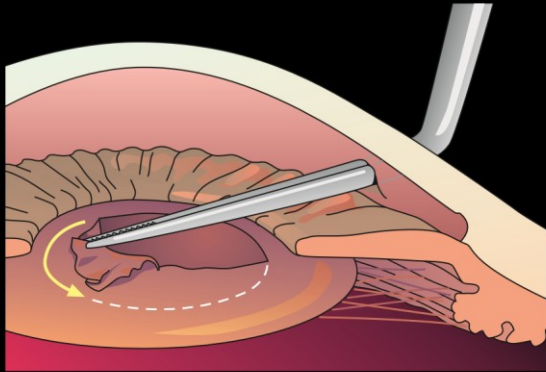
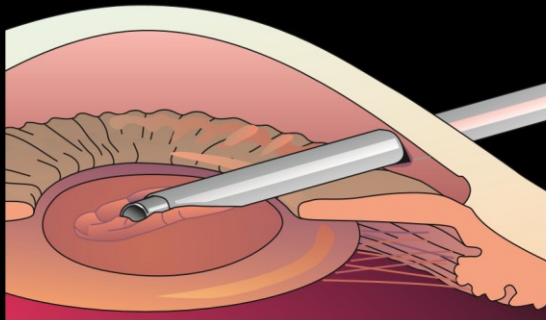
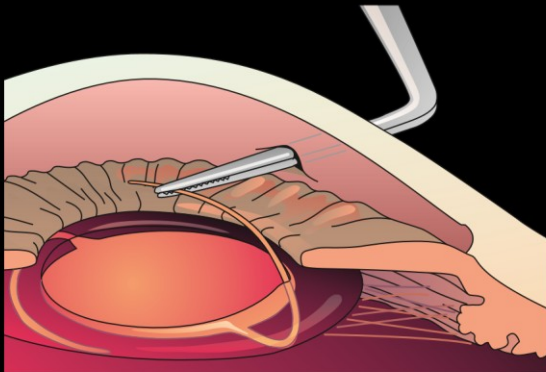


Fig. 7.20 a The anterior capsule of the lens is opened using a continuous curvilinear capsulorhexis.

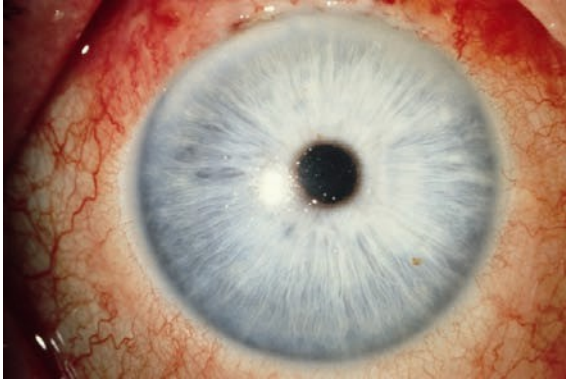


b The nucleus is destroyed by ultrasound (phacoemulsification), and the fragments of the nucleus and cortex are aspirated.



c A posterior chamber intraocular lens is implanted into the capsular bag.

**Patient with a posterior chamber intraocular lens (IOL)**



**Fig. 7.21 a** In a normal pupil in a patient not receiving medication, the IOL is not noticeable.



**b** The same patient after dilation of the pupil with a mydriatic. The IOL is discernible with retroillumination. An attempt is always made to make the diameter of the rhexis in the anterior capsule 0.5–1 mm smaller than the diameter of the IOL.

(IOL) is implanted in the empty capsular bag (Fig. 7.21). Phacoemulsification and IOL implantation require an incision only 3–6 mm in length. Where a tunnel technique is used to make this incision, no suture will be necessary as the wound will close itself.

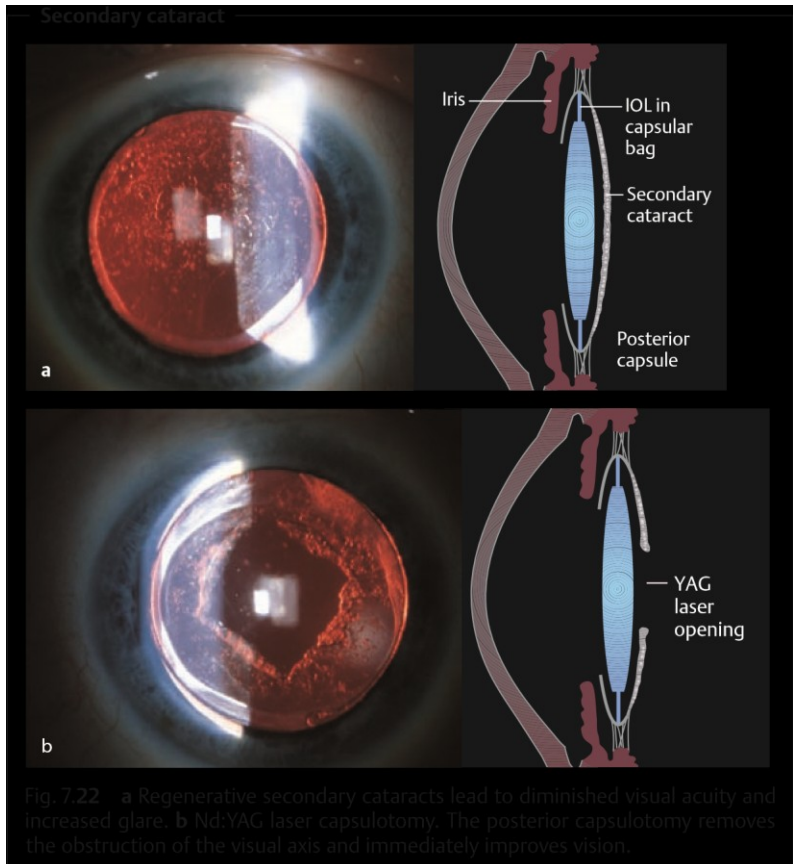
**Advantages over intracapsular cataract extraction.** Extracapsular cataract extraction usually does not achieve the same broad exposure of the retina that intracapsular cataract extraction does, particularly when a secondary cataract is present. However, the extracapsular cataract extraction maintains the integrity of the anterior and posterior chambers of the eye, and the vitreous body cannot prolapse anteriorly as it does after intracapsular cataract extraction. At 0.1–0.2%, the incidence of retinal detachment after extracapsular cataract extraction is about ten times less than after intracapsular cataract extraction, which has an incidence of 2–3%.

### Secondary Cataract

**Epidemiology.** Approximately 30% of cataract patients develop a secondary cataract after extracapsular cataract extraction.

**Etiology.** Extracapsular cataract extraction removes only the anterior central portion of the capsule and leaves epithelial cells of the lens intact along with remnants of the capsule. These epithelial cells are capable of reproducing and can produce a secondary cataract of fibrous or regenerative tissue in the posterior capsule that diminishes visual acuity (Fig. 7.22a).

**Treatment.** A neodymium:yttrium–aluminum–garnet (Nd:YAG) laser can incise the posterior capsule in the visual axis without requiring invasive eye surgery. This immediately improves vision (Fig. 7.22b).



### Special Considerations in Cataract Surgery in Children

Observe changes in the child's behavior. Children with congenital, traumatic, or metabolic cataract will not necessarily communicate their visual impairment verbally. However, it can be diagnosed from these **symptoms**:

Leukocoria.

Oculodigital phenomenon. The child presses his or her finger against the eye or eyes, because this can produce light patterns the child finds interesting.

Strabismus. The first sign of visual impairment (Fig. 7.23).

The child cries when the normal eye is covered.

The child has difficulty walking or grasping.

Erratic eye movement is present.

Nystagmus.

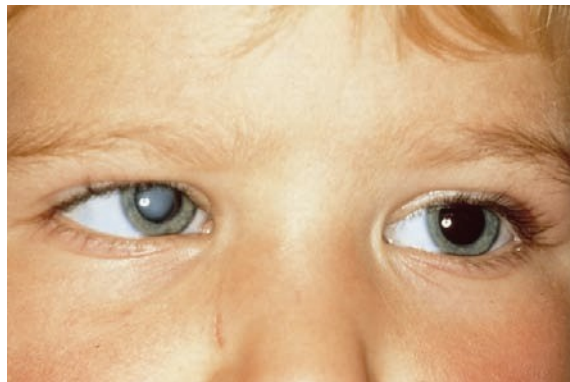**Operate as early as possible.** Retinal fixation and cortical visual responses develop within the first 6 months of life. This means that children who undergo surgery after the age of 1 year have *significantly poorer chances* of developing normal vision.

Children with congenital cataract should undergo surgery as early as possible to avoid amblyopia.

The prognosis for successful surgery is less favorable for *unilateral cataracts* than for bilateral cataracts. This is because the amblyopia of the cataract eye puts it at an irreversible disadvantage in comparison with the fellow eye as the child learns how to see.

**Plan for the future when performing surgery.** After opening the extremely elastic anterior lens capsule, one can aspirate the soft infantile cortex and nucleus. *Secondary cataracts are frequent complications in infants.* The procedure should therefore

#### Congenital cataract



**Fig. 7.23** An 18-month-old child with a congenital cataract (leukocoria) and esotropia in the right eye.

include a *posterior capsulotomy with anterior vitrectomy* to ensure an unobstructed visual axis. The operation *preserves the equatorial portions of the capsule* to permit subsequent implantation of a posterior chamber intraocular lens in later years.

**Refraction changes constantly.** The refractive power of the eye changes dramatically within a short period of time as the eye grows. The refraction in the eye of a newborn is 30–35 diopters and drops to 15–25 diopters within the first year of life (myopic shift).

### **Refractive Compensation**

Two main points need to be noted for optical correction of aphakia in a child—age and whether the cataracts are unilateral or bilateral. Possible methods of correction include:

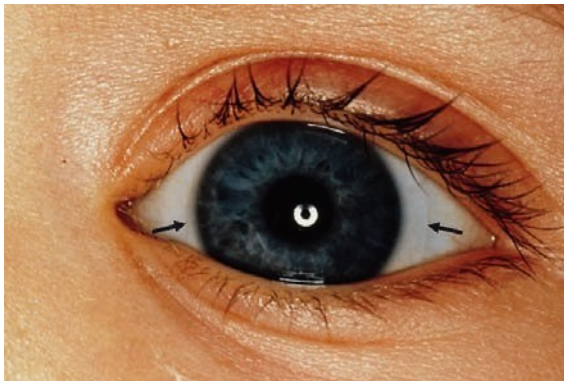
**Glasses** can be fitted in older children with bilateral, but not unilateral aphakia. It should be noted that thick cataract glasses may be inappropriate due to their weight, for cosmetic reasons, due to prismatic distortion and ring scotoma.

**Contact lenses** (Fig. 7.24) are a good option for unilateral and bilateral aphakia. The use of soft contact lenses in infants is difficult and requires intensive cooperation from parents. Usually they are well tolerated up to the age of 2 years.

**IOL implantation** is nowadays a routine procedure in children over the age of 2 or 3 years. The problem in newborns is the myopic shift in the growing eye. An IOL power is therefore calculated by biometry that results in a certain amount of hyperopia, which is then corrected with glasses. During the child's subsequent growth, the hyperopia ideally moves back toward emmetropia.

**Orthoptic postoperative therapy is required.** *Unilateral cataracts* in particular require orthoptic postoperative therapy in the operated eye to close the gap in

### **Refractive compensation with a soft contact lens**



**Fig. 7.24** In a unilateral cataract, a contact lens provides refractive compensation (the arrows indicate the edge of the contact lens).

relation to the normal fellow eye. Regular evaluation of retinal fixation is indicated, as is amblyopia treatment (see patching, p. 489).

Refraction should be evaluated by retinoscopy (see Chapter 16) every 2 months during the first year of life and every 3–4 months during the second year, and contact lenses and eyeglasses should be changed accordingly.

## 7.5 Lens Dislocation

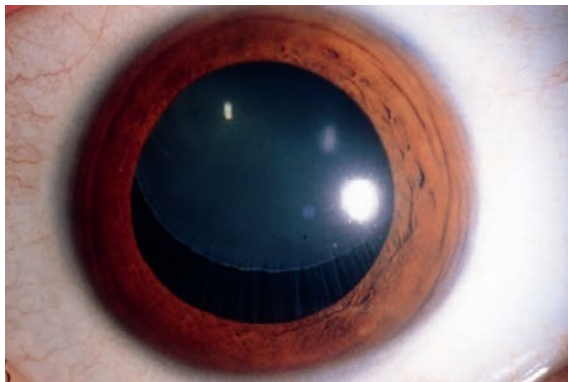
### Definition:

**Subluxation (partial dislocation).** The suspension of the lens (the zonule fibers) is slackened, and the lens is only partially within the hyaloid fossa (Fig. 7.25).

**Luxation (complete dislocation).** The lens is torn completely free and has migrated into the vitreous body or, less frequently, into the anterior chamber.

**Etiology.** There are several causes of lens dislocation (Table 7.5). Most frequently, it is due to **trauma** (see p. 516). Later in life, **pseudoexfoliation** may also lead to subluxation or luxation of the lens. **Hereditary causes** and **metabolic disease** produce lens displacement *early*, but on the whole are *rare*. *Additional rare causes* include **hyperlysinemia** (characterized by retarded mental development and seizures) and **sulfite oxidase deficiency** (which leads to mental retardation and excretion of cysteine in the urine).

### Subluxation of the lens in Marfan syndrome



**Fig. 7.25** The lens is displaced superiorly and medially. As the zonule fibers are intact, a certain amount of accommodation is still possible.

## 7.5 Lens Dislocation

Tab. 7.5 Etiology of lens displacement

Causes	Lens displacement
<b>Hereditary causes (rare)</b>	
Ectopia lentis: isolated and monosymptomatic	Complete or partial displacement of the lens (for example, into the anterior chamber)
Marfan syndrome: characterized by arachnodactyly, long limbs, and laxness of joints	Lens is abnormally round; lens displacement is usually superior and temporal; zonule fibers are elongated but frequently intact
Weill–Marchesani syndrome: symptoms include short stature and brachydactyly	Lens is abnormally round and often too small; lens is usually eccentric and displaced inferiorly
Homocystinuria (metabolic disease): characterized by oligophrenia, osteoporosis, and skeletal deformities	Lens displacement is usually medial and inferior; torn zonule fibers appear as a “permanent wave” on the lens
<b>Acquired causes</b>	
Trauma (probably the most frequent cause)	Zonule defects due to deformation can cause subluxation or luxation of the lens
Pseudoexfoliation (in advanced age)	Zonule weakness due to loosening of the insertion of the fibers on the lens can cause lens displacement
Ciliary body tumor (rare)	Lens is displaced by tumor
Large eyes with severe myopia and buphthalmos (rare)	Zonule defects due to excessive longitudinal growth can cause lens displacement

The most frequent atraumatic causes of lens dislocation are Marfan syndrome, homocystinuria, and Weill–Marchesani syndrome.

**Symptoms.** Slight displacement may be of no functional significance to the patient. More pronounced displacement produces severe optical distortion with loss of visual acuity.

**Diagnostic considerations.** The cardinal symptoms include tremulous motion of the iris and lens when the eye moves (iridodonesis and phacodonesis). These symptoms are detectable using a slit lamp examination.

**Treatment.** Optical considerations (see Symptoms) and the risk of secondary angle closure glaucoma due to protrusion of the iris and dislocation of the lens into the anterior chamber are indications for removal of the lens.

Lang, Ophthalmology: A Pocket Textbook Atlas, 2nd Ed. (ISBN 978-1-58890-555-0), copyright © 2007 Thieme Medical Publishers. All rights reserved. Usage subject to terms and conditions of license.