

Refrakční chirurgie

PRK, LASIK, LASEK, femto LASIK, SMILE (small incision lenticul extraction), LRI, phakic IOL, keraring,

Ferrara

prstenec

LASEK Eye Surgery: How It Works

Reviewed by [Brian S. Boxer Wachler, MD](#)

Like This Page? Please Share!

On This Page: [LASEK vs. LASIK](#) [LASEK vs. PRK](#) [What to expect during and after LASEK surgery](#) [Risks and complications](#)

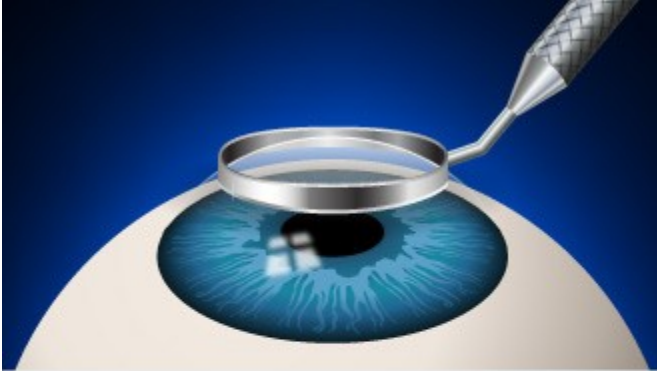LASEK eye surgery is a variation of [PRK](#) to correct [myopia](#) (nearsightedness), [hyperopia](#) (farsightedness) and [astigmatism](#). LASEK combines certain methods from both [LASIK](#) and PRK.

LASIK remains the most popular laser eye surgery, but for people who are not suitable [LASIK candidates](#), PRK or LASEK may be better options and produce comparable outcomes to LASIK.

Like other types of [laser refractive surgery](#), LASEK works by reshaping the [cornea](#) using an excimer laser, allowing light entering the eye to be properly focused onto the [retina](#) for clearer vision without eyeglasses or contact lenses.

The fundamental difference in how LASIK, PRK and LASEK are performed concerns how the eye is prepared for the laser treatment:

LASEK EYE SURGERY



- 1 A circular bladed tool called a trephine is centered on the eye and pressed gently into the corneal epithelium.

[Click to view next slide](#)

- During **LASIK**, a thin circular "flap" is created on the eye's surface using a microkeratome or a femtosecond laser surgical tool. The surgeon then folds back the hinged flap to access the stroma and reshape the corneal tissue using an excimer laser.

The flap is then returned to its original position and serves as a natural bandage, keeping the eye comfortable as it heals. The flap adheres securely without stitches, and healing occurs relatively quickly.

- During **PRK**, instead of creating a corneal flap as in LASIK, the surgeon completely removes the extremely thin outer layer of the cornea (epithelium, which is like a clear "skin layer" covering the cornea), using an alcohol solution, a "buffing" device or a blunt surgical instrument. The underlying corneal stroma is then reshaped with an excimer laser. A new epithelial layer grows back within five days.
- The **LASEK** procedure involves a little of both LASIK and PRK. Like in PRK, the corneal epithelium is separated from the underlying stromal layer. But instead of completely removing and discarding this tissue, as in PRK, the LASEK surgeon pushes an ultra-thin "flap" of epithelium off to one side of the cornea, where it remains attached to the eye (like the thicker flap of corneal tissue created during LASIK surgery).

After the laser treatment is finished, the epithelial tissue is repositioned on the surface of the eye to cover the lasered stroma, and a bandage contact lens is placed on the eye to keep the epithelium in place as it heals.

BEST CANDIDATES

myopia, hyperopia and/or astigmatism, ineligible for LASIK

- **Procedure time:** about 10 minutes per eye
- **Typical results:** 20/20 vision without glasses or contact lenses
- **Recovery time:** several days to several weeks for vision to stabilize
- **Cost:** about \$1,500 to \$2,500 per eye

Another laser eye surgery, called **epi-LASIK** or e-LASIK, is very similar to LASEK. But instead of using alcohol to loosen the epithelium like in LASEK, in epi-LASEK the surgeon typically uses a blunt, plastic blade to separate the epithelial sheet from the eye. This avoids the possibility of a reaction from the alcohol, which can kill epithelial cells.

LASIK, PRK and LASEK all have high success rates and similar vision outcomes. One is not necessarily better than the other in the long term, but vision tends to be more hazy in the first week with LASEK than with LASIK and PRK.

After a thorough [eye exam](#), your [eye surgeon](#) will advise you on the best type of laser eye surgery for your individual needs and requirements.

LASEK vs. LASIK

The hinged flap made in LASEK surgery is created in the epithelial layer of the [eye](#) and is much thinner than the corneal flap created in LASIK (which contains both epithelial and deeper stromal tissues).

This is of particular importance if you have a naturally thin cornea that makes you a less-than-ideal LASIK candidate.

In LASEK, an ultra-thin flap is created on the eye's surface, unlike the thicker flap in LASIK.

The LASEK technique avoids any corneal flap-related [LASIK complications](#) and lessens the likelihood of removing too much cornea with the excimer laser and compromising the structural integrity of the eye. By avoiding a deeper flap, there also is slightly less risk of developing [dry eyes](#) after LASEK eye surgery.

LASEK also may be a better option if you have a high degree of myopia (which requires more tissue removal from the central cornea to correct the refractive error), or if your occupation or hobbies puts you at high risk of an eye injury and dislodging the corneal flap created in LASIK surgery.

It's important to note, however, that LASEK typically involves more discomfort and a longer recovery time compared with LASIK surgery.

LASEK vs. PRK

LASEK is very similar to PRK. Both involve lifting the extremely thin epithelium to access the deeper corneal tissues, instead of creating a thicker corneal flap as in LASIK surgery.

The key difference between LASEK and PRK is that LASEK preserves and then replaces the epithelial layer whereas in PRK the epithelium is completely removed and discarded and a new epithelial layer grows back over the next few days following surgery.

Initially, many surgeons thought that by preserving the epithelium LASEK would have a faster recovery time than PRK. In practice, however, many surgeons have found that the

replaced epithelial layer in LASEK often takes longer to heal compared with the growth of a new epithelial layer after PRK.

As such, PRK remains the most popular of the "surface ablation" techniques (PRK, LASEK and epi-LASIK).

LASEK Eye Surgery: What To Expect

Before. Your eye surgeon will perform a thorough eye exam and general health check to see if you are a suitable candidate for LASEK eye surgery. Many eye surgeons will recommend LASEK only if you are not suited to LASIK eye surgery.

If you wear contact lenses, your doctor typically will instruct you to stop wearing them for a period of time before taking measurements for laser eye surgery as contacts can change the natural shape of your cornea.

As you won't be able to drive yourself home from the surgery, you'll need to arrange someone to drive you. You'll also need to organize time off work — around a week in typical cases — as your eyes heal and your vision begins to improve.

During. Numbing anesthetic drops are first applied to your eye. Then your surgeon makes a circular cut in the corneal

epithelium using a fine blade (trephine). The trephine leaves a small arc-shaped area of the circle uncut, so the epithelial "flap" that's created remains attached to the eye. A diluted alcohol solution is placed over the eye for approximately 30 seconds, which loosens the edges of the epithelium and enables the surgeon to gently push the loosened flap of epithelium to the side.

The excimer laser is then positioned over the eye to reshape the corneal stroma and correct your vision. After the laser treatment is completed, the epithelial flap is repositioned on the eye.

A special contact lens that acts as a protective bandage is then placed over your eye.

LASEK eye surgery is performed on a walk-in, walk-out basis, and should take about 15 minutes per eye. You are awake for the procedure and shouldn't feel any pain, but your surgeon may give you a mild sedative to help you relax.

Vision recovery after LASEK may be slower than for other procedures, but there is less risk of complications such as dry eye.

After. You can return home after a brief period of rest following LASEK surgery. Most people report mild to moderate discomfort in the first few days after LASEK.

You will need to keep the "bandage" contact lens on your eye for approximately four days while the surface epithelial cells heal and regenerate. Your doctor also will prescribe topical steroids and antibiotics for at least three weeks to aid healing and minimize the risk of infection.

Generally, visual recovery after LASEK (and epi-LASIK) is significantly slower than after LASIK and often slower than the recovery after PRK. Initial visual recovery can take up to a week with LASEK (as opposed to 24 hours in typical LASIK cases) and final outcomes can be seen anywhere from a few weeks to several months.

LASEK and PRK outcomes are similar to [LASIK results](#). Most people achieve [20/20 vision](#) after laser eye surgery, and nearly all achieve 20/40 visual acuity or better. Depending on your degree of refractive error, you may still need to wear eyeglasses or contact lenses, but the prescription will be significantly lower.

Like LASIK and PRK, LASEK eye surgery is not necessarily a solution for [presbyopia](#), a naturally occurring age-related loss of

near vision. Your doctor will be able to advise whether you're a suitable candidate for [presbyopia surgery](#) instead.

LASEK Risks and Complications

LASEK and PRK complications are similar to LASIK complications. Side effects can include vision disturbances such as:

Your EyePinion

Of these professions, which one requires the best vision?

Chef Referee Baseball player Surgeon
 Cabdriver Airline pilot

[View Results](#)

- [Blurry vision](#), halos and glare
- Significant overcorrection, undercorrection or regression which may require further surgery or reliance on eyeglasses or contact lenses for some or all activities
- Dry eyes
- [Eye infection](#) and irritation

While LASEK avoids the corneal flap-related risks of LASIK, there are some complications exclusive to LASEK surgery.

In some cases, the thin epithelial flap created during LASEK is not strong enough to be replaced over the treated area and will be removed completely as it would have been in PRK. Typically, this does not pose a risk, but if you have a very high prescription for myopia you may have a greater likelihood of experiencing hazy vision.

The alcohol solution used during LASEK causes tissue damage to epithelial cells that slows the healing process immediately after surgery. Recovery after epi-LASIK typically is faster because no alcohol is used to create the epithelial sheet.

LASEK eye surgery offers a safe and effective alternative to LASIK but typically is performed only if you are not a good candidate for LASIK eye surgery, owing to the faster visual recovery and minimal discomfort associated with LASIK.

An experienced eye doctor will be able to advise you when LASEK is the best vision correction surgery for your individual needs. [AAV](#)

What is Femto-Lasik?

Femto-Lasik or Z-Lasik is the most efficient technology currently available within the field of [laser eye surgery](#). Lasik stands for 'laser-assisted in situ keratomileusis' – the method involved in this type of procedure. Femto represents the technology, in this case the most recent type of laser: the Femtosecond.

The Femtosecond laser method involves the cutting of a microscopically thin flap on the surface of the cornea, after which the Excimer laser is used to correct any existing refractive errors. With Femto-Lasik, we can easily and successfully treat eye diopetre prescriptions between -12 and +6.

Say a rapid farewell to your glasses, [make a no-strings attached appointment today](#).

<http://www.vimeo.com/36132179>

The Focus Eye Clinic uses the Wavelight EX500 Excimer laser and the Ziemer Z8 Femto laser. Both of these devices are considered state-of-the-art.

The combination of both of these devices guarantees predictable and reliable results and extreme precision using a quick, painless and safe technique.

Advantages of Femto-Lasik

1. Optimal safety :
 - Highly reduced risk of complications when cutting the corneal flap.
 - Reduced risk of infection and inflammation
 - Larger treatable surface for increased stability
 - Reduction in retreatment rates
2. Thinner flap:
 - The Femto-Lasik allows for such a thin, uniformly cut corneal flap that

complications are practically non-existent. With these thinner flaps, more corneal tissue is left behind, meaning not only an increase in long-term corneal stability, but also the opportunity to correct higher refractive errors.

3. Even flap thickness:

When using the Femto-Lasik, the surgeon knows beforehand which form, thickness, measurements and capacity each flap entails. This is an important issue when considering treatment for higher refractive errors. When using a scalpel, a surgeon can only know how the flap will look after the cut has been made.

4. Other benefits:

Eyeball measurements are of little importance for Femto-Lasik laser eye surgery.

You will heal in a shorter span of time

and your sight will improve much more quickly.

Visual results are excellent.

During the procedure, the Femto-Lasik laser exercises less pressure on the eye. This means the patient will experience very little discomfort.

Will Femto-Lasik work for me?

Nearly everyone with [nearsightedness](#) (myopia), [farsightedness](#) (hypermetropia) or [astigmatism](#) can be treated using the Femto-Lasik method.

- You are between 18 and 60 years old
- You are in good health
- Refractive errors between -12 and +6
- Refractive errors have not undergone any changes during the past year

People who suffer from very dry eyes or have thin corneas are often not considered for Femto-Lasik surgery. They would be better served using the alternative but excellent PRK method.

For age related vision problems, otherwise known as [presbyopia](#), Femto-Lasik is not the ideal solution. We would recommend [multifocal lens implants](#).

Treatment should be postponed during pregnancy or when breast feeding. We will not carry out Femto-Lasik procedures on patients with the following pathologies: viral eye infections, herpes, diabetes mellitus, keratoconus and any pathologies requiring cortisone therapy.

Still not sure? Come and have a chat. [Make your obligation-free appointment today.](#)

Femto-Lasik pricing

Focus Eye Clinic puts [transparent pricing](#) into practice. You pay the advertised price for Femto-Lasik treatment using the latest technology.

Treatment for one eye costs €1,750. Both eyes will cost €3,250. A no-strings pre-treatment consultation with one of our surgeons is completely free.

Femto-Lasik: practical information

The entire Femto-Lasik procedure as carried out at the Focus Eye Clinic – from arrival to discharge – takes approximately 2 hours.

Before the procedure

On the day of your Femto-Lasik procedure we will repeat all preoperative

measurements.. You will then be given a light sedative. Your eyes will be anaesthetised with a local anaesthetic. There is therefore no need for a full anaesthetic.

During the procedure

Nursing staff will help you onto the operating table situated within the Femto-Lasik treatment room.

They will thoroughly disinfect your anaesthetised eyes and cover them with a sterile dressing. Your eyelashes will be moved aside and your eyes once again anaesthetised using a local anaesthetic. An eyelid holder will be put into place, making it impossible for you to blink or close your eyes.

Cutting the corneal flap takes just 26 seconds using a device placed directly onto the eye. It is via this device that the Femto

Laser forms the flap. Don't worry: nothing you do can change the position of or adjust this device.

After the flap has been formed the surgeon uses the Wavelight-Excimer laser to treat the refractive error. For this, you will need to look into a fixation light for 1 second; after you have done this the laser will automatically follow the movements of your eye.

Finally, the flap is put back, thoroughly rinsed and pressed into place.

After the procedure

You will be taken to a rest and relaxation area where you will stay for approximately 30 minutes. On the day of the procedure itself you should not drive. Please bring someone with you! We do not recommend your using public transport systems. Postoperative medication consists of eye

drops. You will also receive protective glasses which you are required to wear for the following 24 hours.

Aftercare

You will come for a control visit one day, one week and two to three months after the procedure. These visits are included in the listed price.

What risks?

Femto-Lasik laser eye surgery is safer than daily contact lens use. Currently, the most applicable risk is that of Femto-Lasik retreatment. However, the chance of this occurring is less than 0.5%.

As in all types of surgery there is a limited risk of infection and inflammation. You will receive eye drops and protective glasses to reduce such risk.

Older techniques could sometimes lead to permanent dry eyes. The state-of-the-art Femto-Lasik method, together with sufficient preoperative care, has drastically reduced this risk. Any temporary decrease in tear production can be treated with lubricating eye drops and tear duct (lacrimal) plugs.

There is no risk of decreased night vision. In fact, the opposite is true; laser treatment increases contrast in low light conditions.

FAQ

What is an Excimer laser?

With the Excimer laser, thin layers of the cornea are evaporated by way of photo ablation.

This makes it possible to:

- change the corneal profile
- flatten the cornea in cases of nearsightedness
- make the cornea more rounded in cases of farsightedness
- even out the cornea in cases of astigmatism

The newest computer technology can calculate the correct corneal profile automatically, as well as the correct doses of photo ablation. The Wavelight EX500 Excimer laser uses “Perfect Pulse Technology” to guarantee both safety and precision. The 6-sigma tracking system follows all eye movement during the procedure.

Reliability and predictability are guaranteed by way of high resolution calibration for each procedure. Aspheric laser ablation means improved night vision.

How does the Femto-Lasik laser work?

The Ziemer Z8 Femto laser works using the principle of photo disruption: using infrared laser energy, the surgeon creates a pattern of tiny, overlapping spaces immediately under the surface of the cornea. The laser operates at extremely high speeds: impulses of 1 quadrillionth of a second, or 1 femtosecond.

These highly accurate laser impulses split the corneal tissue at a molecular level without creating heat or touching the surrounding tissue. As the laser moves up and down across the eye a complete corneal flap is formed. After the flap has been created the surgeon lifts it with a specially designed instrument. The Excimer laser is then used to shave away thin slices of the cornea and in doing so correct refractive errors. Finally, the surgeon sets the flap back into place.

What are the Femto-Lasik-options: A-Cat, T-Cat and Lasik-Extra?

A-Cat: Femto-Lasik with aberrometry

We now possess sophisticated diagnostic devices which can register extremely subtle refractive errors. These aberrations are so tiny that glasses or contact lenses cannot help. Treatment of specific aberrations (the A-Cat option) can offer more night vision contrast to those people with widened pupils. The surgeon will discuss this option with you should he consider it applicable.

T-Cat: Femto-Lasik with topography

A cornea is usually regular in form (spherical and toric). For some patients, such as those with keratoconus, asymmetrical or irregular astigmatism can only be seen when using topographical imaging. If the surgeon thinks you are a

candidate for topography, he will tell you about the T-Cat option.

Lasik-Extra: Avedro

When using Femto-Lasik therapy for hypermetropia and presbyopia, vision can start to decline within a few years. Until recently, this meant retreatment.

Thanks to the Avedro UV Crosslinking technique, retreatment is no longer necessary. With this technique, we treat the eye after the Lasik procedure with UV light to encourage the attachment of collagen fibres onto the cornea. This means that the new corneal form will be stable.

Refrakční chirurgie

◆Photorefractive Keratectomy

Photorefractive keratectomy (PRK) is one of the refractive procedures using excimer laser to ablate the cornea. It corrects myopia, hypermetropia, presbyopia, and astigmatism. In myopia, the central corneal stroma is ablated to flatten it; in hypermetropia and presbyopia the cornea is made steeper by ablating the desired zone.

◆Technique

Under topical anesthesia the epithelium is debrided. The patient fixates at the target in the microscope. The desired amount of corneal tissue is ablated using the nomogram made with the patient's data. The eye is taped following the procedure or a contact lens is placed. Postoperative medications include antiinflammatory and lubricating drops.

◆ Selected Complications of Photorefractive Keratectomy

Decentered Ablation

Decentration of the ablation zone by 1 mm or more occurs due to improper patient fixation, decentration, or eye movement during the procedure.

◆Presentation

Patients present with decreased visual acuity, diplopia, glare, halos, induced astigmatism .

◆Management

Some decentrations will lessen with time and remodeling. Those that do not improve require corneal topographic studies. Visual symptom improvement may be attempted with weak miotics, contact lens, or re-treatment.

Central Islands

A portion of the central corneal tissue is raised, leading to area of higher central corneal refractive power surrounded by an adjacent area of paracentral stroma. It has an elevation of at least 1 diopter with a diameter of more than 1 mm as compared with the paracentral flat area. It is seen less often now with the increasing use of flying spot laser systems.

◆Presentation

Patients present with visual distortion, double vision, decreased vision.

◆Management

Management consists of waiting and watching and corneal topographic study. Retreatment with the excimer laser may be helpful in selected cases.

Disabling Glare or Halos

◆Presentation

Some patients complain of glare and halos around light, especially in scotopic conditions. These symptoms are more pronounced with smaller ablation zones. They may also be seen with decentered ablations, epithelial ingrowths, and corneal haze.

◆Management

Management consists of constricting the pupil using miotics, topical brimonidine, and secondary ablation with increasing diameter.

Delayed Epithelial Healing

◆Presentation

Nonhealing epithelium even after 3 to 4 days postoperatively is commonly due to a large area of debridement, severe dry eye and prophylactic antibiotic and antiinflammatory eye drops, diabetes mellitus, and other autoimmune disorders. Patients present with watering, discomfort, redness, pain, and photophobia.

◆Management

Management consists of contact lens wear until reepithelialization, liberal use of lubricating drops, and treatment of the underlying cause. Excess nonsteroidal antiinflammatory drugs and corticosteroids should not be used. The patient may be followed up daily until healing.

Infectious Keratitis

Infectious keratitis is unusual, with bacterial causes most common. The inflammation typically causes redness of the eye with a focal infiltrate. Management includes culturing and antibiotic use directed towards the suspected organism until culture results are known.

Haze and Regression

◆Presentation

The healing process of activated keratocytes laying down new collagen fibers leads to corneal haze. The higher the correction the greater the risk of haze developing. Maximum haze is noticed between 1 and 3 months postoperatively and decreases with time. Corneal steepening leads to regression due to the changes in refractive power of the cornea.

◆Management

Topical steroids reduce the incidence of haze and regression. Patients having decreased visual acuity may benefit from re-treatment.

◆Laser In Situ Keratomileusis

Laser in situ keratomileusis (LASIK) is keratorefractive surgery for the treatment of high myopia, hyperopia, and astigmatism.

◆Technique

A corneal flap is created by corneal lamellar incision using a microkeratome or the femtosecond laser. The flap is then reflected and the corneal stroma is reshaped using the excimer laser. The flap is repositioned and realigned correctly after the procedure and allowed to adhere back on its own. It is used in the healing process. Visual recovery is quicker, with less scarring and regression compared with PRK because the epithelial surface is not debrided and the Bowman layer is not ablated.

◆ Selected Complications of Laser In Situ Keratomileusis

Debris after LASIK

◆Presentation

Interface debris is common and often results from meibomian gland secretions or makeup or mascara. These are typically not visually significant unless they occupy a large area and create an interface scar.

To prevent debris, it is important to operate in a lint-free environment, use nonfragmenting sponges, and have patients clean their lids well before surgery to remove all makeup and mascara (Fig. 19.1).

◆Management

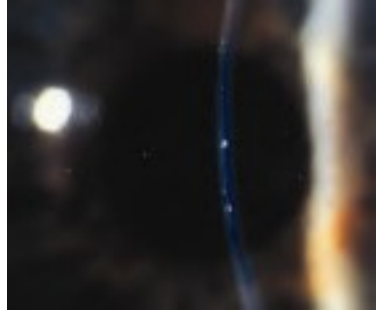
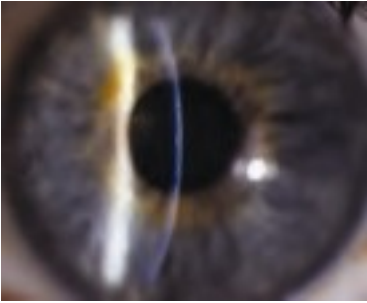
No intervention is needed unless enough debris is present that it is at risk of forming an interface scar or the debris degrades the vision.

Flap Striae

◆Presentation

The patient with flap striae may have monocular diplopia due to irregular astigmatism in the presence of microstriae. It may be a result of mild or significant LASIK flap displacement (Fig. 19.2).

A



B




Fig. 19.1 (A) Mascara in the interface after LASIK. (B) Moderate mascara in the interface. This is typically not visually significant. (C) Metal flecks in the interface, which is typically not reactive or visually

Csignificant.

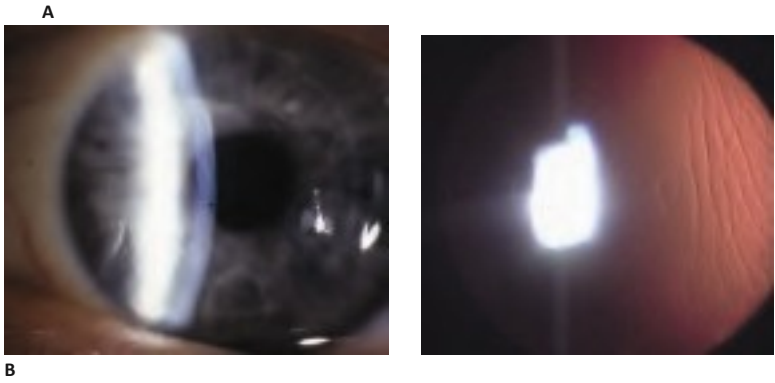


Fig. 19.2 (A) Striae across the visual axis from a displaced flap. **(B)** Peripheral striae that are not always visually significant, yet can occasionally cause induced asymmetric astigmatism. (Continued on page 524)

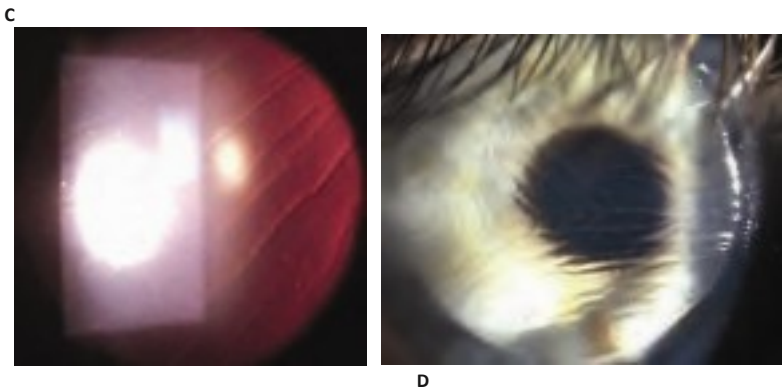


Fig. 19.2 (Continued) (C) Significant striae in the visual axis. **(D)** Severe striae from bunching of the flap.

◆Prevention

A lignment of the created trough by even placement of the corneal cap over the stroma evenly in all directions can help reduce the incidence of striae. Some surgeons advocate making a mark on the epithelium prior to creation of the flap to help with postoperative alignment, yet care must be taken that the epithelium does not shift in relationship to the stroma when using these marks to realign the flap.

◆Management

Microstriae may be observed if not visually significant. If they are visually significant, the surgeon may need to lift the flap, clean the interface from any cells or debris, and stretch the cap by stroking it with Merocel wipes (Medtronic, Minneapolis, MN www.medtronicophthalmics.com/Ophthalmics_Catalog_2007_2008_LR.pdf) until the gutter is well aligned.

Diffuse Lamellar Keratitis

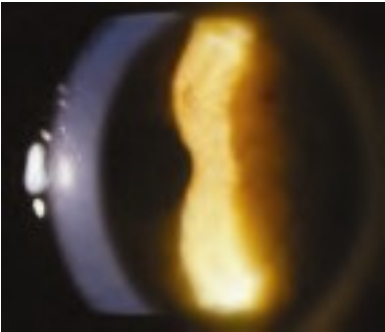
Diffuse lamellar keratitis (DLK) is a sterile inflammation of the flap interface occurring in the first week after LASIK. The condition has also been known as “shifting sands” phenomenon or “sands of the Sahara.”

◆Presentation

Severe DLK may occur in ~1 out of 5000 cases, and mild DLK in ~1 in 50 cases in most centers.

- ◆ *Stage 1* : Defined by the presence of white granular cells in the periphery of the lamellar flap, outside the visual axis (**Fig. 19.3**).
- ◆ *Stage 2*: Defined by migration of cells in the center of the flap, involving the visual axis, in the flap periphery, or in both. It is more frequently seen on day 2 or 3. The result of central migration of cells in stage 1 gives the so-called shifting sands appearance. This occurs in ~1 in 200 cases (**Fig. 19.4**).
- ◆ *Stage 3*: The aggregation of more dense, white, and clumped cells in the central visual axis, with relative clearing in the periphery. This is often, but not always, associated with a subtle decline in visual acuity by 1 or 2 lines and a subjective description of haze by the patient. The frequency of stage 3 may be as high as 1 in 500 cases (**Fig. 19.5**).

A



B

Fig. 19.3 (A) Stage 1 diffuse lamellar keratitis (DLK) with mild cell in the peripheral flap. **(B)** Stage 1 DLK with mild cell in the peripheral flap—high magnification.

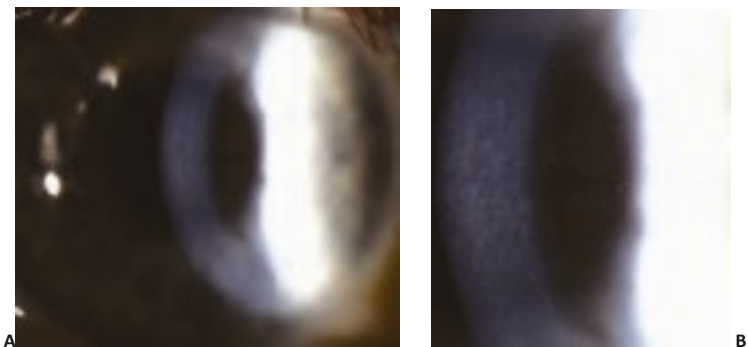

Fig. 19.4 (A) Stage 2 diffuse lamellar keratitis (DLK) with cells in the periphery and central portion of the flap. No significant clumping of the cells is seen in stage 2. **(B)** Stage 2 DLK—high magnification.

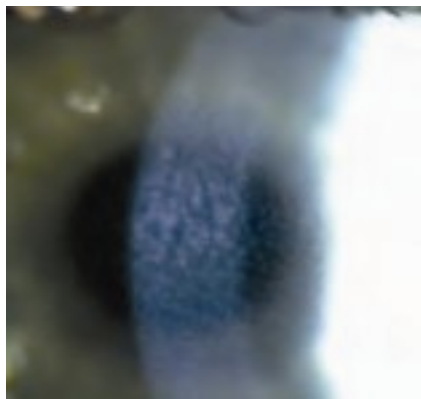
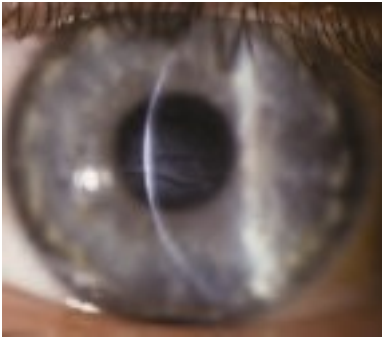
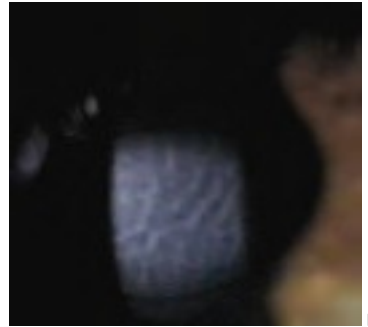
Fig. 19.5 Stage 3 diffuse lamellar keratitis with cells that are now aggregating, typically slightly below the center of the visual axis.

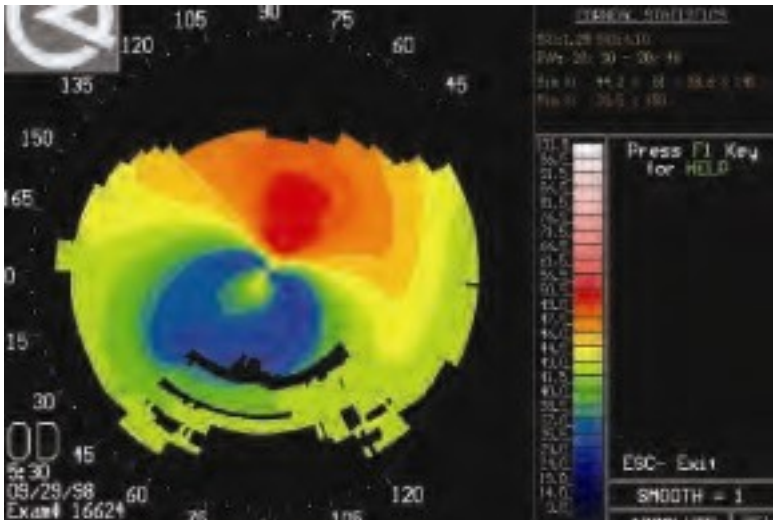


A



B

C



formation and stromal volume loss. A hyperopic shift occurs due to central tissue loss, along with the appearance of corrugated “mud cracks,” which are a serious finding. The incidence is ~1 in 5000 cases (Fig. 19.6).

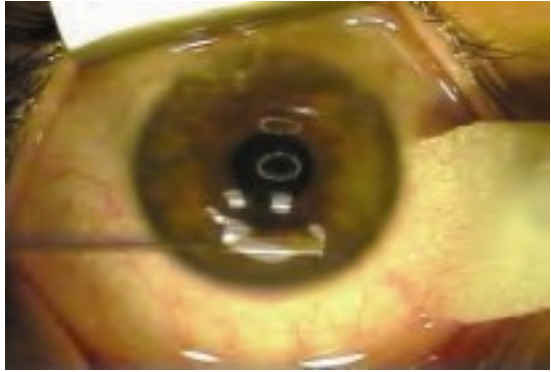


Fig. 19.7 Lifting and gentle irrigation of the flap is ideal management for stage 3 diffuse lamellar keratitis (DLK), typically at day 3 or day 4 after the surgery.

◆Management

- ◆ *Stages 1 and 2*: Topical prednisolone acetate 1% every hour and steroid ointment (fluoromethalone) at bedtime. Follow up in 24 to 48 hours.
- ◆ *Stage 3*: Lifting the flap, debulking the inflammatory reaction by careful irrigation of the bed and undersurface of the cap. It is usually done on day 3 or 4 after the procedure (Fig. 19.7).
- ◆ *Stage 4*: No definitive successful treatment identified. If white cells are still present, then gentle irrigation may be helpful in reducing tissue necrosis. Otherwise, waiting for epithelial hyperplasia may allow improvement in irregular astigmatism. Rigid gas-permeable contact lenses are often helpful for visual rehabilitation. Wavefront-directed surface treatment with mitomycin C can be considered after full epithelial hyperplasia has occurred, usually at ~1 year postoperatively.

Epithelial Ingrowth

Growth of epithelium into the interface between the flap and the stroma results in irregular astigmatism and loss of best corrected visual acuity. The presence of the epithelial cells in the interface can be safely followed without intervention in the majority of cases. The epithelial

cells in the interface can block the supply of nutrients to the underlying stroma and result in necrosis of the flap, extrusion of the epithelium, and a depressed scar.

The epithelial ingrowth can potentially happen in the presence of an epithelial defect created during the procedure. Edema of the LASIK flap overlying the epithelial defect leads to poor adhesion of the cap to the stromal bed and a subsequent route for epithelial cell migration. Epithelial defects are more common in the presence of anterior basement membrane dystrophy (**Fig. 19.8**).

◆Management

Immediate removal of epithelial cells is not always necessary, yet if the epithelial ingrowth is progressing, then it should be removed before reaching a 6-mm optical zone. The flap is lifted and epithelial cells, which may be strongly adherent to the tissue, are scraped with a blunt spatula or Meroceel sponge (Medtronic) from both the back of the flap and the stromal bed. Epithelial cells are also removed from the edge of the flap, along the surface of the flap for ~1.5 mm from the gutter, and in the periphery of the cornea for ~1.5 mm. An absolute alcohol solution can be applied to the stromal bed and the underside of the cap to devitalize the epithelial cells after the scraping. Care must be taken to protect limbal stem cells from alcohol. The flap is replaced in good position and stretched into place to remove any striae. The key to reducing recurrence is to keep epithelial cells from the flap edge until fibrosis has occurred between the flap and the stromal bed. The flap can be sutured to augment this fibrosis, especially in cases with a very high fistula. Typically interrupted sutures of either 10-0 nylon or 10-0 polyglactin are used. Following replacement of the flap, a fibrin/thrombin bioadhesive tissue glue such as Tisseel or Artiss (Baxter, Deerfield, IL) may be applied on the surface side of the stroma and along the gutter between the flap and peripheral stroma.

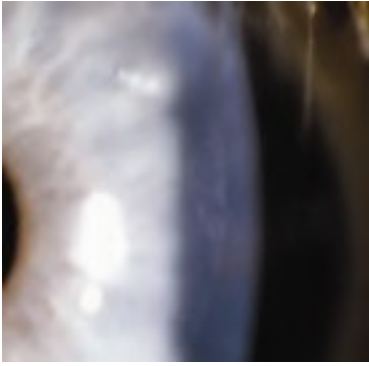
Epithelial Defect after LASIK

The advantage of LASIK over surface treatment with PRK is that an epithelial defect is typically not a part of the LASIK procedure. If a corneal abrasion does occur, discomfort is usually less painful than after PRK because of relative corneal anesthesia from the flap.

◆Management

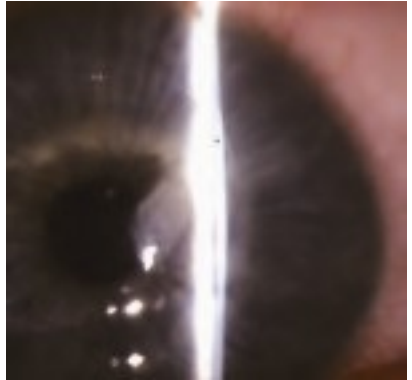If the defect is central, irregular astigmatism can be induced until the defect heals and epithelium regularizes. Presence of an epithelial defect can also lead to corneal edema and subsequent epithelial ingrowth. Healing of the epithelial defect can occasionally occur with redundancy of the basement membrane. If this happens, irregular astigmatism may persist, and a phototherapeutic keratectomy could be used to reduce this redundancy, paying special attention to methods to reduce haze formation afterward. Mitomycin C 0.02% (0.2 mg/mL) may be used to reduce the incidence of corneal haze (**Fig. 19.9**).

A

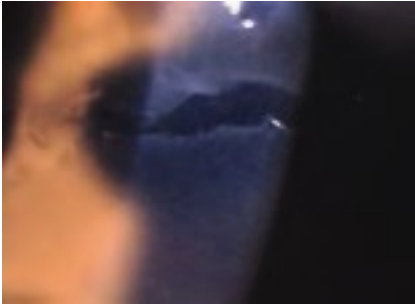

B

C



D



E

Fig. 19.8 (A) Epithelial cells under the flap after LASIK usually start along the peripheral flap edge. (B) Epithelial ingrowth can progress along the flap edge, in which case it may not become visually significant. (C) Epithelial ingrowth is more common where there are more edges along the LASIK flap, such as following radial or astigmatic keratotomy, or limbal relaxing incisions. (D) Epithelial cyst formation is less common after LASIK, yet may result from implantation of epithelium under the flap, and more commonly leads to melting of the overlying flap. (E) Epithelial defects along the flap edge are a common cause of flap swelling which can lead to epithelial ingrowth from poor adherence of the flap.

A




Fig. 19.9 (A) Inflammation under an epithelial defect 3 days after LASIK. (B)

Haze when phototherapeutic keratectomy was
Bmycin C.

done over prior LASIK flap without mito-

Ectasia after LASIK

Post-LASIK ectasia is a progressive central or inferior thinning and steepening of the cornea due to structural instability. Risk factors for corneal ectatic disorders are not well delineated but are likely mainly an underlying predisposition toward keratoconus. Extreme thinning of the cornea or very thin residual stromal bed thickness have also been implicated. Post-LASIK ectasia can present months or even years after the procedure (**Fig. 19.10**).

◆Management

Management consists of ocular hypotensives, rigid gas-permeable (RGP) lenses, deep anterior lamellar keratoplasty, penetrating keratoplasty, and, recently, also Intacs corneal implants (Addition Technology, Inc., Sunnyvale, CA) and collagen crosslinking treatment with riboflavin and ultraviolet light.

Post-LASIK Infectious Keratitis

Corneal infection after LASIK is a rare complication. Microorganisms isolated from infected corneas following LASIK have been *Staphylococcus aureus*, *Staphylococcus epidermidis*, *Nocardia asteroides*, *Streptococcus pneumoniae*, *Streptococcus viridans*, *Aspergillus fumigatus*, and herpes simplex. Nontuberculous mycobacteria or atypical mycobacterial infections have also been reported. They include *M. chelonae*, *M. abscessus*, *M. fortuitum*, *M. szulgai*, *M. mucogenicum*, *M. fortuitum*, *M. terrae*. One of the peculiarities of *Mycobacterium* spp. is the development of resistance

A



B

Fig. 19.11 (A) Infectious keratitis after LASIK. This infectious keratitis cleared with fortified antibiotics. **(B)** Scar in the interface after mycobacterial infection in the interface.

to organomercurials, chlorine, 2% concentrations of formaldehyde and alkaline glutaraldehyde, and other commonly used disinfectants, resulting in difficult disinfections of certain surgical instruments. Iodine-povidone does appear to have some bactericidal activity against these microorganisms. These infections appear to be less common with the prophylactic use of fourth-generation fluoroquinolones such as moxifloxacin and gatifloxacin (**Fig. 19.11**).

◆Differential Diagnosis

Diffuse lamellar keratitis, epithelial ingrowth, fungal keratitis, and intrastromal crystalline keratitis

◆Management

Presumed microbial keratitis after LASIK is managed with culture and appropriate frequent antibiotic treatment. Broad-coverage antibiotics (fortified vancomycin 33 mg/mL or amikacin 50 mg/mL and tobramycin 15 mg/mL or gentamicin 15 mg/mL) should be used frequently initially before the culture and susceptibility tests are available to allow more specific treatment. If the infectious process is not controlled and is resistant to treatment, flap lift, debridement, and irrigation of the interface with an antibiotic solution may hasten resolution. Fourth-generation fluoroquinolones (gatifloxacin and moxifloxacin) have been introduced as an alternative or an adjunct to fortified antibiotics. Corticosteroids are typically avoided during the active infectious process yet may reduce the tendency toward scarring.

A application of a periocular skin prep of povidone-iodide 5% and prophylactic antibiotic use may be useful in reducing the incidence of infectious keratitis at the time of refractive surgery.

Buttonhole with Haze

Potential to create a buttonhole during creation of the flap is more likely with a poor suction of the microkeratome or a damaged blade. Increased haze is then typically seen in any area where the Bowman membrane has been violated (Fig. 19.12).




Fig. 19.12 (A) Irregular flap with a hole in the periphery due to poor blade quality. (B) Buttonhole in the central portion of the flap.

◆Management

If buttonholing or a break in the Bowman membrane occurs within the optical zone, the flap should be repositioned and the ablation is postponed.

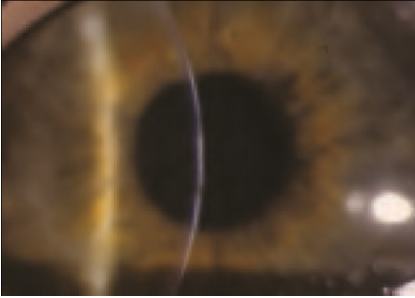
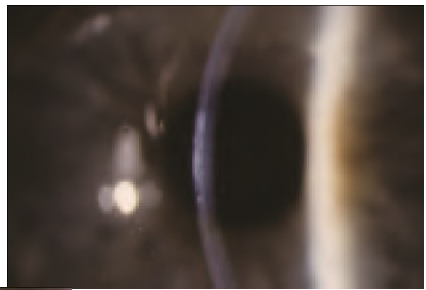
Haze after Excimer Laser Vision Correction

Central haze or scar can result in loss of BCVA, but haze is extremely uncommon after LASIK. Haze formation is more common when an excimer laser surface procedure is performed after previous lamellar surgery has been performed, especially when used without the addition of mitomycin C to the stroma after the ablation. Haze may be more common in primary PRK or LASIK procedures in deeper ablations (Fig. 19.13).

◆Management

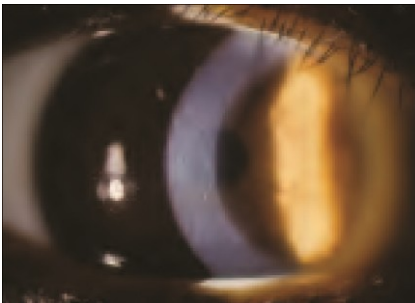
If the patient needs phototherapeutic keratectomy (PTK) or PRK after LASIK or any lamellar surgery careful monitoring for haze should be performed. Some surgeons advocate the use of a solution of mitomycin C 0.02% (0.2 mg/mL) following the ablation. Vitamin C 1 g daily before the procedure is thought to be beneficial. Topical steroids are used for several weeks afterward. Sunglasses with ultraviolet pro-

Fig. 19.13 (A) Haze seen when photorefractive keratectomy (PRK) was performed over the bed of a previous LASIK without the use of mitomycin



B

C. (Continued on page 532) **A Fig. 19.13 (Continued) (B)** Haze after PRK. **(C)** Haze after LASIK.



C

tection are recommended after surface laser procedures. Some surgeons advocate these same haze reduction modalities in primary surface laser procedures also.

Lamellar Interface fluid

Fluid may accumulate in the interface in eyes that have endothelial dysfunction or high intraocular pressure (IOP). Clinically, there is a pocket of fluid in the lamellar interface, decreased vision, and potentially a myopic shift. Microcystic epithelial edema may occur peripheral to the lamellar flap due to the increased IOP. The central corneal pachymetry may be either increased if it reads the entire corneal thickness or reduced if it measures only the thickness of the flap. The IOP may measure quite a bit lower than it actually is when measured over the fluid cyst, due to the tonometer measuring the pressure of the cyst, and not of the eye (**Fig.**

19.14).

◆ **Management**

The interface fluid usually resolves after lowering the IOP or restoring endothelial health.

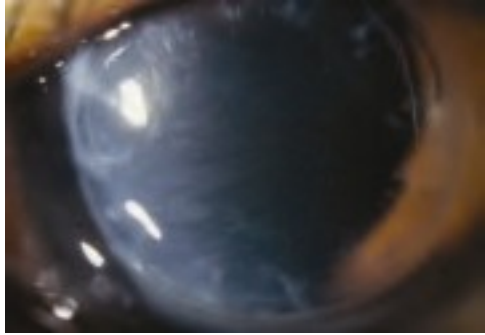
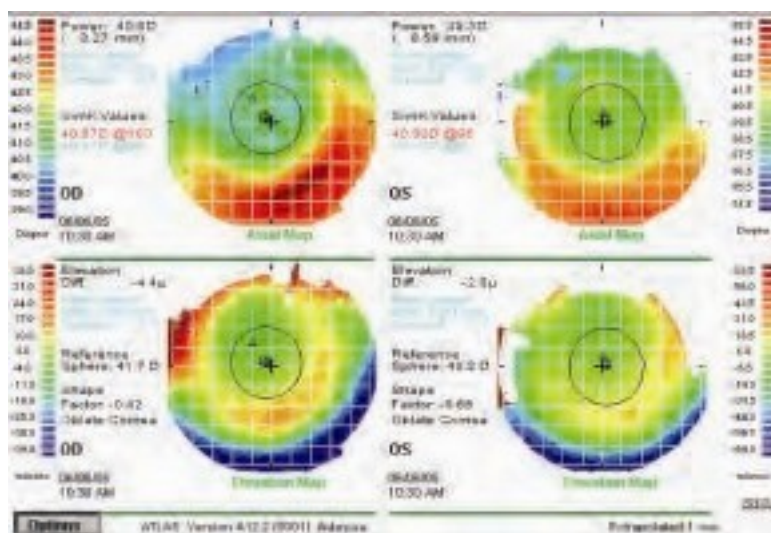


Fig. 19.14 Edema of the interface from poor endothelial function. A similar appearance may occur in a patient with high intraocular pressure.

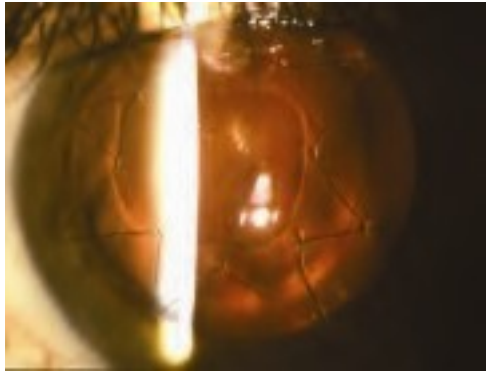
Irregular Astigmatism after LASIK

Irregular astigmatism after excimer laser refractive surgery can occur for a variety of reasons. Decentration of the excimer laser ablation of the cornea is less common with modern-day surgery because of the availability of pupil trackers and wavefront treatments that shift the ablation zone based on the pupil centroid comparison between the preoperative wavefront acquisition and the intraoperative pupil position. Significant decentration can cause irregular astigmatism with glare, monocular diplopia, and loss of best-corrected visual acuity (**Fig. 19.15**).



A

Fig. 19.15 (A) This topographic map shows irregular astigmatism due to asymmetry of the ablation zone. (Continued on page 536)



A

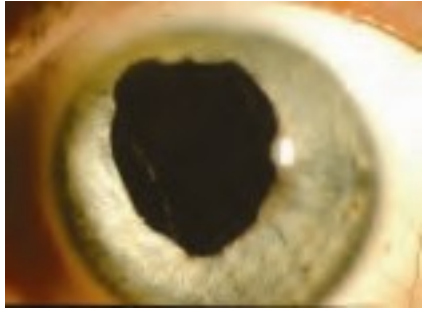


Fig. 19.16 (A) Perforation with an early keratome with need for suturing of the flap. **(B)** Loss of iris in a patient with a perforation with an early keratome. **B**

◆Management

The damage to other intraocular tissues should be assessed. In addition to corneal tissue, the iris and lens could possibly be involved. The cornea should be repaired with 10–0 nylon sutures. If other damage is found, it should further be repaired in the operating room.

◆Wavefront-Guided LASIK

Wavefront systems such as the AMO/VISX WaveScan WaveFront System (Abbott Medical Optics, Santa Ana, CA) are ophthalmic diagnostic instruments that typically utilize a Hartmann-Shack wavefront sensor to measure the refractive error and wavefront

aberrations of the human eye. The system can measure and display aberrations with more complex shapes than just a sphere and cylinder (higher-order aberrations, often described using Zernike polynomials as a mathematical calculation model) (Fig. 19.17).

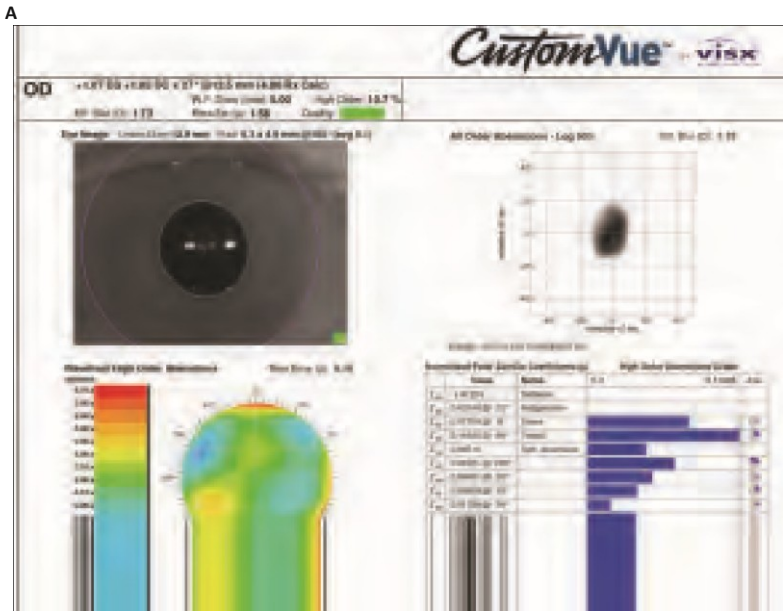


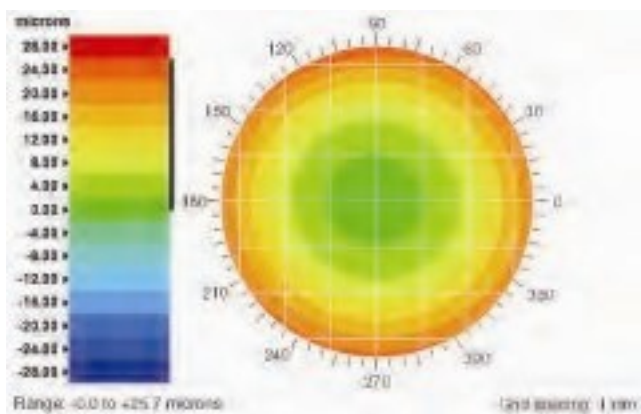
Fig. 19.17 (A) Information on the wavefront map includes the spherical correction, astigmatic correction, and higher-order aberrations as well as the iris detail used by the iris registration and cyclorotation software.

◆ Terminology

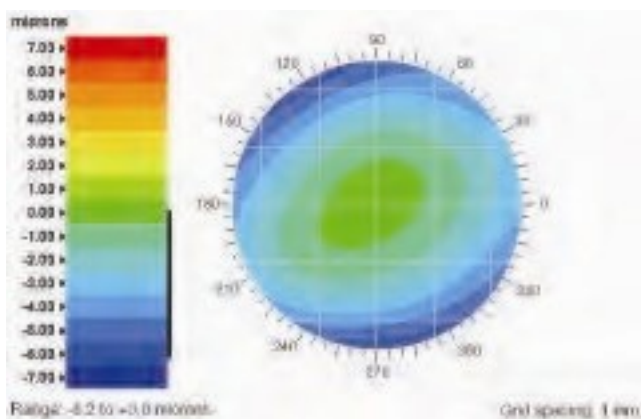
- ◆ Root mean square (RMS) error is the difference between the measured wavescan and an ideal plane wavefront. RMS is measured in micrometers.
- ◆ The higher-order aberrations represents the amount or percentage of higher-order aberrations as a value, or as a fraction of the total RMS of aberrations measured.
- ◆ The point spread function (PSF) attempts to describe the effect of visual aberrations on a point source of light.

◆Wavefront as a Screening Tool

Wavefront diagnostics can be useful in screening for corneal abnormalities that alter the total aberrations of the eye, such as keratoconus, and for assessing treatment options. There is a gradient of visual abnormalities in patients that may cause asymmetric corneas. Some eyes will have corneal or lenticular abnormalities causing distortion of their optical pathway that is apparent on topography or wavefront analysis. In other eyes the irregularities may be more peripheral, and the wavefront may be relatively normal within the central 6 mm.



B



C

Fig. 19.17 (Continued) (B) A myopic wavefront is represented by cooler colors such as green in the center surrounded by warmer colors such as yellow or red. **(C)** A hyperopic wavefront map is represented by the warmer colors centrally surrounded by cooler colors in the periphery.

◆Lenticular Aberrations

Wavefront diagnostics can also be used for preoperative screening and can assist in the diagnosis of a lenticular opacity. If the corneal topography is normal but the wavefront shows an increased amount of trefoil, coma and negative spherical aberrations, it suggests that the lens is the source

Minimally invasive Laser Vision Correction

ReLex® SMILE® from ZEISS is, until now, the only solution for performing small incision lenticule extraction, or SMILE for short. First performed on a sighted patient 10 years ago, today over 1,300 surgeons worldwide practice SMILE. As an FDA approved procedure, it offers clinics an additional Laser Vision Correction option to complete their LVC portfolio.

SMILE offers great prospects for success by expanding your offerings.

Get more information how to grow your business with ZEISS ReLex SMILE:

[Read more](#)

Explore the advantage of ReLex SMILE from ZEISS

Minimally invasive surgery.

With ReLEx SMILE, a lenticule and a small incision of 2-4 mm is created inside the cornea. The preservation of the upper corneal layers and the possibility for fewer transected nerves may preserve biomechanical stability and reduced the incidence of transient dry eye syndrome.

Single step.

With ZEISS ReLEx SMILE, the entire correction is performed as a single-step: one laser, one treatment plan and one laser process.

All-Femto.

Performed on a VisuMax® femtosecond laser, high precision, proven outcomes, predictability and ease of use are what ReLEx SMILE stands for.

ReLEx SMILE indication range for myopia and astigmatism

Sphere: -0.50 to -10.00 D

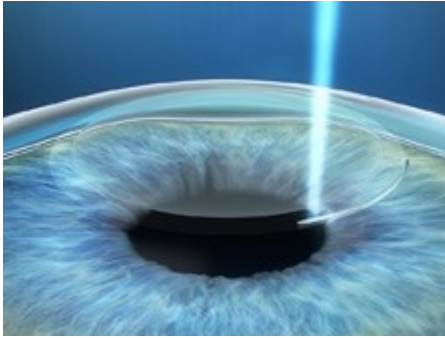
Cylinder: 0 to 5.00 D

Spherical equivalent: -0.50 to -12.50 D

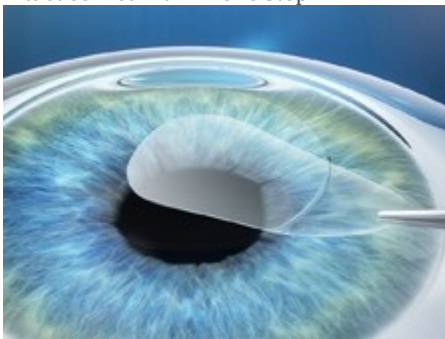- **Treatment steps – Fast and gentle**

- ZEISS ReLEx® SMILE® utilizes the high-precision femtosecond laser VisuMax® from ZEISS to create a lenticule inside the cornea and access incision in a single treatment step. Its outstanding cutting precision, exceptional speed and gentle treatment approach make it an ideal platform for advanced corneal surgery applications such as SMILE.

- *SMILE with VisuMax*

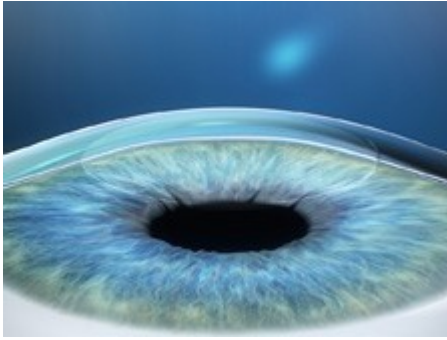


-
- A refractive lenticule and small incision are created inside the intact cornea – all in one step.



-

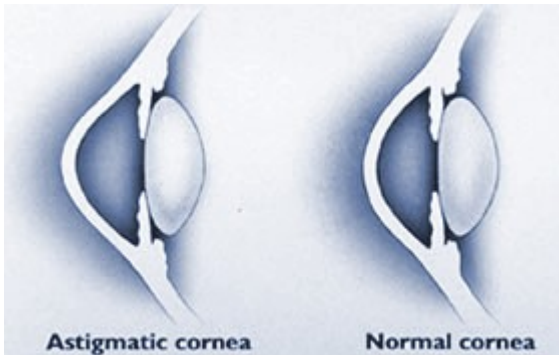
- The lenticule is removed through the incision with only minimal disruption to the corneal biomechanics.



-
- Removing the lenticule changes the shape of the cornea, thereby achieving the desired refractive correction.

- Astigmatism and LRI

Corneal Astigmatism



Whether myopic or hyperopic, most eyes have corneal astigmatism to some degree. Corneal astigmatism means that the front part of your eye, the clear window you look through, is not perfectly round. Instead of being spherical like a basketball, an astigmatic cornea is slightly flattened, more oval in shape like a football, with one side steeper than the other (as illustrated above).

Because the astigmatic cornea is curved more (steeper) in one direction than the other, light entering the eye is refracted differently as it passes through these different areas. This causes light to come into focus at several different points on the back of the eye, rather than ideally coming into focus at just one point.

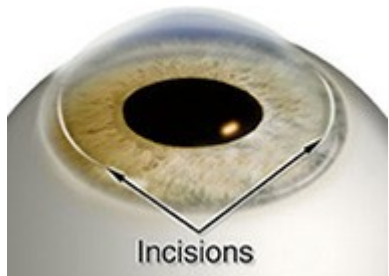
Depending on the direction and the amount of astigmatism, vision through an astigmatic cornea will be affected in various ways. The illustration (below) gives a broad example of the visual effects, depending on the overall direction of the curve:



Limbal Relaxing Incisions For The Correction of Astigmatism

It is most common for eye surgeons to simply prescribe glasses or contact lenses for the correction of astigmatism after cataract surgery. Some surgeons will treat corneal astigmatism at the time of cataract surgery by placing "limbal relaxing incisions" (LRI's). This involves making tiny incisions in the cornea to "relax" or flatten the steeper meridian, thereby causing the corneal curvature to become more rounded, reducing astigmatism.

These long, thin incisions are placed at the very edge of the cornea (known as the corneal limbus) on the steepest meridian, and differ in number and length according to the amount of astigmatism. Relaxing incisions generally do not eliminate corneal astigmatism completely, but rather reduce it to an acceptable level. Because the cornea is living tissue, there may be "over-response" or "under-response" to these incisions. Seldom is corneal astigmatism completely resolved; however, a significant reduction in your astigmatism produces a more satisfactory uncorrected visual result.



Some patients with extreme amounts of astigmatism may still require the addition of limbal relaxing incisions to correct astigmatism after cataract surgery with the AcrySof toric lens. For the patients, with unusually high amounts of astigmatism, implanting the toric lens means that less corneal surgery in the form of a limbal relaxing incision is needed to achieve the same amount of correction.

In the future, the AcrySof Toric Lens will be available in higher powers of astigmatic correction so that for very high amounts of corneal astigmatism can be corrected without the need for the addition of limbal relaxing incisions.

<https://www.lricalculator.com/>

Intracorneal Ring Segments: Types, Indications and Outcomes

Fig. 17.1

Intracorneal ring segment Keraring (Mediphacos)

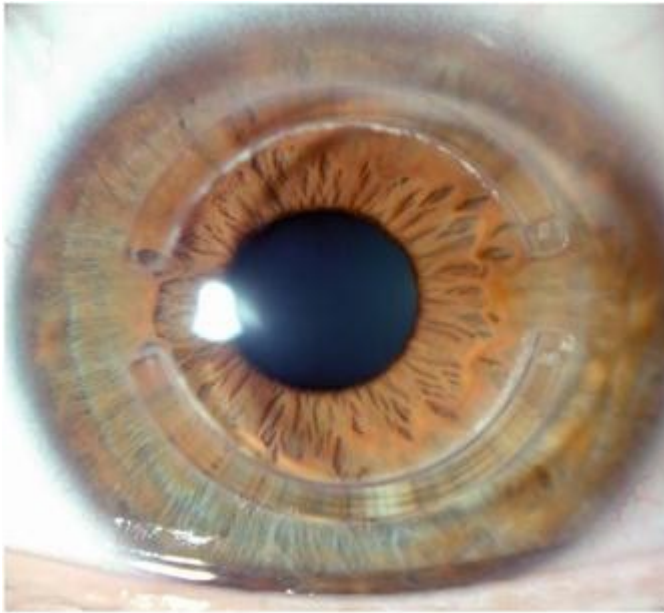


Fig. 17.2

Intracorneal ring segment Intacs (additional technologies)

Table 17.1

Main characteristics of the intracorneal ring segments most commonly used in the clinical practice

Design	Intacs	Kerarings	Ferrara
Arc length (degrees)	150°	90°–210°	90°–210°
Cross section	Hexagonal	Triangular	Triangular
Thickness (mm)	0.25–0.35	0.15–0.35	0.15–0.30
Inner diameter (mm)	6.77	6.00	4.8
Outer diameter (mm)	8.10	7.00	5.4

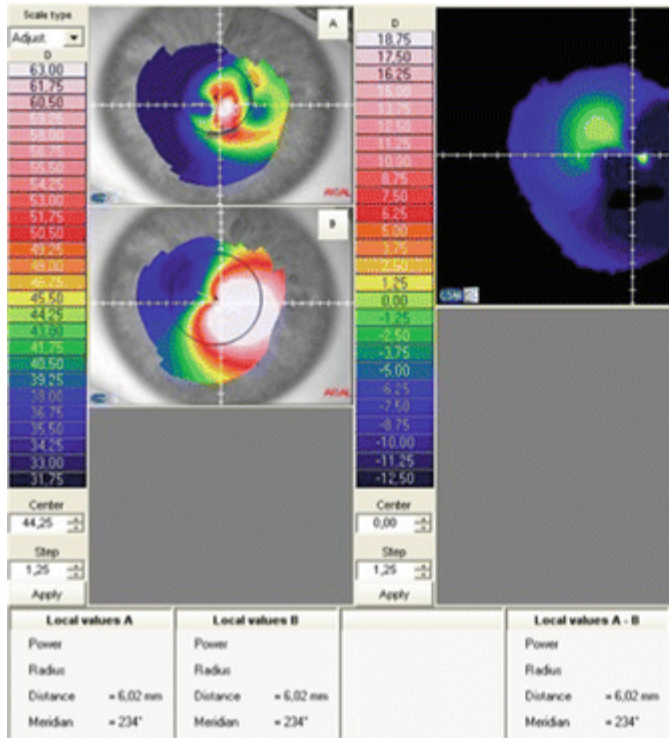


Fig. 17.3

Topography of a patient implanted with a Myring (Dioptex) showing the significant flattening that is observed in the postoperative period. Map A: postoperative topography showing an average SimK of 42.59 D; Map B: preoperative topography showing an average SimK of 58.32 D

Table 17.2

Main characteristics of the intracorneal ring segments with higher flattening capabilities, reserved for those eyes with high myopic refractive errors

Design	Intacs SK	Myring
Arc length (degrees)	150°	360°
Cross section	Oval	Triangular
Thickness (mm)	0.40–0.45	0.15–0.35
Inner diameter (mm)	6.00	5.00–8.00
Outer diameter (mm)	7.00	5.00–8.00

- Intacs SK* (SK means severe keratoconus) are designed with rounded edges to potentially reduce the incidence of visual symptoms since SK segments are placed closer to patient's visual axis than the standard Intacs segments. They are indicated for the treatment of moderate to severe keratoconus (SK) with steep keratometric values >55.00 dioptres. Intacs SK segments seem to offer a compromise between the standard Intacs with 7 mm diameter and the Ferrara or Kerarings which are 5 mm in diameter, because diameter is inversely proportional to effectivity.
- The Myring* is the only one with a full ring (360°) design with published clinical data, and it is implanted within a corneal stromal pocket. They have a greater capacity to flatten and reduce the spherical equivalent than the segments, but do not usually significantly reduce

astigmatism and therefore their use is limited to cases in which patients have a high spherical error and low astigmatism. Daxer et al. support that, while ICRS and incomplete rings are biomechanically neutral, MyoRing strengthens and stabilizes the cornea considerably and subsequently it is no longer necessary to combine it with CXL in progressive keratoconus [13]. This statement still requires long-term studies before its confirmation.

17.5 Surgical Procedure

In order to implant the ICRS into the deep cornea, we need to perform channels within the stroma where the rings will be implanted. For this purpose there are two different surgical options: mechanical and femtosecond laser-assisted technique.

In the mechanical or manual technique, the surgeon must mark the centre of the pupil in order to use it as a reference point during the procedure. Then a calibrated diamond knife is used to create an incision at a depth of 70 % of the corneal pachymetry at the incision point. A suction ring is placed around the corneal limbus in order to fixate the eye during the dissection of the corneal stroma. Then, two semi-circular dissectors are placed through the incision and advanced into the deep stroma in a clockwise and counterclockwise movement aiming to perform the tunnel.

With the femtosecond laser-assisted technique, a disposable suction ring is placed and centred. Afterwards, the cornea is flattened with a disposable aplanation cone, which allows a precise focus of the laser beam thus creating the dissection on the desired depth. Then the tunnel is created at approximately 70 or 80 % of the corneal pachymetry without direct manipulation of the eye. Finally, ICRS are inserted in the created tunnels.

Femtosecond laser produces a more precise and controlled stromal dissection than the manual technique. However, if we are talking about visual and refractive outcomes, most studies that have been conducted concur that both techniques produce similar results in cases of ICRS implantation for keratoconus. On the other hand, femtosecond laser makes the process faster, easier (especially for inexperienced surgeons) and more comfortable for the patient [14–17]. Apart from the safety and efficacy differences between both techniques, Alió and co-workers found that intrastromal segment implantation using femtosecond laser is a method that produces a greater reduction in corneal high order aberrations in eyes with coma aberration $>3.0 \mu\text{m}$ [14, 15].

17.6 Implantation Nomograms

Regardless of the technique used to make the tunnels in the corneal stroma, the number, thickness, position and arc length of the segments are determined based on the manufacturer's nomograms. Likewise, rings are chosen from the nomogram taking into

account the refractive error and the topographic map of the disease. It should also be noted that the incision guiding implantation of the segments in the tunnel is located on the axis of the steepest meridian of the corneal topography.

It is important to consider that although several authors have reported good results implanting ICRS in keratoconic eyes, the main limitations that nomograms have is that most of them are based in anecdotic clinical data, or variables that are very subjective in patients with keratoconus, such as spherocylindrical refraction and topographic pattern of the cone. For instance, it was found that based on the topographic pattern of the keratoconus the best choice was to implant one segment in those cases of inferior steepening and two segments in central cones [18].

Other works published in the literature support that the best location to implant the segments is by placing the corneal incision in the temporal site of the cornea [19–22] or in the steepest meridian of the cornea [23, 24]. There are other works that have reported good results when implanting the ICRS guided by the comatic axis [25]. Recently, Alió and co-workers published a scientific work in which we concluded that the best outcomes for implanting ICRS were observed in those cases where the refractive and topographic cylinder did not differ in more than 15° [12].

As we can see, there are different approaches regarding the guidelines to be used when implanting ICRS. Nevertheless,

today the most widespread nomograms that are used in the clinical practice are those developed by the main manufacturers of ICRS:

17.6.1 Keraring Implant

Three types of nomograms (A, B and C) are used based on the type of corneal asymmetry (Fig. 17.4), on keratometric values and on corrected distance visual acuity (CDVA). The corneal asymmetry type is determined by studying the distribution of corneal irregularity (red) relative to the reference meridian. Accordingly, each case is classified according to Fig. 17.4 :

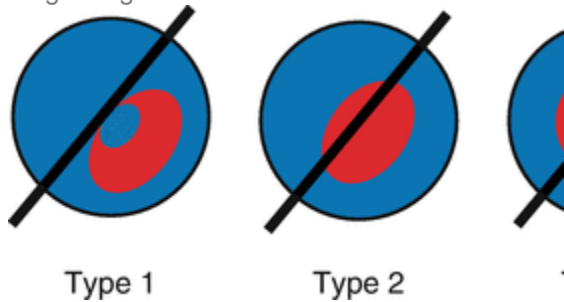


Fig. 17.4

Corneal asymmetry classification according to the area where the corneal irregularity (*red*) is found relative to the reference meridian (*black line*)

- *Type 1*: 100 % of the steep area is located on one side of the reference meridian.

- *Type 2*: The distribution of the steep area is approximately 20/80 %.
- *Type 3*: The distribution of the steep area is approximately 40/60 %.
- *Type 4*: The distribution of the steep area is approximately 50/50 %.

For type 1 and type 2 nomogram A is applied. Nomogram B for type 3 and nomogram C for type 4 (Fig. 17.5). These nomograms should be considered and used as a general guideline only and they should be customised by the surgeon depending on each patient particularities and the results obtained.

2. 2.

Perform corneal topography (axial map).

3. 3.

Take pachymetric map. Determine the minimum corneal thickness at 5.5 and 6.5 mm optical zones.

4. 4.

Determine the steepest corneal meridian (SIM-K). If the refractive axis and the steepest topographic axis do not match, select the topographic meridian.

5. 5.

Compare the thickness of the proposed segment according to the selected nomogram with the minimal corneal thickness obtained in the 6 mm optical zone. The thickness of the segment should not exceed 60 % of the minimal corneal thickness. If it does, a segment

with less thickness should be selected (Table 17.3).

Table 17.3

Safety thickness measurements for selection of intracorneal ring segments

Safety limits					
Proposed segment thickness (μm)	150	200	250	300	350
Minimal corneal thickness required for implant (μm)	250	335	420	500	580

Then we move on to select the reference meridian : If the CDVA > 0.5 , we select the steepest meridian. If the CDVA < 0.5 , select the total coma aberration axis or the steepest meridian by topography (SIM-K). Then draw a line along the reference meridian selected.

To determine the treatment strategy : If the CDVA > 0.4 , program the treatment based on refractive sphere and cylinder obtained by manifest refraction. If the CDVA < 0.3 or if the manifest refraction is not very reliable, program the treatment based on kerometric values.

When it comes to implantation, when the nomogram suggests using two segments, the nomogram data appearing in the top

line of the box should be used for the segment implanted in the area where the ectasia is smaller (flatter meridian), and the data on the lower line shall be for the segment implanted on the steepest meridian. When the nomogram suggests only one segment, this should be implanted on the steepest meridian, where the ectatic area is greater.

17.6.2 Ferrara Implant

Similar tasks must be performed before implanting these segments (Tables 17.4 and 17.5). From topographic astigmatism, the thickness of the ring is defined (Tables 17.6, 17.7 and 17.8). However, in the case of nipple keratoconus, this measurement is not used and the spherical equivalent is used to define the thickness of the ring, which it should be a 210° arc ring (exclusive for this type of keratoconus) (Table 17.9).

Table 17.4

Step-by-step tasks for Ferrara ICRS implantation

Ferrara ring nomogram
1. Define the type of keratoconus: sag, bowtie or nipple
2. Distribution of the ectatic area in the cornea: 0/100, 25/75, 33/66 and 50/50
3. Corneal asphericity (Q)
4. Topographic astigmatism
5. Pachymetry at incision site and ring track

Table 17.5

Distribution of area of corneal ectasia for Ferrara ICRS implantation nomogram





Map	Distribution of ectasia (%)	Description
	0/100	All the ectatic area is located at one side of the cornea
	25/75	75 % of the ectatic area is located at one side of the cornea
	33/66	66 % of the ectatic area is located at one side of the cornea
	50/50	The ectatic area is symmetrically distributed on the cornea

Table 17.6

Ferrara ICRS thickness choice in symmetric bowtie keratoconus

Topographic astigmatism (D)	Intracorneal segment thickness
<2.00	150/150
2.25–4.00	200/200
4.25–6.00	250/250
>6.25	300/300

Table 17.7

Ferrara ICRS thickness choice in sag keratoconus with 0/100 % and 25/75 % asymmetry index

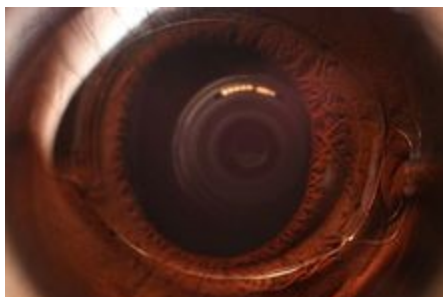
Topographic astigmatism (D)	Intracorneal segment thickness
<2.00	None/150
2.25–4.00	None/200
4.25–6.00	None/250
6.25–8.00	None/300
8.25–10.00	150/250
>10	200/300

Table 17.8


Ferrara ICRS thickness choice in sag keratoconus with 33/66 % asymmetry index

Topographic astigmatism (D)

Medical uses[\[edit\]](#)



An installed PIOL, with flash photography



An installed PIOL, without flash photography

LASIK can correct myopia up to -12 to -14 D. The higher the intended correction the thinner and flatter the cornea will be post-operatively. For LASIK surgery, one has to preserve a safe residual stromal bed of at least 250 μm , preferably 300 μm . Beyond these limits there is an increased risk of developing corneal ectasia (i.e. corneal forward bulging) due to thin residual stromal bed which results in loss of visual quality. Due to the risk of [higher order aberrations](#) there is a current trend toward reducing the upper limits of LASIK and PRK to around -8 to -10 D.^[4] Phakic intraocular lenses are safer than excimer laser surgery for those with significant [myopia](#).^[5]

Phakic intraocular lenses are contraindicated in patients who do not have a stable refraction for at least 6 months or are 21 years of age or younger. Preexisting eye disorders such as uveitis are another contraindication.

Although PIOLs for [hyperopia](#) are being investigated, there is less enthusiasm for these lenses because the anterior chamber tends to be shallower than in myopic patients. A hyperopic model ICL (posterior chamber PIOL) is available.

[Corneal endothelial cell](#) count less than 2000-2500 cells/mm² is a relative contraindication for PIOL implantation.^[2]

Advantages[\[edit\]](#)

PIOLs have the advantage of treating a much larger range of myopic and hyperopic refractive errors than can be safely and effectively treated with corneal refractive surgery. The skills required for insertion are, with a few exceptions, similar to those used in cataract surgery. The equipment is significantly less expensive than an excimer laser and is similar to that used for cataract surgery. In addition, the PIOL is removable; therefore, the refractive effect should theoretically be reversible. However, any intervening damage caused by the PIOL would most likely be permanent. When compared with clear lens extraction, or refractive lens exchange the PIOL has the advantage of preserving natural accommodation and may have a lower risk of postoperative retinal detachment because of the

preservation of the crystalline lens and minimal vitreous destabilization.^[1]

Disadvantages[\[edit\]](#)

PIOL insertion is an intraocular procedure. With all surgeries there are associated risks. In addition, each PIOL style has its own set of associated risks. In the case of PIOLs made of polymethylmethacrylate (PMMA), surgical insertion requires a larger incision, which may result in postoperative astigmatism. By comparison, PIOLS made of collamer (a foldable gel-like substance) requires a very small incision due the flexibility of the material and thus significantly reduces astigmatism risk. In the cases where refractive outcomes are not optimal, LASIK can be used for fine-tuning. If a patient eventually develops a visually significant cataract, the PIOL will have to be explanted at the time of cataract surgery, possibly through a larger-than-usual incision.

Another concern is progressive shallowing of the anterior chamber which normally occurs with advancing age due to the growth of the eye's natural lens. Multiple studies have shown a 12-17 $\mu\text{m}/\text{year}$ decrease in the anterior chamber depth with aging.^{[6][7]} If a phakic IOL patient is assumed to have a 50-year lifespan, the overall decline in ACD may add up to 0.6-0.85 mm, long-term data about this effect are not available. This concern is more important in [ICL](#) because it is implanted in the narrowest part of the anterior segment.

Complications[[edit](#)]

- [Glare](#) and [halos](#) which may cause night time symptoms especially in patients with larger pupil diameters.
- [Cataract](#) which is the most crucial concern for the [Sulcus-Supported PIOLs](#). According to FDA approximately 6% to 7% of eyes develop anterior subcapsular opacities at 7+ years following [Implantable Collamer Lens](#) implantation and 1% to 2% progress to clinically significant cataract during the same period, especially very high myopes and older patients.^{[4][8]}
- [Endothelial cell](#) loss especially for the anterior chamber PIOLs. A study observed a continual steady loss of endothelial cells of -1.8% per year.^[4]
- Pigment dispersion may be seen in iris-fixated and sulcus-supported PIOLs due to iris abrasion during pupillary movement.
- Other complications include glaucoma and PIOL dislocation or decentration.

Preoperative evaluation[[edit](#)]

Anterior chamber depth (ACD, i.e. the distance between the crystalline lens and cornea including the corneal thickness) is required before the surgery and measured with the use of ultrasound.

Iris-fixated IOLs are fixated to iris therefore they have the advantage of being one size (8.5 mm).

Sulcus-supported IOLs need to be implanted in the ciliary sulcus which may have various diameters among individuals, therefore anterior chamber diameter needs to be measured with a calliper or with the use of eye imaging instruments such as Orbscan and high frequency ultrasound. A calliper and Orbscan measure the external limbus-to-limbus diameter of anterior chamber (white-to-white diameter) which provides an approximate estimation of AC diameter but UBM and OCT offer a more adequate measurement of the sulcus diameter (sulcus-to-sulcus diameter) and should be used when available.^[4]

Power calculation[\[edit\]](#)

The power of phakic lens is independent of the axial length of the eye. Rather it depends on central corneal power, anterior chamber depth (ACD) and patient refraction (preoperative spherical equivalent). The most common formula for calculating the power of phakic IOL is the following:^[2]

P : Power of phakic IOL

n : Refractive Index of Aqueous (1.336)

K : Central corneal power in diopters

R : Patient Refraction at the corneal vertex

d : Effective lens position in mm

The effective lens position is calculated as the difference between the anterior chamber depth and the distance between the PIOL and the crystalline lens. From ultrasonographic examinations of PIOLs, the lens-optic distance shows less variability compared with the cornea-optic distance. Therefore, it is preferable to use measured ACD and subtract it with an 'optic-lens' constant to obtain the value of ELP. For the Artisan/Verisyse lens the optic-lens constant is 0.84 mm. The ICL power is calculated using the Olsen-Feingold formula by using a four variable formula modified by a regression analysis of past results.^[3]

Surgical technique[\[edit\]](#)

The Artisan (Verisyse) lens is implanted under pharmacological miosis. After creating proper incision the lens is grasped with curved holding forceps and inserted. Once in the anterior chamber and while firmly holding the lens with forceps, temporal and nasal iris tissue is enclavated with a special needle. The operation is completed with an [iridectomy](#) and the incision is sutured.

The ICL is implanted under pharmacological mydriasis and implanted in the retropupillary position, between the eye's

iris and the crystalline lens, using cartridge-injector or forceps. Both eyes can usually be done on the same day.

Steroid antibiotic eye drops are usually prescribed for 2–4 weeks after surgery. Regular follow-ups are recommended.^[4]