

17 Motility a Strabismus

Definition: **Strabismus** is defined as deviation of an eye's visual axis from its normal position.

There are **two major types of manifest strabismus or heterotropia**.

1. **Concomitant strabismus** (from the Latin "comitare," accompany). The deviating eye *accompanies* the leading eye in every direction of movement. The angle of deviation remains the same in all directions of gaze. This form of strabismus may occur as monocular strabismus, in which only one eye deviates, or as alternating strabismus, in which both eyes deviate alternately.
2. **Paralytic strabismus** results from paralysis of one or more eye muscles. This form differs from concomitant strabismus in that the angle of deviation does not remain constant in every direction of gaze. For this reason, this form is also referred to as **incomitant strabismus**.

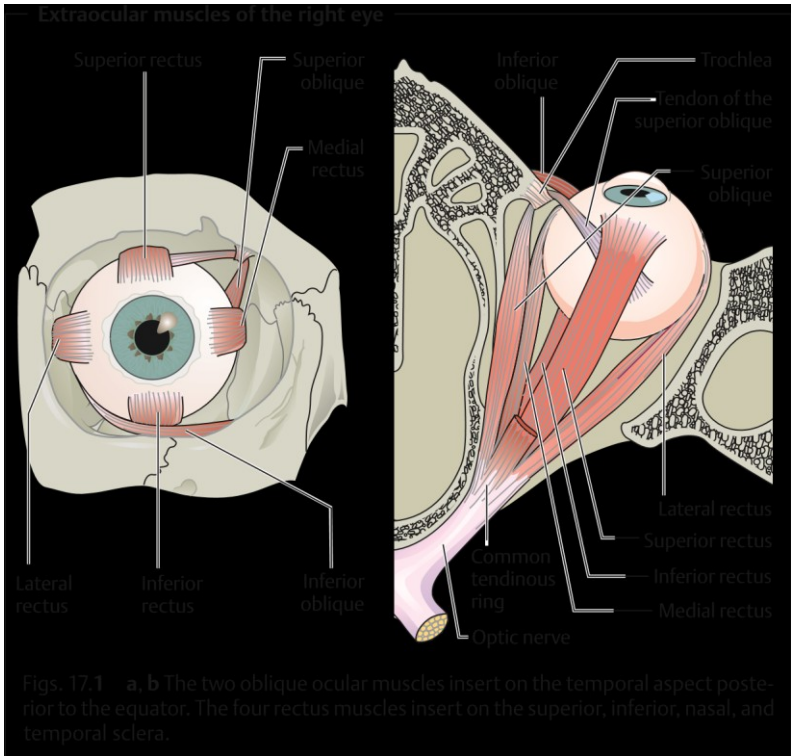
Epidemiology. The incidence of strabismus is about 5–7%. **Esotropia (convergent strabismus)** occurs far more frequently than **exotropia (divergent strabismus)** in Europe and North America. **Concomitant strabismus** usually occurs in children, whereas **paralytic strabismus** primarily affects adults. This is because concomitant strabismus is generally congenital or acquired within the first few years of life, whereas paralytic strabismus is usually acquired, for example as a post-traumatic condition.

17.1 Basic Knowledge

Ocular motility. The movements of the eyeballs are produced by the following extraocular muscles (Fig. 17.1):

The **four rectus muscles:** the superior, inferior, medial, and lateral rectus muscles.

The **two oblique muscles:** the superior and inferior oblique muscles. All of these muscles originate at the tendinous ring except for the inferior oblique muscle, which has its origin near the nasolacrimal canal. The *rectus muscles* envelop the globe posteriorly, and their respective tendons insert into the superior, inferior, nasal, and temporal sclera. The *oblique muscles* insert into the temporal globe posterior to the equator. The insertion of the muscles determines the direction of their pull (Table 17.1).



The connective tissue between the individual ocular muscles is incorporated into the **facial sheath of the eyeball (Tenon's capsule)**. Other important anatomic structures include the **lateral and medial check ligaments** comprising the lateral connections of the orbital connective tissue and the **ligament of Lockwood**. This is comprised of the ligamentous structures between the inferior rectus and inferior oblique that spread out like a hammock to the medial and lateral rectus muscles.

These anatomic structures and the uniform nerve supply to the extraocular muscles (similarly acting muscles have a similar nerve supply) ensure ocular balance. Changes that disturb this balance, such as ocular muscle paralysis that limits or destroys the affected muscle's ability to contract, cause strabismus. The angle of deviation is a sign of abnormal imbalance.

Direction of pull of the extraocular muscles. The **horizontal ocular muscles** pull the eye in only *one* direction: The lateral rectus pulls the eye outward (*abduc-*

17.1 Basic Knowledge

tion); the medial rectus pulls it inward (*adduction*). **All other extraocular muscles** have a *secondary direction of pull* in addition to the primary one. Depending on the path of the muscle, where it inserts on the globe, and the direction of gaze (Fig. 17.1), these muscles may elevate or depress the eye, adduct or abduct it, or rotate it medially (intorsion) or laterally (extorsion). The primary action of the superior rectus and inferior oblique is *elevation*; the primary action of the superior rectus and inferior oblique is *depression*. Table 17.1 shows the primary and secondary actions of the six extraocular muscles. A knowledge of these actions is important to understanding paralytic strabismus.

Nerve supply to the extraocular muscles. The oculomotor nerve (third cranial nerve) supplies all of the extraocular muscles except the superior oblique, which is supplied by the trochlear or fourth cranial nerve, and the lateral rectus, which is supplied by the abducent or sixth cranial nerve (Table 17.1). The **extraocular muscle nuclei** are located in the brain stem on the floor of the fourth ventricle and are interconnected via the medial longitudinal fasciculus, a nerve fiber bundle connecting the extraocular muscles, neck muscles, and vestibular nuclei for coordinated movements of the head and globe (Fig. 17.2). Various **visual areas** in the brain control eye and gaze movements. The location of the muscle nuclei and knowledge of the visual areas are important primarily in gaze paralysis and paralytic strabismus and of particular interest to the neurologist. For example, the type of gaze paralysis will allow one to deduce the approximate location of the lesion in the brain.

All extraocular muscles except for the superior oblique and lateral rectus are supplied by the oculomotor nerve.

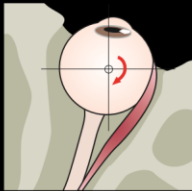

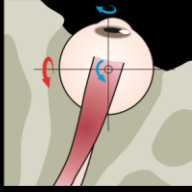
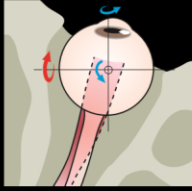
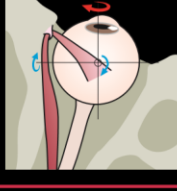
Physiology of binocular vision. Strictly speaking, we “see” with the brain. The eyes are merely the organs of sensory reception. Their images are stored by coding the stimuli received by the retina. The optic nerve and visual pathway transmit this information in coded form to the visual cortex.

The **sensory system** produces a retinal image and transmits this image to the higher-order centers. The **motor system** aids in this process by directing both eyes at the object so that the same image is produced on each retina. The brain can then process this information into **binocular visual impression**. A person has no subjective awareness of this interplay between sensory and motor systems.

There are **three distinct levels of quality of binocular vision**.

1. **Simultaneous vision.** The retinas of the two eyes perceive two images *simultaneously*. In normal binocular vision, both eyes have the *same point* of fixation, which lands on the fovea centralis in each eye. The image of an object always lands on *identical* areas of the retina, referred to as *corresponding points on the retina*. Objects lying on an imaginary circle known as the *geometric horopter* (Fig. 17.3a) are projected to these points on the

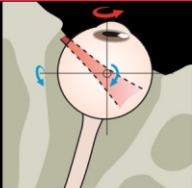
Tab. 17.1 Function of the extraocular muscles with the gaze directed straight ahead

Muscle	Primary action	Secondary action	Example (right eye)	Nerve supply
Lateral rectus	Abduction	None		Abducent nerve
Medial rectus	Adduction	None		Oculomotor nerve
Superior rectus	Elevation	Intorsion and adduction		Oculomotor nerve
Inferior rectus	Depression	Extorsion and adduction		Oculomotor nerve
Superior oblique	Intorsion	Depression and abduction		Trochlear nerve

Continued

17.1 Basic Knowledge

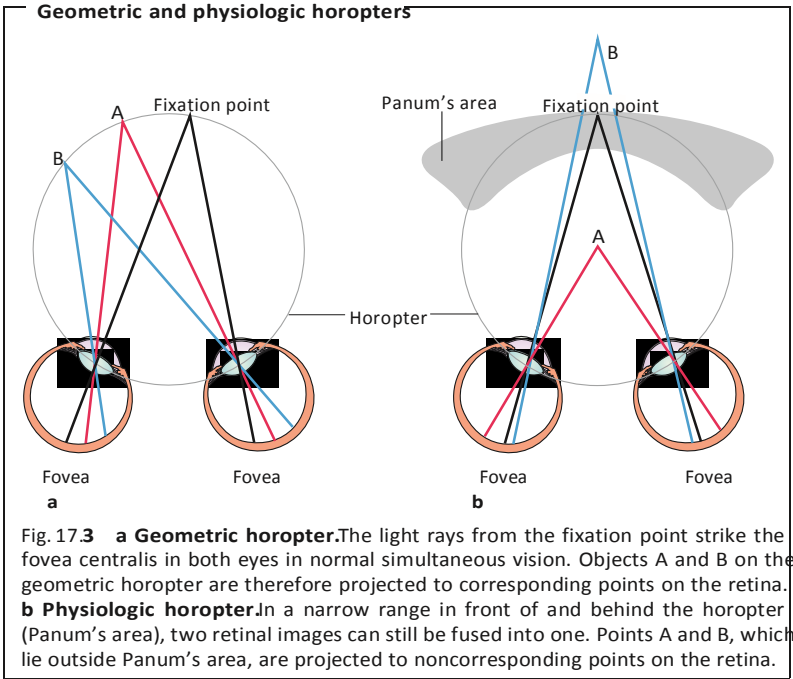
Tab. 17.1 Continued

Muscle	Primary action	Secondary action	Example (right eye)	Nerve supply
Inferior oblique	Extorsion	Elevation and abduction		Oculomotor nerve

Location of the extraocular muscle nuclei and gaze centers

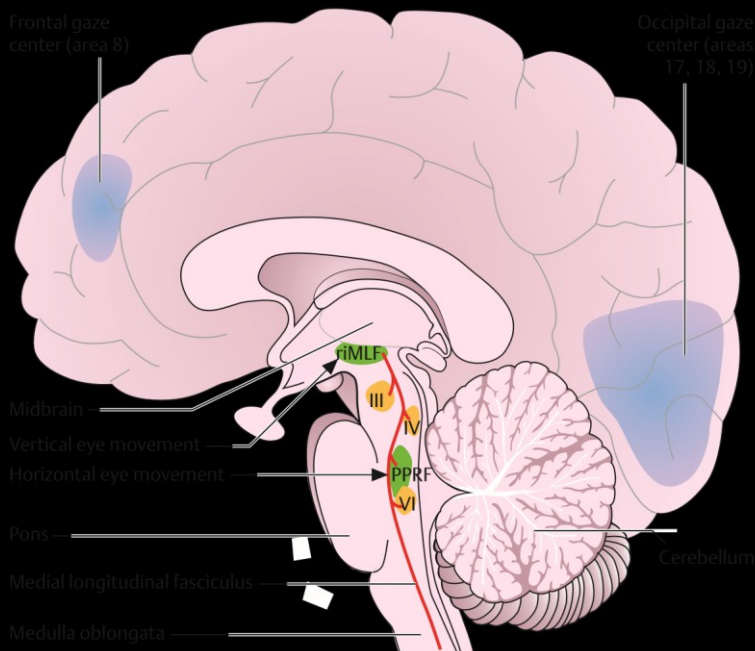

Fig. 17.2 The oculomotor nerve (the third cranial nerve) supplies all of the extraocular muscles except the superior oblique (which is supplied by the trochlear nerve/fourth cranial nerve) and the lateral rectus (supplied by the abducent nerve/sixth cranial nerve). The rostral interstitial nucleus of the medial longitudinal fasciculus (riMLF) is responsible for vertical eye movement and phases of rapid nystagmus. The paramedian pontine reticular formation (PPRF) is responsible for horizontal eye movement.



retina. A different horopter will apply for any given fixation distance. The images of both retinas are therefore identical in normal binocular vision. This phenomenon can be examined by presenting different images to each retina; normally both images will be perceived. This is known as *physiologic diplopia*.

Physiologic diplopia can be demonstrated by placing two vertical pencils in a line along the subject's visual axis, with the second pencil approximately twice as far from the subject as the first. When the subject focuses on one pencil, the other will appear double.

2. *Fusion*. Only where the two retinas convey the same visual impression— i.e., transmit identical images to the brain—will the two retinal images blend into a *single perception*. Impaired fusion can result in double vision (horror fusionis or diplopia).
3. *Stereoscopic vision (perception of depth)*. This is the highest level of quality of binocular vision and is possible only when several conditions are met. For objects to be projected to corresponding or identical points on the ret-

ina, they must lie on the *same* geometric horopter. Objects lying in front of or behind this circle will not be projected to corresponding points but to *noncorresponding or disparate points* on the retina. The result is that these objects are perceived as double images (diplopia). However, objects within a narrow range in front of and behind the horopter are fused into a *single image*. This area is referred to as *Panum's area*. The brain processes noncorresponding retinal images within Panum's area into a single three-dimensional visual perception and does not interpret them as double images (Fig. 17.3b). On the contrary, the brain uses the double images to distinguish differences in depth.

17.2 Concomitant Strabismus

Definition: Concomitant strabismus differs from paralytic strabismus in that the angle of deviation remains the same in every direction of gaze. The deviating eye follows the normal fellow eye at a constant angle.

Epidemiology. Concomitant strabismus occurs almost exclusively in children.

Approximately 5.3–7.4% of children are affected. In 60–70% of cases, the disorder initially manifests itself within the first 2 years of life.

Etiology. Vision at birth is neither focused nor binocular, and both sensorimotor coordination and binocular vision are very unstable during the first few years of life. *Impairments of the sensory or motor systems or central processing of visual perceptions* that occur during this time can disturb the coordination between the eyes and lead to strabismus. However, the causes of concomitant strabismus are often unclear. The following causes have been identified to date:

Genetic factors. Approximately 60% of children with strabismus have a family history of increased incidence.

Uncorrected refractive errors are partially responsible for the occurrence of strabismus. Children with *hyperopia* (farsightedness) tend to have *esotropia*. This is because convergence (simultaneous inward movement of both eyes while focusing on a nearby object) and accommodation (focusing on an object) are coupled. Children with hyperopia have to accommodate *without converging* when gazing into the distance to compensate for their refractive error. However, accommodation always triggers a convergence impulse that can cause esotropia.

Insufficient fusion. This can occur in conjunction with *anisometropia* (unequal refractive power in the two eyes) and *aniseikonia* (unequal retinal image size). It can also occur in *heterophoria* (latent strabismus) after one eye has been covered with a bandage for a prolonged period.

Unilateral visual impairment. Severe nearsightedness, corneal scarring, lens opacities (cataract), macular changes, and retinal disorders can cause secondary strabismus. *Retinal causes* include retinoblastoma, Coats disease, retinopathy of prematurity, retinal detachment, or central retinal scarring in congenital toxoplasmosis.

Any initial examination of a patient with strabismus must invariably include examination of the fundus of both eyes under mydriasis in addition to examination of the anterior segments of the eye.

Other possible causes of concomitant strabismus include:

- Perinatal lesions such as preterm birth and asphyxia
- Cerebral trauma and encephalitis

Pathophysiology. Deviation of the visual axis of the deviating eye causes objects to be projected to noncorresponding points on the retina. One would expect these patients suffer from constant double vision because the left and right eyes supply different information to the brain. However, the central nervous system utilizes two mechanisms to help avoid double vision in concomitant strabismus.

1. **Suppression.** A central inhibiting mechanism suppresses the visual stimuli from the deviating eye. There are two different types of suppression. *Central scotoma.* This visual field defect occurs when the perceived object is projected to the same location on the fovea in both eyes but strabismus causes the eyes to perceive it as separate objects. As this would cause confusion, the object projected on the fovea of the deviating eye is suppressed. *Fixation point scotoma.* This visual field defect occurs when the image perceived by the leading eye is projected to a point *next to the fovea* in the deviating eye. This results in diplopia as the fixation point does not lie within the fovea as it would in physiologic sight. The scotoma occurs at this noncorresponding point next to the fovea to suppress the diplopia.
2. **Sensory adaptation.** In *binocular* vision with the gaze directed straight ahead, the fixation point of the *deviating eye* can fall *beyond* the fovea. This produces *anomalous retinal correspondence* as the fixation point in the nondeviating eye always falls *on* the fovea. This means that the image created in the deviating eye is *not as sharply focused* as the image in the leading eye and is suppressed.

Amblyopia secondary to suppression. Constant suppression in strabismus in the form of a central and fixation scotomas can lead to severe amblyopia, especially in children below the age of six. The prospects for successful treatment decrease with age, and amblyopia becomes irreversible beyond the age of six to eight. Amblyopia only occurs in unilateral strabismus. In alternating strabismus, fixation or deviation alternates between both eyes so that both eyes learn to see. A differential diagnosis must distinguish amblyopia in strabismus from other forms of amblyopia. These are listed in Table 17.2.

Strabismus occurring before the age of six will frequently lead to amblyopia.

Early examination and treatment by an ophthalmologist are crucial.

Tab. 17.2 Forms of amblyopia

Forms of amblyopia	Cause	Treatment
--------------------	-------	-----------

Amblyopia with strabismus	Suppression of the deviating eye	Occlusion therapy
Deprivation amblyopia	Organic disease, such as ptosis or cataract	Early surgery and occlusion therapy in applicable cases
Refractive amblyopia	Different refractive errors	Correction with eyeglasses or contact lenses and occlusion therapy in applicable cases
Bilateral amblyopia	Nystagmus, astigmatism, late correction of refractive errors	None

Forms of Concomitant Strabismus

These essentially include the following forms:

Esotropia. Inward deviation of the visual axis.

Exotropia. Outward deviation of the visual axis.

Hypertropia and hypotropia. Ocular deviation with one eye higher or lower than the other.

Cyclotropia. This refers to the rotation of one eye around its visual axis. An isolated form of strabismus (i.e., one that does not occur in combination with paralytic strabismus), this disorder is extremely rare and therefore will not be discussed in greater detail.

Esotropia

Epidemiology. Esotropia is one of the most commonly encountered forms of strabismus.

Symptoms and diagnostic considerations. There are three forms of esotropia:

1. **Congenital or infantile esotropia.** Strabismus is *present at birth* or develops *within the first 6 months of life*. This form is characterized by a large alternating angle of deviation (Fig. 17.4), lack of binocular vision, latent nystagmus (involuntary oscillation of the eyeballs that only occurs or becomes more pronounced when one eye is covered), intermittent inclination of the head in the direction of the leading eye, and additional hypertropia (primary oblique muscle dysfunction and dissociated vertical deviation).

Another motility disorder that always occurs in infantile strabismus syn-

Alternating esotropia

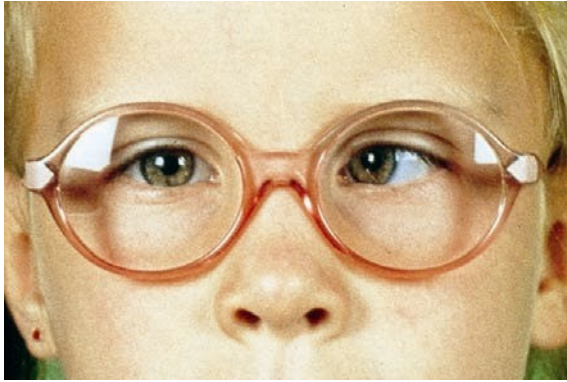

Fig. 17.4 In this form of strabismus, the eyes take the lead alternately.
a Eye position when fixating an object on the right.



b Eye position when fixating an object on the left.

drome is the A or V pattern deviation. This is the result of *anomalous central control*—i.e., anomalies in the pattern of nerve supply to the rectus and oblique muscles.

“*A pattern deviation*” refers to an inward angle of deviation that increases in upgaze and decreases in downgaze.

“*V pattern deviation*” refers to an inward angle of deviation that decreases in upgaze and increases in downgaze.

2. **Acquired strabismus.** Two forms are distinguished:

1. Strabismus begins *at the age of incomplete sensory development*—i.e., between the ages of one and three. Usually the disorder manifests itself at the age of two and leads to sensory adaptation syndromes in the form of *unilateral* strabismus. Amblyopia is usually already present, and correspondence is primarily anomalous.
2. Strabismus becomes manifest *between the ages of three and seven*. This form of *acute late strabismus with normal sensory development* is encountered far less frequently than other forms. As binocular vision is already well developed, affected children cannot immediately suppress the visual images of the deviating eye. As a result, they suffer from *sudden* double vision at the onset of strabismus, which they attempt to suppress by closing one eye. *Immediate* treatment is indicated to preserve binocular vision. This consists of the following steps:
 - Objective examination of refraction with the pupils dilated with atropine or cyclopentolate is performed to determine whether a refractive error is present. Clinical experience has shown that moderate and severe hyperopia will be detected more frequently than in the congenital form.
 - The angle of deviation is precisely determined and corrected with prism eyeglasses.
 - Surgery is indicated if eyeglass correction fails to improve the angle of deviation within a few weeks or the eyes are emmetropic.

Binocular vision is well developed in late strabismus with normal sensory development. Surgery within 3–6 months will allow the patient to maintain or regain stereoscopic vision.

3. **Microstrabismus.** This is defined as unilateral esotropia with a *minimal cosmetic effect*—i.e., an angle of deviation of 5° or less. As a result, microstrabismus is often diagnosed too late—i.e., only at the age of four to six. By that time the resulting amblyopia in the deviating eye may be severe. Another sequela of microstrabismus is anomalous retinal correspondence.

Binocular vision is partially preserved despite anomalous retinal correspondence and amblyopia. However, it can no longer be improved by treatment. For this reason, treatment is limited to occlusion therapy to correct the amblyopia.

Abnormal Accommodative Convergence/Accommodation Ratio

When the accommodative convergence/accommodation ratio is abnormal, the angle of deviation may fluctuate depending on whether the fixated object is far or near. For example in *accommodative esotropia*, the angle of deviation is larger with close objects than with distant objects. The disorder is corrected with bifocal eyeglasses, which in the case of accommodative esotropia have a strong near-field correction (Fig. 17.5). A residual angle of deviation may remain despite the eyeglass correction.

However, the angle of deviation may also improve to the point that the visual axes are parallel with good binocular vision.

Accommodative esotropia in the right eye



Fig. 17.5 a The gaze is directed through the distance portion of bifocals.



b The gaze is directed through the near-field portion of the bifocals. The arrow indicates the dividing line between the distance and near-field portions.

An abnormal accommodative convergence/accommodation ratio will cause fluctuations in ocular deviation in near and distance fixation.

Exotropia

Exotropia (divergent strabismus) is less common than esotropia. As it is usually acquired, the disorder is encountered more often in adults than in children, who more frequently exhibit esotropia. Exotropia less frequently leads to amblyopia because the

strabismus is often alternating. Occasionally what is known as “*panorama vision*” will occur, in which case the patient has an expanded binocular field of vision. The following forms are distinguished: **Intermittent exotropia**. This is the *most common form* of divergent strabismus. In intermittent exotropia, an angle of deviation is present only when the patient gazes into the distance; the patient has normal binocular vision in near fixation (Fig. 17.6). The image from the deviating eye is suppressed in the deviation phase. This form of strabismus can occur as a *latent disorder* in mild cases, meaning that the intermittent exotropia only becomes manifest under certain conditions, such as fatigue.

Secondary exotropia occurs with reduced visual acuity in one eye resulting from disease or trauma.

Consecutive exotropia occurs after esotropia surgery. Often the disorder is overcorrected.

Intermittent exotropia in the right eye

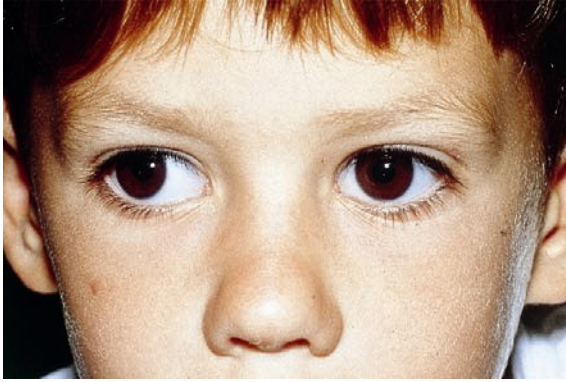
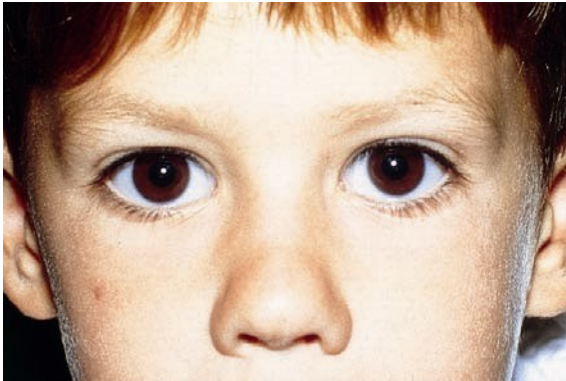
Fig. 17.6 a The right eye deviates in distance fixation.



b No deviation is present in near fixation.

Vertical Deviations (Hypertropia and Hypotropia)

Like A pattern and V pattern deviations, vertical deviations are also typically caused by anomalies in the pattern of nerve supply to the rectus and oblique muscles. Vertical deviations are usually associated with esotropia or exotropia, for example in infantile strabismus. Primary oblique muscle dysfunction and dissociated vertical deviation are common in this setting.

Primary oblique muscle dysfunction is characterized by *upward vertical deviation* of the adducting eye during *horizontal eye movements*.

Dissociated vertical deviation is *alternating upward deviation of the eyes*. The respective nonfixating eye or the eye occluded in the cover test will be elevated.

Diagnosis of Concomitant Strabismus

Evaluating Ocular Alignment with a Focused Light

This is a fundamental examination and is usually the first one performed by the ophthalmologist in patients with suspected concomitant strabismus. The examiner holds the light beneath and close to his or her own eyes and observes the light reflexes on the patient's corneas (*Hirschberg's method*) in near fixation at a distance of 30 cm. Normally, these reflexes are symmetrical. Strabismus is present if the corneal reflex deviates in one eye. The corneal reflexes are symmetrical in normal binocular vision or pseudostrabismus; in esotropia, exotropia, and vertical deviation, they are asymmetrical.

Diagnosis of Infantile Strabismic Amblyopia (Preferential Looking Test)

Strabismus occurs most frequently in the newborn and infants and must also be treated at this age to minimize the risk of visual impairment. As the examiner cannot rely on patient cooperation at this age, examination techniques requiring minimal patient cooperation are necessary. The preferential looking test can be used for early evaluation of vision beginning at the age of 4–6 months. This test cannot reliably detect strabismic amblyopia. However, Teller acuity cards (Fig. 17.7) are sufficiently sensitive for early detection of deficits in the presence of *defects of the entire visual system*.

Procedure. The infant is shown a card (Teller acuity card) with the same background brightness and half of the card striped. The examiner is hidden behind a viewing case that covers him or her from the front and side. An observation pinhole in the middle of the card allows the examiner to observe only the infant's eyes and determine which side of the card the infant is fixating on.

Infants who prefer the striped side have good fixation.

Diagnosis of strabismus in children with the Teller acuity card



Fig. 17.7 The Teller acuity card is located in a viewing case behind which the examiner sits. This permits the examiner to see upon which half of the card the infant fixates. Infants who prefer the striped side have good fixation.

Diagnosis of Unilateral and Alternating Strabismus (Unilateral Cover Test)

A unilateral cover test can distinguish between manifest unilateral strabismus and alternating strabismus. The patient is requested to fixate on a point. The examiner then covers one eye and observes the uncovered eye (Fig. 17.8).

In **unilateral strabismus**, the *same eye always deviates*. When the deviating eye is covered, the uncovered eye (the leading, nondeviating eye) remains focused on the point of fixation. When the nondeviating eye is covered, the uncovered deviating eye has to take the lead. To do so, it will first make a visible adjustment. In esotropia, this adjustment is from medial to lateral; in exotropia, it is from lateral to medial.

In **bilateral alternating strabismus**, *both eyes will alternately fixate and deviate*.

Measuring the Angle of Deviation

Exact measurement of the angle of deviation is crucial to prescribing the proper prism correction to compensate for the angle of deviation and to the corrective surgery that usually follows. A measurement error may lead to undercorrection or overcorrection of the angle of deviation during the operation. *Example*: esotropia of + 15 is corrected by shifting the medial rectus 4.0 mm posteriorly and shortening the lateral rectus 5.0 mm.

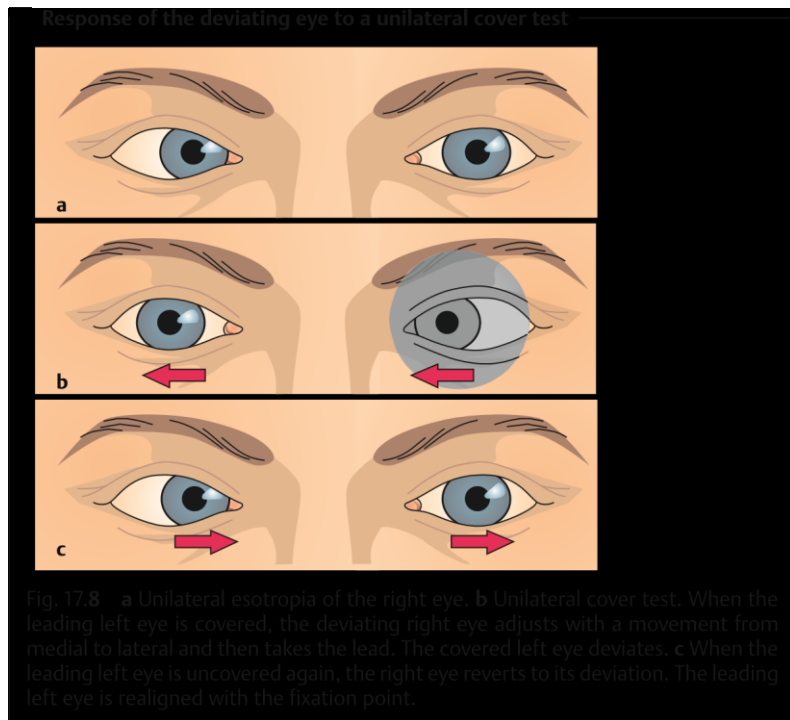


Fig. 17.8 a Unilateral esotropia of the right eye. b Unilateral cover test. When the leading left eye is covered, the deviating right eye adjusts with a movement from medial to lateral and then takes the lead. The covered left eye deviates. c When the leading left eye is uncovered again, the right eye reverts to its deviation. The leading left eye is realigned with the fixation point.

The angle of deviation is measured with a **cover test in combination with the use of prism lenses of various refractive powers**. The patient fixates on a certain point with the *leading eye* at a distance of 5 m or 30 cm, depending on which angle of deviation is to be measured. The examiner places prism lenses of different refractive power before the patient's deviant eye until the eye no longer makes any adjustment. This is the case when the angle of deviation corresponds to the strength of the respective prism and is fully compensated for by that prism. The tip of the prism must always point in the direction of deviation during the examination.

Prism bars simplify the examination. These bars contain a series of prisms of progressively increasing strength arranged one above the other.

Maddox's cross (Fig. 17.9) is a device often used to measure the angle of deviation. A light source mounted in the center of the cross serves as a fixation point. The patient fixates the light source with his or her *leading eye*. The *objective angle of deviation is measured* with prisms as described above. In

Maddox's cross




Fig. 17.9 A Maddox cross is frequently used only as a fixation object when examining children. The patient fixates on the light source in the center. The two scales (a large numbered scale for testing at five meters and a fine scale for testing at one meter) are only relevant for verbal patients asked to describe the location of the area of double vision, for example in paralytic strabismus. (See text for a description of the examination procedure.)

children, often only the objective angle of deviation is measured as this measurement does not require any action on the part of the patient except for fixating a certain point, in this case the light source at center of the cross. In adults, the examiner can ask the patient to describe the *location of the area of double vision* (double vision may be a sequela of paralytic strabismus, which is the most common form encountered in adults). This uses the graduations on the Maddox's cross. The cross has two scales, a large numbered scale for testing at 5 meters and a fine scale for testing at 1 meter (see Fig. 17.9). The patient describes the location of the area of double vision according to a certain number on this scale. The examiner selects the appropriate prism correction according to the patient's description to correct the angle of deviation of the paralyzed eye. This superimposes the images seen by the deviating eye and the nondeviating eye to eliminate the double vision.

The angle of deviation can be measured in prism diopters or degrees. One prism diopter refracts light rays approximately half a degree so that two prism diopters correspond to one degree.

Determining the Type of Fixation

This examination is used to ascertain *which part of the retina of the deviating eye* the image of the fixated point falls on. The patient looks through a special ophthalmoscope and fixates on a small star that is imaged on the fundus of the eye. The examiner observes the fundus.

In **central fixation**, the image of the star falls on the fovea centralis.

In **eccentric fixation**, the image of the star falls on an area of the retina outside the fovea (Fig. 17.10). Usually this point lies between the fovea and the optic disc.

Aside from the type of fixation, one can also estimate potential *visual acuity*.

The greater the distance between where the point of fixation lies and the fovea, the lower the resolving power of the retina and the poorer visual acuity will be. Initial treatment consists of occlusion therapy to shift an eccentric point of fixation onto the fovea centralis.

Testing Binocular Vision

Bagolini test. This test uses flat lenses with fine parallel striations. The striations spread light from a point source into a strip. The lenses are mounted in the examination eyeglasses in such a manner that the strips of light form a diagonal cross in patients with intact binocular vision. The patient is asked to describe the pattern of the strips of light while looking at the point source. Patients who describe a cross have normal simultaneous vision. Patients who see only one diagonal strip of light are suppressing the image received by the respective fellow eye.

Ophthalmoscopic testing of fixation

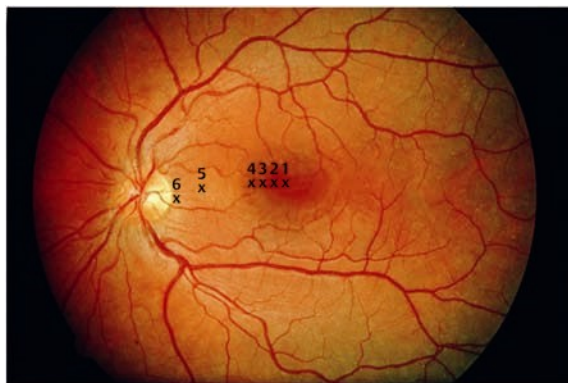


Fig. 17.10
1, foveal fixation; 2, parafoveal fixation; 3, macular fixation; 4, paramacular fixation; 5 and 6, eccentric fixation.

Lang's test. This test can be used to determine depth perception in infants. A card depicts various objects that the child only sees if it can perceive depth.

Treatment of Concomitant Strabismus

Treatment of concomitant strabismus in children. Treatment is generally longterm. The duration of treatment may extend from the first months of life to about the age of 12. Specific treatments and therapeutic success are determined not only by the clinical course but also by the child's overall personality and the parents' ability to cooperate. The whole course of treatment can be divided into **three phases with corresponding interim goals**:

1. The ophthalmologist determines whether the cause of the strabismus can be treated with **eyeglasses** (such as hyperopia).
2. If the strabismus cannot be fully corrected with eyeglasses, the next step in treatment (parallel to prescribing eyeglasses) is to minimize the risk of amblyopia by **occlusion therapy**.
3. Once the occlusion therapy has produced sufficient visual acuity in both eyes, the alignment of one or both eyes is corrected by **surgery**. Late strabismus with normal sensory development is an exception to this rule (for further information, see Surgery). The alignment correction is required for normal binocular vision and has the added benefit of cosmetic improvement.

Treatment of concomitant strabismus in adults. The only purpose of surgery is cosmetic improvement. A functional improvement in binocular vision can no longer be achieved. However, cosmetic improvement with surgery is indicated to avoid or at least reduce psychological suffering.

Eyeglass Prescription

Where the strabismus is due to a cause that can be treated with eyeglasses, then eyeglasses can eliminate at least the accommodative component of the disorder. Often residual strabismus requiring further treatment will remain despite eyeglass correction.

Treatment and Avoidance of Strabismic Amblyopia

Strict occlusion therapy by eye patching or eyeglass occlusion is the most effective method of avoiding or treating strabismic amblyopia. *Primarily the leading eye* is patched.

Eye patching. Severe amblyopia with eccentric fixation requires an eye patch (Fig. 17.11). Eyeglass occlusion (see next section) entails the risk that the child might attempt to circumvent the occlusion of the good eye by looking over the rim of the eyeglasses with the leading eye. This would compromise the

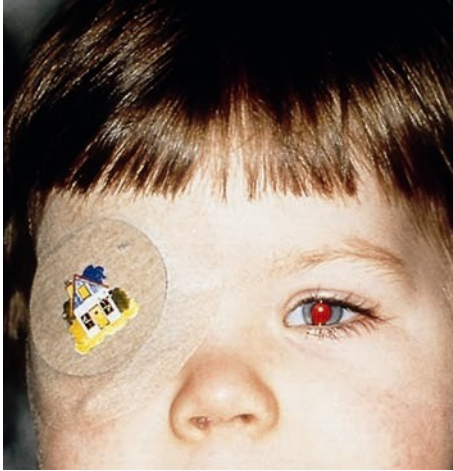Occlusion treatment for amblyopia

Fig. 17.11 The leading eye is patched for several hours or days at a time to improve visual acuity in the deviating amblyopic eye.

effectiveness of occlusion therapy, whose purpose is to train the amblyopic eye.

Eyeglass occlusion. Mild cases of amblyopia can usually be treated successfully by covering the eyeglass lens of the leading eye with an opaque material. In such cases, the child usually does not attempt to look over the rim of the eyeglasses because the deviating eye has sufficient visual acuity.

Procedure. The duration of occlusion therapy must be balanced so as to avoid a loss of visual acuity in the leading eye. The leading eye is occluded for several hours at a time in **mild amblyopia**, and for several days at a time in **severe amblyopia** depending to the patient's age. For example, the nondeviating eye in a 4-year-old patient is patched for 4 days while the deviating eye is left uncovered. Both eyes are then left uncovered for 1 day. This treatment cycle is repeated beginning on the following day.

Amblyopia must be treated in early childhood. The younger the child is, the more favorable and rapid the response to treatment will be. The upper age limit for occlusion therapy is approximately the age of nine. The earlier therapy is initiated, the sooner amblyopia can be eliminated.

The goal of treatment in infantile strabismus is to achieve *alternating strabismus* with *full visual acuity* and *central fixation* in both eyes. Binocular vision is less important in this setting. It is not normally developed anyway in patients who develop strabismus at an early age and cannot be further improved.

17.3 Heterophoria

Surgery

Surgery in infantile strabismus syndrome. Surgery should be postponed until after amblyopia has been successfully treated (see previous section). It is also advisable to wait until the patient has reached a certain age. Adequate followup includes precise measurement of visual acuity at regular intervals in tests that require the patient's cooperation, and such cooperation is difficult to ensure in young patients below the age of four. Surgical correction in a very young patient prior to successful treatment of amblyopia involves a risk that a decrease in visual acuity in one eye may go unnoticed after the strabismus has been corrected. However, the child should undergo surgery prior to entering school so as to avoid the social stigma of strabismus. In such a case, surgery achieves only a *cosmetic correction of strabismus*.

Surgery in late strabismus with normal sensory development. In this case, surgery should be performed as early as possible because the primary goal is to preserve binocular vision, which is necessarily absent in infantile strabismus syndrome.

Procedure. The effect of surgery is less to alter the pull of the extraocular muscles than to alter the position of the eyes at rest. **Esotropia** is corrected by a combined procedure involving a medial rectus recession and a lateral rectus resection. The medial rectus is released because its pull is "too strong" (see Fig. 17.1), whereas the lateral rectus is shortened to increase its pull. The degree of correction depends on the angle of deviation. **Primary oblique muscle dysfunction** is corrected by inferior oblique recession and if necessary by doubling the superior oblique to reinforce it. **Exotropia** is corrected by a lateral rectus recession in combination with a medial rectus resection.

17.3 Heterophoria

Definition: Heterophoria refers to a muscular imbalance between the two eyes that leads to misalignment of the visual axes only under certain conditions (see below). This is in contrast to orthophoria, muscular balance with parallel visual axes. Heterophoria is typified by *initially parallel visual axes* and *full binocular vision*.

The following forms are distinguished, analogously to manifest strabismus:

Esophoria. Latent inward deviation of the visual axis.

Exophoria. Latent outward deviation of the visual axis.

Hyperphoria. Latent upward deviation of one eye.

Hypophoria. Latent downward deviation of one eye.

Cyclophoria. Latent rotation of one eye around its visual axis.

Epidemiology. This disorder occurs in 70–80% of the population. The incidence increases with age.

Etiology and symptoms. Heterophoria does not manifest itself as long as image fusion is unimpaired. Where fusion is impaired as a result of alcohol consumption, stress, fatigue, concussion, or emotional distress, the muscular imbalance can cause intermittent or occasionally permanent strabismus. This is then typically associated with symptoms such as headache, blurred vision, diplopia, and easily fatigued eyes.

Diagnostic considerations. Heterophoria is diagnosed by the **uncover test**. This test simulates the special conditions under which heterophoria becomes manifest (decreased image fusion such as can occur due to extreme fatigue or consumption of alcohol) and eliminates the *impetus to fuse images*. In contrast to the cover test, the uncover test focuses on the *response of the previously covered eye immediately after being uncovered*. Once uncovered, the eye makes a visible adjustment to permit fusion and recover binocular vision.

Treatment. Heterophoria requires treatment only in symptomatic cases. Convergence deficiencies can be improved by **orthoptic exercises**. The patient fixates a small object at eye level, which is slowly moved to a point very close to the eyes. The object may not appear as a double image. **Prism eyeglasses** to compensate for a latent angle of deviation help only temporarily and are controversial because they occasionally result in an increase in heterophoria. **Strabismus surgery** is indicated only when heterophoria deteriorates into clinically manifest strabismus.

17.4 Pseudostrabismus

A broad dorsum of the nose with epicanthal folds through which the nasal aspect of the palpebral fissure appears shortened can often simulate strabismus in small children (Fig. 17.12). The child's eyes appear esotropic

Pseudostrabismus

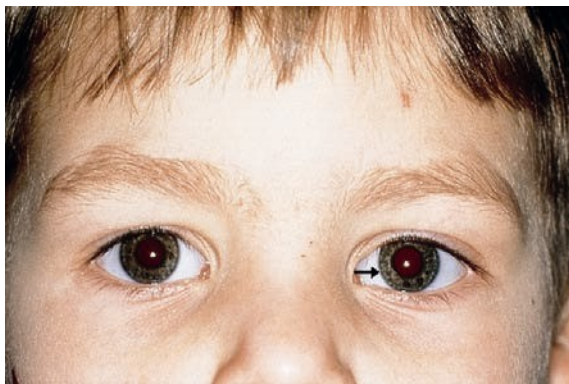

Fig. 17.12 Esotropia of the left eye (arrow) is only simulated by a broad dorsum of the nose. The corneal reflexes demonstrate parallel visual axes.

especially when gazing to the side. Testing with a focused light will reveal that the corneal reflexes are symmetrical, and there will be no eye adjustments in the cover

test. Usually the epicanthal folds will spontaneously disappear during the first few years of life as the dorsum of the nose develops.

17.5 Ophthalmoplegia and Paralytic Strabismus

Definition: Ophthalmoplegia can affect one or more ocular muscles at the same time. The condition may be partial (**paresis**, more common) or complete (**paralysis**, less common). The result is either gaze palsy or strabismus (paralytic strabismus), depending on the cause (see next section) and severity.

Gaze palsy. Impairment or failure of coordinated eye movements. For example, in cyclovertical muscular palsy, the upward and downward gaze movements are impaired or absent.

Paralytic strabismus. Strabismus due to:

- *Isolated* limited motility in *one eye*.
- *Asymmetrical* limited motility in *both eyes*.

The angle of deviation does not remain constant in every direction of gaze (as in concomitant strabismus) but increases in the direction of pull of the paralyzed muscle. This is referred to as an *incomitant* angle of deviation.

Etiology and forms of ocular motility disturbances. Two forms are distinguished.

Congenital ocular motility disturbances may be due to the following causes:

- Prenatal encephalitis
- Aplasia of the ocular muscles
- Birth trauma

Acquired ocular motility disturbances may be due to the following causes:

- Diabetes mellitus
- Multiple sclerosis
- Intracranial tumors
- Arteriosclerosis
- Central ischemia (apoplexy)
- AIDS
- Trauma and other causes

Ocular motility disturbances are either neurogenic, myogenic, or due to mechanical causes.

Neurogenic ocular motility disturbances (see also ophthalmoplegia secondary to cranial nerve lesions, p. 501) are distinguished according to the location of the lesion (Table 17.3):

Lesions of the nerves supplying the ocular muscles. This condition is referred to as an *infranuclear* ocular motility disturbance and is the most common cause of paralytic strabismus. The following nerves may be affected:

- Oculomotor nerve lesions are rare and cause paralysis of several muscles.

- Trochlear nerve lesions are common and cause paralysis of the superior oblique.
- Abducent nerve lesions are common and cause paralysis of the lateral rectus.

Tab. 17.3 Classification of neurogenic ophthalmoplegia according to the location of the lesion (see Table 17.2)

Ocular motility disturbance	Causes	Location of lesion	Effects
Infranuclear ocular motility disturbance	In younger patients: <ul style="list-style-type: none"> – Trauma – Multiplesclerosis – Infectiousdisease In older patients: <ul style="list-style-type: none"> – Vascular disease – Diabetes – Hypertension – Arterio-sclerosis 	Lesion in one of the nerves supplying the ocular muscles: <ul style="list-style-type: none"> – Oculomotornerve – Trochlearnerve – Abducentnerve 	Palsy of one or several extraocular muscles of one or both eyes resulting in strabismus or complete gaze palsy
Nuclear ocular motility disturbance	Multiple sclerosis Myasthenia gravis Meningoencephalitis Syphilis AIDS	Lesion of the ocular muscle nucleus	Palsy of the extraocular muscles of both eyes in varying degrees of severity
Supranuclear ocular motility disturbance Horizontal gaze palsy	Diabetes Apoplexy Tumor Encephalitis Vascular insult Multiple sclerosis	Lesion in the paramedian pontine reticular formation (PPRF; see Fig. 17.2)	All conjugate eye movements on the side of the lesion are impaired Peripheral paresis is often also present Both eyes are affected

Tab. 17.3 Continued

Ocular motility disturbance	Causes	Location of lesion	Effects
Vertical gaze palsy (Parinaud syndrome)	Midbrain infarctions Tumors of the quadrigeminal region such as pineal gland tumors and germinomas	Lesion in the medial longitudinal fasciculus (MLF; see Fig. 17.2)	Isolated upward or downward gaze palsy (common) Combined upward and downward gaze palsy (rare) Moderately wide pupils Impaired accommodation Convergence nystagmus Jerky upper eyelid retraction
Internuclear ocular motility disturbance (INO)	Younger patients with bilateral INO – Multiplesclerosis Older patients with unilateral INO – Brain stem infarction	Lesion in the medial longitudinal fasciculus (MLF; see Fig. 17.2)	Medial nerve palsy or impaired adduction in one eye in side gaze with intact near reflex convergence (see Fig. 17.13) Jerk nystagmus in the abducted eye as long as the palsy persists In <i>bilateral INO</i> , fine vertical nystagmus in the direction of gaze

Lesions of the ocular muscle nuclei. This condition is referred to as a *nuclear* ocular motility disturbance (see Fig. 17.2).

The oculomotor nuclei supply both sides but the nerves are not close together. Therefore, bilateral palsy suggests a nuclear lesion, whereas unilateral palsy suggests a lesion of one nerve.

Lesions of the gaze centers. This condition is referred to as a *supranuclear* ocular motility disturbance (see gaze centers, Fig. 17.2). It very often causes gaze palsy.

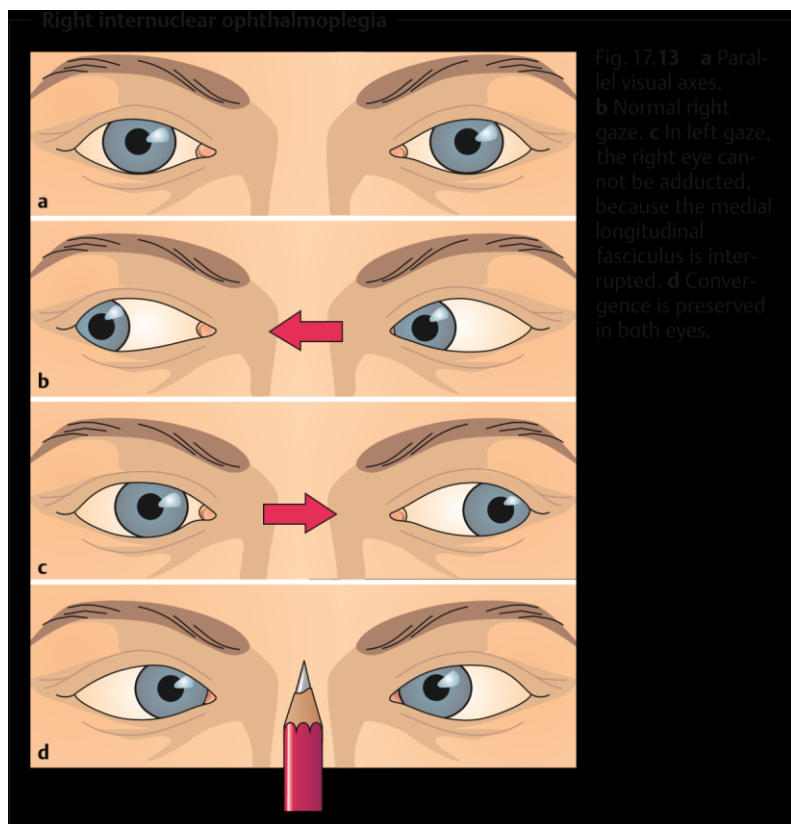
Another possible but rare condition is a *lesion of the fibers connecting two nuclei*.

This condition is referred to as an *internuclear* ocular motility disturbance and may occur as a result of a lesion of the medial longitudinal fasciculus (see Figs. 17.2 and 17.13, internuclear ophthalmoplegia).

Myogenic ocular motility disturbances are rare. These include palsies due to the following causes:

Graves disease is the most common cause of myogenic ocular motility disturbances.

Because it alters the contractility and ductility of the ocular muscles, it can result in significant motility disturbances (see Chapter 15).



Ocular myasthenia gravis is a disorder of neuromuscular transmission characterized by the presence of acetylcholine receptor antibodies. Typical symptoms of ocular

myasthenia gravis include fluctuating weakness that is clearly attributable to any one cranial nerve. The weakness typically increases in severity during the course of the day with fatigue. Important diagnostic aids include the following tests:

- Simpson test. The patient is asked to gaze upward for 1 minute. Gradual drooping of one of the patient's eyelids during the test due to fatigue of the levator palpebrae strongly suggests myasthenia gravis.
- Tensilon (edrophonium chloride) test. This test is used to confirm the diagnosis. The patient is given 1–5 mg of intravenous Tensilon (edrophonium chloride). When myasthenia gravis is present, the paresis will disappear within a few seconds. (Reference should be made to a textbook of neurology for a detailed description of this test.)

Chronic progressive external ophthalmoplegia (CPEO) is usually a bilateral, gradually progressive paralysis of one or more extraocular muscles. In the final stages, it results in complete paralysis of both eyes. Because the paralysis is symmetric the patient does not experience strabismus or double vision.

Ocular myositis is inflammation of one or more extraocular muscles. The pathogenesis is uncertain. Ocular motility is often limited not so much in the direction of pull of the inflamed muscle as in the opposite direction. While there is paresis of the muscle, it is characterized primarily by insufficient ductility. Often additional symptoms are present, such as pain during eye movement.

Mechanical ocular motility disturbances include palsies due to the following causes:

Fractures. In a blow-out fracture for example, the fractured floor of the orbit can impinge the inferior rectus and occasionally the inferior oblique. This can interfere with upward gaze and occasionally produce strabismus. *Hematomas.*

Swelling in the orbit or facial bones, such as can occur in an orbital abscess or tumor.

Symptoms. *Strabismus.* Paralysis of one or more ocular muscles can cause its respective antagonist to dominate. This results in a typical strabismus that allows which muscle is paralyzed to be determined (see Diagnostic considerations). This is readily done especially in abducent or trochlear nerve palsy as the abducent nerve and the trochlear nerve each supply only one extraocular muscle (see Table 17.1).

Example: abducent nerve palsy (Fig. 17.14). A lesion of the abducent nerve paralyzes the lateral rectus so that the eye can no longer be *abducted*. This paralysis also causes the muscle's antagonist, the medial rectus, to dominate. Because this muscle is responsible for *adduction*, the affected eye remains *medially rotated*.

Left abducent nerve palsy

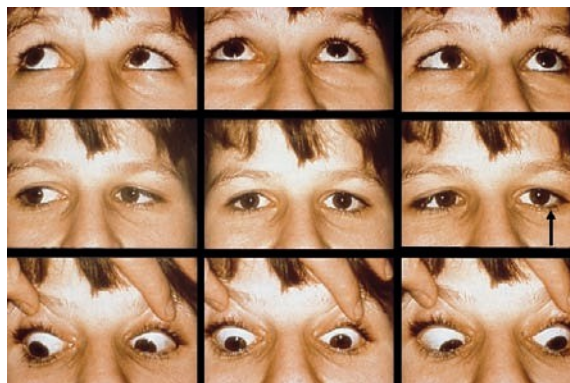

Fig. 17.14 The left eye remains immobile in left gaze (arrow).

Gaze palsy. Symmetrical paralysis of one or more muscles of both eyes limits ocular motility in a certain direction. For example, *vertical gaze palsy* or *Parinaud syndrome*, which primarily occurs in the presence of a pineal gland tumor, involves a lesion of the rostral interstitial nucleus of the medial longitudinal fasciculus (see Fig. 17.2). Paralysis of *all extraocular muscles* leads to complete gaze palsy. Gaze palsy suggests a supranuclear lesion—i.e., a lesion in the gaze centers. Examination by a neurologist is indicated in these cases. **Double vision.** Loss of binocular coordination between the two eyes due to ophthalmoplegia leads to double vision. Normal vision can be expected in patients with only moderate paresis. As the onset of paresis is usually sudden, double vision is the typical symptom that induces patients to consult a physician. Some patients learn to suppress one of the two images within a few hours, days, or weeks. Other patients suffer from persistent double vision. Children usually learn to suppress the image quicker than adults.

Causes. Double vision occurs when the image of the fixated object only falls on the fovea in one eye while falling on a point on the peripheral retina in the fellow eye. As a result, the object is perceived in two different directions and therefore seen double (Fig. 17.15). The double image of the deviating eye is usually somewhat out of focus as the resolving power of the peripheral retina is limited. Despite this, the patient cannot tell which is real and which is a virtual image and has difficulty in reaching to grasp an object.

The *distance between the double images* is greatest in ophthalmoplegia in the original direction of pull of the affected muscle.

Example: trochlear nerve palsy (Fig. 17.16). The superior oblique supplied by the trochlear nerve is primarily an intorter and depressor in adduction (see Table 17.1); it is also an abductor when the gaze is directed straight ahead.

Crossed and uncrossed diplopia

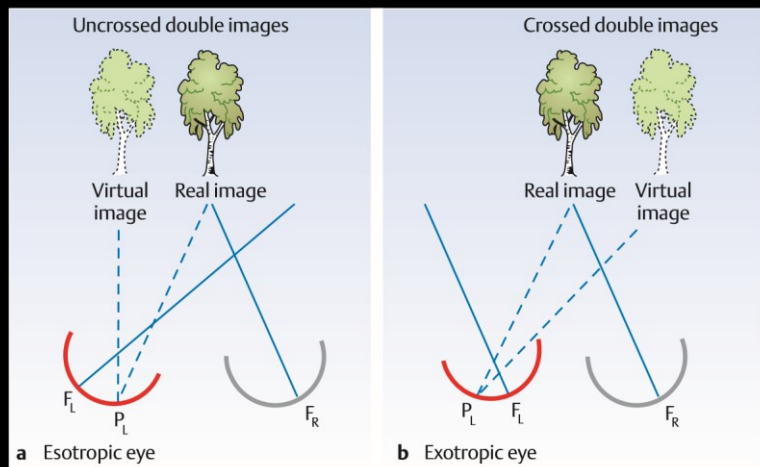


Fig. 17.15 a Esotropia in the left eye (L) with uncrossed images. The right eye (R) is the leading eye, and the left eye is esotropic. The visual image falling on the fovea in the leading eye falls on the nasal retina next to the fovea (P_L) in the esotropic eye and is perceived in space in a temporal location. The object is seen as two uncrossed or homonymous images.

b Exotropia in the left eye (L) with crossed images. The right eye (R) is the leading eye, and the left eye is exotropic. The visual image falling on the fovea in the leading eye falls on the temporal retina next to the fovea (P_L) in the exotropic eye and is perceived in space in a nasal location. The object is seen as two crossed or heteronymous images.

Right trochlear nerve palsy

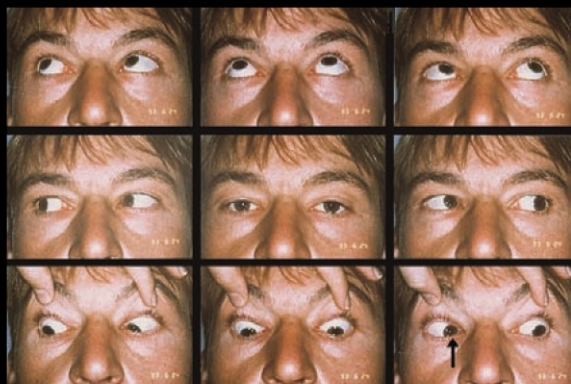

Fig. 17.16 Vertical deviation of the right eye in left downward gaze (arrow).

Therefore, the limited motility and upward deviation of the affected eye is most apparent in depression and intorsion as when reading. The distance between the double images is greatest and the diplopia most irritating in this direction of gaze, which is the main direction of pull of the paralyzed superior oblique.

Compensatory head posture. The patient can avoid diplopia only by attempting to avoid using the paralyzed muscle. This is done by assuming a typical compensatory head posture in which the gaze lies within the binocular visual field; the patient tilts his or her head and turns it toward the shoulder opposite the paralyzed eye.

The *Bielschowsky head tilt test* uses this posture to confirm the diagnosis of trochlear or fourth cranial nerve palsy (Fig. 17.17). In this test, the examiner tilts the patient's head toward the side of the paralyzed eye. If the patient then fixates with the normal eye, the paralyzed eye will deviate. When the

Bielschowsky head tilt test



Fig. 17.17 **a** When the patient tilts her head to the left (toward the normal side), the right eye does not deviate upward when the normal left eye fixates. **b** When the patient tilts her head to the right (toward the side of the paralyzed muscle), the right eye deviates upward when the normal left eye fixates.

patient's head is tilted toward the normal side, there will be no vertical deviation (see Diagnostic considerations for further diagnostic procedures).

Ocular torticollis. The compensatory head posture in trochlear nerve palsy is the most pronounced and typical of all cranial nerve palsies. *Congenital* trochlear nerve palsy can lead to what is known as ocular torticollis.

Incomitant angle of deviation. The angle of deviation in paralytic strabismus also varies with the direction of gaze and is not constant as in concomitant strabismus. Like the distance between the double images, the angle of deviation is greatest when the gaze is directed in the direction of pull of the paralyzed muscle. The angle of deviation can be classified according to which eye fixates:

A *primary angle of deviation* is the angle of deviation when fixating with the normal eye. This angle is small.

A *secondary angle of deviation* is the angle of deviation when fixating with the paralyzed eye. This angle is large.

The secondary angle of deviation is always larger than the primary angle. This is because both the paralyzed muscle and its synergist in the fellow eye receive increased impulses when the paralyzed eye fixates. For example when the right eye fixates in right abducent nerve palsy, the left medial rectus will receive increased impulses. This increases the angle of deviation.

Cranial nerve palsies. The commonest palsies are those resulting from cranial nerve lesions. Therefore, this section will be devoted to examining these palsies in greater detail than the other motility disturbances listed under Etiology. It becomes evident from the examples of causes listed here that a diagnosis of ophthalmoplegia will always require further diagnostic procedures (often by a neurologist) to confirm or exclude the presence of a tumor or a certain underlying disorder such as diabetes mellitus.

Abducent nerve palsy.

Causes. The main causes of this relatively common palsy include vascular disease (diabetes mellitus, hypertension, or arteriosclerosis) and intracerebral tumors. Often a tumor will cause increased cerebrospinal fluid pressure, which particularly affects the abducent nerve because of its long course along the base of the skull. In *children*, these transient isolated abducent nerve palsies can occur in infectious diseases, febrile disorders, or secondary to inoculations.

Effects. The lateral rectus is paralyzed, causing its antagonist, the medial rectus, to dominate. Abduction is impaired or absent altogether, and the affected eye remains medially rotated (see Fig. 17.14). Horizontal homonymous (uncrossed) diplopia is present (see Fig. 17.15). The images are farthest apart in abduction.

Example: right abducent nerve palsy.

Compensatory head posture with right tilt

Esotropia when the gaze is directed straight ahead

Largest angle of deviation and distance between images in right gaze

No angle of deviation or diplopia in left gaze

Retraction syndrome (special form of abducent nerve palsy).

Causes. Retraction syndrome is a congenital unilateral motility disturbance resulting from a lesion to the abducent nerve acquired during pregnancy. **Effects.** The lateral rectus is no longer supplied by the abducent nerve but by fibers from the oculomotor nerve that belong to the medial rectus. This has several consequences. As in abducent nerve palsy, *abduction is limited* and slight esotropia is usually present. In contrast to abducent nerve palsy, the globe recedes into the orbital cavity when *adduction is attempted*. This narrows the palpebral fissure. This *retraction of the globe* in attempted adduction results from the simultaneous outward and inward pull of two antagonists on the globe because they are supplied by the same nerve (oculomotor nerve).

Trochlear nerve palsy.

Causes. The commonest cause is trauma; less common causes include vascular disease (diabetes mellitus, hypertension, and arteriosclerosis). Trochlear nerve palsy is a relatively common phenomenon.

Effects. The superior oblique is primarily an intorter and a depressor in adduction. This results in upward vertical deviation of the paralyzed eye in adduction and vertical strabismus (see Fig. 17.16). Patients experience vertical diplopia; the images are farthest apart in depression and intorsion. Compensatory head posture is discussed in the section on symptoms. Diplopia is absent in elevation.

Oculomotor nerve palsy.

Causes. The causes of (rare) complete oculomotor nerve palsy are mainly diseases of the vascular system e.g., aneurysms and other vascular processes.

Effects.

Complete oculomotor nerve palsy. *Every intraocular and almost every extraocular muscle* is affected, with loss of both accommodation and pupillary light reaction.

The failure of the parasympathetic fibers in the oculomotor nerve produces mydriasis. Ptosis is present because the levator palpebrae is also paralyzed. The paralyzed eye deviates in extorsion and depression as the function of the lateral rectus and superior oblique is preserved. Patients do not experience diplopia because the ptotic eyelid covers the pupil.

Partial oculomotor nerve palsy:

- External oculomotor nerve palsy (isolated paralysis of the *extraocular* muscles supplied by the oculomotor nerve; see Fig. 17.1) is characterized by deviation in extorsion and depression. If the ptotic eyelid does not cover the pupil, the patient will experience diplopia.
- Internal oculomotor nerve palsy is isolated paralysis of the *intraocular* muscles supplied by the oculomotor nerve. This is characterized by loss of accommodation (due to paralysis of the ciliary muscle) and mydriasis (due to paralysis of the sphincter pupillae). Patients do not experience diplopia as there is no strabismic deviation (see also Tonic pupil and Adie syndrome, p. 233).

Combined cranial nerve palsies. The third, fourth, and sixth cranial nerves can be simultaneously affected, for example in a lesion at the apex of the orbital cavity or in the cavernous sinus. A clinical suspicion of combined lesion can be supported by a

corneal sensitivity test as the ophthalmic division of the trigeminal nerve, which provides sensory supply to the cornea, runs through the cavernous sinus. Where there is loss of corneal sensitivity, whether the lesion is located in the cavernous sinus must be determined.

Diagnosis of ophthalmoplegia. Examination of the nine diagnostic positions of gaze (see Chapter 1). The patient is asked to follow the movements of the examiner's finger or a pencil with his or her eyes only. The six cardinal directions of gaze (right, upper right, lower right, left, upper left, lower left) provide the most information; upward and downward movements are performed with several muscles and therefore do not allow precise identification of the action of a specific muscle. Immobility of one eye when the patient attempts a certain movement suggests involvement of the muscle responsible for that movement.

The **Bielschowsky head tilt test** is performed only where trochlear nerve palsy is suspected (see Symptoms).

Measuring the angle of deviation. Measuring this angle in the nine diagnostic directions of gaze provides information about the severity of the palsy, which is important for surgical correction. This is done using a Harms tangent table (Fig. 17.18). In addition to the vertical and horizontal graduations of Maddox's cross, the Harms table also has diagonals. These diagonals permit the examiner to measure the angle of deviation even in patients with a compensatory head tilt, such as can occur in trochlear nerve palsy.

Differential diagnosis. Table 17.4 shows the most important differences between paralytic strabismus and concomitant strabismus.

Treatment of ophthalmoplegia. Surgery for paralytic strabismus should be postponed for at least 1 year to allow for possible spontaneous remission. Preoperative diagnostic studies to determine the exact cause are indicated to permit treatment of a possible underlying disorder, such as diabetes mellitus. Severe diplopia can be managed temporarily by patching the eyes alternately until surgery. Alternatively, an eyeglass lens with a prism correction for the paralyzed eye can be used to compensate for the angle of deviation and eliminate diplopia. Eyeglasses with nonrefracting lenses can be used for patients

Measuring the angle of deviation with the Harms tangent table



Fig. 17.18 The patient sits at a distance of 2.5 meters from the table and fixates on the light in the center. The examiner evaluates the nine diagnostic positions of gaze. The grid provides the coordinates for measuring the horizontal and vertical deviations, and the diagonals are used to measure the angle of deviation at a head tilt of 45° (Bielschowsky head tilt

test in trochlear nerve palsy). A small projector with positioning cross hairs mounted on the patient's forehead permits the examiner to determine the patient's head tilt with a relatively high degree of precision. The tilt of the image (paralytic strabismus often leads to image tilting) can also be measured with the Harms tangent table. To do so, the fixation light in the center of the table is spread into a band of light.

who do not normally wear corrective lenses. Prism lenses may not always be able to correct extreme strabismus. If surgery is indicated, care must be taken to correctly *gauge the angle of deviation*. The goal of surgery is to eliminate diplopia in the normal visual field—i.e., with head erect, in both near and distance vision. It will not be possible to surgically eliminate diplopia in *every visual field*.

Procedure. The *antagonist of the respective paralyzed muscle* can be *weakened* by recession. Resecting or doubling the paralyzed muscle can additionally reduce the angle of deviation.

Strabismus surgery for ophthalmoplegia is possible only after a one-year regeneration period.

17.6 Nystagmus

Tab. 17.4 Differential diagnosis between concomitant strabismus and paralytic strabismus

Differential criterion	Concomitant strabismus	Paralytic strabismus
Onset	At an early age, initially only periodically	At any age, sudden onset
Cause	Hereditary, uncorrected refractive error, perinatal injury	Disease of or injury to ocular muscles, supplying nerves, or nuclei
Diplopia	None; image suppressed (except in late strabismus with normal sensory development)	Diplopia is present
Compensatory head posture	None	Constant
Depth perception	Not present	Only present when patient assumes compensatory head posture (see Symptoms)
Visual acuity	Usually unilaterally reduced visual acuity	No change in visual acuity
Angle of deviation	Constant in every direction of gaze	Variable, increasing in the direction of pull of the paralyzed muscle

17.6 Nystagmus

Definition: Nystagmus refers to bilateral involuntary rhythmic oscillation of the eyes, which can be jerky or pendular (jerk nystagmus and pendular nystagmus). The various forms of nystagmus are listed in Table 17.5.

Etiology. The etiology and pathogenesis of nystagmus are still unclear. Nystagmus is also a *physiological phenomenon* that can be elicited by gazing at rapidly moving objects (e.g., when looking out of the window of a moving train; this is known as optokinetic nystagmus, a form of jerk nystagmus).

Treatment. Where nystagmus can be reduced by convergence, prisms with an outward-facing base may be prescribed. In special cases, such as when the patient assumes a compensatory head posture to control the nystagmus, Kestenbaum's operation may be indicated. This procedure involves parallel shifts in the horizontal

extraocular muscles so as to weaken the muscles that are contracted in the compensatory posture and strengthen those that are relaxed in this posture.

Tab. 17.5 Forms of nystagmus

Forms	Onset	Characteristics	Type of nystagmus
Ocular nystagmus	Congenital or acquired in early childhood	Occurs in organic disorders of both eyes, such as albinism, cataract, color blindness, vitreous opacification, or macular scarring Significant visual impairment Secondary strabismus may also be present	Pendular nystagmus
Congenital nystagmus	Congenital or acquired in early childhood (at the age of 3 months)	Nystagmus is not curbed by fixation but exacerbated Oscillation is usually horizontal Intensity varies with the direction of gaze (usually less in near fixation than in distance fixation)	Constant alternation between pendular and jerk nystagmus
Latent nystagmus	Congenital or acquired in early childhood	Always associated with congenital strabismus Manifested only by spontaneously uncovering one eye when fixation changes Direction of oscillation changes when fixation changes (see right column)	Right oscillating nystagmus in right fixation Left oscillating nystagmus in left fixation Nystagmus occurs as jerk nystagmus
Fixation nystagmus	Acquired	Occurs in disorders of the brain stem or cerebellum due to vascular insults, multiple sclerosis, trauma, or tumors	Pendular or other abnormal form of oscillation