

## 1 úrazy oka

### **Mechanické**

Tupá

Perforující

S cizím tělískem

Magnetické- sideróza

Kovové nemagnetické- meď, mosaz- chalkóza

nekovové – plasty, sklo, dřevo

sympatická oftalmie

### **Chemické**

**Alkálie**

**kyseliny**

**Záření(infračervené, UV, rtg, alfa, částice gama)**

## ◆ Anterior Segment Trauma

### **Eyelid Laceration**

Blunt and penetrating facial trauma may result in eyelid laceration. The laceration may be extramarginal, may involve the eyelid margin, or may cause tissue loss. Eyelid trauma is often associated with vehicle accidents, falls, sport-related traumas, and assaults. Eyelid laceration is more common in young males due to occupational and recreational preferences. Proper management is necessary to preserve correct lid dynamics and cosmetic appearance.

### ◆Presentation

Patients usually complain of mild pain and epiphora. Displacement or abnormalities of the canthal angles may indicate canthal ligament injury. Lacerations of the deep head of the medial canthal ligament may cause telecanthus. Hyphema, other ocular adnexa traumas, and orbital fractures may be present (Fig. 1.1).

### ◆Management

The mechanism of injury should be investigated first, followed by a complete ocular examination to rule out injuries to the globe. If no globe rupture is present, lids should be everted, palpated, and examined for foreign bodies. The laceration should be carefully examined to determine depth, extension, and margin involvement. Photography of the lesions is recommended. Canalicular involvement and injury to the levator and the supraorbital nerve should be excluded. A computed tomographic scan should be obtained when globe rupture and foreign bodies are

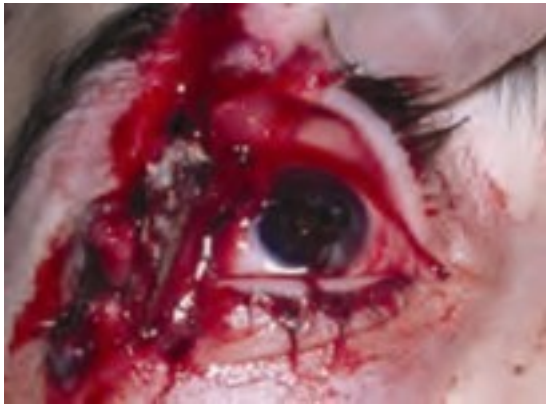

Fig. 1.1 Eyelid laceration involving the eyelid margin with loss of tissue.

1

suspected. Tetanus prophylaxis and baseline serology for human immunodeficiency virus (HIV) and hepatotropic viruses should be considered. Surgical repair should be performed under local anesthesia, with good lighting and magnification. After adequate anesthesia, wound cleaning, and decontamination, the laceration should be repaired using Vicryl (Ethicon, Inc., Somerville, NJ) or silk 6-0 suture. Posterior tendon repair and canalicular repair should precede lid suturing. Eyelid margin laceration should be sutured with a vertical mattress technique. Finally, antibiotic ointment should be applied to the wound, and systemic antibiotic therapy should be considered if contamination is suspected. Possible complications include posttraumatic upper lid ptosis and corneal ulceration due to corneal exposure or an exposed suture.

## Lacrimal System Trauma

The lacrimal drainage apparatus consists of the lacrimal puncta on the upper lid and the lower lid, the canaliculi, the common canaliculus, the lacrimal sac, and the nasolacrimal duct. From their origin at the puncta, the canaliculi run medially toward the internal angulus of the eye, where they join to form the common lacrimal canaliculus that opens in the lacrimal sac. Canalicular lacerations are the most frequent cause of injury to the lacrimal system and occur in up to 16% of all eyelid injuries. Common causes of canalicular laceration include vehicle accidents, falls, assaults, sharp trauma, and animal bites. Successful management of these injuries depends on prompt intervention and good

surgical technique to minimize the incidence of posttraumatic epiphora due to scarring and stenosis in any tract of the lacrimal drainage system.

### ◆Presentation

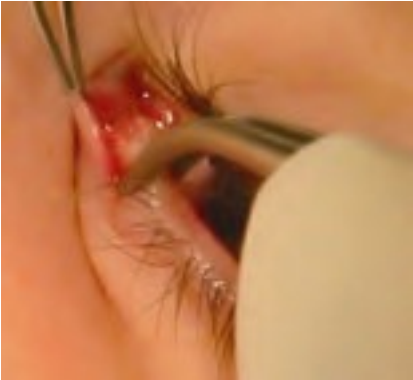Patients usually present with a history of trauma and mild pain. The lacrimal drainage system lesion may be obvious or occult. The use of methylene blue or fluorescein-tinged water irrigation through the puncta and subsequent visualization of the dye in the wound may be helpful in identifying the cut end (Fig. 1.2A,B).

### ◆Differential Diagnosis

Lid laceration not involving the lacrimal drainage system, preexisting epiphora

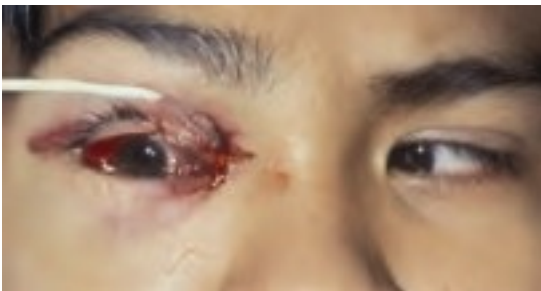### ◆Management

The mechanism of injury should be investigated, and a complete ophthalmic examination should be performed. The injury to the lacrimal drainage system can be proven with Bowman probe insertion in the puncta or by irrigation with fluorescein-stained saline solution. Tetanus prophylaxis should be considered. Surgical repair should provide accurate approximation of the severed ends to promote mucosal healing. Most surgeons use silicone intubations of the system, followed by apposition of the pericanalicular tissues with microscopically assisted 7–0 suture. The medial canthal ligament is often injured from the trauma and must be repaired to restore lid function and anatomy. The success rate with silicone intubation and microscopic reanastomosis ranges from 86 to 95%.



A

**Fig. 1.2 (A)** Lacrimal system trauma with laceration of the inferior canaliculus. **(B)** Canalicular injury with eyelid laceration.



B

## Subconjunctival Hemorrhage

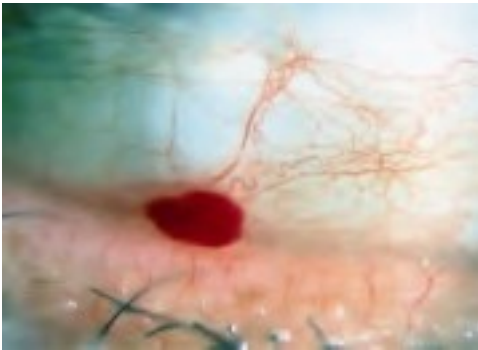
Subconjunctival hemorrhage follows the bleeding of conjunctival and episcleral blood vessels into the subconjunctival space. It is usually associated with minor trauma or arises spontaneously with increased venous pressure due to violent Valsalva maneuvers. Less frequently subconjunctival hemorrhage can be associated with severe hypertension and coagulopathies. Various drugs, such as warfarin, nonsteroidal antiinflammatory drugs (NSAIDs), and steroids can make conjunctival vessels more susceptible. It is also a normal sequela of ocular surgery.

### ◆Presentation

A bright red and flat collection of blood is seen underneath the conjunctiva; it is usually sharply demarcated at the limbus and surrounded by normal conjunctiva. This condition is usually asymptomatic. If pain, photophobia, or diminished visual acuity occurs, a more serious pathological condition should be considered (Fig. 1.3).

### ◆Differential Diagnosis

The differential diagnosis of subconjunctival hemorrhage includes other causes of red eye, such as conjunctivitis, episcleritis, iritis, acute glaucoma, and dendritic ulcer. Kaposi sarcoma, or other conjunctival neoplasms with secondary hemorrhage should be taken into consideration.



**Fig. 1.3** Subconjunctival hemorrhage. A bright red and flat collection of blood is seen underneath the conjunctiva; it is sharply demarcated and surrounded by normal conjunctiva.

### ◆Management

Blood pressure should be checked in all patients, and if there is a history of recurrent, unprovoked subconjunctival hemorrhages, a bleeding diathesis should be investigated. The uncomplicated hemorrhage, not associated with any significant trauma or bleeding diathesis, is typically a self-limiting condition that requires only reassurance. Cold compresses for 24 hours and artificial tears can be used for mild irritation. Hemorrhage clears spontaneously in 1 to 2 weeks. Elective use of NSAIDs is typically discouraged.

## Conjunctival Laceration

The conjunctiva is a strong and resilient tissue, but it may be lacerated in cases of ocular trauma with pointed and sharp objects, such as broken glass. It may be isolated or part of more severe intraocular injuries.

### ◆ Presentation

Patients usually present with a history of ocular trauma and complain of red eye, mild pain, and foreign body sensation. Slit-lamp examination reveals a conjunctival surface defect. The edges are usually retracted and rolled up, disclosing the underlying white sclera. Subconjunctival hemorrhages and chemosis are often present. Fluorescein staining under the cobalt filter will enhance the visualization of the defect (Fig. 1.4).

### ◆ Management

An accurate history of ocular trauma and a complete ophthalmic examination are necessary: topical anesthesia may be used to accurately investigate the underlying sclera in search of injuries and subconjunctival foreign bodies. However, patients under topical anesthesia may lose symptoms associated with the presence of a foreign body. A Seidel test should be performed to rule out a ruptured globe.

B-scan ultrasonography and a computed tomographic scan of the orbit may be useful to exclude intraocular or intraorbital foreign bodies.

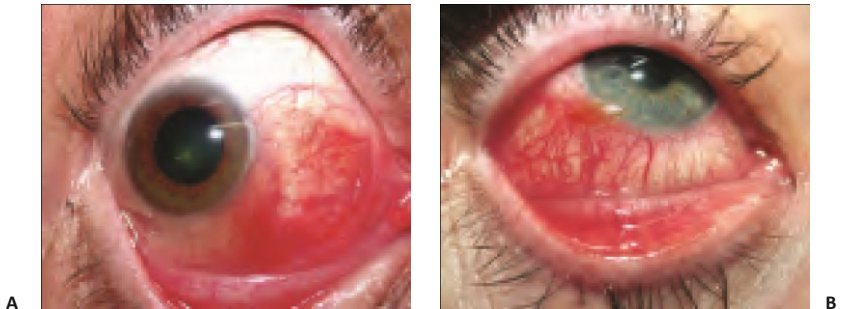


Fig. 1.4 Conjunctival laceration and foreign body. (Courtesy Pablo Gili M.D.)

In the absence of a ruptured globe or perforating injuries, small conjunctival lacerations heal without surgical repair. Large lacerations (e.g., greater than 1.0 to 1.5 cm) may be sutured (e.g., Vicryl 8-0). Pressure patching for 24 hours and prophylactic antibiotic ointment (e.g., gentamicin) three times a day for 4 to 7 days should suffice.

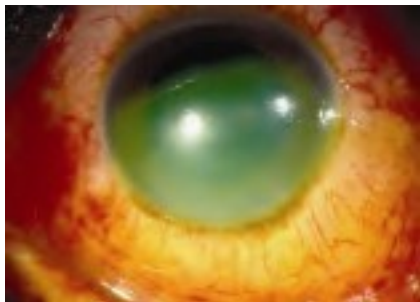
## Chemical Exposure

Chemical burns constitute a true ocular emergency and should be treated promptly. Chemical burns may be caused by either acidic or alkaline agents. Acid burns cause coagulative necrosis of the corneal epithelium. The formation of a coagulum limits penetration and corneal damage. Hydrofluoric acid is an exception because it causes liquefactive necrosis. Common acids causing ocular burns include sulfurous acid (present in some bleaches), sulfuric acid (present in car batteries), hydrochloric acid (used in swimming pools), nitric acid, chromic acid, and acetic acid. Alkali burns are typically more severe because alkaline agents are lipophilic

and penetrate more rapidly than acids. They combine with cell membrane lipids and cause saponification of cell membranes, cell death, and disruption of the extracellular matrix. The release of collagenases and proteases after the injury leads to corneoscleral melting. Alkali substances that commonly cause ocular burns contain sodium hydroxide (caustic soda), ammonium hydroxide (fertilizer production), potassium hydroxide, and calcium hydroxide. Chemical burns are often bilateral and are frequently due to industrial and occupational exposures.

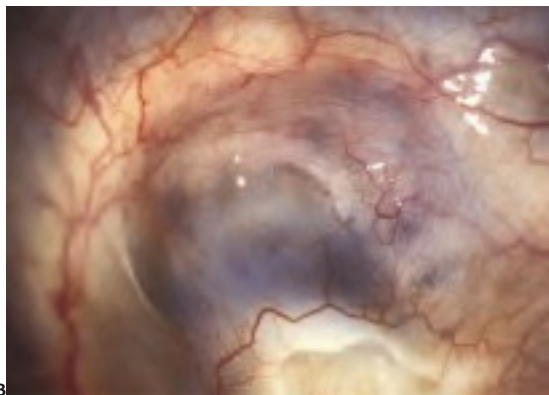
### ◆Presentation

The diagnosis of ocular chemical burn is typically based on history of contact with alkaline or acid agents. The symptoms usually include pain, photophobia, blepharospasm, reduced vision, and excessive tearing. If the burn is mild or moderate, the conjunctiva is hyperemic. Focal conjunctival chemosis, hyperemia, or hemorrhages can be present. Eyelid edema and first- to second-degree periocular skin burns can be seen. Corneal findings may range from superficial punctate keratitis (SPK) to focal epithelial defects. In severe conditions white areas of conjunctival and limbal ischemia can be seen. Corneal findings usually consist of total epithelial loss, stromal hazing, and, in some cases, complete opacification. Other signs include anterior chamber reaction and second- or third-degree periocular burns. (Fig. 1.5A,B).



A

**Fig. 1.5 (A)** A moderate chemical injury with 6 hours of limbal blanching, a large epithelial defect, and stromal haze. **(B)** The sequelae of a severe chemical injury demonstrating a scarred and vascularized cornea. This eye underwent a permanent keratoprosthesis. (Courtesy of Christopher Rapuano)



B

### ◆Differential Diagnosis

Thermal burns, ultraviolet (UV) keratitis, ulcerative keratitis

### ◆Management

Chemical burns are considered a true ophthalmologic emergency and require immediate care. The first priority is immediate and copious irrigation with sterile irrigating solution or saline solution. If these solutions are not available, tap water can be used. Irrigation should be continued until neutral pH is reached. Insertion of a lid speculum and topical anesthetic prior to irrigation facilitates the procedure. After irrigation a good history with an exact identification of the chemical agent should be obtained. Slit-lamp examination with fluorescein staining should be performed. Eyelids should be everted to search for residual chemicals and foreign bodies. The goal of therapy is to reduce pain, inflammation, and risk of infection. Thus cycloplegic agents (avoid phenylephrine because it is a vasoconstrictor), oral analgesics (avoid repeated applications of topical anesthetics because they can delay epithelial healing), and ophthalmic antibiotics (avoid aminoglycoside antibiotics because they impair epithelial healing) should be administered. The use of topical steroids remains controversial. They can limit inflammation-mediated ocular damage, but they retard wound healing and predispose to infection. Severe burns can be managed with adjunctive therapy: ocular hypotensive medications if the intraocular pressure is elevated, collagenase inhibitors if any melting of the cornea occurs, lysis of conjunctival adhesions if present, and active surgical removal of necrotic tissue. Long-term complications of chemical burns include perforation, scarring, corneal neovascularization, symblepharon, glaucoma, cataracts, and retinal damage. Ultimate prognosis is related to the degree of limbus ischemia, the depth of the corneal injury, and the presence of symblepharon.

## Corneal Abrasion

Corneal abrasions represent one of the most common ophthalmic problems seen in emergency departments. A corneal abrasion is the disruption of the protective epithelium covering the cornea; it may be caused by direct or tangential impact. Common causes are scratches from fingernails, animal paws, tree branches, or a paper cut. Another common cause is contact lens overwear. A large number of corneal abrasions are preventable. High-risk workers (e.g., woodworkers, metal workers) and players of certain sports (e.g., hockey, racquetball, cross-country skiing, mountain biking) should wear appropriate eye protection.

### ◆Presentation

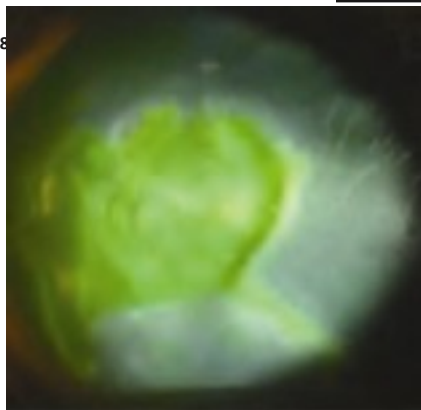
The patient's history typically includes eye trauma and subsequent acute pain. Presenting symptoms usually include severe pain, excessive tearing, photophobia, foreign body sensation, blepharospasm, and blurred vision. At slit-lamp examination diffuse corneal edema, epithelial disruption, and circumcorneal injection can be seen (**Fig. 1.6**).

### ◆Differential Diagnosis

Acute angle glaucoma, herpes ulcers and other corneal ulcers, corneal foreign body, and corneal perforation

### ◆Management

Visual acuity should be assessed because it may be significantly reduced if the abrasion is on the optic axis. Upper and lower tarsal conjunctiva should be inspected carefully for foreign bodies. If examination is limited by excessive pain, one drop of topical anesthetic could be administered for diagnostic purposes. At slit-lamp ex-



**Fig. 1.6** Corneal defect stained with fluorescein. (Courtesy of Nibaran Gangopadhyay)

amination the visualization of the corneal abrasion can be improved using fluorescein staining under blue-cobalt filtered light. The abrasion should be documented in size, shape, depth, and localization. A Seidel test should be performed to rule out possible full-thickness injury. Intraocular pressure should be measured in both eyes, and the anterior chamber should be carefully investigated for evidence of iritis. Prevention of infection is a key point in corneal abrasion treatment. An antibiotic ointment should be used; consider antipseudomonas coverage for abrasions due to contact lens overwear. Patients with contact lens-associated corneal abrasion or a wound that is caused by vegetable matter should have antipseudomonas coverage (e.g., tobramycin, ciprofloxacin, gentamicin, ofloxacin). Oral analgesics are often necessary owing to the severity of pain. Topical NSAIDs (e.g., diclofenac, ketorolac) may be useful in reducing pain. Patients using topical NSAIDs may take fewer oral analgesics. Never provide topical anesthetics to take home because they can delay wound healing. One drop of topical cycloplegic can be used if the patient is really photophobic. This relieves ciliary spasm, reduces pain, and improves comfort. Pressure patching is no longer recommended. It should be used for 6 hours only if pain is severe. Given the risk of infection, do not patch if the lesion is caused by vegetable matter or contact lenses. Healing of small abrasions is expected within 24 to 48 hours. Deep and large abrasions may require 5 to 7 days to heal. Most corneal abrasions (small and peripheral) do not need any follow-up. However, contact lens wearers or patients with a central or large abrasion should be reevaluated in 24 hours and every 2 to 3 days until abrasion clears. Patients should return sooner if symptoms worsen.

## Corneal Foreign Body

A corneal foreign body is a common cause of visits for ophthalmic emergencies. It frequently occurs when one is grinding and drilling steel without wearing protective goggles.

### ◆Presentation

The patient's history usually includes an ocular trauma. The more frequent symptoms are mild or moderate pain, foreign body sensation, excessive tearing, photophobia, and blurred vision. At slit-lamp examination one or more objects can be seen lodged superficially or embedded within the cornea. Metallic foreign bodies may leave rust rings in the surrounding cornea. Other signs include a circumlimbal conjunctival injection, eyelid edema, and a sterile infiltrate surrounding the foreign body (Fig. 1.7).



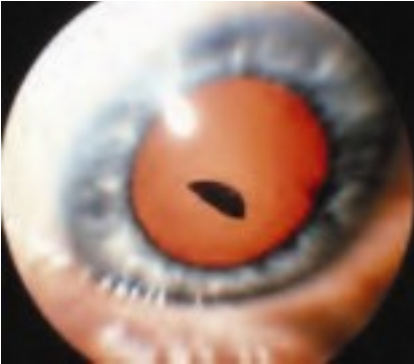

Fig. 1.7 Corneal foreign body.

### ◆ Differential Diagnosis

Corneal abrasion, intraocular foreign body, bacterial or fungal keratitis

### ◆ Management

After having assessed visual acuity, it is important to rule out a possible perforating injury. This can be done using a Seidel test (instill fluorescein to inspect for aqueous leakage), measuring intraocular pressure, and paying attention to anterior chamber reaction. Consider a b-scan ultrasound and an orbital computed tomographic scan to exclude intraocular and intraorbital foreign bodies. If there is no perforation, the object can be removed under topical anesthesia (e.g., proparacaine 0.5%) using a foreign body spud or a 25-gauge needle. This operation can be facilitated by sterile irrigation. The rust ring can be removed using an ophthalmic drill. These procedures should be performed at slit lamp by well-trained and experienced physicians. Before and after the removal, antibiotic drops should be applied until healing. A topical cycloplegic can be used to reduce photophobia and pain. Patients should be reevaluated every 2 to 3 days until the wound is healed and the infiltrate resolved.

## Corneal Laceration

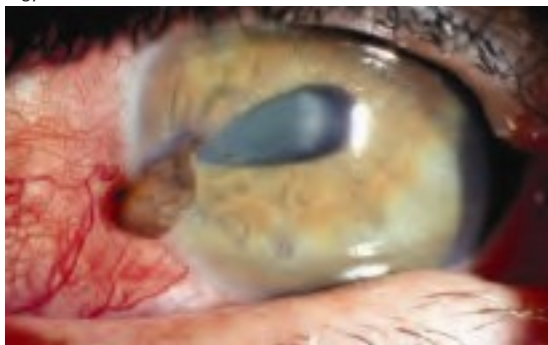The laceration can be partial thickness or full thickness.

### ◆ Presentation

In partial-thickness laceration, the anterior chamber is not entered, and, therefore, the cornea is not perforated. If the Seidel test is positive, a full-thickness laceration is present. In full-thickness laceration the patient presents with tearing, pain, and loss of vision. Associated findings include: shallow anterior chamber, anterior synechiae, corneal opacity with endothelial dysfunction, or cataract. Intraocular pressure may be very low (Fig. 1.8).

### ◆ Management

A history and complete ophthalmic examination are required to ascertain the diagnosis. While managing a partial-thickness laceration, a cycloplegic (e.g., scopol-



**Fig. 1.8** Penetrating corneal laceration with iris prolapse.  
(Courtesy Pablo Gili M.D.)

amine 0.25%) and an antibiotic (e.g., frequent polymyxin B/bacitracin ointment such as polysporin) or fluoroquinolone drops, depending on the nature of the wound, are started immediately.

When a moderate to deep corneal laceration is accompanied by wound gape, it is often best to suture the wound closed in the operating room to avoid excessive scarring and corneal irregularity, especially in the visual axis. Tetanus toxoid for dirty wounds is a must.

Note that small, self-sealing, or slow-leaking lacerations may be treated with aqueous suppressants, bandage soft contact lenses, fluoroquinolone drops four times a day. Alternatively, a pressure patch and twice-daily antibiotics may be used. Avoid topical steroids.

### Traumatic Iritis

A blunt trauma to the eye can cause traumatic inflammation of the iris or, more accurately, of the anterior uveal tract. This leads to the presence of inflammatory cells in the anterior chamber of the eye. Traumatic iritis generally develops quickly after the trauma and usually affects only the injured eye.

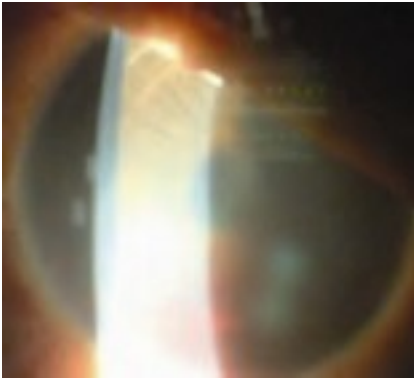
#### ◆Presentation

Patients usually present with a history of ocular trauma. Symptoms include pain, photophobia, and possibly headache. Pain typically worsens when either the injured eye or the uninjured eye is exposed to bright light (due to consensual pupillary constriction). Signs include cells and flare in the anterior chamber and perilimbal injection (**Fig. 1.9**). The iris pupillary margin of the involved eye may be different in shape compared with the contralateral.

#### ◆Differential Diagnosis

Traumatic corneal abrasion, traumatic microhyphema, other causes of anterior uveitis

#### ◆Management



or ulcer should suggest the diagnosis of

traumatic iritis. This diagnosis can be

confirmed by the presence of cells and **Fig. 1.9**

Posttraumatic hyphema and iritis. (Courtesy of Amar Agarwal, Dr.

Agarwal's Eye Hospital, Chennai, India)

flare in the anterior chamber at slit-lamp examination. A complete ophthalmic evaluation should be performed, including tonometry and fundus examination. Treatment typically consists of cycloplegic agents. In refractory cases and if no corneal epithelial defect is detected, a steroid drop could be given. Patients should be re-evaluated within a week; if iritis is resolved, medication can be discontinued.

## Iris Sphincter Tear

Blunt injury often causes tears in the sphincter pupillae of the iris.

### ◆Presentation

The patient may be asymptomatic or may have glare and photophobia. The tears in the pupillary margin can be visualized on slit lamp examination (**Fig. 1.10**)

### ◆Differential Diagnosis

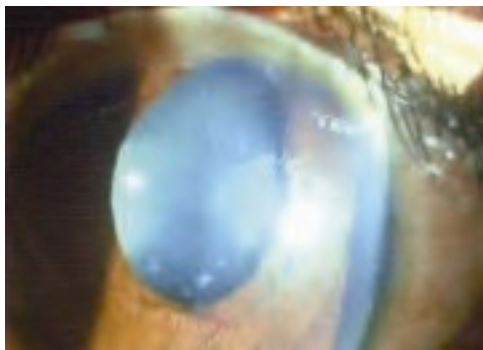Other causes of a dilated pupil (e.g., pharmacological mydriasis)

### ◆Management

A thorough ocular examination is done to rule out any other coexisting damage. It may be left alone untreated. If causing symptoms, and if cataract extraction is also being planned, one may perform a pupiloplasty or use aniridia segments.

## Traumatic Cataract

Traumatic cataract can develop after various types of insult: blunt or perforating trauma, electric shock, infrared, UV, and ionizing radiation. Blunt trauma is the most common cause, and coup and contrecoup injuries, along with equatorial expansion, are the pathophysiological mechanism responsible for ocular damage. As regards lens injury, “coup” is the cause for Vossius ring (iris pigment remains imprinted on the anterior capsule), and “contrecoup” is responsible for the shock waves that may lead to anterior or posterior capsular rupture and subsequent lens opacification. The equatorial stretching can disrupt the zonules and capsule. The

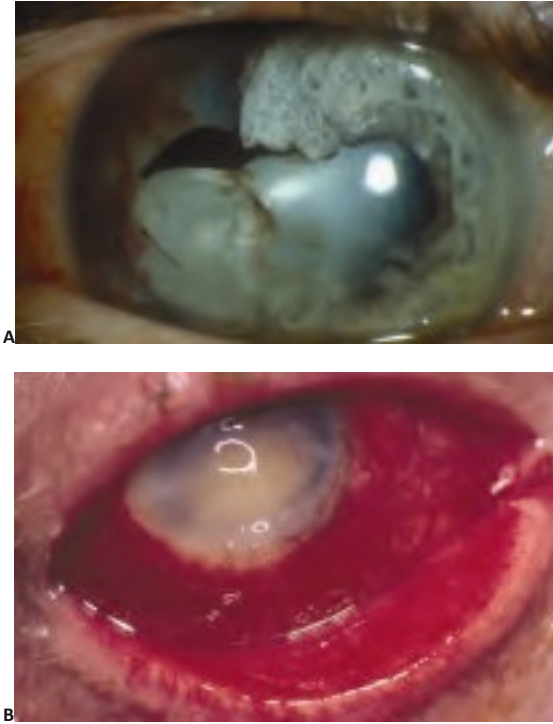


**Fig. 1.10** Sphincter tear. (Courtesy of Amar Agarwal, Dr. Agarwal's Eye Hospital, Chennai, India)

release of lens proteins due to capsule rupture can lead to phacoanaphylactic uveitis, characterized by the presence of polymorphonuclear leukocyte (eosinophils) and giant cell infiltration surrounding lens materials. The occlusion of the trabecular meshwork due to lens proteins and macrophages can lead to an acute rise in intraocular pressure. Glaucoma can also be secondary to relative pupillary block due to posterior synechiae or lens swelling (phacomorphic glaucoma).

### ◆Presentation

If no perforating trauma or trauma-related symptomatic iritis occurs, the patient could wait for days, weeks, or months before searching for medical care. The patient usually presents with a history of trauma and may complain of decreased vision and monocular diplopia. At slit lamp examination, cataract associated with blunt trauma usually appears as stellate or rosette-shaped “visual axis” opacification located inaxis and involving the posterior capsule. Perforating trauma leads to cortical opacification at the site of injury. This opacification usually remains localized, but if the capsular tear is large enough, the entire lens may opacify. Hyphema, signs of iritis, and lens dislocation or subluxation may be present (**Fig. 1.11A,B**).



**Fig. 1.11 (A)** Cataract and iridodialysis secondary to severe penetrating trauma. **(B)** Posttraumatic endophthalmitis.

#### ◆ Differential Diagnosis

Senile cataract, ectopia lentis, angle recession glaucoma, and hyphema

#### ◆ Management

Mechanism of injury and past ocular history should be investigated first. Then a ruptured globe and intraocular foreign body should be ruled out and a complete ophthalmic examination should be performed. Type and extent of lens opacification and the presence of ocular inflammation, hyphema, phacodonesis, iridodonesis, angle recession, lens swelling, lens dislocation, or subluxation should be documented. Zonular disruption may be detected gonioscopically through a dilated pupil. Posterior segment trauma-related pathology should be investigated by funduscopy. If opacification obstructs the view of the posterior segment, ultrasonography may be helpful. Medical treatment should be directed to focal and off-axis opacities, inflammation, and intraocular pressure rise. Miotics can help to obtain a clear visual axis, inflammation can be controlled with corticosteroids, increased intraocular pressure can be treated with standard ocular hypotensive medications. However, surgical removal of the lens usually resolves these complications. Decreased visual acuity, lens-induced inflammation or glaucoma, capsular rupture with lens swelling, and poor visualization of posterior segment pathology are indications for surgery. Standard phacoemulsification is preferred if the lens capsule is intact and there is sufficient zonular support; intracapsular extraction is indicated for zonular instability or anterior dislocation. In cases of posterior dislocation or posterior capsular rupture, pars plana lensectomy and vitrectomy may be preferred. As regards lens implantation,

capsular fixation is indicated if zonular support and the lens capsule are intact; capsular tension rings may help in cases of limited zonular dialysis. If the posterior capsule is compromised but sufficient zonular support remains, sulcus fixation should be chosen. A suture fixation approach would be the best if both zonular and capsular support are inadequate. If no posterior support is maintained, anterior chamber positioning should be considered. Complications associated with traumatic cataract include glaucoma (pupillary block glaucoma, phacolytic glaucoma, phacomorphic glaucoma, angle recession glaucoma), phacoanaphylactic uveitis, hyphema, retinal detachment, choroidal rupture, traumatic optic neuropathy, and globe rupture.

## Lens Dislocation/Subluxation

Subluxation is partial disruption of the zonular fibers; the lens is decentered but remains partially in the pupillary aperture. Dislocation is complete disruption of the zonular fibers; the lens is displaced out of the pupillary aperture. Trauma (most common cause), Marfan syndrome, homocystinuria, Weill–Marchesani syndrome, acquired syphilis, congenital ectopia lentis, aniridia, Ehlers–Danlos syndrome, Crouzon disease, hyperlysinemia, sulfite oxidase deficiency, high myopia, chronic inflammations, and hypermature cataract are some of the causes of lens subluxation.

### ◆Presentation

Decreased vision and double vision that persist when covering one eye (monocular diplopia) are the main symptoms. Critical signs are decentered or displaced lens, iridodonesis (quivering of the iris), and phacodonesis (quivering of the lens). Other signs include marked astigmatism, cataract, angle closure glaucoma as a result of pupillary block, acquired high myopia, vitreous in the anterior chamber, and asymmetry of the anterior chamber depth (Fig. 1.12)

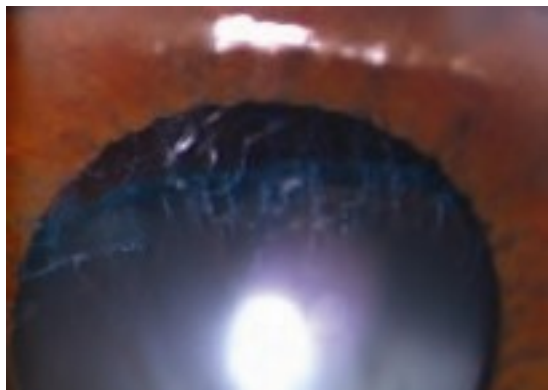


Fig. 1.12 Lens subluxation and zonular disruption.

### ◆Management

Family, personal, medical, and trauma history is very important. Systemic examination should evaluate stature, extremities, hands, and fingers as necessary. Rapid plasma reagin test and fluorescent treponemal antibody absorption test, sodium nitroprusside test, echocardiography, and urine chromatography to rule out homocystinuria are needed.

- ◆*Lens dislocated into the vitreous:* Surgically remove the lens.
- ◆*Lens capsule intact, patient asymptomatic no signs of inflammation:* Observe.

- ◆ *Lens capsule broken eye inflamed*: Lensectomy is done either through the pars plana or by using a limbal approach
- ◆ *Subluxation*
  - ◆ *Asymptomatic* : Observe.
  - ◆ *High uncorrectable astigmatism or monocular diplopia*: Surgical removal of the lens.
  - ◆ *Symptomatic cataract* : Options include surgical removal of the lens.
  - ◆ *Pupillary block*: Treatment is identical to that for aphakic pupillary block.
  - ◆ *Marfan syndrome is present*: Refer the patient to a cardiologist for an annual echocardiogram and management of any cardiac-related abnormalities. Prophylactic systemic antibiotics are required if the patient undergoes surgery (or a dental procedure) to prevent endocarditis.
  - ◆ *Homocystinuria is present* :
    - ◆ Administer pyridoxine, 50 to 1000 mg by mouth four times a day.
    - ◆ Reduce dietary methionine.
    - ◆ Avoid surgery if possible because of the risk of thromboembolic complications. If surgical intervention is necessary, anticoagulant therapy is indicated.

## Microhyphema/Hyphema

Traumatic hyphema is defined by postinjury accumulation of blood within the anterior chamber. Microhyphema consists of suspended erythrocytes in the anterior chamber, generally visible at slit lamp. Equatorial expansion after blunt trauma induces stress to angle structures, which can lead to rupture of iris and ciliary body vessels with subsequent hemorrhage. Lacerating injury can be associated with direct damage of blood vessels and hypotony. Some conditions such as rubeosis iridis, juvenile xanthogranuloma, hemophilia, leukemia, and the use of drugs that alter platelet or thrombin function may facilitate the onset of hyphema. A significant number of sight-threatening complications may develop, which requires careful follow-up for hyphema patients.

### ◆ Presentation

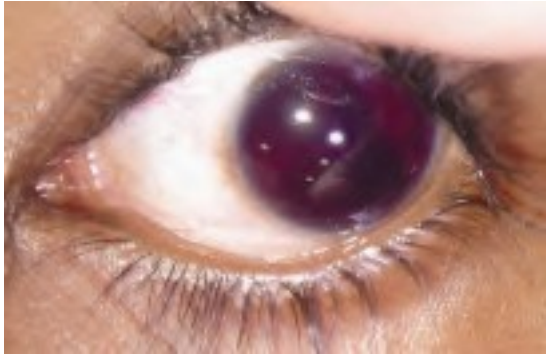Patients usually present with a history of blunt trauma. Pain and blurred vision are common symptoms. Hyphemas are graded on the amount of blood within the anterior chamber: grade I is less than one third filling of the anterior chamber, grade II hyphemas have more than one third but less than one half of the anterior chamber filled with blood, grade III is more than one half but less than total filling, grade IV is a total hyphema, also known as eight-ball hyphema (Fig. 1.13).

### ◆ Differential Diagnosis

Uveitic glaucoma and causes of spontaneous hyphema such as juvenile xanthogranuloma, iris cavernous hemangioma, hypertension, and bleeding disorders

### ◆ Management

Mechanism and time of injury should be investigated carefully. A history of sickle cell trait or disease should be sought out. Inspection for gross ocular injury and evaluation of the adnexa should be performed. A ruptured globe should be ruled out. A complete ocular examination is imperative and must include intraocular pressure measurement and dilated funduscopy evaluation. Gonioscopy should be deferred until hyphema resolves to detect potential rebleeding sites and angle recession. A drawing of the hyphema documenting shape and size should be recorded at every ophthalmic evaluation. Depending on the patient's history, hemoglobinopathies and bleeding disorders should be investigated. B-scan ultrasonography may be useful in patients with large hyphemas, when ophthalmoscopy is not feasible. Noncompliant patients or those with increased risk of rebleeding, uncontrolled



**Fig. 1.13** Posttraumatic hyphema. Grade II hyphemas have more than one third but less than one half of the anterior chamber filled with blood.

glaucoma, positive sickle cell trait, or anemia should be considered for inpatient hospitalization. The elevation of the patient's head to 30 to 45 degrees while lying supine may facilitate the settling and layering of the hyphema in the inferior anterior chamber, allowing an easier classification of the hyphema, an earlier evaluation of the posterior pole, and a more rapid improvement in visual acuity. A transparent plastic shield should be used to protect the involved eye from further injury. Its transparency allows recognizing rebleeding or sudden visual loss.

Medical treatment includes topical cycloplegics (1 drop of 1% atropine three times a day for up to 5 days) to increase the patient's comfort (consider the risk of precipitating acute glaucoma in patients with a narrow chamber angle) and topical steroids (0.1% dexamethasone) to decrease inflammation, reduce anterior chamber reaction, and prevent the incidence of secondary hemorrhage (caution should be exerted if steroids are used for a prolonged period because they can increase the risk of cataract and glaucoma). Topical and systemic antifibrinolytics, such as aminocaproic acid, could be used to prevent rebleeding and retarding clot lysis. The more common side effects of aminocaproic acid include vomiting, diarrhea, and postural hypotension. Its systemic use should be avoided in patients with hepatic or renal disease. Persistent increased intraocular pressure should be treated initially with topical  $\beta$ -blockers. If this treatment is unsuccessful, topical  $\alpha$ -agonist or carbonic anhydrase inhibitor may be added in patients without sickle cell trait or disease. Aspirin and other NSAIDs should be discontinued. Uncontrolled elevated intraocular pressure (at least 45 mm Hg for 5 days) could be surgically treated with paracentesis and anterior chamber washout. Other indications to surgery are early corneal staining or rebleeding hyphemas. Smaller hyphemas are usually self-limiting and clear within 5 days. Large hyphemas are associated with complications and the worst prognosis. Such complications are secondary hemorrhage, corneal blood staining, glaucoma, anterior and posterior synechiae, cataract, and optic atrophy.

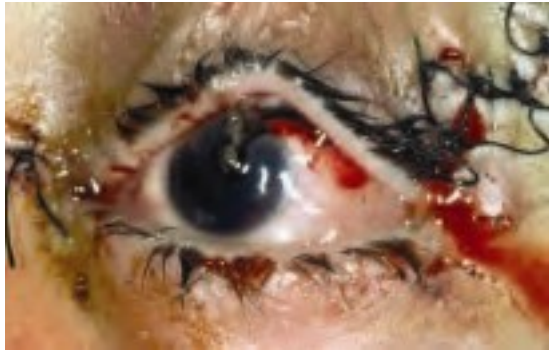## Ruptured Globe

A ruptured globe is a devastating injury with significant long-term consequences for the patient. It represents a discontinuity of the eye's outer membranes caused by blunt or penetrating trauma. Ruptures resulting from blunt trauma usually occur at the sites where the sclera is weakest, such as at the insertion of the extraocular muscles, around the optic nerve, and at the limbus. Sharp objects with sufficient momentum may directly perforate the globe. Globe rupture is more common in young males owing to their occupational and recreational preferences. High myopia and previous eye surgery can make tissues more vulnerable to rupture. A ruptured globe is an ophthalmic emergency and requires surgical repair as soon as possible. The visual outcome depends largely on early recognition and prompt intervention.



### ◆Presentation

The patient usually presents with a history of ocular trauma. Symptoms include pain, which can be not extremely severe in the case of sharp injury, and decreased vision. Diplopia may be present due to extraocular muscle entrapment or dysfunction and trauma-associated cranial nerve palsy. At physical examination the globe rupture may be obvious or occult. A full-thickness corneal or scleral laceration is a sign of globe perforation. Prolapse of the iris or extrusion of ocular contents may be present. Severe conjunctival hemorrhage, usually involving 360 degrees of bulbar conjunctiva, typically indicates globe rupture. Other accompanying signs include irregular pupil, hyphema, lens injury, commotio retinae, vitreous hemorrhage, choroidal rupture, retinal tears and detachments, and traumatic optic neuropathy. A ruptured globe may present with both enophthalmos and exophthalmos, depending on the presence of an associated retrobulbar hemorrhage (**Fig. 1.14**).



**Fig. 1.14** Perforating ocular trauma.

### ◆Management

The mechanism and the circumstances of injury and the nature of the traumatizing object should be investigated. Visual acuity should be documented and extraocular muscle function should be evaluated. Pupils should be examined for size, shape, and light reflex. The diagnosis of a ruptured globe should be made by slit lamp or penlight. The orbit and adnexa should be examined for injuries, foreign bodies, bone deformity, and eyeball displacement. Intraocular pressure measurement is contraindicated to avoid pressure to the globe. The eye should be protected with a shield. Systemic prophylactic antibiotics and analgesics, if advisable, should be administered. The patient should receive tetanus immunization if indicated and be kept nothing per os. The imaging study of choice is computed tomography; if it is not available a plain x-ray film should be obtained. Magnetic resonance imaging may be useful to identify soft tissue and globe injuries, but it is contraindicated if a metallic foreign body is suspected. Careful B-scan ultrasonography may be useful to identify the site of rupture and intraocular foreign bodies. Surgical repair should be prompt. If there is no expectation to restore vision, enucleation should be considered. Endophthalmitis and sympathetic ophthalmia are possible sight-treating complications that should be borne in mind.

## ◆ Posterior Segment Trauma

### Posttraumatic Vitreous Hemorrhage

Vitreous hemorrhage results from bleeding into one of the several potential spaces formed around and within the vitreous body. This condition can follow injuries to the retina and uveal tract and their associated vascular structures. Neovascularization occurring in diseases like proliferative diabetic retinopathy may predispose to bleeding, even if the trauma is mild. Other disorders that promote the release of angiogenic vasoactive factors and subsequent formation of neovascular and fragile vessels that can easily bleed are ischemic retinopathy secondary to retinal vein occlusion, retinopathy of prematurity, and proliferative sickle cell retinopathy. Traumatic vitreous hemorrhage in children may be a sign of child abuse (shaken baby syndrome).

### ◆ Presentation

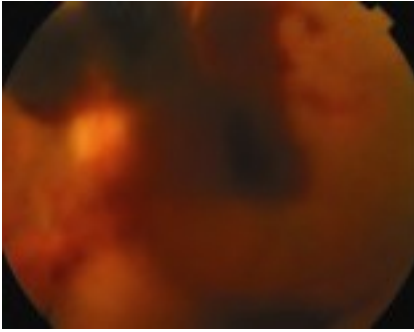
Patients with traumatic vitreous hemorrhage usually present with a complaint of decreased visual acuity, floaters, cloudy vision, perception of shadows, visual haze, and photophobia. Patients may not remember the traumatic insult. Direct ophthalmoscopy reveals a diminished red reflex that can be black in severe cases. Indirect ophthalmoscopic examination discloses the presence of blood in the anterohyaloid or retrohyaloid spaces or within the vitreous gel. Usually a subhyaloid hemorrhage suggests a source of bleeding anterior to the retina, whereas a hemorrhage posterior to the internal limiting membrane implies a source of bleeding within the retina. Long-standing hemorrhages can evolve in white masses (Fig. 1.15).

### ◆ Differential Diagnosis

Differential diagnosis of traumatic vitreous hemorrhage includes other vitreous hemorrhages not related to trauma. Spontaneous vitreous hemorrhage may occur in conditions like proliferative retinopathies, choroidal or ciliary body melanoma, retinoblastoma, uveitis, sarcoidosis, ocular manifestation of syphilis, or histoplasmosis.

### ◆ Management

A detailed history is very important. Underlying pathologies and mechanism of trauma should be documented. A complete eye examination should be performed, including slit lamp examination, intraocular pressure measurement, and dilated fundus evaluation. Globe perforation and intraocular foreign body should be ruled out. B-scan ultrasonography can be used when the fundus is difficult to visualize, disclosing the presence of retinal detachment, retinal tears, intraocular foreign body, or intraocular tumor. Initial therapy consists of bed rest with 30- to 45-degree head elevation (allows the blood to settle inferiorly) and avoidance of anticoagulative drugs and intense Valsalva maneuvers. Conclusive therapy is fired at the underlying cause: retinal breaks can be closed with laser photocoagulation, and surgery can resolve retinal detachments. Vitrectomy is also indicated in longstanding vitreous hemorrhage (2 to 3 months) and when vitreous hemorrhage is associated with rubeosis and ghost-cell glaucoma. Complications of vitreous hem-



**Fig. 1.15** Posttraumatic vitreous hemorrhage.

orrhage usually develop when large amounts of blood remain for long periods in the vitreous cavity and include enhanced proliferative retinopathy, hemosiderosis bulbi and consequent iron toxicity, ghost-cell glaucoma, amblyopia (resulting from visual deprivation), and myopic shift in infants.

### Comotio Retinae

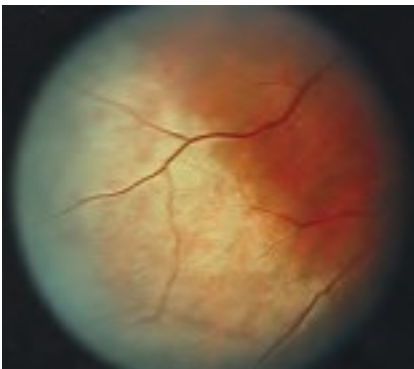Comotio retinae is a clinical entity first described in 1873 by Berlin and is characterized by a transient whitening at the deep sensory retina. This condition is common; it has been shown to be responsible for 9.4% of all posttraumatic fundus changes. The mechanism of injury is the contrecoup force following blunt ocular trauma that causes degeneration of the photoreceptors' outer segments and subsequent phagocytosis by retinal pigment epithelium cells. The presence of edema in the outer plexiform layers, nuclear layers, and subretinal space has been demonstrated. Angiographic evidence has supported the belief that retinal and choroidal vessels do not play a significant role in the pathogenesis of this condition.

#### ◆Presentation

Patients may be asymptomatic if commotio retinae is limited to the peripheral retina, or they may complain of decreased vision if the whitening occurs in the foveal region. Visual acuity may be variably affected and does not always relate to the degree of opacification. Ophthalmoscopic examination reveals a cloudy opacification of the retina, usually with poorly defined margins. It can be located anywhere within the posterior segment. In some cases the entire posterior pole can be involved, and it may appear as a pseudocherry red spot. Retinal vessels are clearly visible and appear undisturbed. Other associated traumatic pathology may be present, such as subretinal, intraretinal, and preretinal hemorrhages; macular holes; macular detachments, and choroidal ruptures (**Fig. 1.16**).

#### ◆Differential Diagnosis

Differential diagnosis of commotio retinae includes retinal detachment, central artery occlusion, branch retinal artery occlusion, and retinal white without pressure.



**Fig. 1.16** Peripheral commotio retinae with undefined posterior borders.

### ◆Management

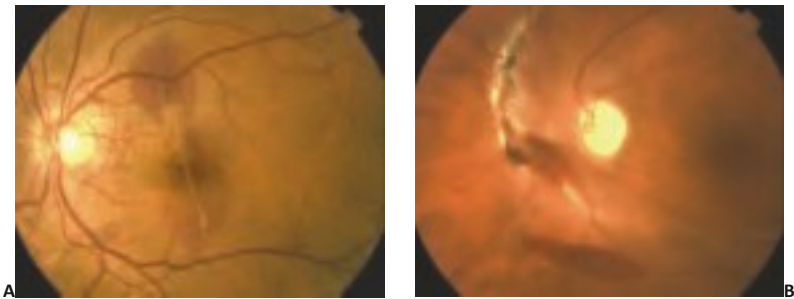
The mechanism of trauma should be documented. A complete ophthalmic examination should be performed, including dilated fundus evaluation and scleral depression if there is no evidence of hyphema, microhyphema, or iritis. The retinal whitening usually fades within some weeks, and no treatment is available, only observation. About 60% of patients fully recover vision, and 40% sustain permanent visual loss. Complications of commotio retinae include cystoid areas that may degenerate into macular holes, photoreceptor loss, retinal pigment epithelium (RPE) migration, degeneration, atrophy, or hyperplasia.

### Choroidal Rupture

Traumatic choroidal rupture is a common occurrence after a blunt ocular trauma (5 to 10%). It is a defect in the Bruch membrane, the choroid, and the retinal pigment epithelium. When sudden anteroposterior compression and equatorial expansion subsequent to ocular blunt trauma take place, the sclera has enough tensile strength and the retina has enough elasticity to be relatively protected. Because the Bruch membrane does not have these properties, it is prone to break. The damage at the choriocapillaris vessels may lead to subretinal, sub-retinal pigment epithelium, or intrachoroidal hemorrhage. In the acute phase the overlying hemorrhage and the retinal edema may obscure the choroidal rupture itself. Typically, during the healing phase, choroidal neovascularization occurs and in most cases resolves spontaneously. Conditions associated with an increased fragility of the Bruch membrane, such as angioid streaks, are risk factors for traumatic choroidal rupture.

### ◆Presentation

Patients usually present with a history of ocular blunt trauma, decreased vision, and a variety of visual field defects (paracentral, central, sector scotomas). At ophthalmoscopic examination the choroidal lesion appears as a yellow-white, crescent-shaped, subretinal streak, concentric to the optic disc. The border of the rupture may be hyperpigmented or hypopigmented. Often the overlying hemorrhage may obscure the choroidal rupture (**Fig. 1.17A,B**).



**Fig. 1.17 (A)** Traumatic choroidal rupture. **(B)** Traumatic choroidal rupture.

### ◆Differential Diagnosis

Angioid streaks, high myopia, subretinal neovascular membranes, ocular histoplasmosis syndrome, choroidal neovascularization, pseudoxanthoma elasticum

### ◆Management

A complete ocular examination is mandatory. Fluorescein angiography may be considered to confirm the presence of choroidal rupture and to detect choroidal neovascularization. Indocyanine green angiography may be useful when subretinal hemorrhage obscures choroidal neovascularization

recognition. Conservative treatment is advised for most traumatic choroidal ruptures. Extrafoveal choroidal neovascularization may be treated with laser photocoagulation. Pars plana vitrectomy and membrane extraction may be considered for subfoveal and juxtafoveal choroidal neovascularization. Good visual outcomes are expected if the rupture does not involve the fovea. Possible complications are hemorrhagic or serous macular detachment.

## Posttraumatic Retinal Tears and Detachment

Ocular trauma is responsible for 10% of retinal detachments. Usually the traumatic injury causes an anterior-posterior compression of the globe and a lateral expansion of the equator. This results in a tractional force on the vitreous base, where the vitreous body is physiologically adherent to the peripheral retina. Retinal breaks are the result of vitreous traction at the ora serrata or in sites of focal vitreoretinal adhesion (such as corioretinal scars and lattice degeneration). In the presence of vitreous syneresis, fluid dissects the retina, giving rise to retinal detachment. Common abnormalities causing posttraumatic retinal detachments are retinal dialysis and giant retinal tears. Another mechanism of injury is retinal necrosis as a result of direct trauma to the sclera. It is often associated with retinal hemorrhages and edema and leads to large and irregularly shaped retinal tears. High myopia and sites of focal vitreoretinal adherence are risk factors for traumatic retinal detachment.

### ◆Presentation

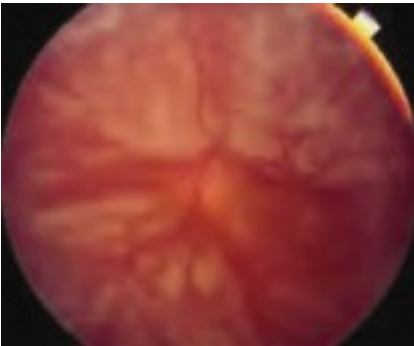Retinal detachments and retinal tears can be diagnosed months or years after the trauma, so the causal nexus is not always easy to identify. Patients can present complaining of mild blurring of vision, floaters, photopsia, and visual-field defects. Ophthalmoscopic findings that suggest a vitreoretinal interface involvement after a trauma include vitreous base avulsion, retinal dialysis, retinal tears of various shapes and dimensions (giant, round, horseshoe), and retinal detachment. Once the retina becomes detached, it appears as an elevated, slightly opaque, corrugated surface that undulates freely with eye movements. In the cases of retinal detachment intraocular pressure is usually lower than that of the fellow eye (Fig. 1.18).

### ◆Differential Diagnosis

Penetrating trauma, retinal detachments caused by other conditions (proliferative, tractional, postoperative, exudative), acute retinal necrosis, senile retinoschisis

### ◆Management

A complete ophthalmic evaluation should be performed, including intraocular pressure measurement and accurate retinal examination. Retinal abnormalities, vitreoFig. 1.18 Retinal detachment secondary to a retinal dialysis.



retinal tractions, tears, and detachments must be recorded. B-scan ultrasonography and optical coherence tomography are useful imaging studies when media opacities impair a complete ophthalmoscopic retinal examination. Retinal tears may be treated successfully by laser photocoagulation and cryopexy. However, some giant retinal tears may progress to retinal detachment regardless of therapy. For this reason a prophylactic scleral buckle may be considered in the cases of an elevated tear flap or focal vitreoretinal traction. Retinal detachments are essentially managed with surgery. Common procedures are vitrectomy, pneumatic retinopexy, and scleral buckling to support the dialysis. Perfluorocarbonate liquids or gas bubbles can be used intraocularly to facilitate the retina's adherence. The final postsurgery visual acuity depends primarily on whether the macula was involved in the retinal detachment: once the macula is detached, photoreceptors start to degenerate, impairing visual recovery. Other concurrent damages to the macula, such as macular holes, commotio retinae, or choroidal rupture, may limit final visual acuity.

## Traumatic Macular Hole

A macular hole is a full-thickness defect of the retina involving the foveal region. Traumatic macular hole was first described in 1869 by Knapp. Since then a large number of cases have been reported and, despite several publications, the exact mechanism of traumatic macular hole formation remains controversial. Some theories have been proposed to explain development of traumatic macular holes: historical hypotheses claimed traumatic, cystic degeneration, and vitreous and vascular etiologies. In more recent times, Johnson et al advanced that equatorial expansion causes retinal flattening and tangential traction. Yamada et al observed that vitreous traction may play a role in the formation of some traumatic macular holes. Tornambe proposed the experimental hydration theory, stating that the altered homeostasis due to a break in the internal retinal layer leads to intraretinal swelling and hole formation. The incidence of traumatic macular holes varies from 1 to 9%. Patients are usually young and male. Most traumatic macular holes derive from closed-globe contusion injuries from various insults, the most common being blunt ocular trauma caused by a variety of types of balls. Traumatic macular holes can also be caused by accidental yttrium-aluminum-garnet (i.e., YAG) laser burns.

### ◆Presentation

Patients usually present with a history of ocular trauma and subsequent reduction of central visual acuity, which is usually 20/80 to 20/400. Ophthalmoscopic examination normally discloses a full-thickness and well-defined hole in the center of the macula. It is usually round or elliptical and measures 300 to 500 μm. Other common findings are the presence of small yellow deposits at the level of the retinal pigment epithelium (RPE) and a ring of subretinal fluid surrounding the hole. Associated epiretinal membrane and operculum are typically missing. Erythrocytes and inflammatory cells may be present in the vitreous, and associated ocular injuries are common (Fig. 1.19).

### ◆Differential Diagnosis

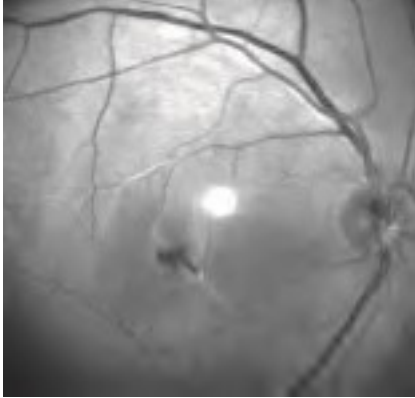
Idiopathic macular hole, epiretinal membrane

### ◆Management

A complete ophthalmic examination should be performed, including intraocular pressure measurement and careful posterior segment evaluation. Useful imaging studies include fluorescein angiography, optical coherence tomography, and B-scan ultrasonography. Microperimetry may document the pattern of visual acuity loss. Vitrectomy has been shown to close traumatic macular holes effectively and improve vision. Current technique includes removal of the posterior hyaloid and all epiretinal membranes from the macular area and prolonged postoperative macular gas tamponade. Spontaneous closure of traumatic macular holes is relatively frequent. Therefore, a period of observation before deciding on surgical intervention is recommended. Associated macular RPE atrophy and choroidal injury may limit visual outcomes.

## Intraocular Foreign Body

The ophthalmic pathologies caused by an intraocular foreign body arise from two mechanisms: the direct damage caused by the penetrating injury and its associated complications, depending on the size, shape, and momentum of the object; and the damage caused by the existence of an intraocular foreign body, such as metal toxicity and microbial endophthalmitis. Metallosis bulbi is an extensive ocular damage caused by the chronic presence of a reactive metallic foreign body, most commonly made of iron or copper. Siderosis is characterized by a rusty brown deposit and discoloration involving the lens and the iris, and retinal degenerative



**Fig. 1.19** Traumatic macular hole.

pigmentary changes. Chalcosis is made distinctive by the presence of a greenish blue ring in the peripheral cornea (Kayser-Fleischer ring), greenish coloration of the iris, anterior subcapsular cataract, and refractive deposits on the surface of the retina. Commonly, intraocular foreign bodies arise from hammering and using power tools. Protective eyewear can prevent most injuries.

### ◆Presentation

Patients usually present with a suggestive history, but ophthalmologists should take into account that a patient may be unaware of any object penetrating the eye. Patients may be asymptomatic or complain of decreased vision and eye pain. The foreign body may be visible at slit-lamp examination of the anterior segment; other signs include corneal entry wound, iris transillumination defect, irregular pupil, lens damage, and anterior chamber reaction. Dilated indirect ophthalmoscopy may reveal a posterior segment foreign body and associated injuries, such as vitreous hemorrhage, retinal tears, and detachment (**Fig. 1.20**).

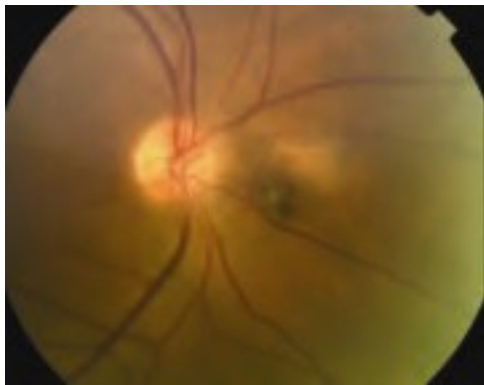
### ◆Differential Diagnosis

Other causes of sudden visual loss

### ◆Management

History should be carefully investigated, including mechanism of injury and foreign body composition. Ocular examination should be performed, with attention to possible sites of ocular perforation. The anterior chamber and posterior segment should be evaluated carefully. The direct visualization of the foreign body is usually very informative for the surgeon. Computed tomography is the imaging study of choice; if it is unavailable a plain x-ray may be considered in the case of a metallic foreign body. A careful use of B-scan ultrasonography may be convenient to localize the foreign body even if the globe is open. If a chronic intraocular foreign body is found, electroretinography is a useful for evaluating retinal function in the metallosis bulbi. Topical and

systemic antibiotic therapy, topical steroids, and tetanus prophylaxis (if needed) are required prior to the surgical intervention. The timing of surgery depends on the nature and location of the foreign body



**Fig. 1.20** Intraocular foreign body.

and on the risk of endophthalmitis. Foreign bodies in the anterior chamber should be extracted through a paracentesis and with the auxiliary use of viscoelastics to reduce possible damage to the lens and the corneal endothelium. Foreign bodies embedded in the lens do not automatically result in cataract. If no opacification is evident and there is no risk of siderosis, then they can be left in situ. Vitrectomy is the surgical procedure of choice for posterior segment foreign bodies. In the case of magnetic foreign bodies, they can be removed with the use of a strong intraocular magnet. Proper forceps should be used for nonmagnetic foreign bodies. Associated injuries should be treated accordingly. If possible a culture of the foreign body or of a sample of vitreous may be useful if an infection is suspected. Possible complications of intraocular foreign bodies include endophthalmitis, metallosis, corneal scarring, cataract, retinal detachment, and elevated intraocular pressure.

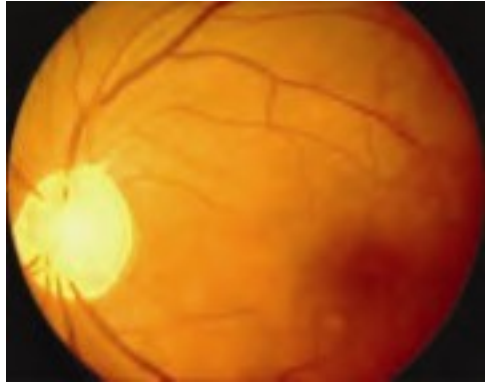### Traumatic Optic Neuropathy

Trauma-associated lesion of the optic nerve can occur anywhere in the course of the nerve. The injury can be due to laceration of the nerve by a foreign body or a bone fragment, compression of the nerve, and hemorrhage or perineural edema. It is usually associated with head trauma or midfacial fracture. Optic nerve trauma is often due to vehicle accidents, falls, recreational sports, assaults, or penetrating orbital trauma. The frequency of optic nerve injury in the United States occurring in closed head trauma varies from 0.5 to 5.0% (**Fig. 1.21**)

#### ◆Presentation

Typically, patients present with a history of head injury and report a classic sequence of events: the patient recovers consciousness after head injury and experiences a posttraumatic loss of visual function in one eye. Visual acuity and color vision may be altered, and visual field defects may be present. The critical sign is a new ipsilateral afferent pupillary defect. Optic atrophy usually occurs weeks after retrobulbar trauma. Injuries to the optic nerve may be either direct or indirect. Direct injuries include the following:





**Fig. 1.21** Traumatic optic neuropathy. (Courtesy of Athiya Agarwal, Dr. Agarwal's Eye Hospital, Chennai, India)

- ◆ *Optic nerve avulsion*: It usually follows severe orbital trauma with an acute and serious visual loss. Ophthalmoscopy shows the absence of the optic disc and peripapillary hemorrhage.
- ◆ *Optic nerve transection*: The vision loss is immediate and complete, and computed tomographic scanning reveals the bone fragment or the foreign body transecting the optic nerve.
- ◆ *Optic nerve sheath hemorrhage*: Visual function abnormalities may vary and proptosis may not be present. Magnetic resonance imaging may be helpful in confirming the diagnosis. The visual loss associated with this condition may be reversible via sheath fenestration.
- ◆ *Orbital hemorrhage*: It is associated with proptosis and ophthalmoplegia. Raised intraocular pressure may be initially controlled with topical ocular hypotensive agents. If conservative measures fail, lateral canthotomy and hemorrhage drainage should be considered.
- ◆ *Orbital emphysema*: Injuries to the thin bones limiting the paranasal sinus may produce a one-way valve that results in an air accumulation in the orbit with subsequent compression of the optic nerve, proptosis, and elevation in the intraocular pressure. Drainage of the intraorbital air usually resolves this condition.

Indirect optic nerve injury usually results from a blunt trauma to the superior orbital rim or the frontal area. The compression forces are then transmitted via orbital bones to the orbital apex and optic canal. Compression and contusion of the nerve produce a compartment syndrome that results in localized optic nerve ischemia and edema.

#### ◆ Differential Diagnosis

Posttraumatic intraocular lesions, preexisting neuropathies, factious amblyopia

#### ◆ Management

The management of indirect optic nerve injury should include complete ocular examination, color vision testing, visual field testing, computed tomographic scanning of the head and orbit, and B-scan ultrasonography. Other tests that may be useful are visual evoked potential and electroretinography. The treatment of optic nerve indirect injury is somewhat controversial. Very high-dose corticosteroids have been proposed to limit free-radical amplification of the injury response. Surgery may be reserved, when indicated, for the cases of direct injury or to decompress the optic canal in indirect injuries. Nevertheless, the serious complications of surgery, such as iatrogenic damage of the optic nerve or of the adjacent structures, should be carefully considered.

## ◆Orbital Trauma

### Orbital Fractures

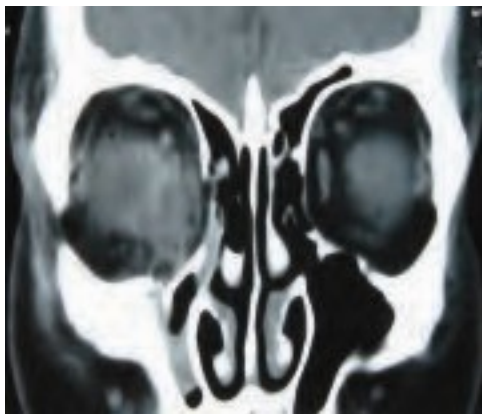
Blow-out fracture of the inferior wall of the orbit is the most common of the orbital fractures. The medial wall of the orbit is the thinnest of all and is commonly associated with multiple wall fractures of the orbit.

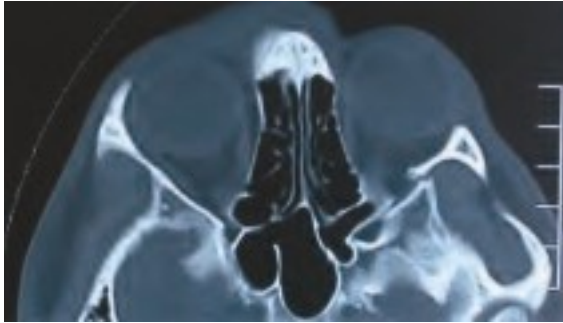
### ◆Presentation

Patients present with pain (especially on attempted vertical eye movement), local tenderness, binocular double vision, eyelid swelling and crepitus after nose blowing, and recent history of trauma. Examination reveals restricted eye movement (especially in upward or lateral gaze), subcutaneous or conjunctival emphysema, hypoesthesia in the distribution of the infraorbital nerve (ipsilateral cheek and upper lip), and enophthalmos (may initially be masked by orbital edema). Associated signs include nosebleed, eyelid edema, and ecchymosis. Superior rim and orbital roof fractures may show hypoesthesia in the distribution of the supratrochlear or supraorbital nerve (ipsilateral forehead) and ptosis. Trismus, malar flattening, and a palpable step-off deformity of the inferior orbital rim are characteristic of tripod fractures (**Fig. 1.22A,B**).

### ◆Differential Diagnosis

Orbital edema and hemorrhage without a blow-out, cranial nerve palsy





**Fig. 1.22 (A)** Blow-out fracture inferior wall. **(B)** Orbital blowout fracture of the lateral wall. (Image (A) Courtesy of Soosan Jacob, Dr. Agarwal's Eye Hospital, Chennai, India)

### ◆Management

Complete ophthalmologic examination, including measurement of extraocular movements and globe displacement. Check pupils and color vision carefully to rule out a traumatic optic neuropathy. Forced-duction testing is performed. Computed tomographic scan of the orbits is obtained in all cases of suspected orbital fractures.

Treatment includes nasal decongestants (e.g., pseudoephedrine nasal spray, twice a day); broad-spectrum oral antibiotics (e.g., cephalexin 250 to 500 mg by mouth four times a day, or erythromycin 250 to 500 mg by mouth four times a day) for 7 days may be used but are not mandatory. Apply ice packs to the orbit for the first 24 to 48 hours. Surgical repair should be considered based on the following criteria.

Immediate repair (usually within 24 hours) is required if there is evidence by computed tomographic scan of entrapped muscle or periorbital tissue in combination with diplopia and nonresolving bradycardia, heart block, nausea, vomiting, or syncope.

Repair in 1 to 2 weeks is done if there is evidence of persistent, symptomatic diplopia in primary or downgaze that has improved at 1 week, with positive forced ductions and evidence of entrapment on computed tomography or large floor fractures (more than one half of the orbital floor) that have caused or are likely to cause cosmetically unacceptable enophthalmos.

### Intraorbital Foreign Body

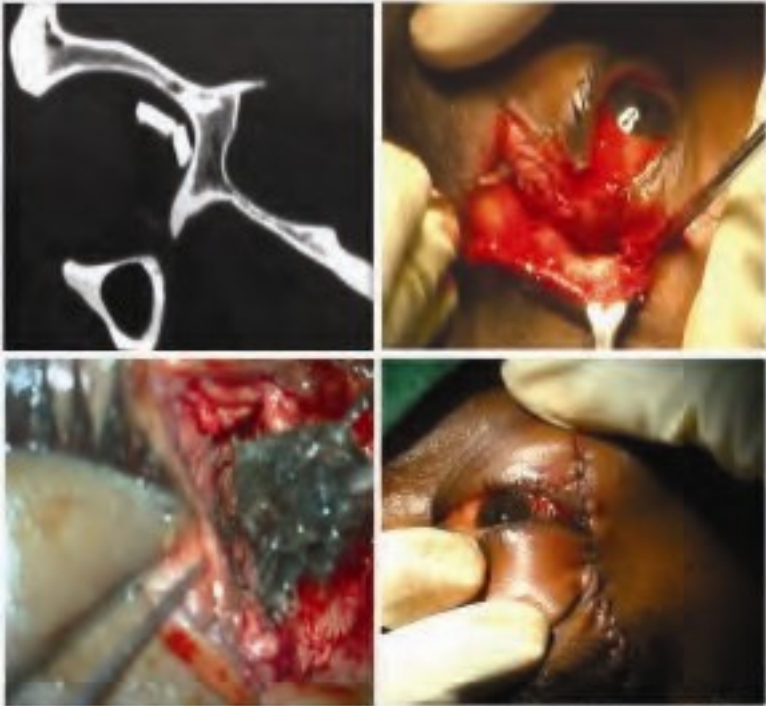Intraorbital foreign bodies can occur either from high-velocity injuries or from relatively minor traumas. The nature of the object is fundamental in determining the severity of ocular and orbital complications. Organic foreign bodies are poorly tolerated and often lead to inflammation. Most metals, stone, glass, and plastic are usually inert and well tolerated. Thus inorganic foreign bodies typically cause decreased vision or orbital complications due to direct trauma, whereas organic foreign bodies can easily develop orbital infections.

### ◆Presentation

Patients may present with a recent history of trauma and severe pain. However, they can also be asymptomatic and do not recall the trauma at all. Pain, decreased vision, and diplopia are common presenting symptoms. Intraorbital foreign bodies can be subtle and not easily identifiable on examination. Clinical signs include palpable ocular mass, proptosis, afferent pupillary defect, edema and ecchymosis of the eyelids, laceration of the conjunctiva or the periocular tissues, and limitation of the extraocular movements. Organic foreign bodies may induce a marked inflammatory response with elevation of the serum white cell count (**Fig. 1.23**).

◆ **Management**

A detailed history is necessary to determine the mechanism of injury and the nature of the foreign body. A complete ophthalmologic examination should be performed, with particular attention to fundusoscopic examination, intraocular pressure, and pupillary reaction. Ocular and periocular inspection should be addressed to discover an entry wound. Neurological testing and attention to the patient's mental status are required to evaluate a possible neurological injury. The imaging study of choice is computed tomographic scan. It can reveal most foreign bodies, and it is safe in case of metallic foreign bodies. However, wooden or plastic foreign bodies can be missed on computed tomographic scan or can be misidentified as intraorbital air. Once a metallic foreign body has been



excluded, magnetic resonance

CD

**Fig. 1.23** Orbital foreign body removal. **(A)** Computed tomographic scan showing radiopaque foreign body within the orbit. **(B)** Foreign body approached through wound of entry. **(C)** Foreign body located and removed. **(D)** Final appearance after removal of both foreign bodies and closure of wound. (All images courtesy of Soosan Jacob, Dr. Agarwal's Eye Hospital, Chennai, India; courtesy, Pablo Gili)

nance imaging can be useful in diagnosing wooden and plastic foreign bodies. Ultrasonography represents a complementary test. The medical treatment consists of tetanus prophylaxis and broad-spectrum systemic antibiotic therapy. Surgical removal of the foreign body depends on the nature and the location of the object. Surgical intervention is indicated if signs of infection or optic nerve compression are evident. Moreover, all organic and poorly tolerated foreign bodies should be surgically removed. Asymptomatic patients with small, nonorganic intraorbital foreign bodies do not require any surgical intervention.

### Retrobulbar Hemorrhage

Orbital hemorrhage in the potential space surrounding the globe may occur after blunt trauma and subsequent injury to the orbital vessels. The orbit is an enclosed space with limited capacity for expansion. The globe and septum can be displaced anteriorly to some extent, giving rise to proptosis. However, this forward movement is limited, and the increased volume results in increased intraorbital pressure and compression of the structures contained in the orbit. Traumatic hemorrhage in the retrobulbar space may lead to acute loss of vision due to central retinal artery occlusion, direct optic nerve compression, or compression of the optic nerve vasculature. Acute retrobulbar hemorrhage is a rare and sight-threatening complication of blunt eye trauma, but it can be reversible when diagnosed and treated promptly.

#### ◆ Presentation

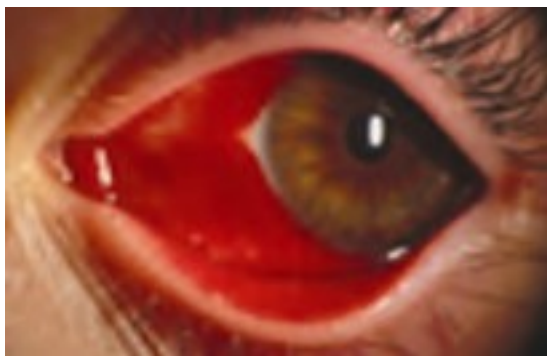Patients usually present with a recent history of trauma or orbital surgery, pain, and decreased vision. Acute retrobulbar hemorrhage gives rise to marked clinical signs: painful exophthalmos or proptosis with resistance to retropulsion, restriction of extraocular movements, diffuse subconjunctival hemorrhage, periorbital edema, and ecchymosis. Intraocular pressure is typically raised. Congested conjunctival vessels, partial or complete ophthalmoplegia, afferent pupillary defect, and color vision disturbances may also be present. An orbital computed tomographic scan demonstrates a retrobulbar hematoma (**Fig. 1.24**).

### ◆Differential Diagnosis

Orbital cellulitis, isolated orbital fracture, globe rupture, carotid cavernous fistula, and varix

### ◆Management

Computed tomography is the imaging study of choice to determine retrobulbar hemorrhage and associated orbital injuries. However, it should be delayed in sight-threatening cases. Medical therapy consists of ocular hypotensive medications, but it is considered an ancillary procedure for patients presenting with increased orbital pressure and decreased vision. These patients should undergo emergent decompression of the orbital space via surgical drainage. Surgical procedure consists of lateral canthotomy and cantholysis. Early recognition and prompt surgical intervention preserve and restore vision in most cases.



**Fig. 1.24** Retrobulbar hemorrhage.

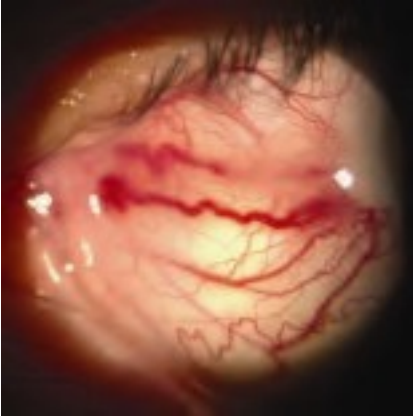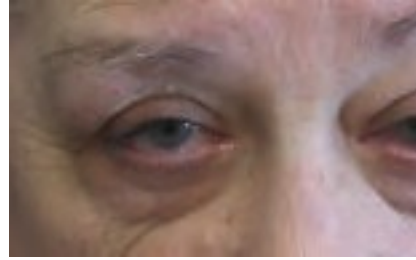### Posttraumatic Pulsating Exophthalmos

The classic clinical picture of pulsating exophthalmos, which is a rare condition, can be produced by posttraumatic carotid-cavernous fistulas. Cerebral traumas account for 75% of carotid-cavernous fistulas, which are initiated by tears in the walls of the intracavernous internal carotid artery or its branches. Thus arterial blood may short-circuit in the venous complex of the cavernous sinuses. Other causes of pulsating exophthalmos are congenital arteriovenous malformations, arteriosclerosis-related retrobulbar aneurysms, and neurofibromatosis.

### ◆Presentation

Patients typically complain, days or weeks after trauma, of a severe and sudden cephalic and orbital pain, a roaring sound in the head synchronous with the pulse, decreased vision, diplopia, and ophthalmoplegia. The pulsating exophthalmos is usually reducible. Inspection reveals engorged and chemotic conjunctiva. Palpation of the eye discloses a thrill, and auscultation reveals an ocular or cephalic bruit synchronous with the pulse. Other ocular signs include dilated retinal veins, disk edema, retinal vein occlusions, venous stasis retinopathy, and increased intraocular pressure due to altered outflow in the vortex veins (**Fig. 1.25A,B**).

A



**Fig. 1.25 (A)** Posttraumatic carotid cavernous fistula. **(B)** Engorged vessels and chemotic conjunctiva in a

patient with a traumatic carotid cavernous fistula.

#### ◆Differential Diagnosis

Pulsating exophthalmos that is not trauma related

#### ◆Management

A complete ophthalmological examination should be performed, including dilated fundoscopic examination and intraocular pressure measurement. The function of cranial nerves III, IV, and VI should be tested. The diagnosis can be confirmed by echography, digital angiography, and computed tomography. Therapy is directed to thrombosis of the fistula and normalization of orbital hemodynamics via transorbital or transvenous embolization. The increase in intraocular pressure can be initially treated medically.