

Strabismus

Introduction

Actions of the extraocular muscles depend on the position of the globe at the time of muscle contraction.

3 types of eye movements are:

- Ductions
- Versions
- Vergences

Ductions

Ductions are monocular eye movements – **adduction, abduction, elevation** (sursumduction), **depression** (deorsumduction), **intorsion and extorsion**.

Agonist is the primary muscle moving the eye in any direction.

Synergist is a muscle acting in conjunction with the agonist.

Antagonist acts in opposite direction to the agonist.

Sherrington 's law

This law about reciprocal innervation states that increased innervation and contraction of a muscle is automatically associated with reciprocal decrease in innervation and contraction of its antagonist.

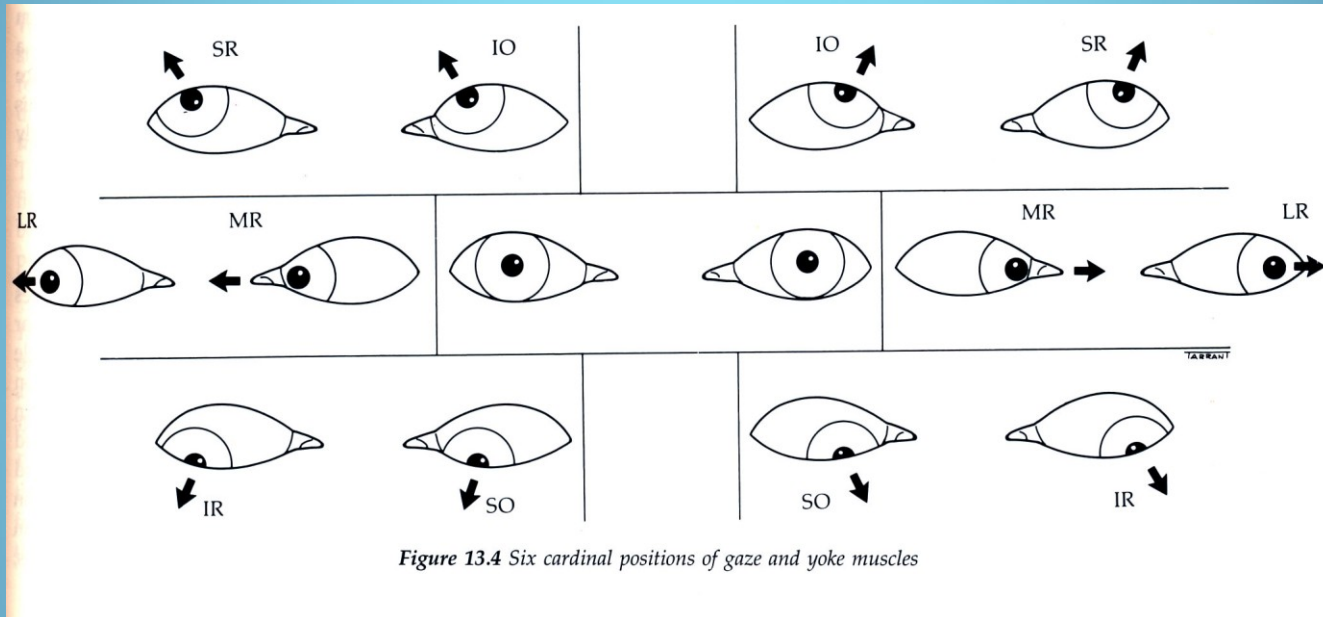
Versions

Versions are binocular movements in which two eyes move synchronously and symmetrically in the same direction as follows:

- **Dextroversion** (right gaze), **laevoversion** (left gaze), **sursumversion** (up-gaze), **deorsumversion** (down-gaze). These 4 movements bring the eyes into the secondary positions of gaze.
- **Dextroelevation** (gaze up and right), **dextrodepression**, **laevoelevation**, **laevodepression** = tertiary positions of gaze.
- **Dextrocycloversion** (rotation of the superior limbus of both eyes to the right) and **laevocycloversion** (rotation to the left).

6 cardinal positions of the gaze: dextrovesrion, laevoversion, dextroelevation, laevoelevation, dextrodepression and laevodepression.

Six cardinal positions of gaze and yoke muscles



Yoke muscles and Hering 's law

Yoke muscles

When the eyes are moving into each of the 6 cardinal positions of gaze, a muscle of one eye is paired with a yoke muscle of the opposite eye.

Hering 's law

States that during any conjugate eye movement, equal and simultaneous innervation flows to the yoke muscles

Vergences

Vergences are binocular movements in which the two eyes synchronously and symmetrically in opposite direction

Convergence = the ability of two eyes to turn inwards

Divergence = the ability to turn outwards from a convergent position

Binocular single vision (BSV)

BSV is achieved when both eyes are used together. Slightly dissimilar images, arising in each eye, are appreciated as a single image by the process of fusion.

In addition, this synthesis also results in 3-D vision (stereopsis).

BSV is acquired and reinforced during the first few years of the life.

Requires **3 factors** for its development:

1. Clear vision in both eyes
2. Ability of the visual areas in the brain to promote fusion of the two slightly dissimilar images
3. Precise coordination of the two eyes for all directions of gaze

Double vision

A squint is a misalignment of the visual axes which may be latent (phoria) or manifest (tropia). A manifest deviation may cause:

- Diplopia

Compensatory mechanisms for double vision:

- Suppression – „active neglect“ of the vision by the visual cortex in the squinting eye
- Strabismic amblyopia – as a result of continued monocular suppression of the deviated eye
- Abnormal head posture – to turn the eyes as far as possible from the field of action of the weak muscle

Clinical evaluation

- **History**: age of onset, family history, diplopia, abnormal head posture
- **Visual acuity**
- **Reflection test**: deviation of corneal light reflex
- **Cover tests**: cover-uncover test and alternate cover test
- **Maddox** and **Hess** test
- **Test of binocular cooperation** (Worth 's four – dot test, Bagolini striated glasses, synoptophore)
- **Tests for stereopsis** (Titmus test, TNO random test)

Examination

Visual acuity

Type of test depends on age of the child.

E test, Kay picture test

Cover test




Figure 13.11 Kay picture test

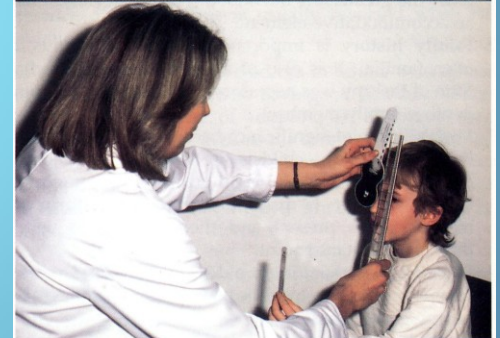
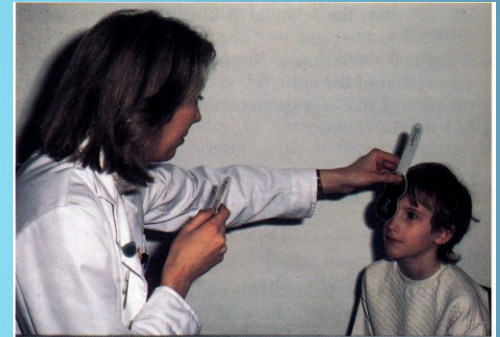

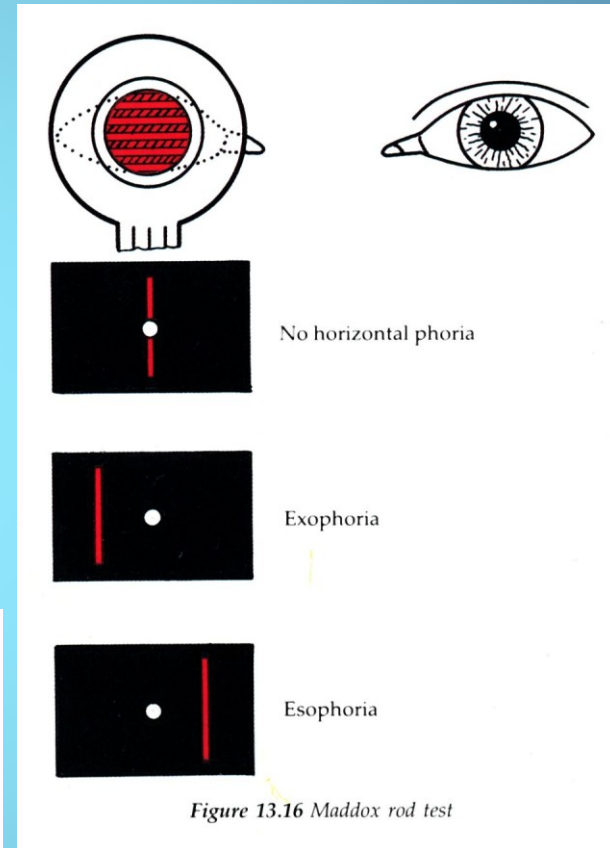

Figure 13.14 Top: cover-uncover test; middle and bottom: prism and alternate cover test

Examination

Maddox wing

Disociates the two eyes
for near fixation and
measures the amount
of heterophoria

Titmus test



Examination

Hess test

is a dissimilar image test which is used in patients with parietic deviation



Figure 13.18 Lees screen

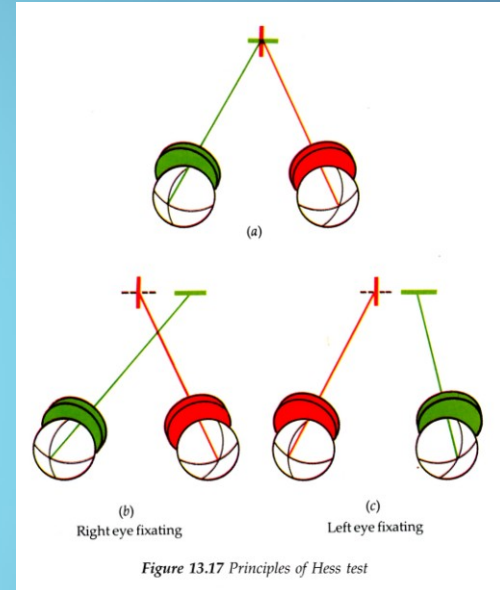


Figure 13.17 Principles of Hess test

Worth 's four-dot test

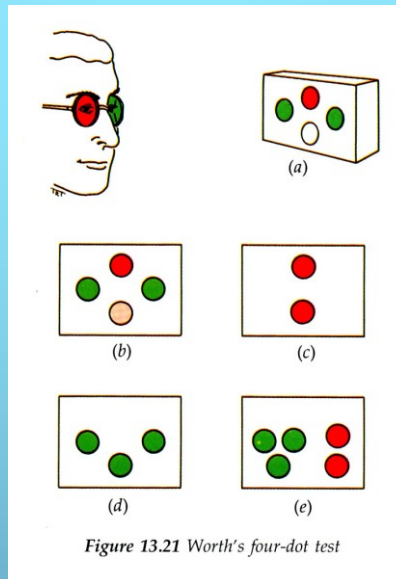


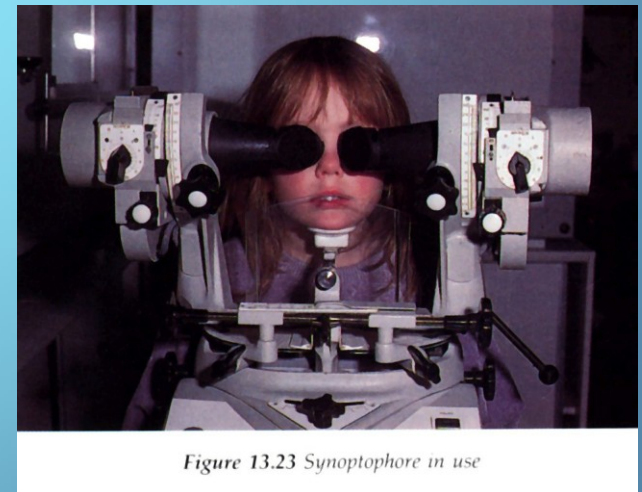
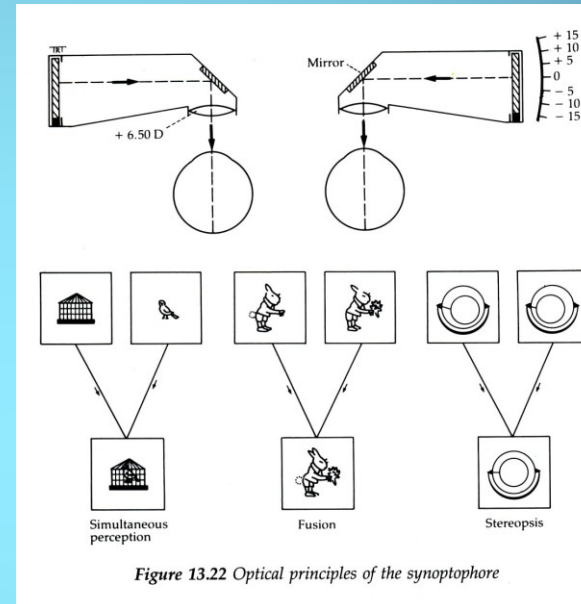
Figure 13.21 Worth's four-dot test

Examination

Synoptophore

two cylindrical tubes with a mirrored right-angled bend and a +6,5D lens in each eyepiece.

Synoptophore can determine the 3 grades of BSV (simultaneous perception, fusion and stereopsis)



Clinical Features

Esotropias

- **Infantile esotropia**
- **Accommodative esotropia** (refractive, non refractive, mixed)
- **Non-accommodative esotropia** (stress-induced, sensory deprivation, divergence insufficiency, spasm of near reflex, consecutive, sixth nerve palsy)

Exotropias

- **Intermittent**
- **Constant** (congenital, decompensated intermittent, sensory deprivation, consecutive)

Clinical features

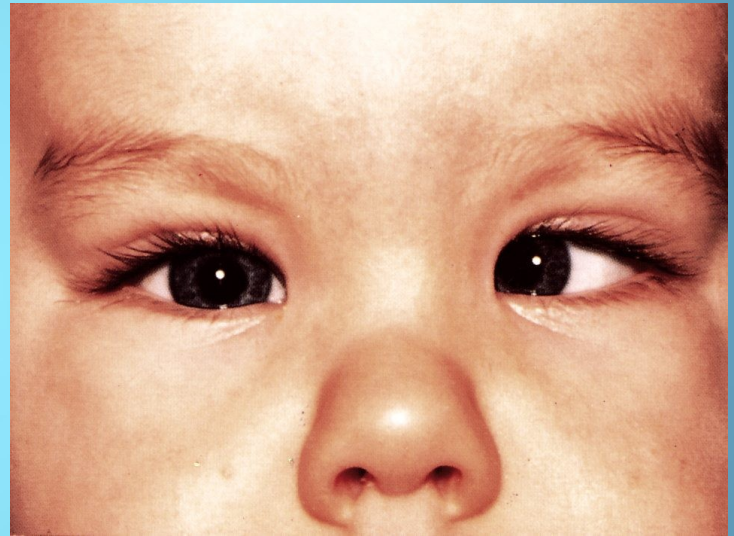Esotropias

- **Infantile esotropia**

Presentation is within the first 6 months of birth in an otherwise normal infant

Management

surgery (recession of both medial recti)



Clinical features

- Accomodative esotropia

Becomes manifest at
about the age of 2,5
years

Management
refraction

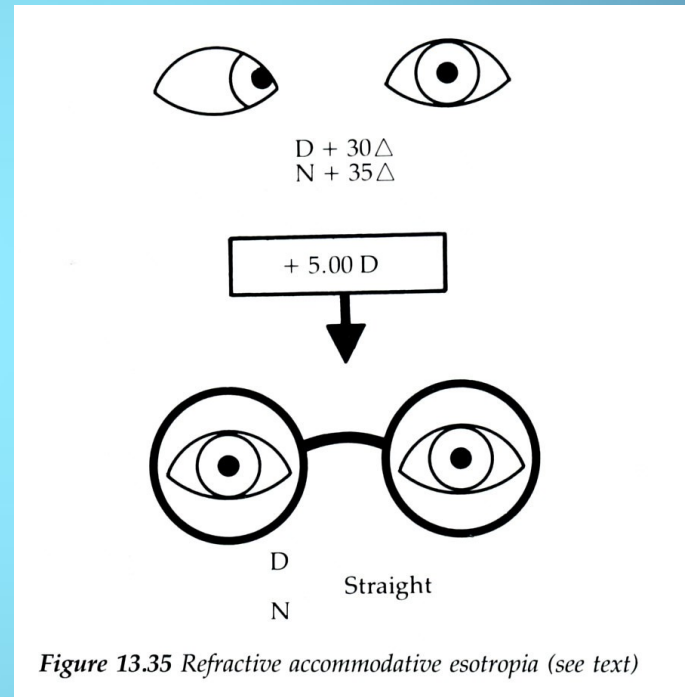


Figure 13.35 Refractive accommodative esotropia (see text)

Clinical features exotropias

- **Intermittent**

Fluctuation between
phoria and tropia

Management

Spectacles, orthoptic
treatment, surgery
(recessions of both
lateral recti)

- **Constant**

Presentation is present at
birth, in contrast to
infantile esotropia

Treatment

Surgical bilateral medial
rectus resection

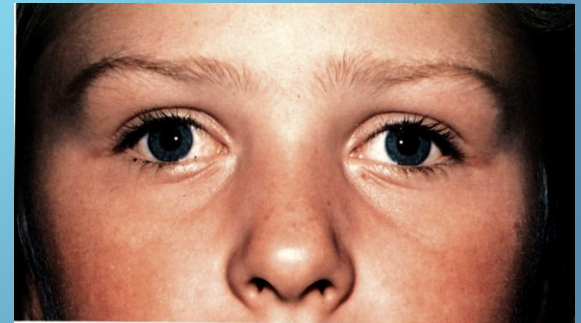

Figure 13.41 Right divergent strabismus

Principles of strabismus surgery

Weakening procedures

- Recession
- Marginal myotomy
- Myectomy
- Posterior fixation suture

Strengthening procedures

- Recession
- Tucking
- Advancement

- Procedures changing direction of muscle action (transposition of the horizontal recti)

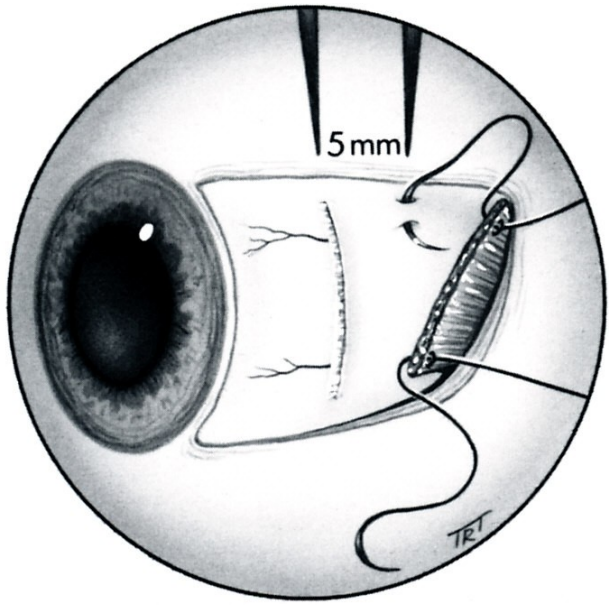


Figure 13.44 Recession of horizontal rectus muscle

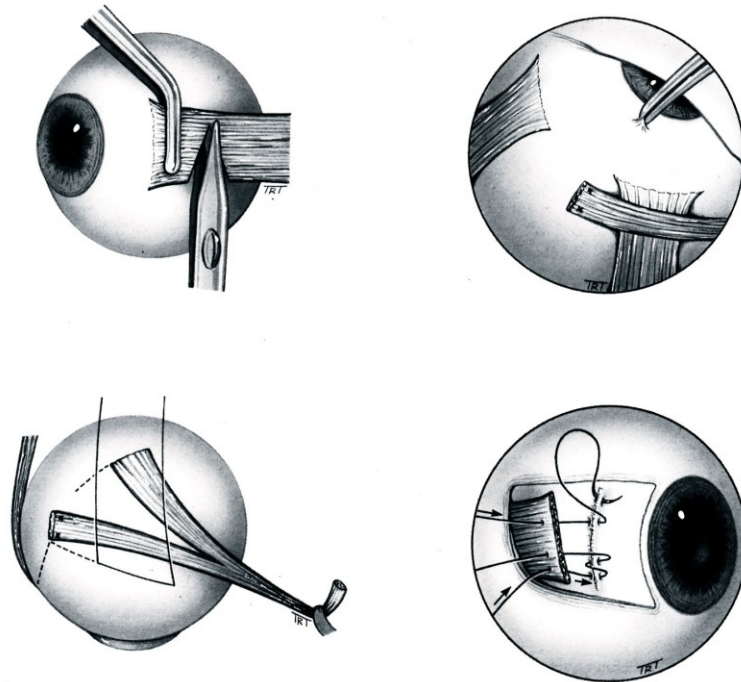


Figure 13.45 Top left: marginal myotomy; top right: inferior oblique recession; bottom left: advancement of anterior half of superior oblique tendon; bottom right: resection of horizontal rectus muscle