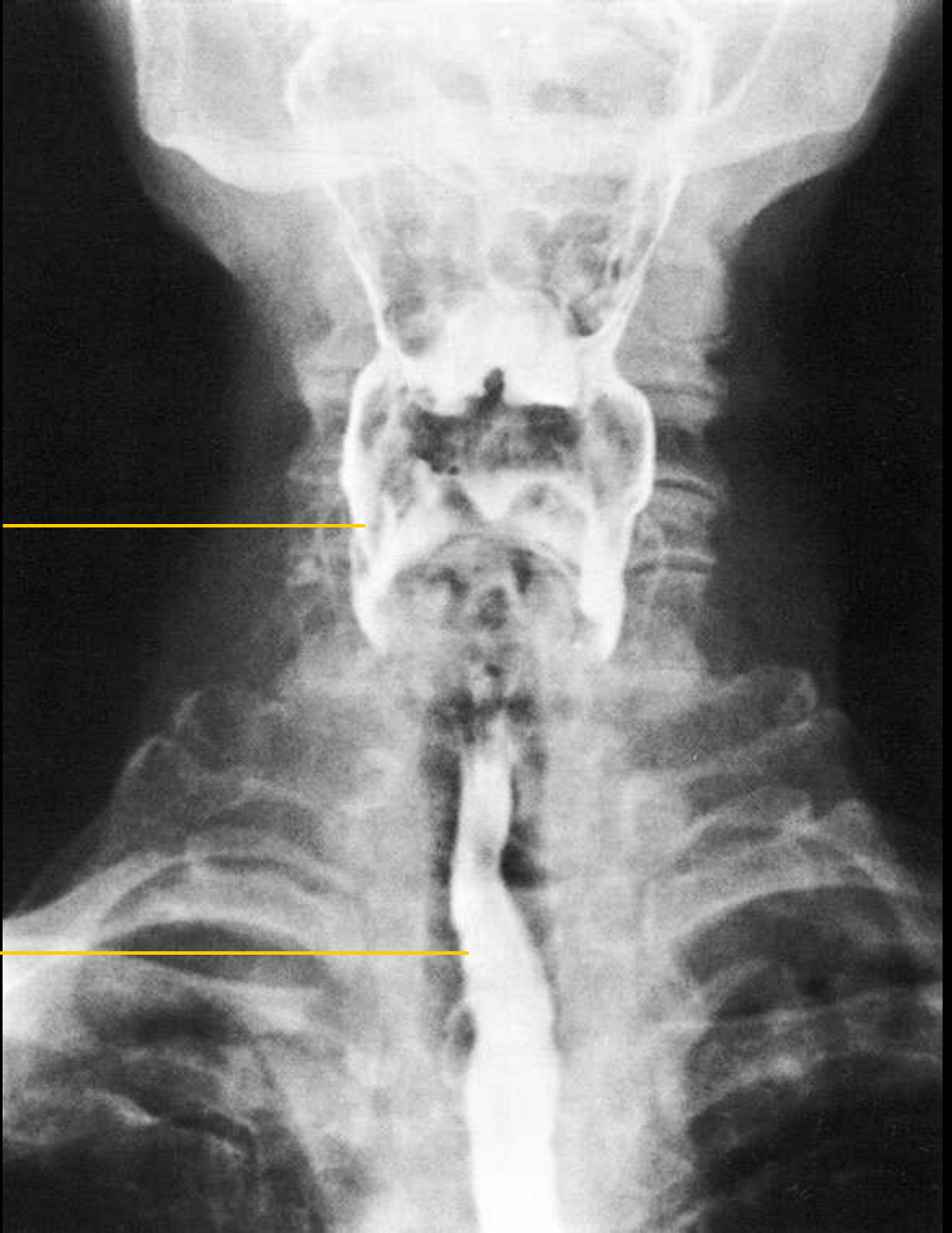


# Oesophagografie

sagitální projekce

**hltan**  
(recessus  
piriformis)

**jícen**



# Oesophagografie

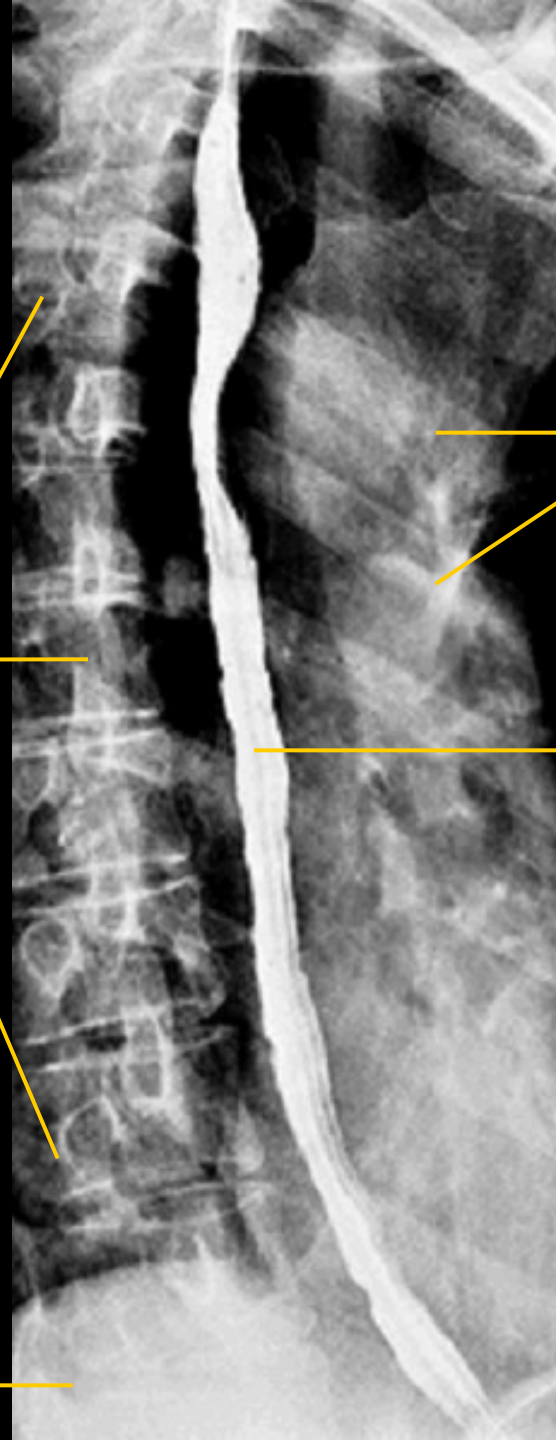
boční projekce

hrudní obratle

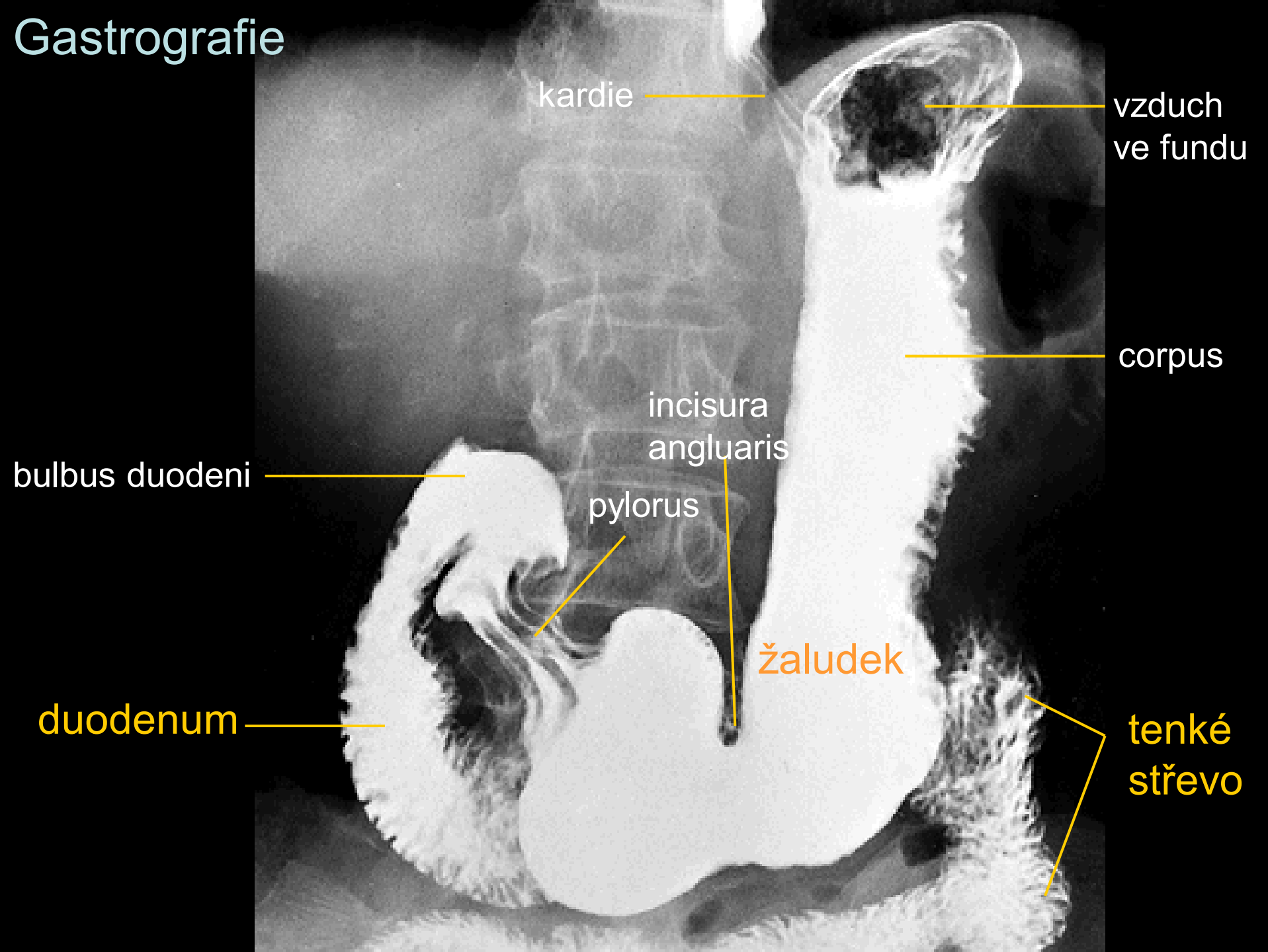
žebra

jícen

bránice



# Gastrografie



kardie

vzduch  
ve fundu

corpus

incisura  
angularis

bulbus duodeni

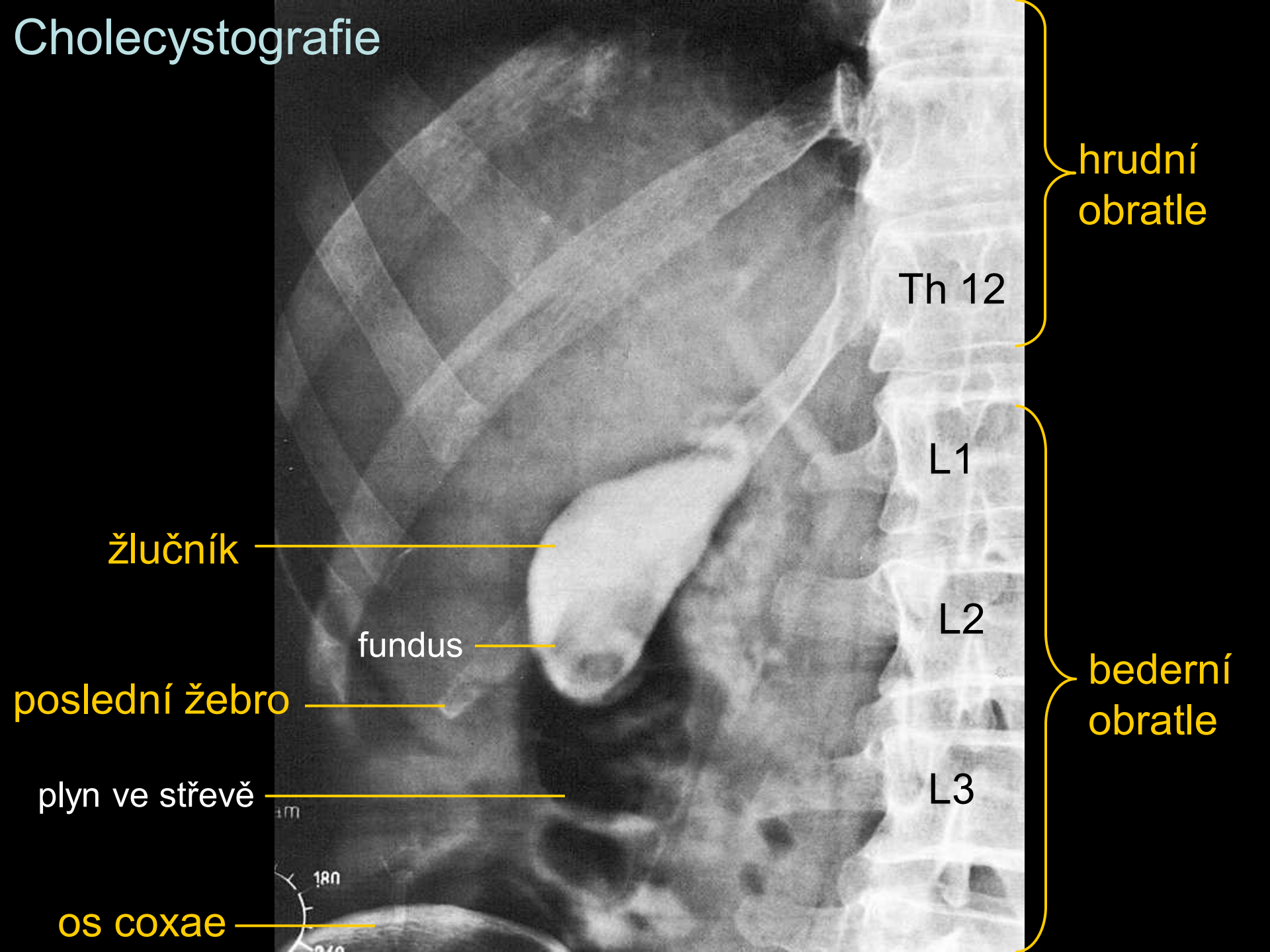
pylorus

žaludek

duodenum

tenké  
střevo

# Cholecystografie



hrudní  
obratle

Th 12

L1

L2

bederní  
obratle

L3

žlučník

fundus

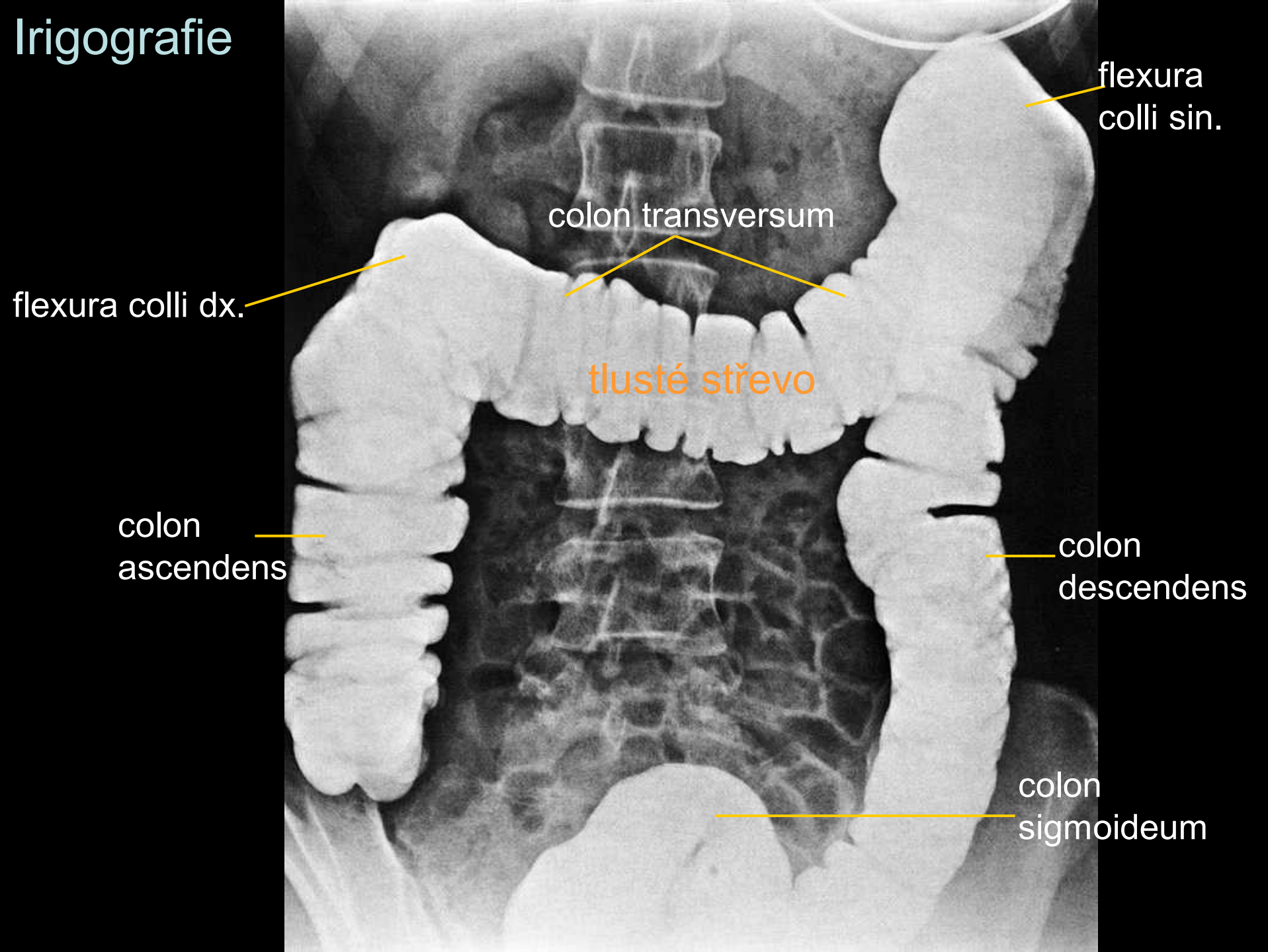
poslední žebro

plyn ve střevě

os coxae



# Irigografie



flexura  
colli sin.

colon transversum

flexura colli dx.

tlusté střevo

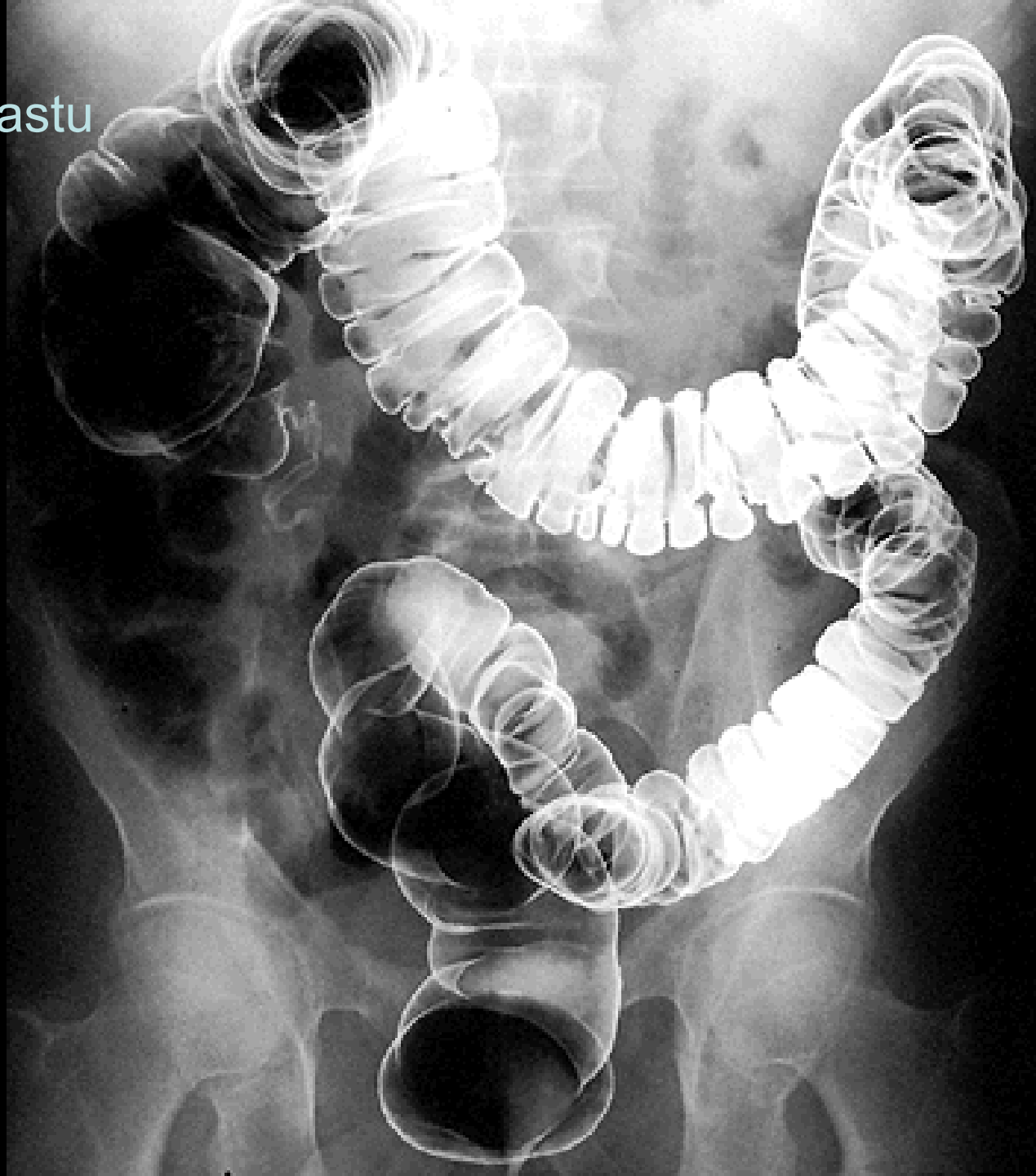
colon  
ascendens

colon  
descendens

colon  
sigmoideum

# Irigografie – metoda dvojího kontrastu

Chemický čistý síran  
barnatý + vzduch



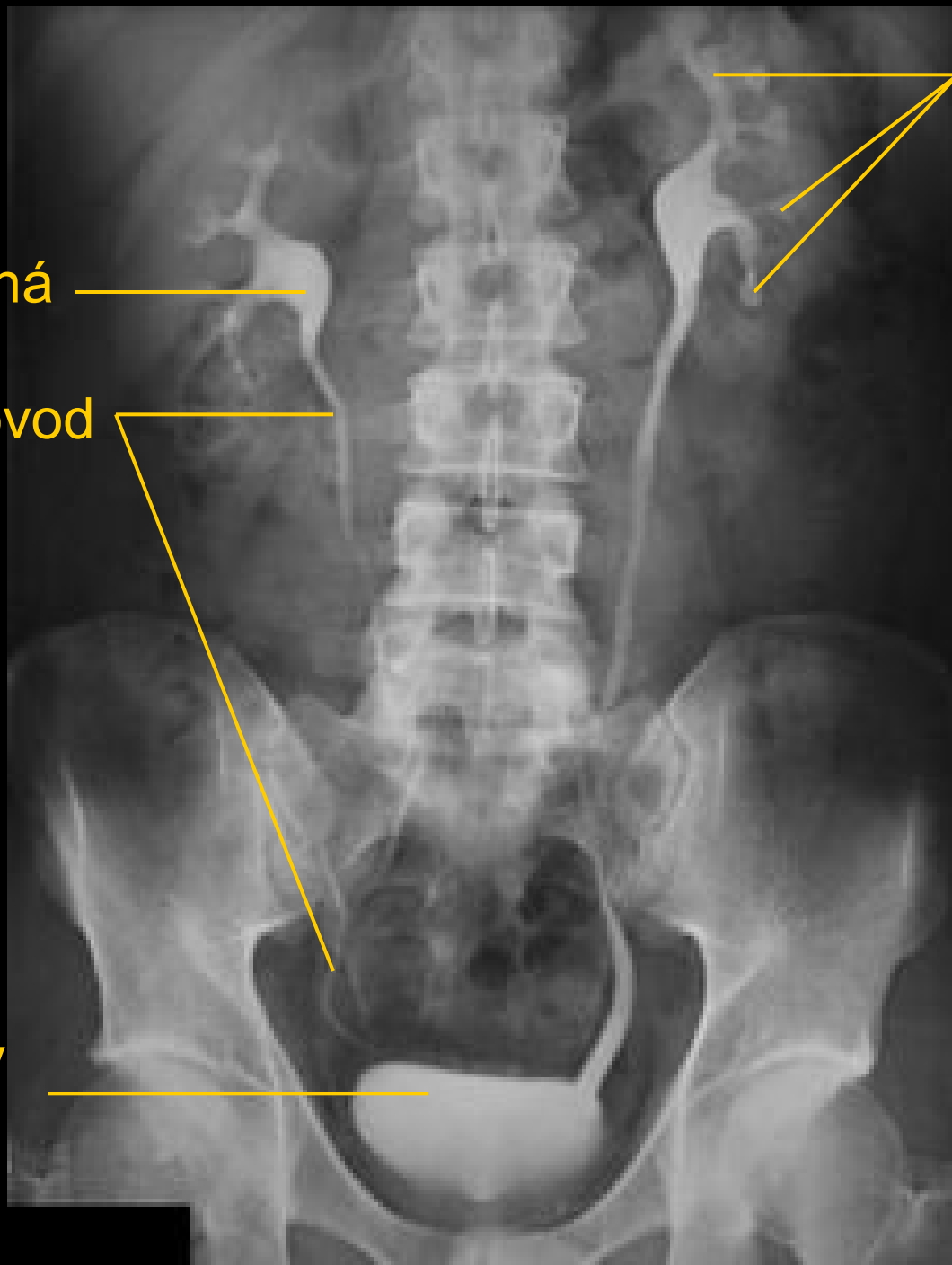
# Vylučovací urografie

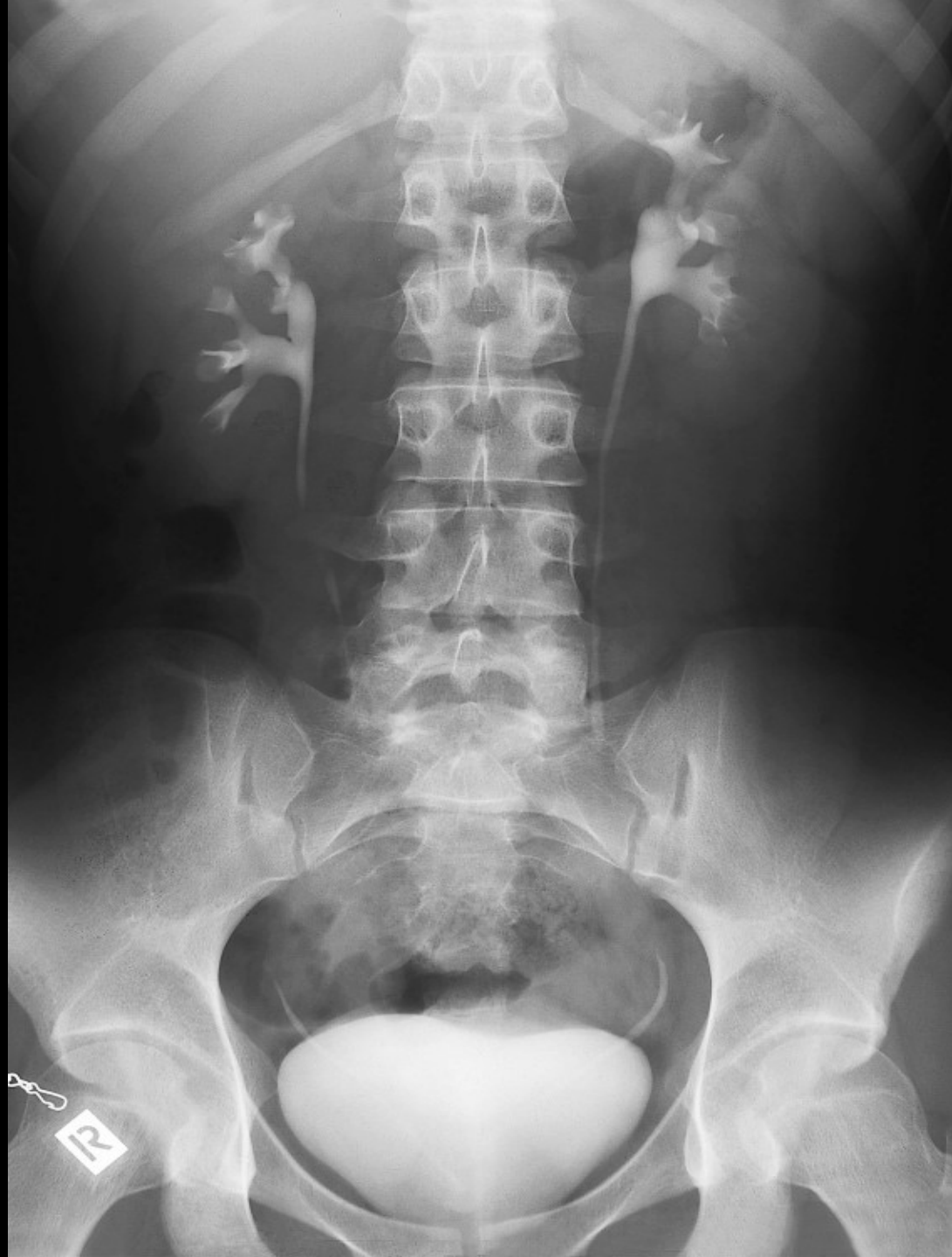pánvička ledvinná

močovod

močový  
měchýř

kalichy  
ledvinné







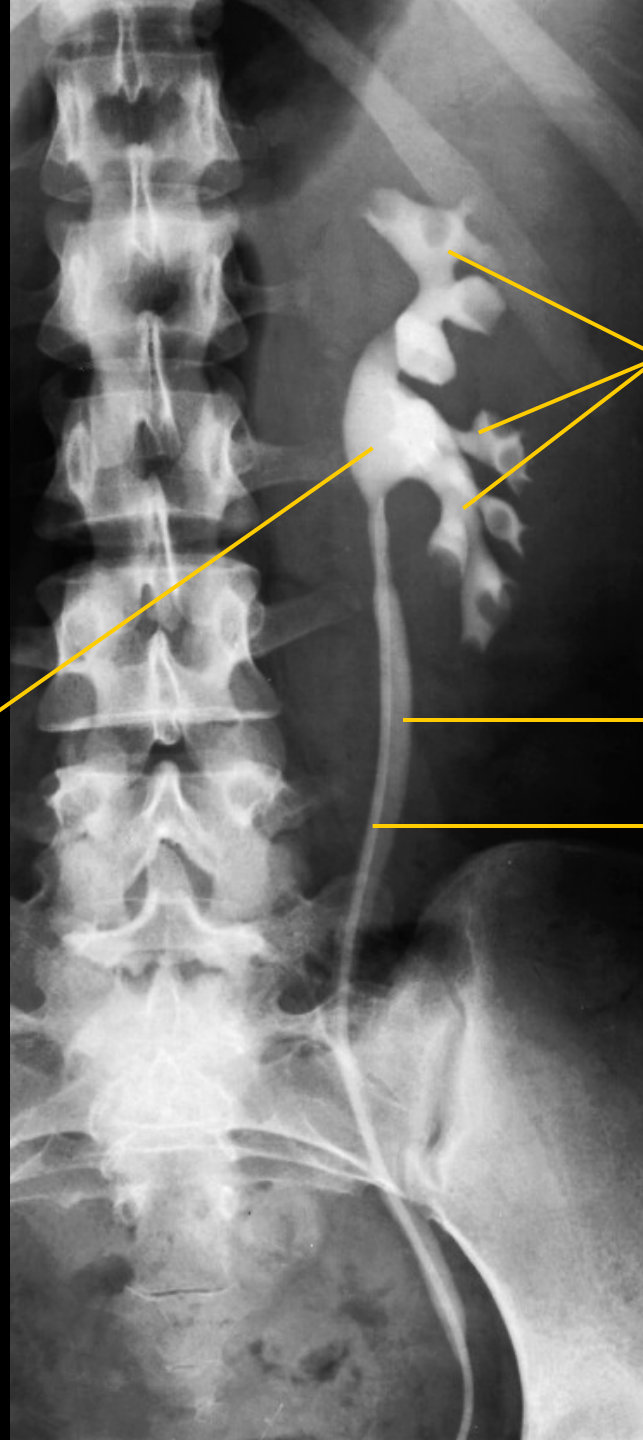
# Ascendentní pyelografie

pánvička ledvinná

kalichy ledvinné

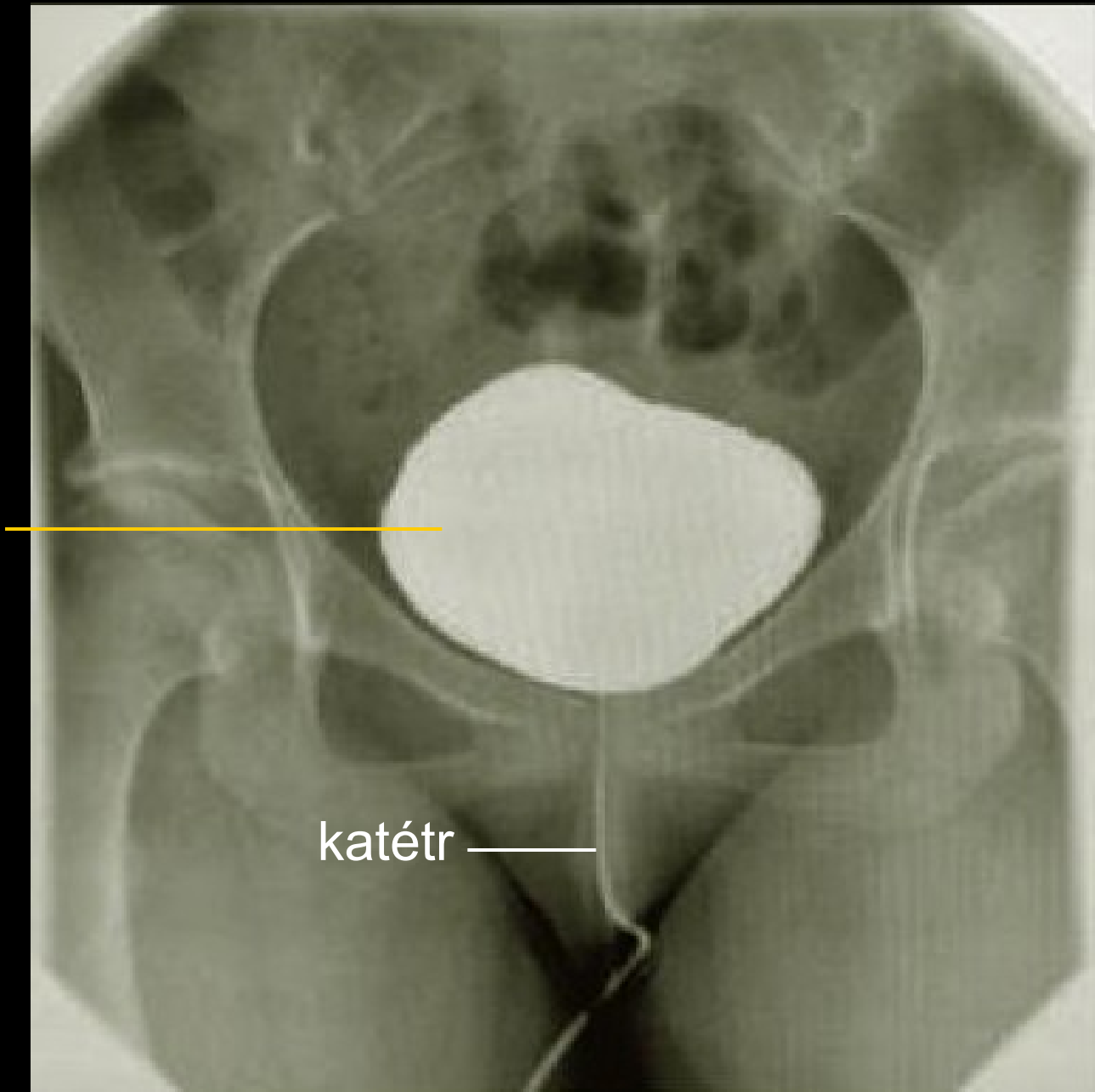
močovod

katétr



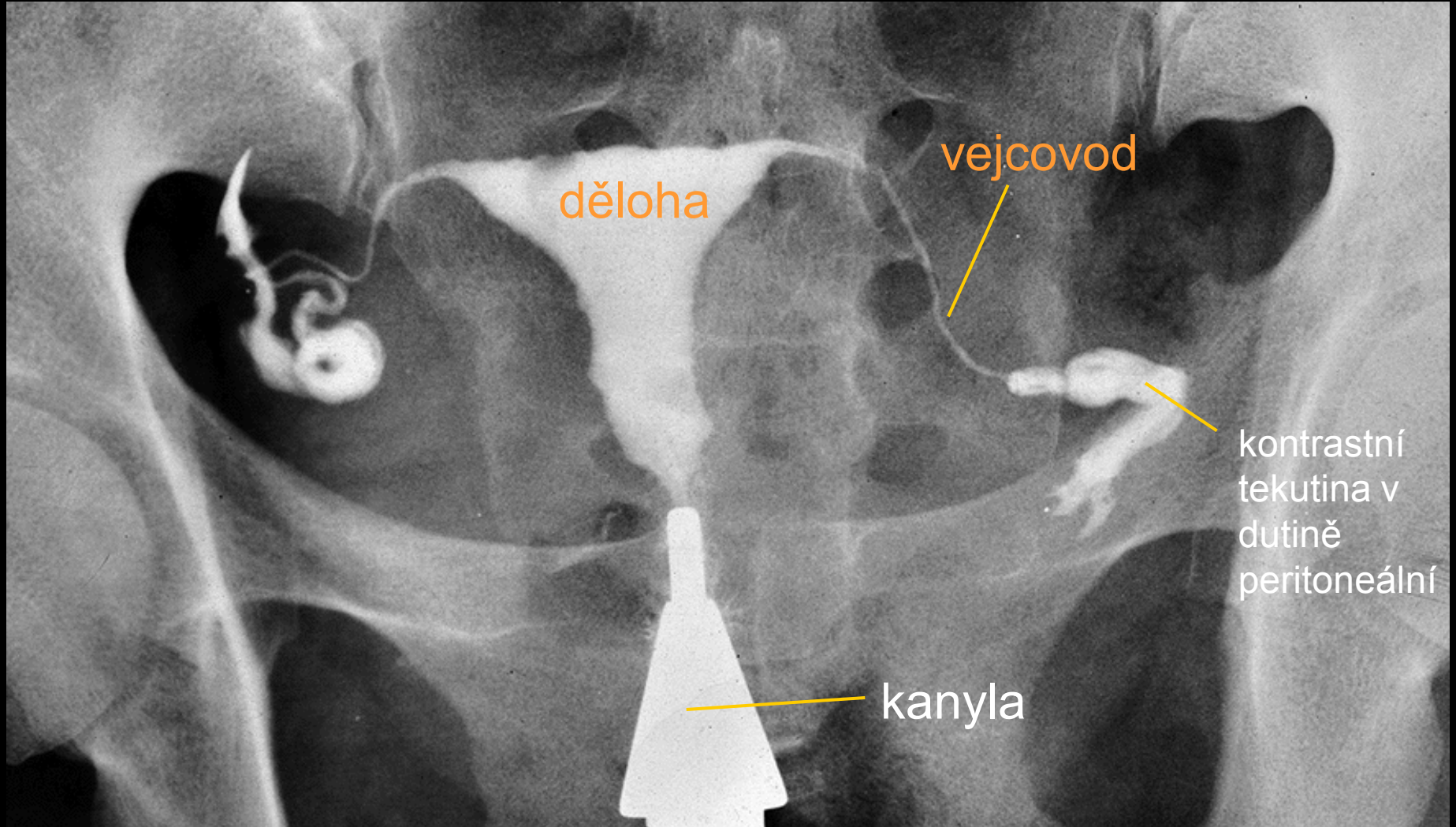
# Cystografie

močový měchýř



katétr

# Hysterosalpingografie



# Angiografie

Arteriogram truncus coeliacus

a. hepatica  
comm.

a. gastrica sin.

a. lienalis

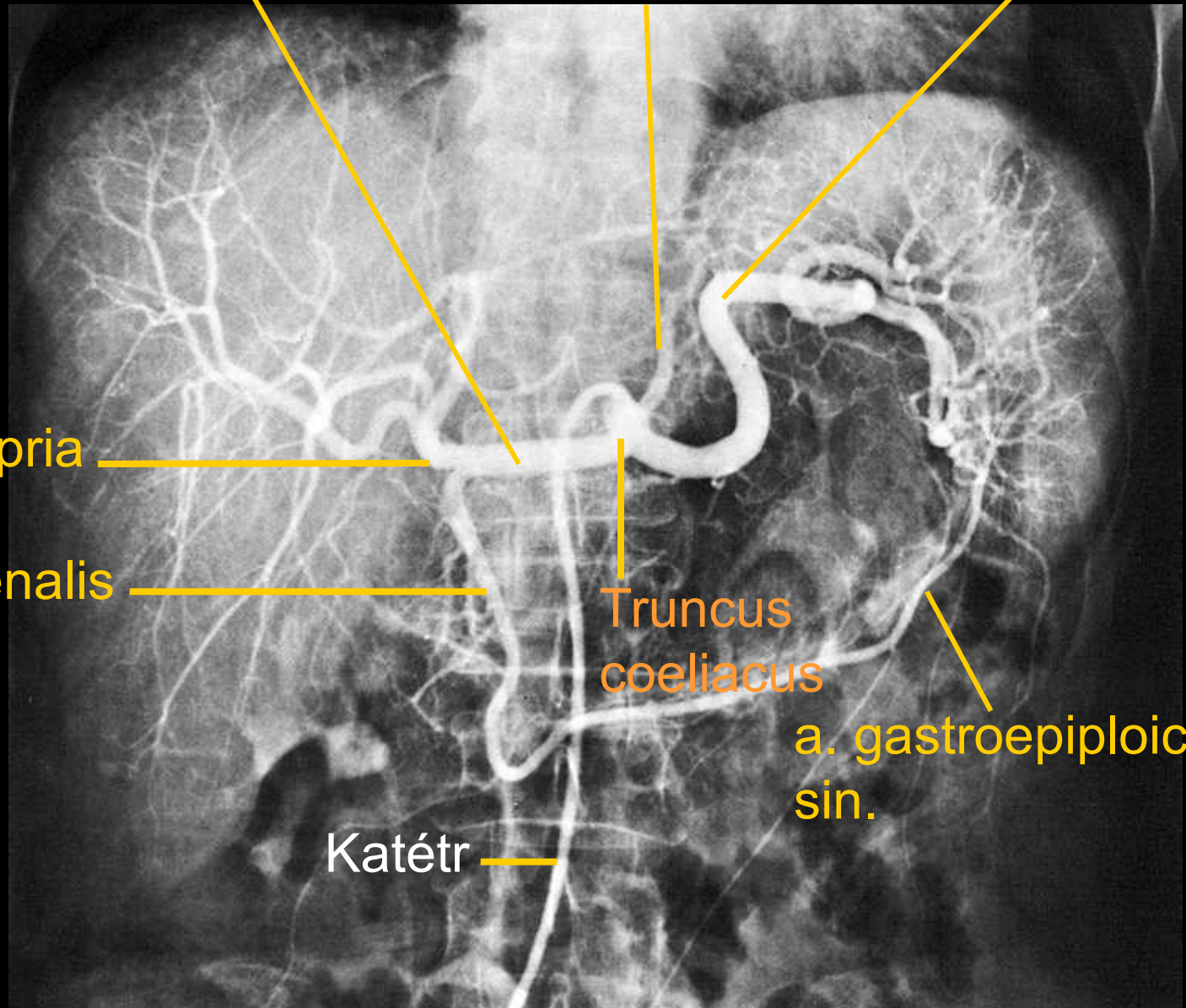
a. hepatica propria

a. gastroduodenalis

Truncus  
coeliacus

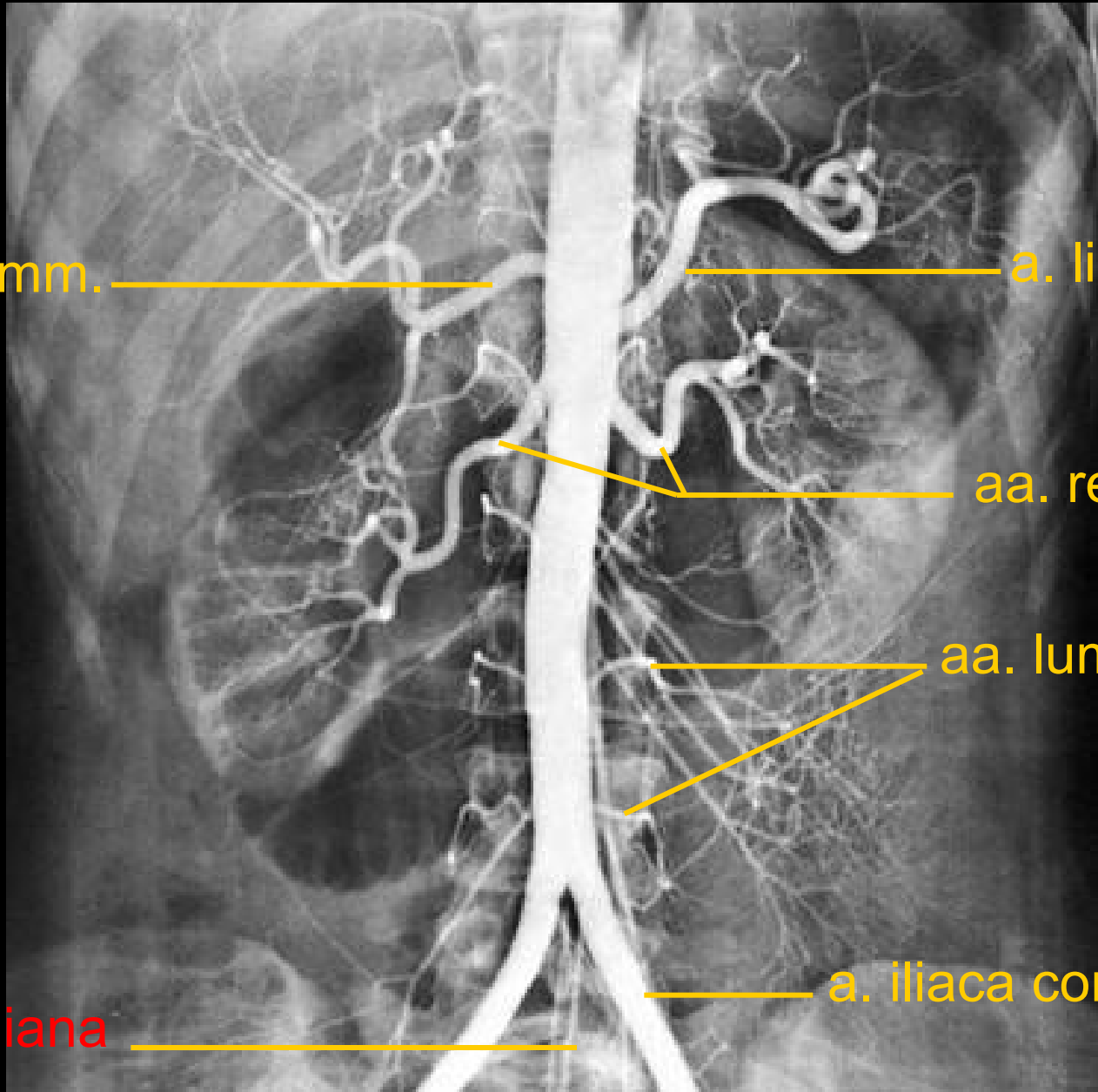
a. gastroepiploica  
sin.

Katétr



# Angiografie

Arteriogram břišní aorty



a. hepatica comm.

a. lienalis

aa. renales

aa. lumbales

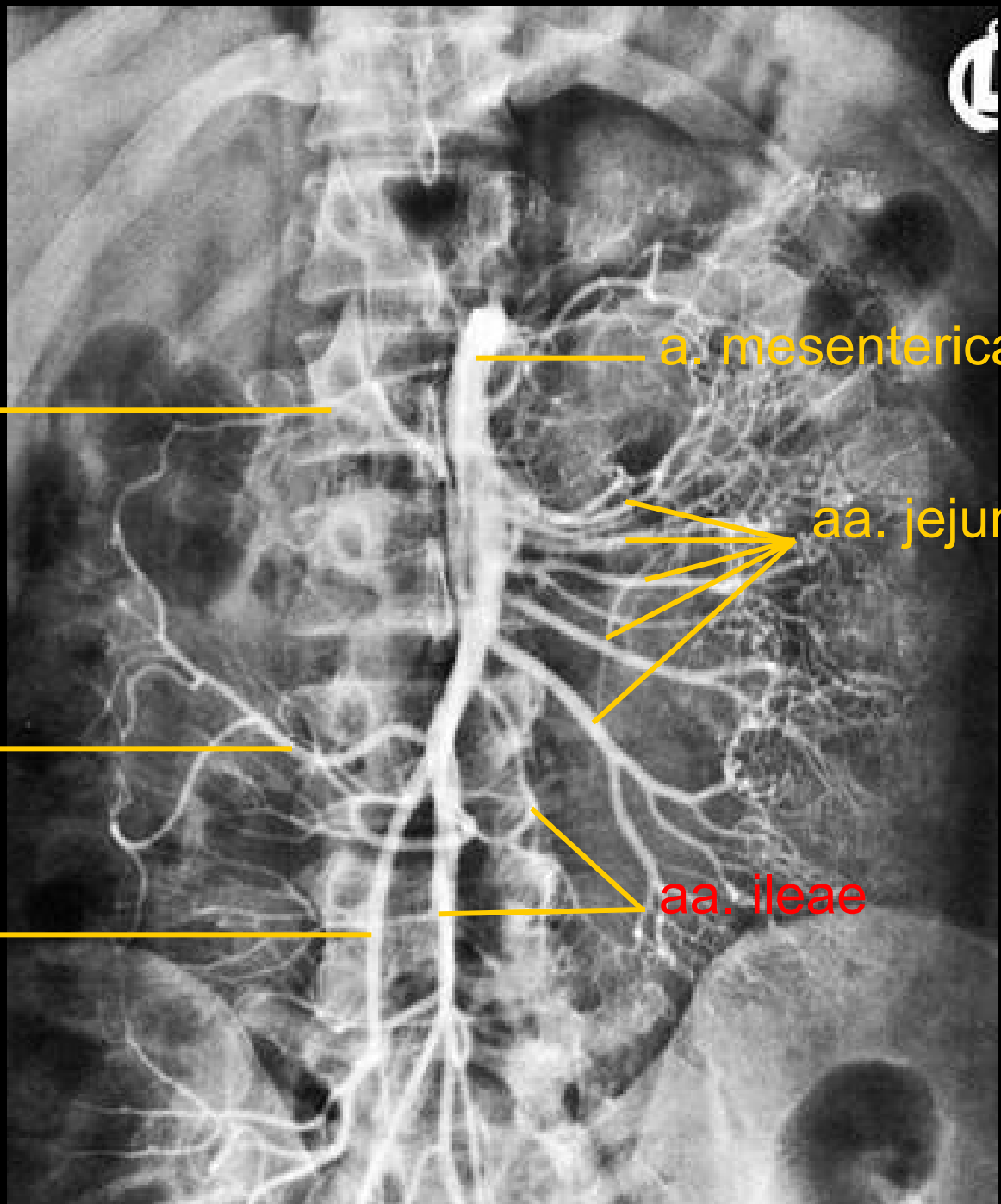
a. iliaca com. sin

a. sacralis mediana



# Angiografie

Arteriogram břišní aorty



a. colica media

a. mesenterica sup.

a. colica dx.

aa. jejunales

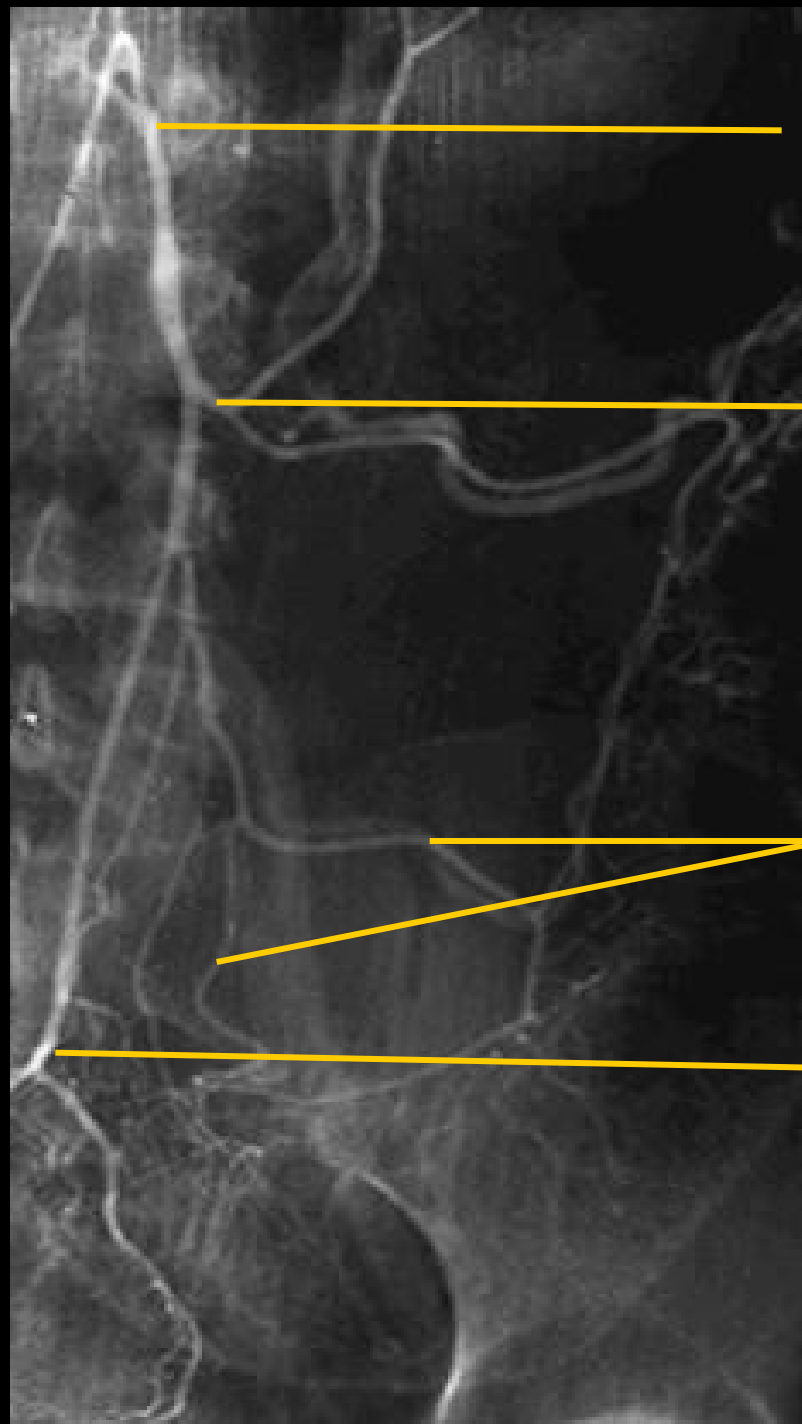
a. ileocolica

aa. ileae



# Angiografie

Arteriogram břišní aorty



a. mesenterica inf.

a. colica sin.

aa. sigmoideae

a. rectalis inf.

# Angiografie

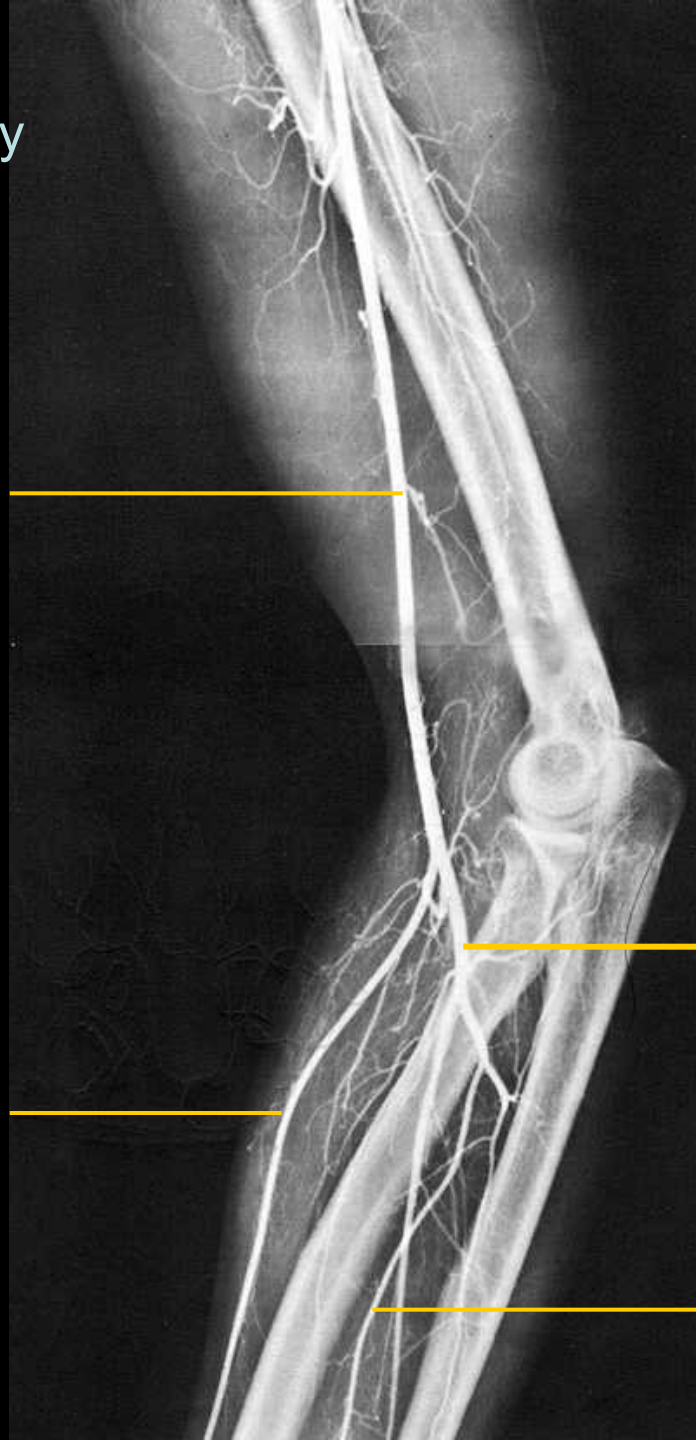Arteriogram horní končetiny

a. brachialis

a. radialis

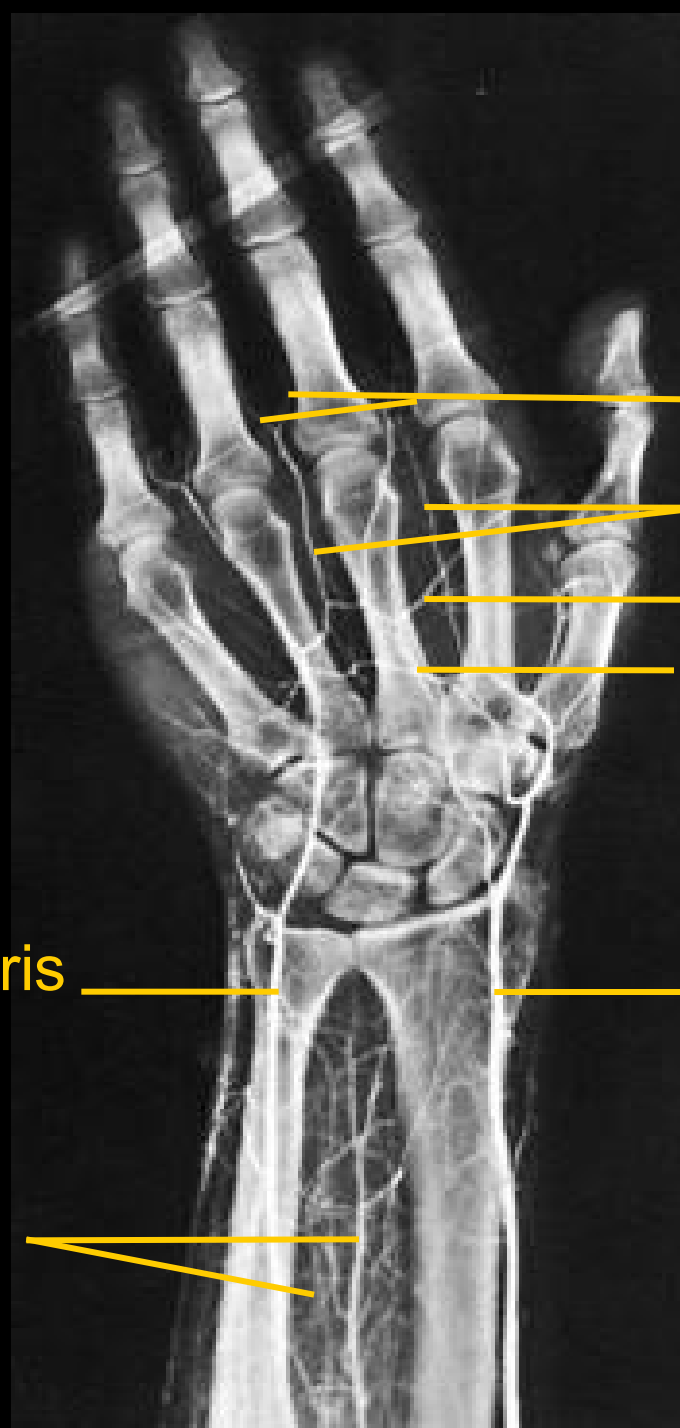
a. ulnaris

a. interossea ant.



# Angiografie

Arteriogram ruky



aa. digit. palm. propr.

aa. digit. palm. comm.

arcus palmaris spf.

arcus palmaris prof.

a. ulnaris

a. radialis

aa. interosseae

# Angiografie

Arteriogram pánve

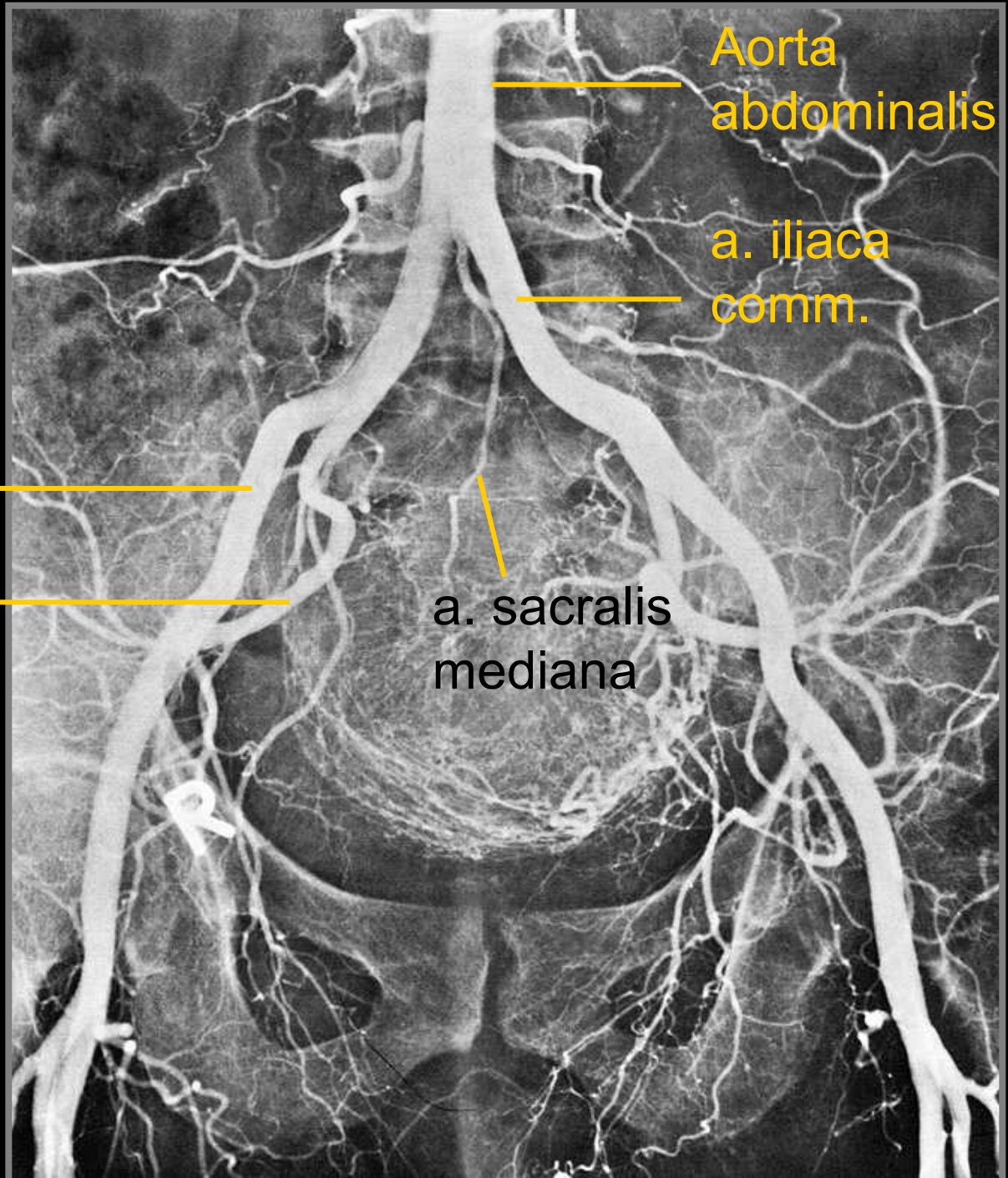
a. iliaca ext.

a. iliaca int.

Aorta  
abdominalis

a. iliaca  
comm.

a. sacralis  
mediana



# Angiografie

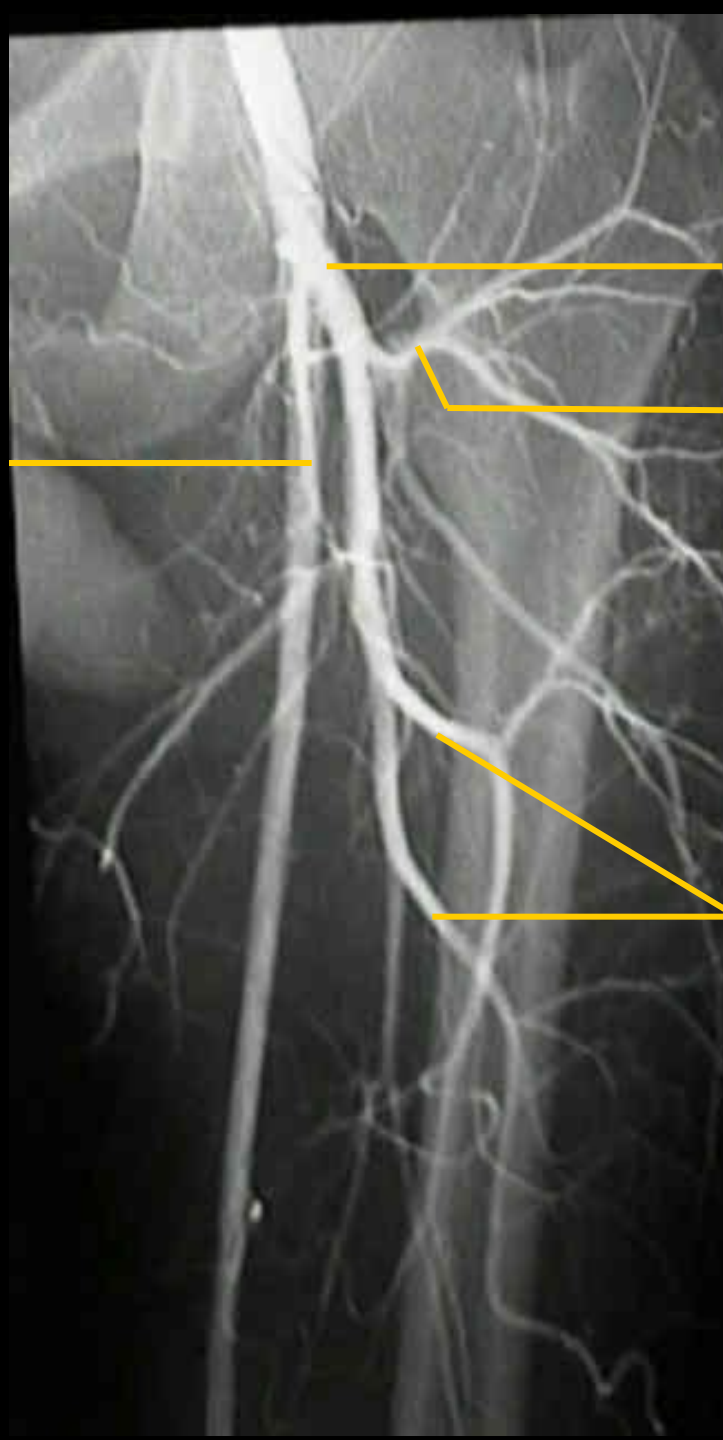
Arteriogram DK

a. femoralis

a. profunda femoris

a. circ. femoris lat.

aa. perforantes



# Angiografie

Arteriogram DK

a. genus desc.

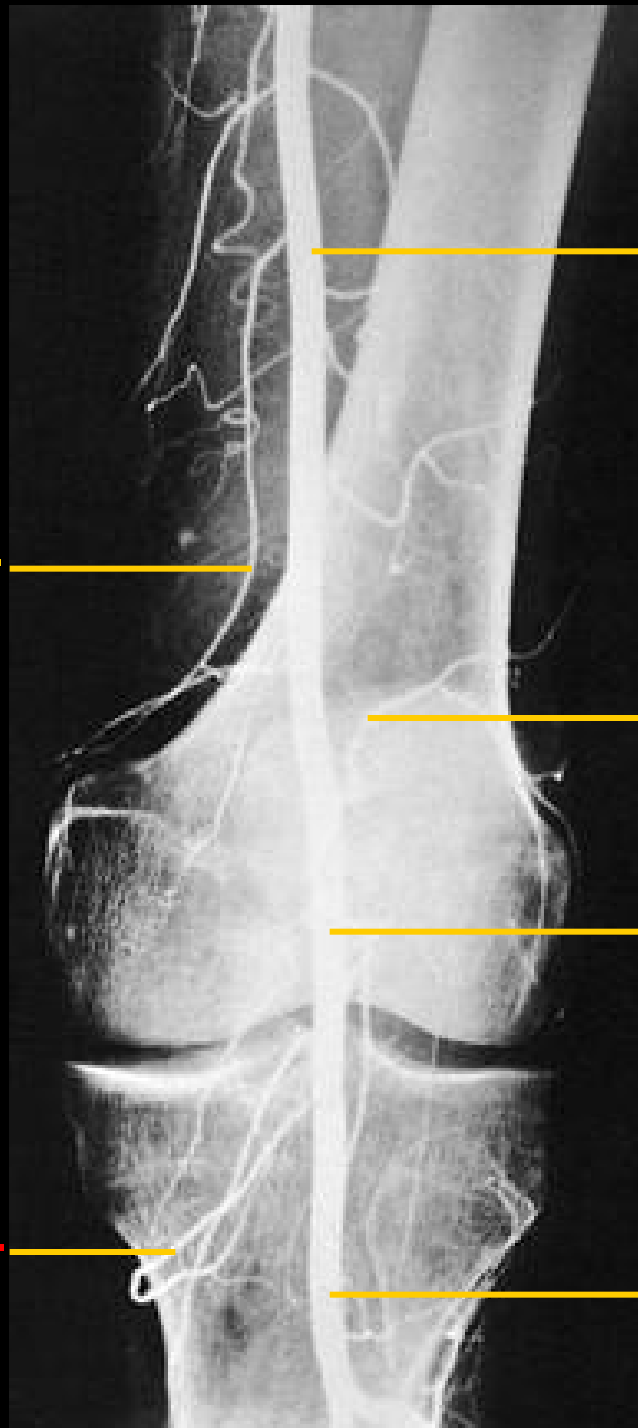
a. genus inf.

a. femoralis

a. genus sup.

a. poplitea

a. tibialis post.





# Angiografie

Flebogram hrudníku

v. jug. int. dx.

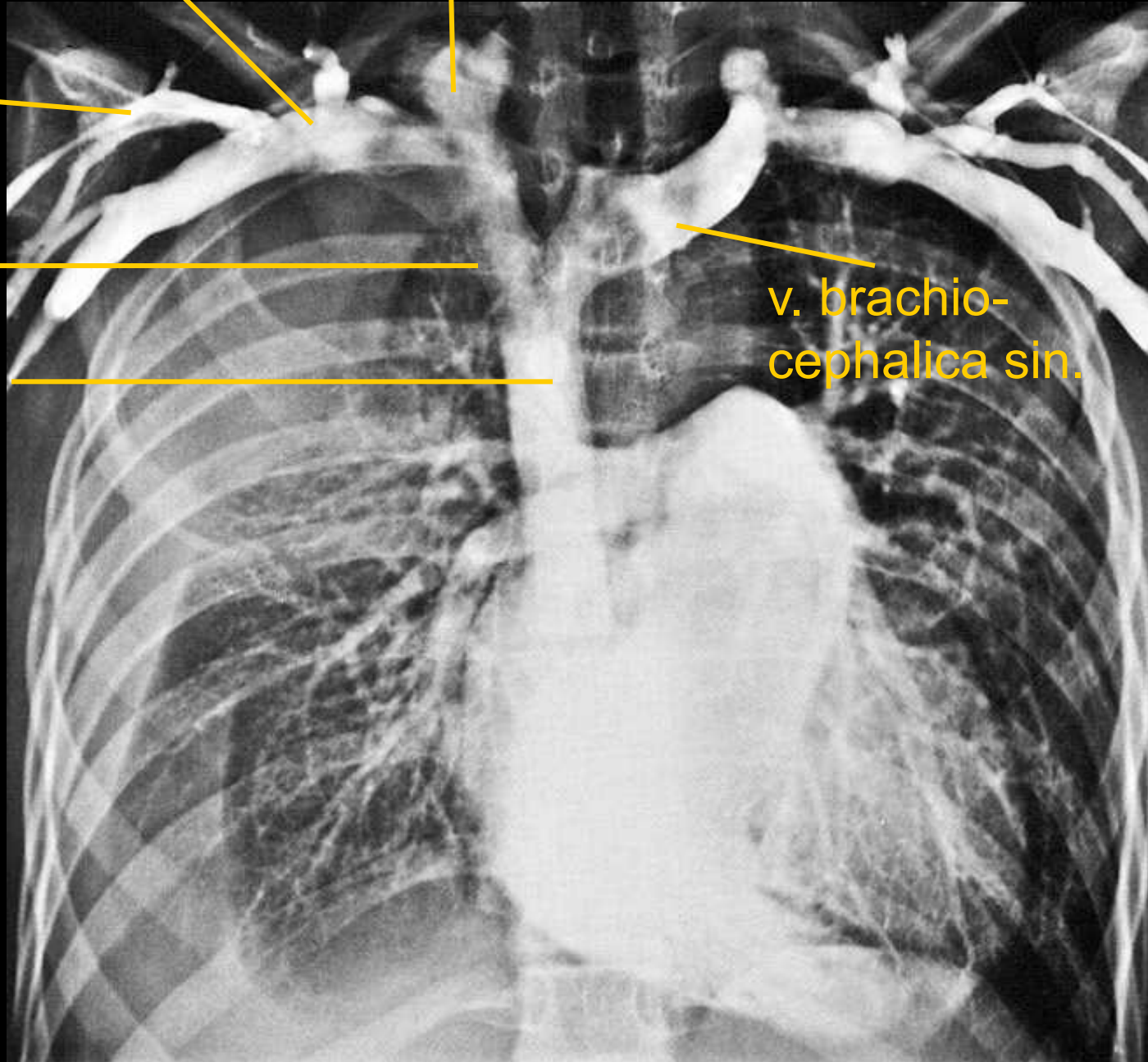
v. subclavia dx.

v. cephalica dx.

v. brachio-  
cephalica dx.

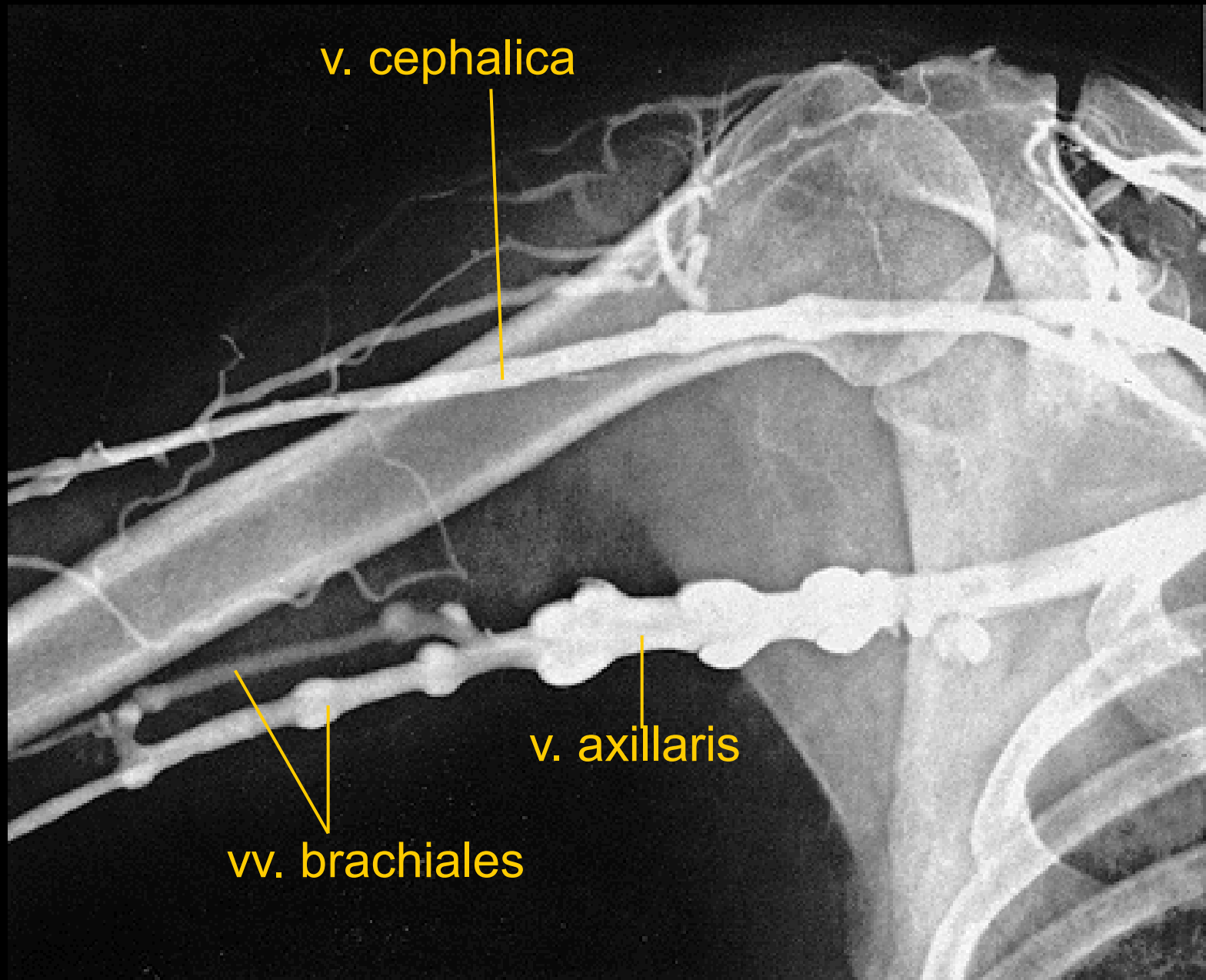
v. cava sup.

v. brachio-  
cephalica sin.



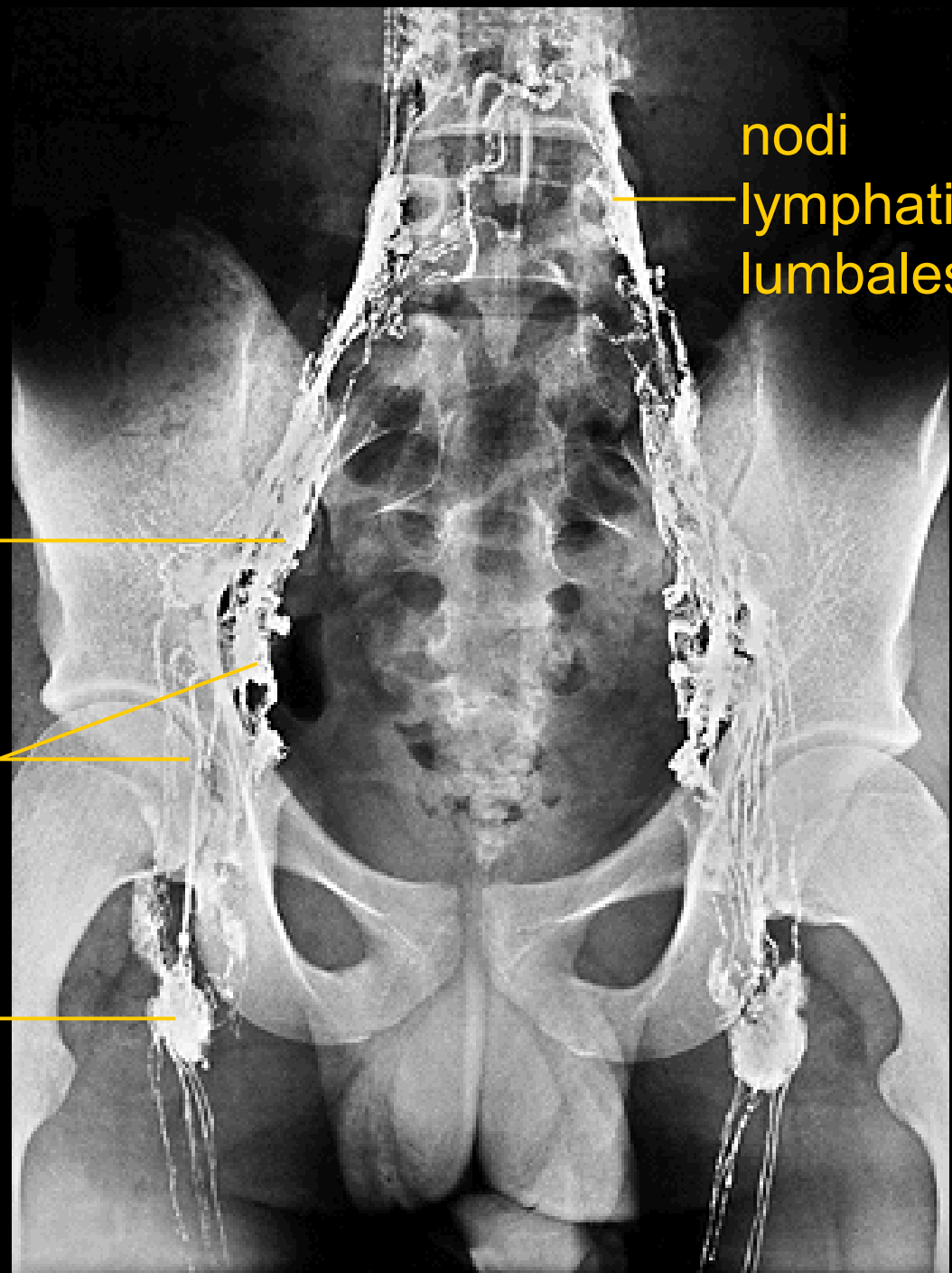
# Angiografie

Flebogram horní končetiny



# Angiografie

Lymfogram břicha a dolní  
končetiny



nodi  
lymphatici  
lumbales

nodi lymphatici  
iliaci communes

nodi lymphatici  
iliaci int. et ext.

nodi lymphatici  
inguinales