

THE CEREBRUM (*telencephalon*)

THE CEREBRUM (*telencephalon*)

- **Developmentally most advanced part of the CNS**
- The largest part of the brain, which gives shape and size

The outer structure of the cerebrum

Cerebral hemisphere (*haemispheria cerebri*): a pair component of the cerebrum - *haemispherium dextrum* and *sinistrum*, each hemisphere is consist of two basic parts:

- **pars basilaris**: is formed by nuclei of grey matter located within the hemisphere, so-called *basal ganglia*
- **pars pallialis**: forms so-called ***pallium*** – mantle, which covers from above basal part, it contains grey matter, so-called **cerebral cortex** and white matter, which lies on basal ganglia within hemisphere

- Cerebral hemisphere is antero-posterior elongated quarter-sphere, both hemispheres form together half-sphere
- Right and left hemisphere are separated from each other in the median plane through a deep fissure (***fissura longitudinalis cerebri***)
- The cerebral hemispheres are separated from cerebellar hemispheres through transversally extending fissure (***fissura transversa cerebri***)
- We distinguish three surfaces on the hemispheres:
facies inferior (inferior surface)
facies medialis (inner surface)
facies superolateralis (outer convex surface)

- on the bottom of fissura longitudinalis cerebri, there is **corpus callosum** (it presents the main and largest commissure of the cerebrum)

The cerebral lobes

Each hemisphere is divided into five lobes:

Frontal lobe (*lobus frontalis*): touches the inner surface of the frontal bone- **polus frontalis**

Parietal lobe (*lobus parietalis*): touches the inner surface of the parietal bone

Occipital lobe (*lobus occipitalis*): touches the inner surface of the occipital bone- **polus occipitalis**

Temporal lobe (*lobus temporalis*): touches the inner surface of the temporal bone

Insular lobe (*lobus insularis*): is located within pit between temporal, frontal and parietal lobes (within *fossa lateralis*), it is not visible on the surface of the brain

- The hemispheres are furrowed on their surface with numerous grooves (***sulci***) and there are created folds (***gyri***), the process of forming grooves and folds is called **gyrification** and serves for enlargement of surface of the cerebral cortex and increasing the number of neurons, to the main grooves belong:
 - **sulcus centralis**
 - **sulcus parietooccipitalis**
 - **fissura cerebri lateralis**

Internal structure of the cerebrum

- **Cerebral cortex** (*cortex*): outer layer of pallium, component of *pars pallialis*
- **Body of white matter** (*corpus medullare*): inner layer of pallium, component of *pars pallialis*
- **basal ganglia** (*striatum*): structures corresponding to *pars basilaris*

1. Cerebral cortex

- Cerebral cortex is a layer of grey matter covering cerebral hemispheres
- It forms the outer layer of pallium, it is gyrificated, its surface has circa 0,25 m². Cerebral cortex contains 3 – 6 layers of neurons on the cross-section,
- from morphological and phylogenetic aspects we distinguish the following sections of the cerebral cortex

Allocortex (paleocortex, archicortex)
Neocortex

1. allocortex

- Phylogenetically oldest part of cerebral cortex
- Three-layer structure- it contains three morphologically different layers of neurons, in human only about 5% of surface of cerebral cortex
- from phylogenetical viewpoint, we distinguish two developmental stages of allocortex:

a) paleocortex: original cerebral cortex, which present so called olfactory brain (*rhinencephalon*), in human paleocortex occupies just about 1% surface of cerebral cortex (olfactory centre)

b) archicortex: main component of so-called limbic system, it evolved as the seat of emotional reactions, emotion (instincts) are in lower vertebrates (partly in human as well) connected especially with smell (main source of information needed to orientation in environment), with whom has archicortex close anatomical relations (is located next to paleocortex, olfactory brain), archicortex covers in human only about 4% of surface of cerebral cortex on the base of hemispheres and in adjacent areas

2. neocortex

- developmentally younger part of cerebral cortex
- It contains six morphologically different layers of neurons
- In human neocortex covers circa 95% of surface of cerebral cortex and it is a seat of the highest control functions, the basic six-layer structure of neocortex differs at various places of hemispheres

- We know so-called cytoarchitectonic maps dividing cerebral cortex into several areas with approximately the same internal structure, the most widely used is Brodmann's map, which divides (whole) cerebral cortex into 11 areas (*regiones*) and 52 surfaces (*areae*)
- From the functional point of view, we can divide cerebral cortex into so-called functional areas of cerebral cortex – districts, which represent the seats of the highest processing and integration of motor and sensory information (motor cortex, sensory, visual, auditory etc.)

Functional areas of the cerebral cortex

- almost every functional area has two components – **primary** (it accepts information from receptors or emits commands for the muscle activity) and **secondary (association)** (it provides deeper analysis of specific functions and an integration with other cortical and subcortical centres)

The cortical motor centres

- It is about the areas of cerebral cortex, whose neurons emit impulses for muscle activity
- their axons therefore continue into lower levels of CNS as descending (motor) pathways
- Within the cerebral cortex, there are especially located specific control areas for functions controlling striated muscle
- **primary motor area**- voluntary movement- pyramidal tract - damage = flaccid paralysis (***gyrus praecentralis***)
- **secondary (association) motor area**- more complicated movements, preparation of movement - damage = spastic paralysis and speech failure (***gyrus frontalis superior***)
- **premotor area**- preparation of movement – cooperation with movements of eye bulb - damage = apraxia (***gyrus frontalis*** – posterior part)
- **frontal eye field**- damage = deviation of ocular axis

The cortical sensory centres

- Accept information from skin receptors, about locomotor system and visceral organs through the sensory tracts
- It goes about a centre of somatosensory system and viscerosensory system as well
- primary sensory area- the sense of touch - damage = hypesthesia (a decrease in sensation) (***gyrus postcentralis***)
- secondary (association) sensory area- less precise sensation – recognizing of objects through touch (parietal lobe – superior part of ***fissura lateralis***)

The cortical sensory areas (in the stricte sense)

- **Centres of sensory perception (it goes about the specialized sensory organs)**
- **information come from receptors within sensory organs through appropriate sensory nerves**
- **Olfacoty area**
- **Gustatory area**
- **Visual area**
- **Auditory area**
- **Vestibuar area**

Language centers

- **speech (ability of language, spoken and written) is specific property only in human. We have two control centres— motor and sensory, which cooperate very closely and are interconnected through a bundle of nerve fibers (so-called fasciculus arcuatus)**
- **Both control centers are located within dominant (i. e. mostly left) hemisphere**

Broca's (motor) cortical area - in right-handers in L-hemisphere, in left-handers in R-hemisphere

- It is located in frontal lobe in front of primary motor cortex
- This center controls movements of muscles, which are used by spoken speech and written speech as well, gives one the ability to express oneself
- damage – you understand the speech, but you can't speak

Wernicke's (sensory) cortical area - in dominant hemisphere

- It is located in posterior part of temporal lobe, next to association auditory area, with which it has very close functional relation
- It allows to understand spoken speech also written speech (ability to read) and meaning of mimic expression (gesticulation)
- damage – you don't understand the speech, you can speak but unintelligibly (you don't know what you are saying)

The highest control centres

- It goes about seats of highest functions, e.g. cortex of limbic system, which controls emotional behavior and memory, language centres...

Association cortical areas

- Here are integrated somatosensory, visual and auditory cortical areas
- They are located in cortical areas of lobus parietalis, occipitalis, temporalis
- Especially for human the main importance has so-called *frontal association cortex* which is located in anterior parts of frontal lobe and is interconnected with thalamus, limbic system and RF, here are realized the highest mental functions, here originates a sense of consciousness and self-confidence,
- damage- apathy, emotional lability (frontal lobotomy)

Limbic system

- **Seat of memory and source of emotion and motivation**
- **Response of limbic system – affective behavior - fear, anger, aggression, pleasure, disgust**
- **motivation - hunger, thirst, sexual and reproductive behavior**
- **cortical structures (preservation of life and genus)**
- **Nuclei within cerebrum- amygdala**
- **Nuclei of diencephala and brain stem – nuclei of thalamus and hypothalamus**
- **Connections of limbic system**

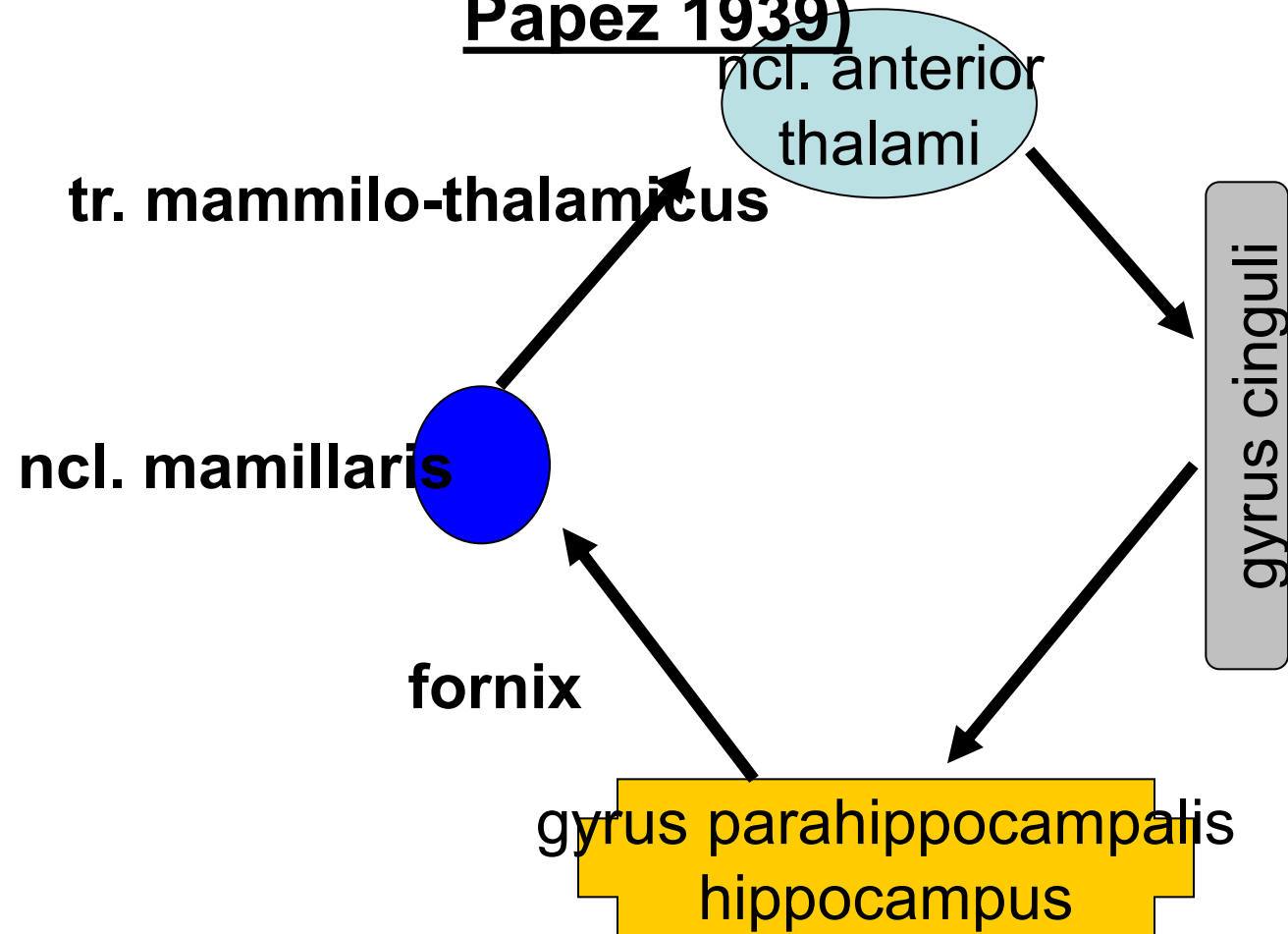
Amygdala

- **The largest complex of grey matter, temporal lobe**
- **Aferent information – from cortex (smell, taste) and from BG, hypothalamus and RF**
- **Efferent information – hypothalamus, BG, thalamus, brain stem**
- **Integration of sensory information – it is able to affect somato- and visceromotor systems**
- **damage- calming- disorders of emotional experiences**
- **irritation- increased attention, fear, anxiety, aggression**

Hippocampus

- **damage** - loss of ability to learn and to remember

Papez circuit (James Papez 1939)



• it has not specific function

Dominance of hemispheres

- For the macroscopic point of view, both hemispheres (their cortex) are approximately the same, but they differ in their functional activity
- In a number of functions usually one hemisphere prevails, it is so-called **dominant hemisphere**
- In circa 96% of right-handers and circa 70% of left-handers, the right hemisphere is dominant
- Right hemisphere is used in most people in nonverbal skills (three-dimensional vision, face recognition, emotional content of speech, aesthetic perception etc.)
- Left hemisphere is used in verbal skills (which require analysis of situation or logical thinking etc.)

2. THE WHITE MATTER OF THE CEREBRUM

- The white matter of the cerebrum is called *corpus medullare*, it is formed by numerous nerve fibers (tracts), which connect various places in hemispheres or lead from hemispheres into other parts of nervous system

association tracts: tracts, which connect two different places in the same hemisphere, e.g. *fasciculus arcuatus* – tract connecting Broca's and Wernicke's centre of speech

comissural tracts: tracts connecting two places in opposite hemispheres, they provide coordinated action of both hemispheres, the largest comissure is *corpus callosum*

projection tracts: tracts connecting cerebral cortex with lower levels of CNS (or vice versa), they arise (or enter) from brain stem through crura cerebri into hemispheres and here they fanlike diverge to cortex – this fan-shaped structure is formed by nerve fibers and called - *corona radiata*

Association tracts - connect variable distant cortical areas of hemisphere

- Short fibers
- Long fibers

Comissural tracts

- Homotropic
- Heterotropic
 - corpus callosum
Lobus frontalis, parietalis,
occipitalis + auditory areas
 - commissura anterior
Lobus temporalis,
olfactory areas, regions
of hippocampus
 - commissura posterior
Posterior nuclei of thalamus
 - commissura fornicis
Gyrus hippocampi and
regions of hippocampus

Projection tracts – bundles of axons, form connection between cerebral cortex and lower located structures

Short projection tracts

Long projection tractss

capsula interna

Ascending - lead sensory information,
cross - *radiatio talami, optica, acustica*

Descending - lead motor information,
cross - *tractus corticospinalis*

Capsula interna

CAPSULA INTERNA

- accumulation of neural tracts between thalamus and BG
 - crus anterior – fibers of anterior tr. thalamocorticalis and tr. frontopontinus
 - genu - tr. corticonuclearis (for muscles of head and neck)
 - crus posterior - tr. corticospinalis (topographically)
 - tr. corticoreticularis, tr. corticorubralis
 - tr. thalamocorticalis, tr. parieto- , temporo-occipitopontinus
 - radiatio optica – end of visual pathway
 - radiatio acustica – end of auditory pathway

3. BASAL GANGLIA

- It goes about large nuclei of grey matter, which are located laterally to thalamus, they are embedded into depth of white matter
- basal ganglia are functionally **involved into motor neuronal circuits** (like motor cerebral cortex, large nuclei of grey matter of mesencephalon and cerebellum) – basal ganglia are interconnected with all these parts
- They participate especially in forming of programs for intended movements, **coordination between reflecting and intentional activity**
- They are not able to generate input information for movement
- **They are crucial for integration of motor functions**
- **They form together with cerebellum connection between sensory and motor system**
- **emotion, cognitive functions**

- **Corpus striatum**= nucleus caudatus + putamen
- **Nucleus lentiformis**= globus pallidus (pallidum) + putamen
- **Clastrum**
- **Nucleus amygdalae** (almond), which is functionally involved in limbic system

Damage of basal ganglia

- **Chorea**- involuntary movements at rest and at motion as well, disappears in sleep
- **Athetosis**- slow twisting movements of the distal parts of extremities, grimaces, unclear speech
- **Ballism**- involuntary movements of large amplitude- flying movements
- **Parkinsonism**- muscle hypertonia, worsened motion, resting tremor disappearing in sleep, silent speech, small handwriting

Brain ventricles

Ventriculus lateralis

- In hemispheres

Foramen interventriculare

Ventriculus tertius

- Between both thalamus

Aqueductus mesencephali

Ventriculus quartus

- Between brain stem and cerebellum

- **liquor cerebrospinalis (150ml, daily 500ml)**
- **apertura mediana et laterales ventriculi IV. – subarachnoid space**

Lumbar puncture

Hydrocephalus

Blood supply of the brain

A. vertebralis

A. carotis interna

Circulus arteriosus Willisii

Sinus durae matris

Thank you for your attention.

- **Obrázky:**
- **Atlas der Anatomie des Menschen/Sobotta. Putz,R., und Pabst,R. 20. Auflage. München:Urban & Schwarzenberg, 1993**
- **Netter: Interactive Atlas of Human Anatomy.**
- **Naňka, Elišková: Přehled anatomie. Galén, Praha 2009.**
- **Čihák: Anatomie I, II, III.**
- **Drake et al: Gray's Anatomy for Students. 2010**