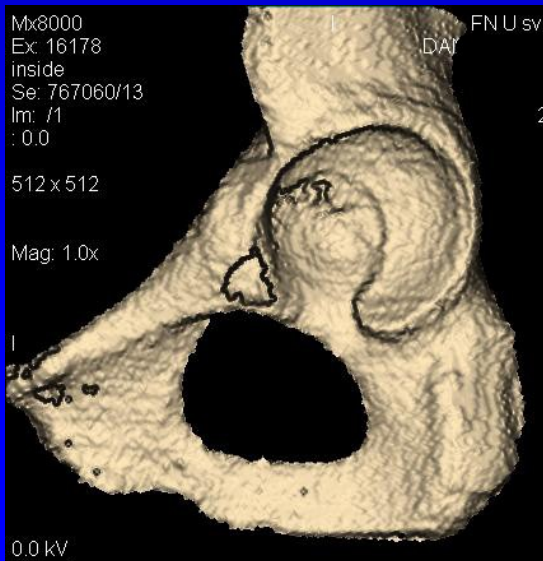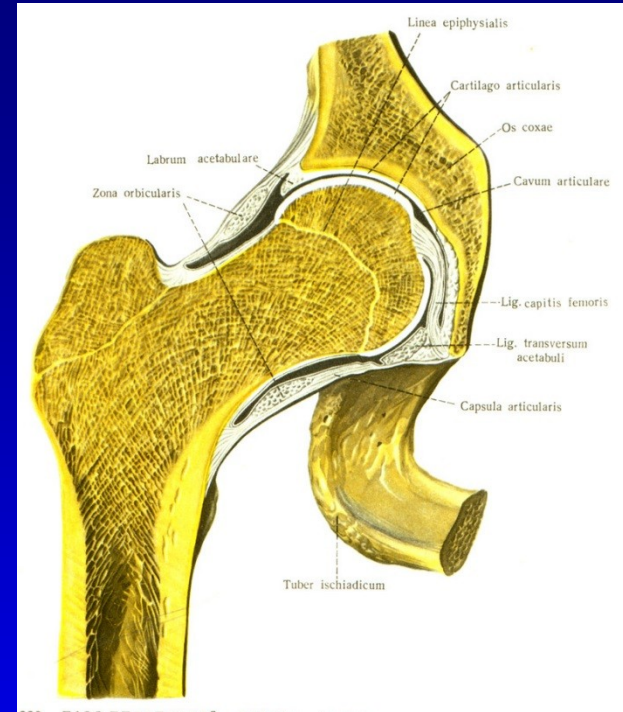


Total hip arthroplasty

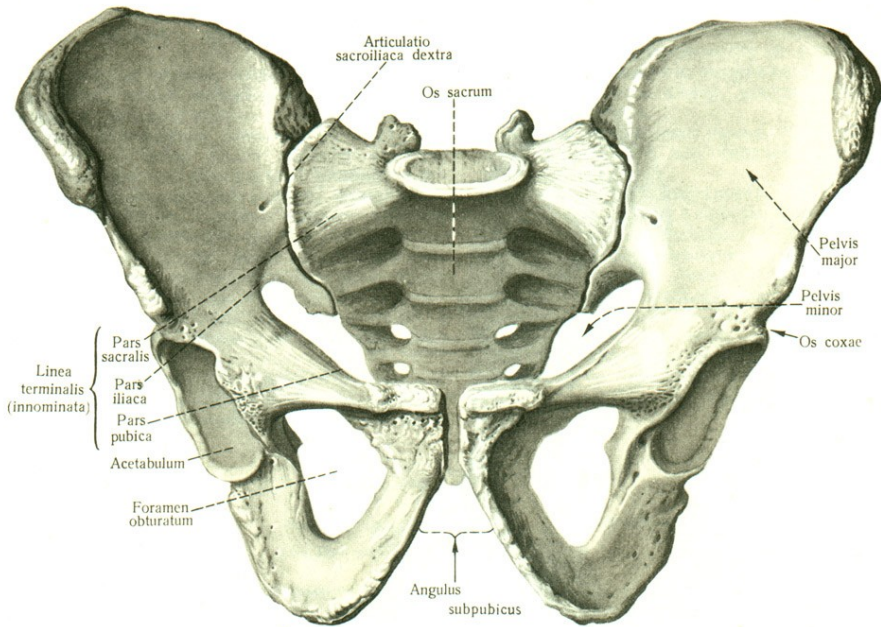
Z. Rozkydal

Hip joint

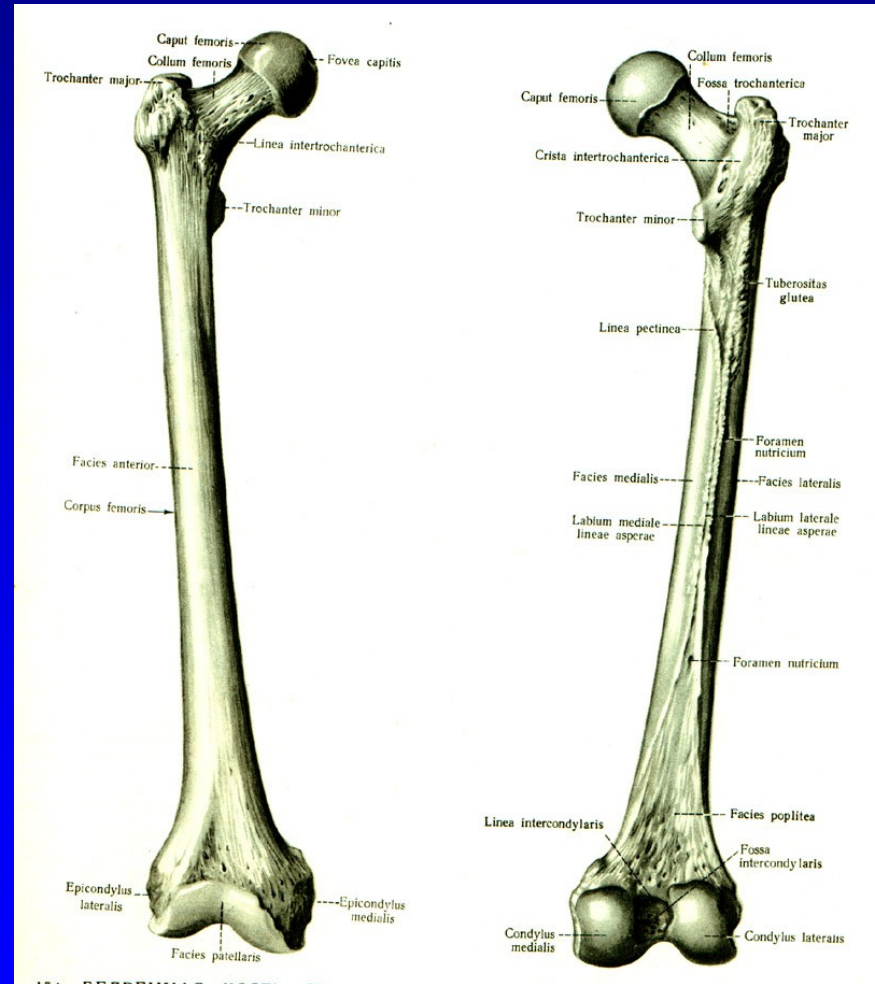
Enarthrosis



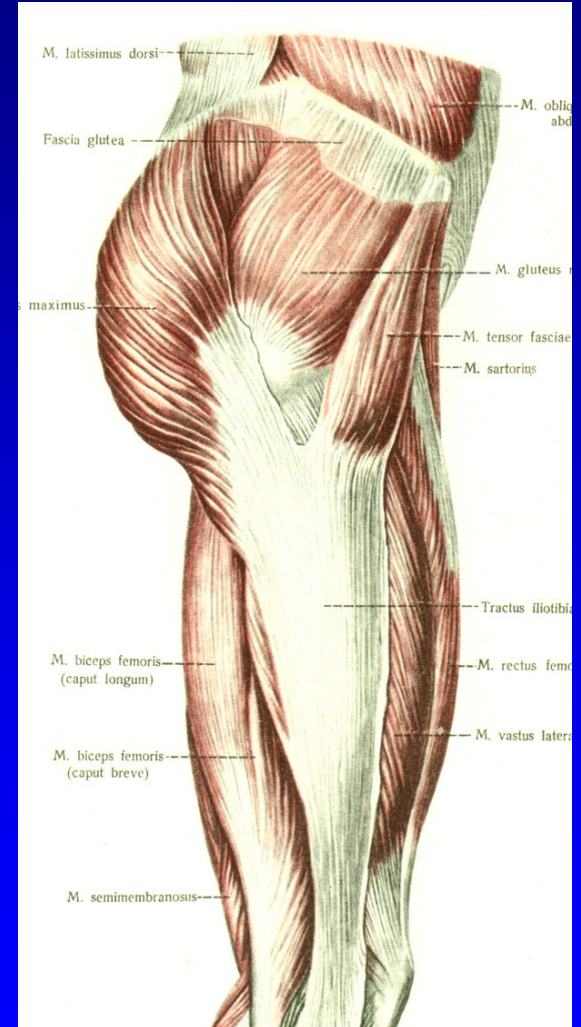
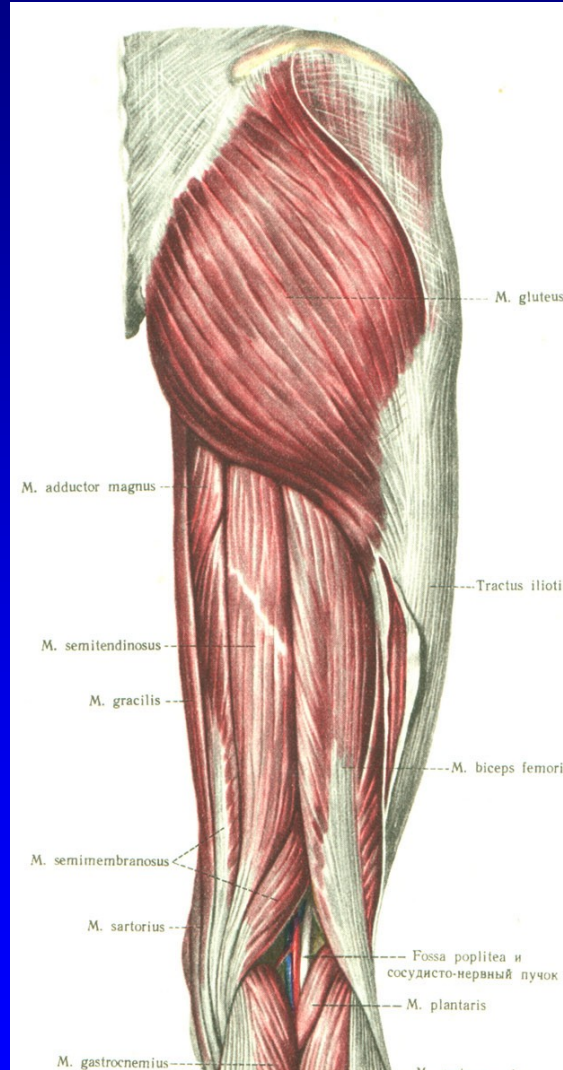
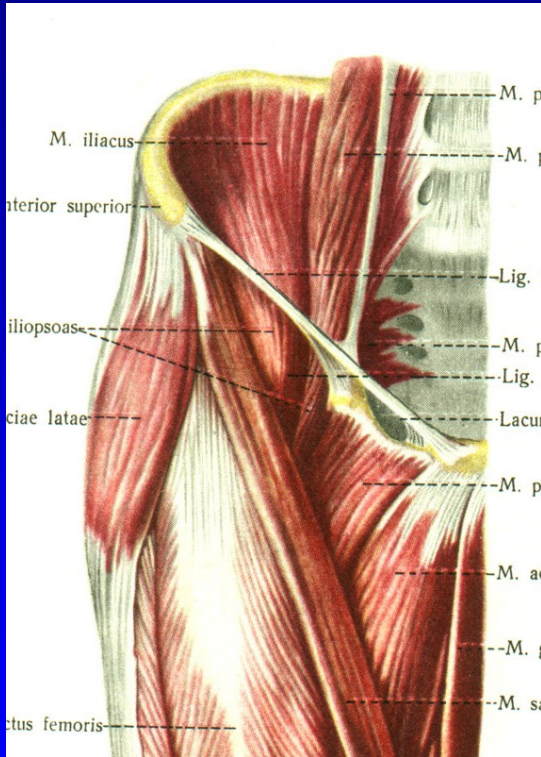
Pelvis



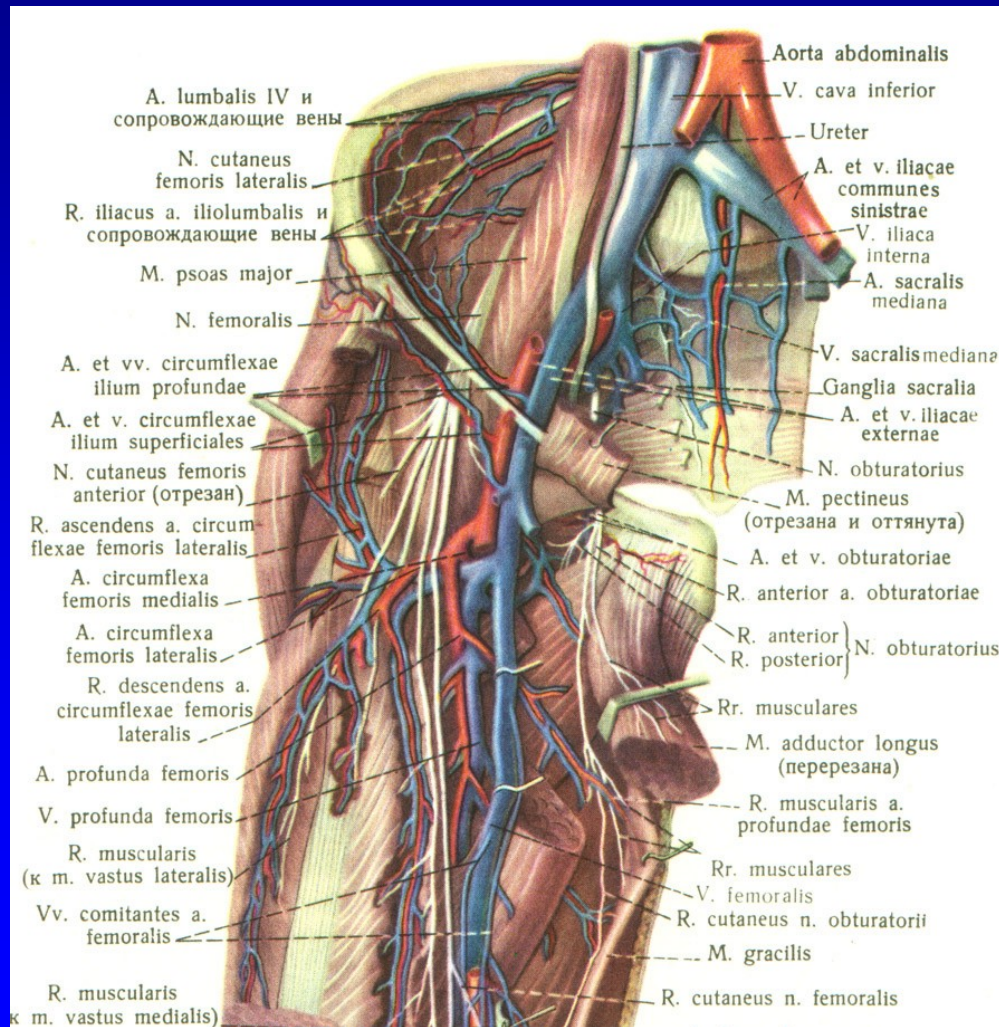
Femur



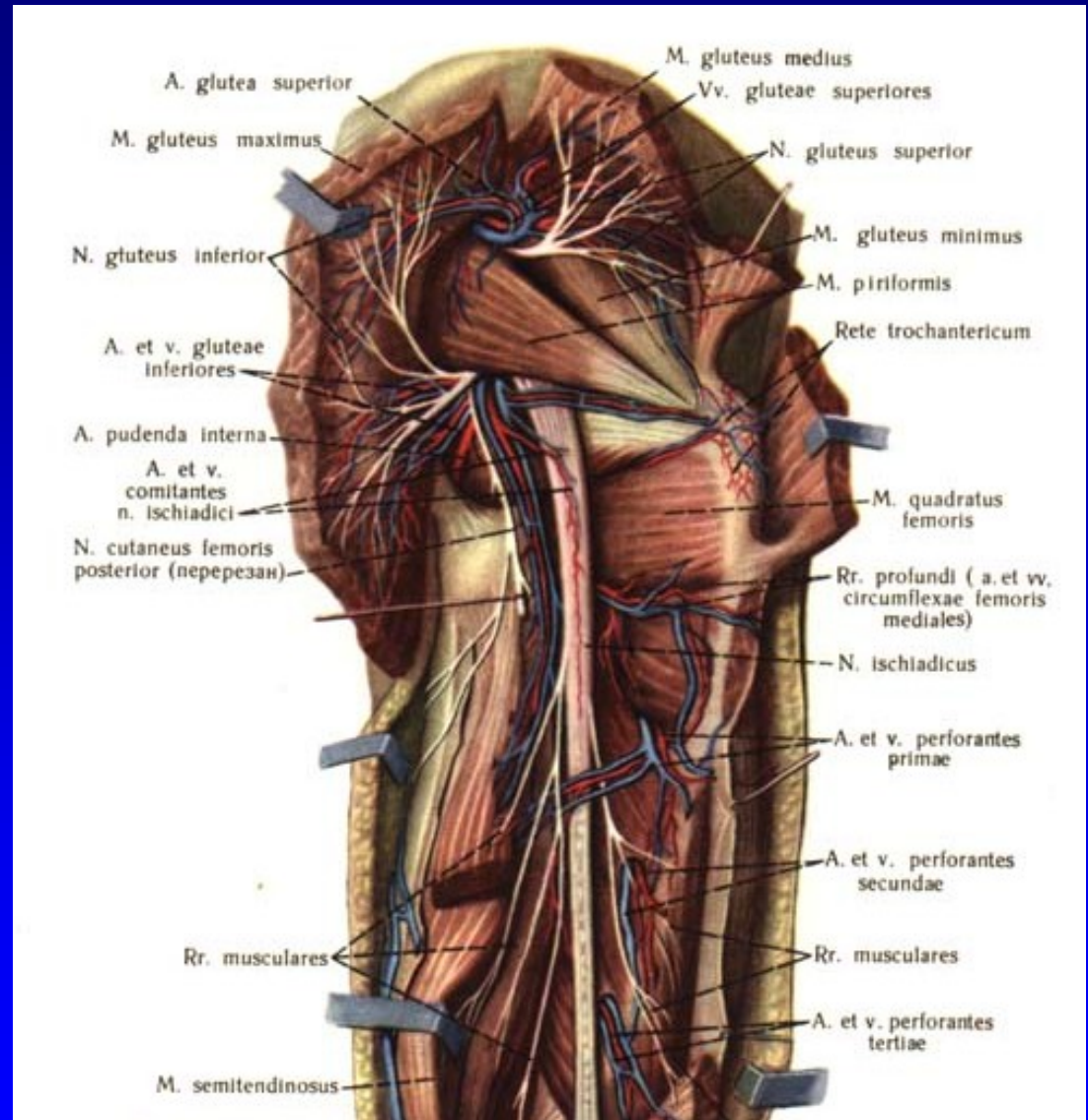
Muscles



Femoral nerve



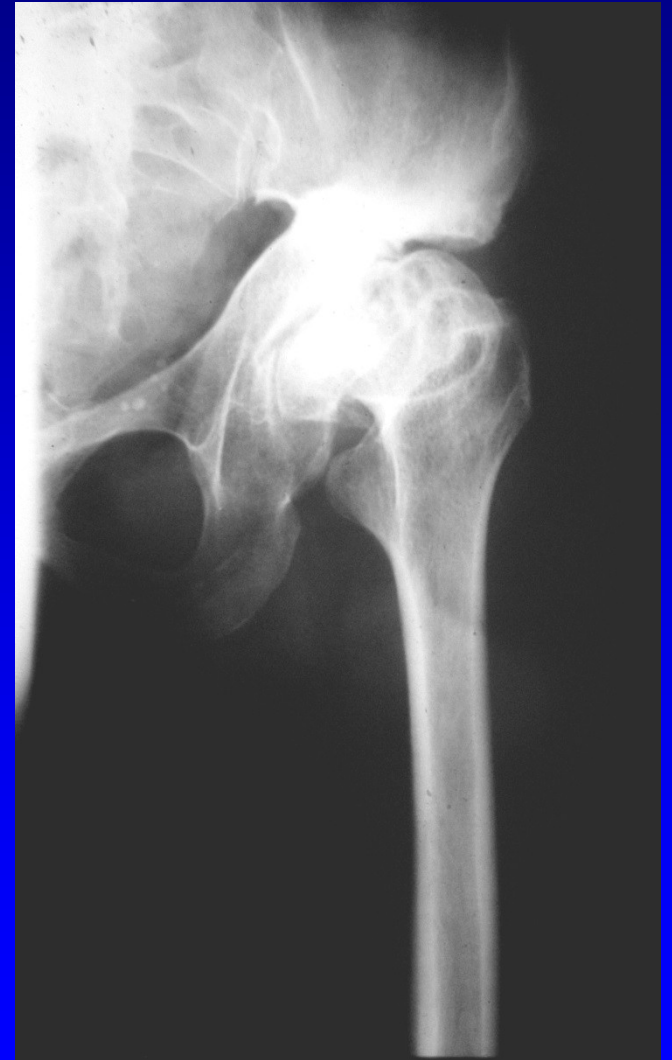Sciatic nerve



Indication for THA

- Painful condition
+ unsuccessful conservative
treatment

Dyscomfort



Indications

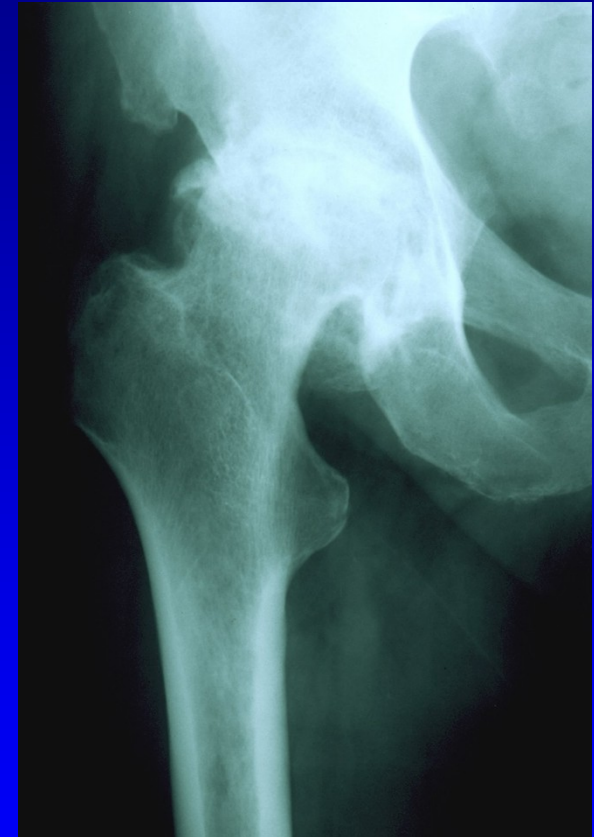Primary osteoarthritis

Secondary osteoarthritis:
congenital, posttraumatic,
after infection

Rheumatoid arthritis

Psoriatic arthropathy

Avascular necrosis
of the femoral head



Primary osteoarthritis

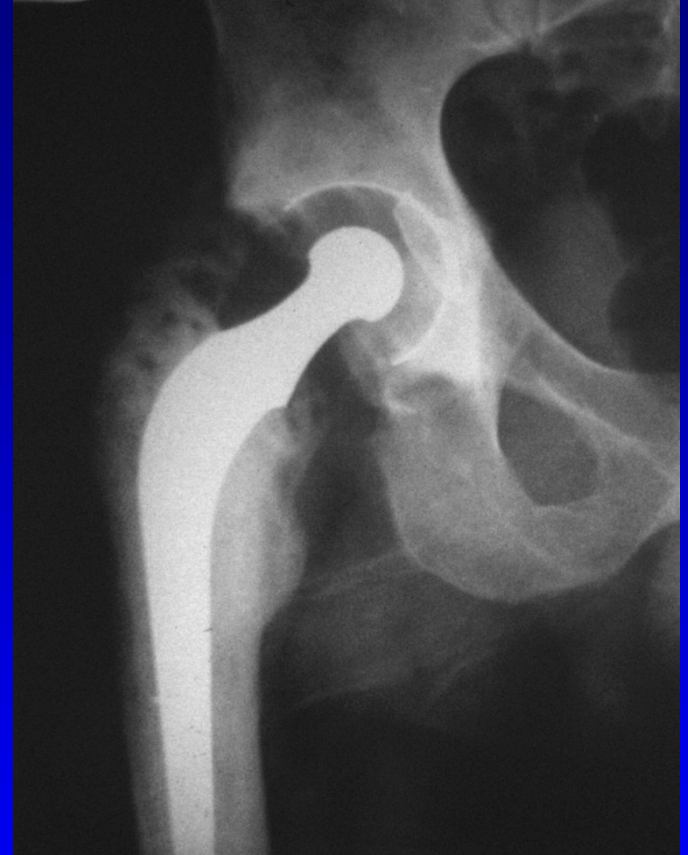
Historie

Sir John Charnley
Low friction arthroplasty
Acrylic dental cement


Polymethylmetacrylate
– bone cement



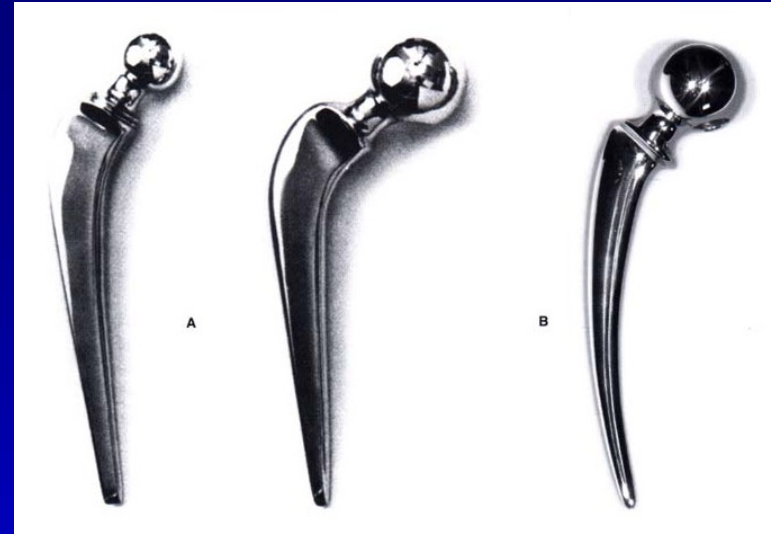1962



Low friction arthroplasty

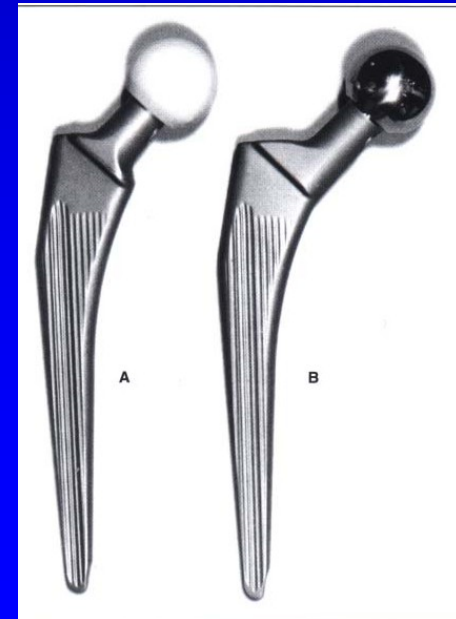


Prof. M. E. Müller




1964 -1965
Setzholzprothese

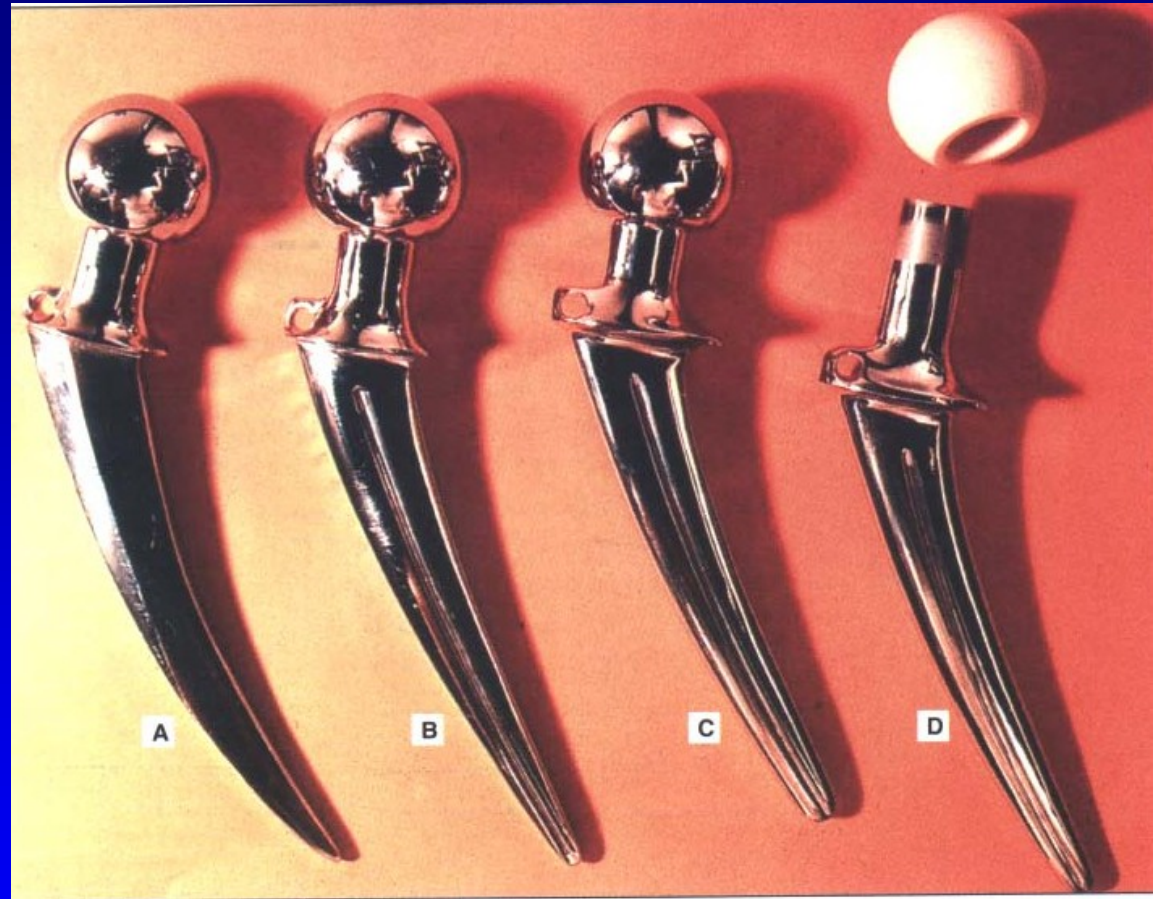1966
Banana - shaped



1977
Geradschaftprothese



Prof. MUDR. Oldřich Čech, DrSc.



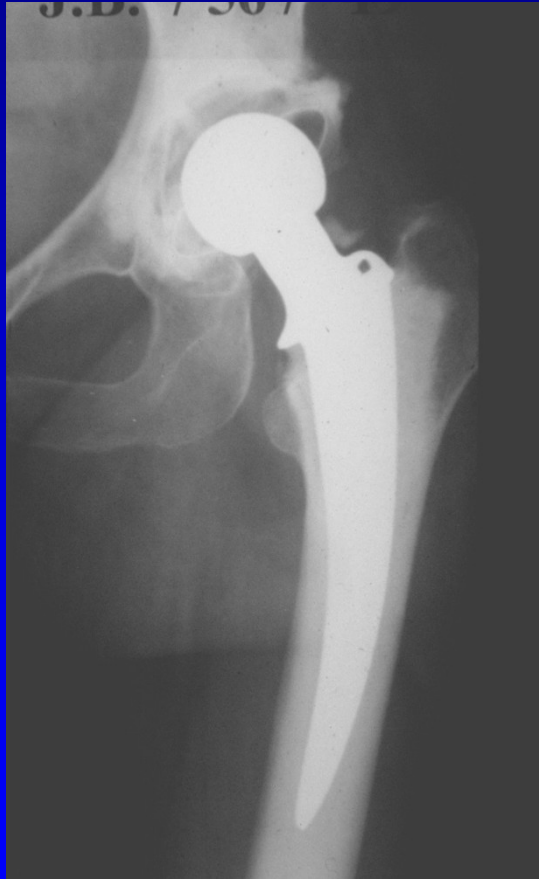
1972

1986

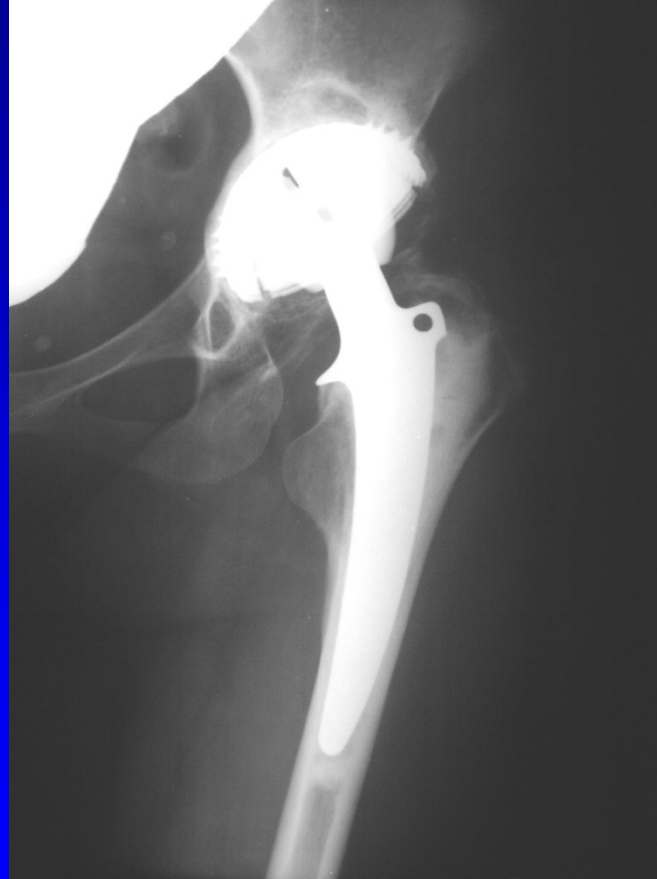Stems Poldi- Čech

Fixation in the bone

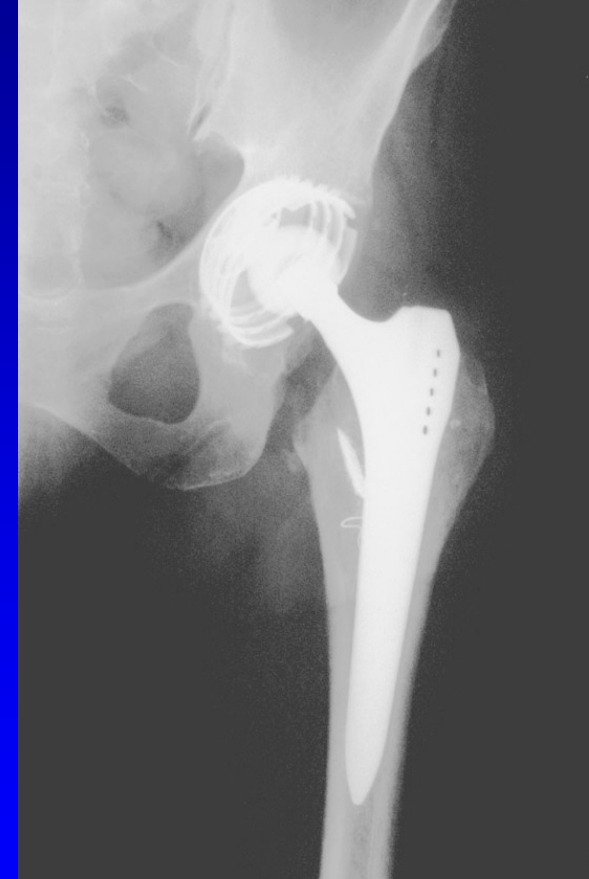Types of THA



Cemented



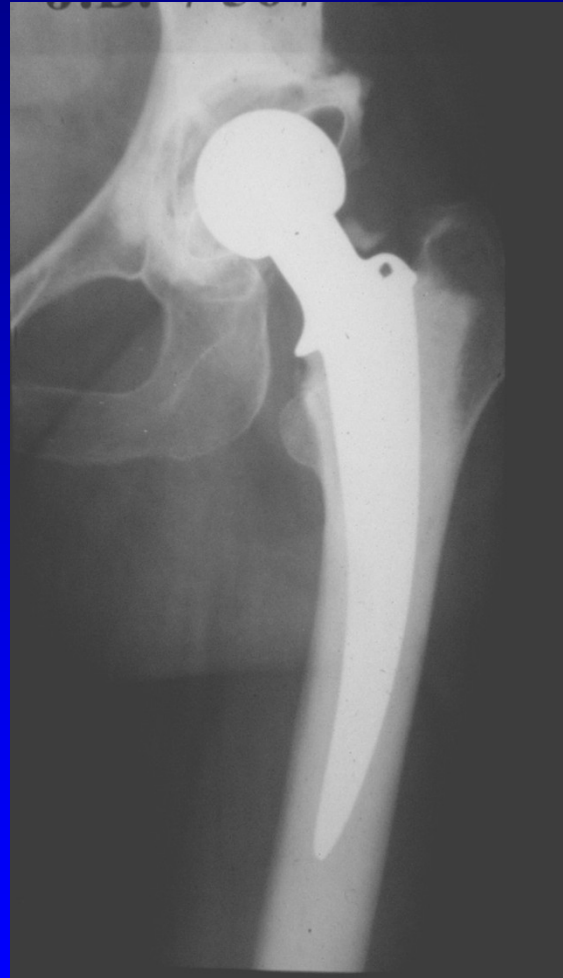Hybrid



Uncemented

Primary THA

Polyethylene cup

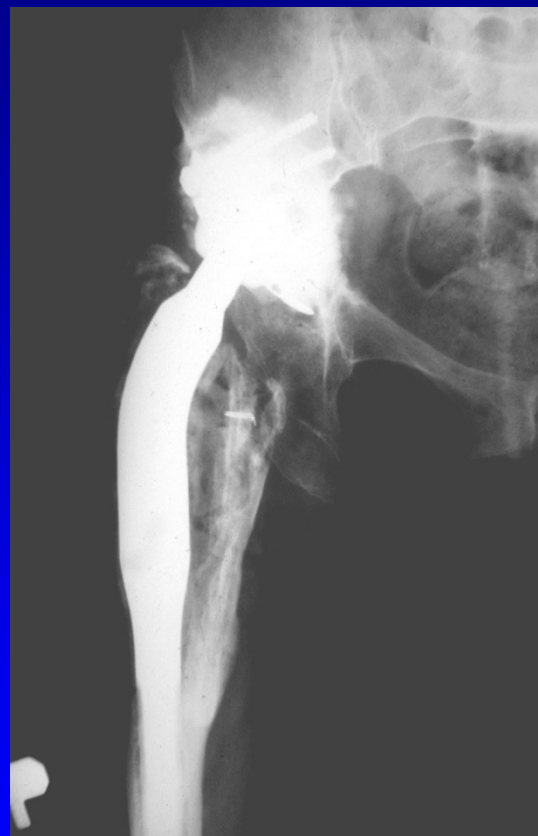
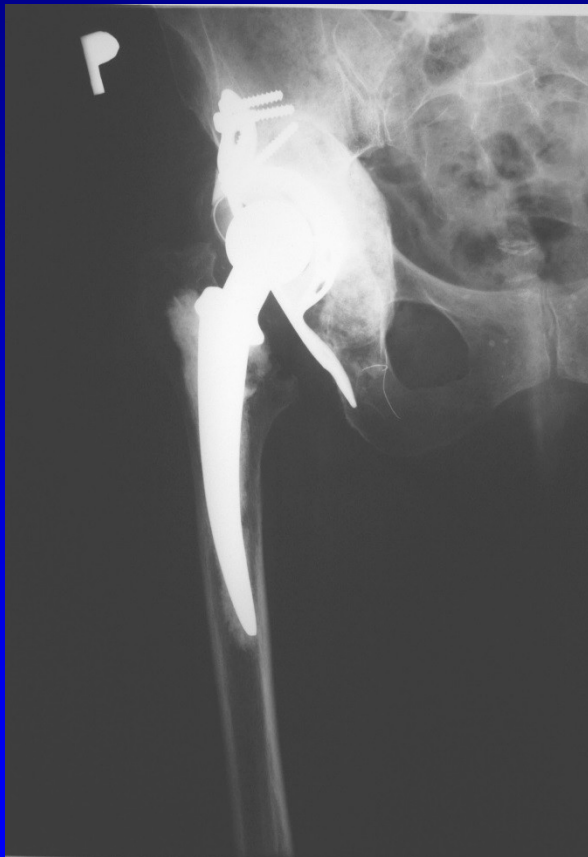
Head

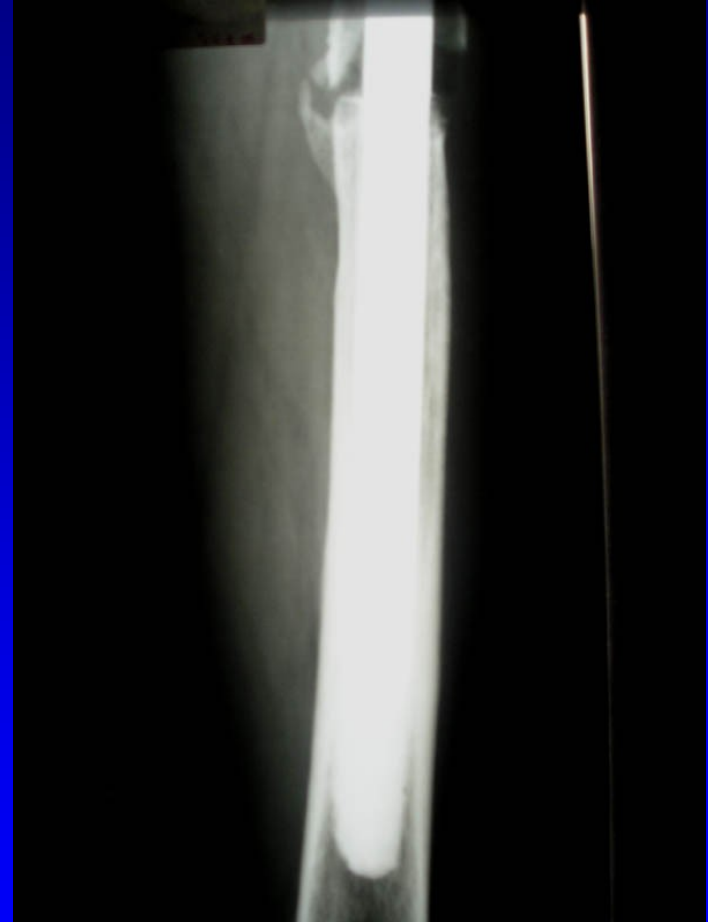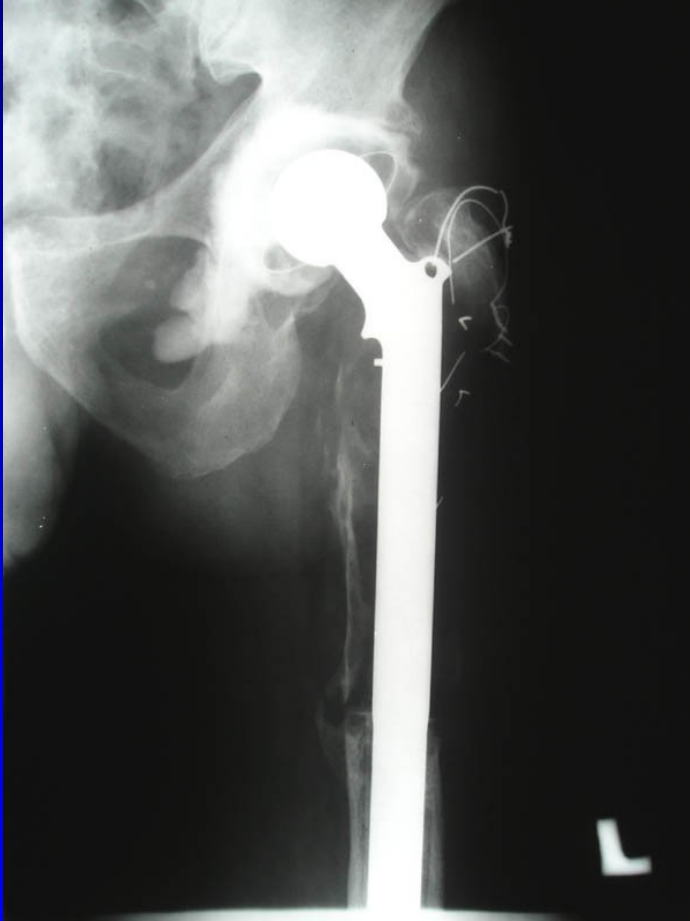Neck

Stem

Revision THA

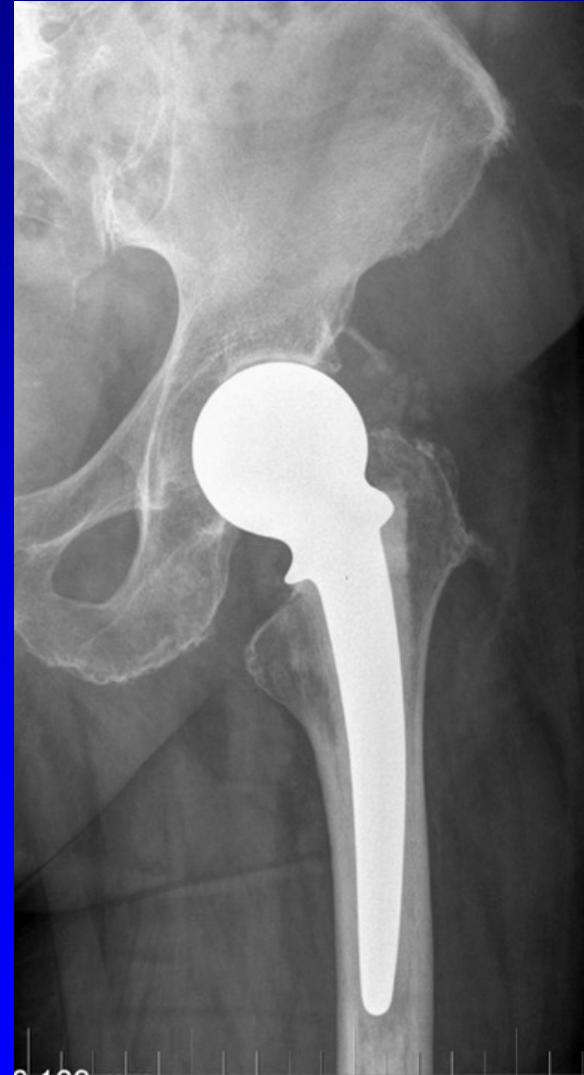
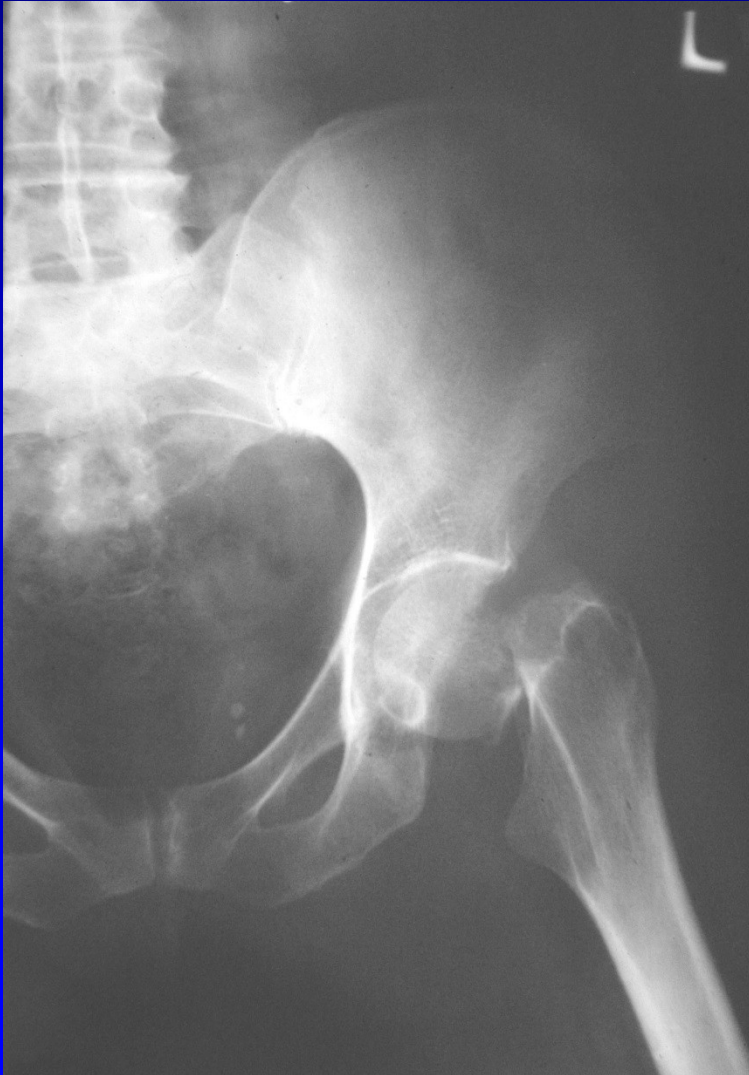
For tumors



Femoral head prosthesis

Thompson




Metal

- Steel
- Cobalt - chromium-molybdenum alloys
- Titanium alloys



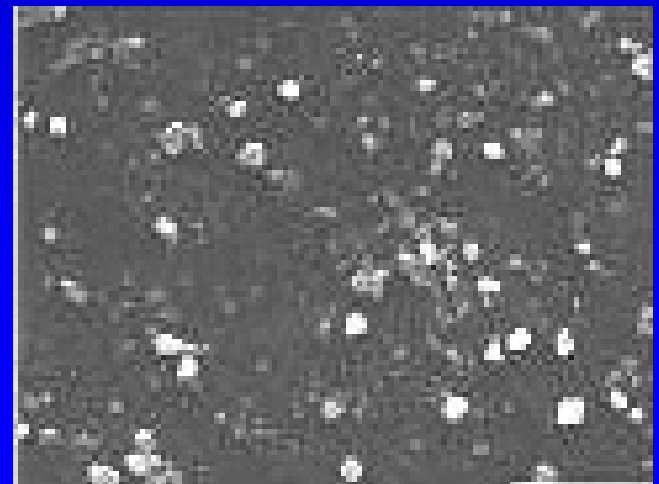

Polyethylen

- UHMWPE :
ultra- high- molecular-
weight- polyethylen



Polyethylen

- Linear wear 0,1 - 0,2 mm / year
- Volumetric wear 0,3 - 10 mg / year
- Cold flow – plastic deformation
- Abrasion and delamination
- Oxidative degradation
- Modern trends:
highly crosslinked polyethylen
- with vitamin E




PE wear particles, 1 um

XPE- highly-cross-linked polyethylen + vitamin E



Antioxidant

Increases mechanical properties
of PE



Ceramic

- Corundum or Zirconium AL_2O_3
- Smooth surface
- Less wear: 0,005 - 0,15 mm / year



Ceramic



Smoother surface

Less amount of wear of particles

Particles are bioinert



Wear of head/PE cup
under 0,15 mm/ year

Wear of ceramic head/ceramic insert
under 0,002 mm/ year



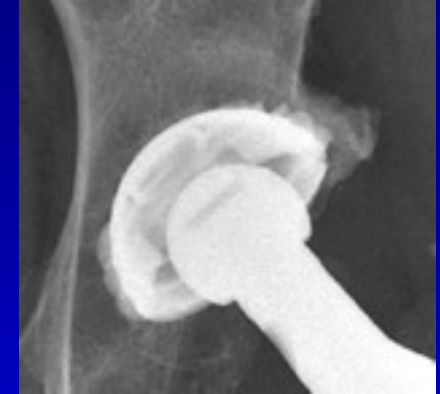Contact : head - cup

- Metal- polyethylen
- Ceramic- polyethylen
- Ceramic -ceramic



Diameter of the head

22, 28, 32, 36, 38, 40 mm

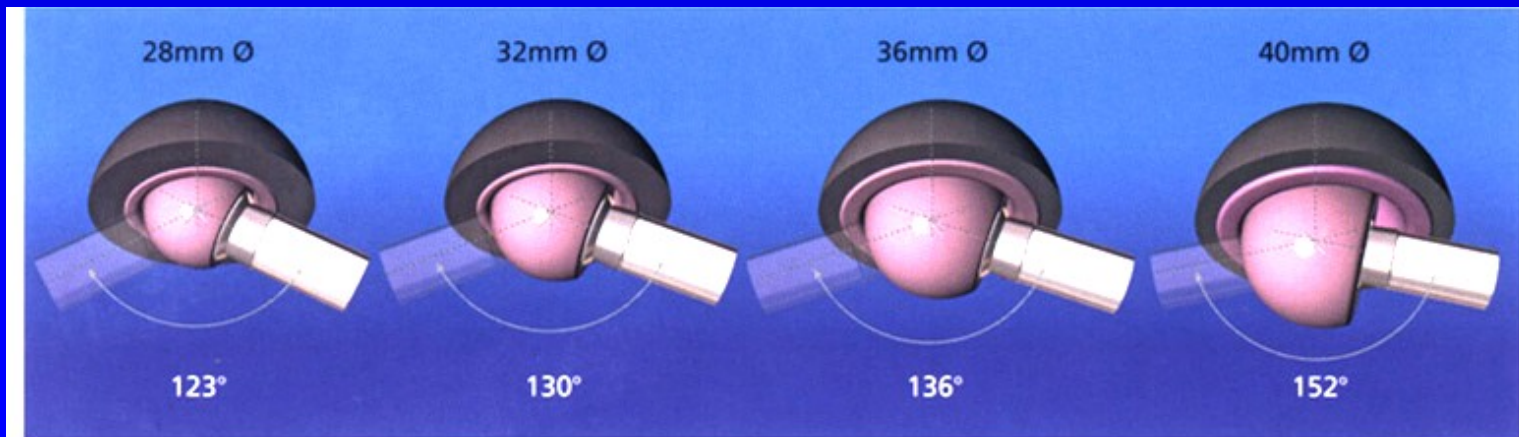


Advantage of 36 mm head:

Higher stability

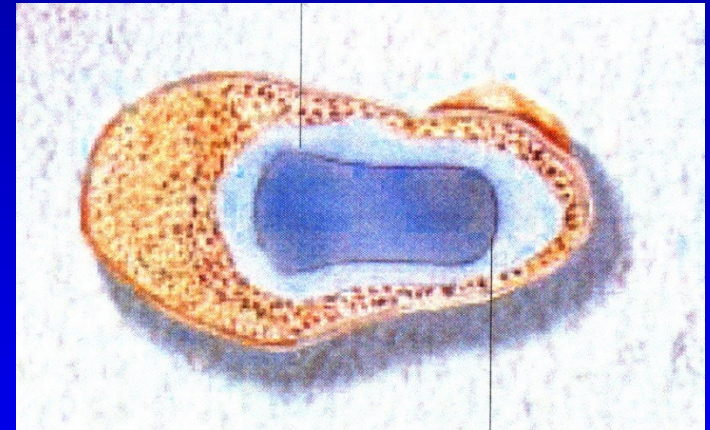
Greater range of motion

Less impingement neck- edge of the cup

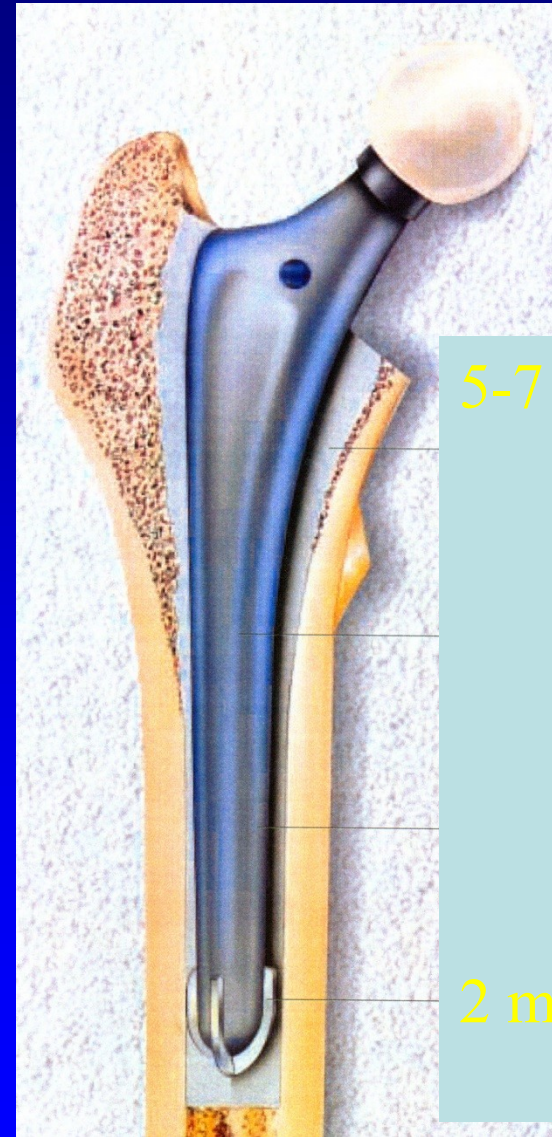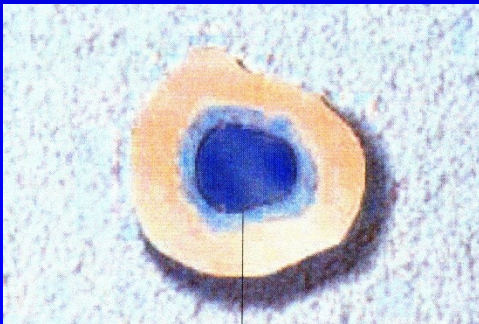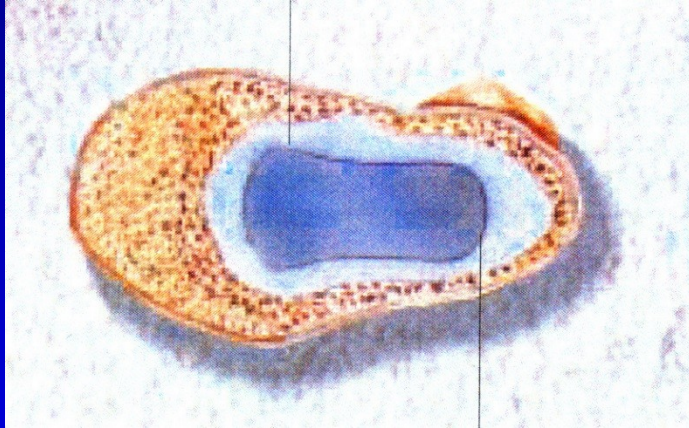


Bone cement

- Polymethylmetacrylate
- Powder polymer, fluid monomer
- Exothermic reaction 83- 100 C
- Hardening in 10 min.
- Adverse effects: hypotension, coagulation of proteins, cytotoxicity



Cemented THA

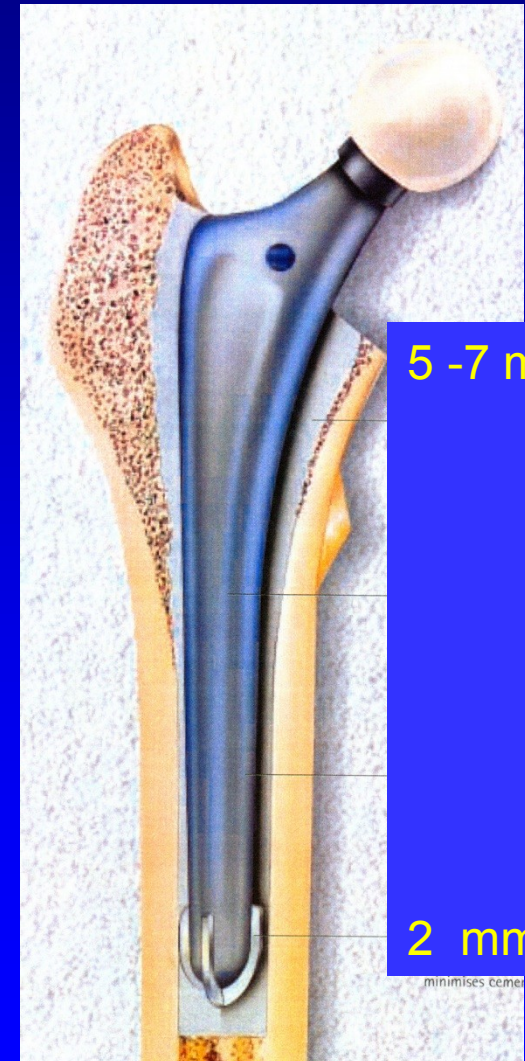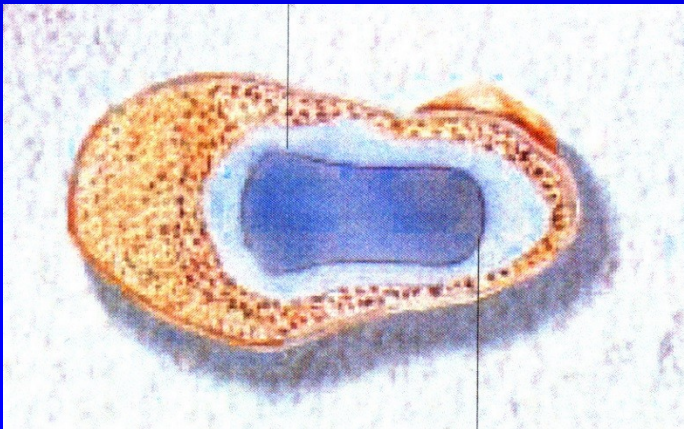


5-7 mm

2 mm

Cementing technique

- Interdigitation into bone trabeculae
- Regular layer:
 - under the cup 3 mm
 - around the stem 2- 7 mm




Acetabular component


- Cemented: polyethylen
- Noncemented: metal- backed
with PE insert
with ceramic insert



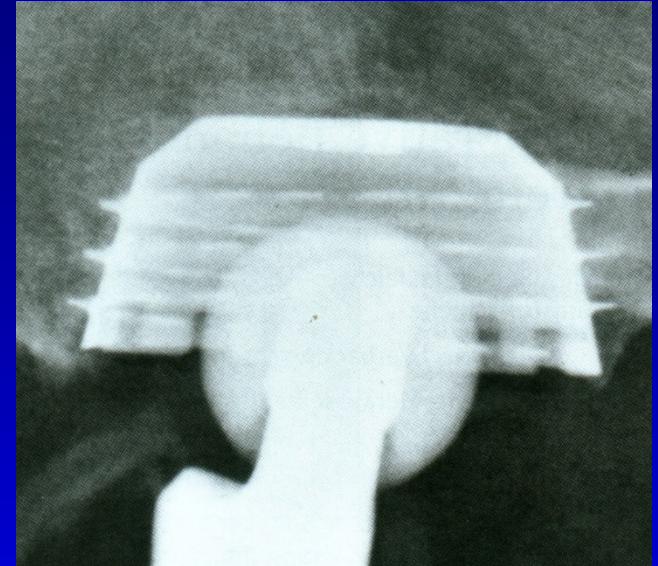
Uncemented cup



Press - fit



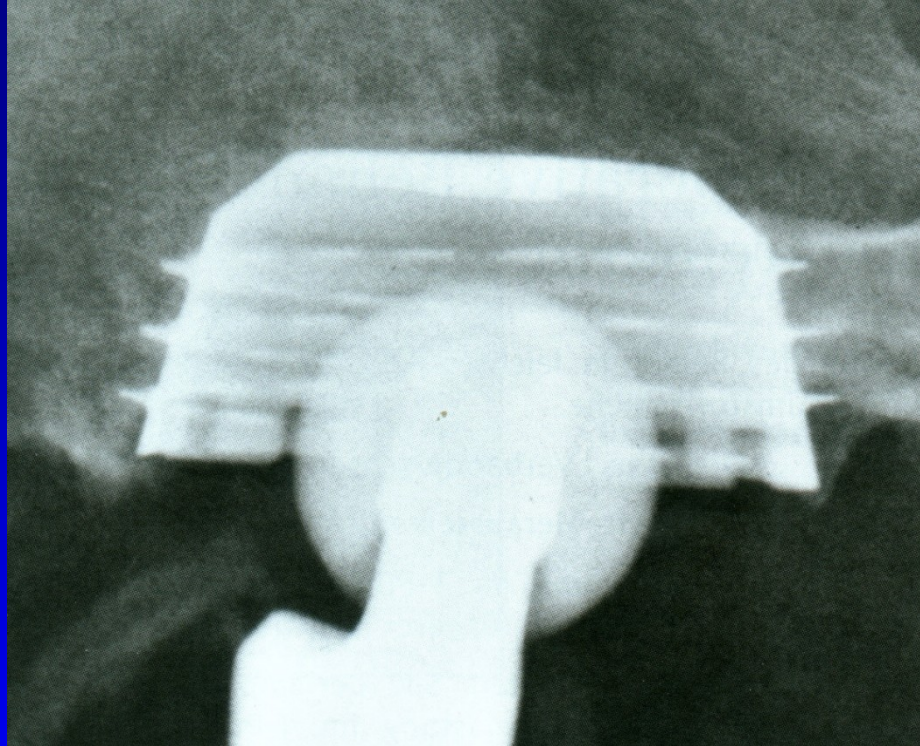
Expansion



Threaded

Primary fixation: mechanical anchorage in the bone

Uncemented cup



Secondary fixation: osteointegration of the implant on the surface of bone

Surface of cementless implant

Macroporosity

Microporosity

Pores on the surface $5\ \mu\text{m}$ - $600\ \mu\text{m}$

Pores above $800\ \mu\text{m}$ - fibrous tissue

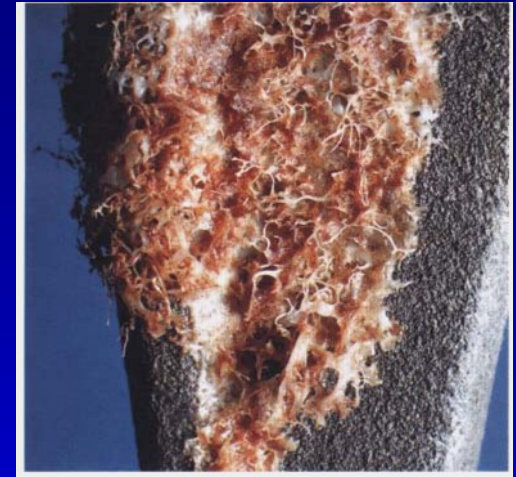Adhesive surfaces:

Trabecular Metal

Trabecular Titan

Pores $300\ \mu\text{m}$

High initial stability




Hydroxyapatite surface

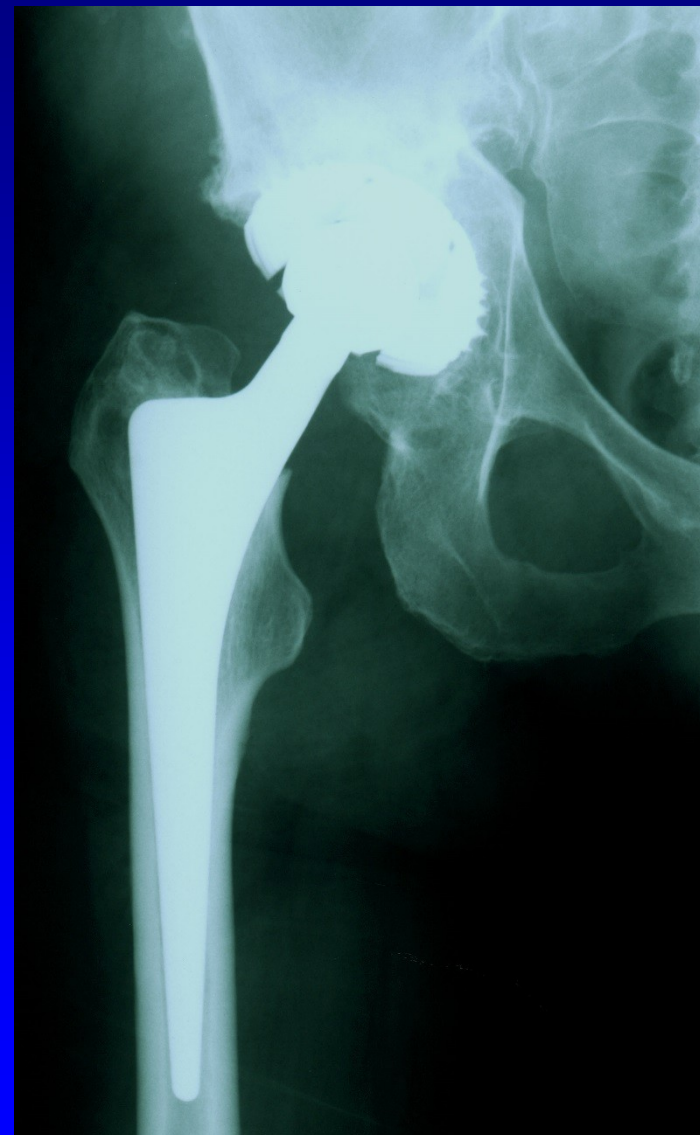
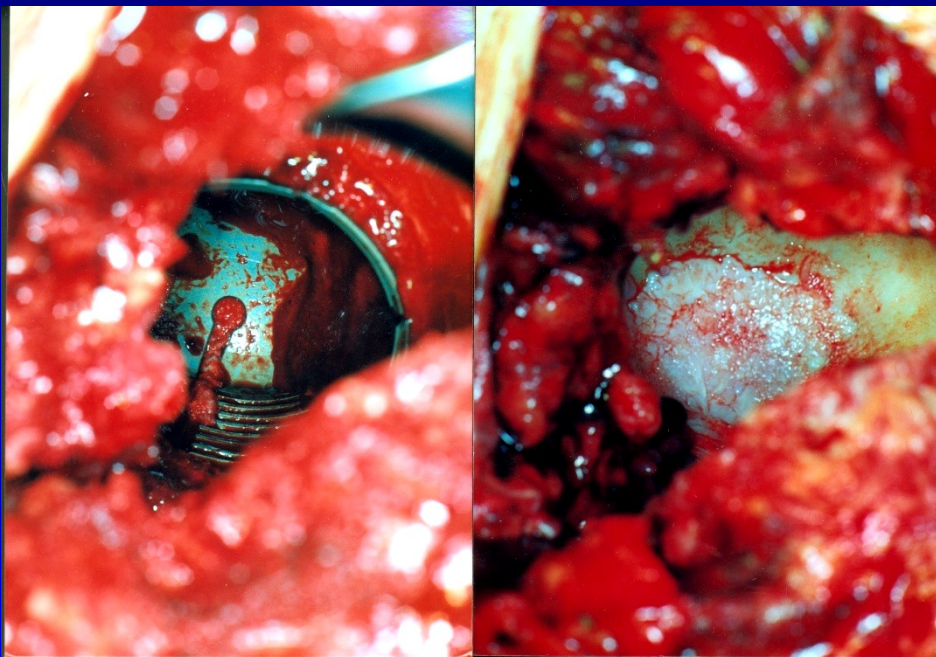
Bioactive

Osteoconductive

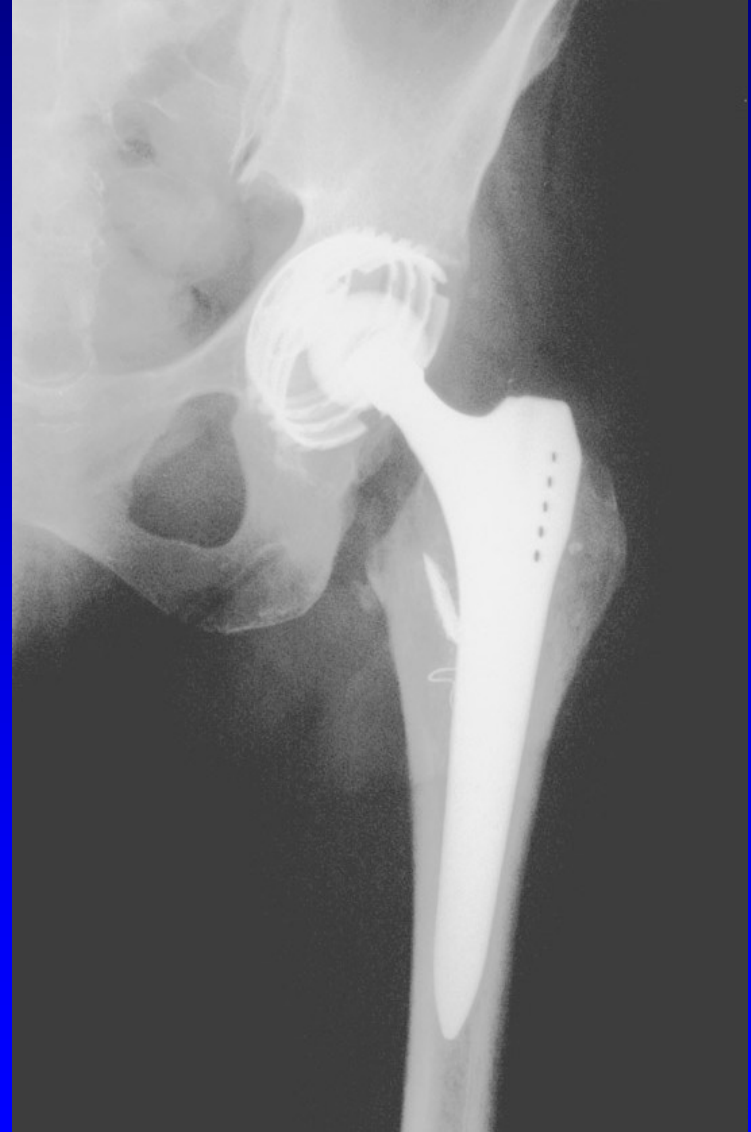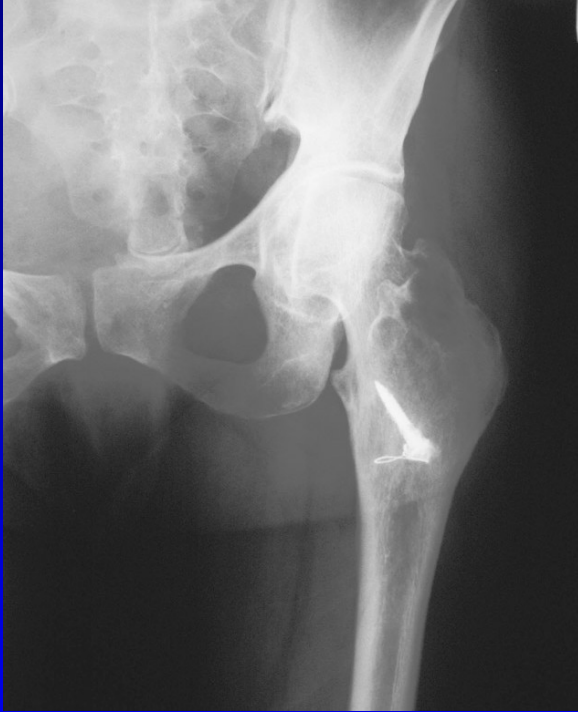Chemical bonds bone- hydroxyapatite



Expansion cup- CLS

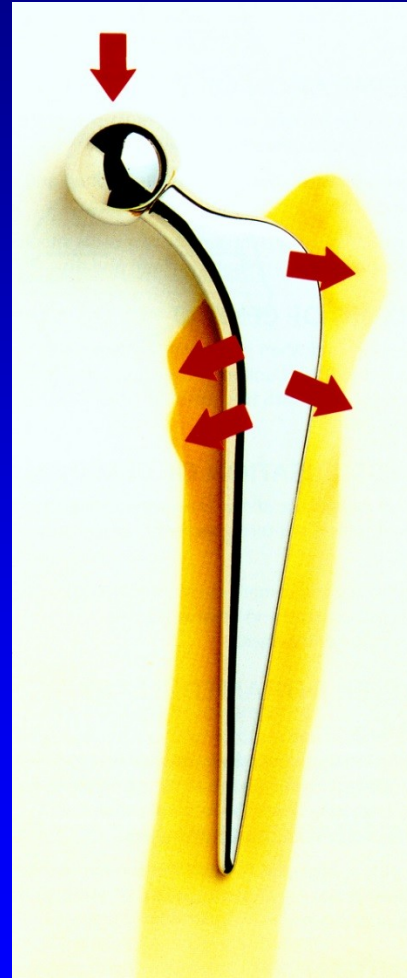


Bicon – Zweymüller cup

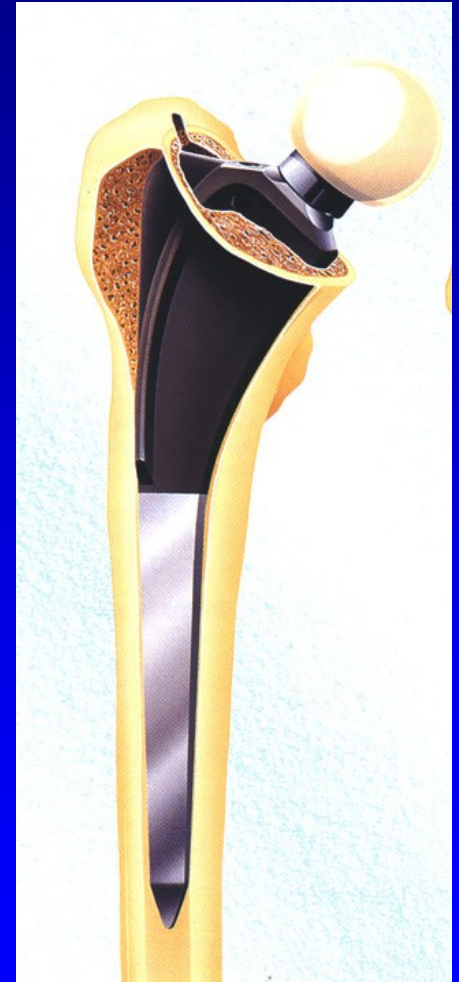

Femoral component

- High polished surface for cementing fixation
- Porous surface for cementless fixation

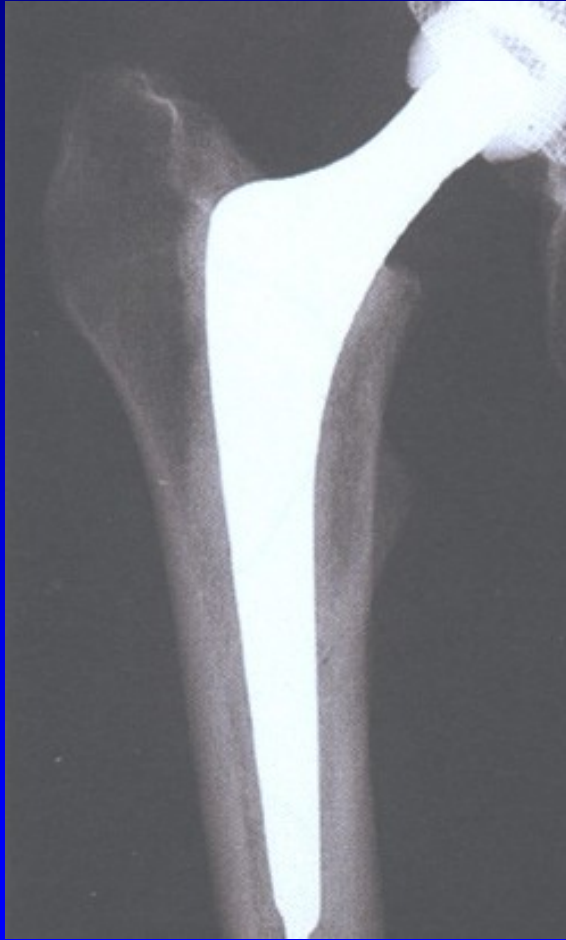


Cemented

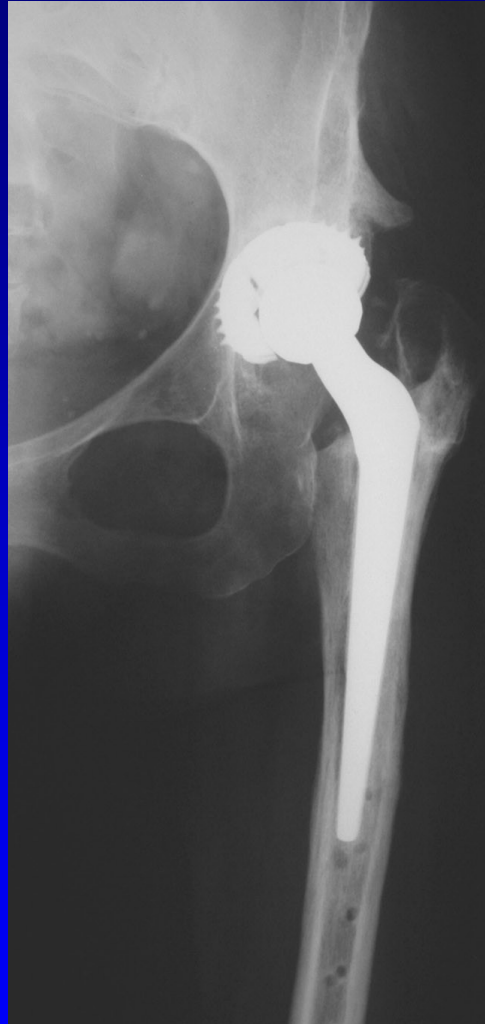


Cementless

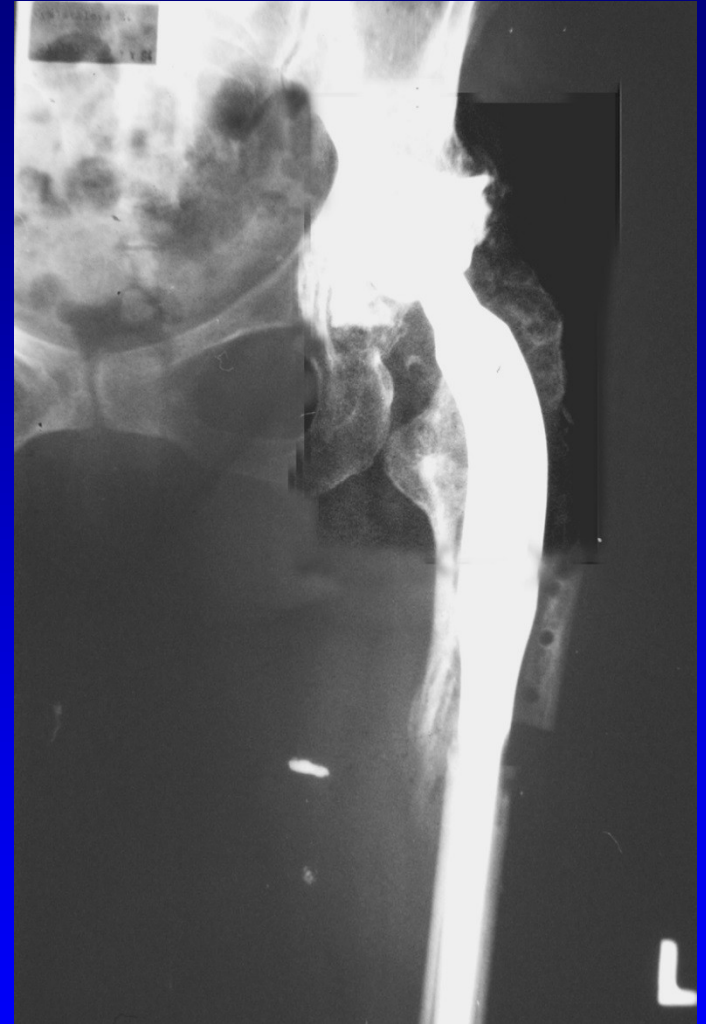Morscher, Spotorno MS – 30 stem cemented



Uncemented stems



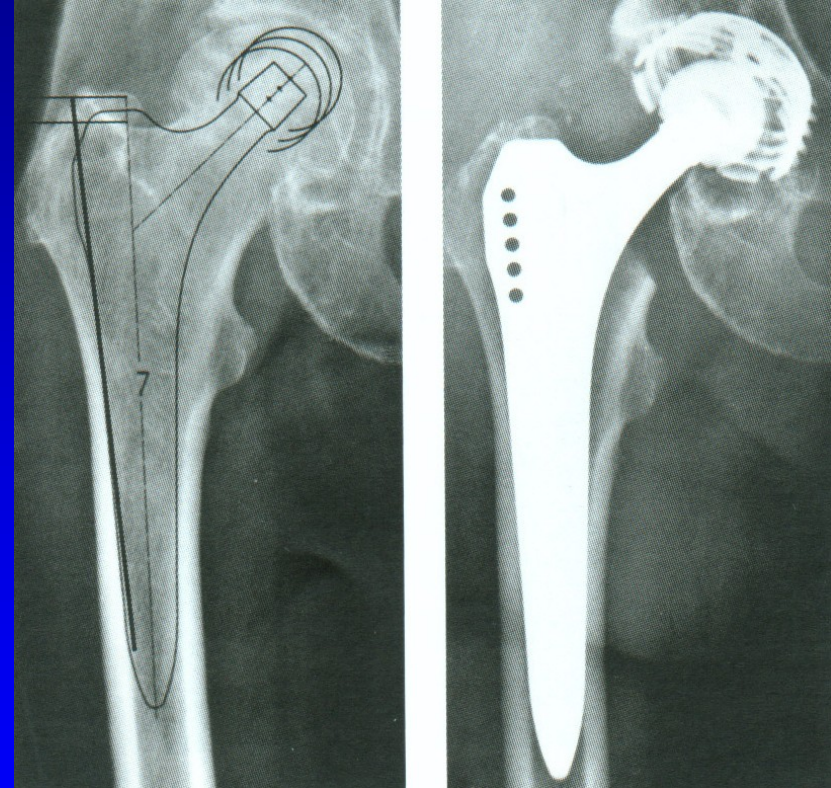
Proximal fixed



Distal fixed

Uncemented stem

- Primary fixation:
- Mechanical anchorage in the bone
- Secondary fixation of the implant on the bone surface

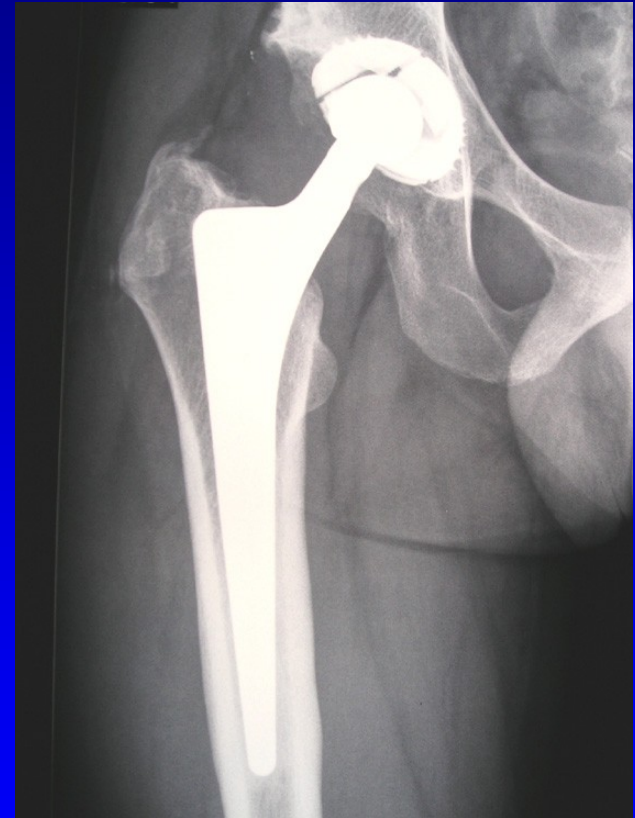


Indication scheme

- Uncemented to 60 y.
- Hybrid 61 - 70 y.
- Cemented over 70 y.

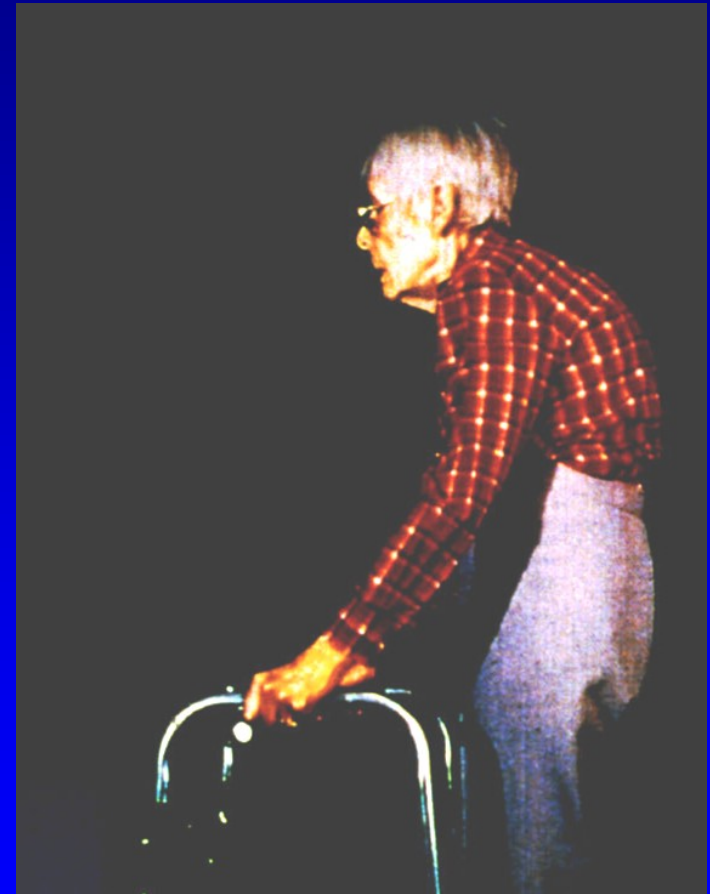
Prerequisite for good result

- Choice of the patient
- Preop. examination
- Prevention of infection
- Choice of the implant
- Operative technique
- Postop. management
- Activity of the patient
- Regular follow- up
- Prevention of infection
- Prevention of aseptic loosening

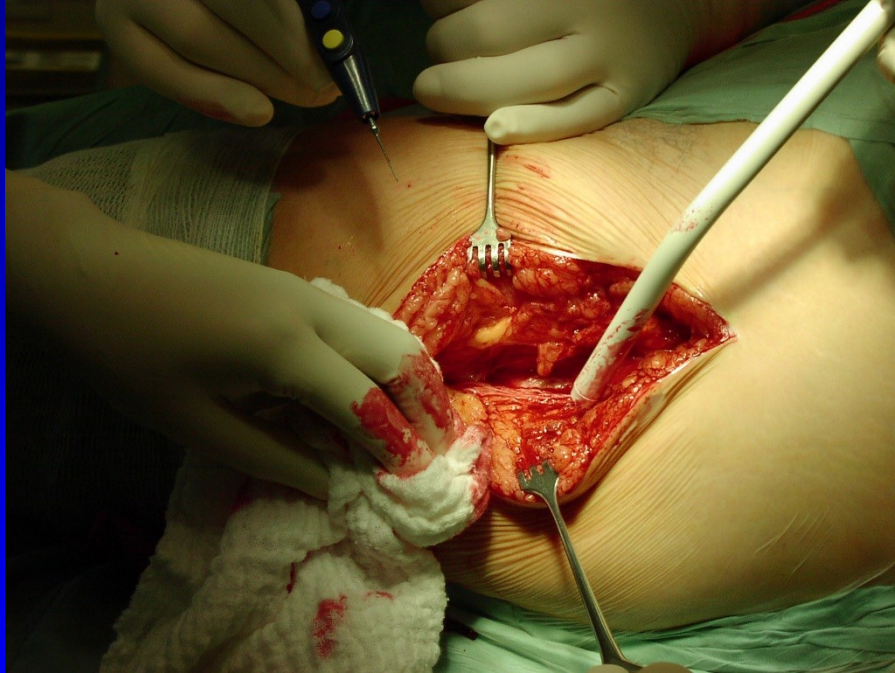


Contraindication

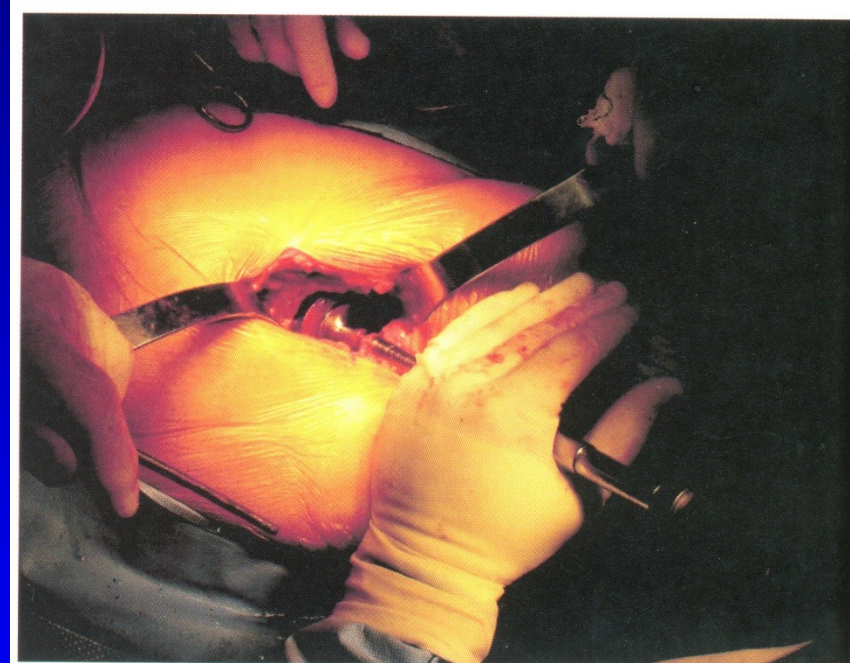
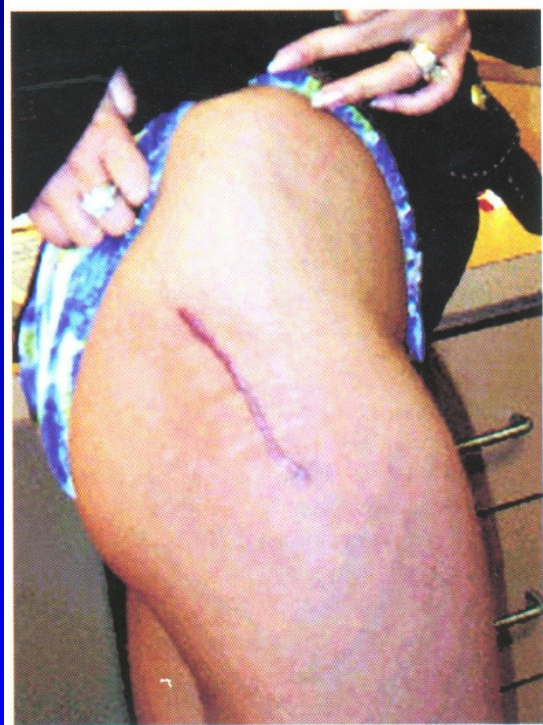- Active infection of the hip
- Infection in the body
- General condition not good
- Neurogenic arthropathy
- Extreme low bone quality
- No cooperation of the patient
- Relative: age over 80 y.
elevated ESR



Approaches



MIS- mini invasive surgery



Physiotherapy

1. In bed
 2. Sitting, drainage ex
 3. - 5. walking
 6. + stairs
- 7-21 – in physiotherapy dpt.
3 months- spa resort

Full weight bearing. Cemented THA after one month
Uncemented after 12 weeks

Fast track physiotherapy, discharge 3-4 days, home care

Operative technique

Femur – brush

pulsatile lavage

sealing of medular cavity prox.- dist.

drainage of the femur

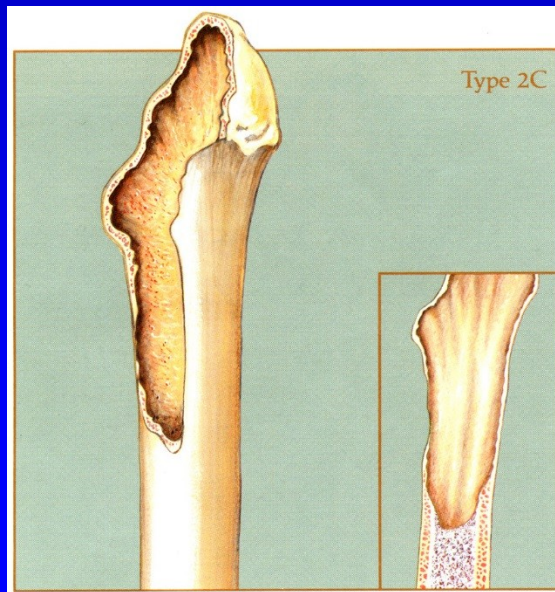
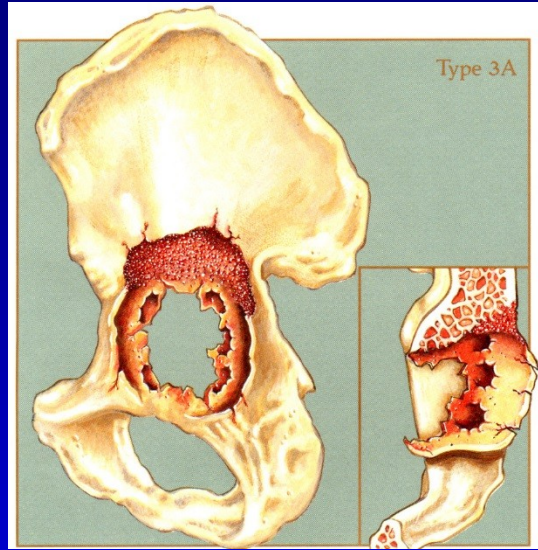
Vacuum mixing of bone cement

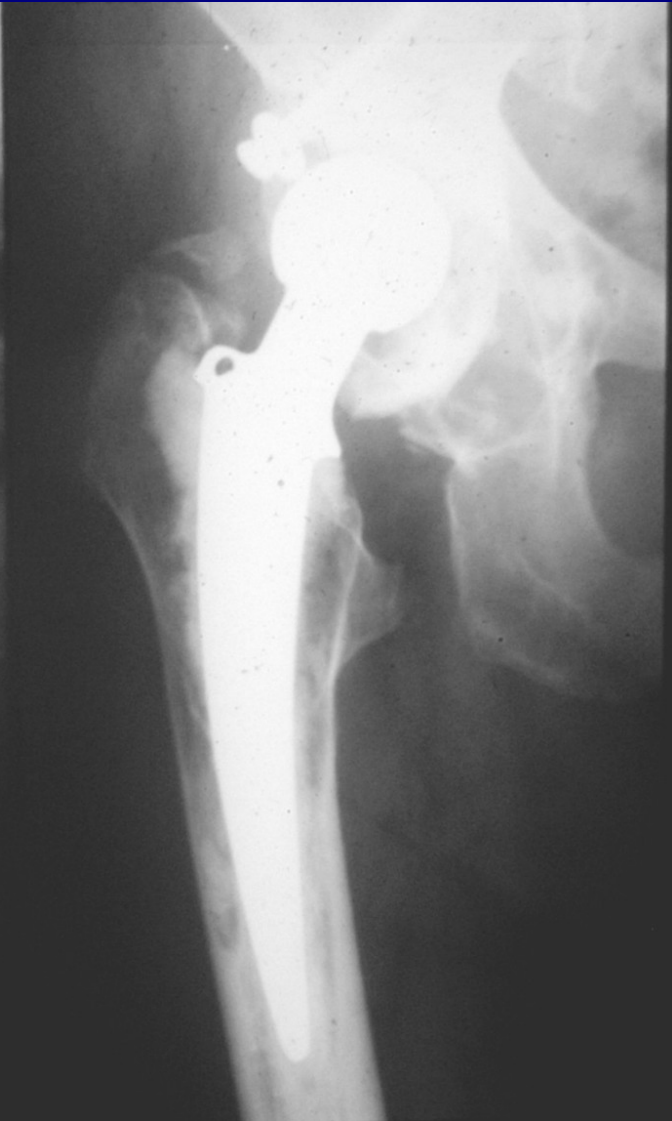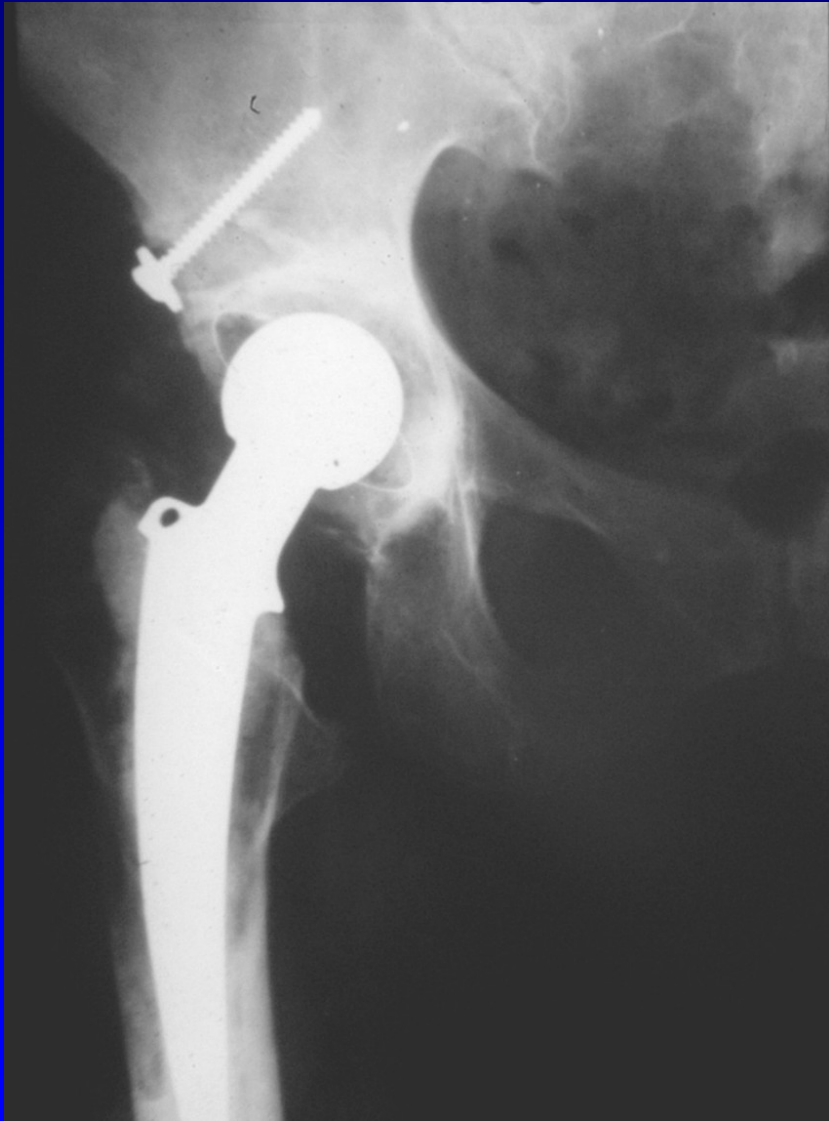
Pressurisation of bone cement

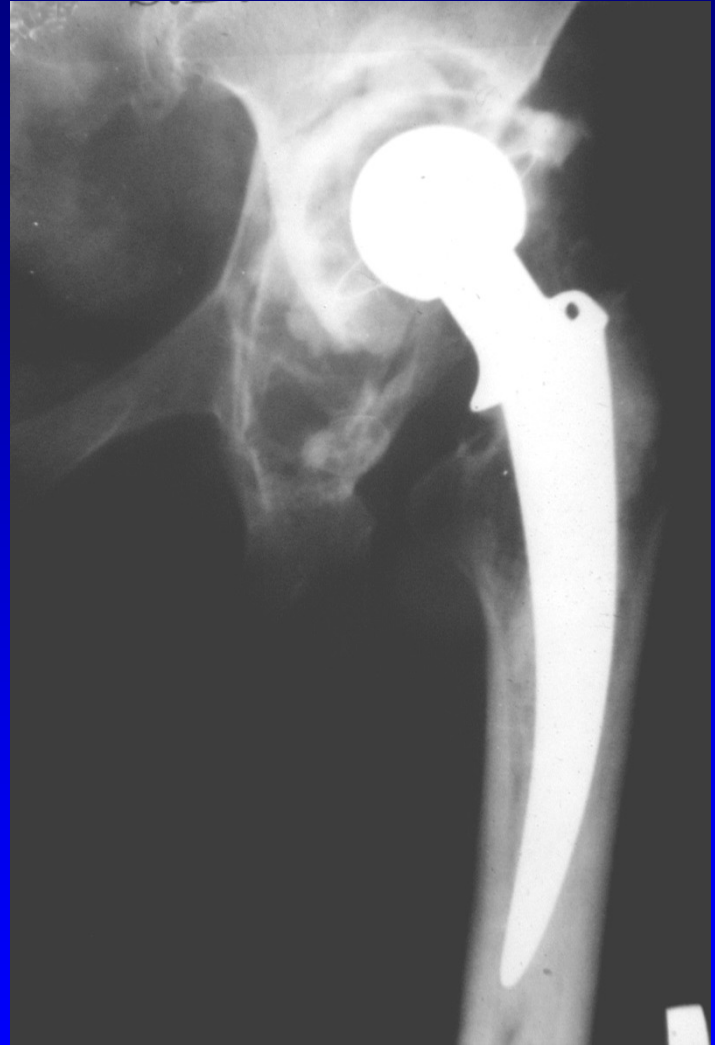
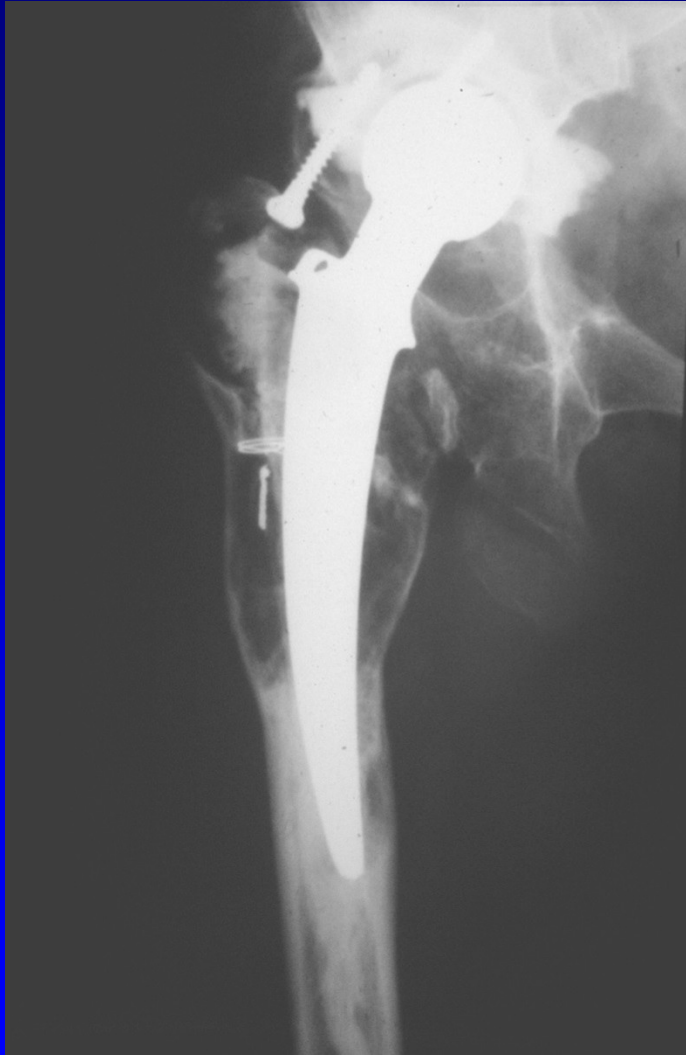Timing of insertion of the stem

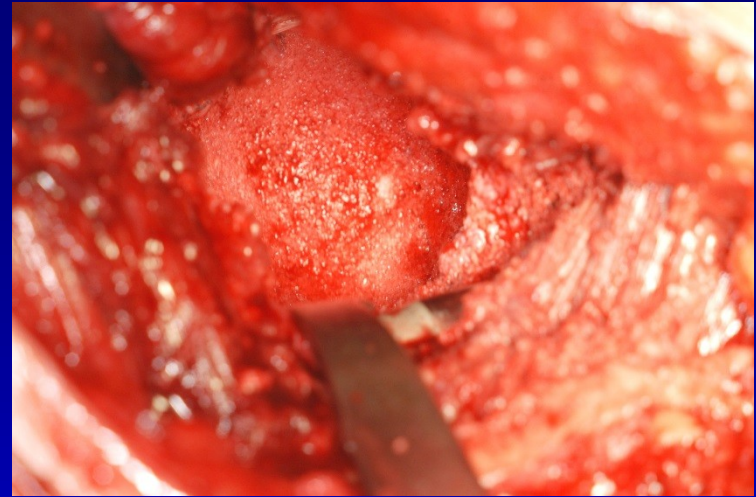
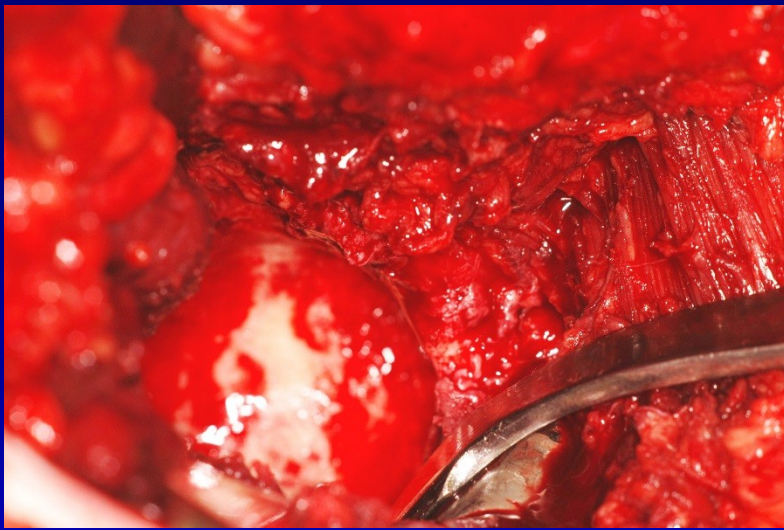
Continuous pressure

Revision THA

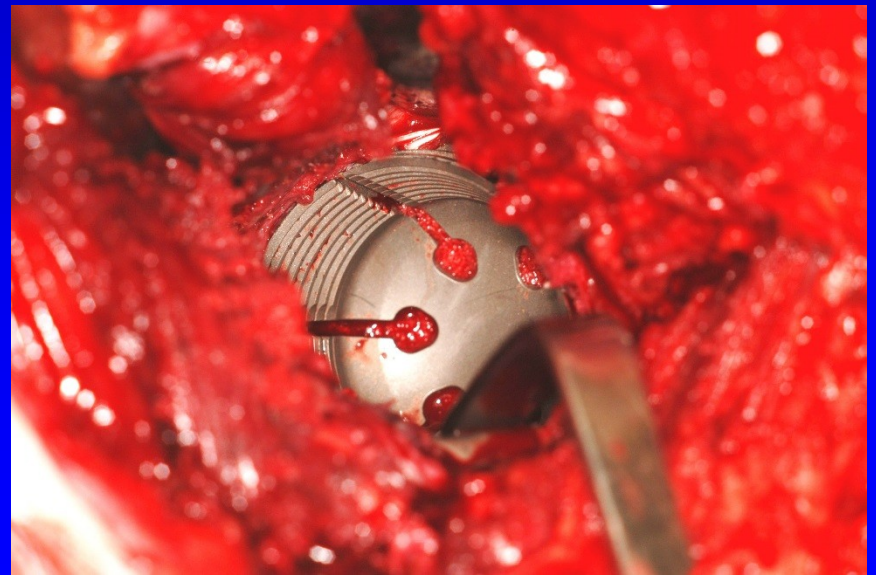
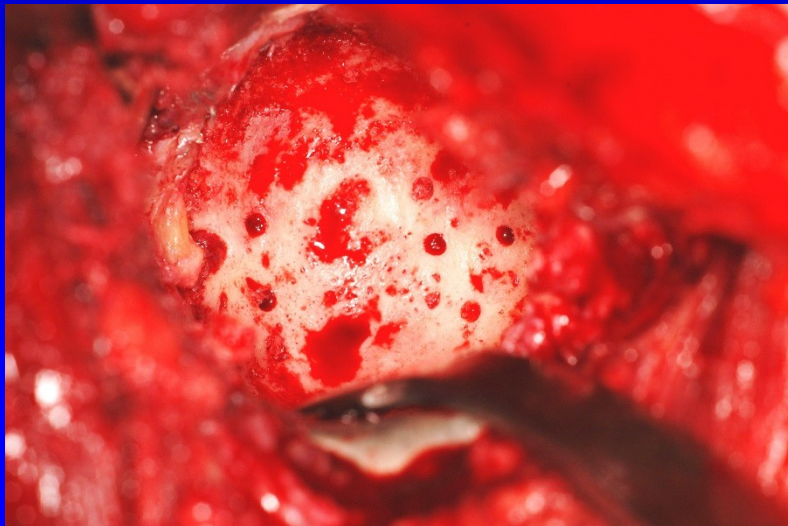



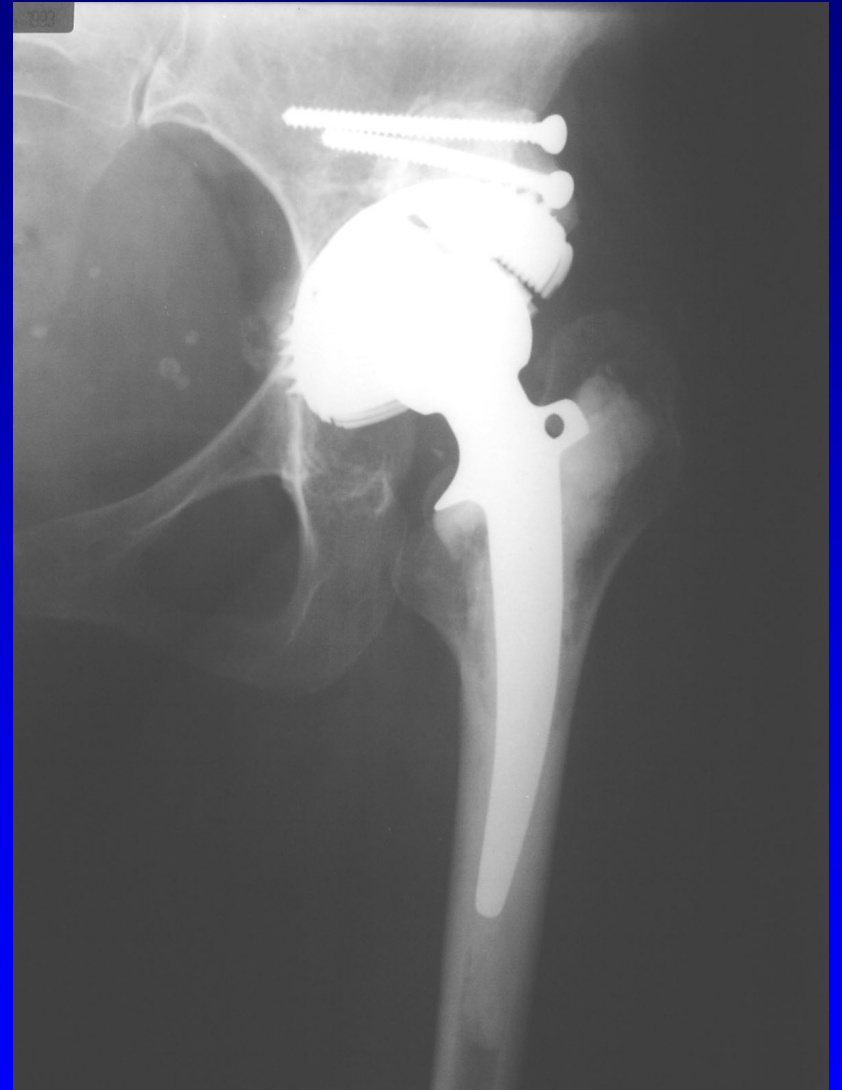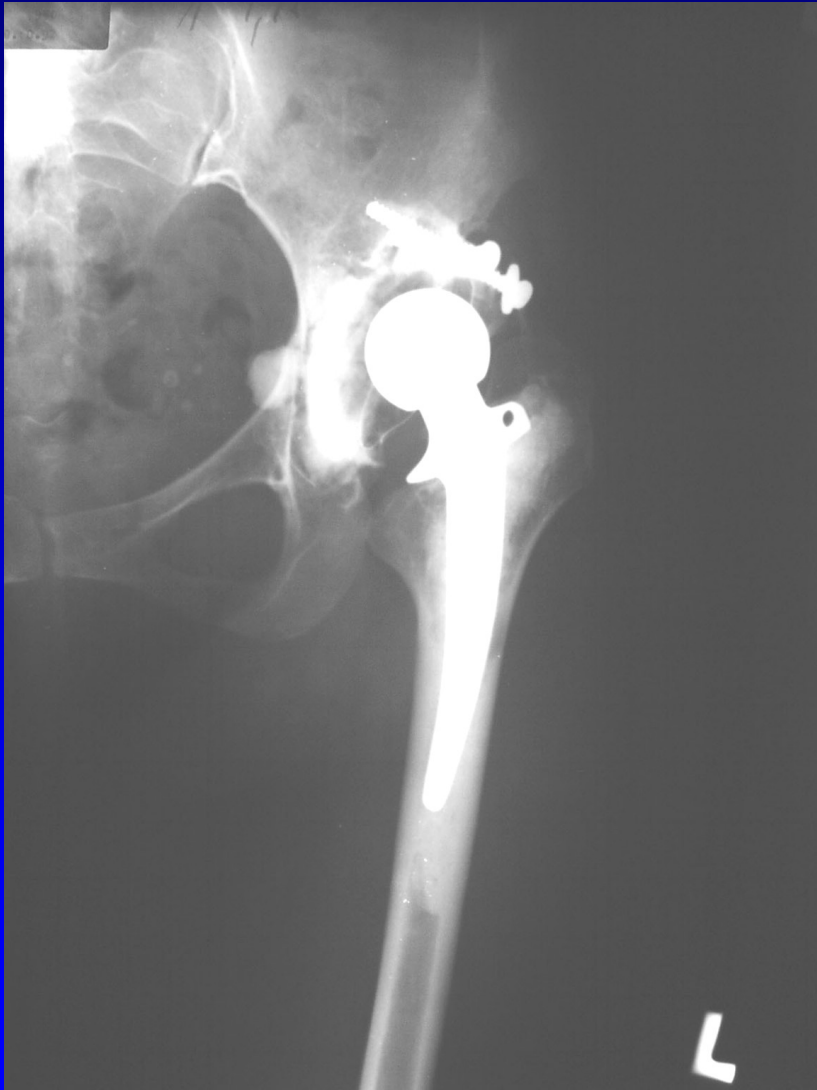


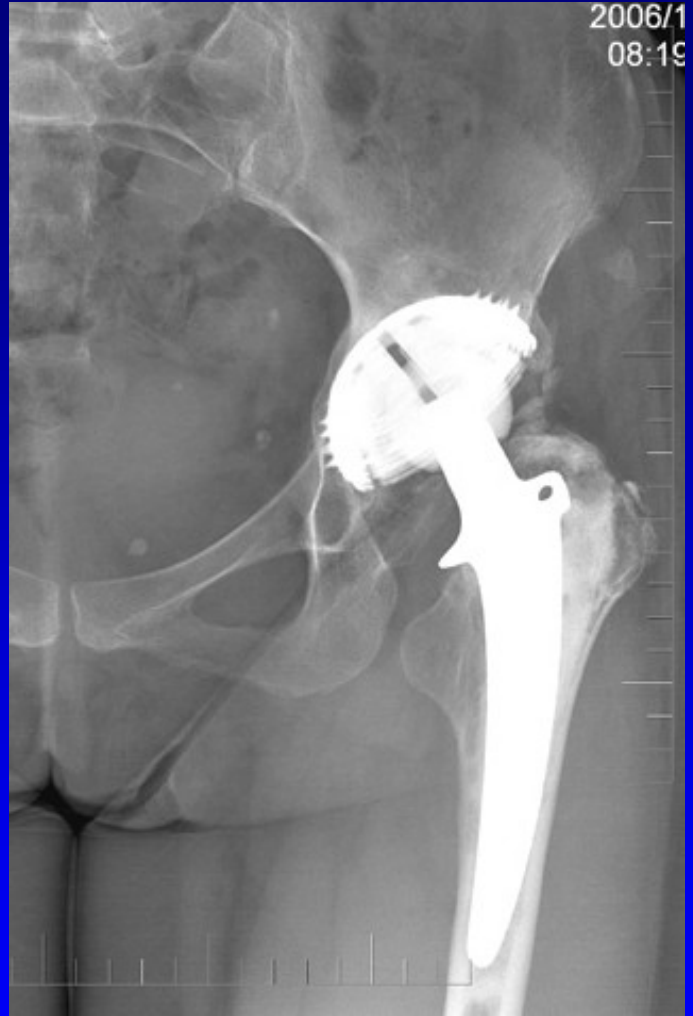
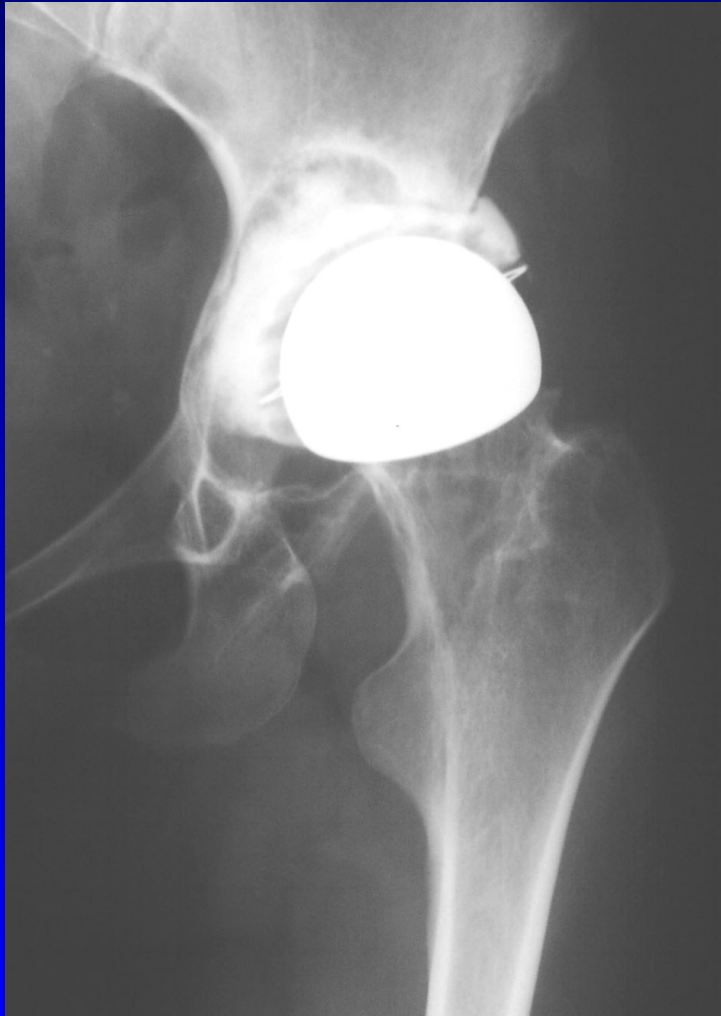


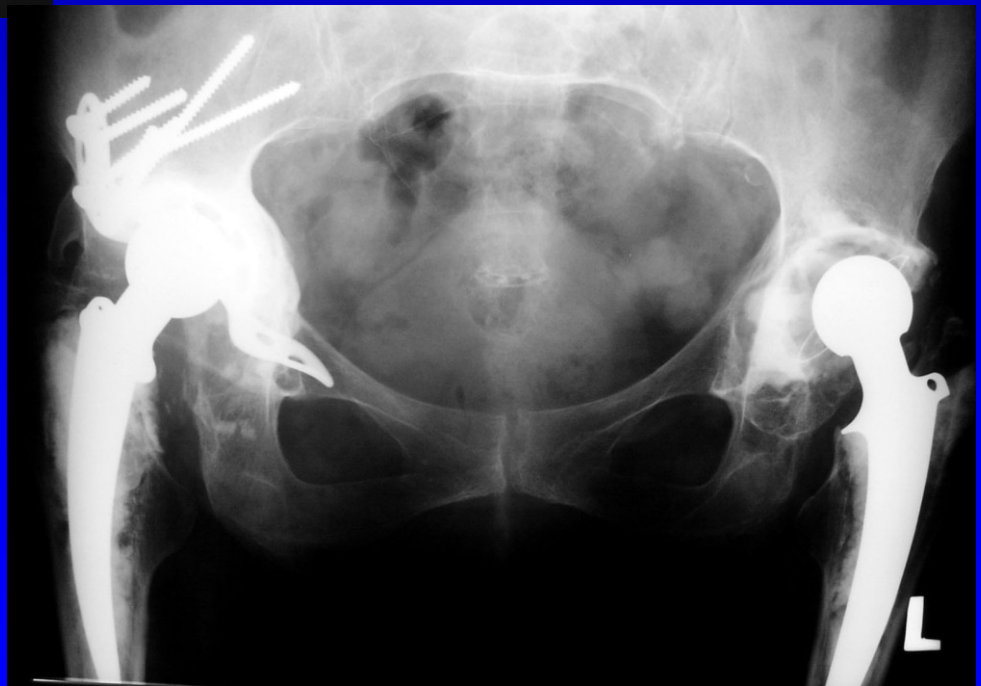
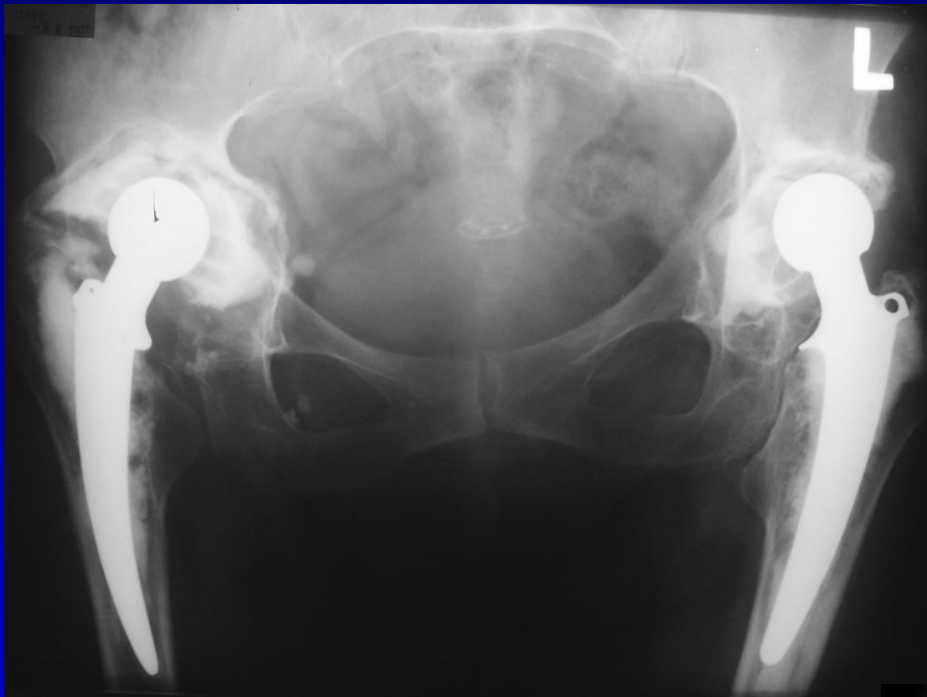
Revision of the acetabulum



Revision THA







Periprosthetic infection

St. aureus

St. coagulase negative

Streptococci

Enterococci, others

MRSA, MRSE

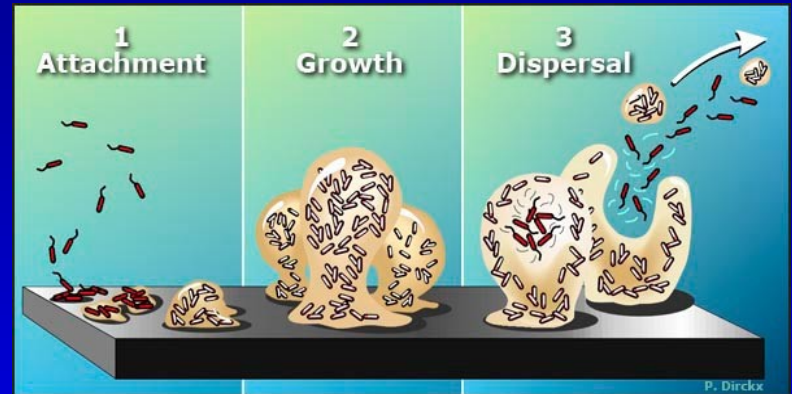Polyresistant G- bacteria

Sessile form and planctonic

Race for surface

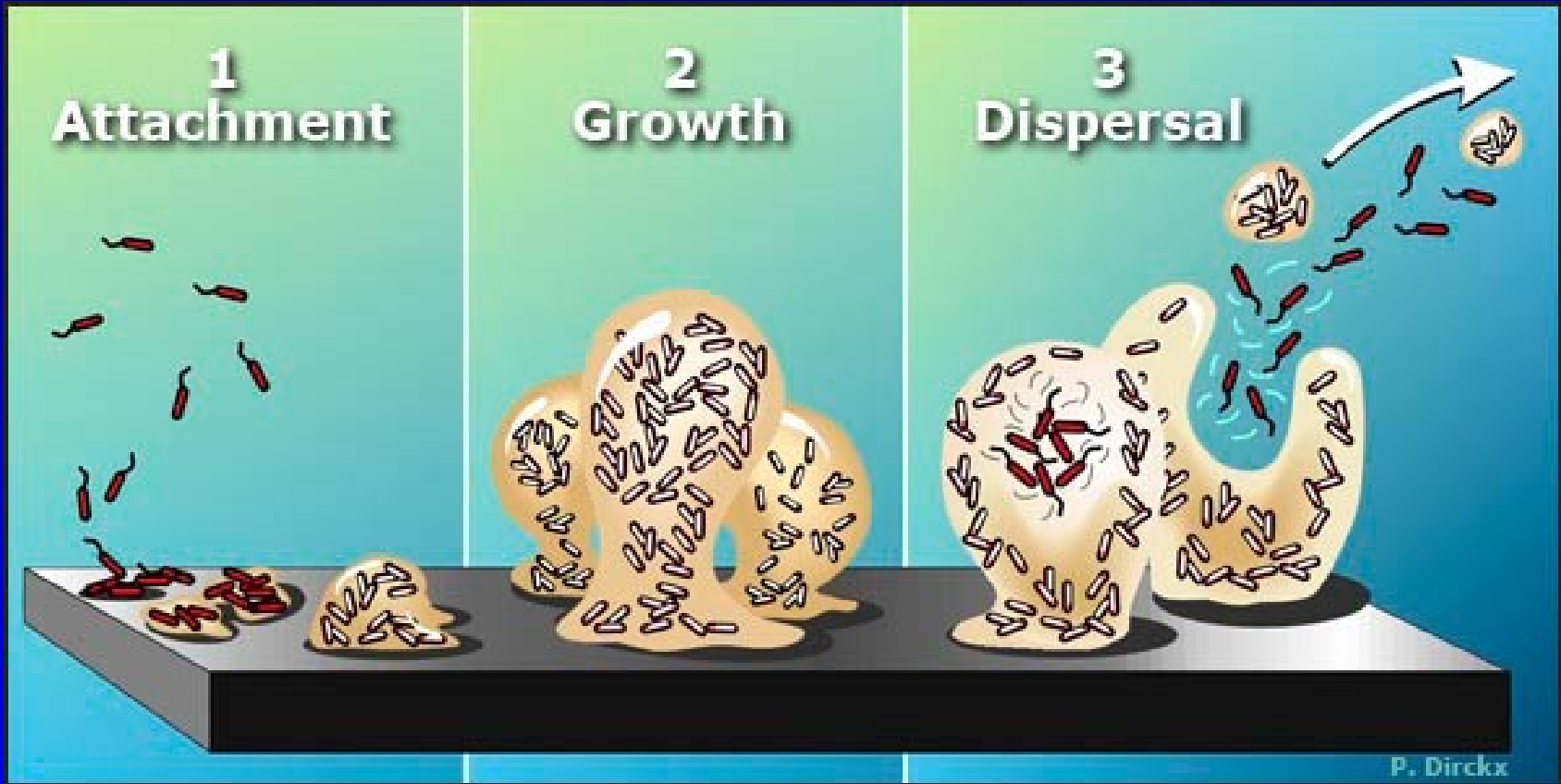
They produce glycocalyx- mucose substance
of glycoproteins

It leads to high resistance
to antibodies and antibiotics



Biofilm

Biofilm



Adhesion of bacteria
- reversible

Exopolymers
- glycolalyx
- extracelular matrix
irreversible

Releas to surrounding
tissue

Periprosthetic infection- diagnostics

Clinicly

Labor: CRP, leu, ESR

aspiration of pus

X-ray- osteolysis, loosening

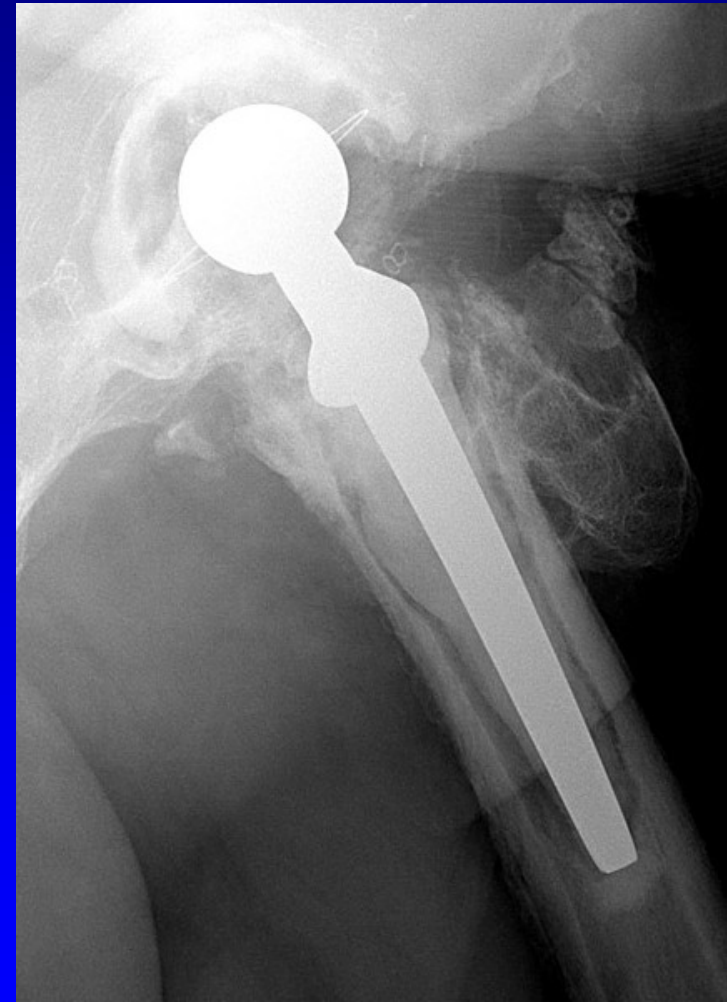USG (abscesus)

Scintigraphy

Sonication of the implant

Bacteriological examination

Long cultivation

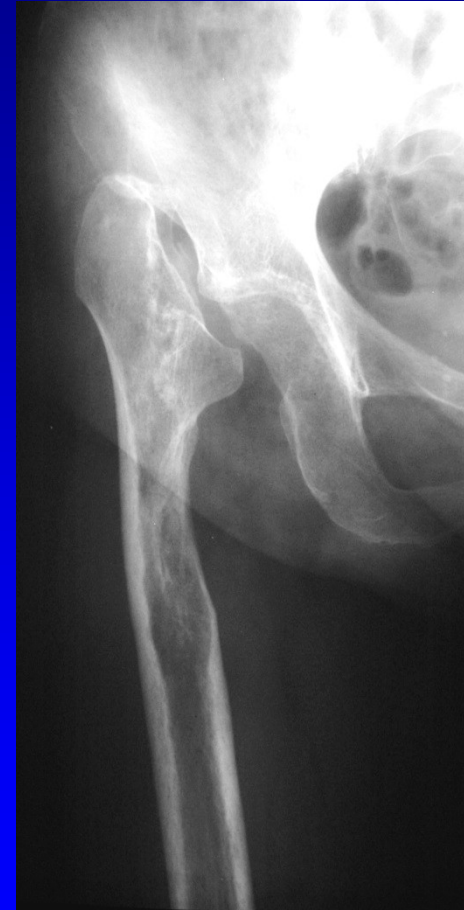

Periprosthetic infection- PPI

Acute PPI

Chronic PPI

Late haematogenous PPI



Management

To start treatment as soon as possible:
10-14 days from the onset of symptoms

Prerequisite: cooperation of the patient
informed physician

Periprosthetic infection-treatment

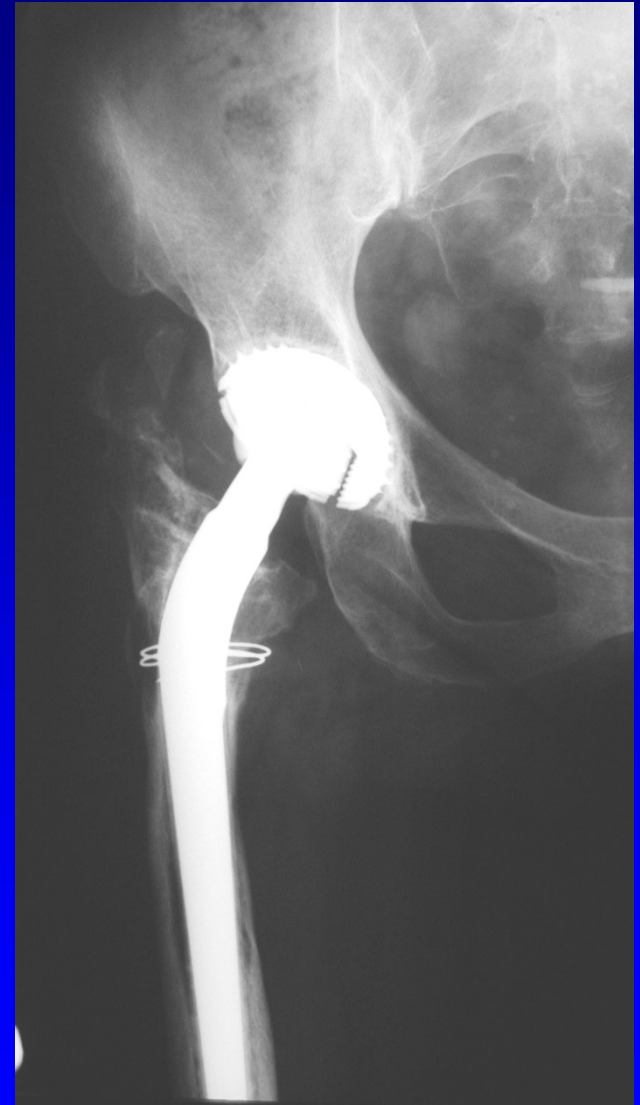
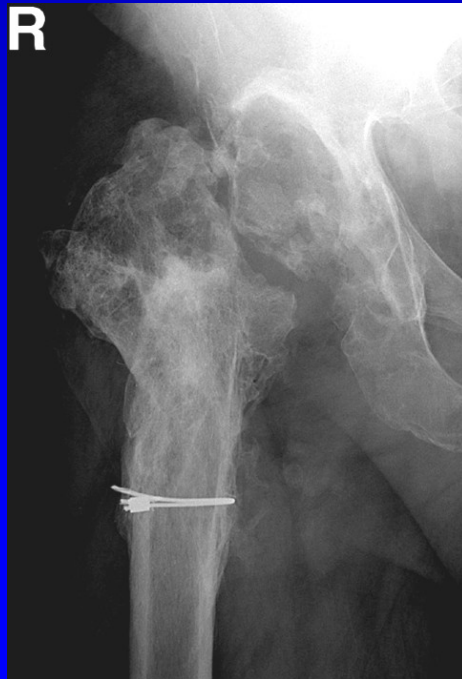Debridement

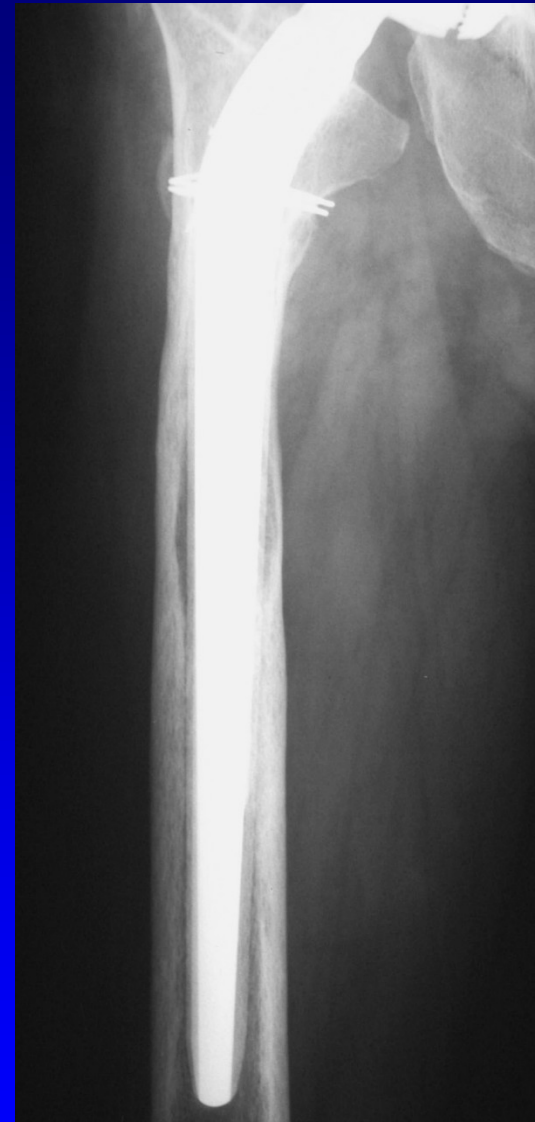
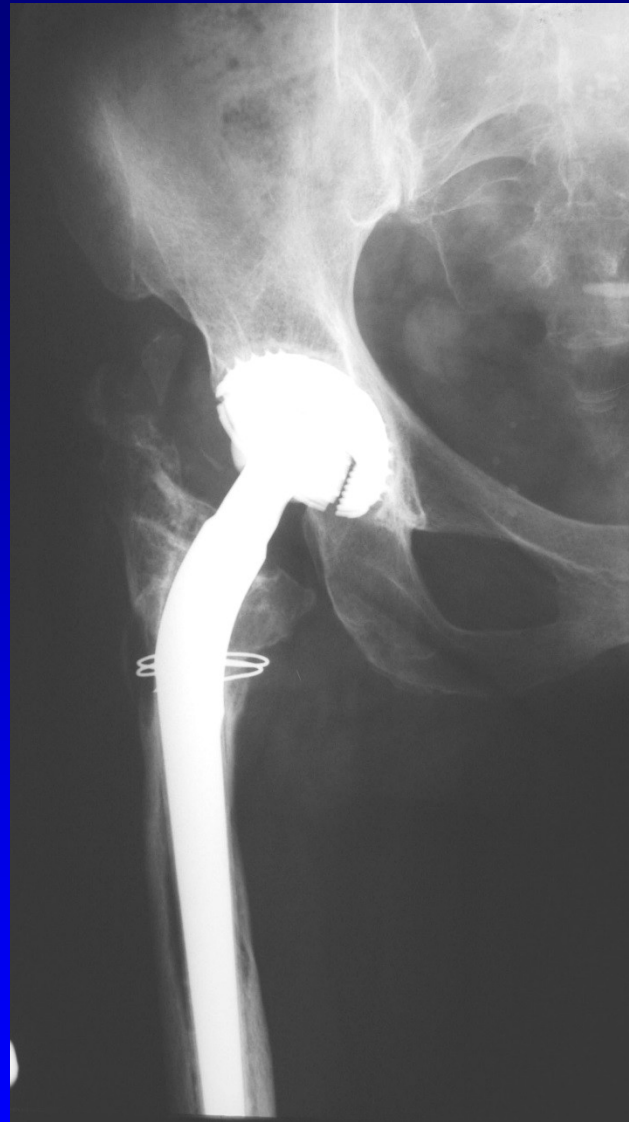
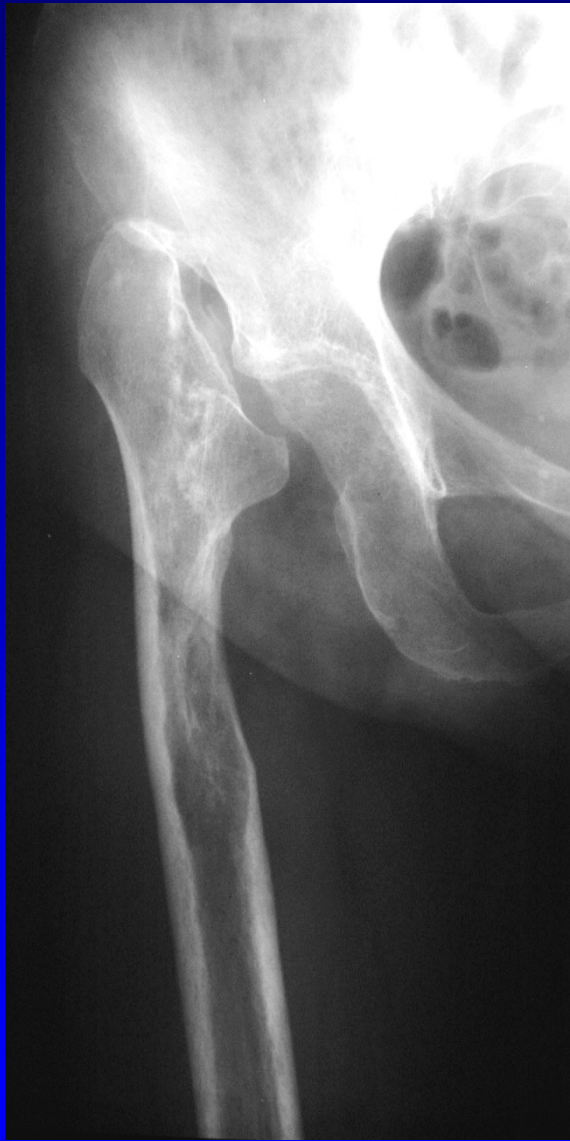One stage surgery

Two stage surgery

Resection arthroplasty

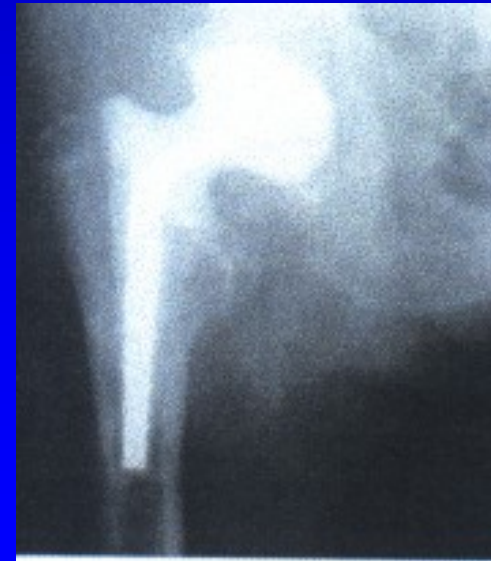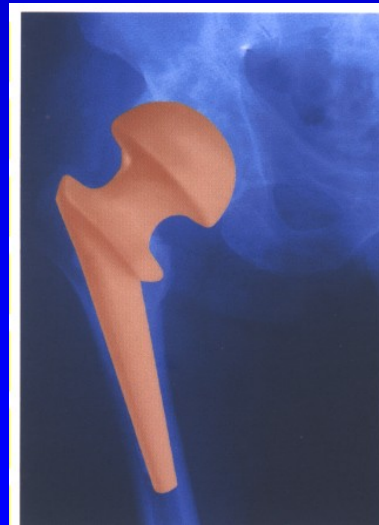
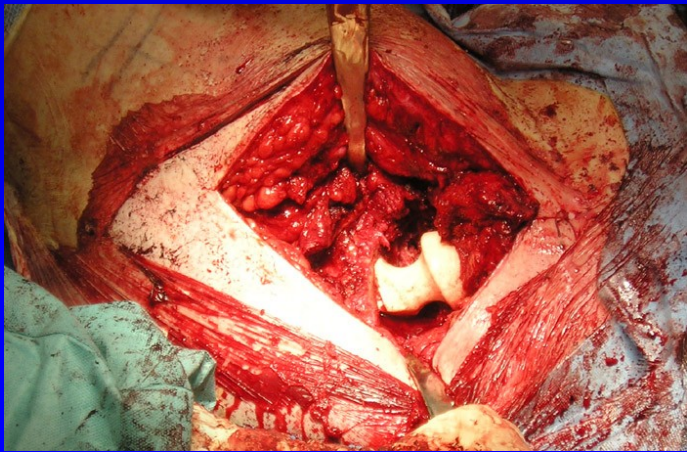
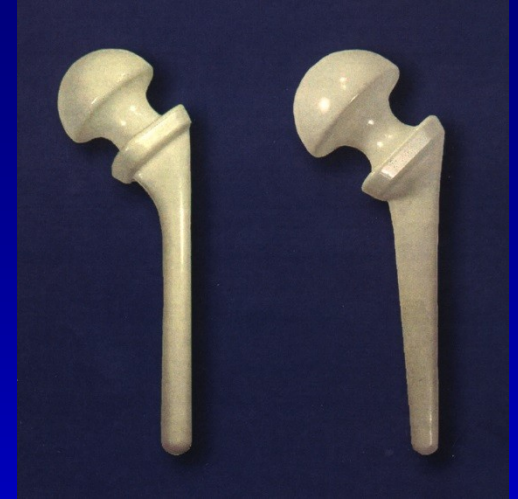Antibiotic suppression





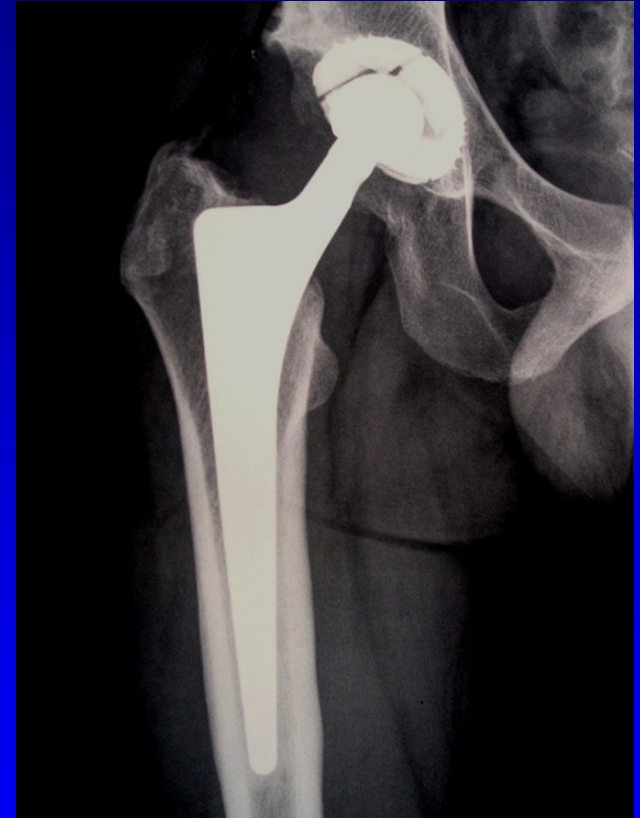
Hip spacers

- Two stage surgery
- Better ROM
- Better walking
- Revision is easier
- Local concentration of antibiotics
 - Gentamycin a Vancomycin
 - Cover 90 % of all pathogens



Principles

Experience of the hospital
Long term results
National registries
Operative technique
Reliable implants
Activity of the patient
Regular follow up



Daily activity after THA

No lifting and wearing of heavy objects
No strenuous manual labor
Limited running and jumping
No contact sports

Recommended sports:
swimming, bicycle, tennis
tourism, skiing?

