

Pathological fractures

Pazourek L., Rozkydal, Z.

I.orthopaedic dpt., St. Anna Hospital,
Medical faculty, Brno

Features

Fracture in bone with pathological lesion decreasing the strength of bone

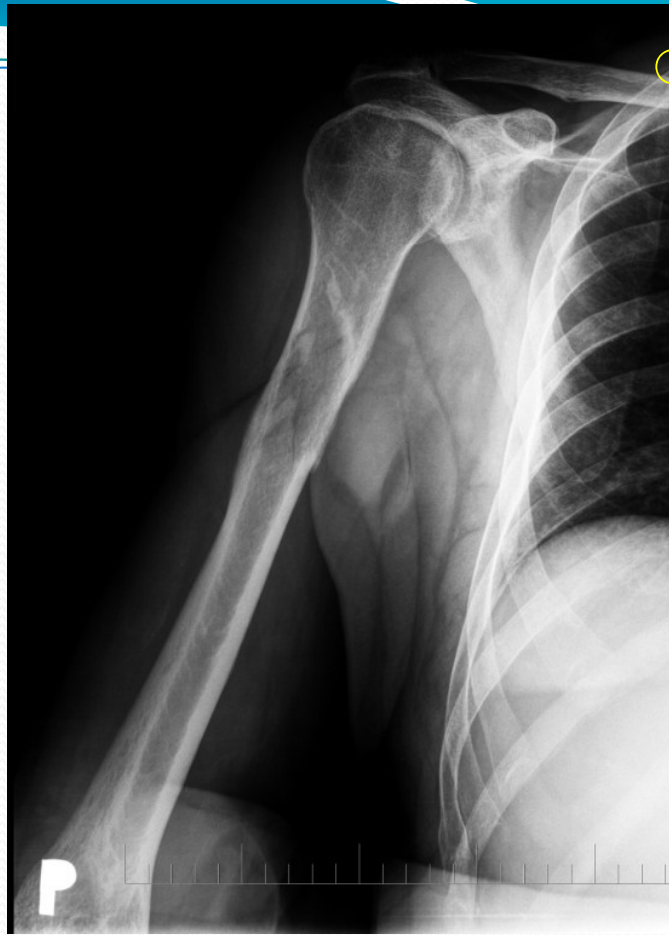- Without trauma
- Minimal violence
- Normal traumatic mechanism

Etiology

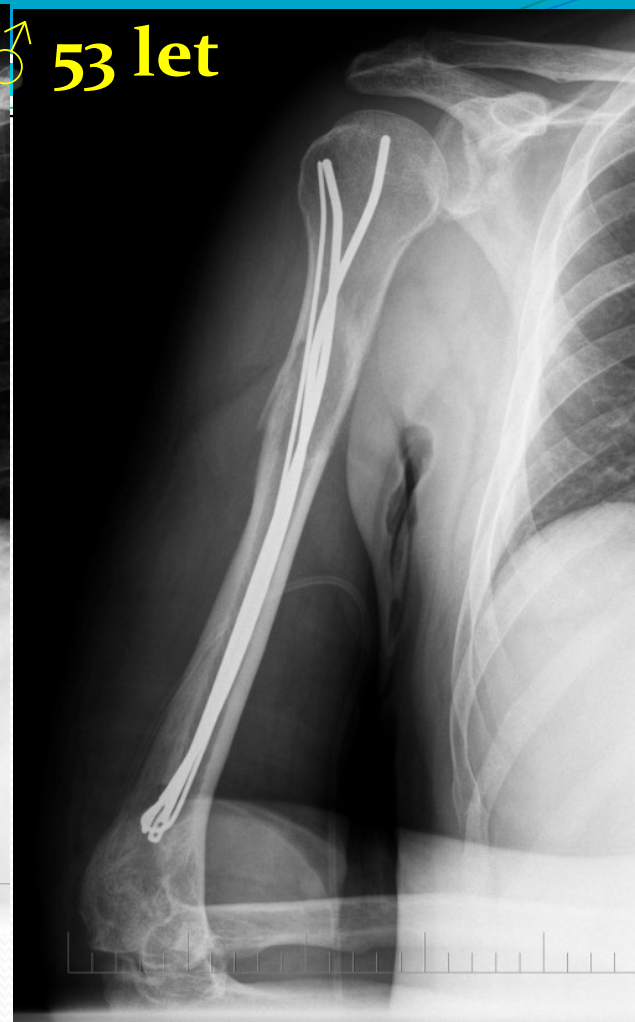- Metabolic diseases
 - osteoporosis
 - osteomalacia, HPT
- Local lesions
 - bone metastasis, multiple myeloma
 - benign tumors
 - malignant tumors
- Congenital anomalies
 - osteogenesis imperfecta,..
- Other entities
 - Paget 's disease of bone, fibrous dysplasia
 - osteomyelitis
 - osteonecrosis

Fr. by opening a
bottle

i.m. osteosynthesis



♂ 53 let

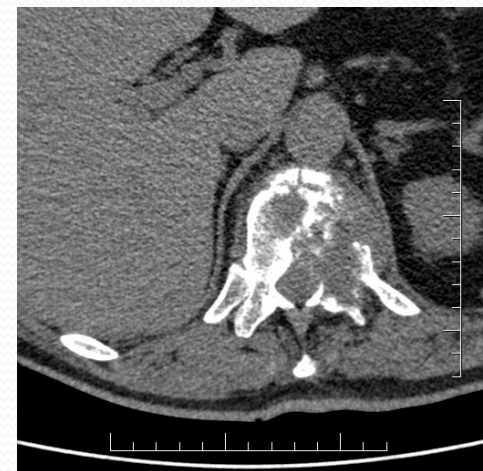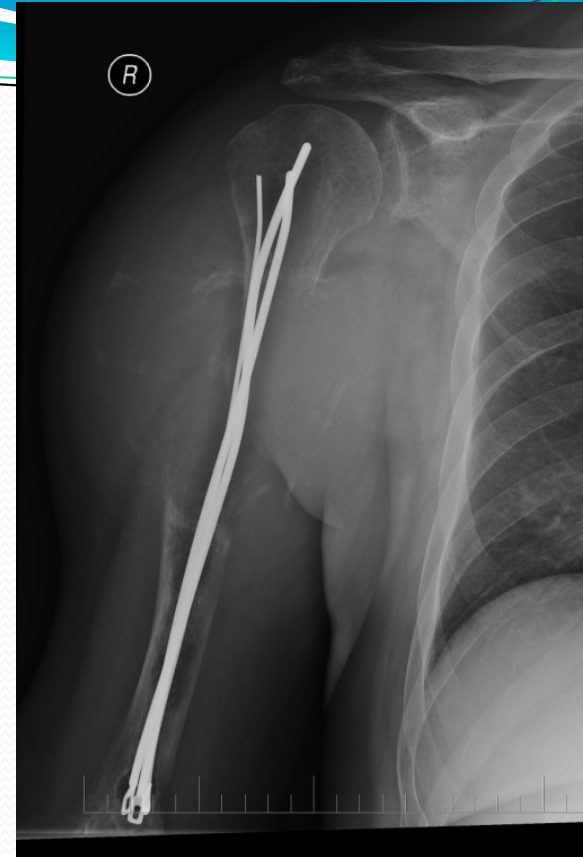


Increasing swelling and mass in
upper arm

X- ray repeated no finding

back pain after 3 months

- After 4 months referred to our clinic
- Exulceration
- Th 12 large osteolytic lesion
- Risk o paraplegia
- Metastasis of carcinoma from small cells



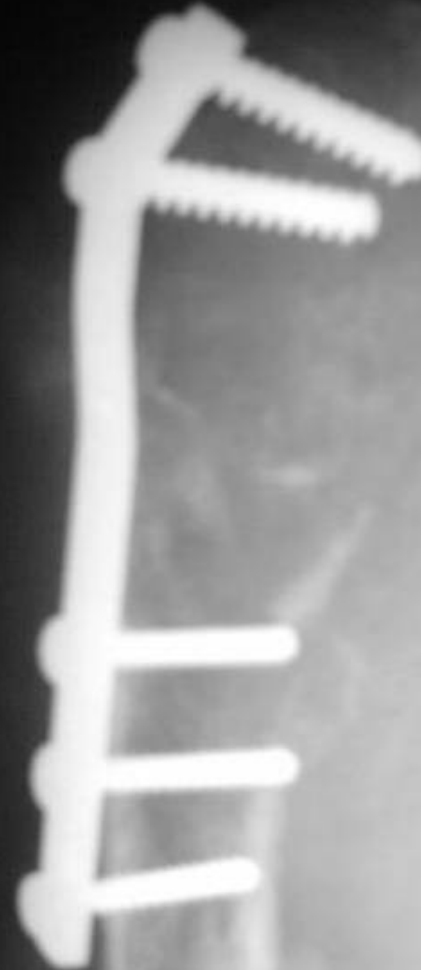
Metastasis of carcinoma

♂ 26 let

Fr. by driving a car

- AO plate osteosynthesis
- Afterwards increasing mass
- X ray after 3 months

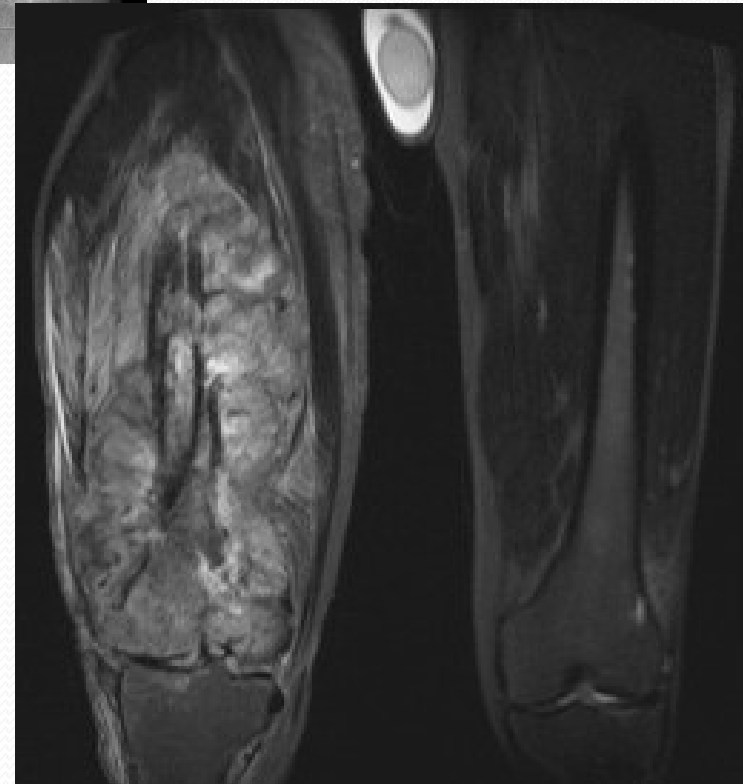
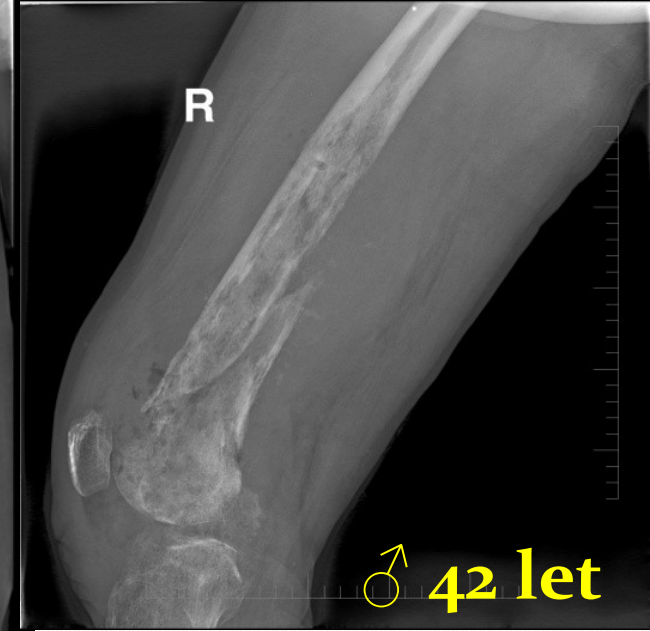
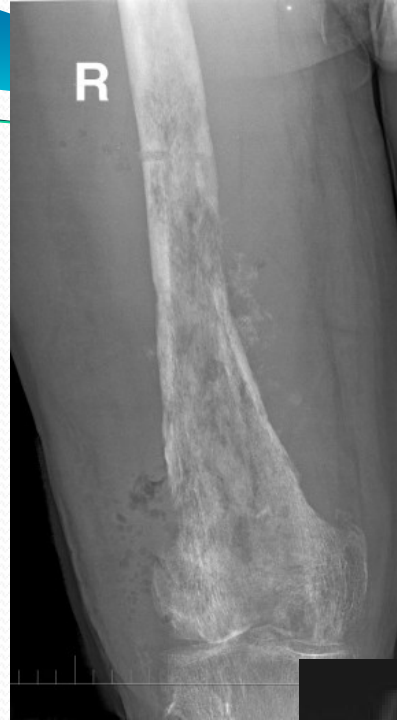**OSTEOSARCOMA
HIGH-GRADE**



Fall on stairs

- Supracondylar fr.
- Osteosynthesis with a nail
- Increasing pain and swelling
- After 6 months removal of metal a biopsy
- Fracture not healed
- Referred to our clinic

LEIOMYOSARCOMA G3



Bone metastases of carcinoma

- Breast, prostate, kidney, lung, thyreoid gland
- Assessment of prognosis
 - Visceral or bone lesions, solitary or multiple lesions
 - Type of primary tumor, staging
 - Time of first occurrence
 - Sensitivity to other treatment
 - Comorbidities and general condition
 - Pathological fracture makes always the prognosis worse
 - Multidisciplinary access

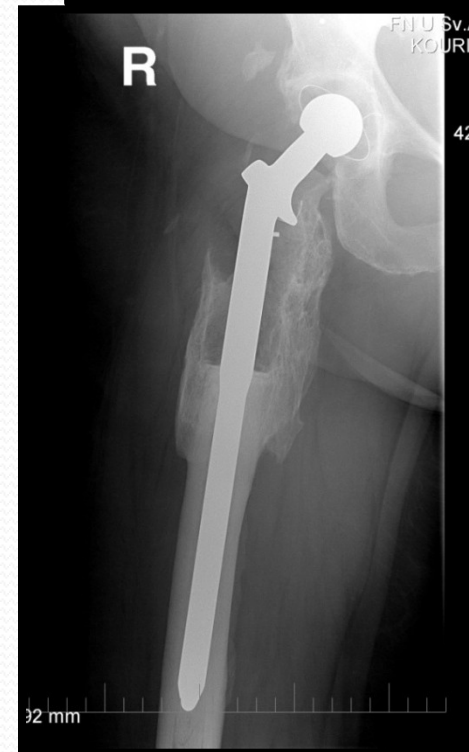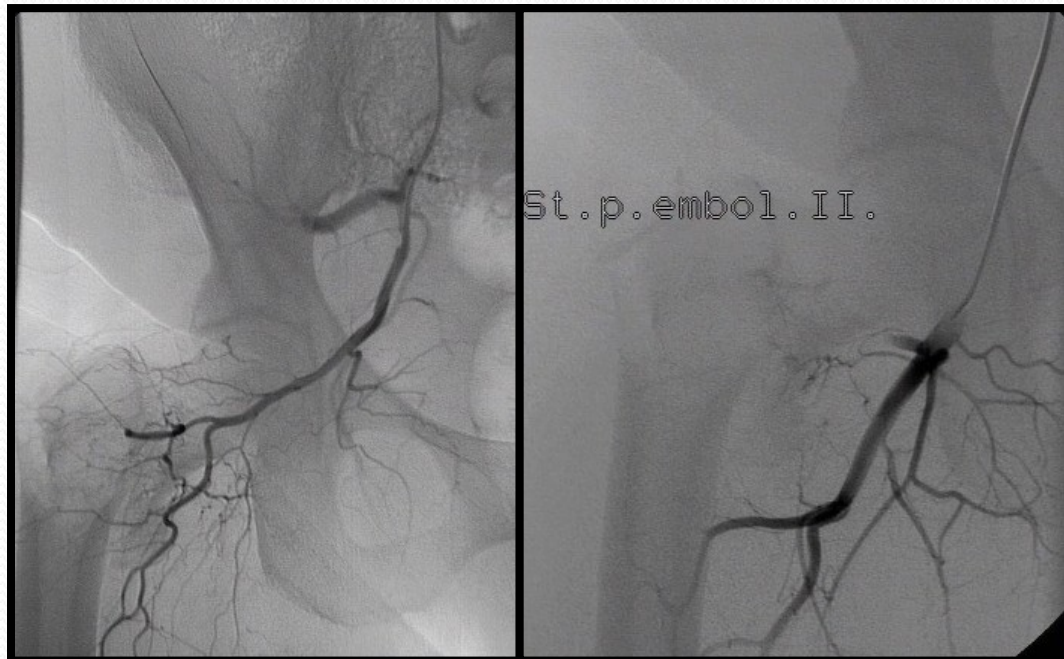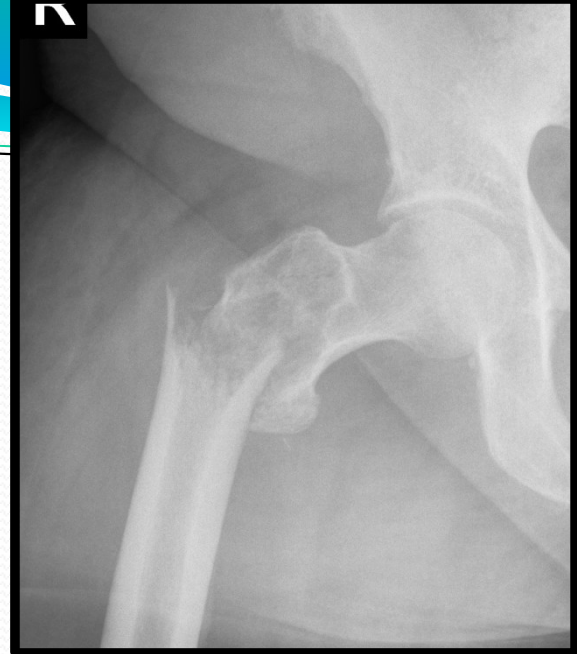Mirel's score

points	1	2	3
Localisation	Upper extr.	Lowe extr.	Pertrochant. region
Pain	low	medium	big
Type	Osteoplastic	mixed	Osteolytic
Size	<1/3 widht of bone	1/3 – 2/3 widht of bone	>2/3 widht of bone
≤ 7 ponts	Risk 4%		Preventive ORIF no
8 points	Risk 15%		Indication for ORIF on border
≥ 9 points	Risk 33% and more		Indication for preventive ORIF

TU-THA

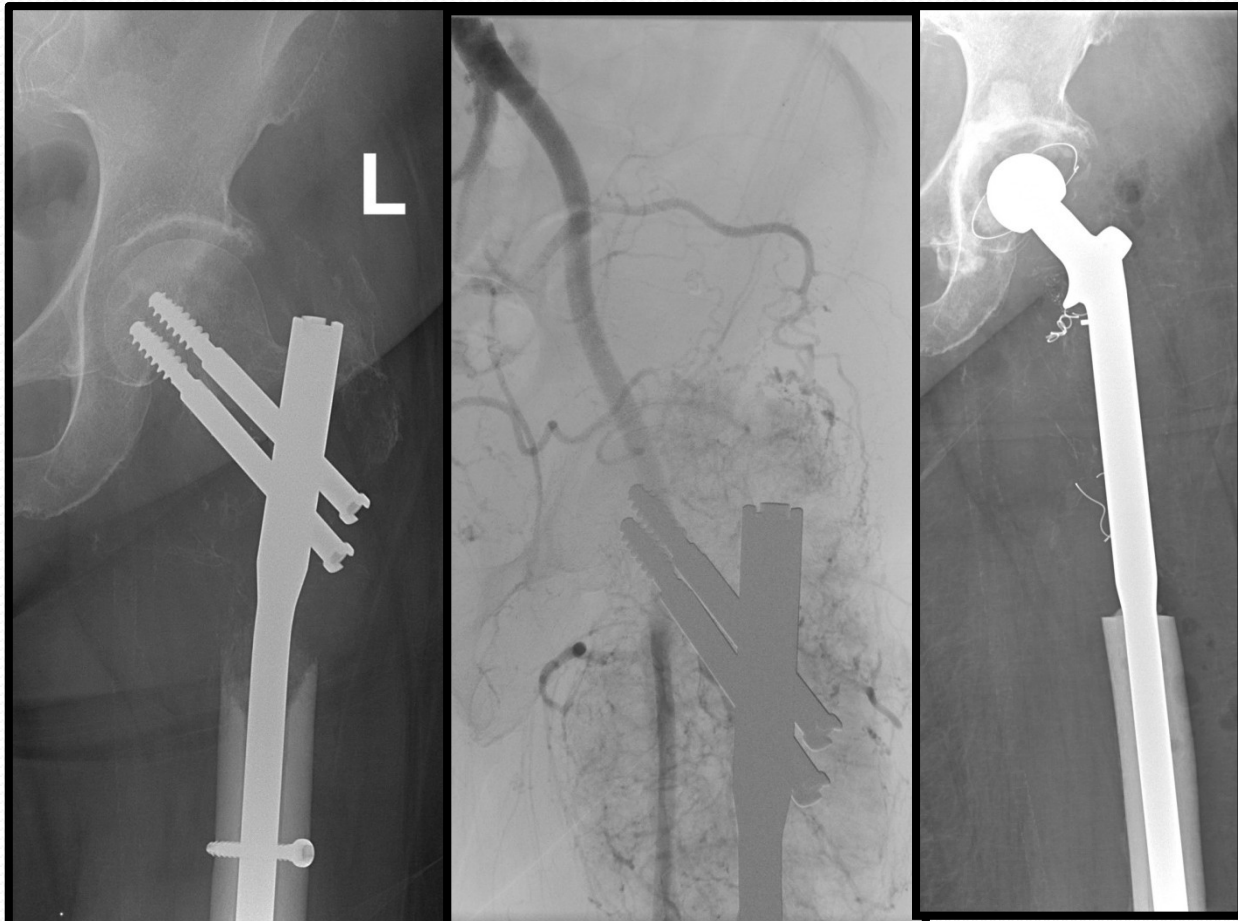
optimal solution

- Metastasis of clear cells renal carcinoma (angiography with embolisation)



- Condition after osteosynthesis for pathological fr. with metastasis of renal tumor, progresion of osteolytic lesion
No adjuvant chermotherapy

Angiography +
embolisation,
resection
TU THA



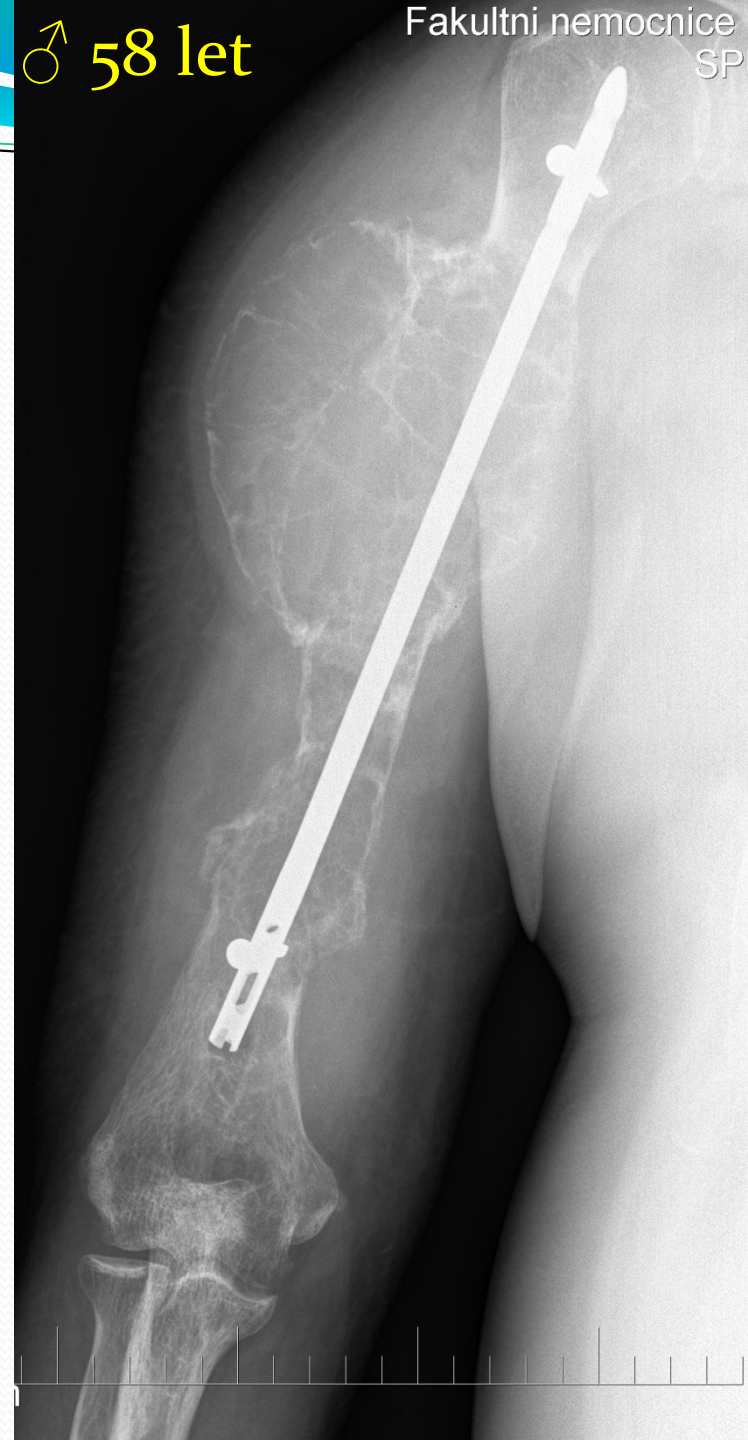Total thyroidectomy 7 years ago,
radiotherapy and chemotherapy

- X-ray osteosynthesis 2 years ago,
no further treatment

METASTASIS of thyroid carcinoma

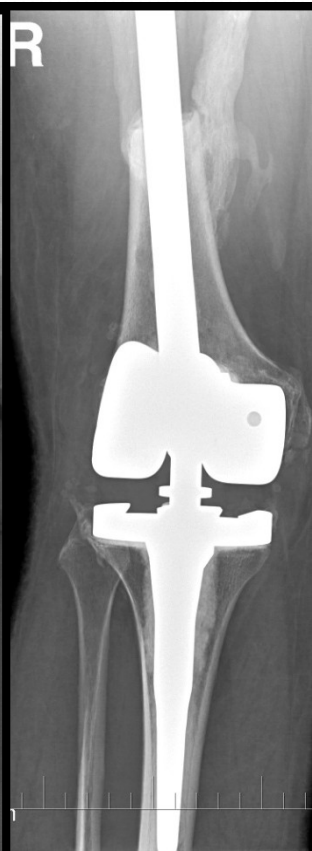
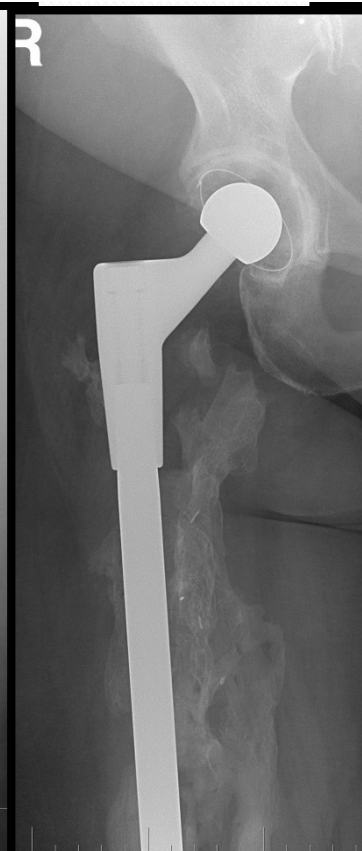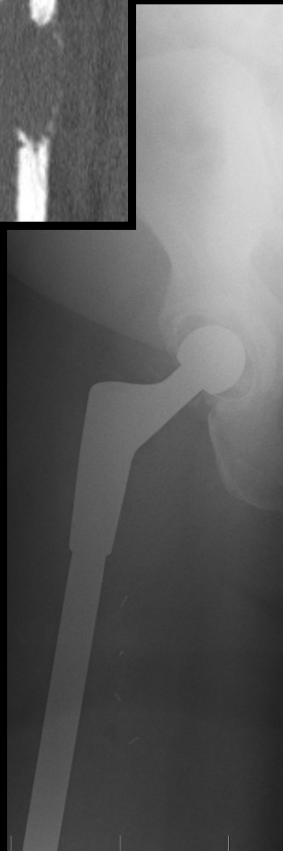
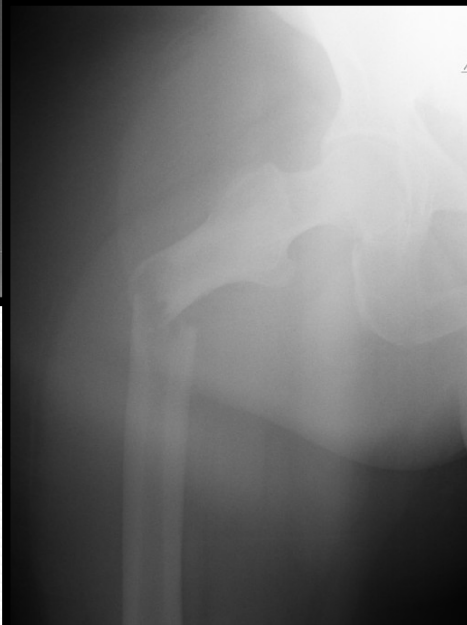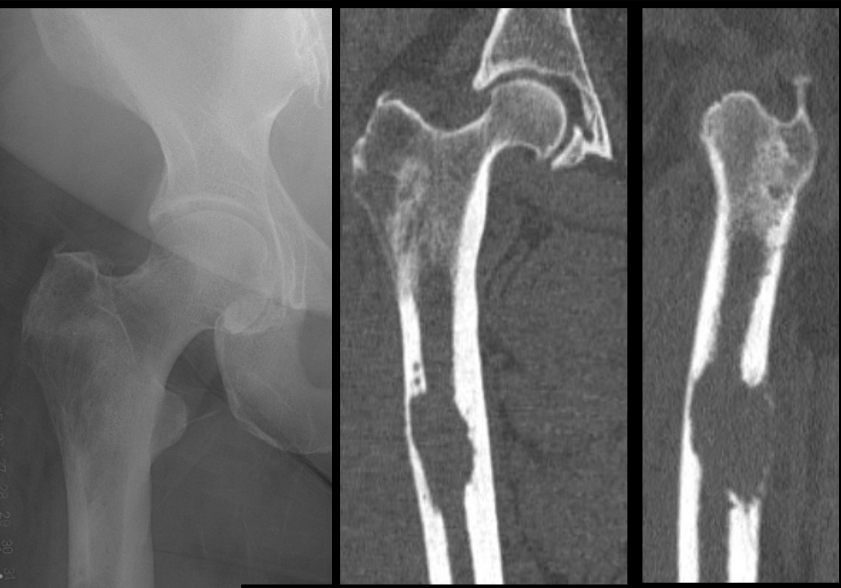- No further treatment for humeral
lesion
- No radiotherapy

Disarticulation in shoulder

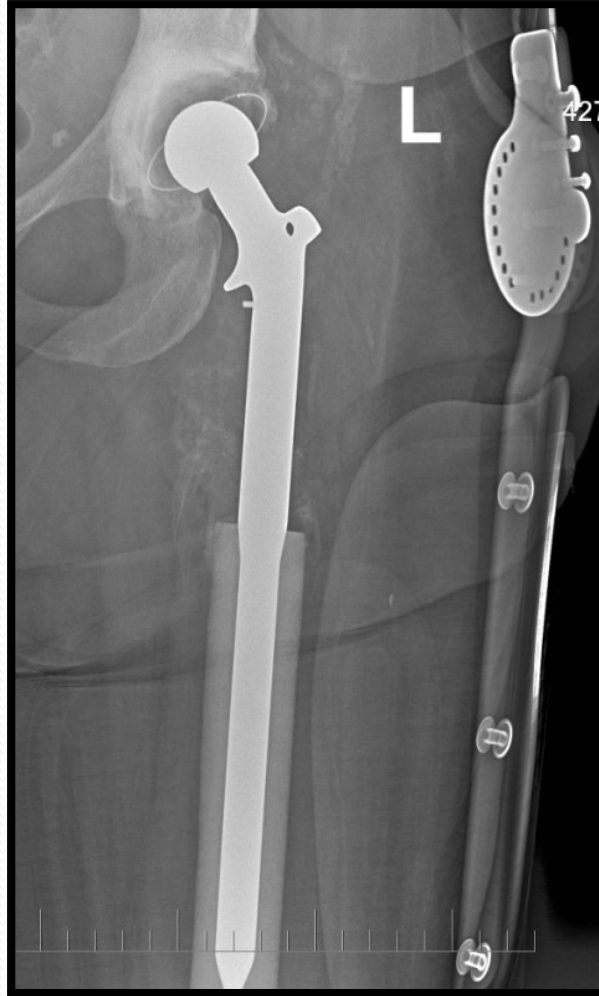
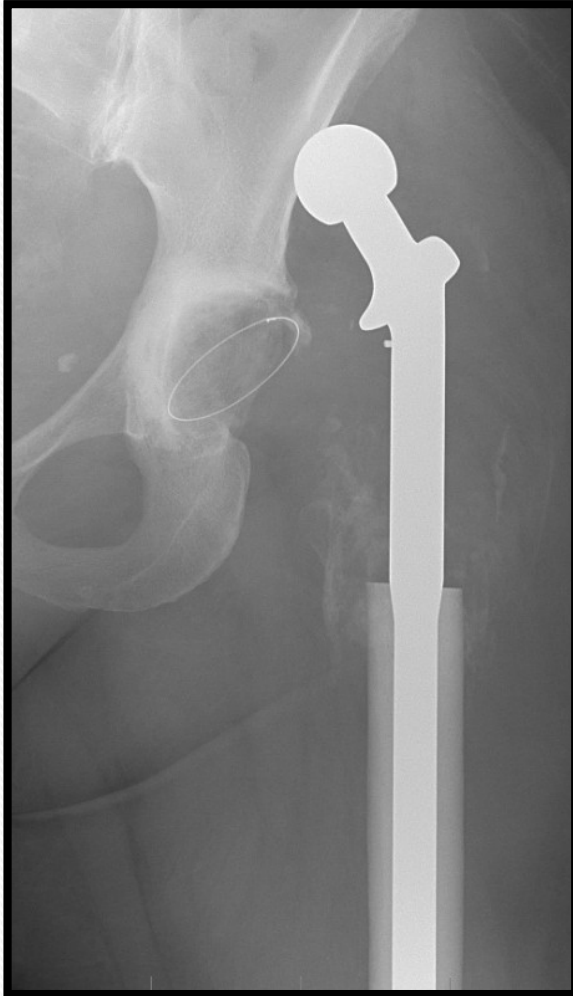
Total femur

Metastasis of breast carcinoma,
good prognosis

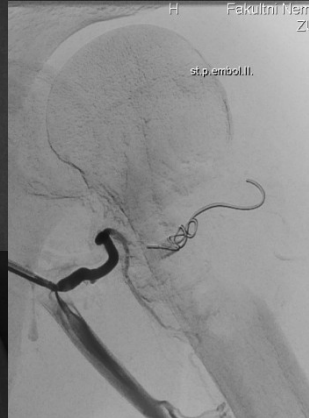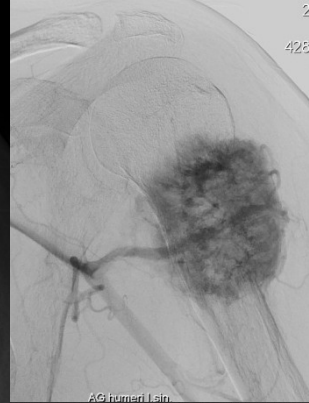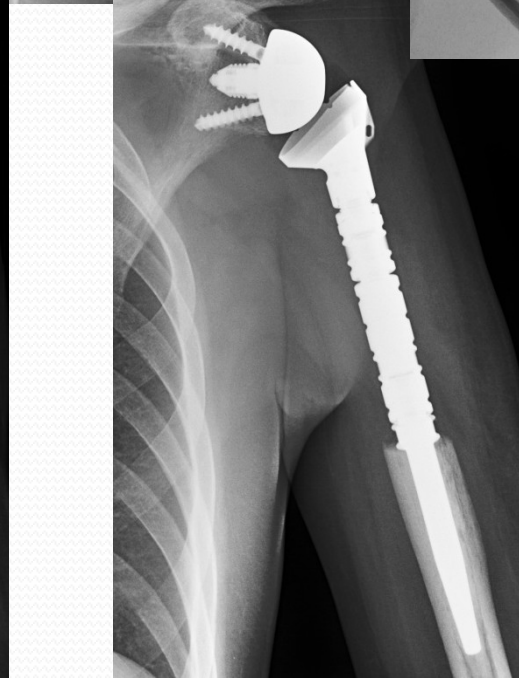
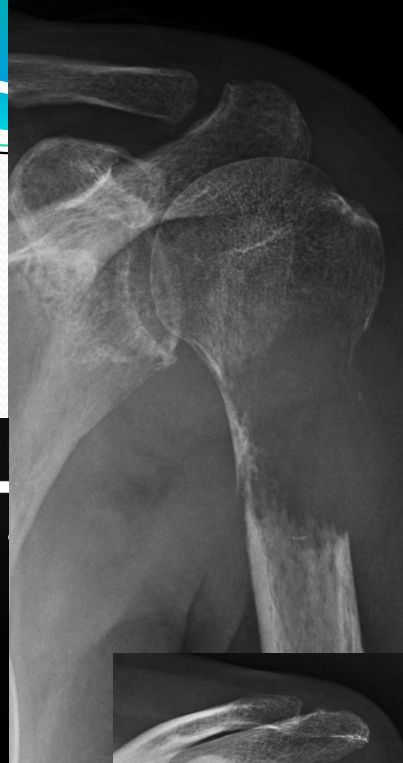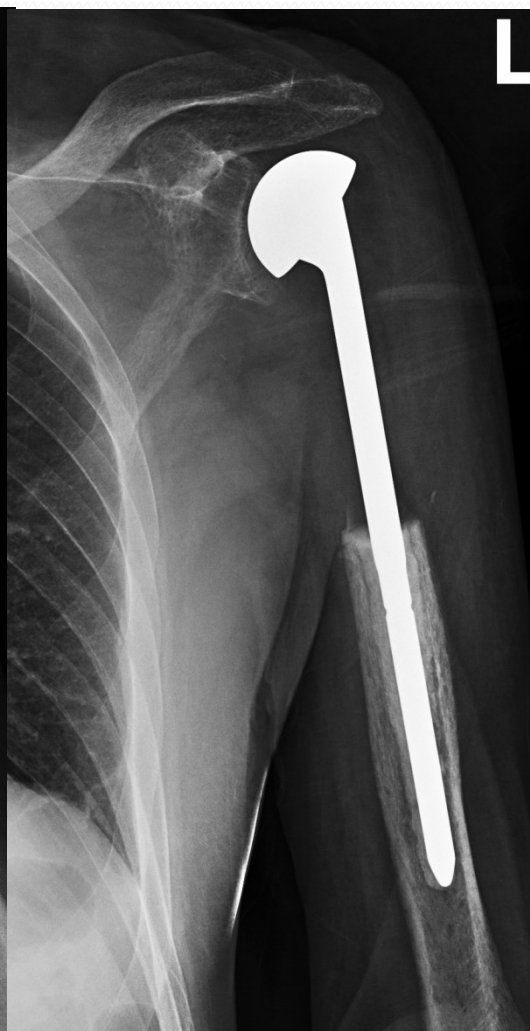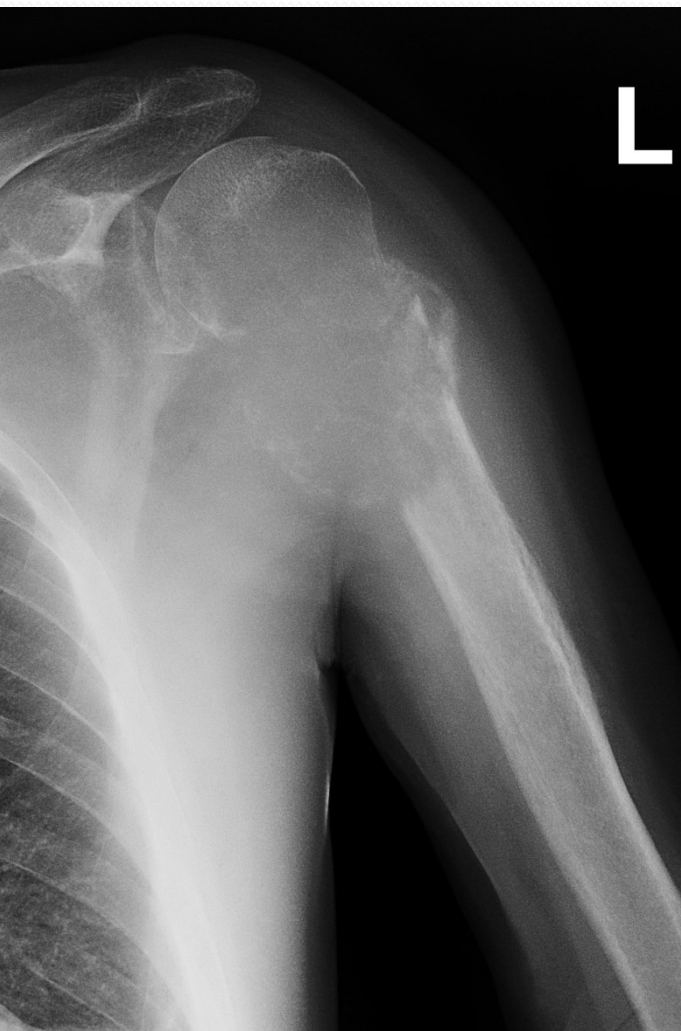


Dislocation of TU THA

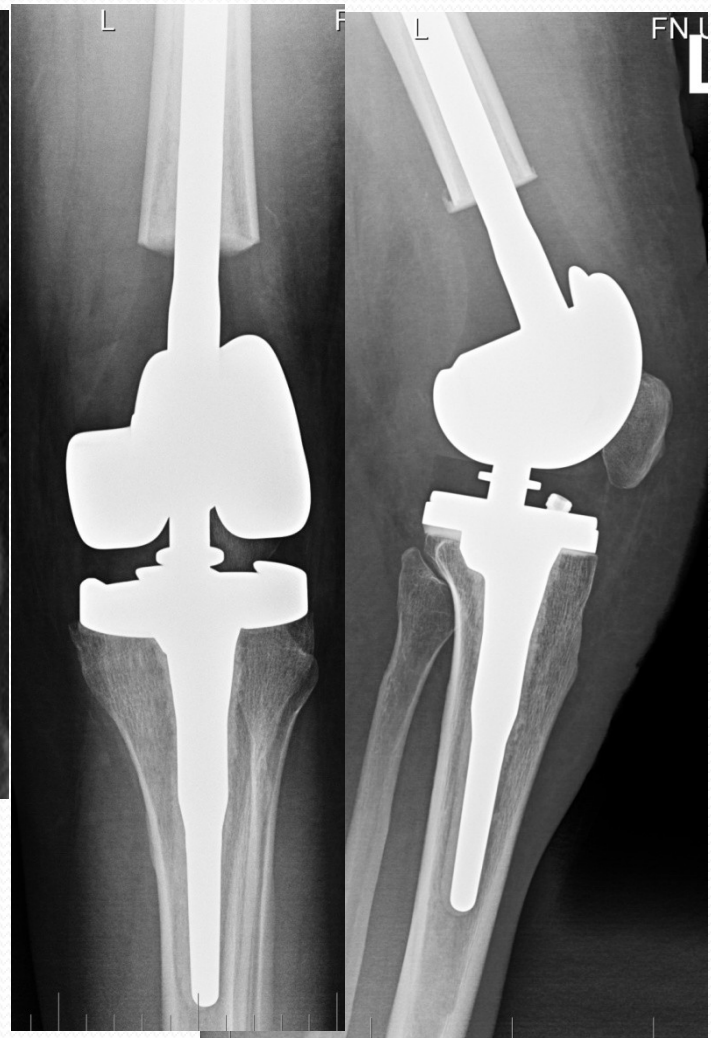
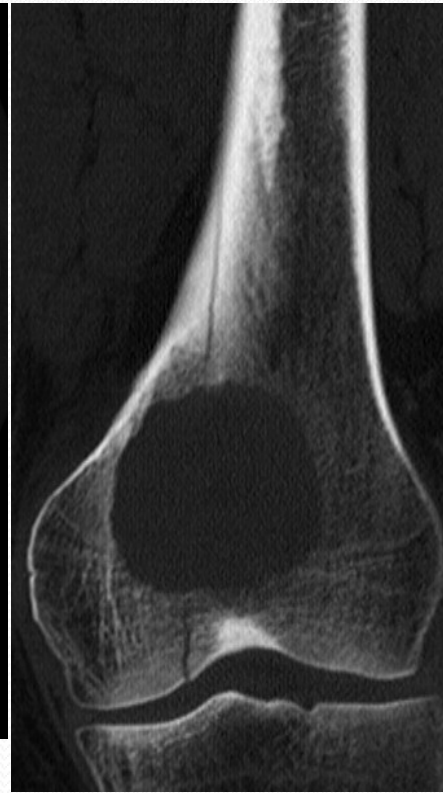
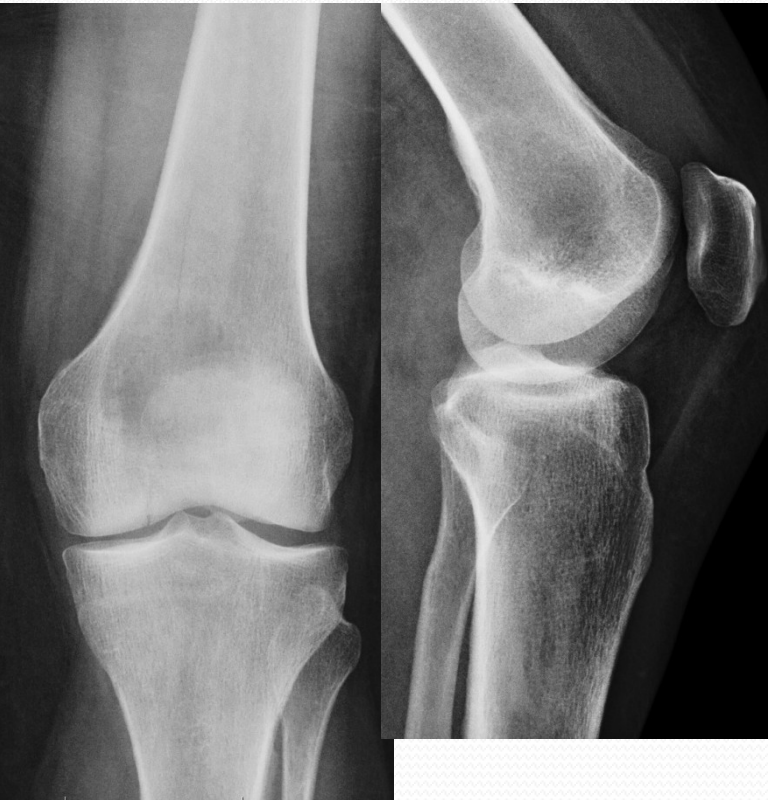Head prosthesis

Reverse total shoulder replacement



TU-TKA

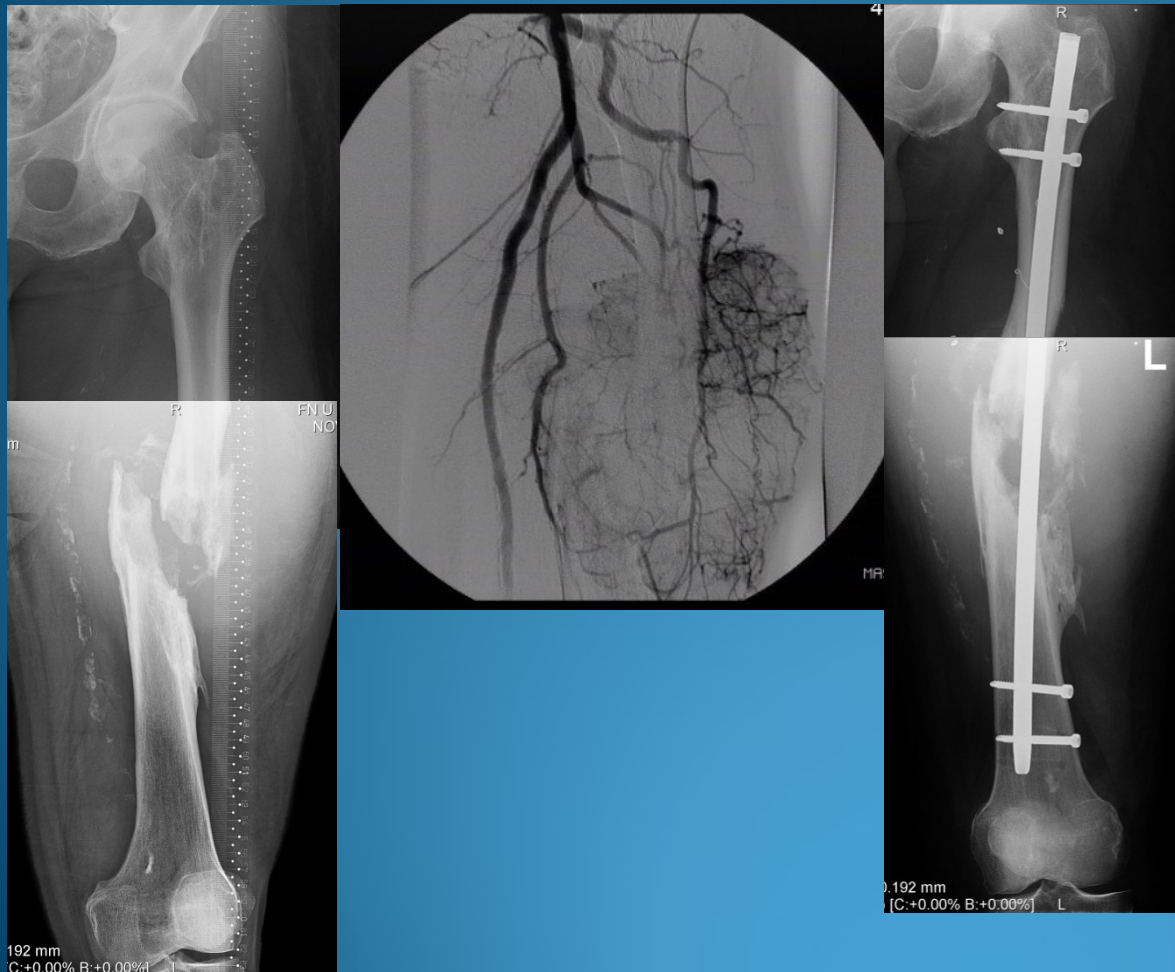


Metastasis in diaphyseal region

- Femur and humerus
- Types
 - i.m. nail
 - Resection + cement a osteosynthesis
 - Resection + intercalary spacer
 - Resection + bone graft and osteosynthesis

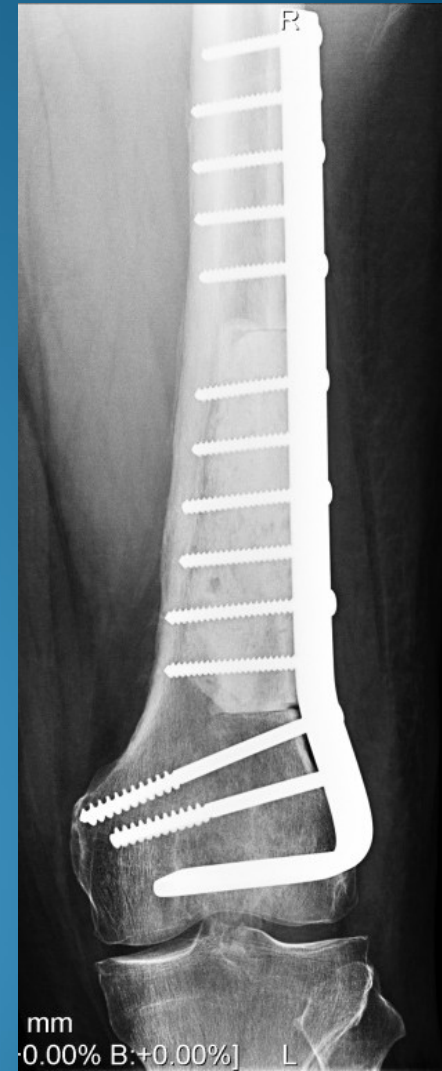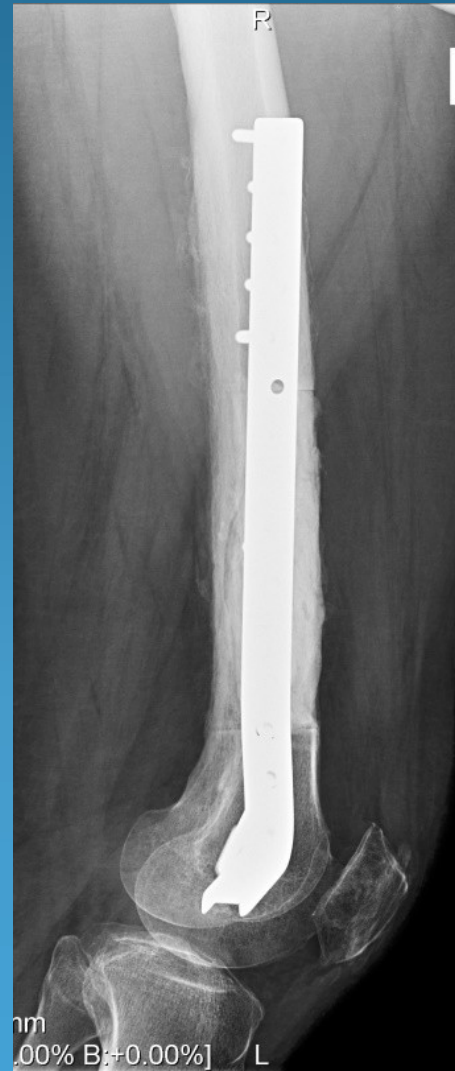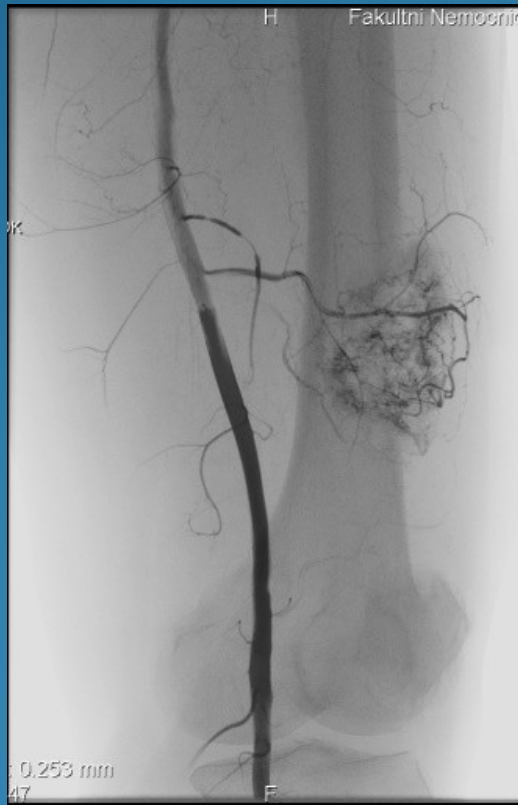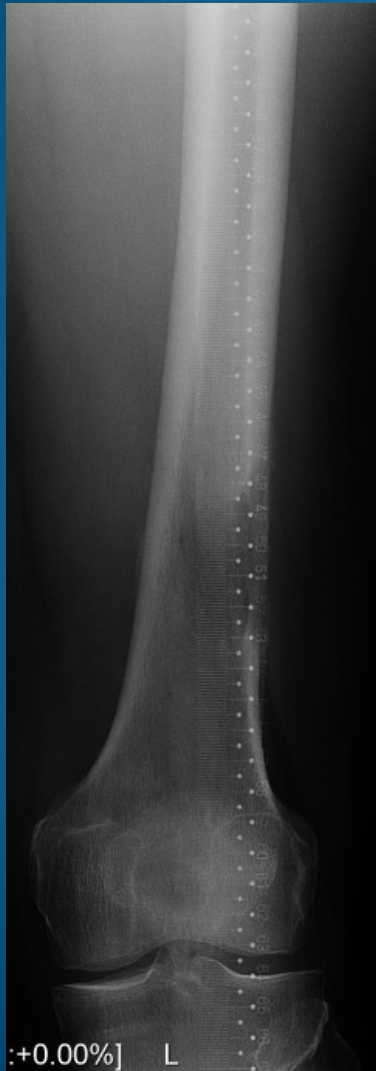
Radiotherapy in a case of nonradical surgery

i.m. nail

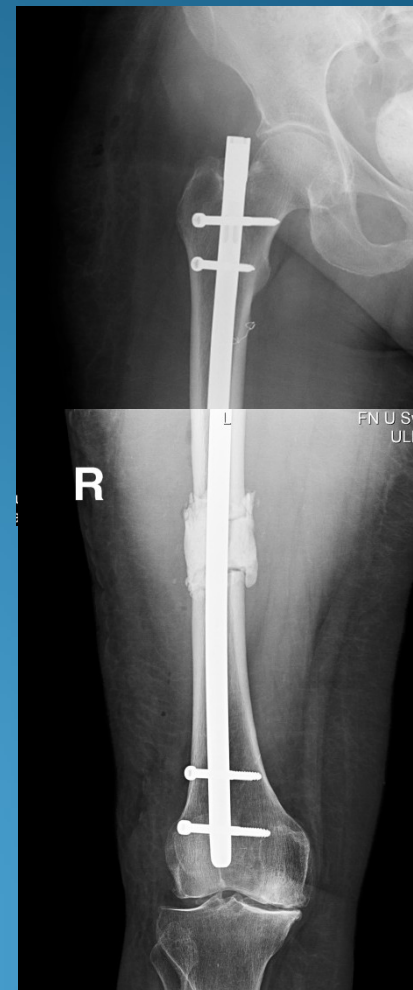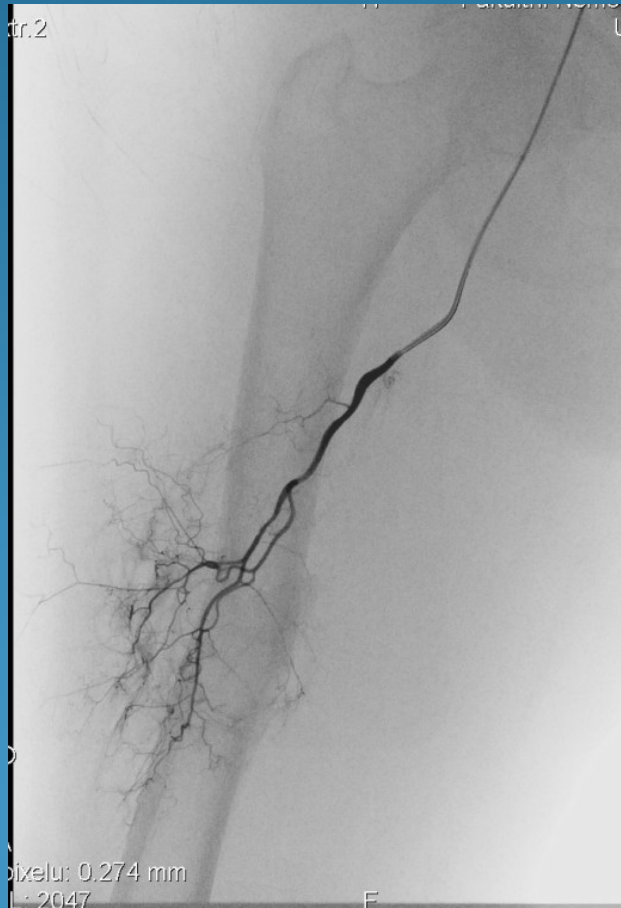

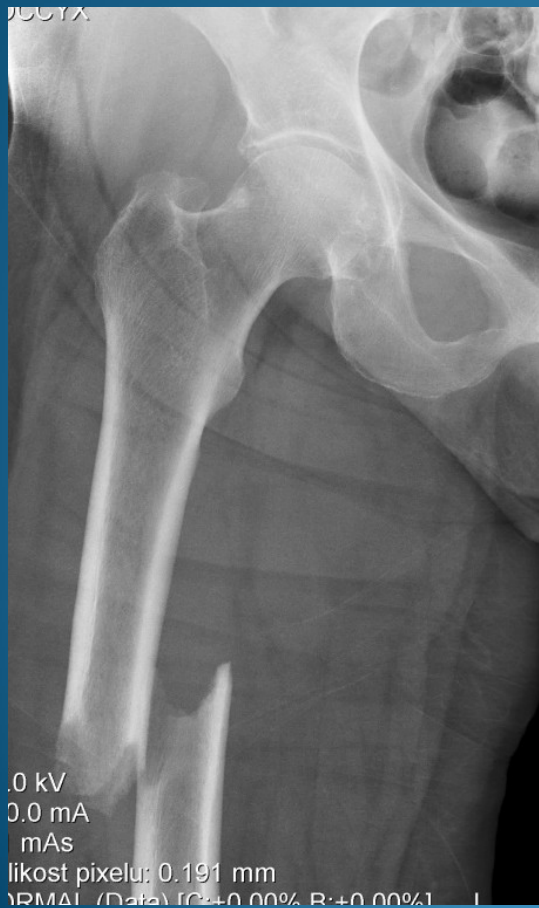
- Tumor in situ
- paliative surgery
- wrong prognosis
- Adjuvant radiotherapy

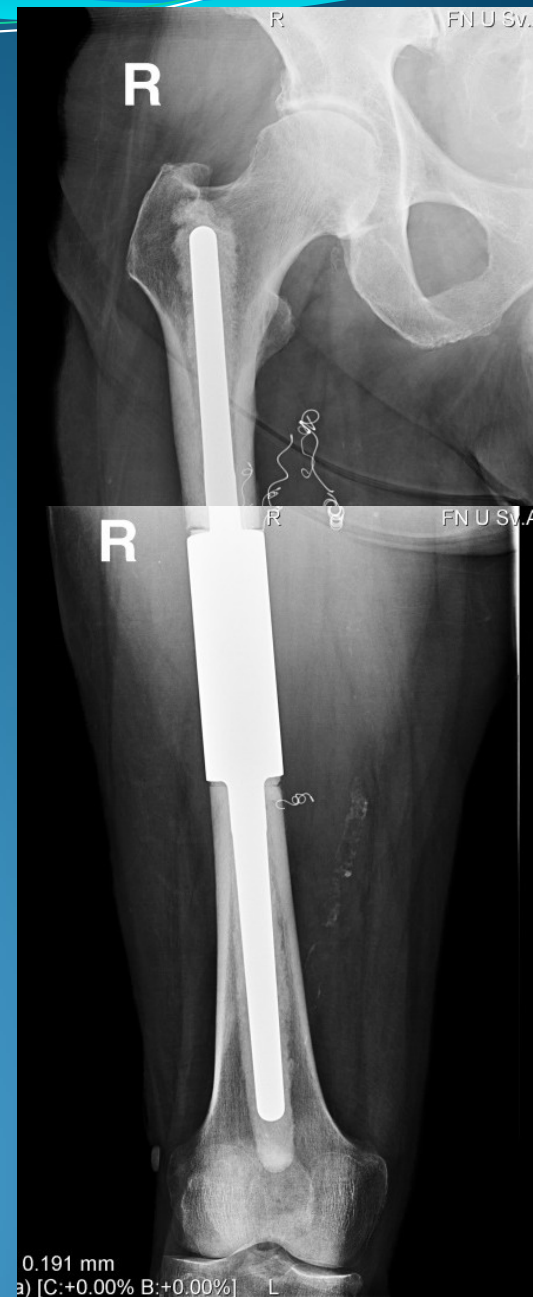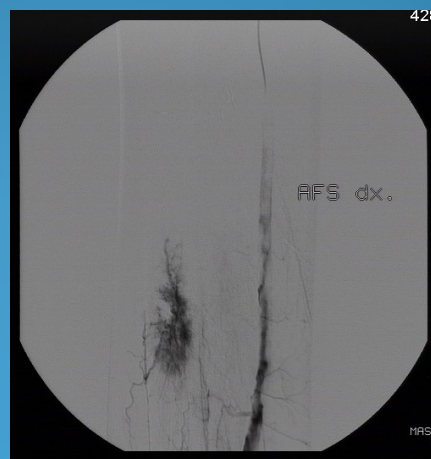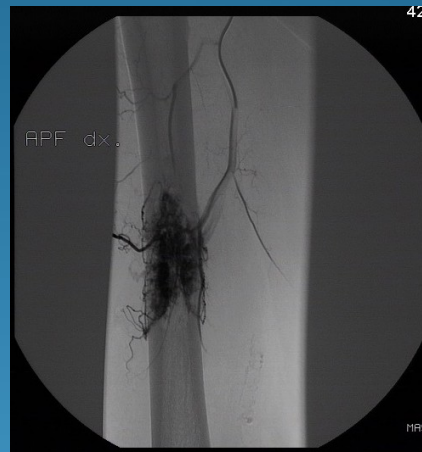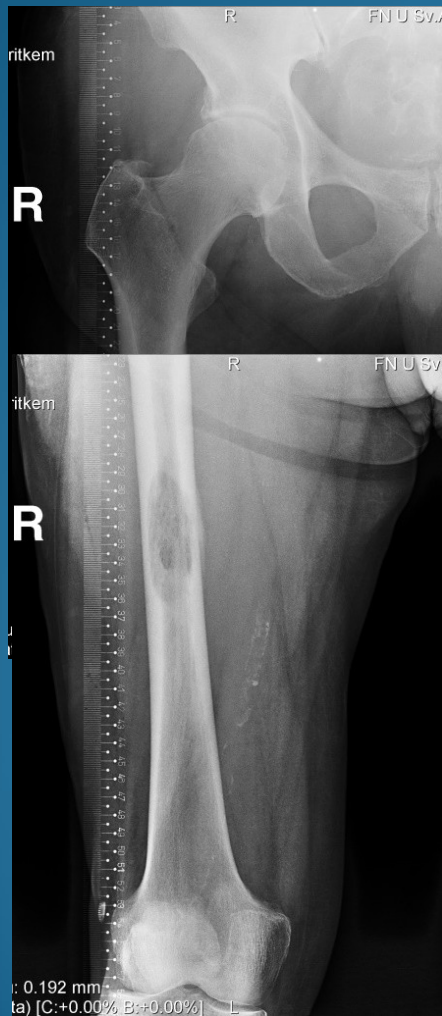
Curretage + osteosynthesis + cement



Resection + i.m. nail and cement

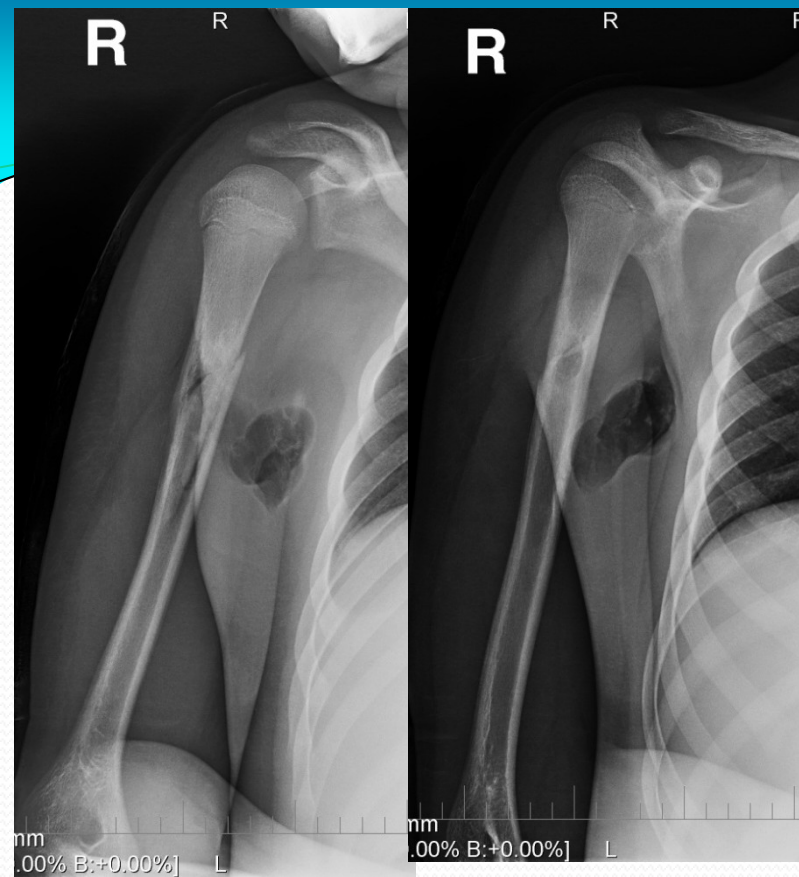


Diaphyseal spacer

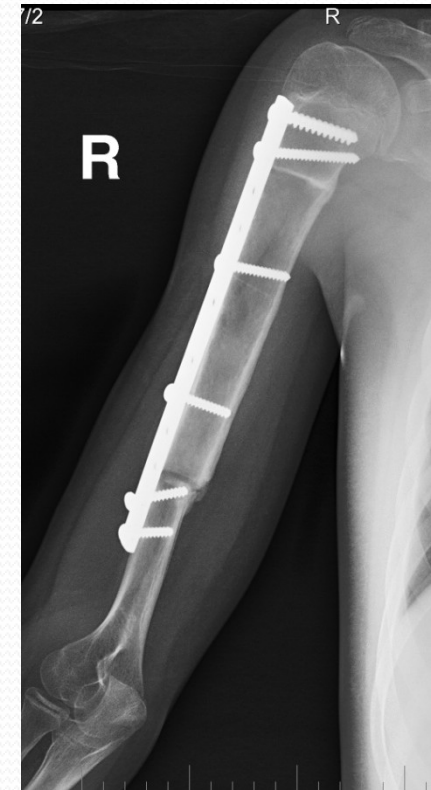
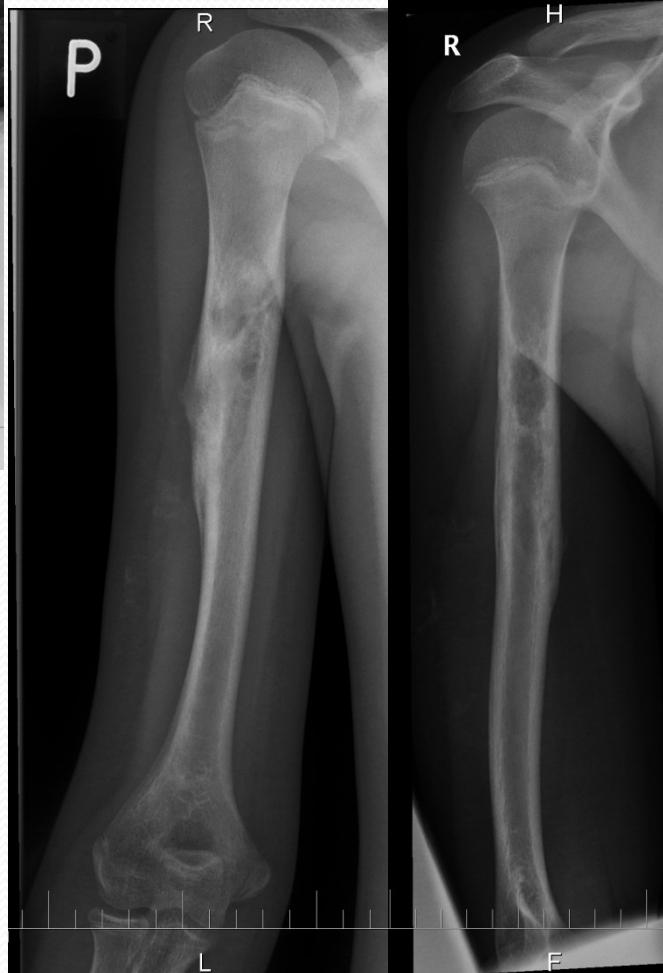
Primary malignant bone tumors

- Osteosarcoma, Ewing sa, chondrosarcoma
- Pathological fracture
 - Worse prognosis
 - High risk of dissemination
 - Less chance for local control
 - Amputation ?



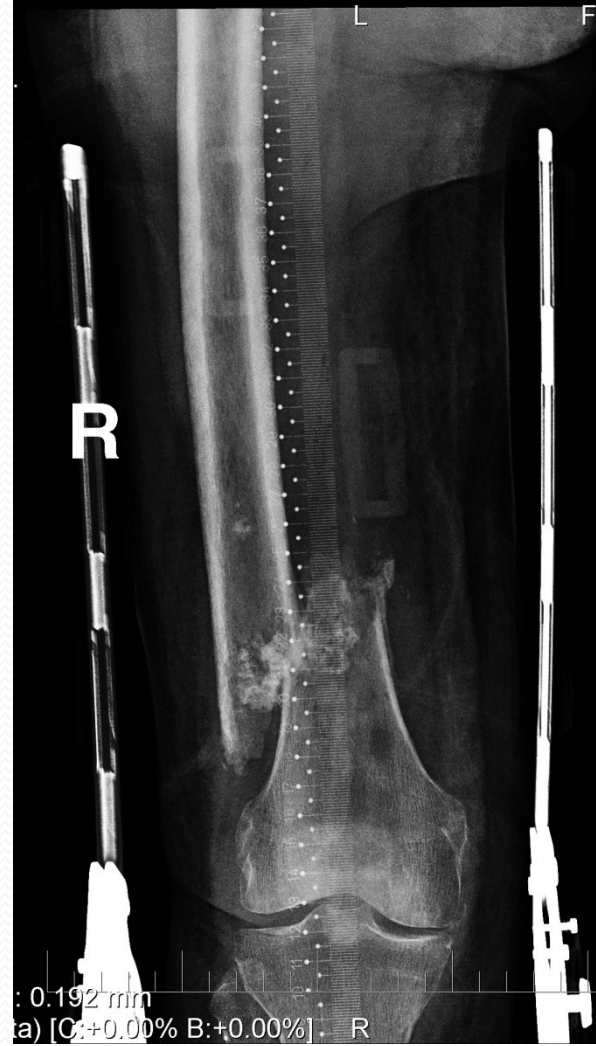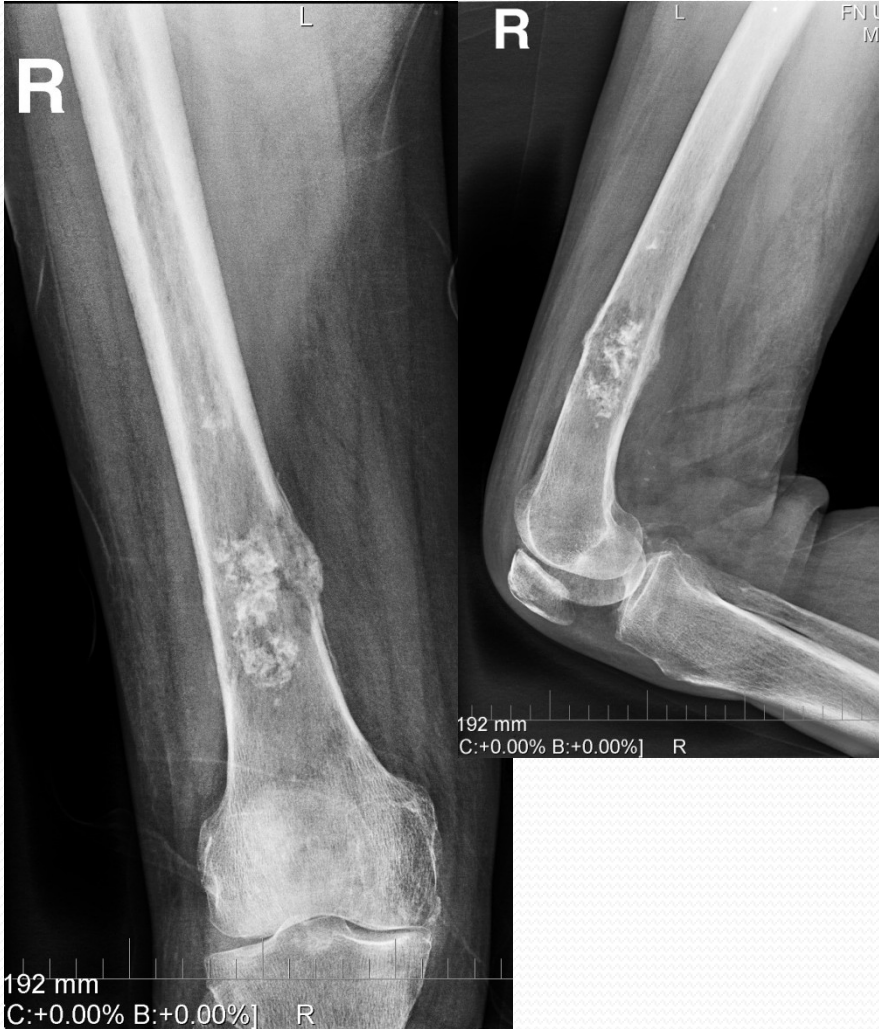Orthosis
chemotherapy



Resection
bone graft
plate

13 let boy
By throwing of a ball
**High grade
osteosarcoma**

73 let, Dediferentiated chondrosa G3



Pathol. fracture
Amputation