

1. SUPERIOR OR SUPERIUS?**MAIOR OR MAIUS?****ANTERIOR OR ANTERIUS?**

Vena cava

superior

Cornu

maius

Arteria

anterior

Membrum

superius

Ductus

maior

Ductus

anterior

Extremitas

superior

Ala

maior

Segmentum

anterius

Palpebra

superior

Musculus

maior

Margo

anterior

Labium

superius

Curvatura

maior

Bronchus

anterior

Facies

superior

Flexura

maior

Nucleus

anterior

Meatus

superior

Fossa

maior

Cornu

anterius

Arteria

superior

Foramen

maius

Nodus

anterior

Plexus

superior

Tuberculum

maius

Tuberculum

anterius

Segmentum

superius

Circulatio

maior

Radix

anterior

Regio

superior

Pelvis

maior

Crus

anterius

2. PUT COMPARATIVES AND SUPERLATIVES INTO THE PLURAL

Musculi longi

longiores

longissimi

Cavitates parvae

minores

minimae

Radices latae

latiores

latissimae

Defectus magni

majores

maximi

Gradus parvi

minores

minimi

O-tiones acutae

acutiores

acutissimae

Foramina parva

minora

minima

Infarctus recentes

recentiores

recentissimi

Ossa brevia

breviora

brevissima

Partes molles

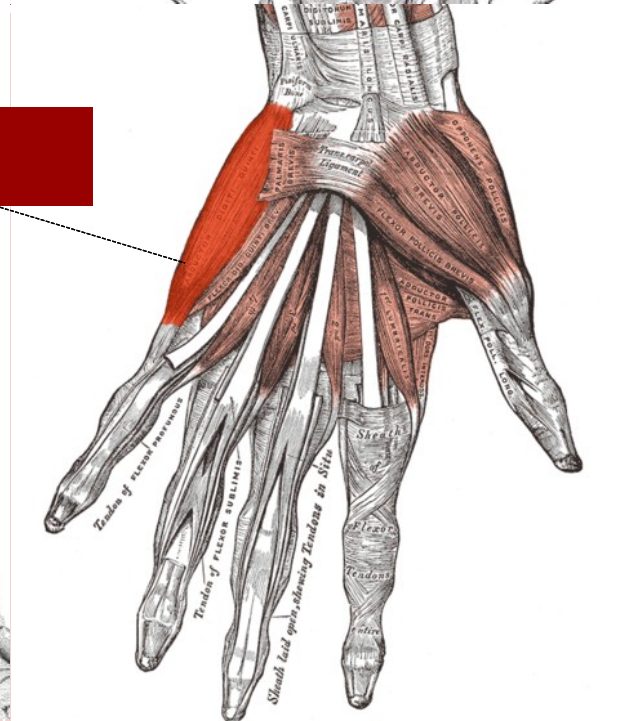
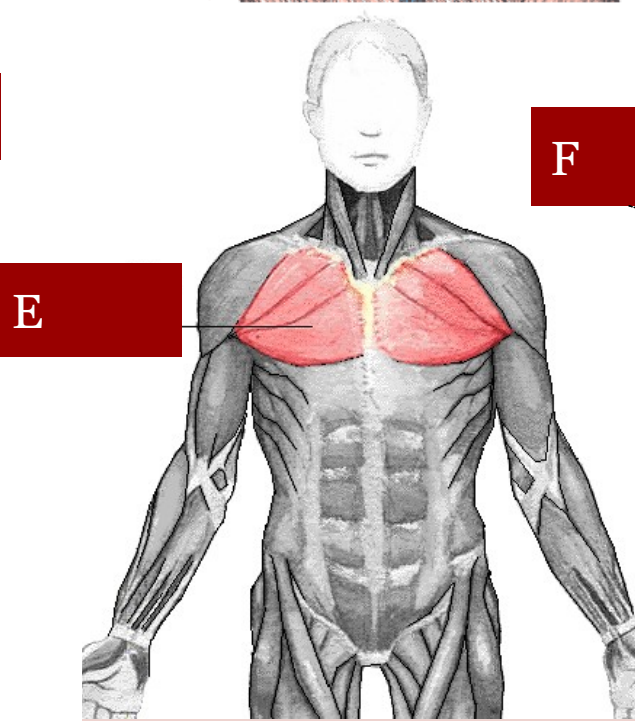
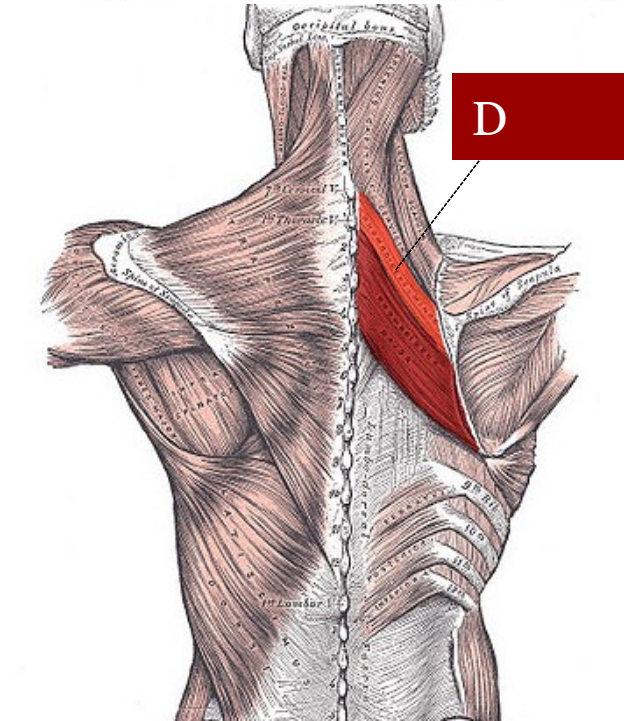
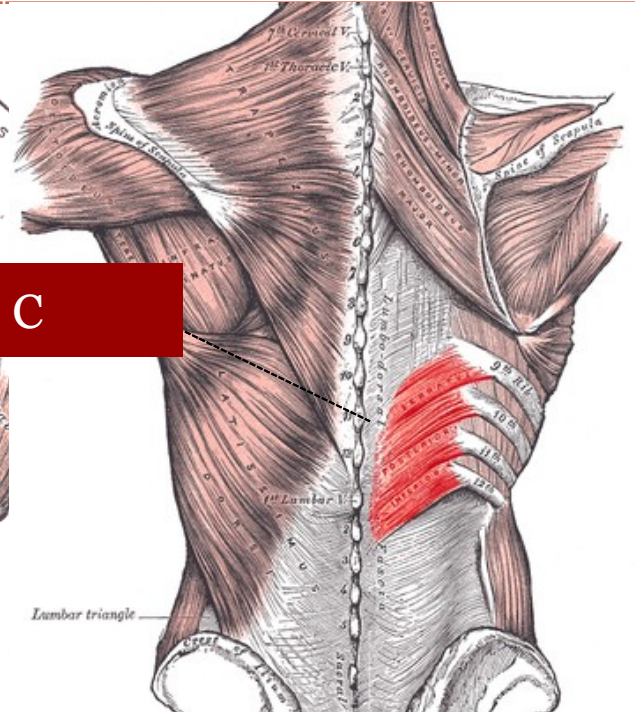
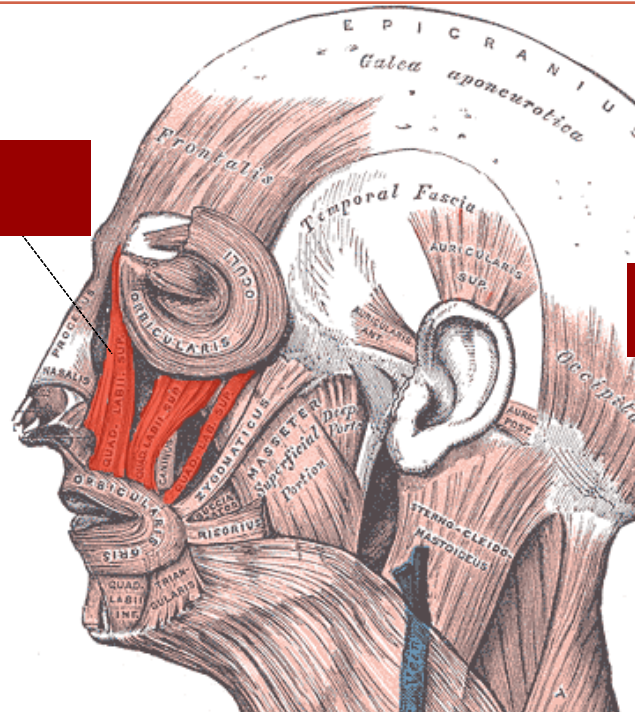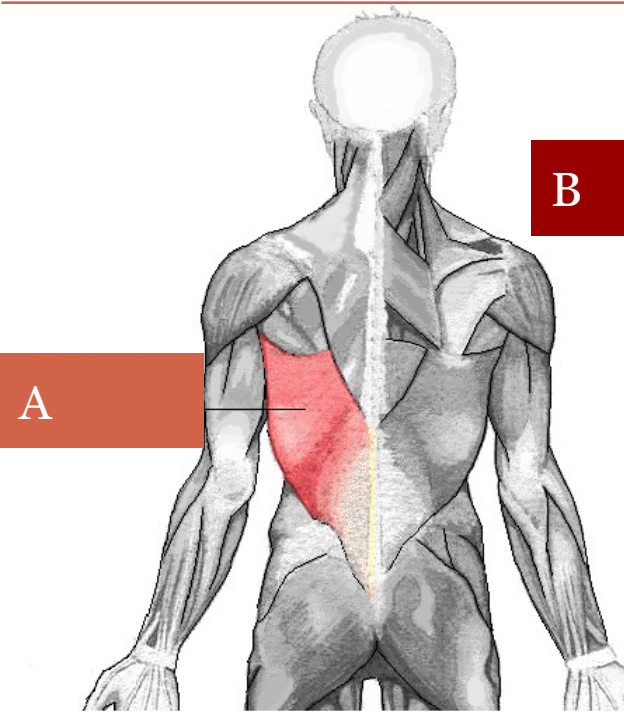
molliores

mollissimae

Therapiae longae

longiores

longissimae



EXPRESSING POSITION



- A) PREPOSITIONS**
- B) PREFIXES**
- C) COMPARATIVE FORMS**
- D) ADJECTIVES**

A) PREPOSITIONS



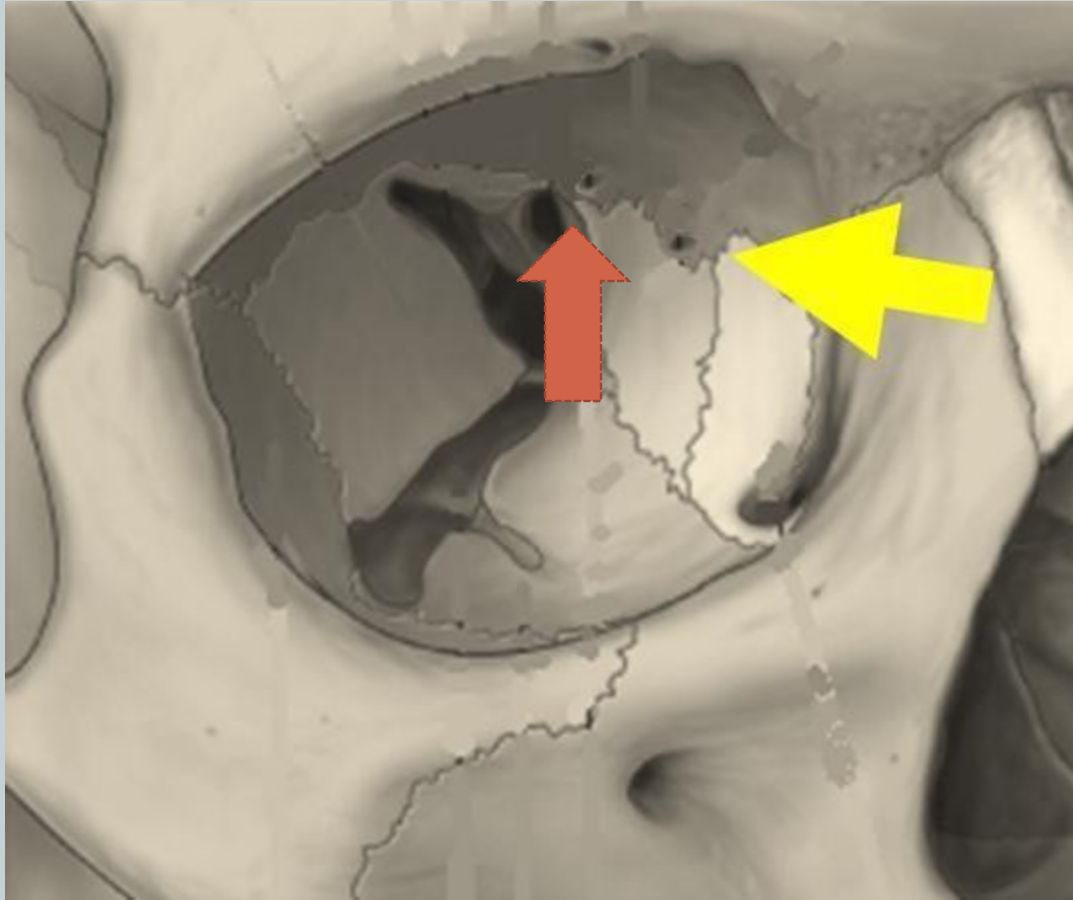
- **WITH ABLATIVE**

- corpus alienum in aure interna
- vulnus morsum sub genu l.dx.

- **WITH ACCUSATIVE**

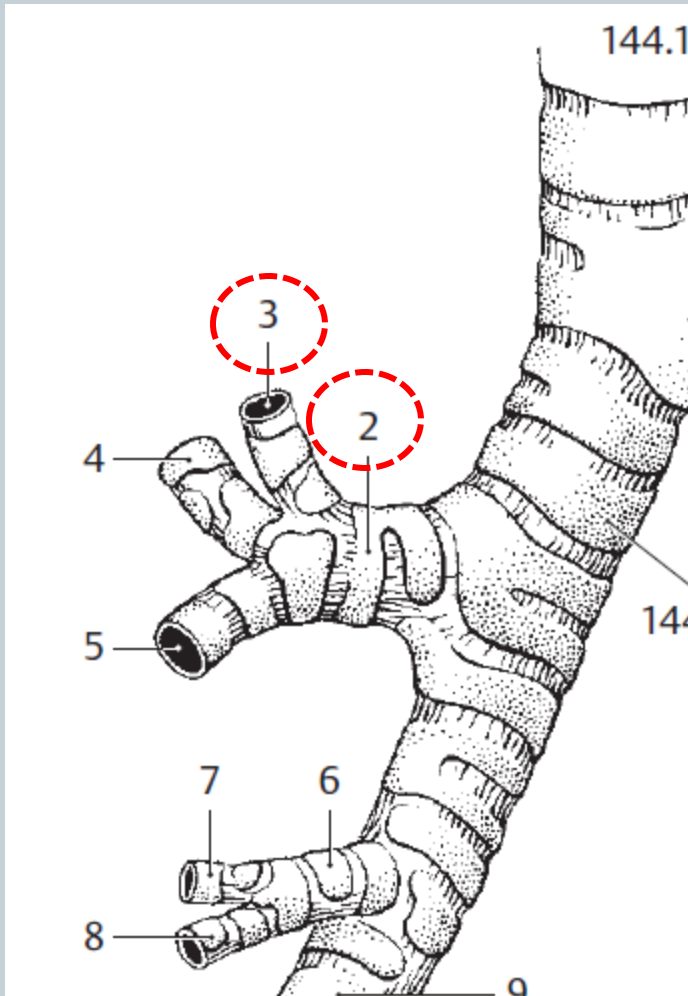
- funiculus umbilicalis circum collum fetus
- tumor ad hepar increscens

B) COMPARATIVE FORMS

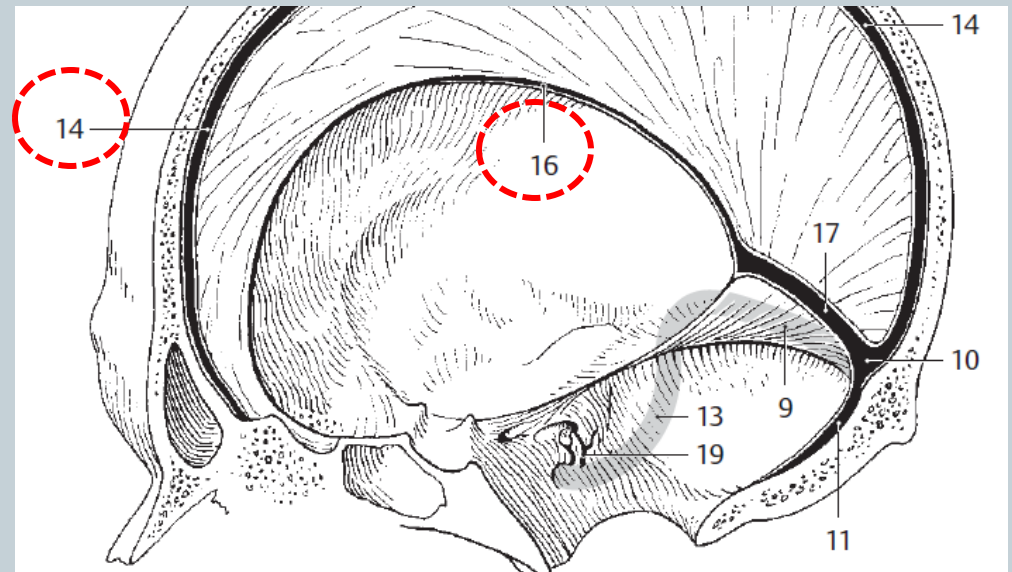


foramen ethmoidale
anterior / posterior

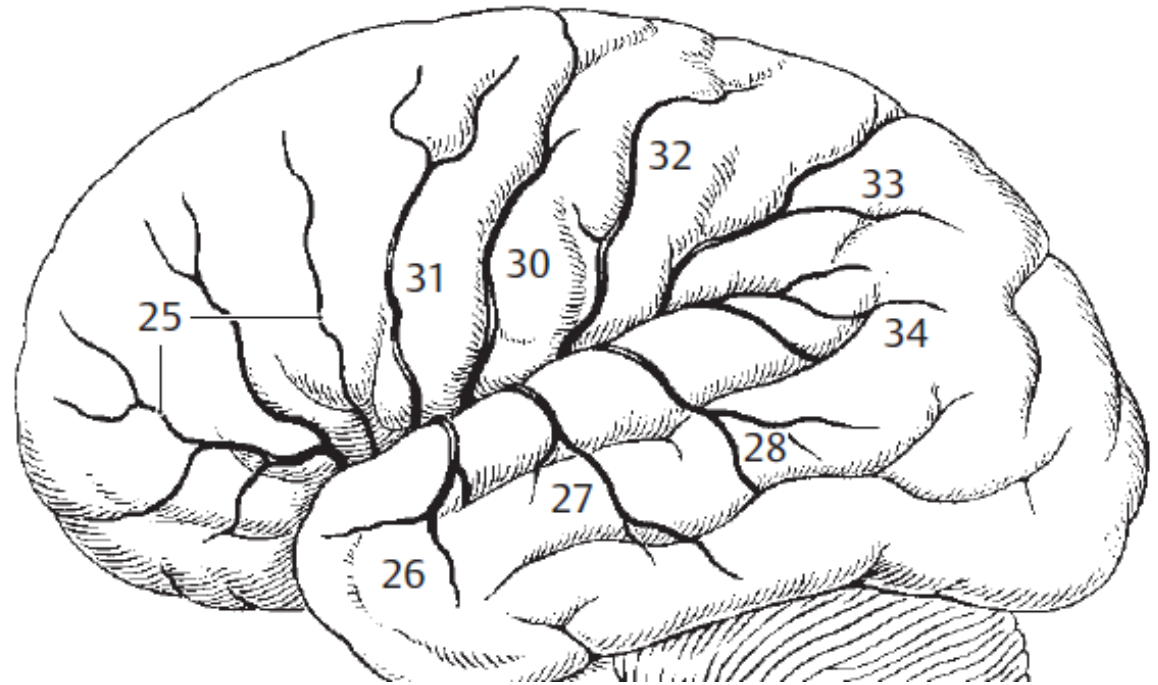
C) ADJECTIVES



bronchus segmentalis **apicalis**
bronchus **lobaris** superior dexter



sinus **sagittalis** superior / inferior



25 a. **frontobasalis lateralis**

26 a. temporalis **anterior**

27 a. temporalis **media**

28 a. temporalis **posterior**

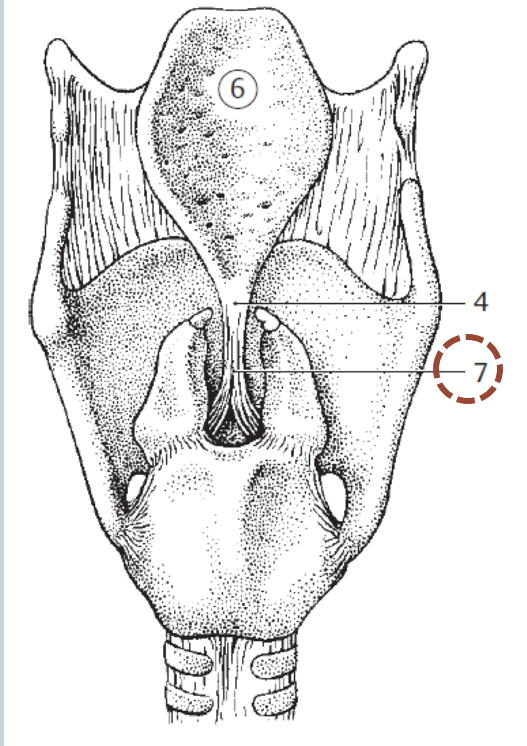
30 a. sulci centralis

31 a. sulci **precentralis**

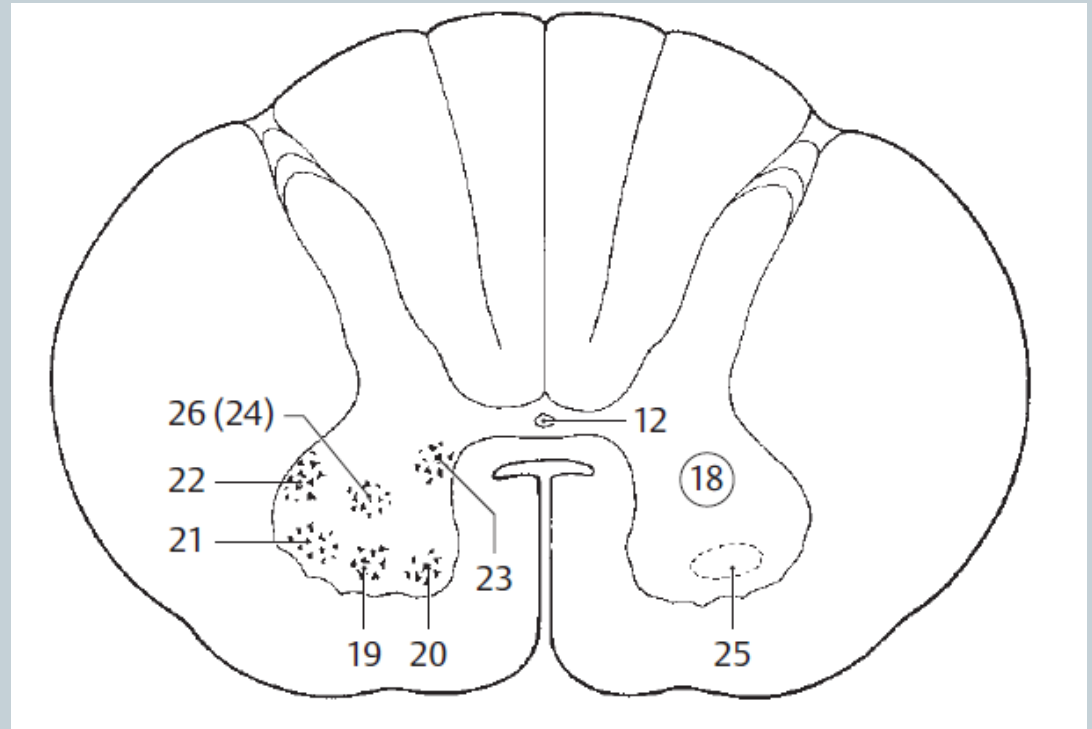
32 a. sulci **postcentralis**

33 aa. parietales **anterior** et **posterior**

D) COMBINED TERMS

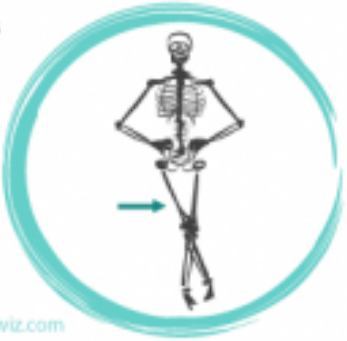
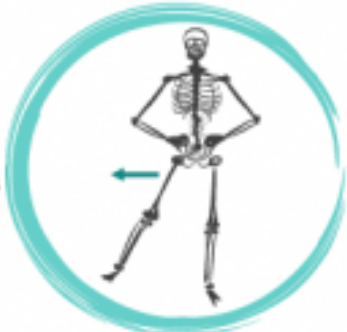
lig. **thyroepiglotticum**



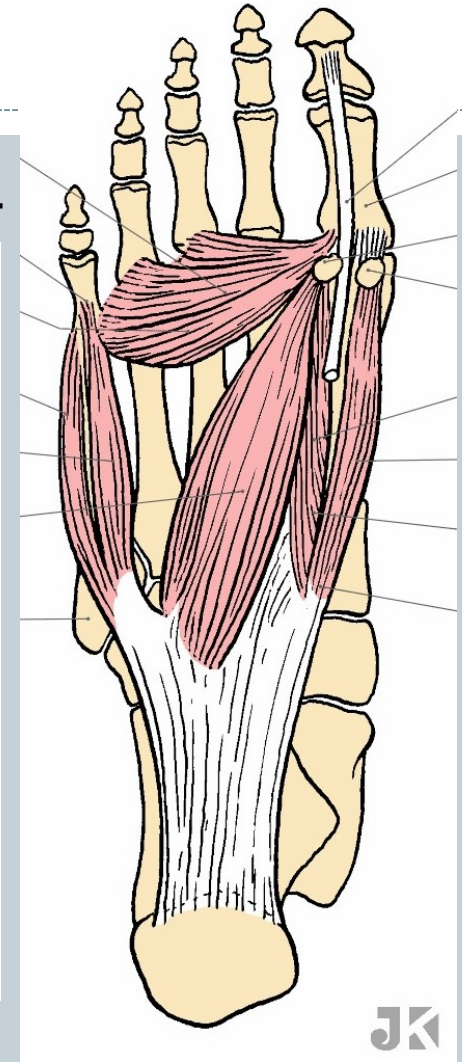
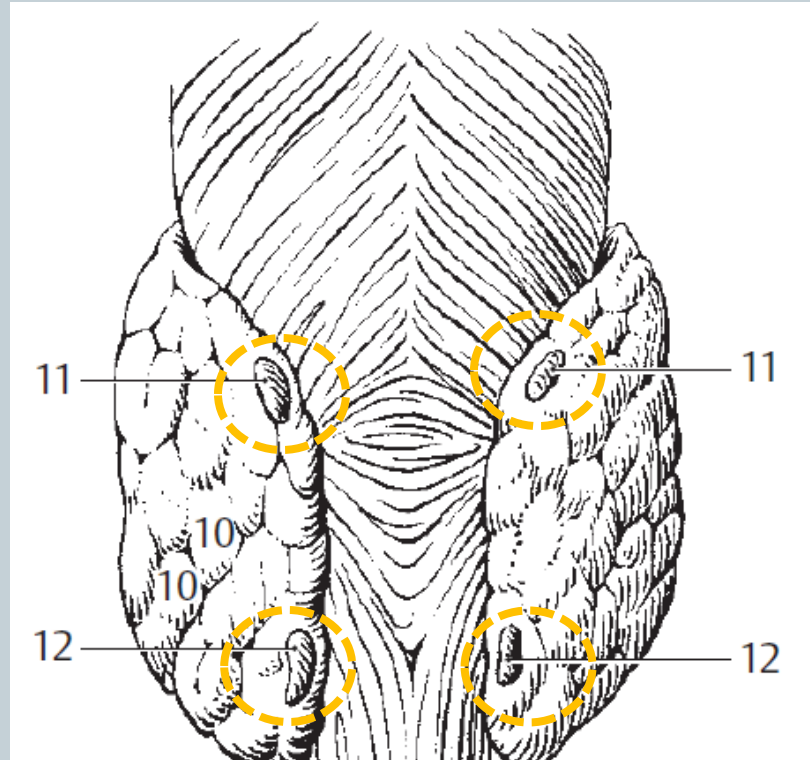
- | | |
|---------------------------------|----|
| nucleus anterolateralis | 19 |
| n. anteromedialis | 20 |
| n. posterolateralis | 21 |
| n. retroposterolateralis | 22 |
| n. posteromedialis | 23 |

E) PREFIXES



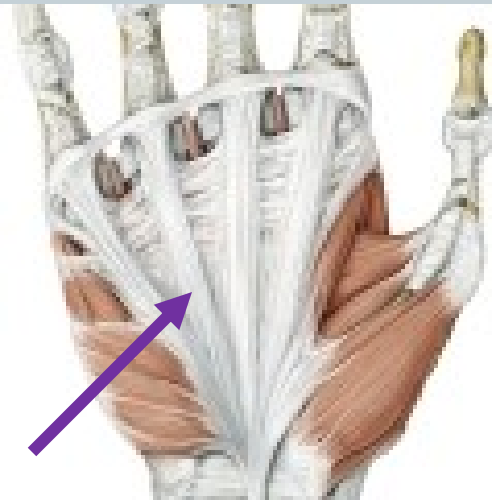
ab-

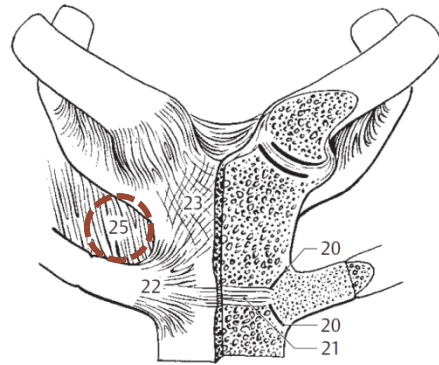
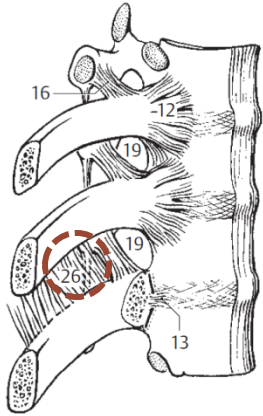
apo-



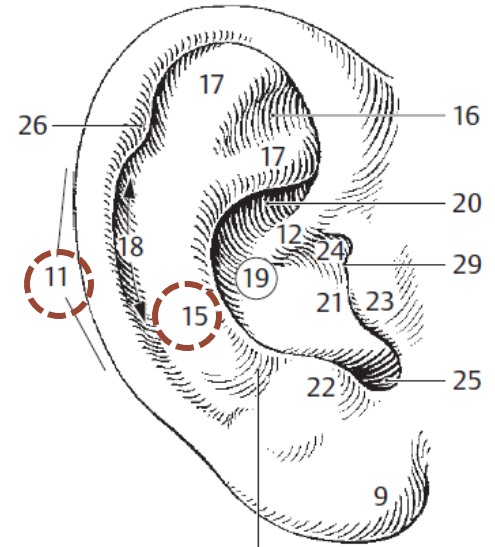
ad-

par(a)-

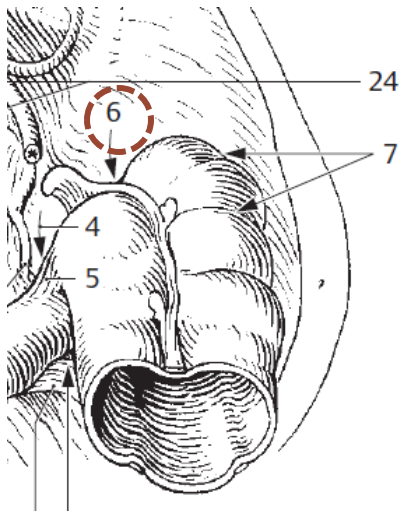




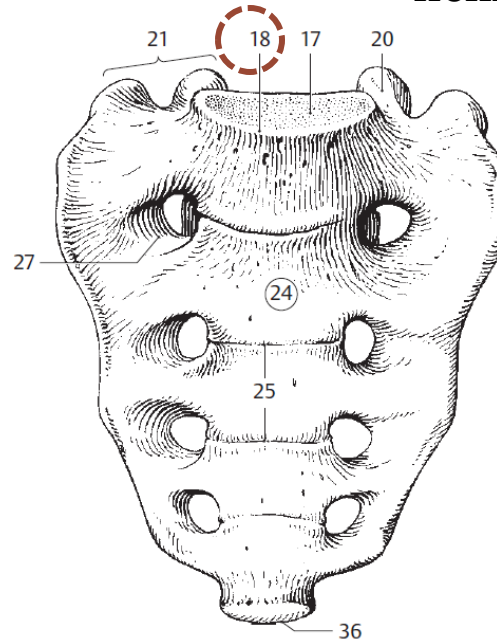
membrana **inter**costalis *interna* / *externa*



helix / **ant(i)**helix

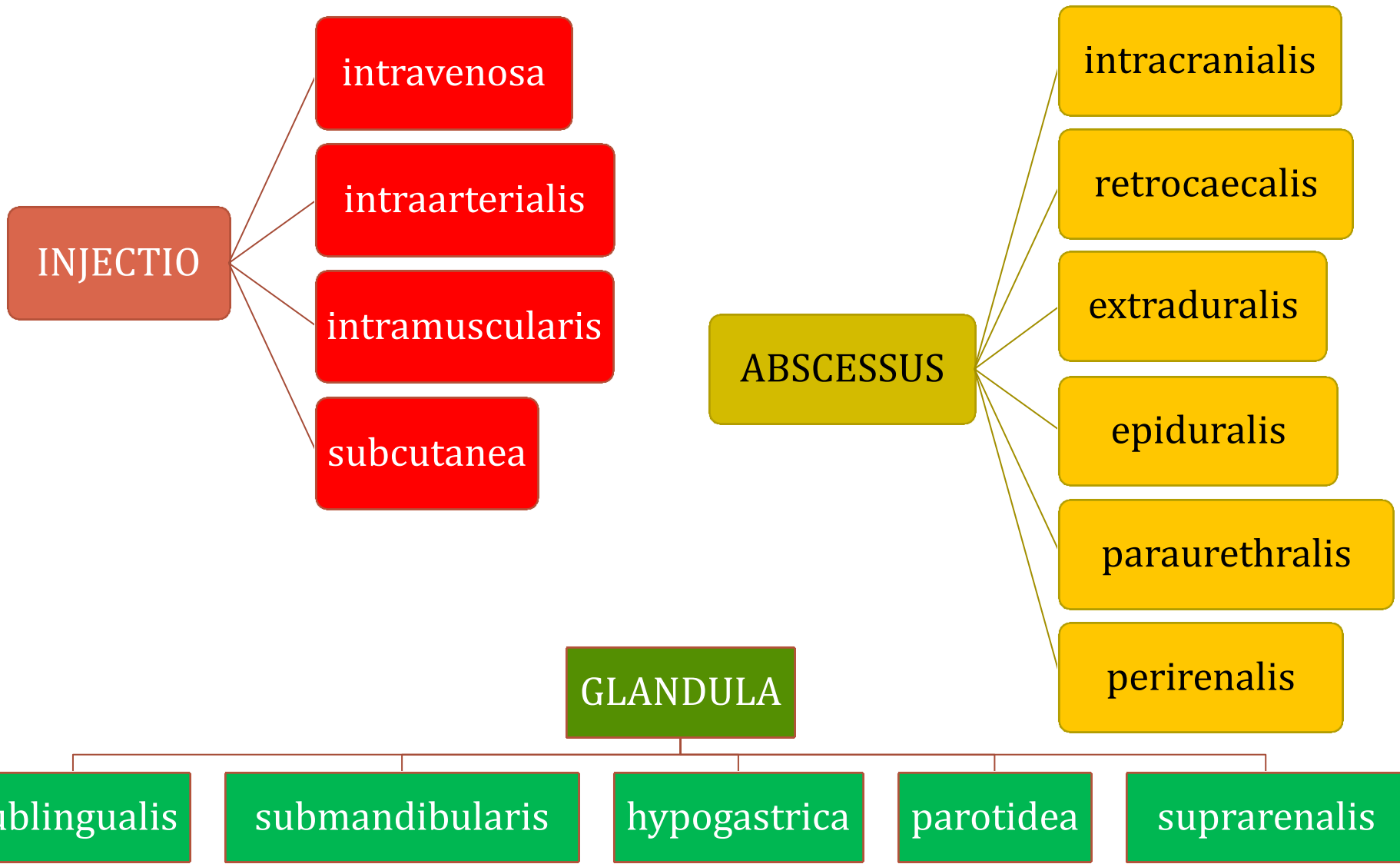


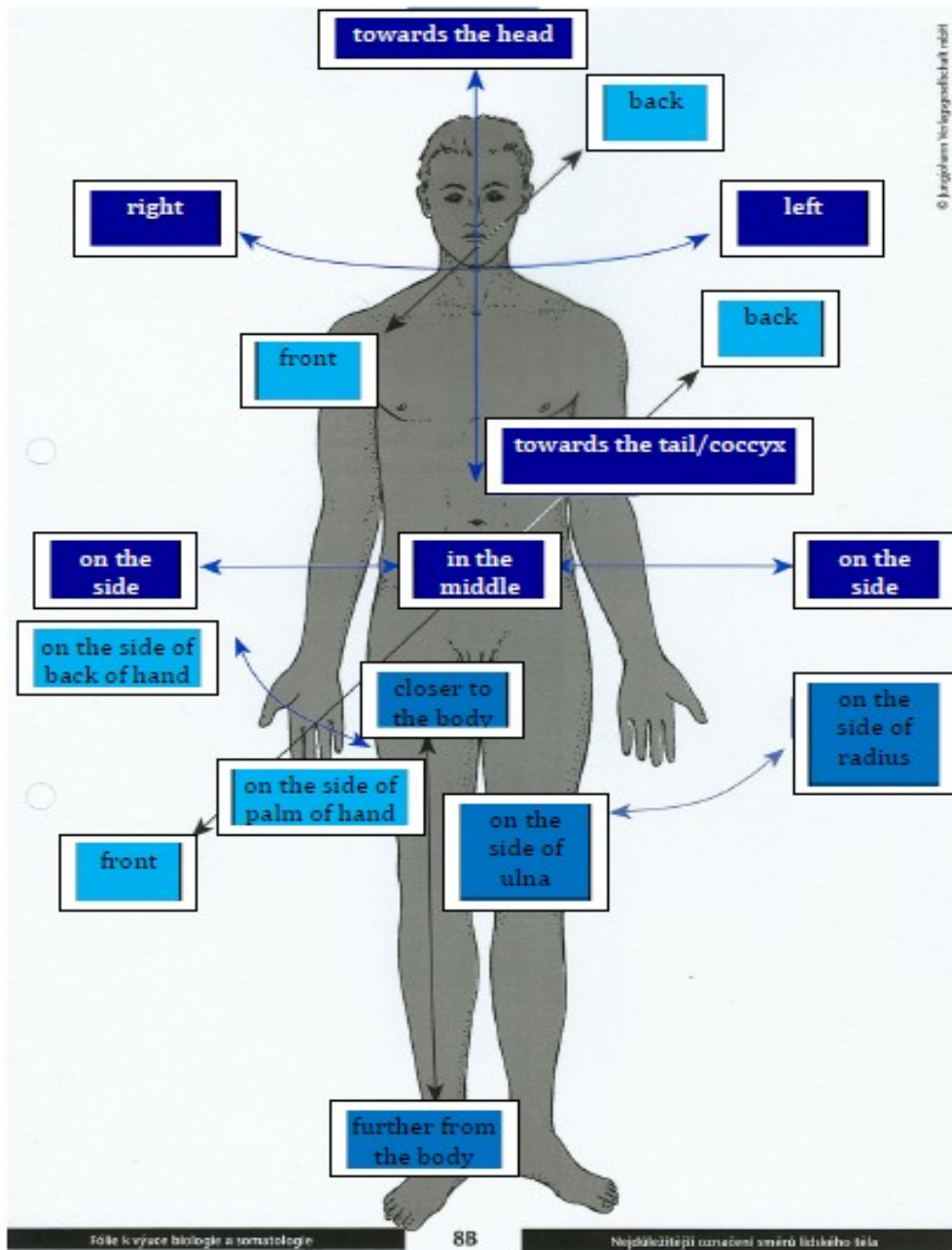
recessus
retrocaecalis



promontorium
ossis sacri

GUESS THE MEANING OF THE PREFIX AND ANALYZE THE TERMS





True or False?

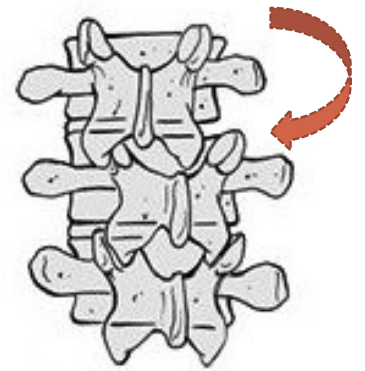
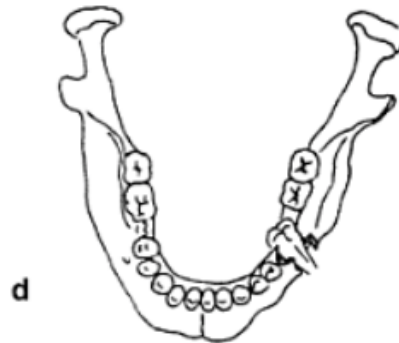
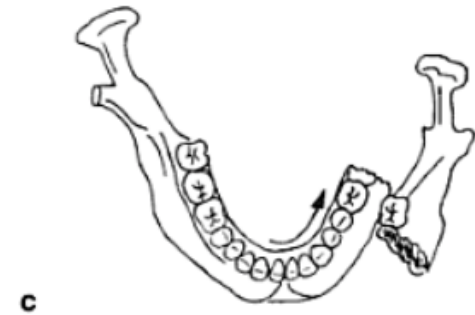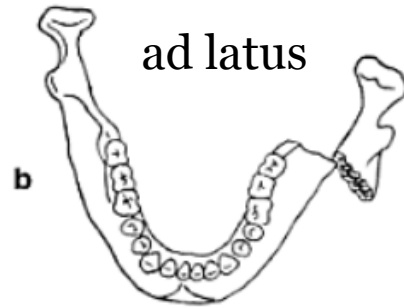
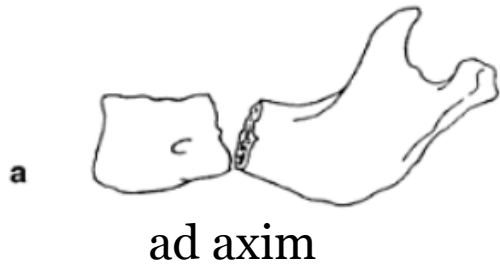
	YES	NO
1. In anatomical position the palmar surface is in <i>posterior</i> position.		✓
2. The sternum is <i>anterior</i> to the heart.	✓	
3. The clavicles are <i>mediales</i> to the sternum.		✓
4. The elbow is <i>proximalis</i> to the wrist.	✓	
5. The aorta is <i>ventralis</i> to the spinal column.	✓	
6. The skin is <i>profundus</i> to the muscles.		✓
7. The blood drawn from a fingertip is <i>peripheralis</i> .	✓	

Fractures - addition



DISLOCATED FRACTURES
CLASSIFICATION
FRACTURE HEALING
TOOTH FRACTURES

Dislocated fractures



ad peripheriam

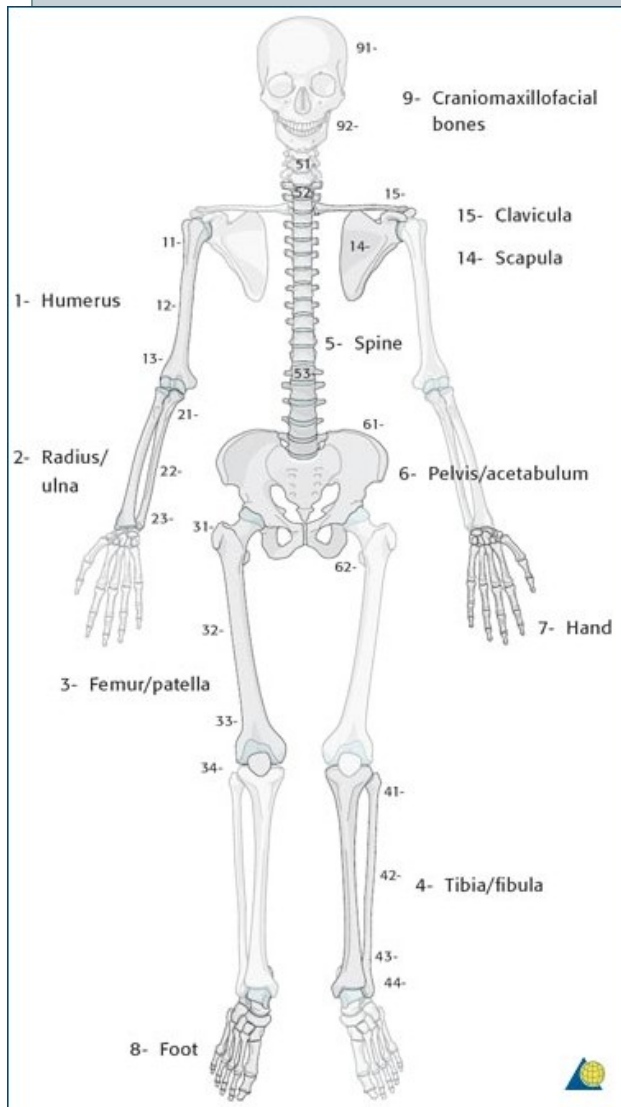
ad longitudinem


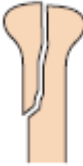
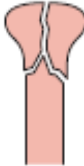




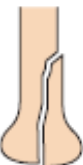
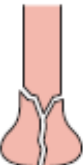
cum contractione

cum distractione

AO Classification of fractures

S 4220 Fractura colli chirurgici humeri l. dx. comminutiva AO 11-C3

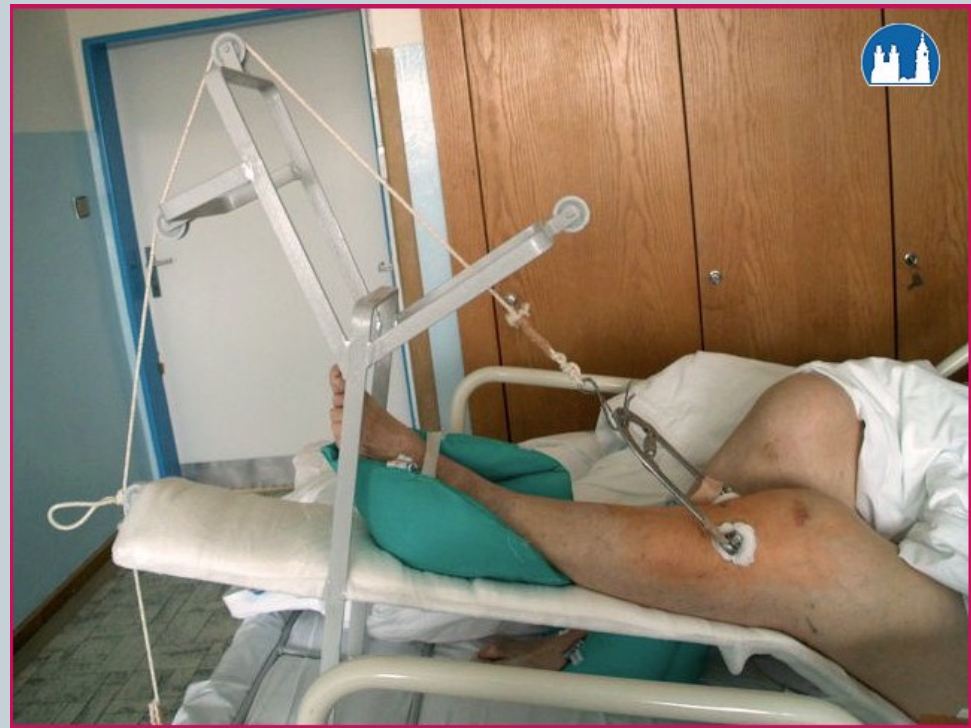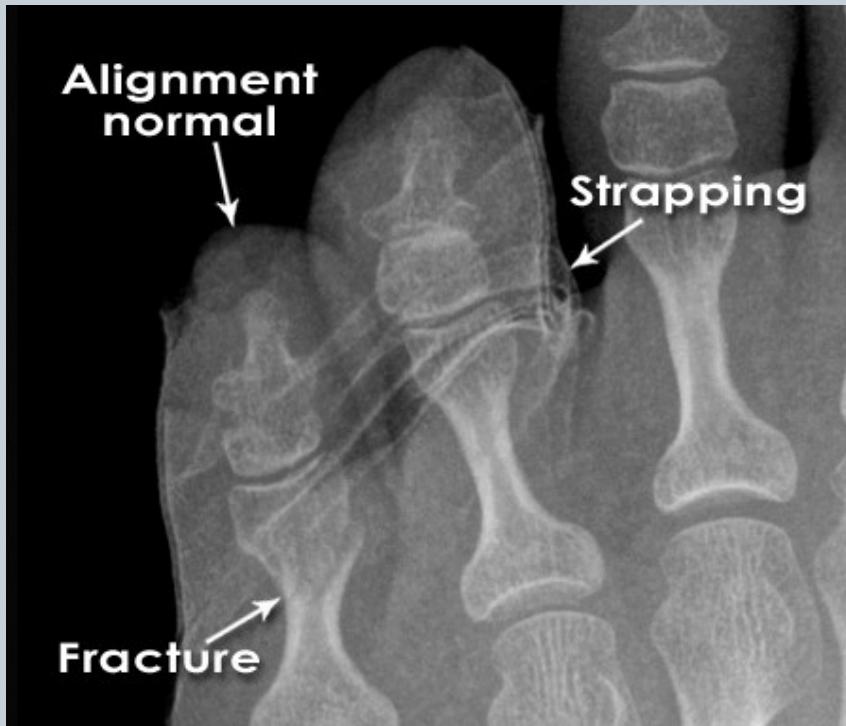


	A	B	C
1 Proximal	 <p>Extraarticular</p> <p>No involvement of displaced fractures extending into the articular surface</p>	 <p>Partial articular</p> <p>Part of the articular component is involved, leaving the other part attached to the meta-/diaphysis</p>	 <p>Complete articular</p> <p>Articular surface involved, metaphyseal fracture completely separates articular component from the diaphysis</p>
2 Diaphyseal	 <p>Simple</p> <p>One fracture line, cortical contact between fragments exceeds 90% after reduction</p>	 <p>Wedge</p> <p>Three or more fragments, main fragments have contact after reduction</p>	 <p>Complex</p> <p>Three or more fragments, main fragments have no contact after reduction</p>
3 Distal	 <p>Extraarticular</p> <p>No involvement of displaced fractures extending into the articular</p>	 <p>Partial articular</p> <p>Part of the articular component is involved, leaving the other part</p>	 <p>Complete articular</p> <p>Articular surface involved, metaphyseal fracture completely</p>

Fracture Healing:

1: REPOSITIO = REDUCTIO fragmentorum

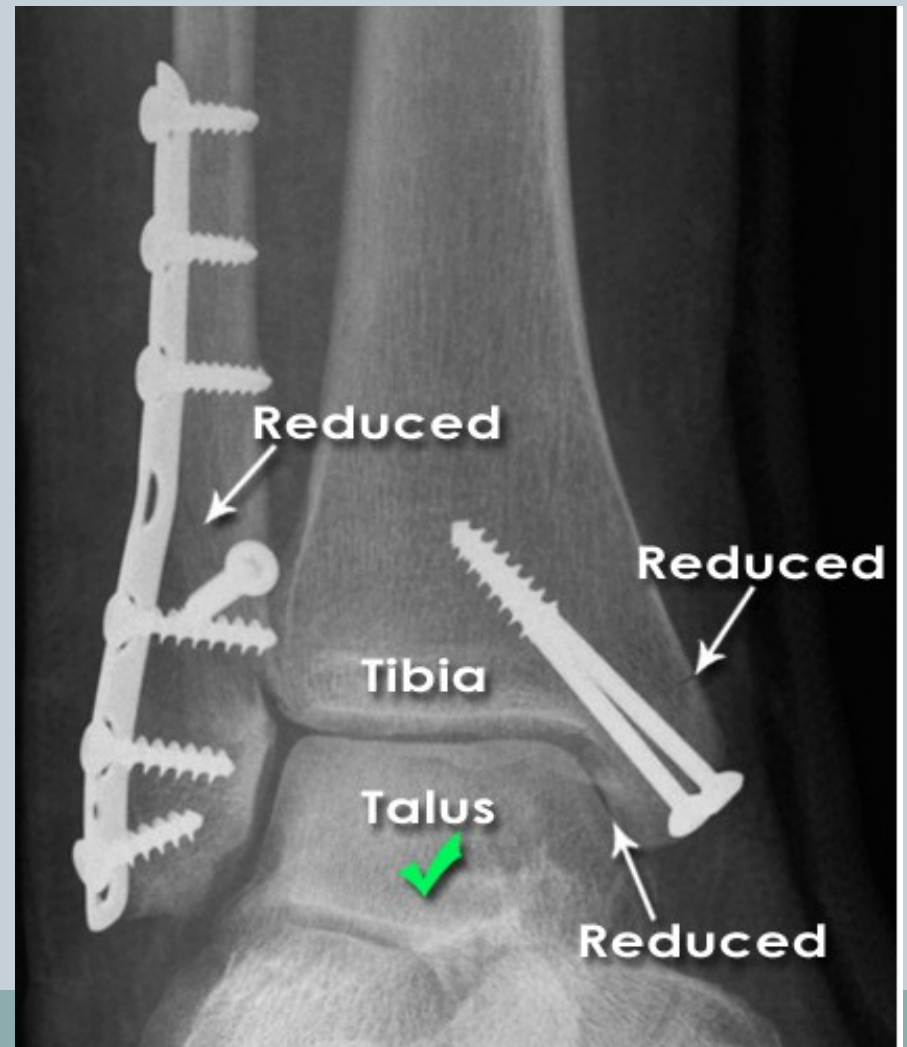

CLOSED (short /long term)



Fracture Healing:

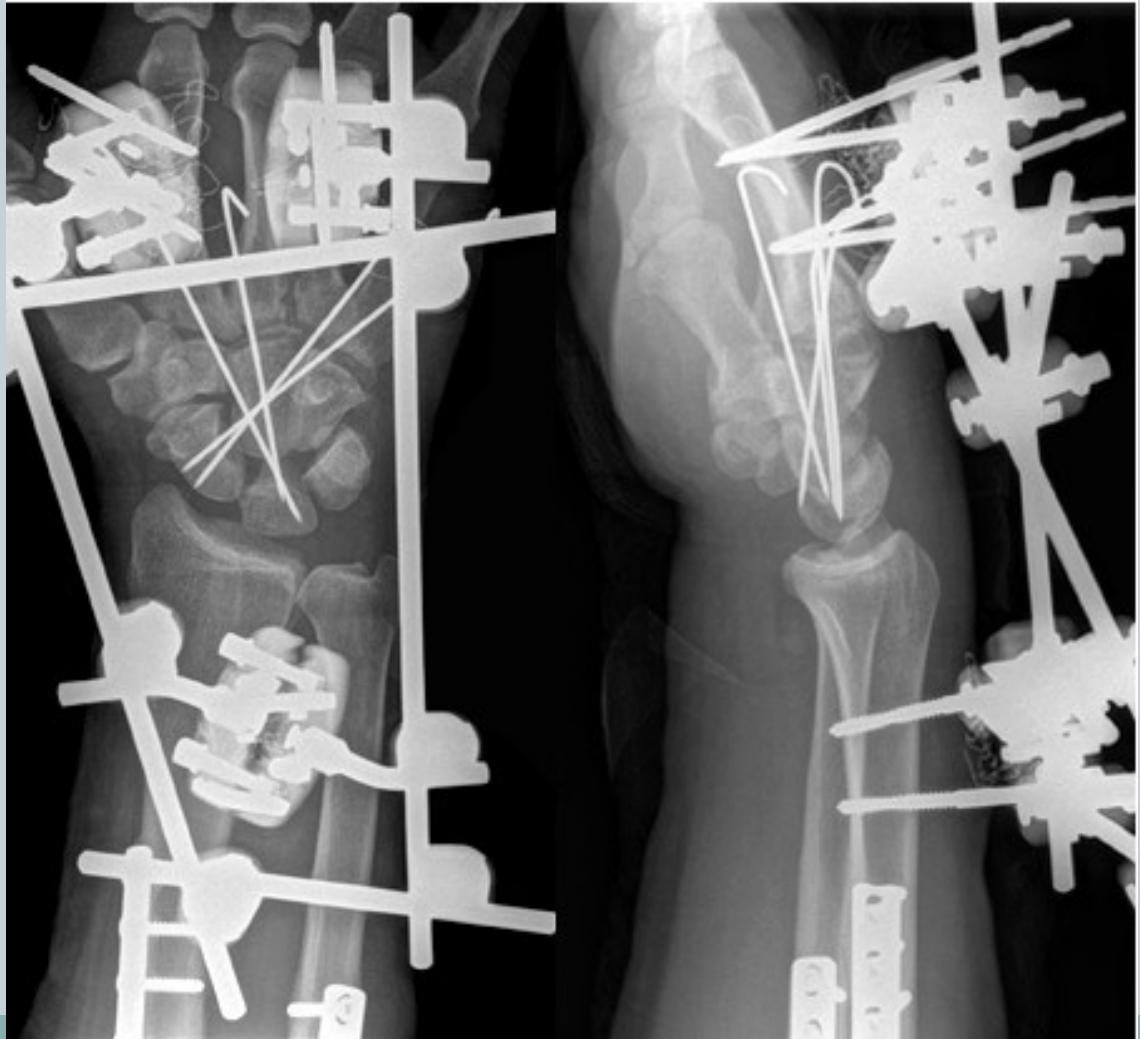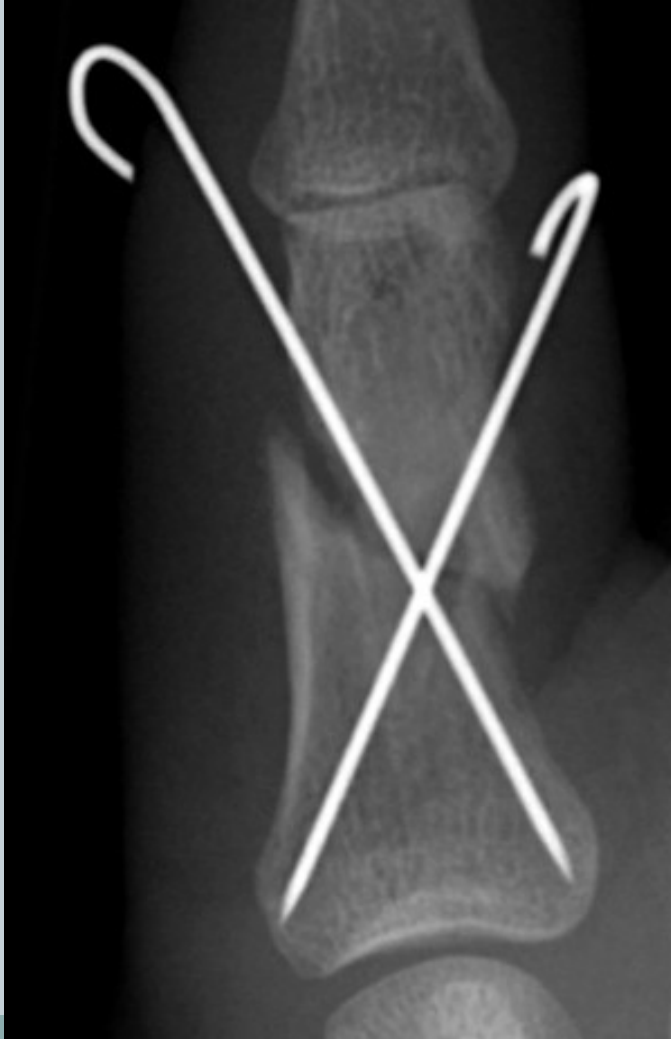2: FIXATIO = STABILISATIO fragmentorum

INTERNAL FIXATION



Fracture Healing:

2: FIXATIO = STABILISATIO fragmentorum



Name types of permanent teeth



4

3

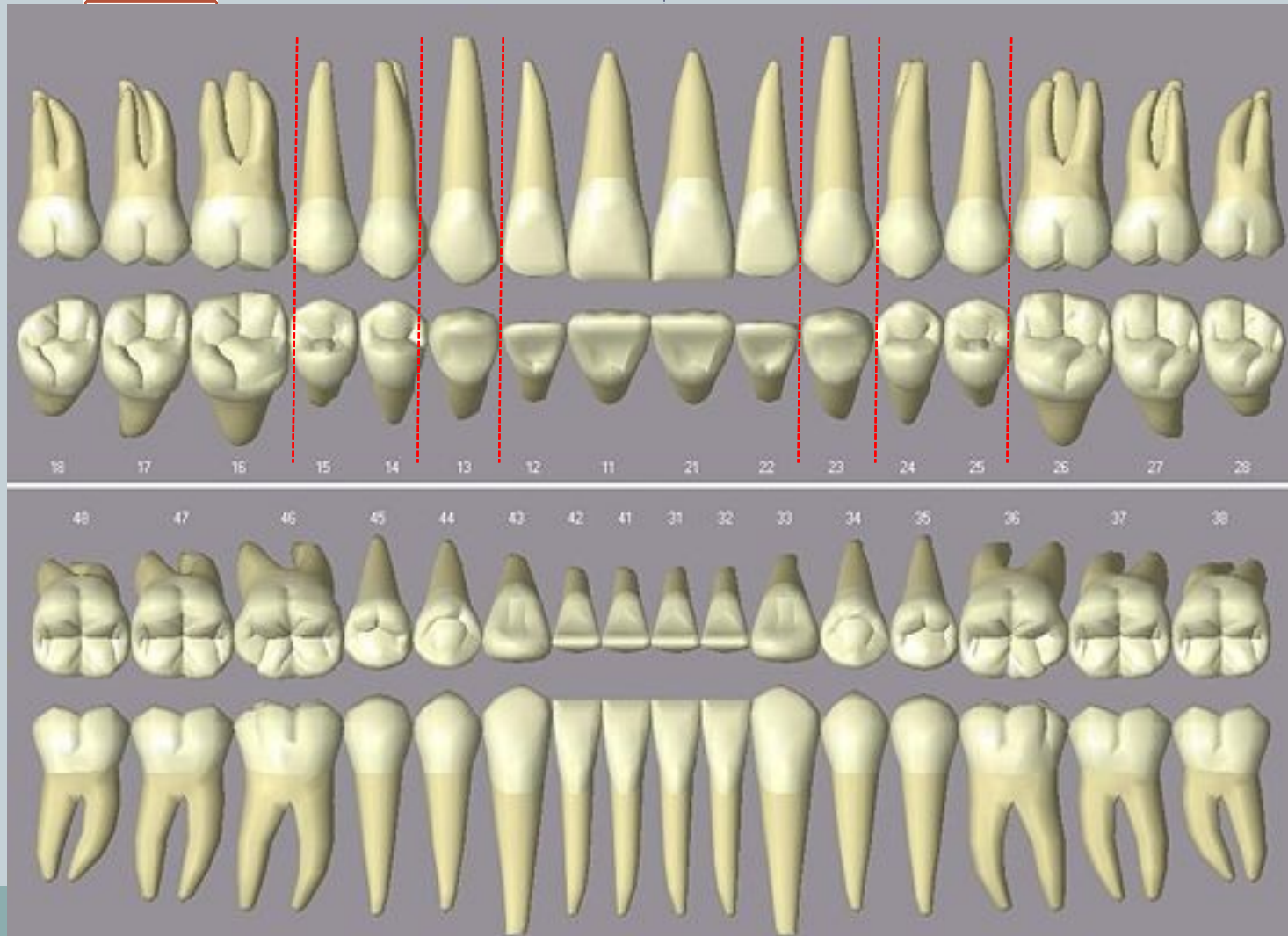
2

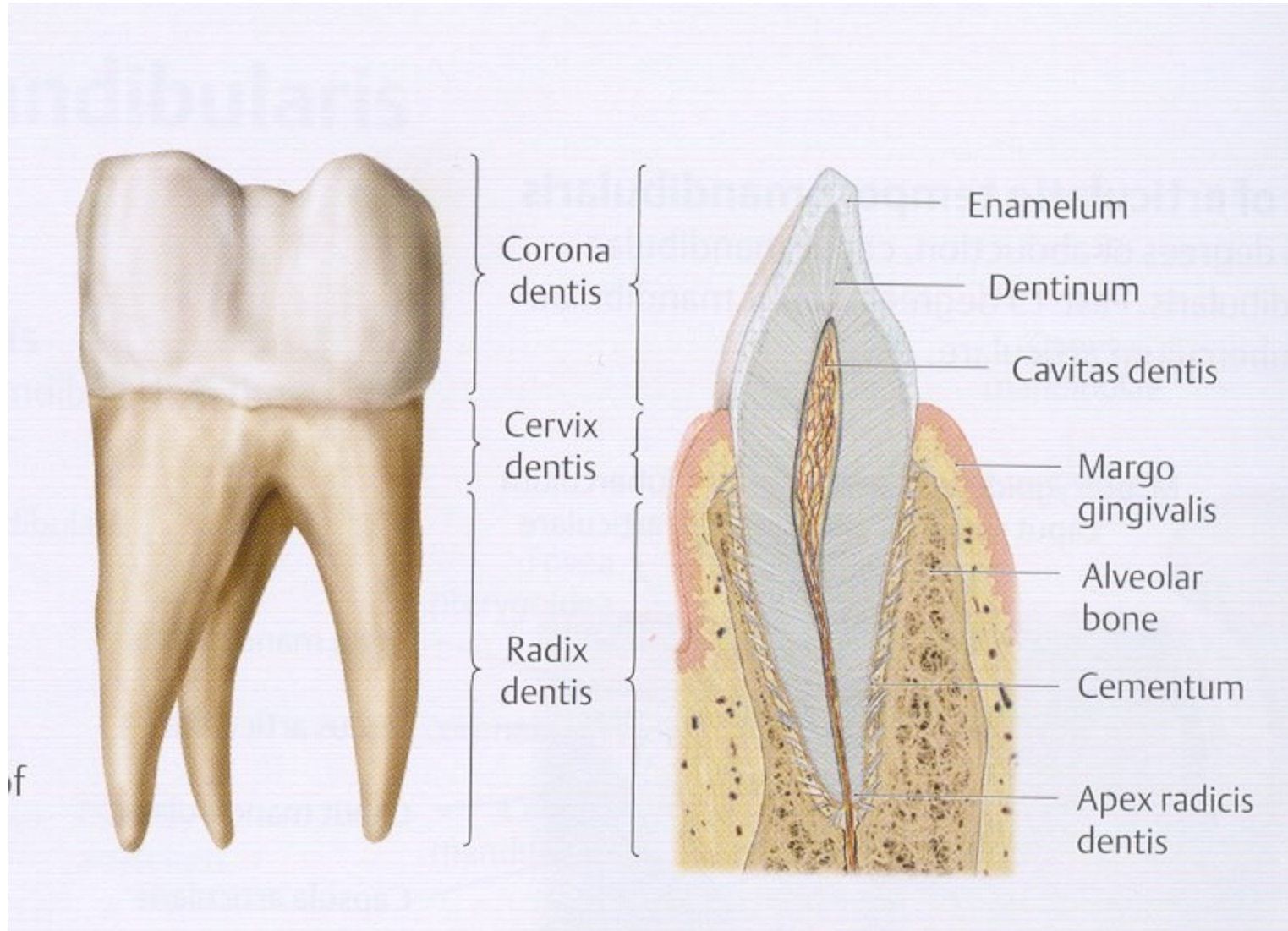
1

2

3

4





Translate types of tooth fractures : ICD S 02.50-54

23

Fracture of
tooth
enamel

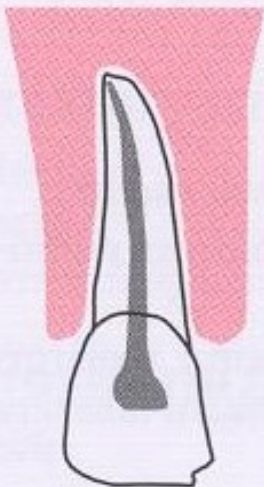
**Simple
fracture of
the tooth
crown not
penetrating
to the
dental pulp**

Complicated
fracture of
the tooth
crown
penetrating
to the dental
pulp

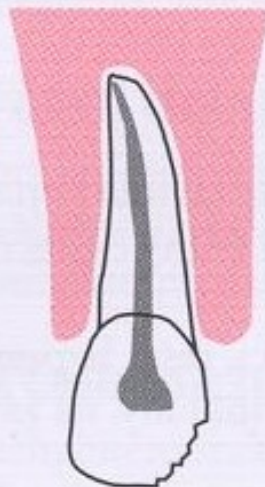
**Fracture of
the tooth
root**

Fracture of
the tooth
crown and
tooth root

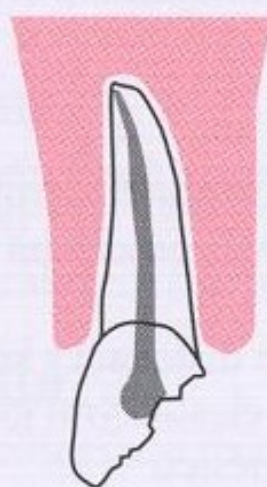
S02.50



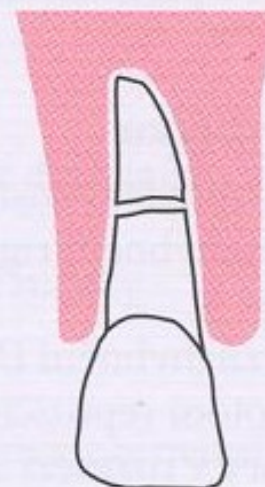
S02.51



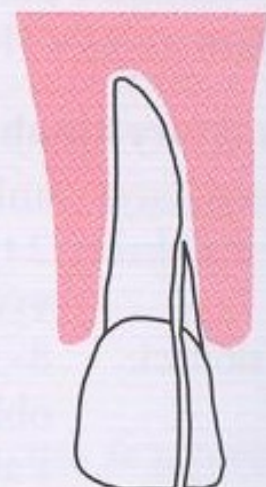
S02.52



S02.53



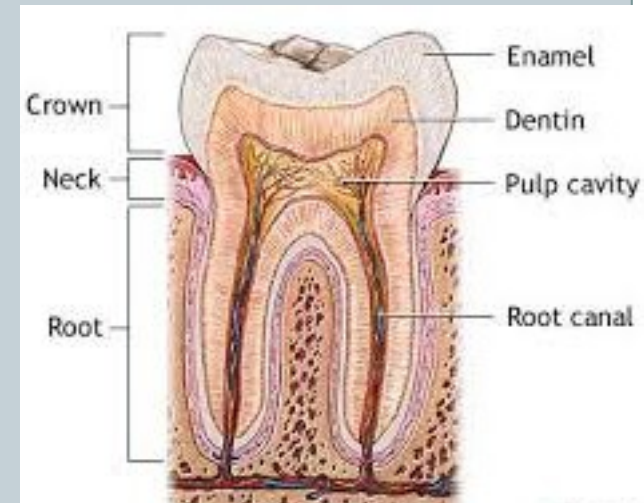
S02.54



1) Number types of tooth decay based on its severity, start from the simplest

2) Identify all adjectives, which declension are they?

- 4 A. *caries profunda simplex*
- 3 B. *caries media*
- 6 C. *caries ad pulpam penetrans*
- 2 D. *caries superficialis*
- 5 E. *caries profunda pulpa proxima*
- 1 F. *caries incipiens*



Authentic reports :1



Dg:

S8220 Fr. cruris l.sin cum fr.fibulae duplex disloc.aperta
stp. OS FE 17.7. 2010
V2331 Mot.x auto,;zra.při nás.,výs.;volný čas
S730 Luxatio coxae l.sin centralis stp. repositionem 17.7
S332 Luxatio art. SI l. sin stp. reposit. 17.7.
S3240 Fr. acetabuli l.sin transv.disloc. stp. OS 19.7.
S818 Decollement partis proximalis cruris l.sin.
S711 Vulnus lacerum reg. femoris l.sin.

collement = severe damage of soft tissues

Authentic reports :2

Dg: T068 Polytrauma
I259 Srdeční selhání
S3200 Fractura corporis vertebrae lumbalis II.
S2240 Fractura costarum IV.-XII. l.sin.
S2700 Pneumothorax l.sin.
S2710 Haemothorax l.sin.
S3240 Fractura acetabuli l.sin.
S3210 Fractura massae later. l.sin. ossis sacri
S3250 Fractura rami superior et inferior ossis pubis l.sin.
S7200 Fractura subcapitalis femoris l.sin.
S4241 Fractura epicondyli ulnaris humeri l.sin. aperta Tscherne I
W1311 Pád z bud., konstr.n.propad.;obytné instituce;volný čas



Fr. aperta TSCHERNE I

- open fracture with small skin injury without its contusion
- negligible bacterial contamination

Profesor Dr. Harald **Tscherne** (1933), Traumatology Clinic, Hannover: *Classification of fractures* published in 1982, T. divides fracture into open and closed. The most important for him is the degree of the soft tissues damage.

Create a clear Latin diagnose based on the passages in red



A 52-year-old man came to the emergency department at this hospital because of debilitating weakness in his legs and hips; he was unable to stand and had edema of the legs with extension to the waist. He reported increased irritability and bruising on his arms.

The chest CT scan obtained the next day showed a **lung abscess in the left upper lobe** and bilateral pleural effusions. MRI of the abdomen revealed **diskitis of the second and third lumbar vertebrae and an abscess extending into the right diaphragmatic crus.**

MRI also revealed **compression fractures of the L2 and L3 vertebral bodies** with enhancement, T₂-weighted hyperintensity, and very mild enhancement of the intervertebral disk, as well as an associated adjacent **dorsal epidural abscess, adjacent psoas muscle abscesses bilaterally, and dorsal paraspinal muscle abscesses.**

MRI of the brain performed 10 days after admission showed an **ischemic lesion in the right medial temporal lobe.**