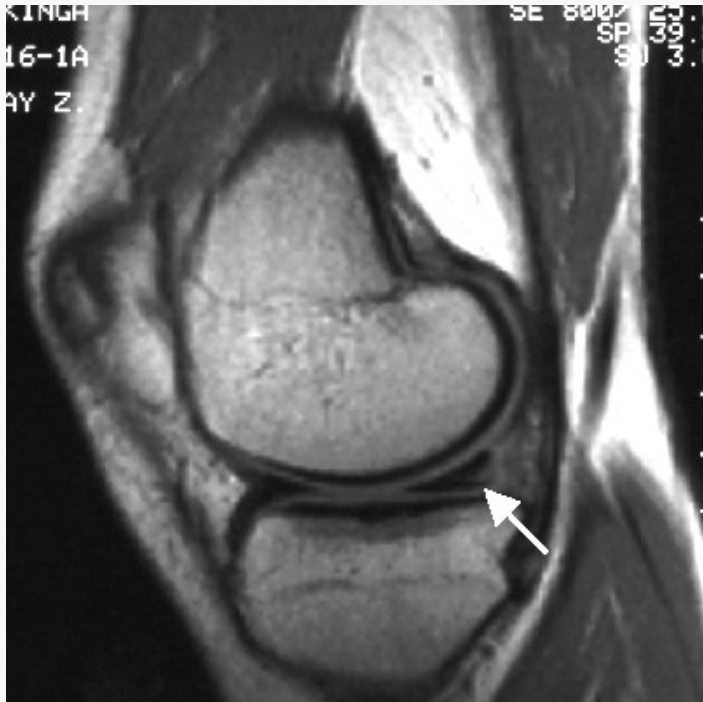

# Injuries



# Laesio

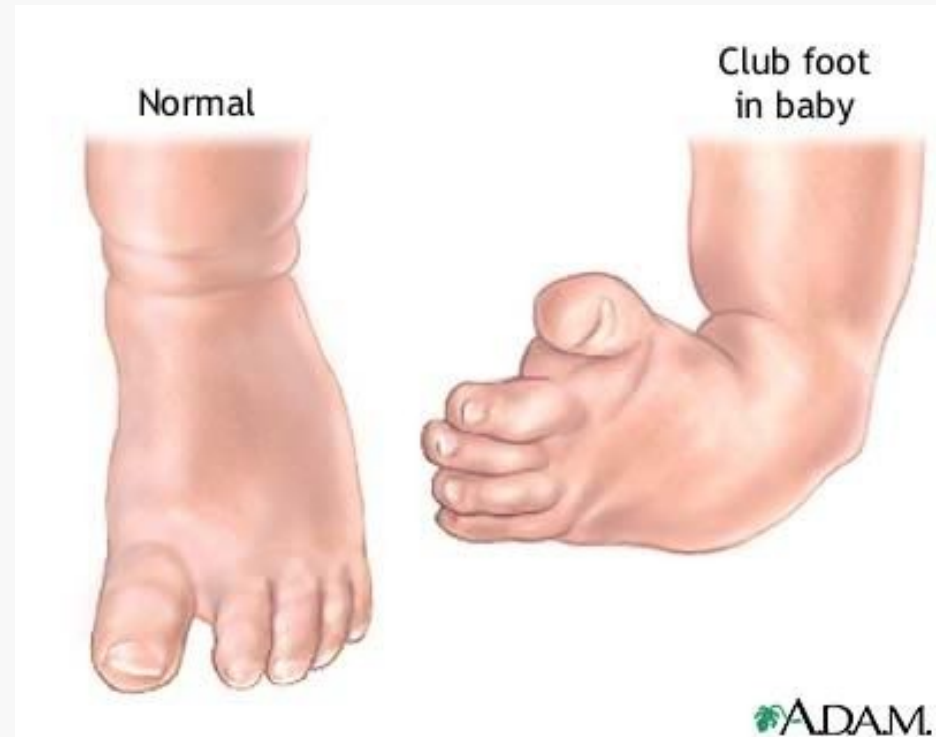- Any damage of an organ or tissue that leads to its damaged function

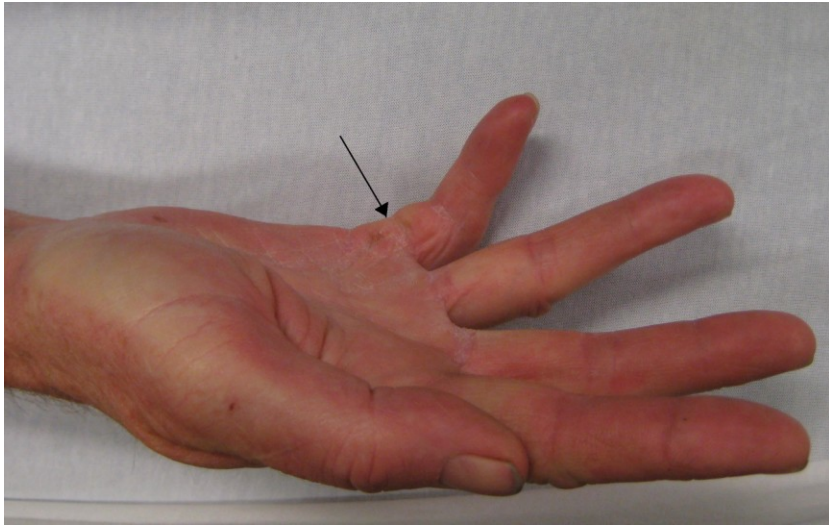


Torn meniscus

# Deformitas

- Permanent bodily malformation of the shape of and organ or part of the body

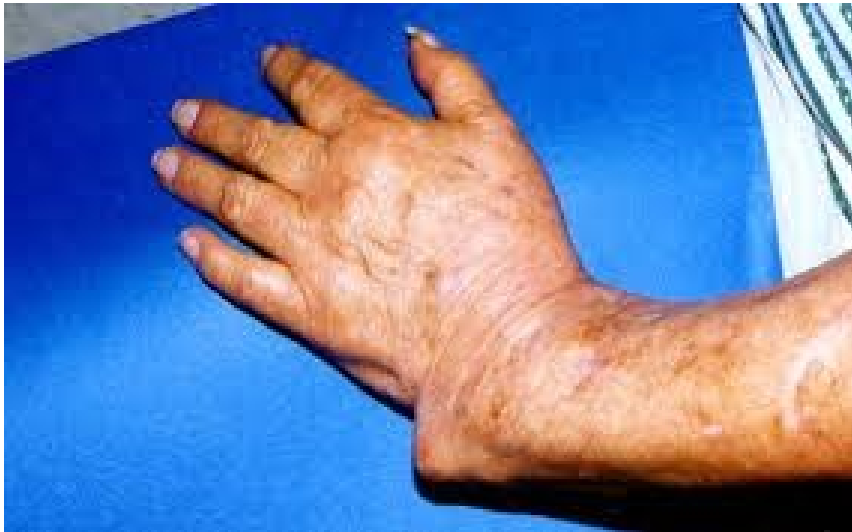



*Laesio – ligamentum –  
musculus – flexor – digitus  
– quintus – manus – lateris –  
dexter*

***ENDINGS?***

***Laesio ligamenti muscoli flexoris digiti quintii manus lateris dextri***



***FORMULATE A DIAGNOSE:***

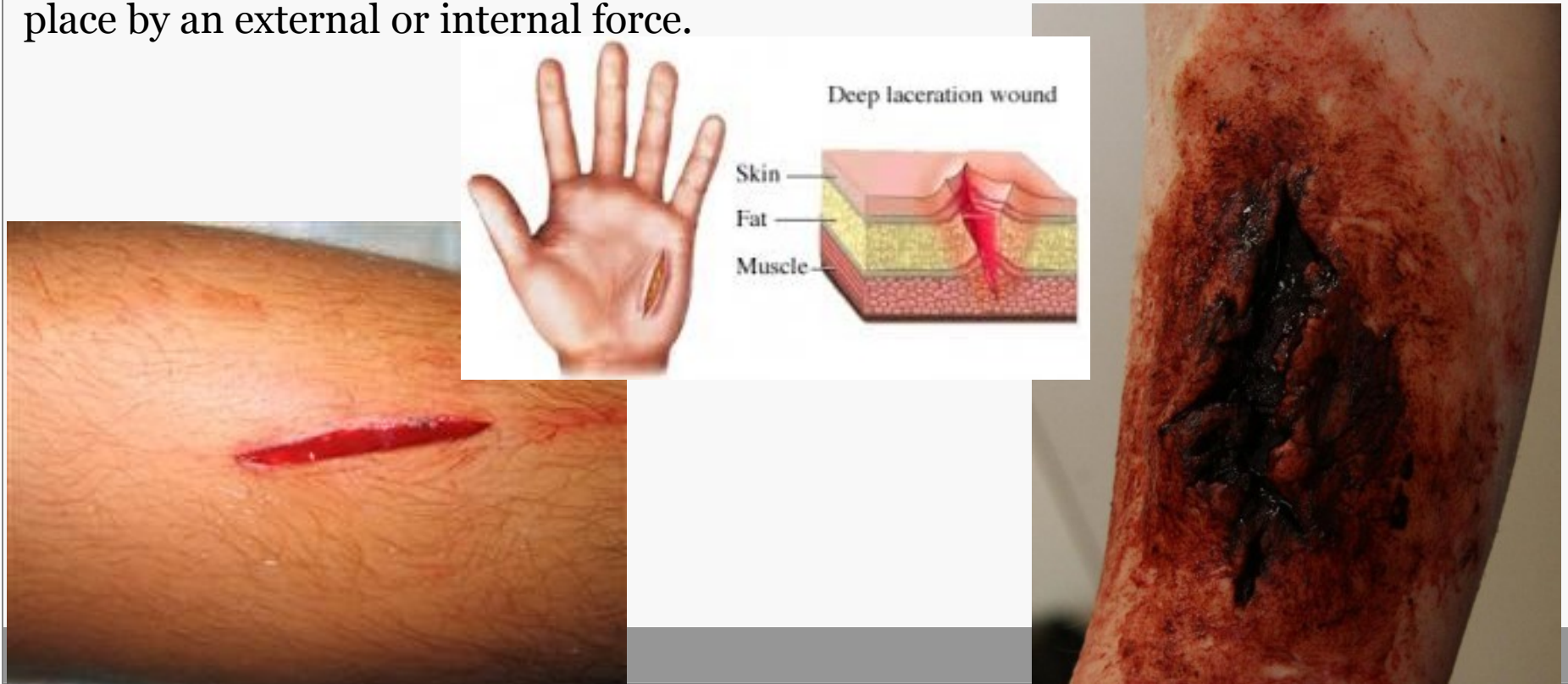*Deformitas antebrachii l.  
sin.*

*Derformitas antebrachii  
lateris sinistri*

Laceratio, onis, f. = vulnus lacerum



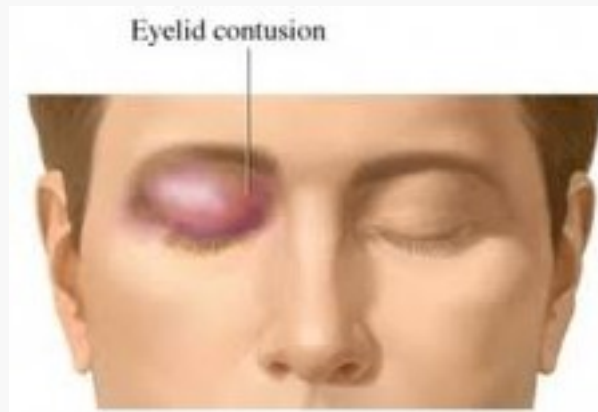**A torn ragged wound.** A wound produced by the tearing of body tissue. External lacerations may be small or large and may be caused in many ways, such as a blow from a blunt instrument, a fall against a rough surface, or an accident with machinery. Lacerations within the body occur when an organ is compressed or moved out of place by an external or internal force.



# Contusio, onis, f. = vulnus contusum

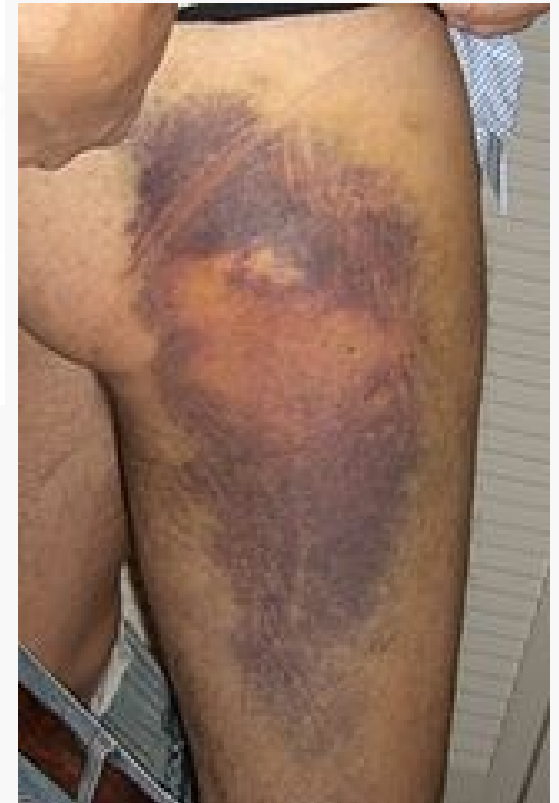

**Bruise wound**, an injury to tissues with skin discoloration and without breakage of skin. Blood from the broken vessels accumulates in surrounding tissues, producing pain, swelling, and tenderness, and the discoloration is the result of blood seepage just under the skin.

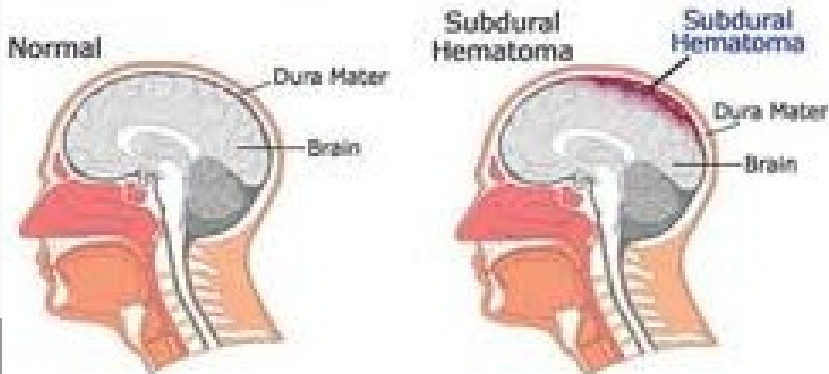


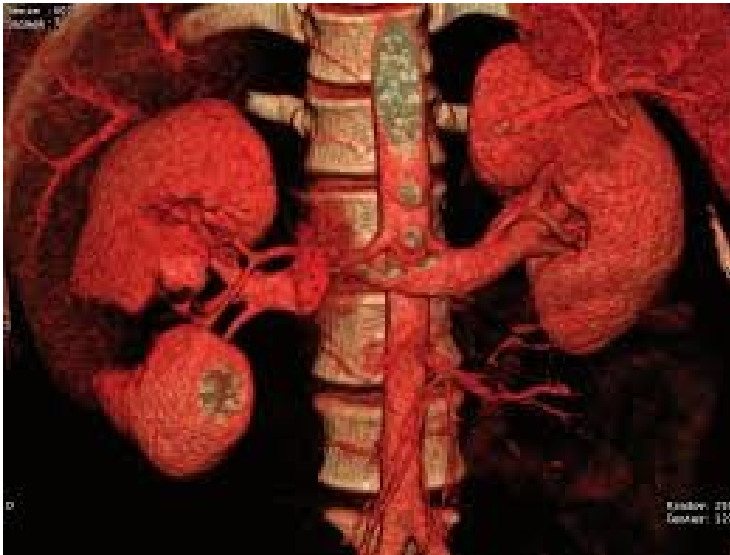## Haematoma

=Localized swelling filled with blood



## Subdural Hematoma

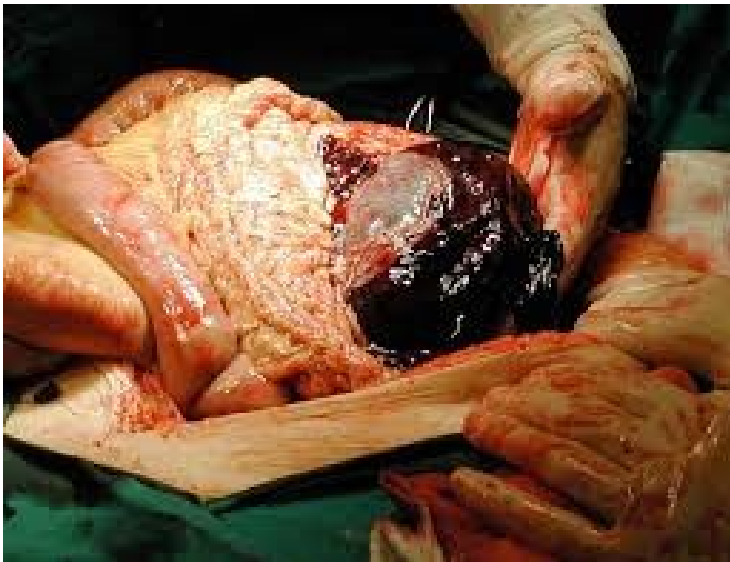



## *ABBREVIATIONS?*

*Laceratio renis l. dx.*

*( lateris dextri)*

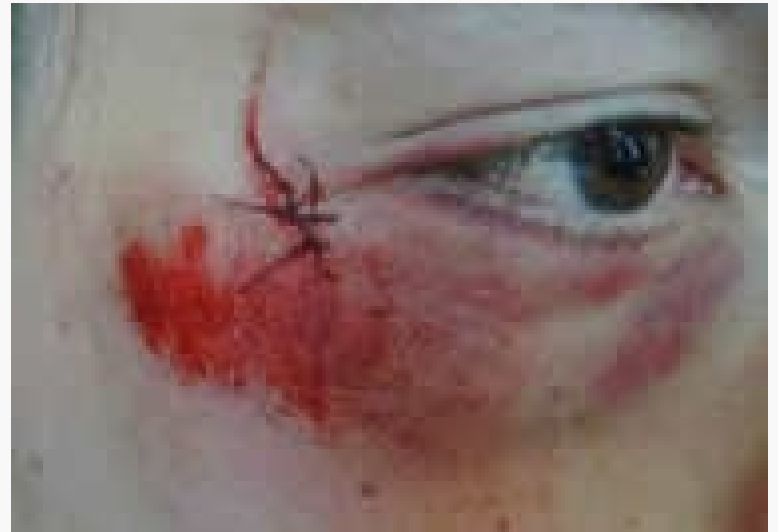
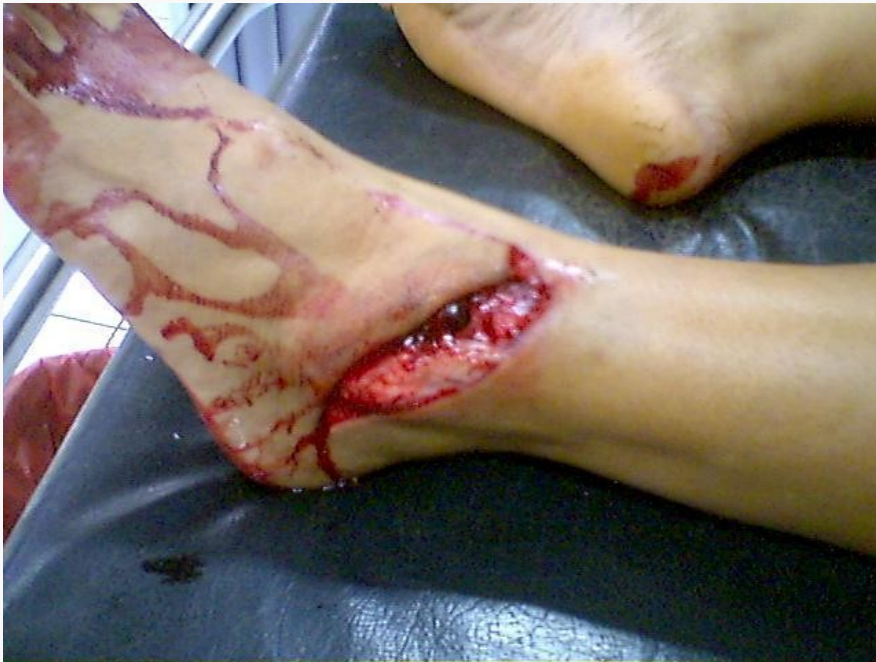
*Contusio lienis*

*Mors ex*

contusione lienis

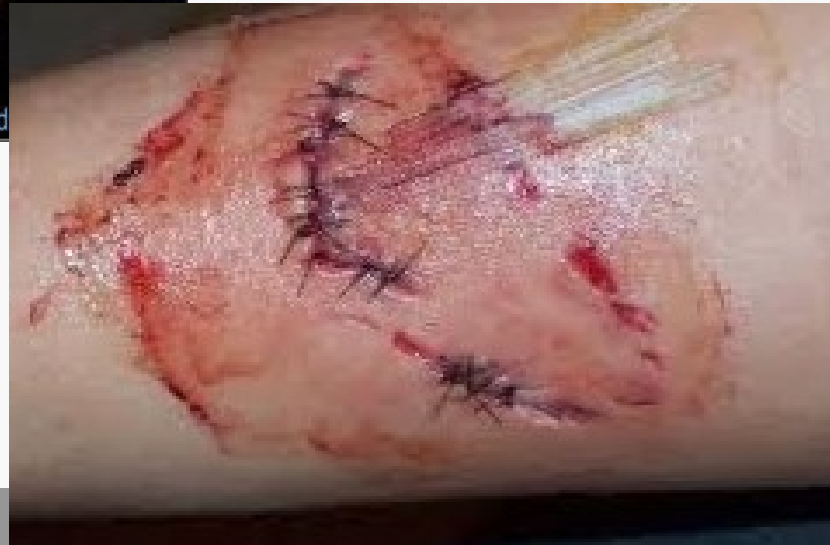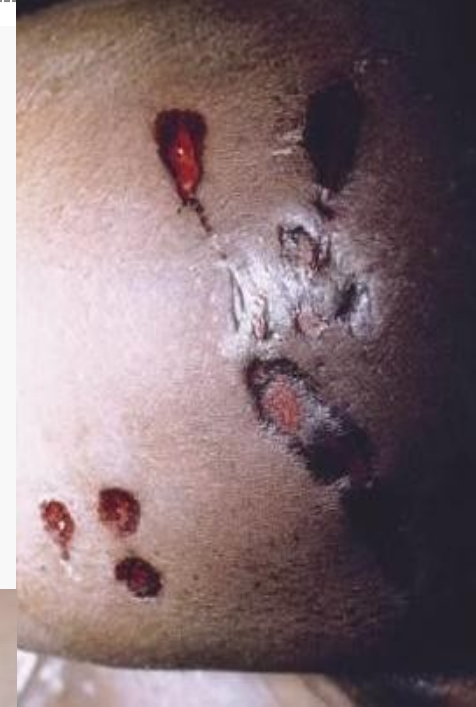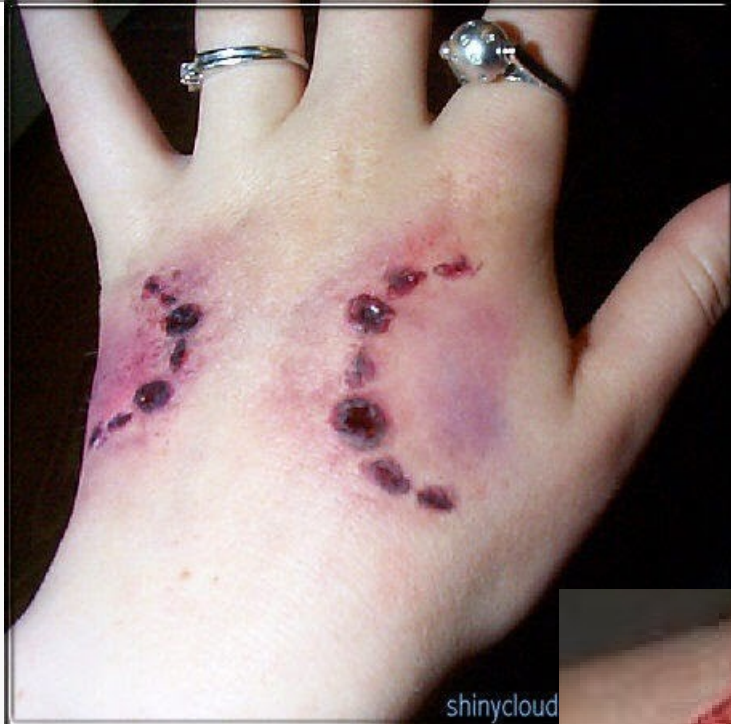# Vulnus contusolacerum



# Vulnus morsum



**Bite wound** – this wound is usually also contusolacerum (torn and bruise)



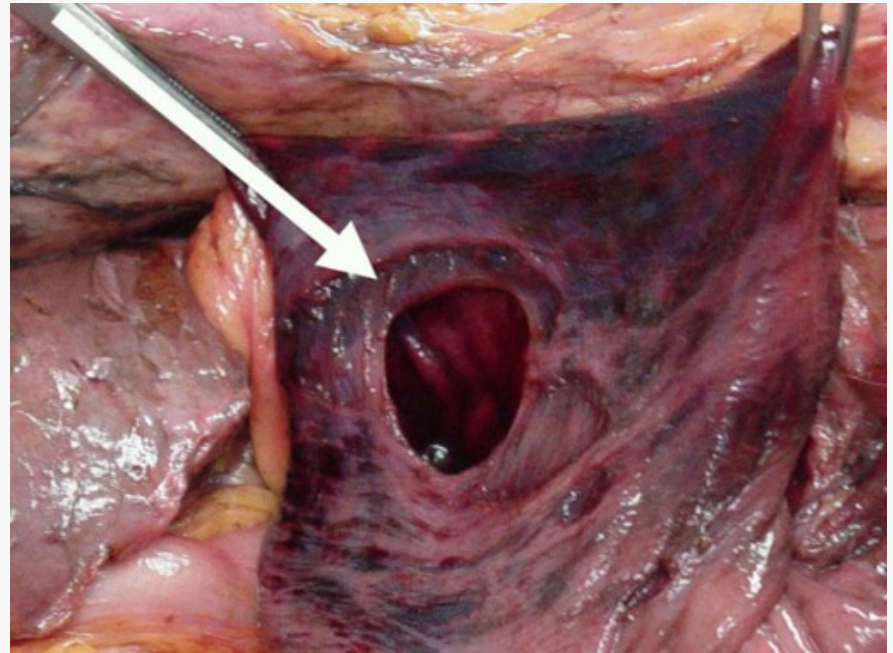
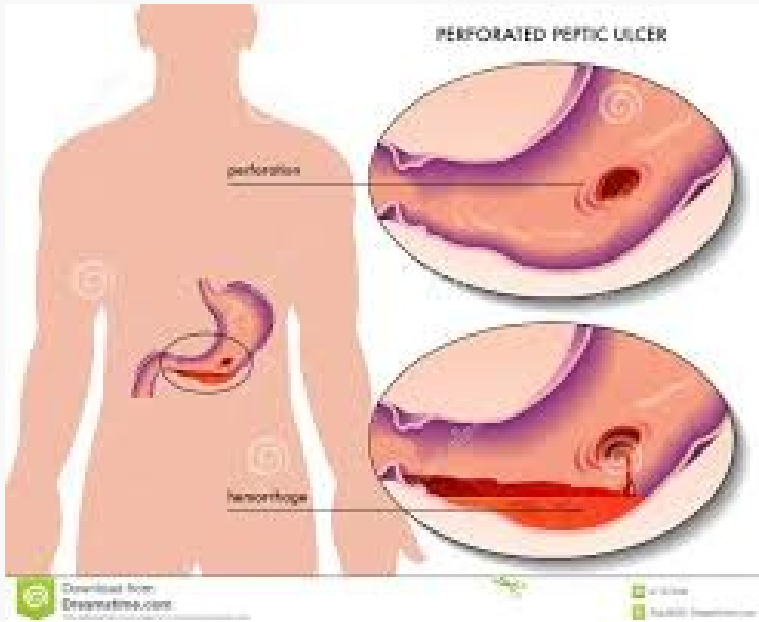


# Perforatio, onis, f.

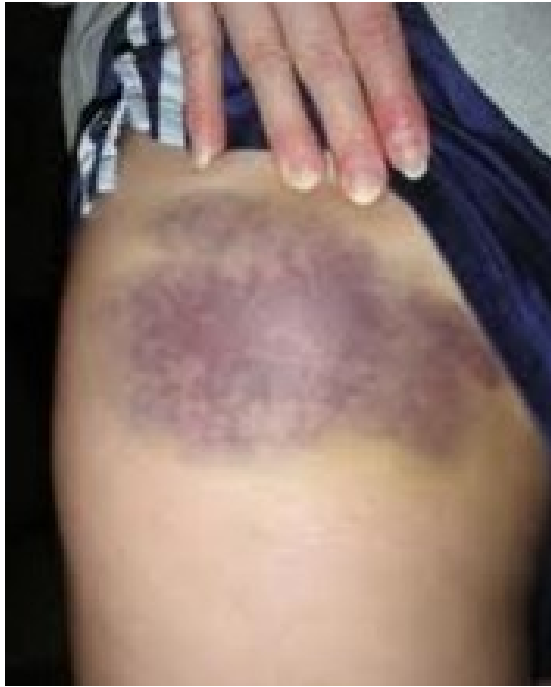

## **Perforation -**

Hole through the whole thickness of a tissue or membrane

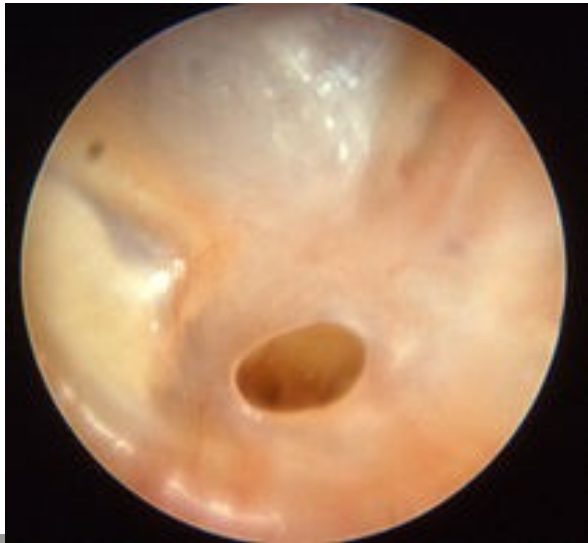

Perforatio fundi gastrici



*Contusio femoris lateris  
dextri cum haematomate*

***FILL IN MISSING ENDINGS***



*Perforatio membranae  
tympani*

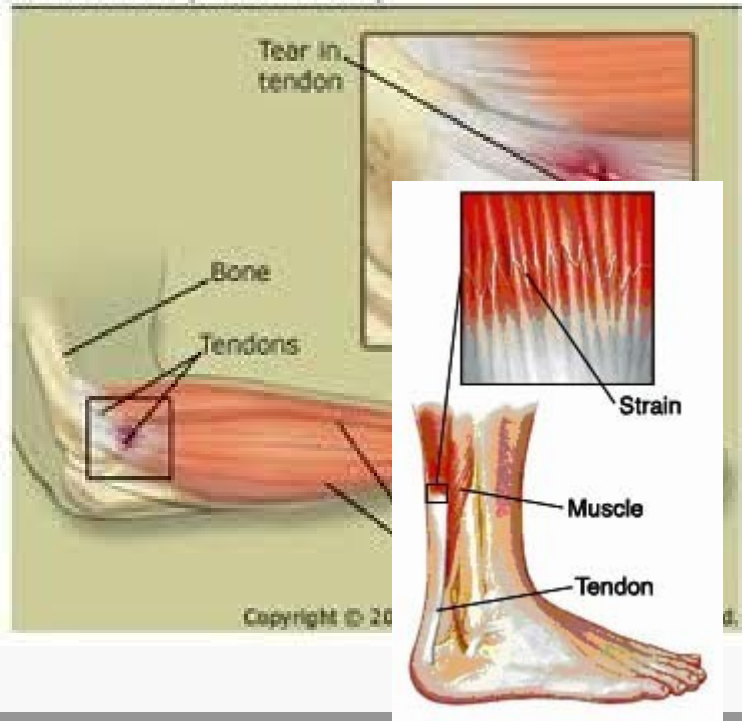***Status post***  
*perforationem membranae tympani*

# Distensio, onis, f.

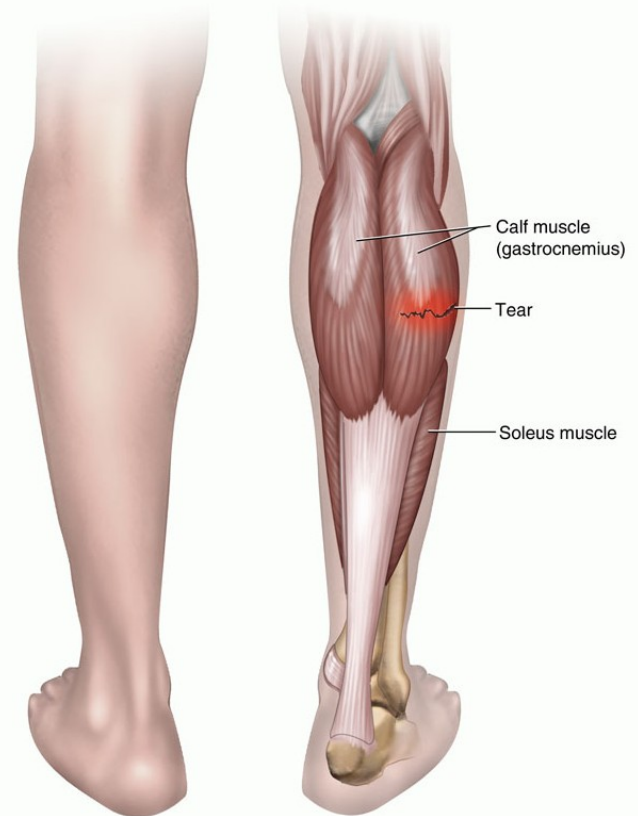


**strain** = an injury to a muscle or tendon in which the muscle fibres tear as a result of overstretching

Tendinitis (Elbow strain)



Calf Muscle Strain

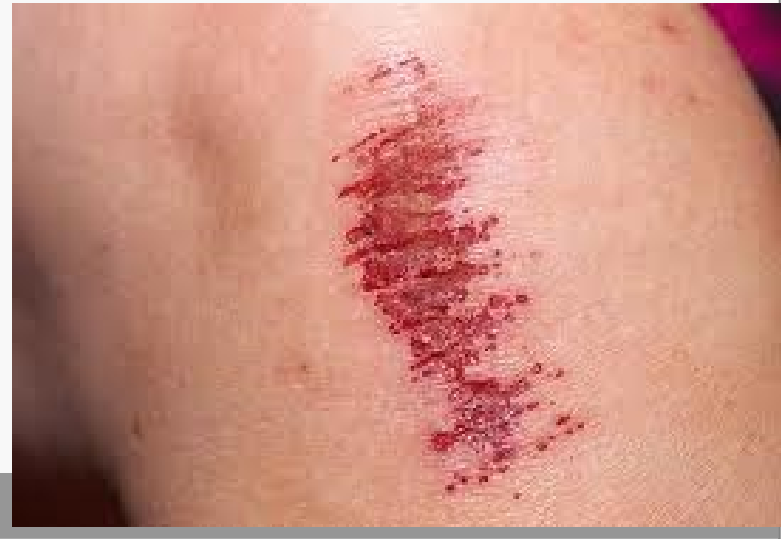
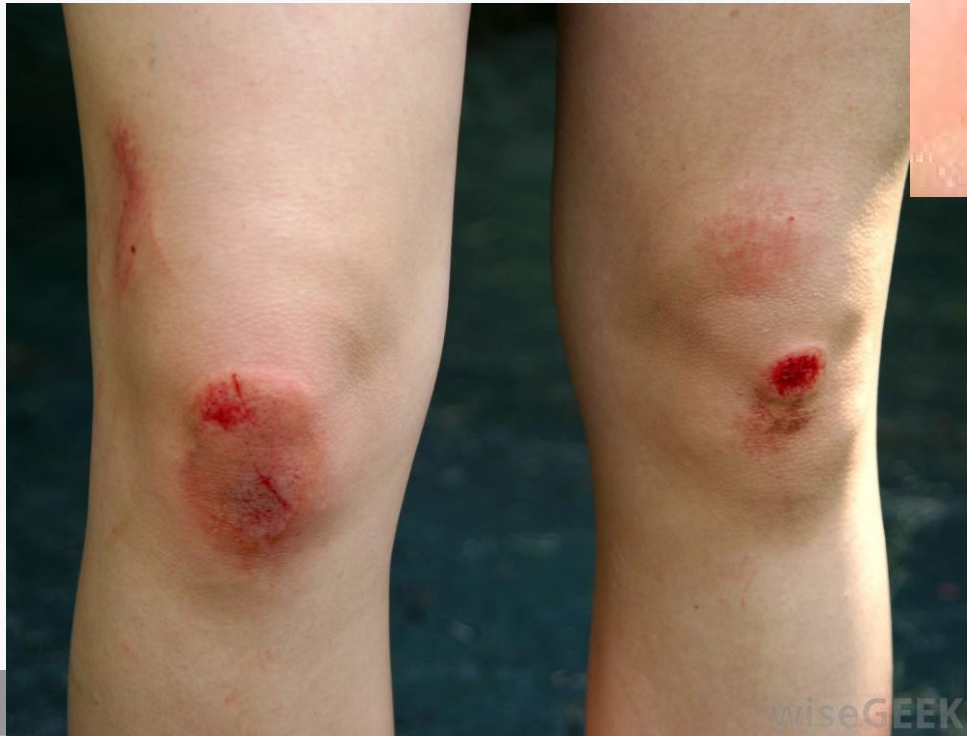
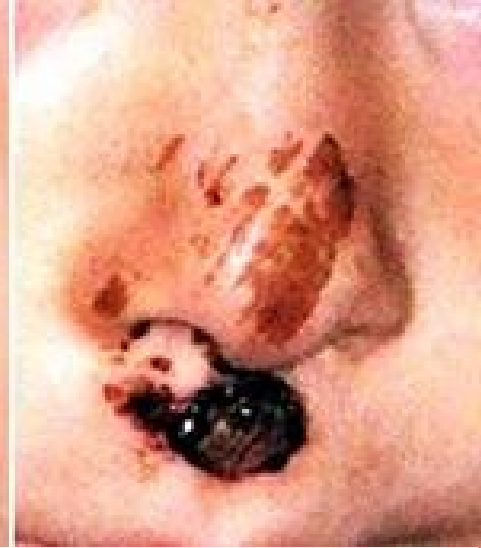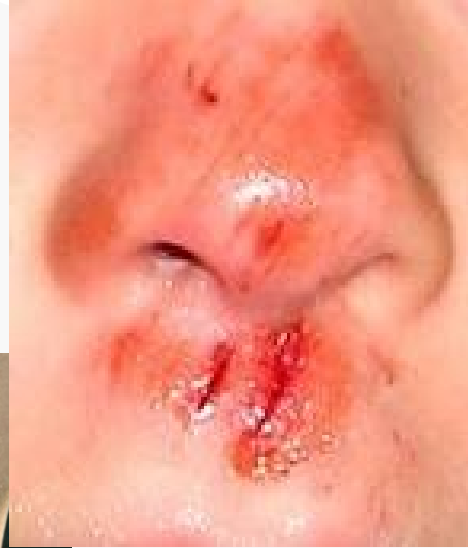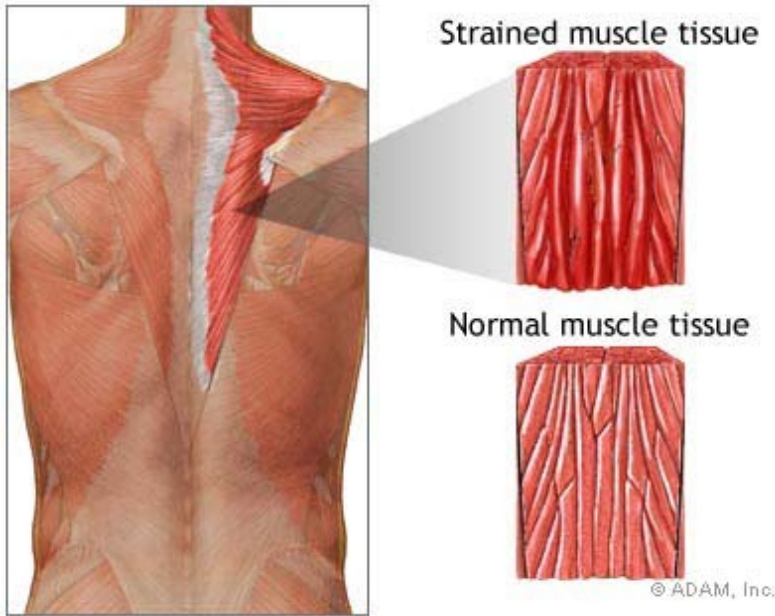
# Excoriatio, onis, f.



**scrape**

= skin surface removed

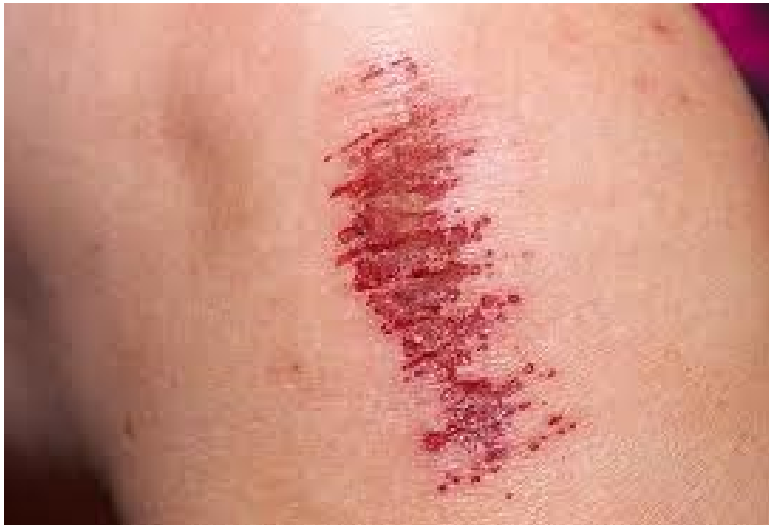



*Musculus trapezius l. dx.*

*Distensio*

musculi trapezii lateris dextri

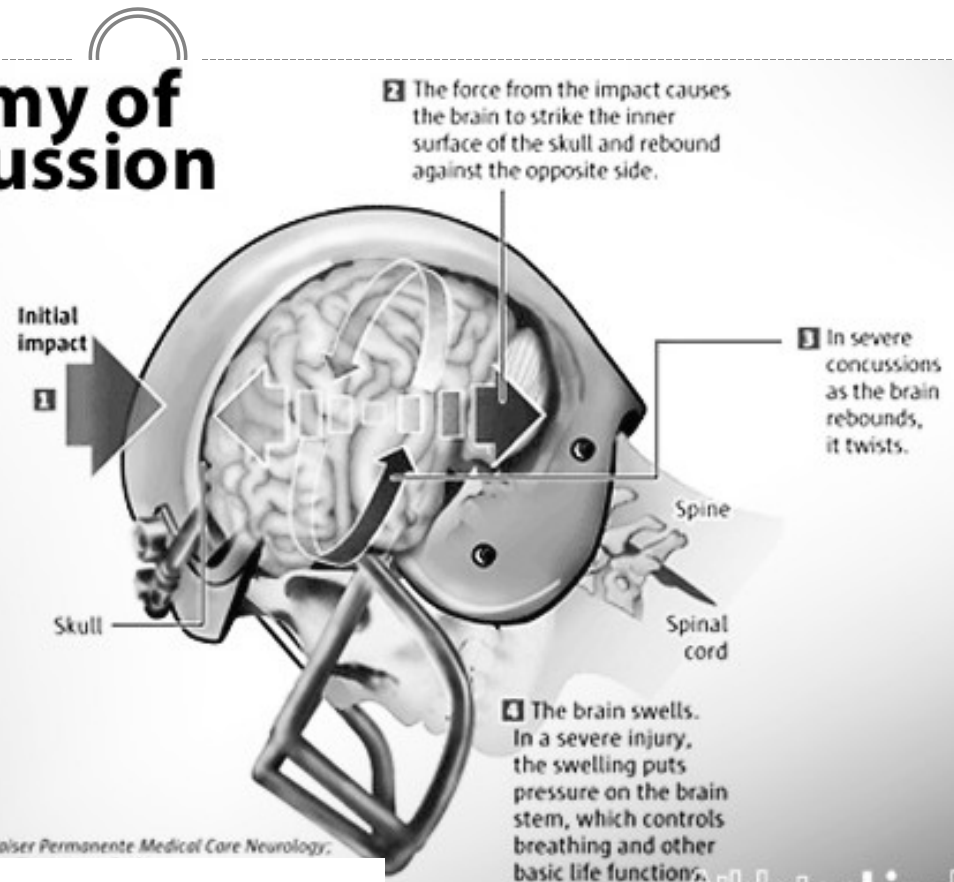


*Excoriationes* faciei  
*(face)*, manus *(hand)*  
*l. utr. et* genus  
*(knee)*

# Commotio, onis, f.

**concussion** = a violent jarring or shaking that results in a disturbance of brain function

## Anatomy of a concussion



AthletesLiveHere.com

### Common signs of concussion:



Dizziness



Nausea



Headaches



Light Sensitivity

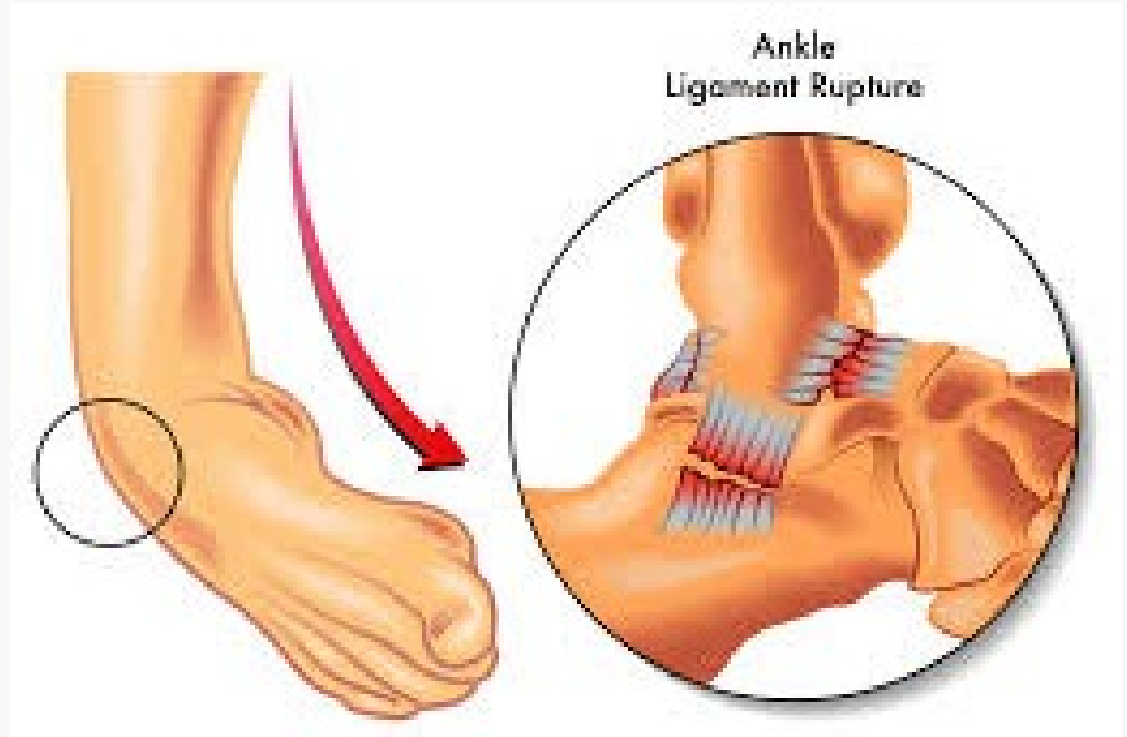
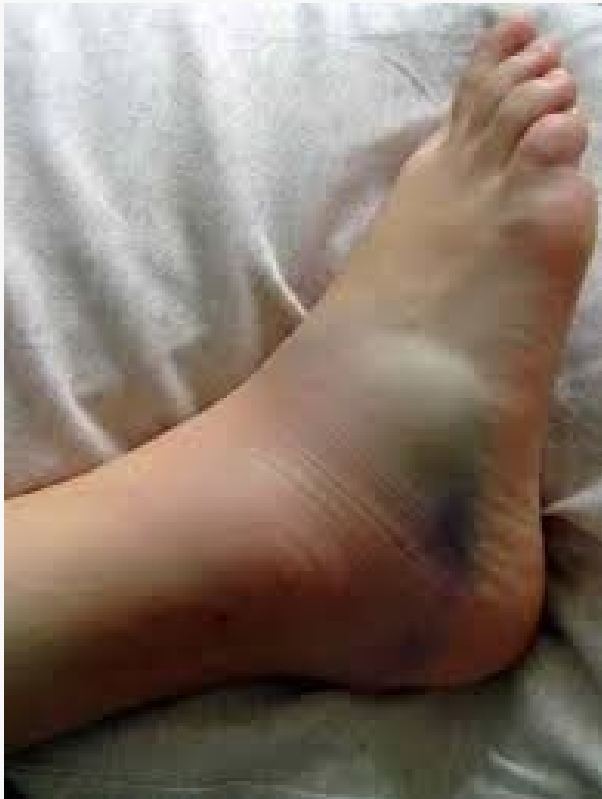
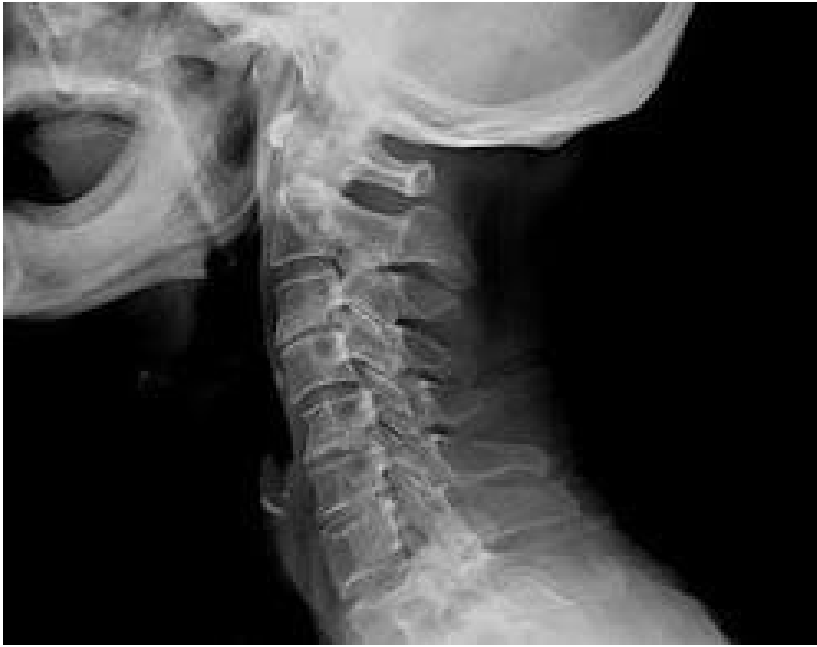Confusion

# Distorsio, onis, f.



**sprain, distorsion** = a joint injury in which some of the fibers of a supporting ligament are ruptured but the continuity of the ligament remains intact





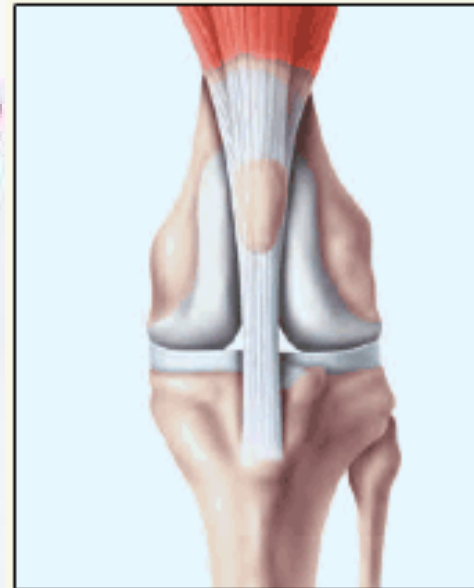
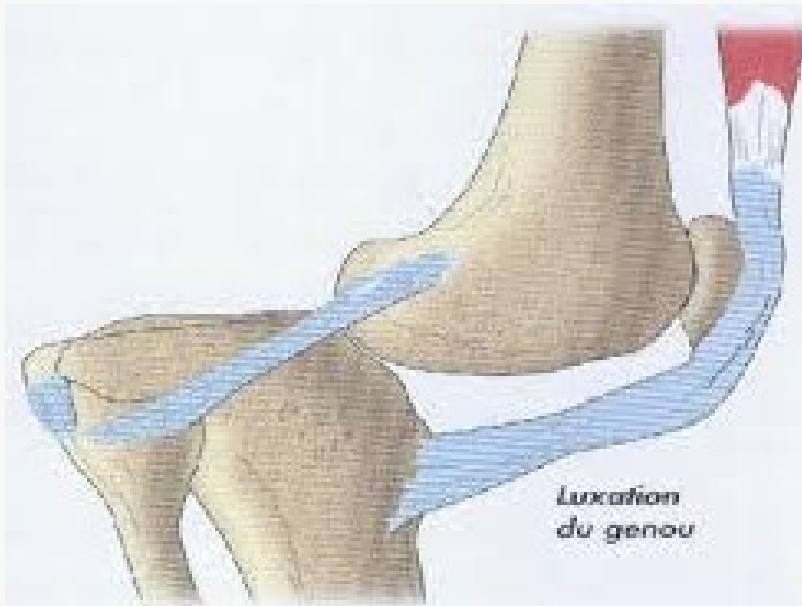
*Susp. distorsionis columnae vertebralis partis cervicalis*

*Susp.* = ?      suspicio = suspicion

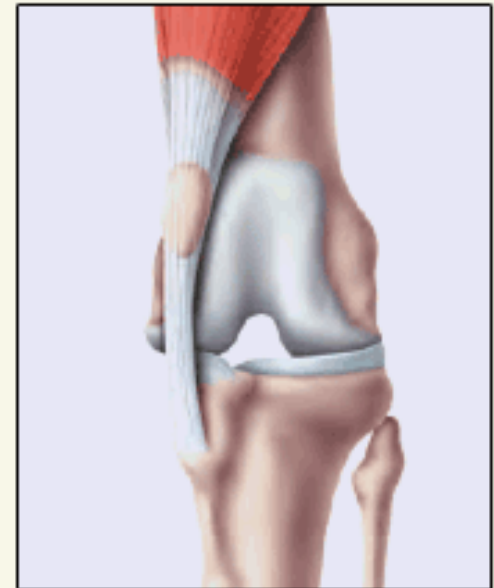

# Luxatio, onis, f.

**Luxation** = displacement of a bone from a joint



*Normal patellar alignment. The patella and quadriceps are in alignment and the patella is seated in the groove.*

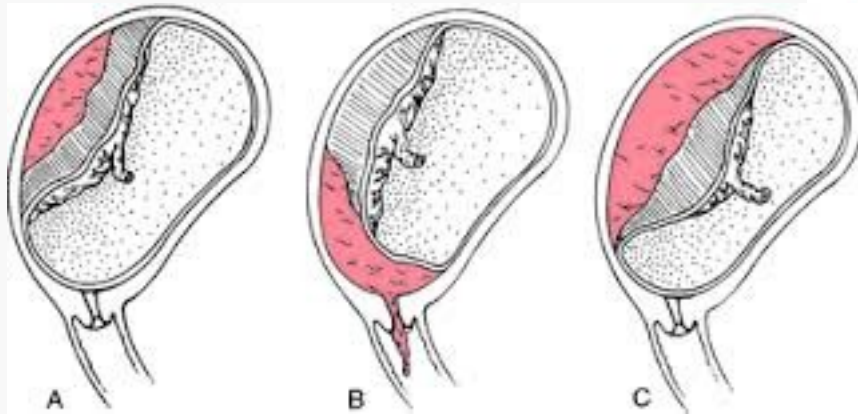


*Medial patellar luxation. The quadriceps and patella are medial to the trochlear groove and the tibia is rotated medially.*

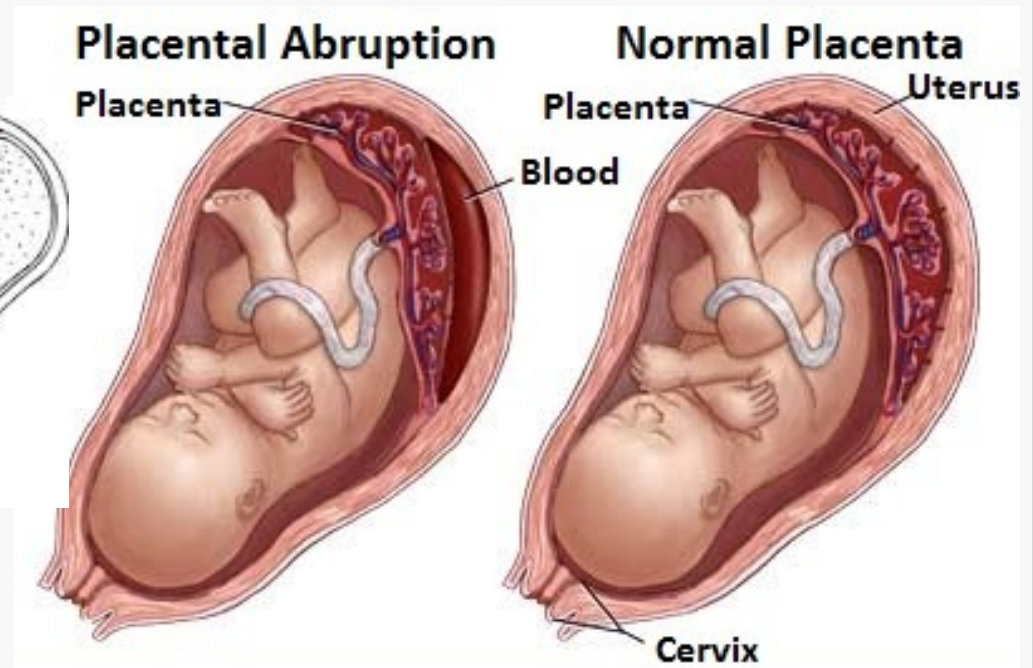
# Abruptio, onis, f.

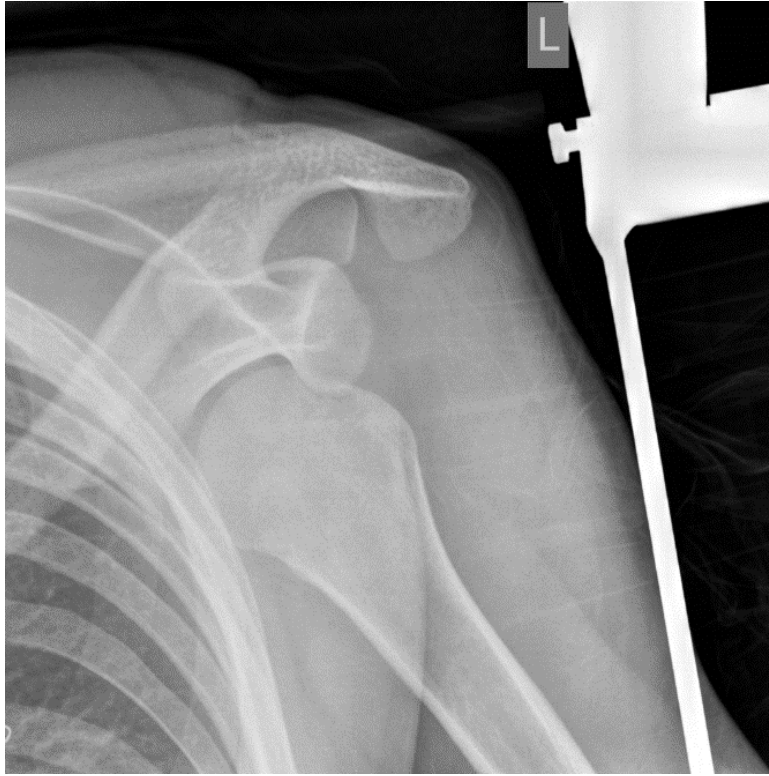

A tearing away, separation, or detachment



Placental abruption





*humeri | sinistri | fractura | luxatione | cum | lateris*

***PUT IN THE CORRECT ORDER***

fractura humeri lateris sinistri cum luxatione

# Combustio, onis, f.

## burn wound

Epidermis

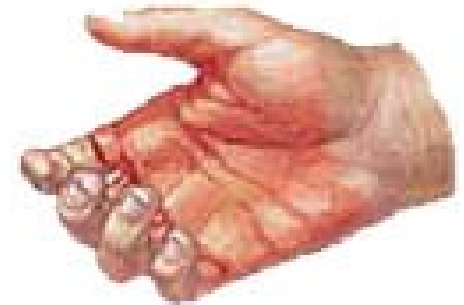Dermis

Subcutaneous

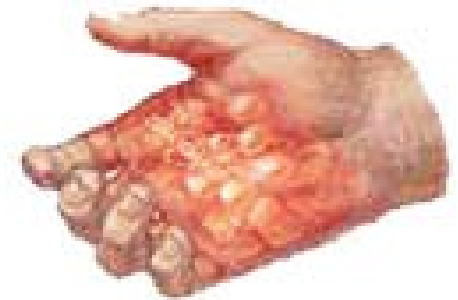Muscle



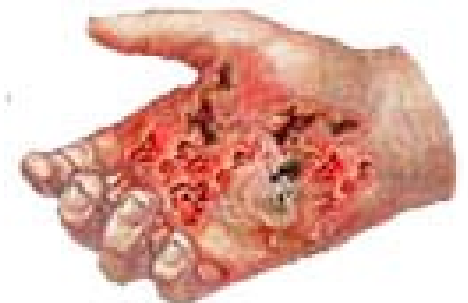Superficial  
(first degree)  
burn



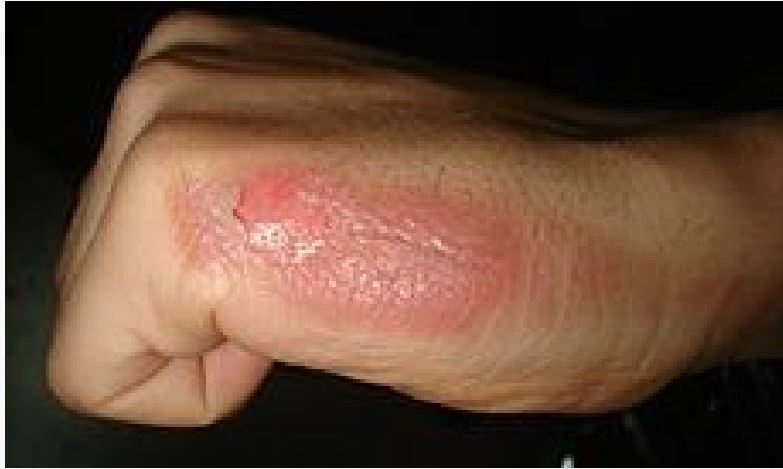Partial thickness  
(second degree)  
burn



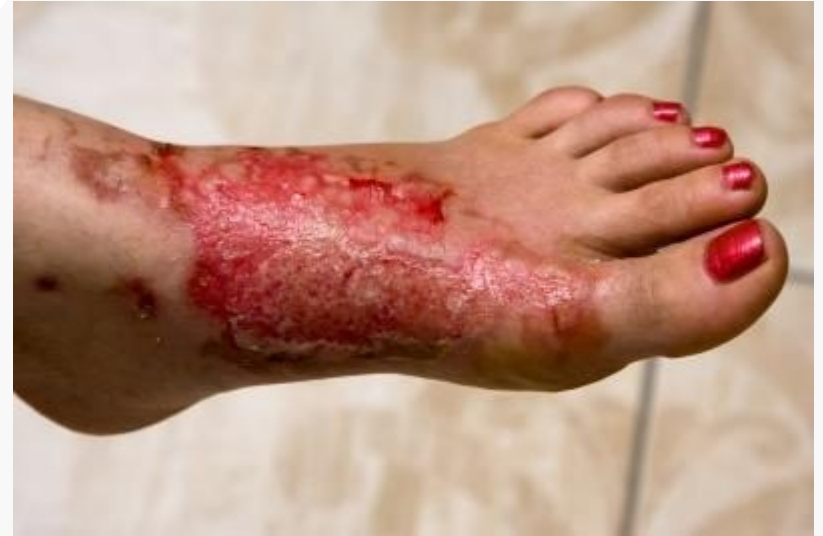Full thickness  
(third degree)  
burn



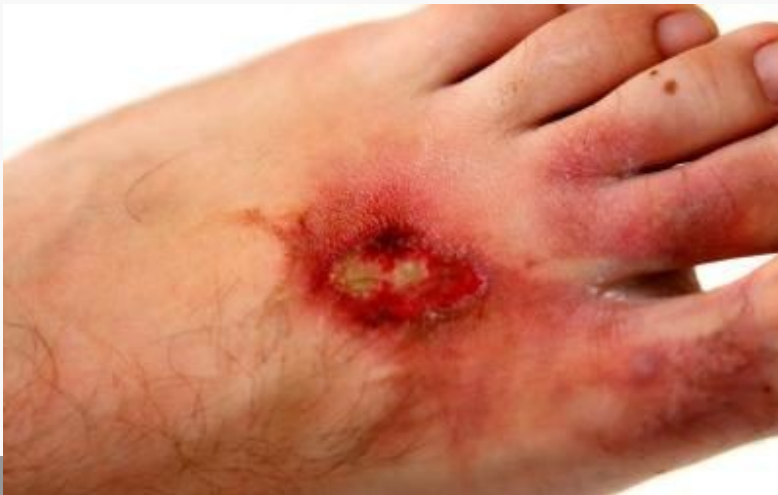# Combustio, onis, f.



2<sup>nd</sup> degree/grade burn



3<sup>rd</sup> degree/grade burn



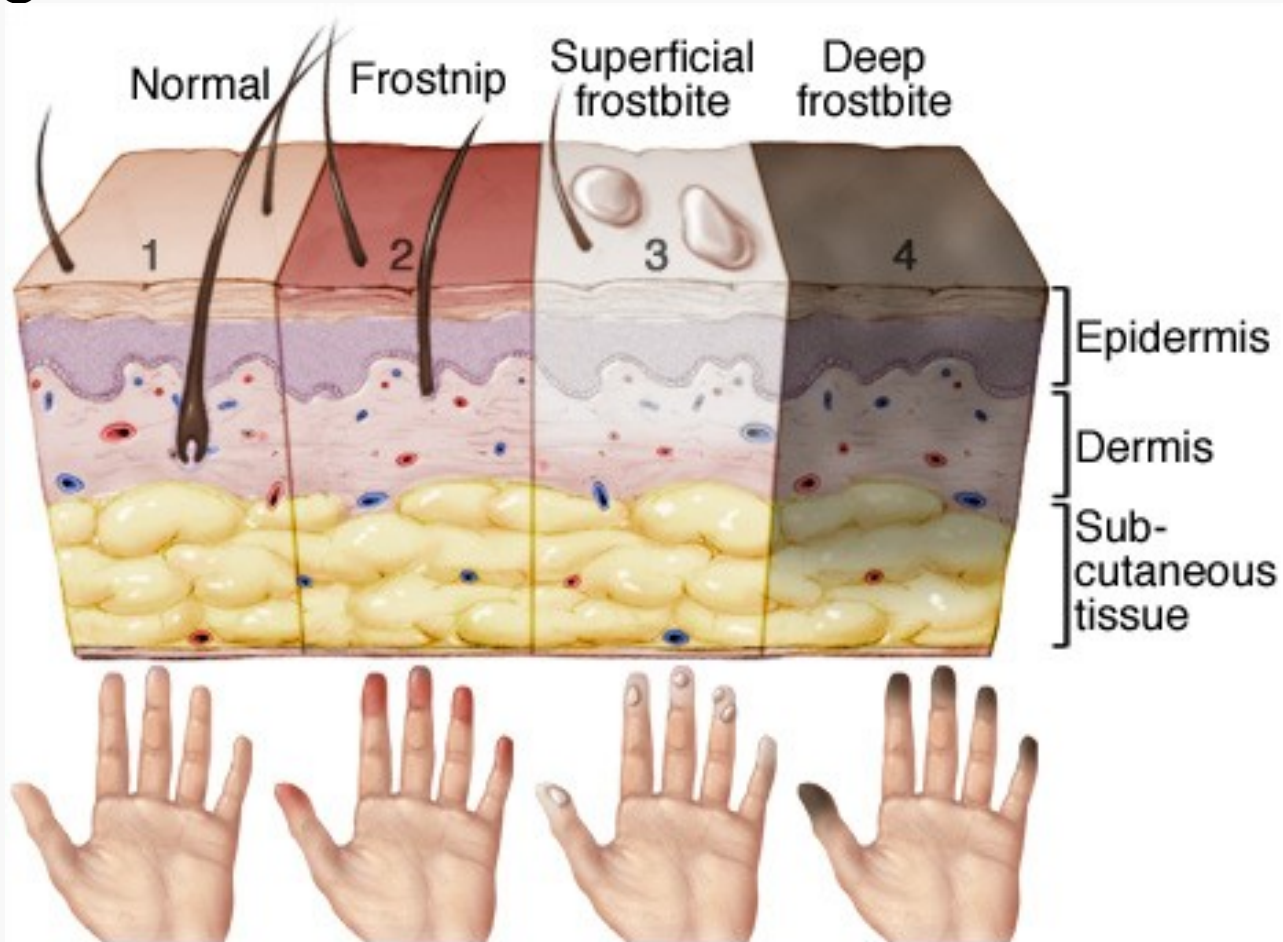
## **infected burn wound**

-change in the color of the skin around the burn, swelling, strange odor, the wound sinks deeper into the skin and gets larger, green or yellow pus develops, a fever

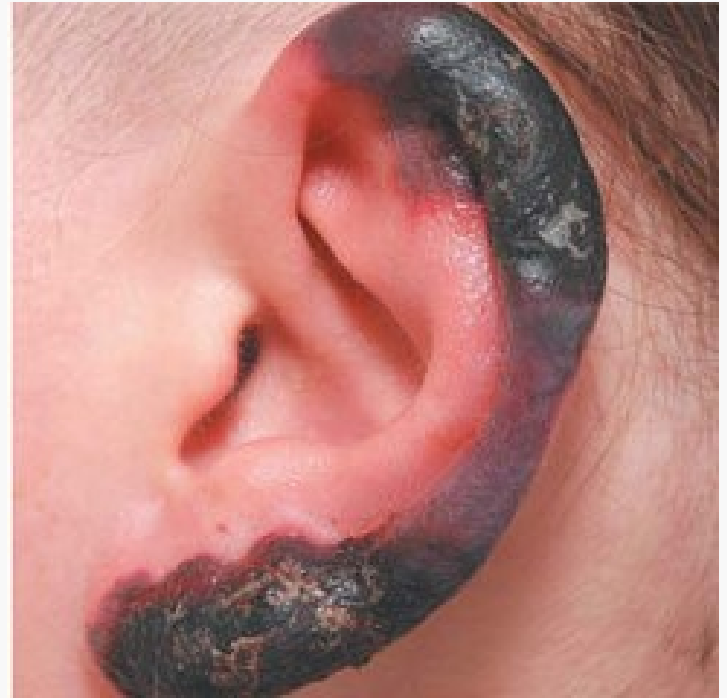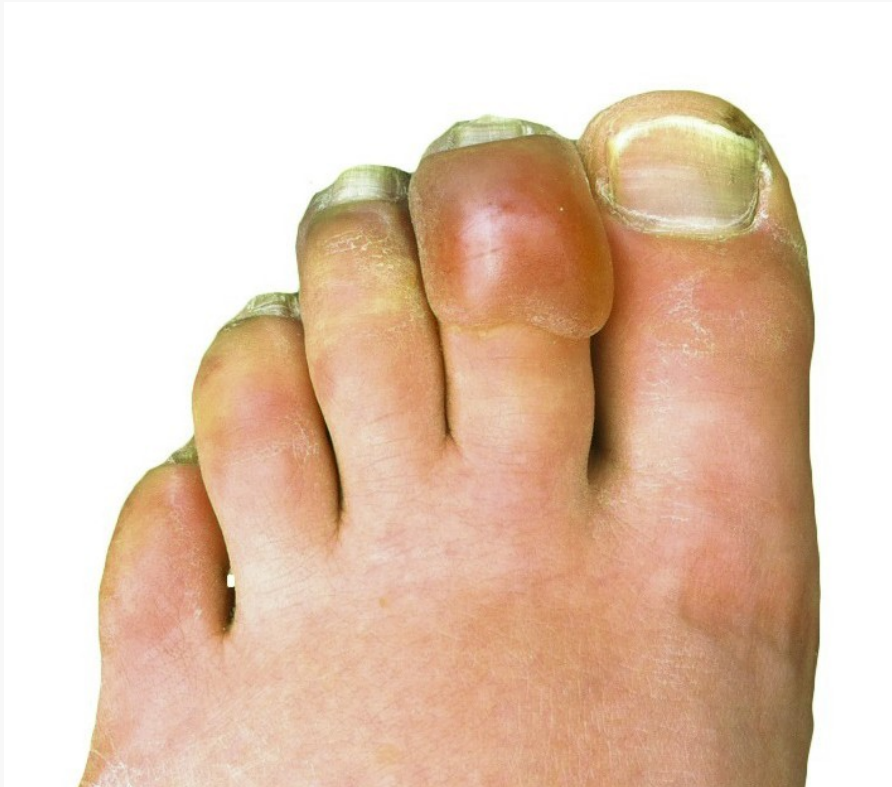# Congelatio, onis, f.

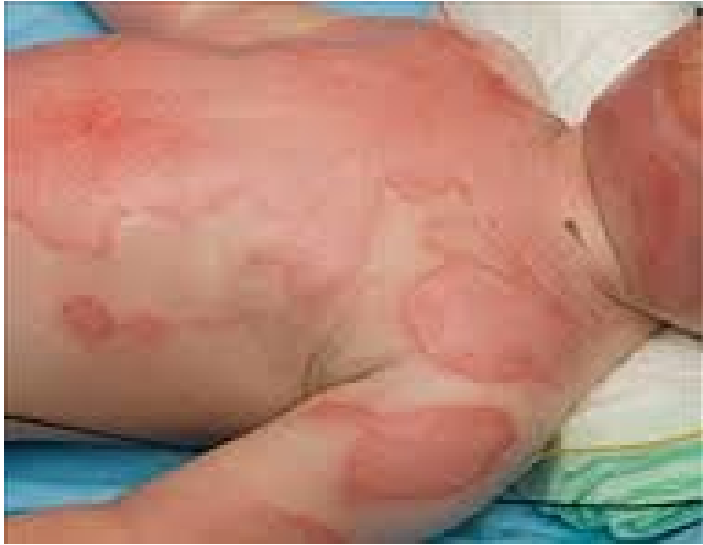

## frostbite



# Congelatio, onis, f.

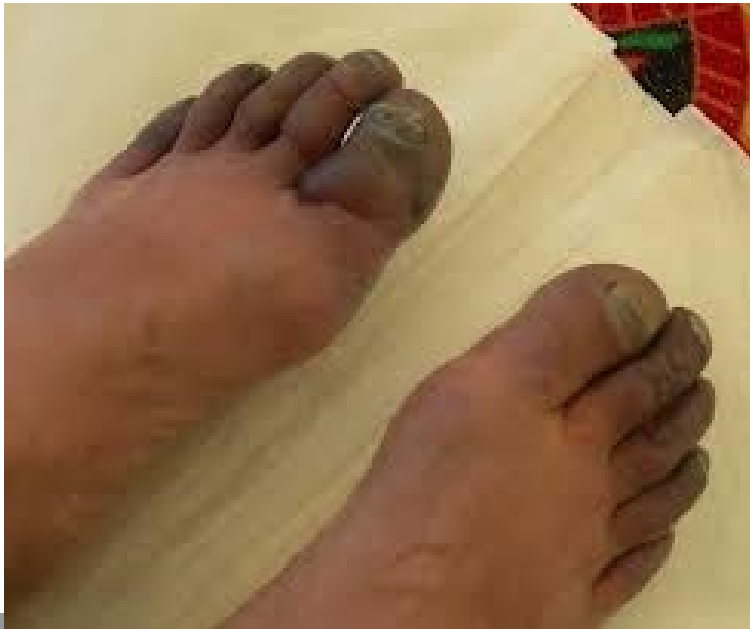



*Combustio thoracis, cervicis  
et faciei*

***PLURAL?***

combustiones thoracis, cervicis  
et faciei



*Congelationes extremitatum  
inferiorum gr. IV.*

***WHAT DOES „GR. IV.“  
MEAN?***