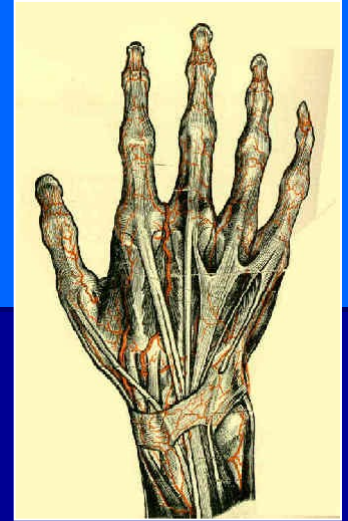
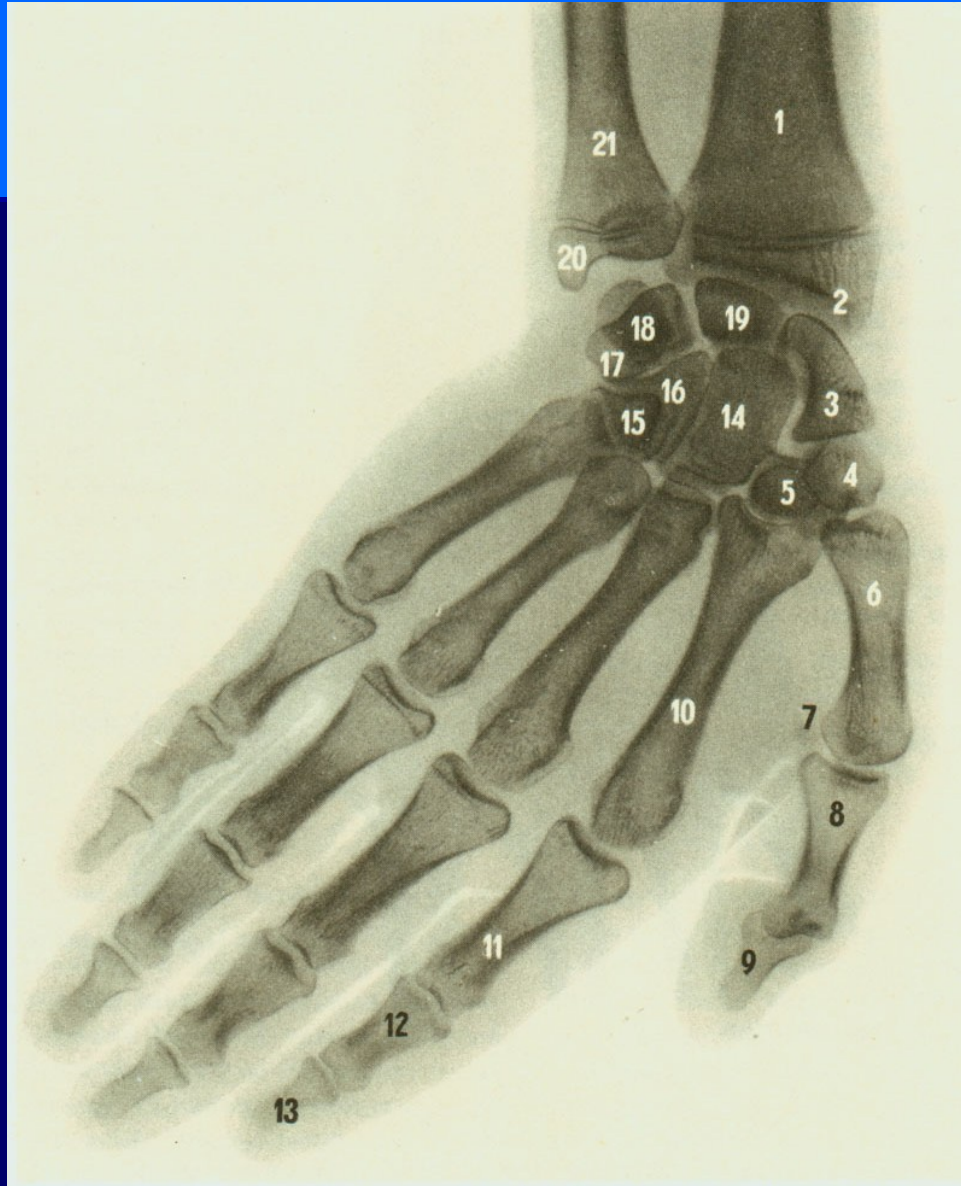

Wrist and hand

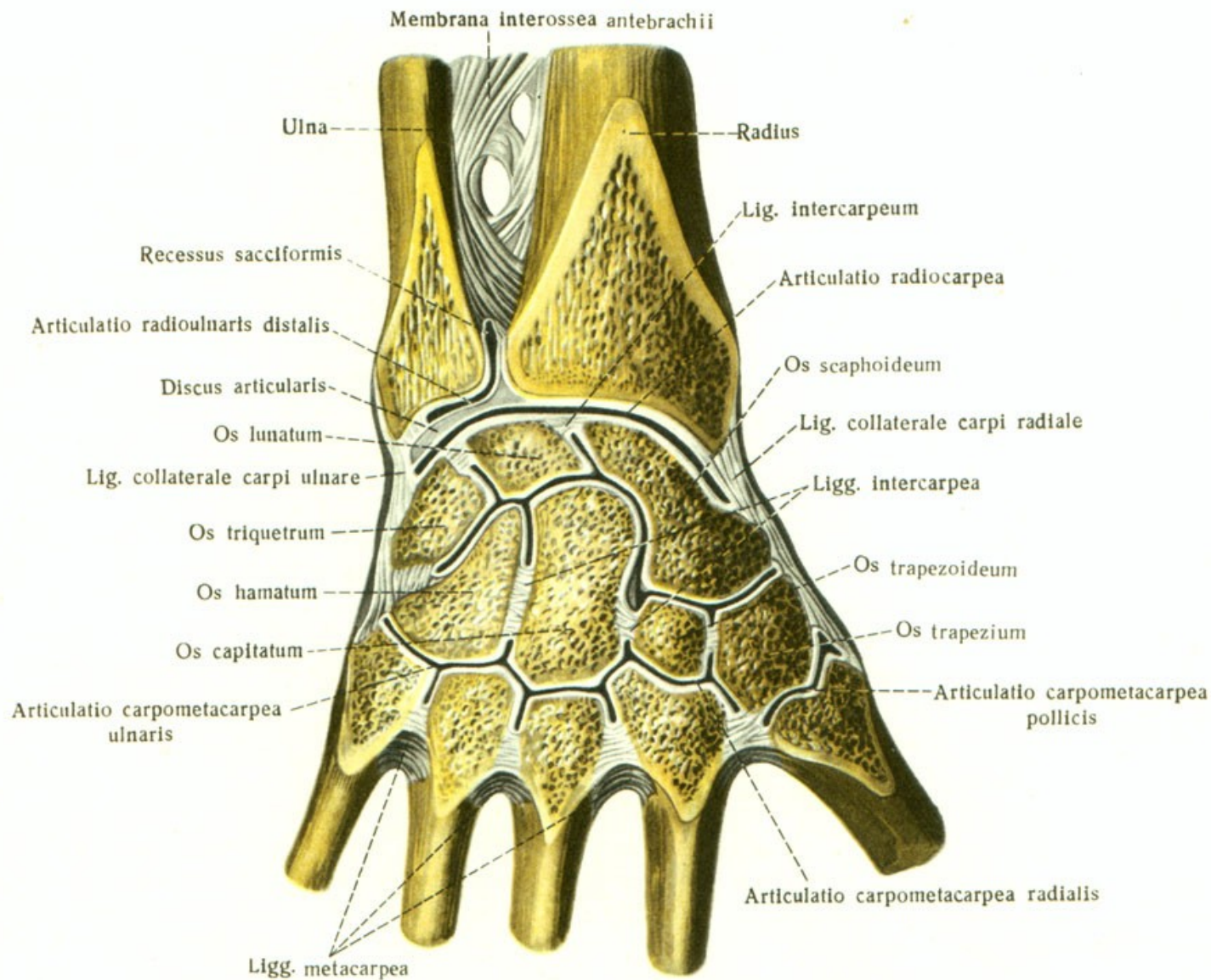


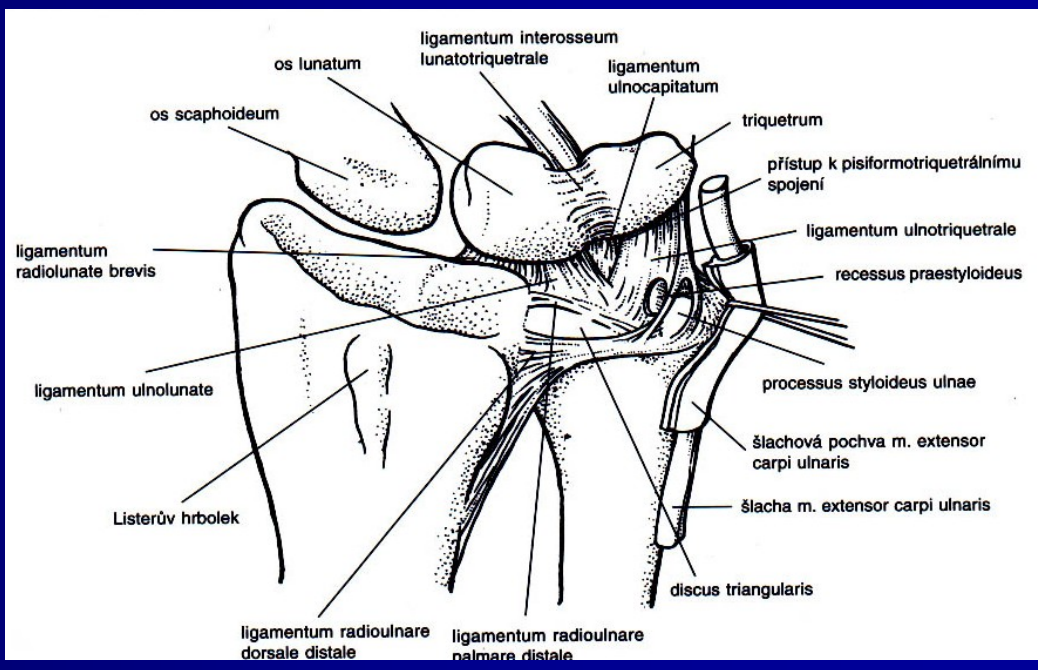
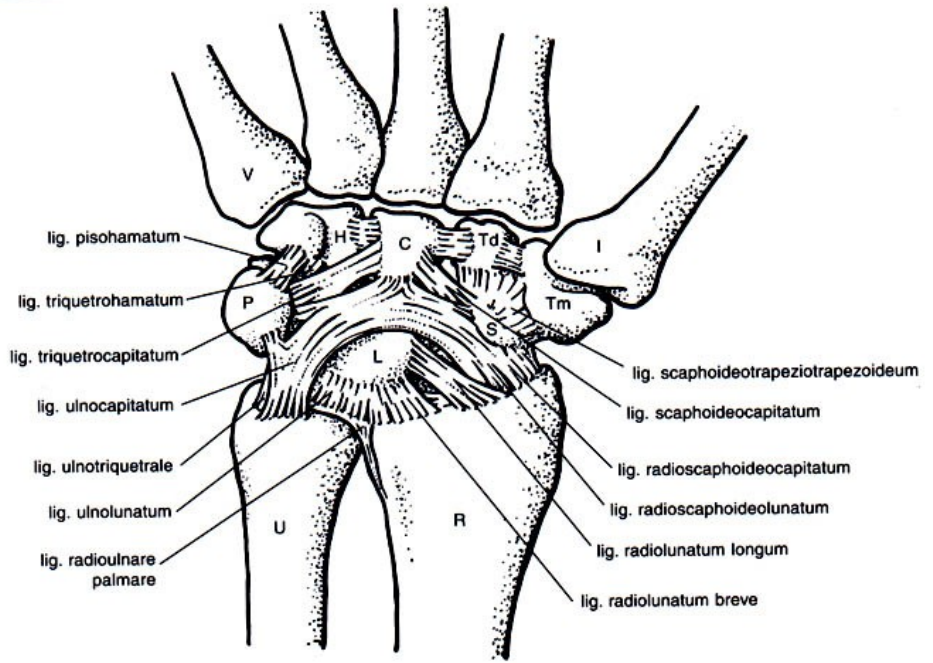
Rozkydal, Z. Nachtnebl L.

Skeleton

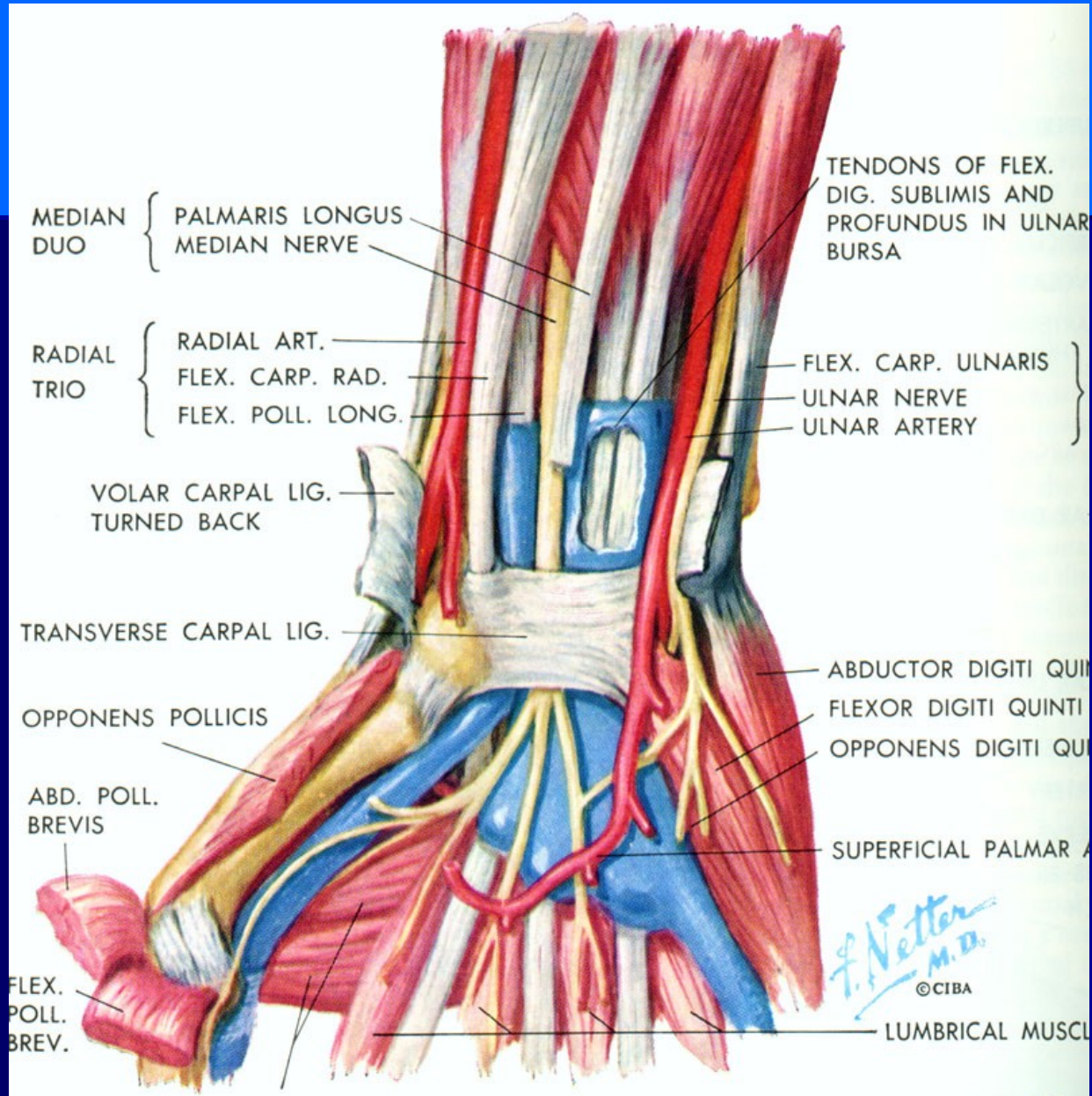


Wrist

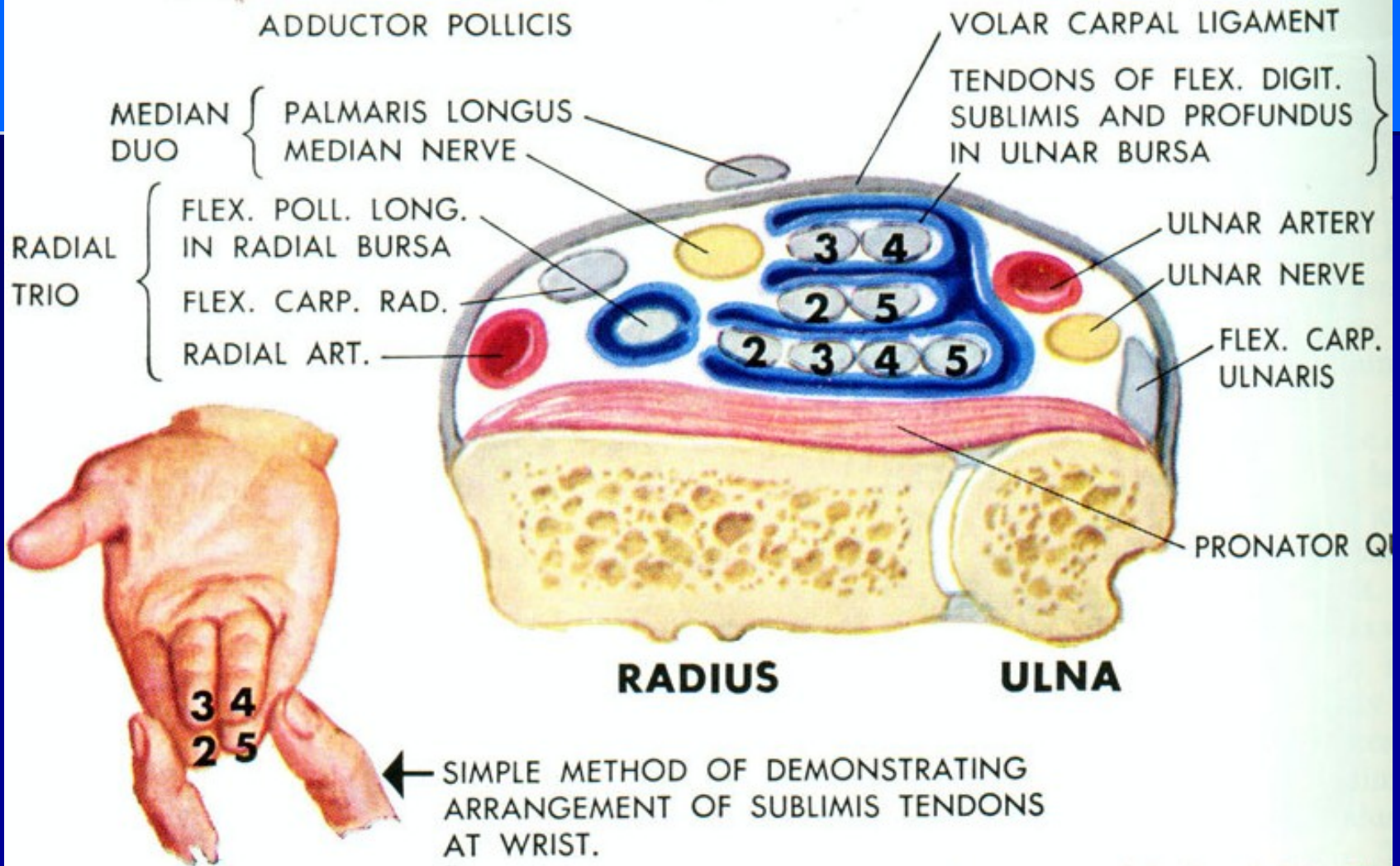




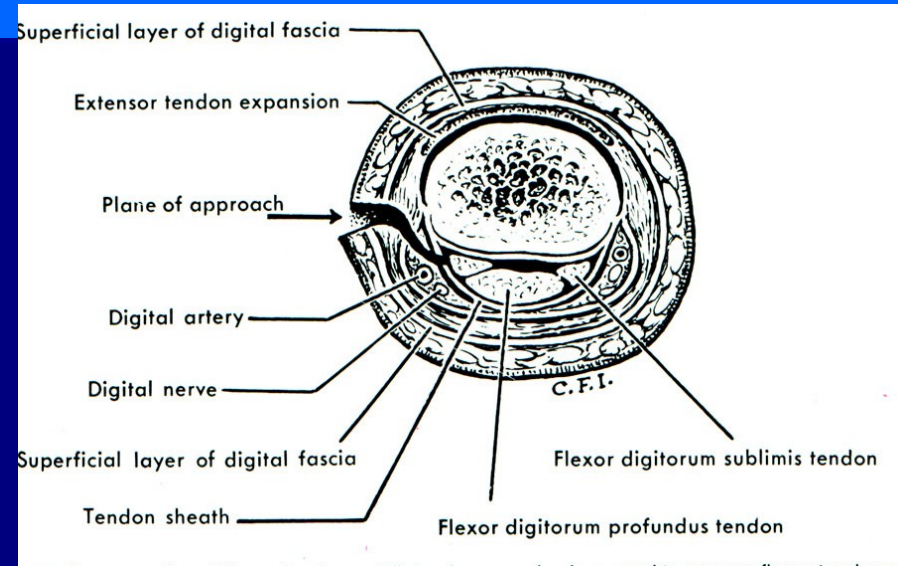
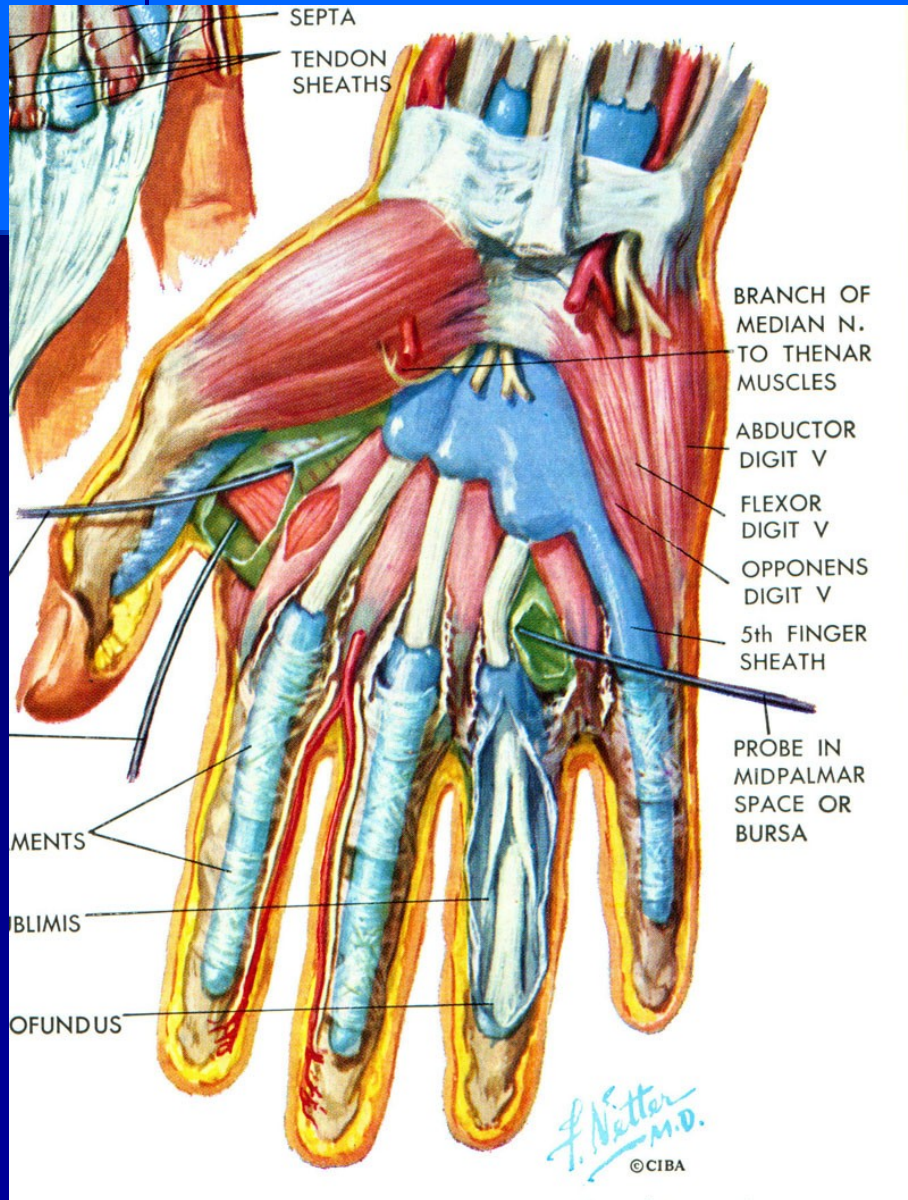
Anatomy



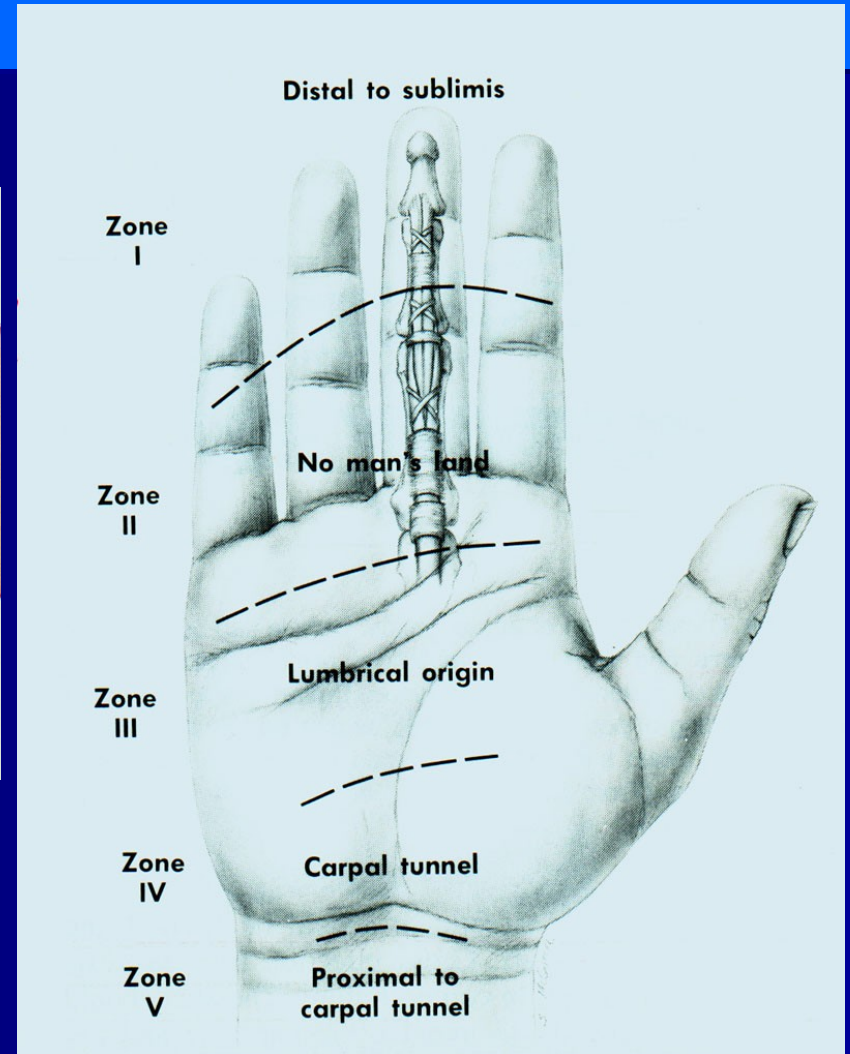
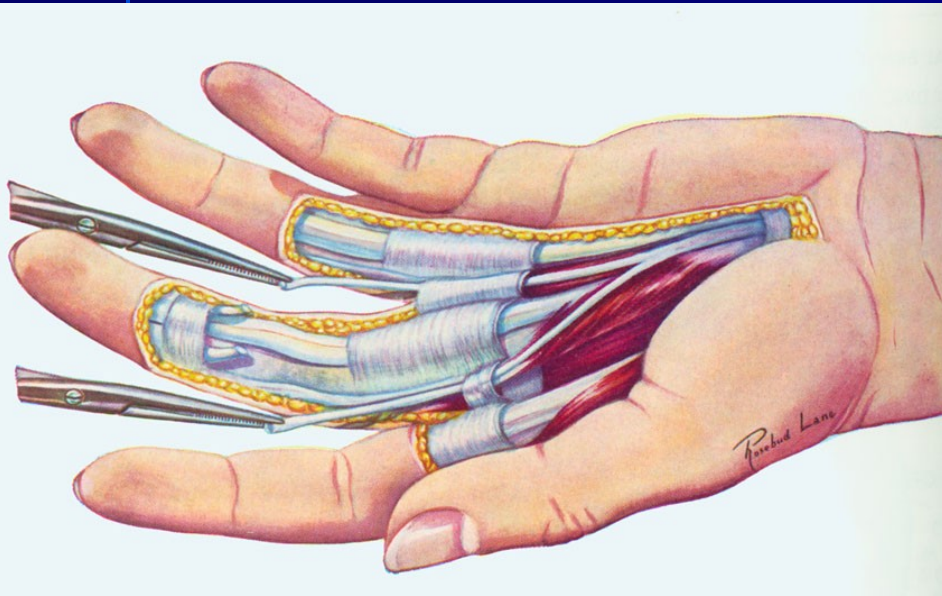
Anatomy



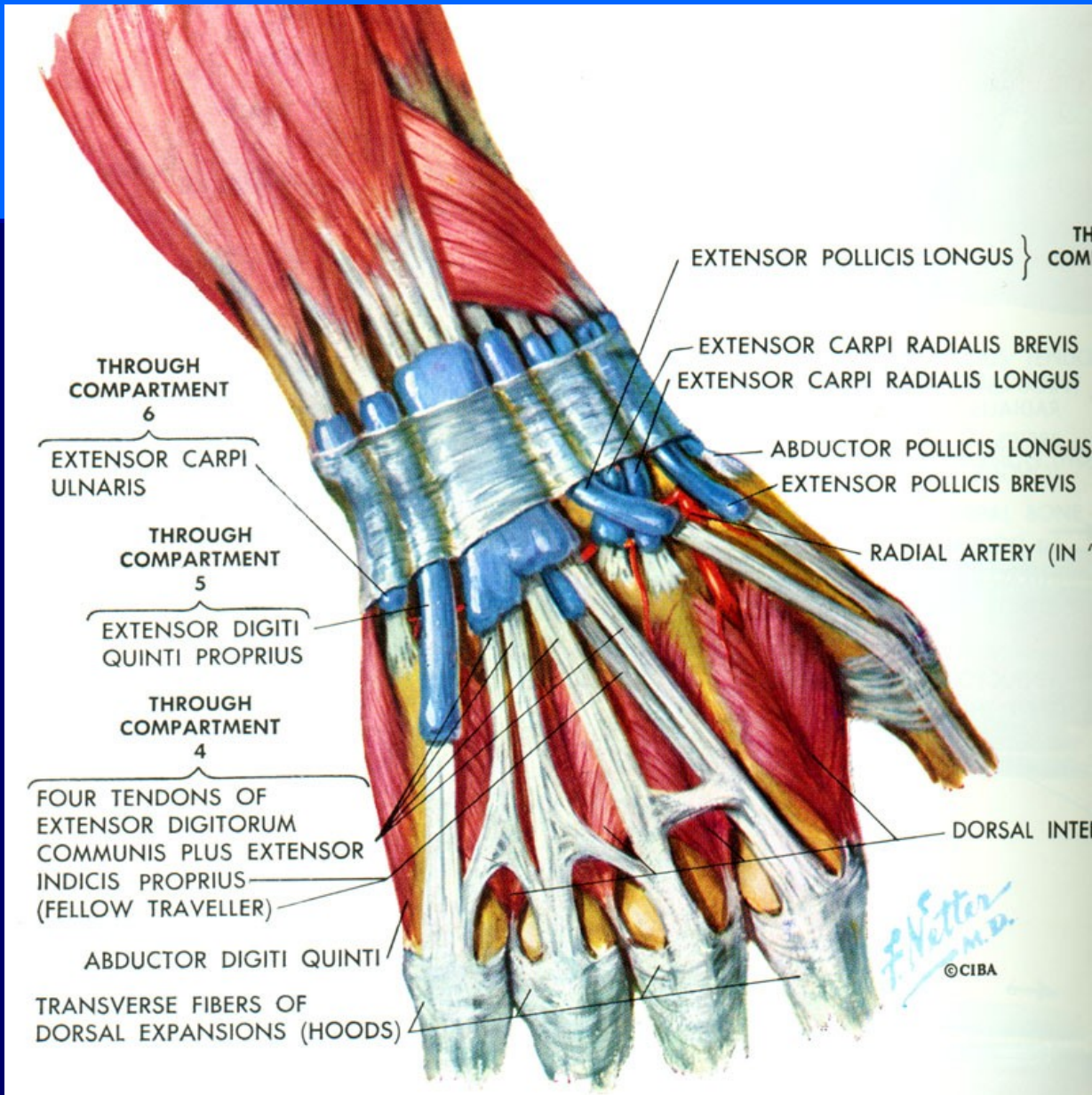
Anatomy



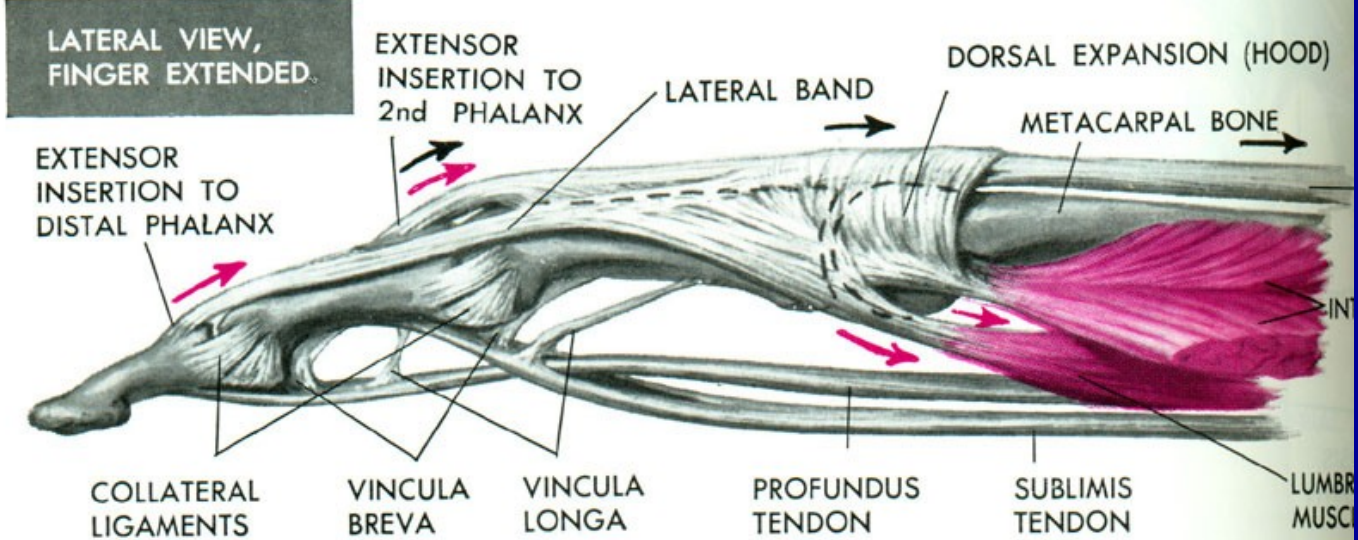
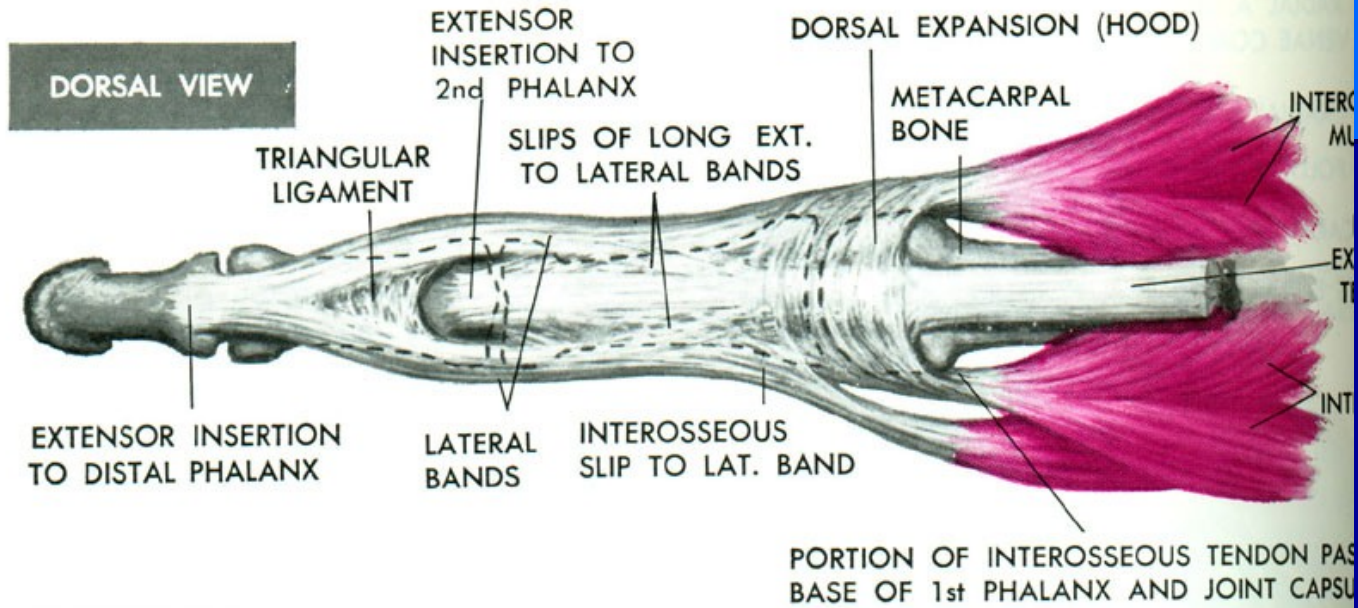
System of pulleys



Anatomy



Anatomy of extensor apparatus

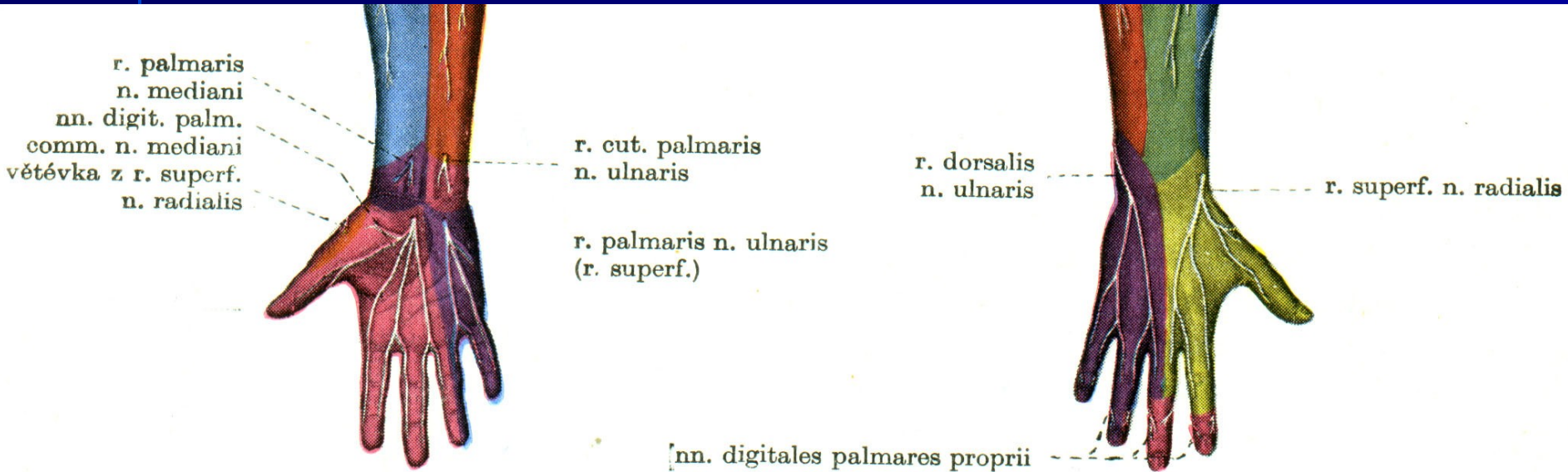


Extensor apparatus

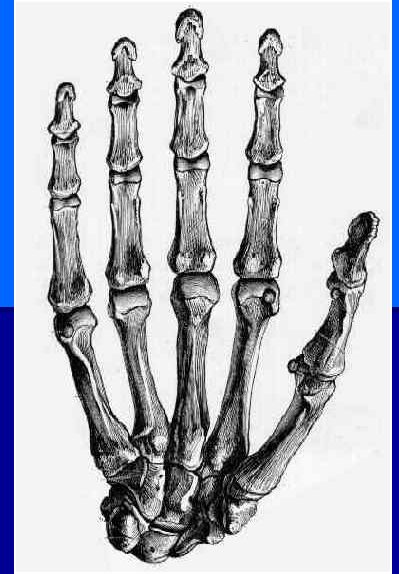


**Lateral bands from z mm. lumbricales
and mm. interossei**

Inervation of the hand



Function of the hand

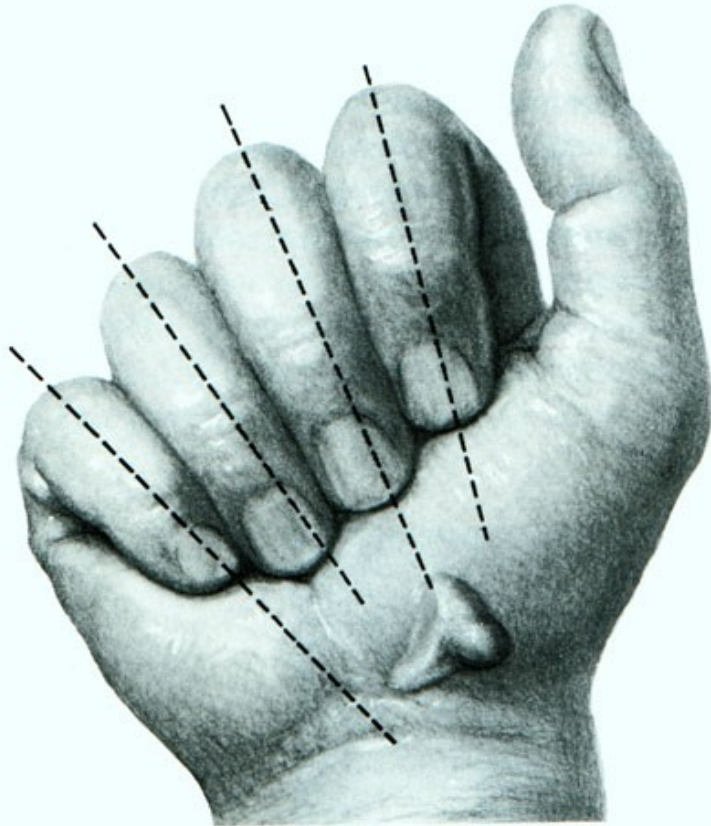


- **Hook**
- **Grip**
- **Fine movements**
 - intrinsic muscles
 - opposition of the thumb

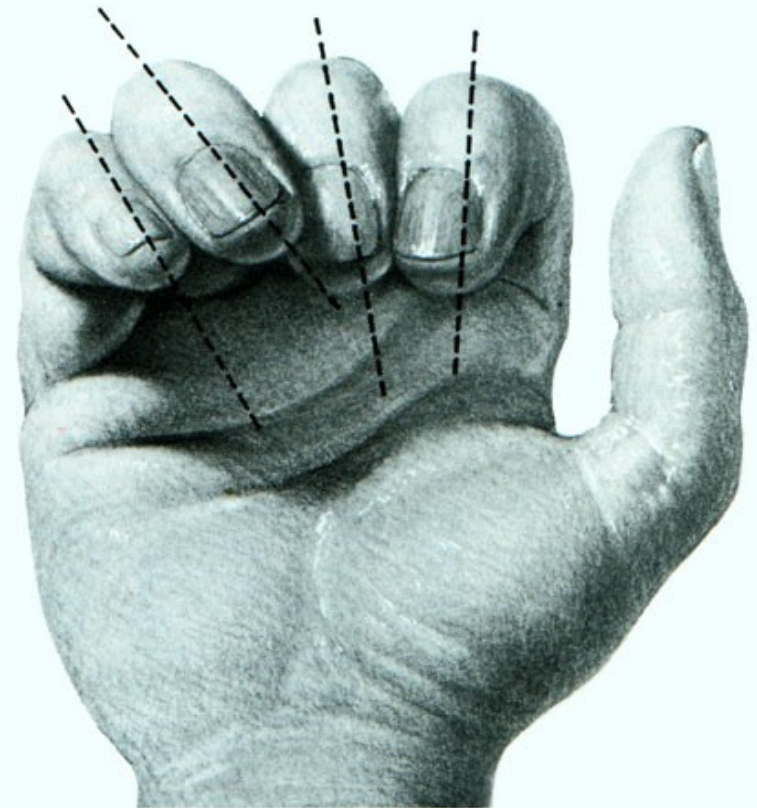Clinical examination

- **ROM**
- **Function of muscles**
- **Skin**
- **Trophicity**
- **Examination of C spine, shoulder, elbow**
- **R.A., systemic disorders**

Alignment of fingers, rotation

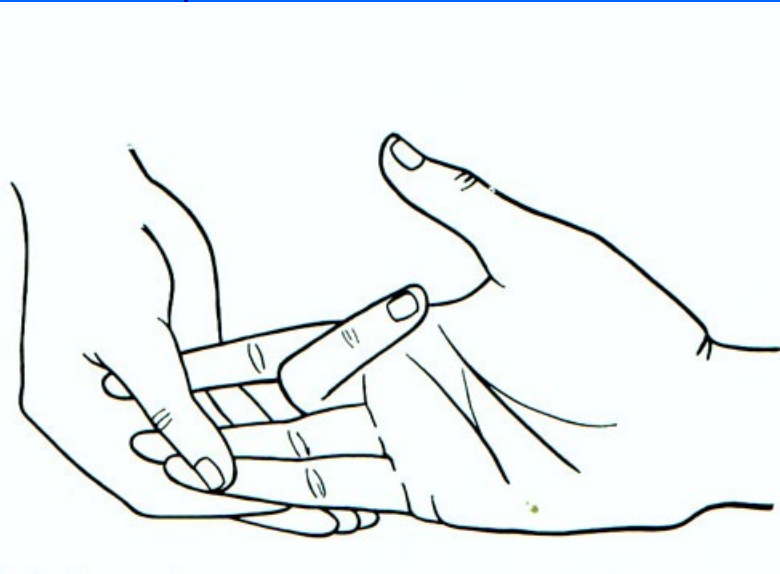


Normal flexion of fingers

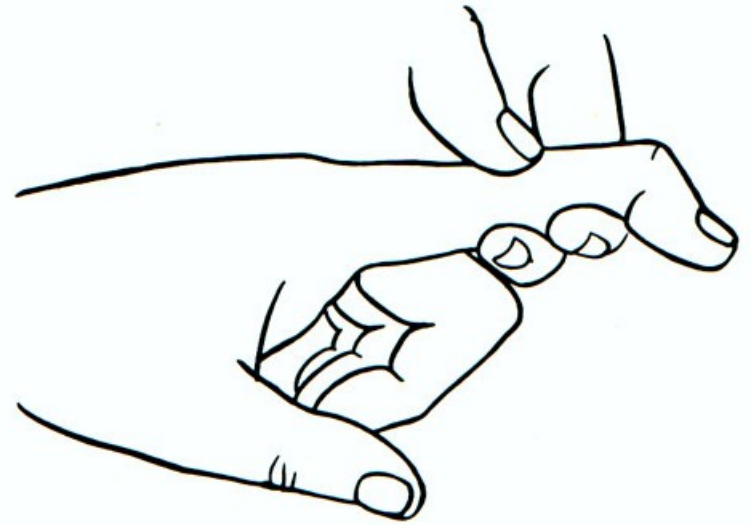


Flexion of fingers with
malrotation of ring finger

Test for flexors

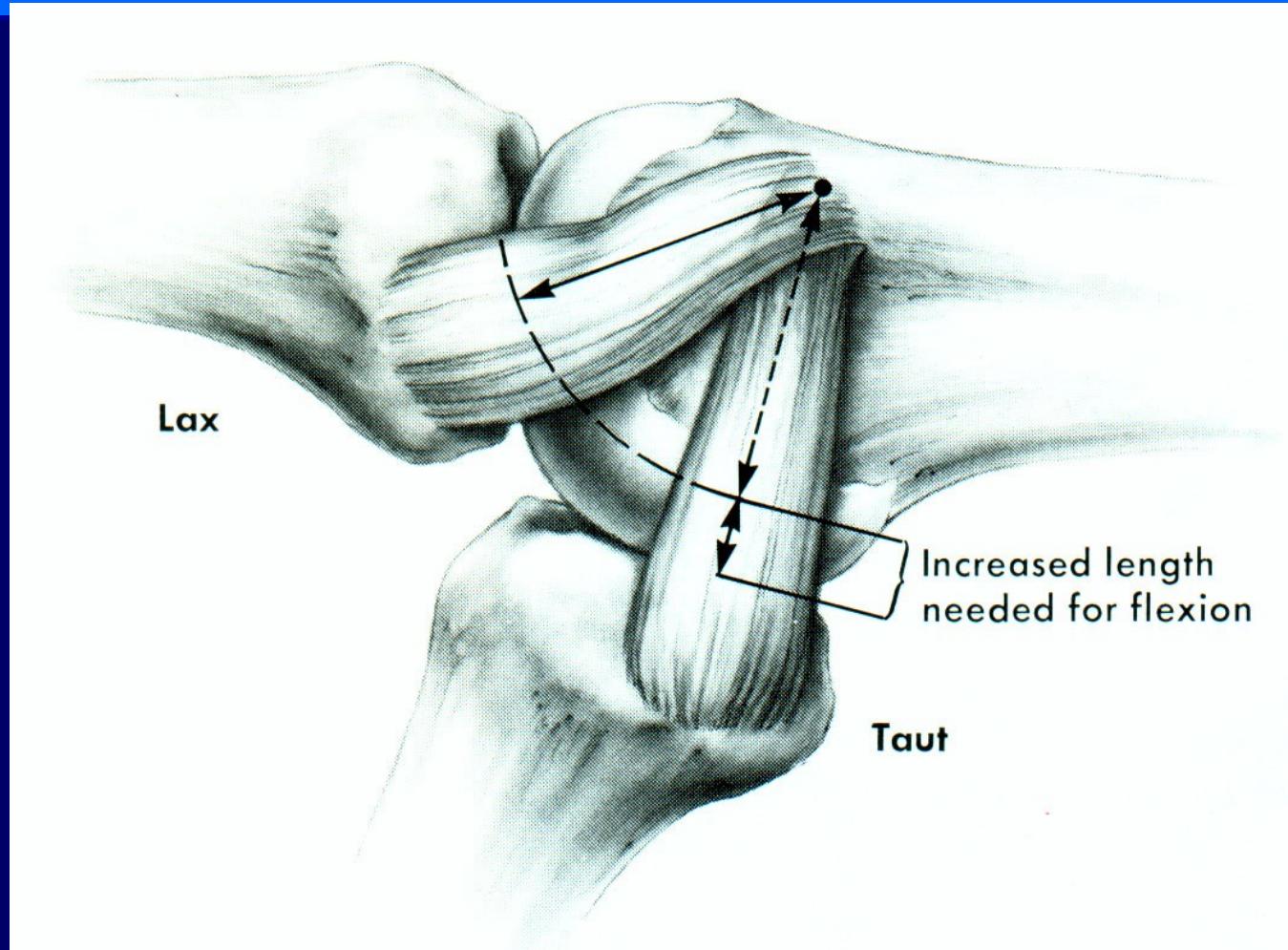


M. flexor dig. superficialis.



M. flexor dig. profundus.

Length of collateral ligaments of MP, PIP, DIP joints



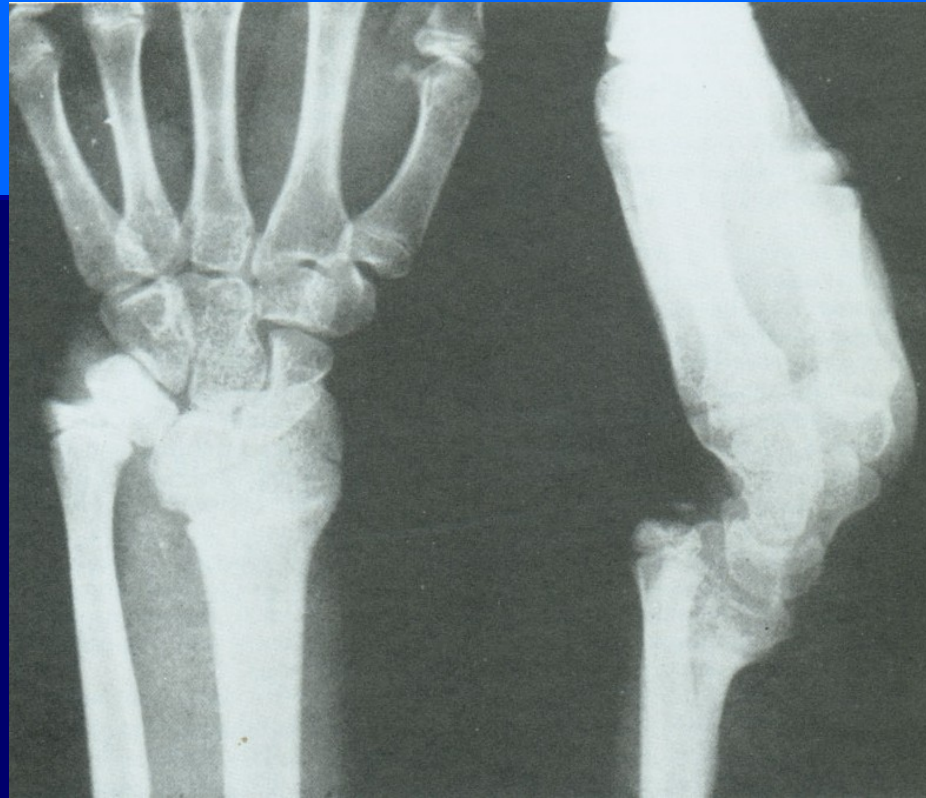
Congenital disorders

aplasia radii congenita

aplasia ulnae congenita

Madelung deformity

Madelung deformity



- Short distal radius, volar bending
- Bajonet position of the hand
subluxation of carpal bones

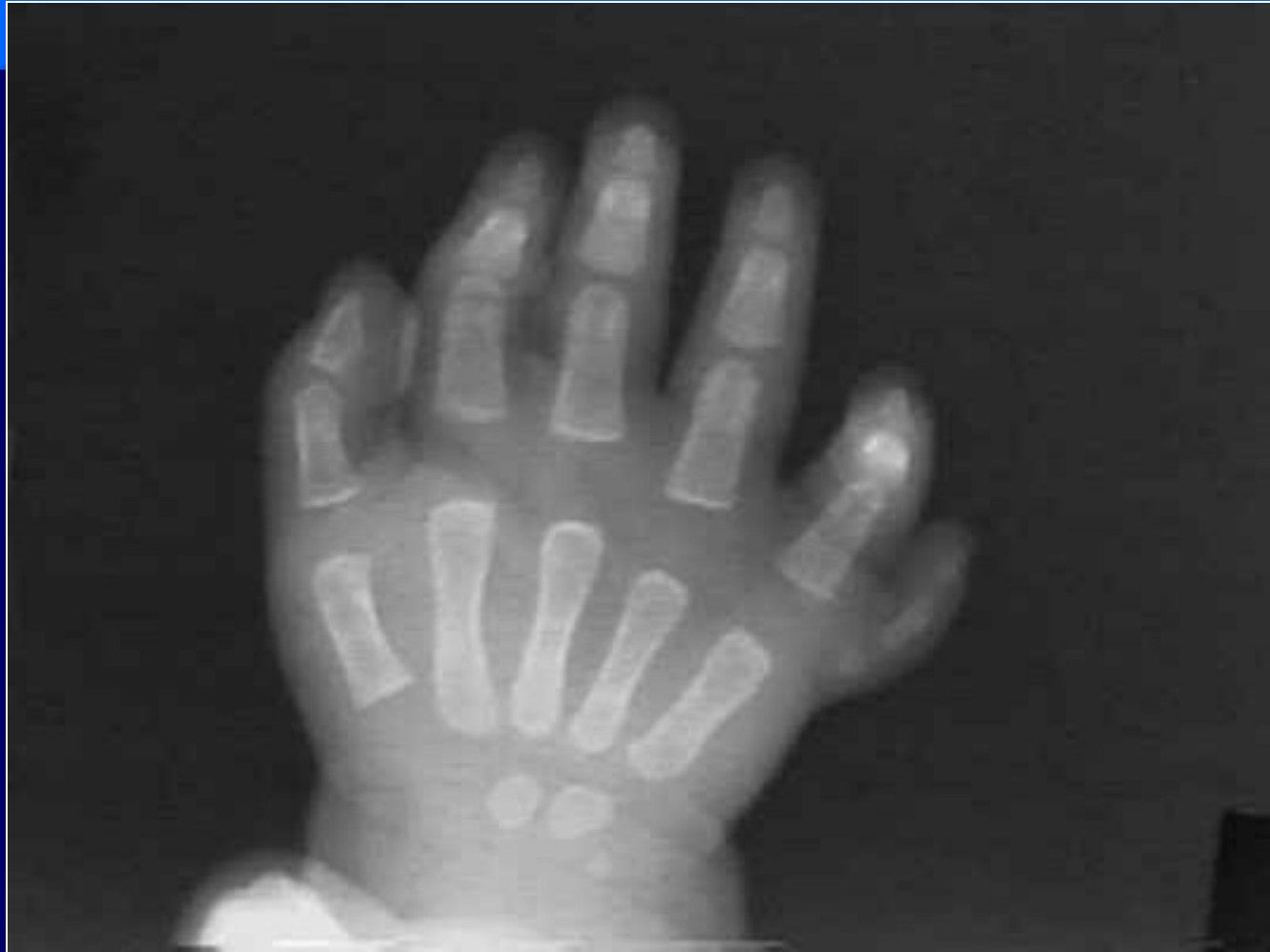Therapy- shortening of ulna, corrective OT of radius

Congenital disorders

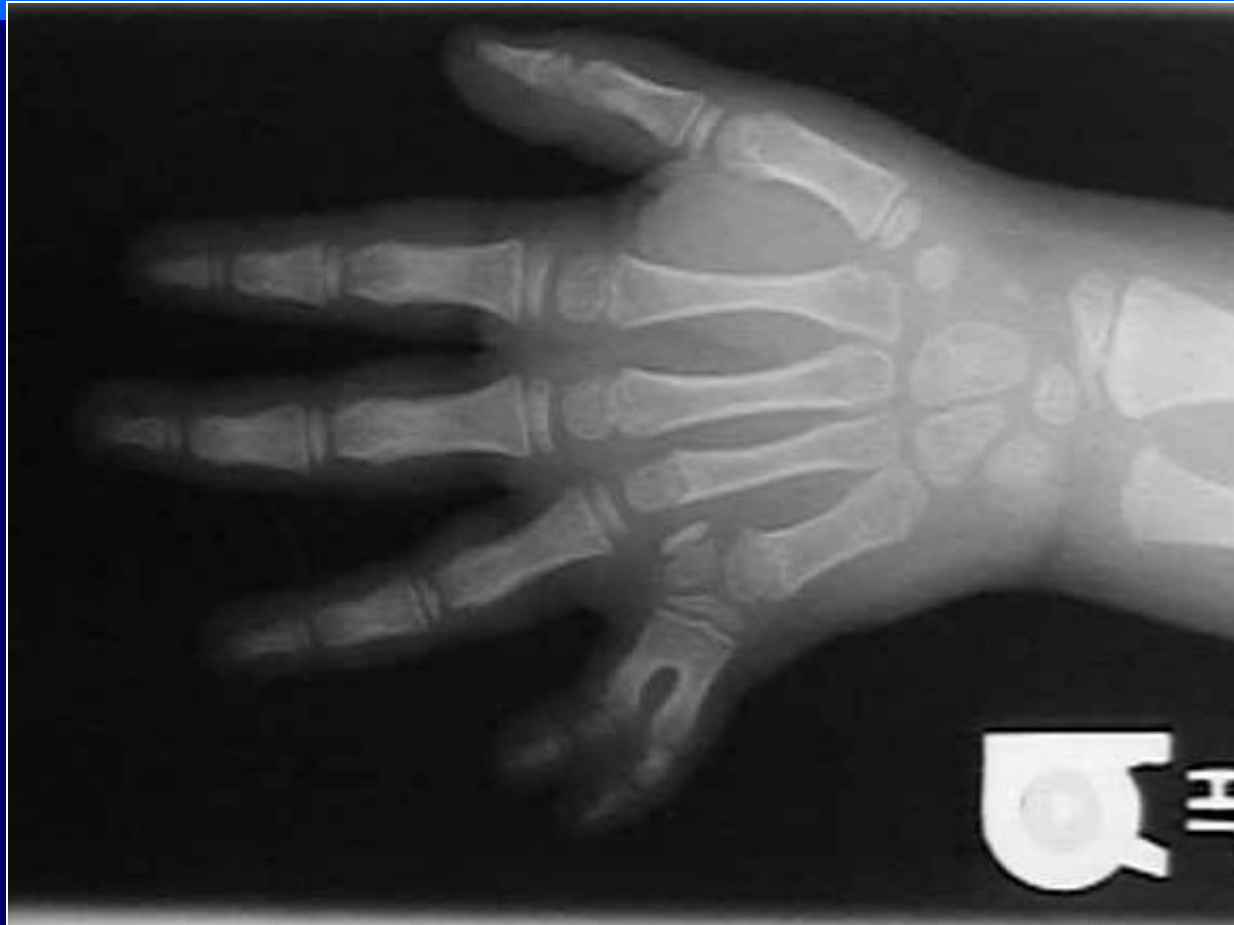■ **Types**

- adaktylia
- oligodaktylia ...
- brachydaktylia ...
- polydaktylia ...
- syndaktylia ...
- clinodaktylia ...
- camptodaktylia ... flexion contracture
of 5. finger
-

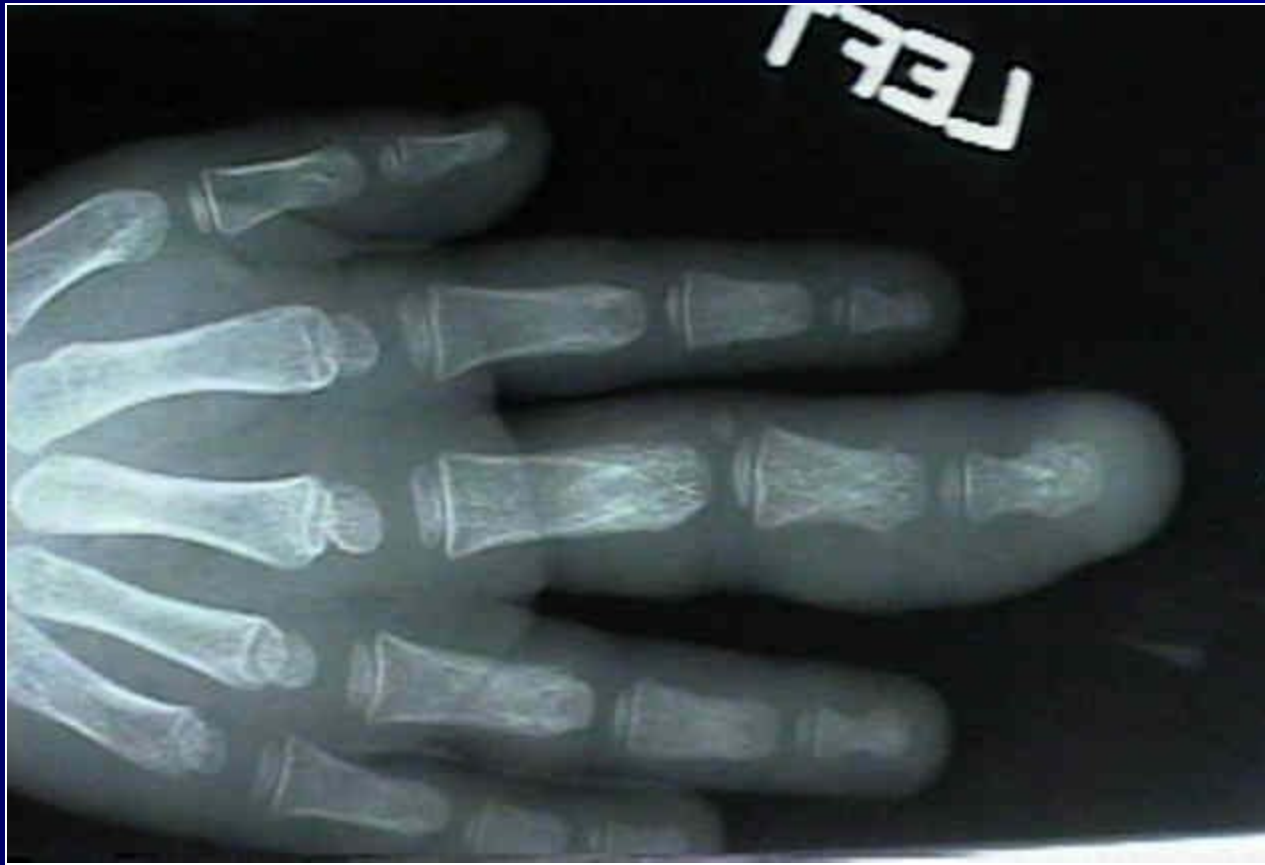Polydaktylia



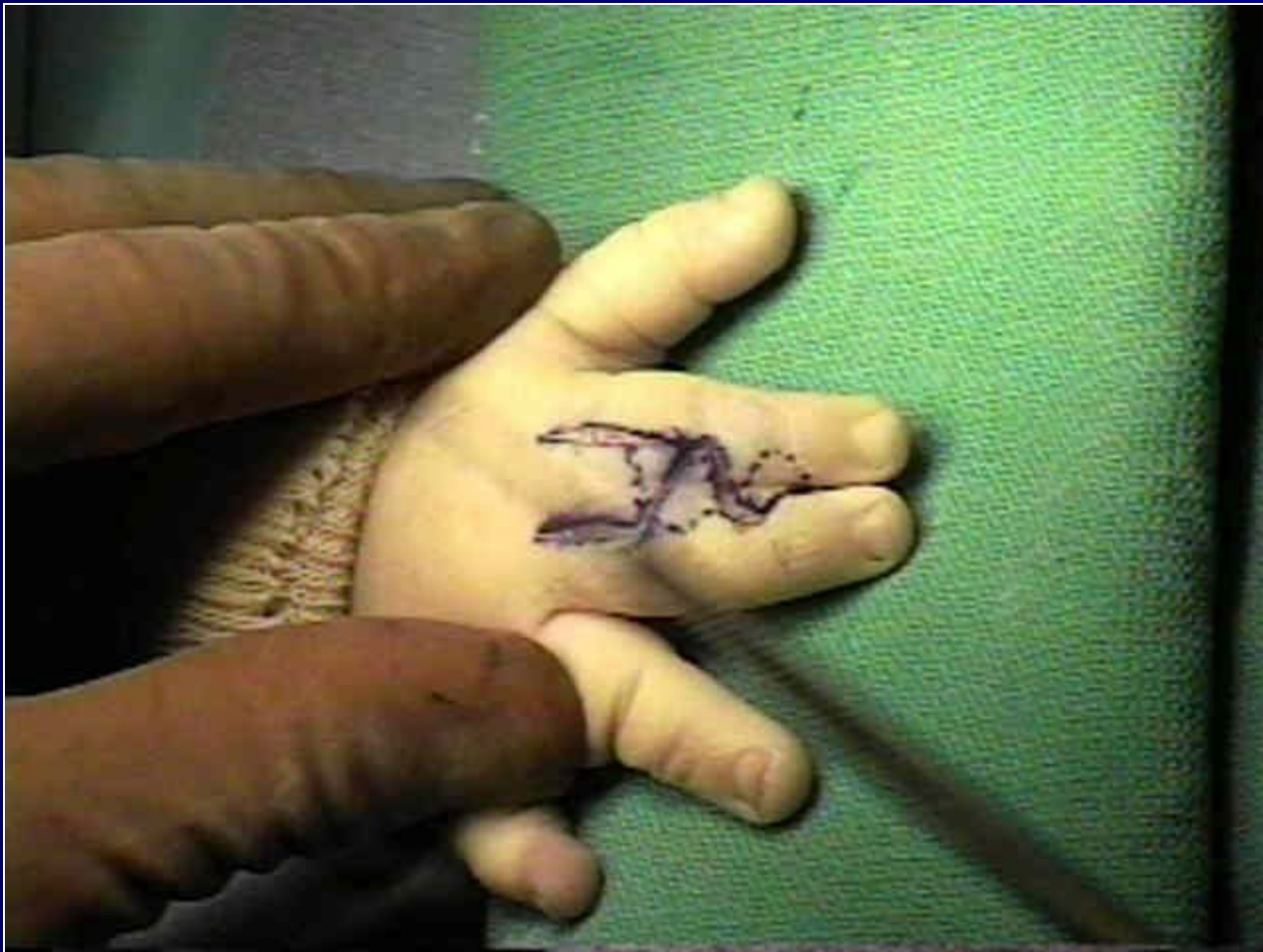Polydaktylia



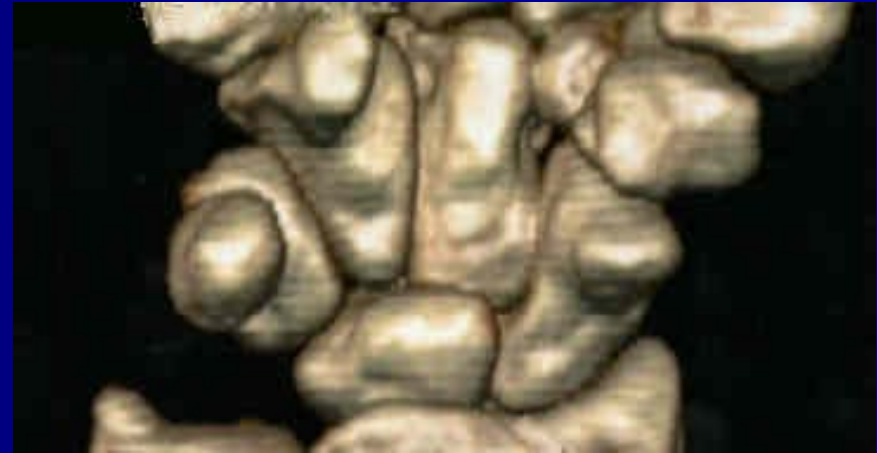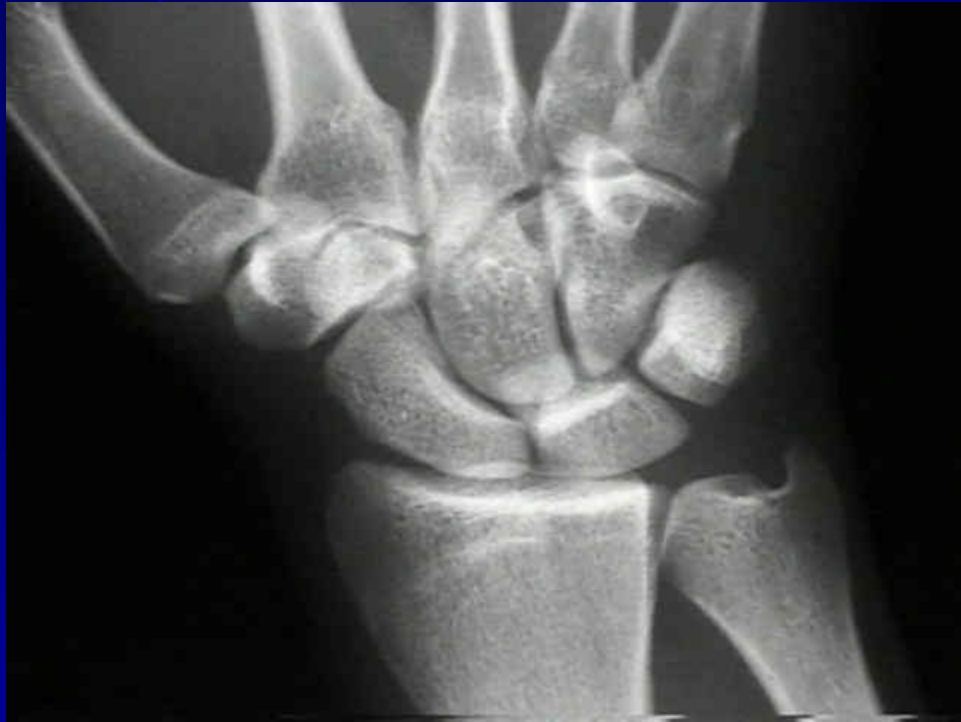Makrodaktylia



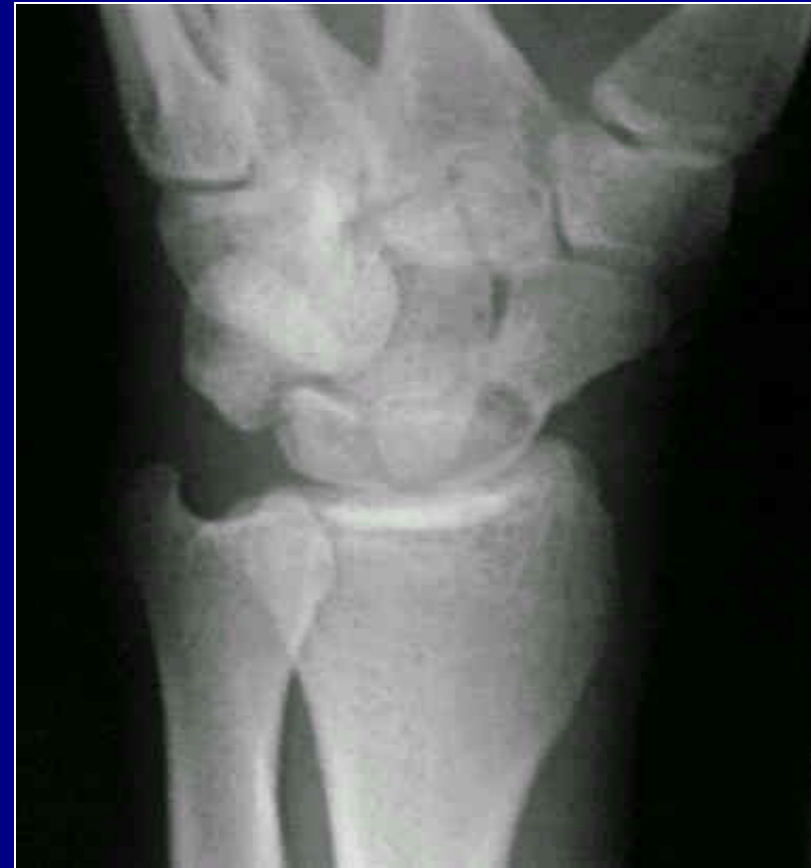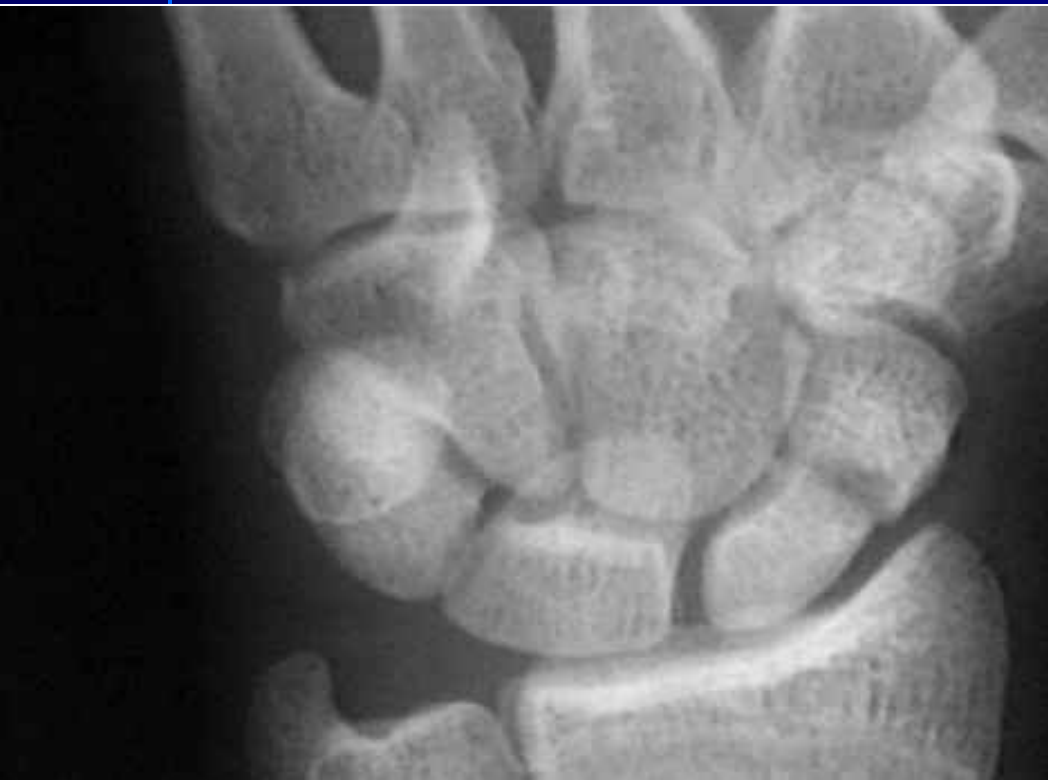Syndaktylia



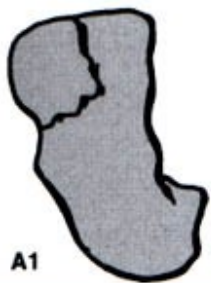X- ray of the wrist joint



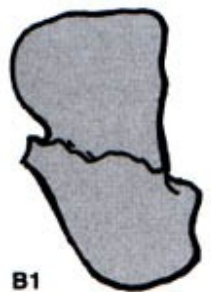Fracture of scaphoid bone



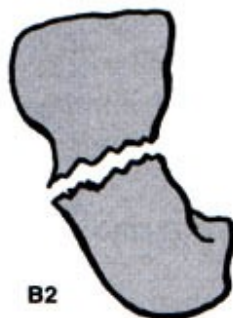typ A stabilní zlomeniny



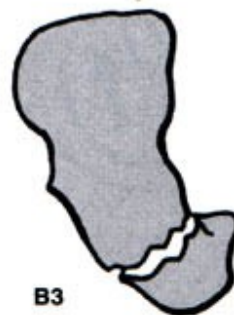typ B nestabilní zlomeniny



distální horizontálně
šikmá zlomenina



zlomenina těla

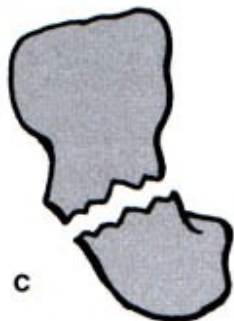

zlomenina
proximálního pólu

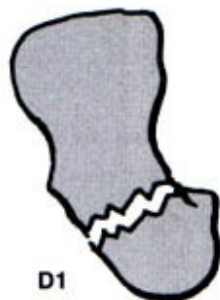

transscaphoideální perilunární
dislokace karpu

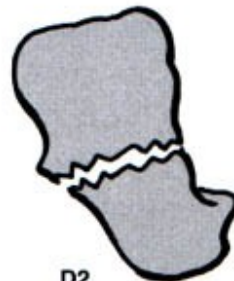typ C opožděné hojení



typ D trvalé kostní nezhojení

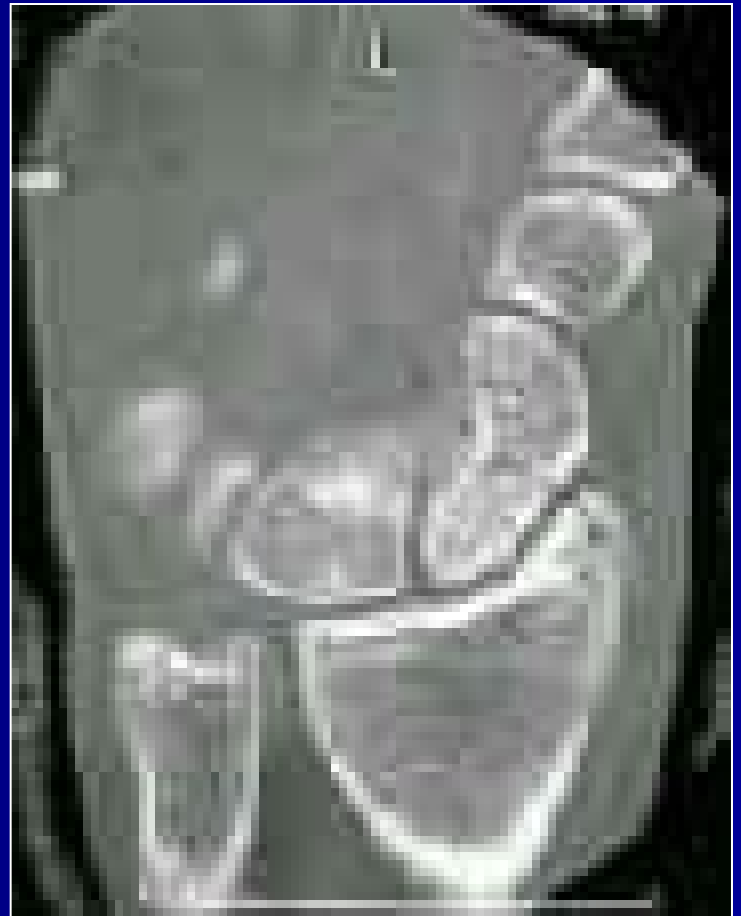
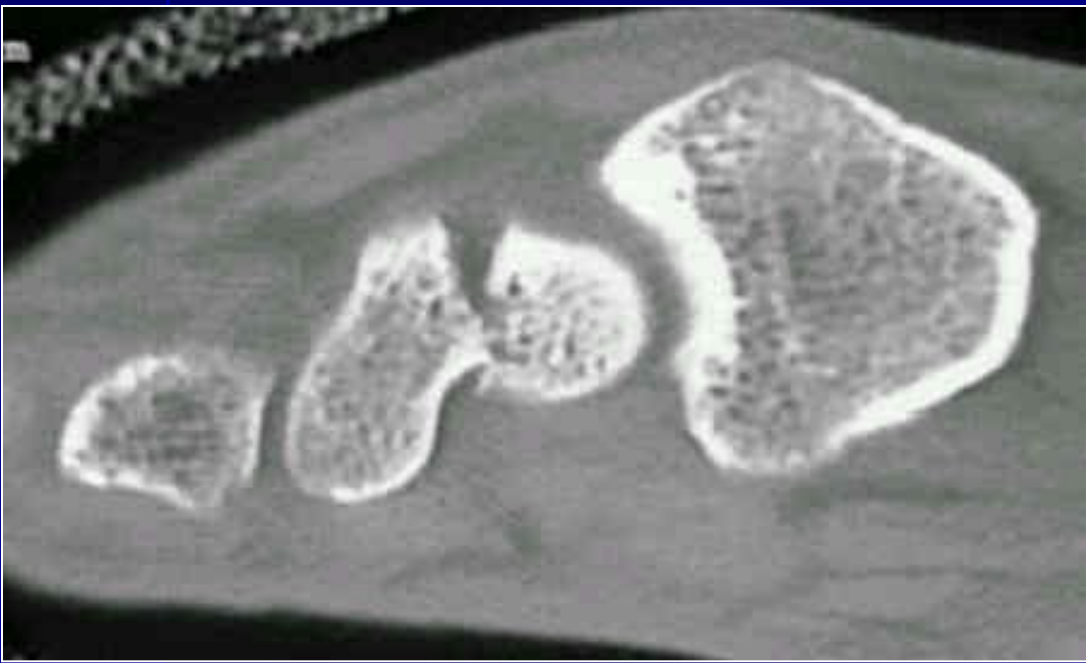
zhojení vazivem



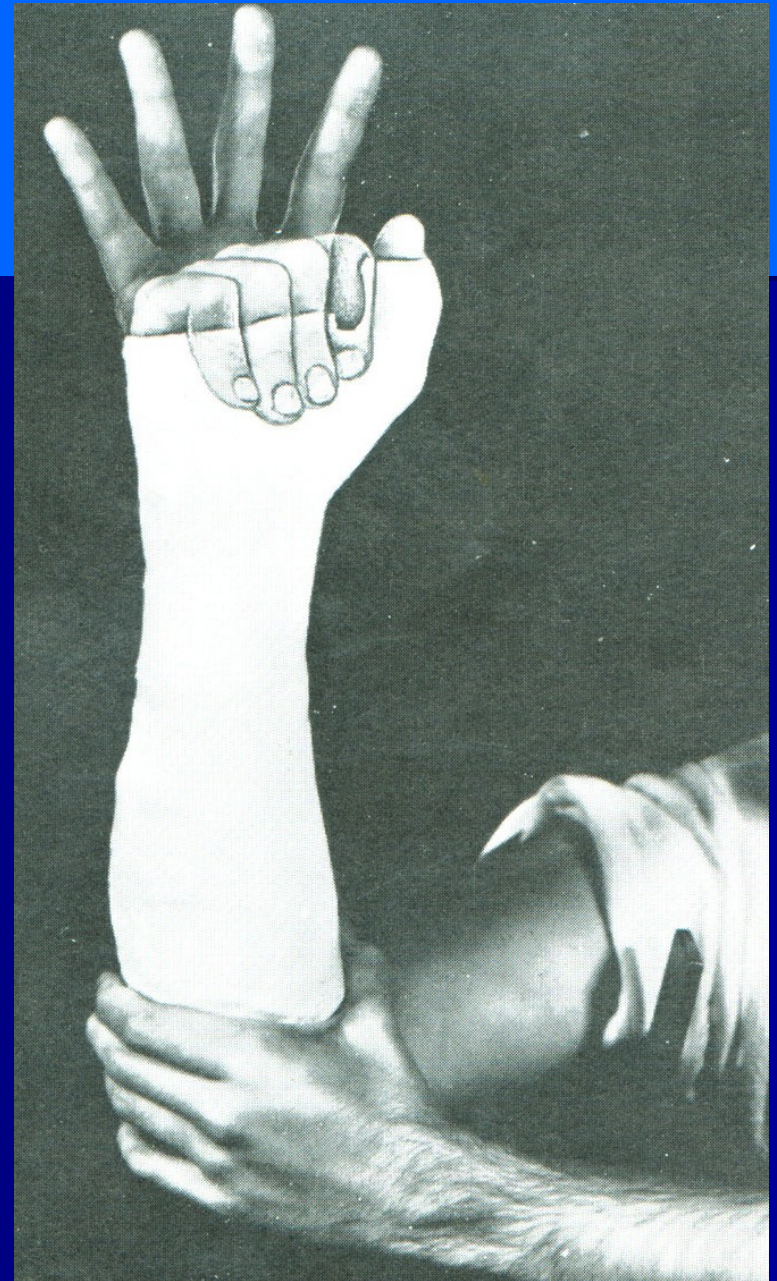pseudoartróza

CT

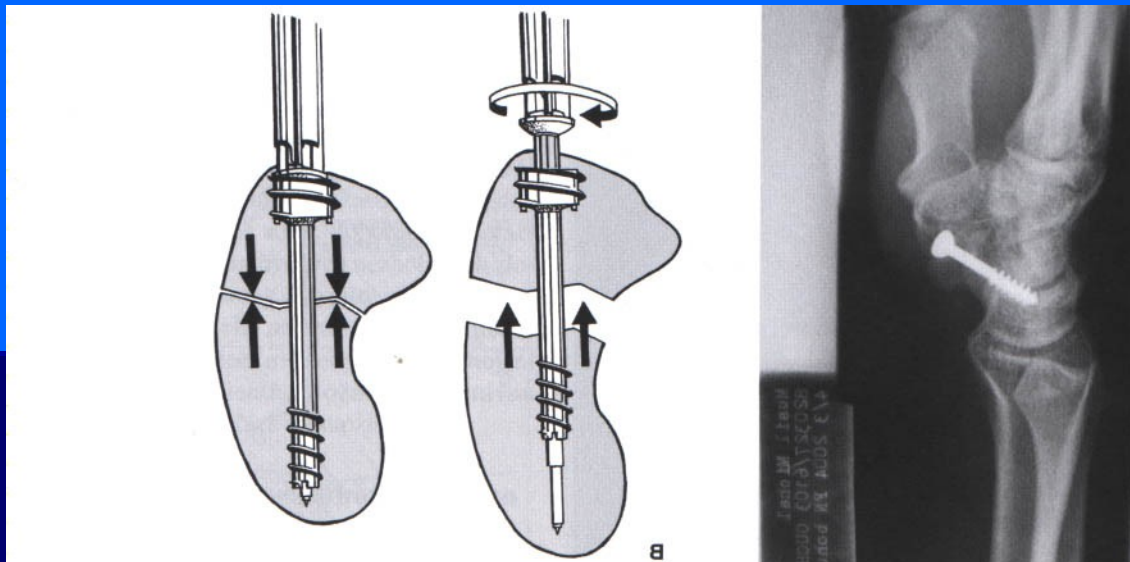


Conservative treatment

Plaster of Paris 8-12 weeks



Operative treatment



typ A stabilní zlomeniny

A1 A2

typ B nestabilní zlomeniny

B1 B2 B3 B4

distální horizontálně
šikmá zlomenina

zlomenina těla

zlomenina
proximálního pólu

transcapoidéální perilunární
dislokace karpu

typ C opožděné hojení

c

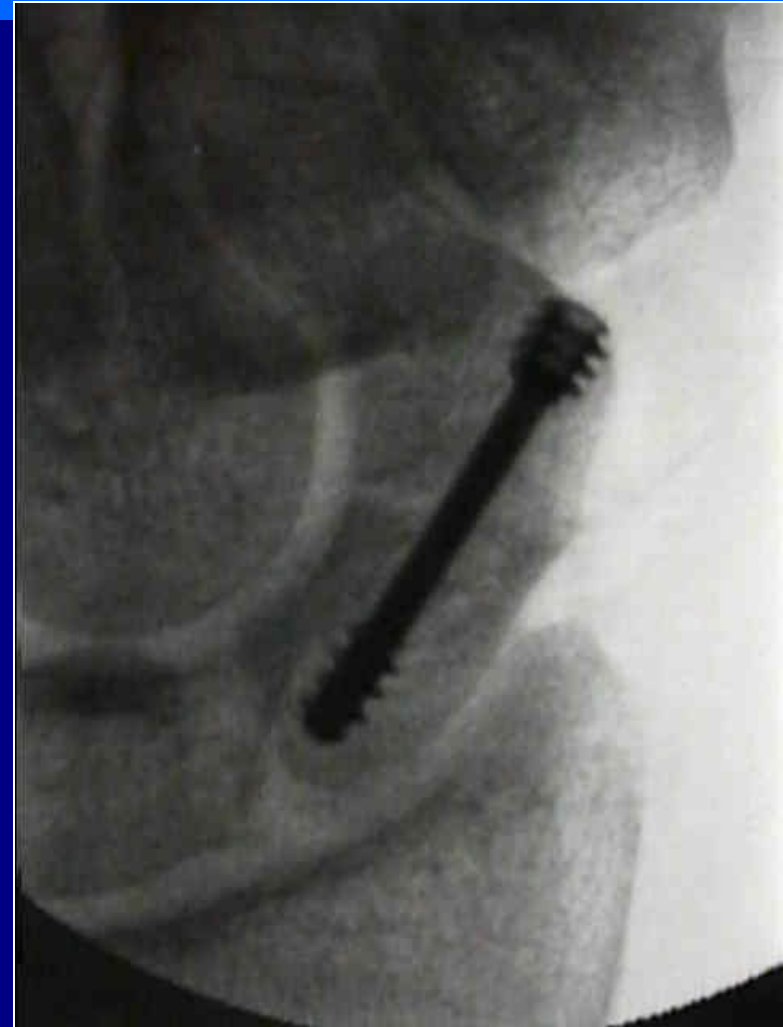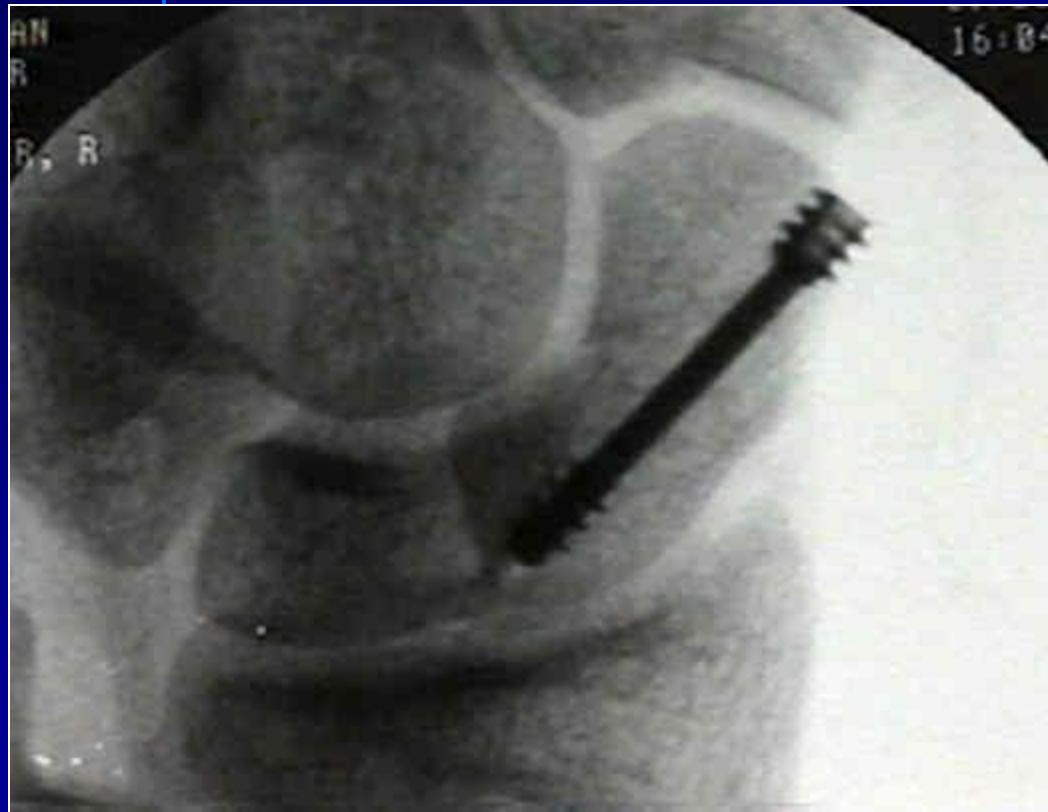typ D trvalé kostní nezhojení

D1 D2

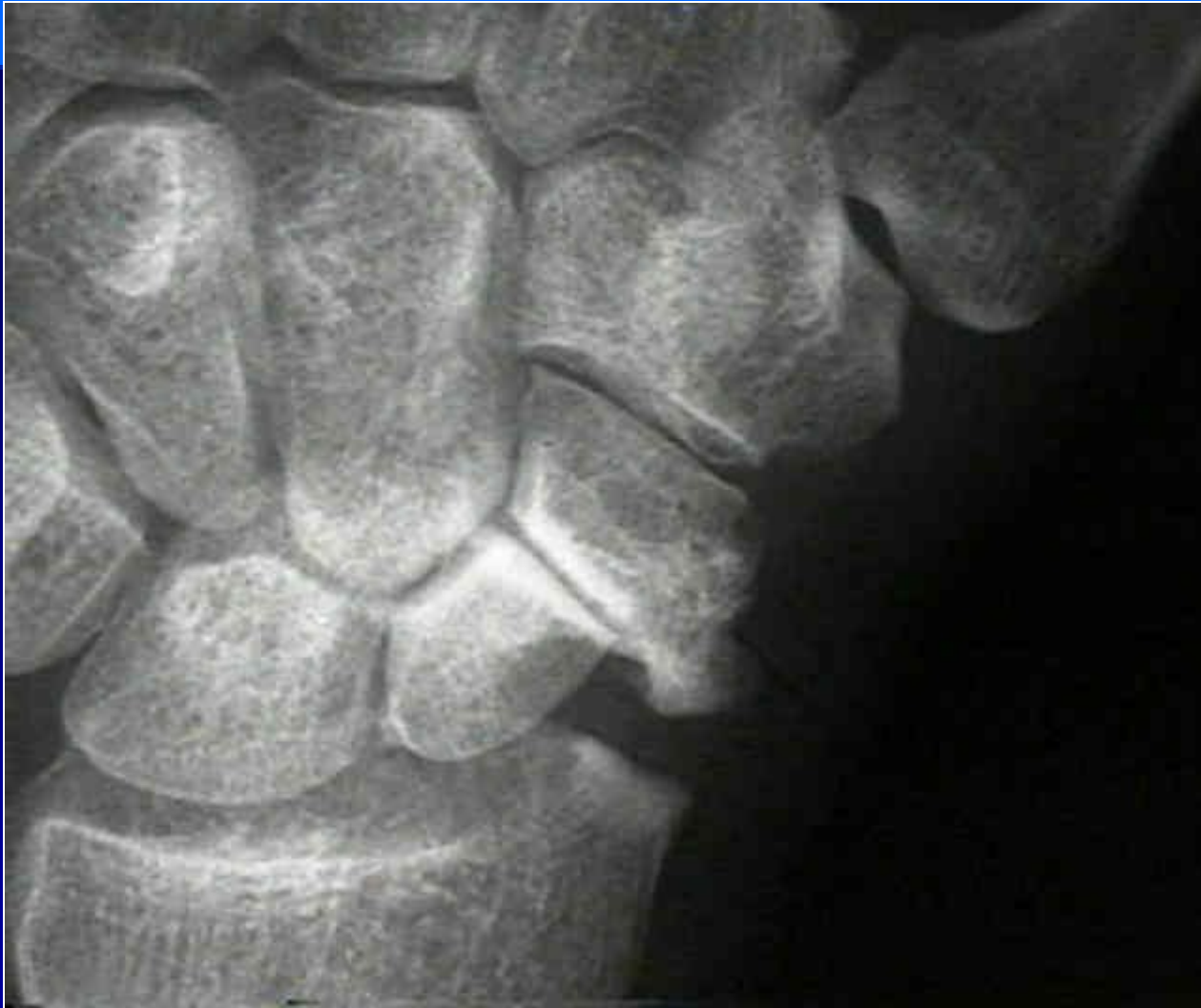zhojení vazivem

pseudoartróza

Herbert screw

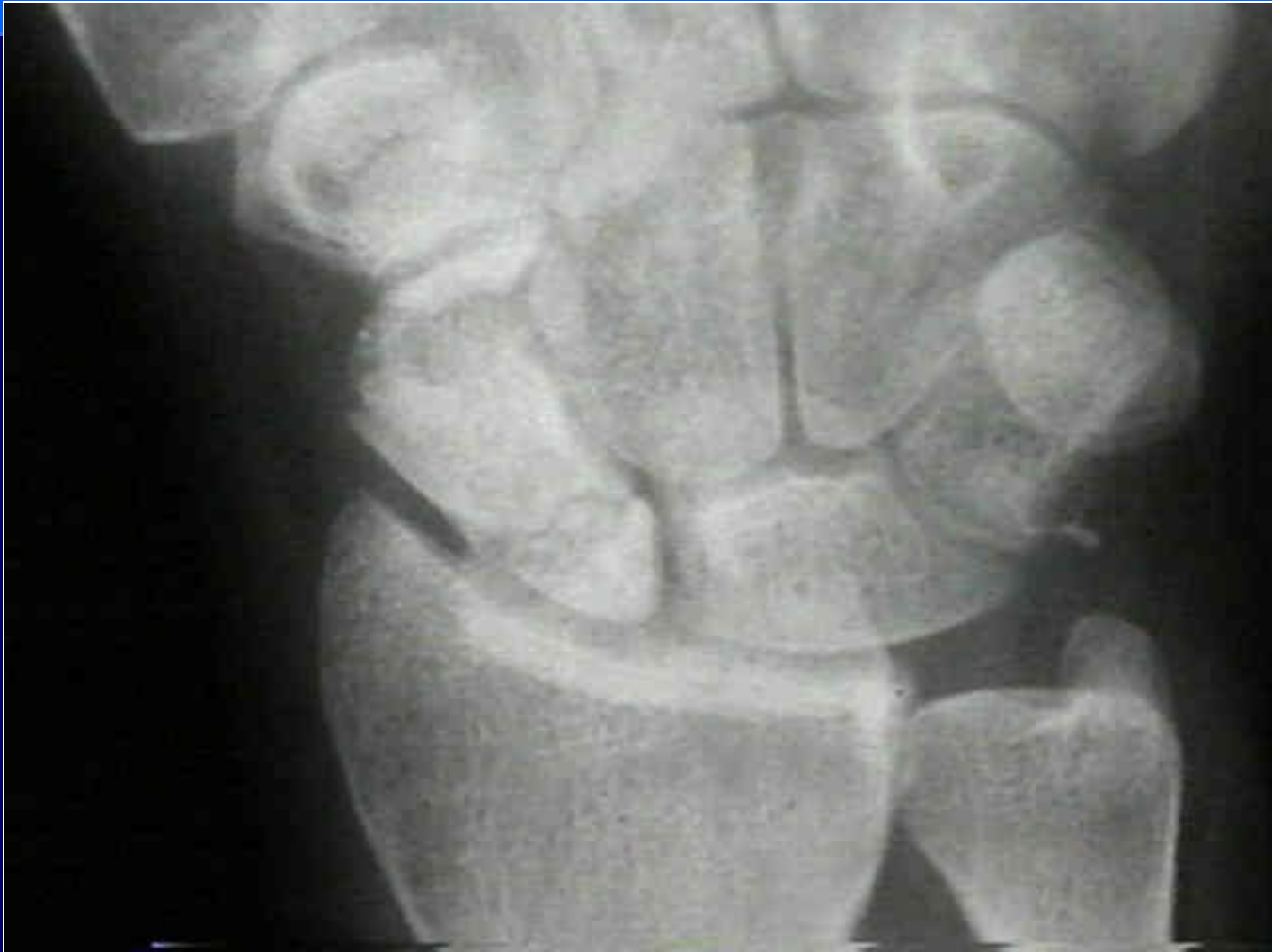

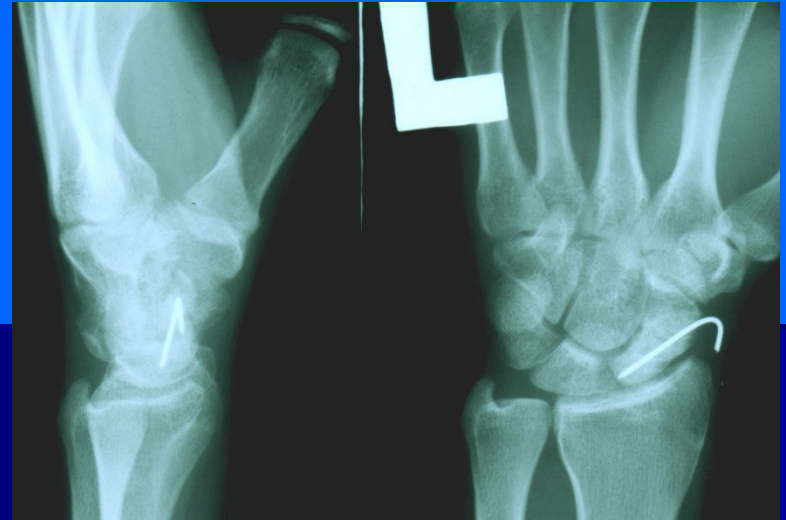
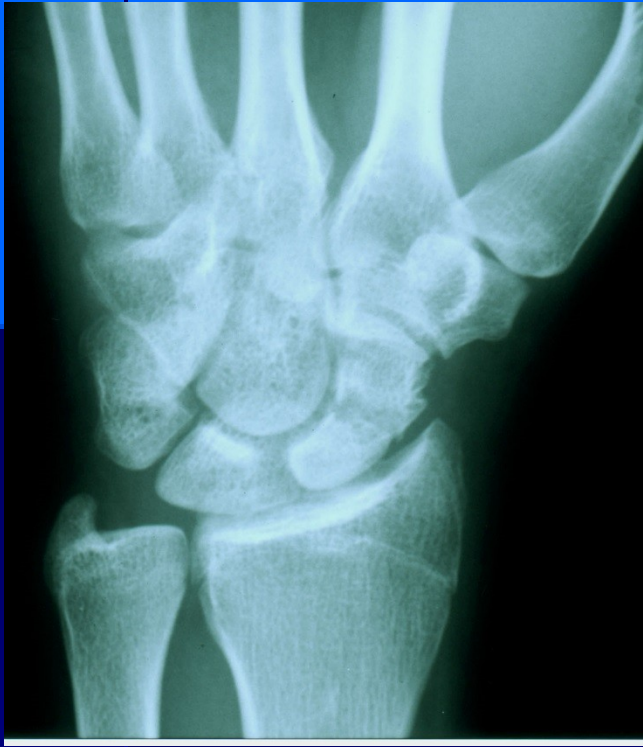Pseudoarthrosis of scaphoid bone



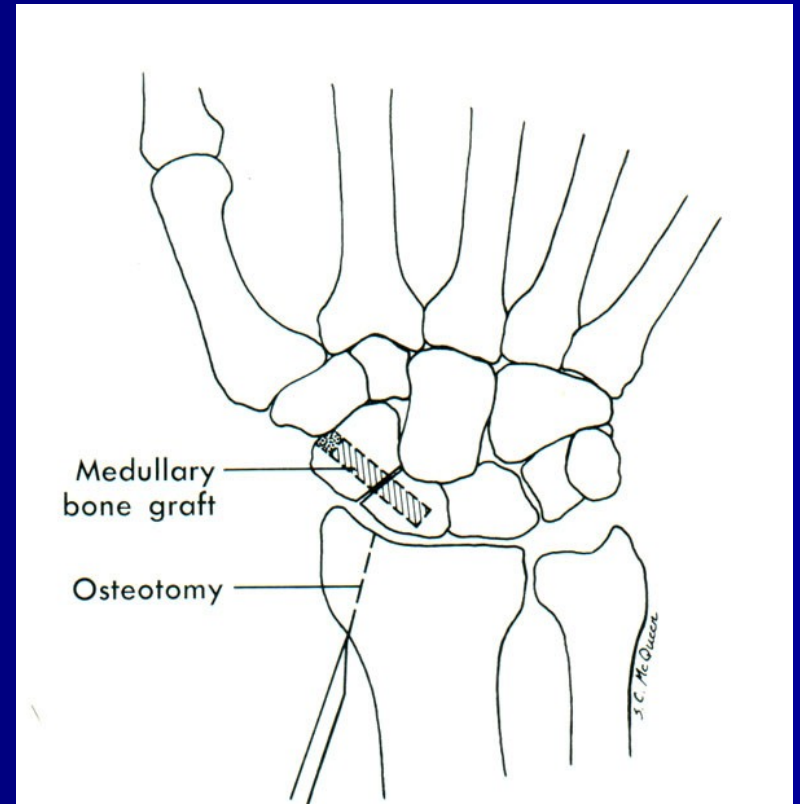
- X-ray

Avascular necrosis of scaphoid bone

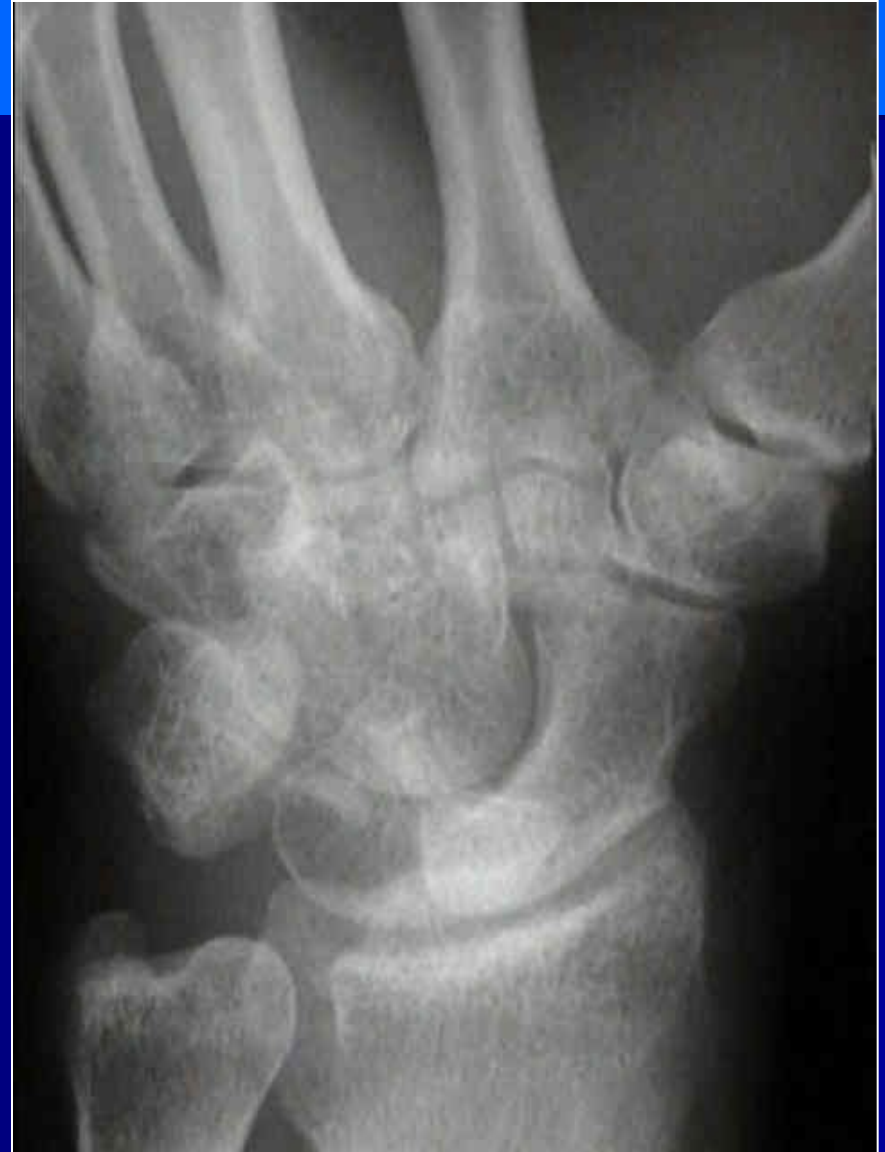
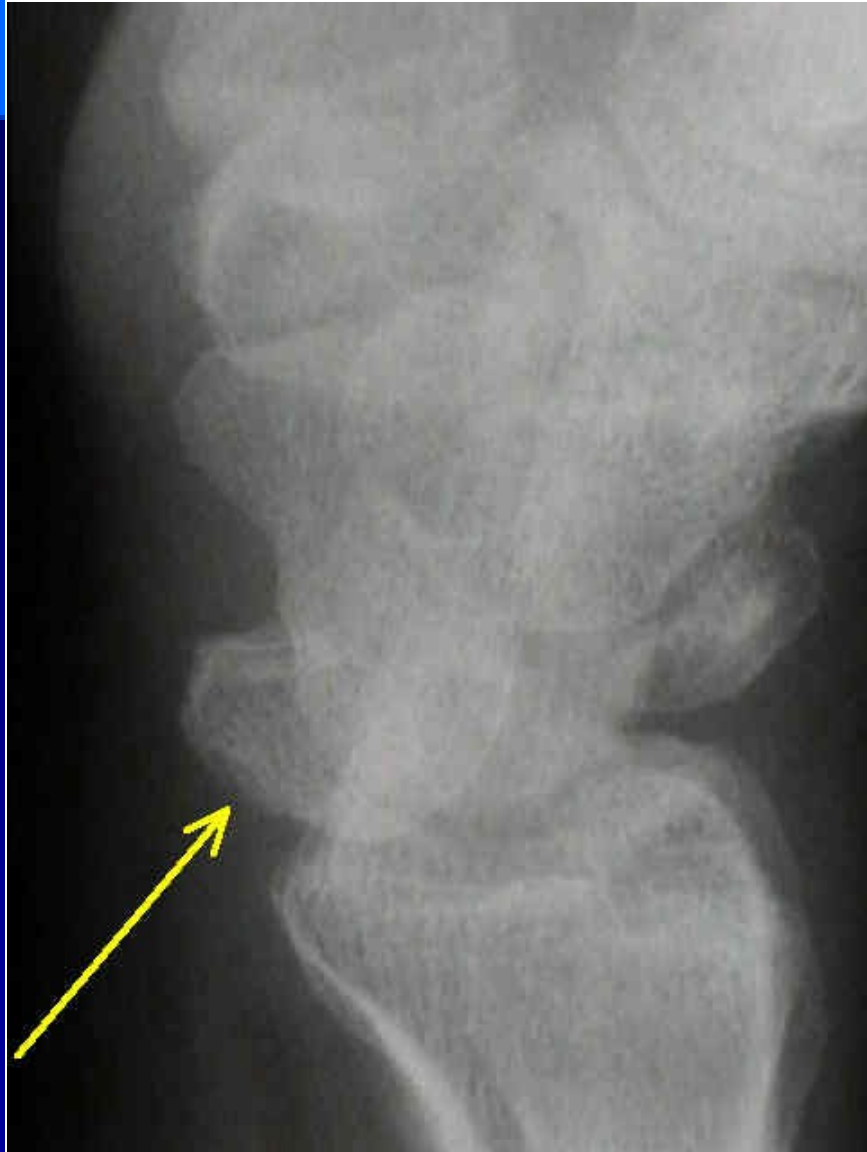


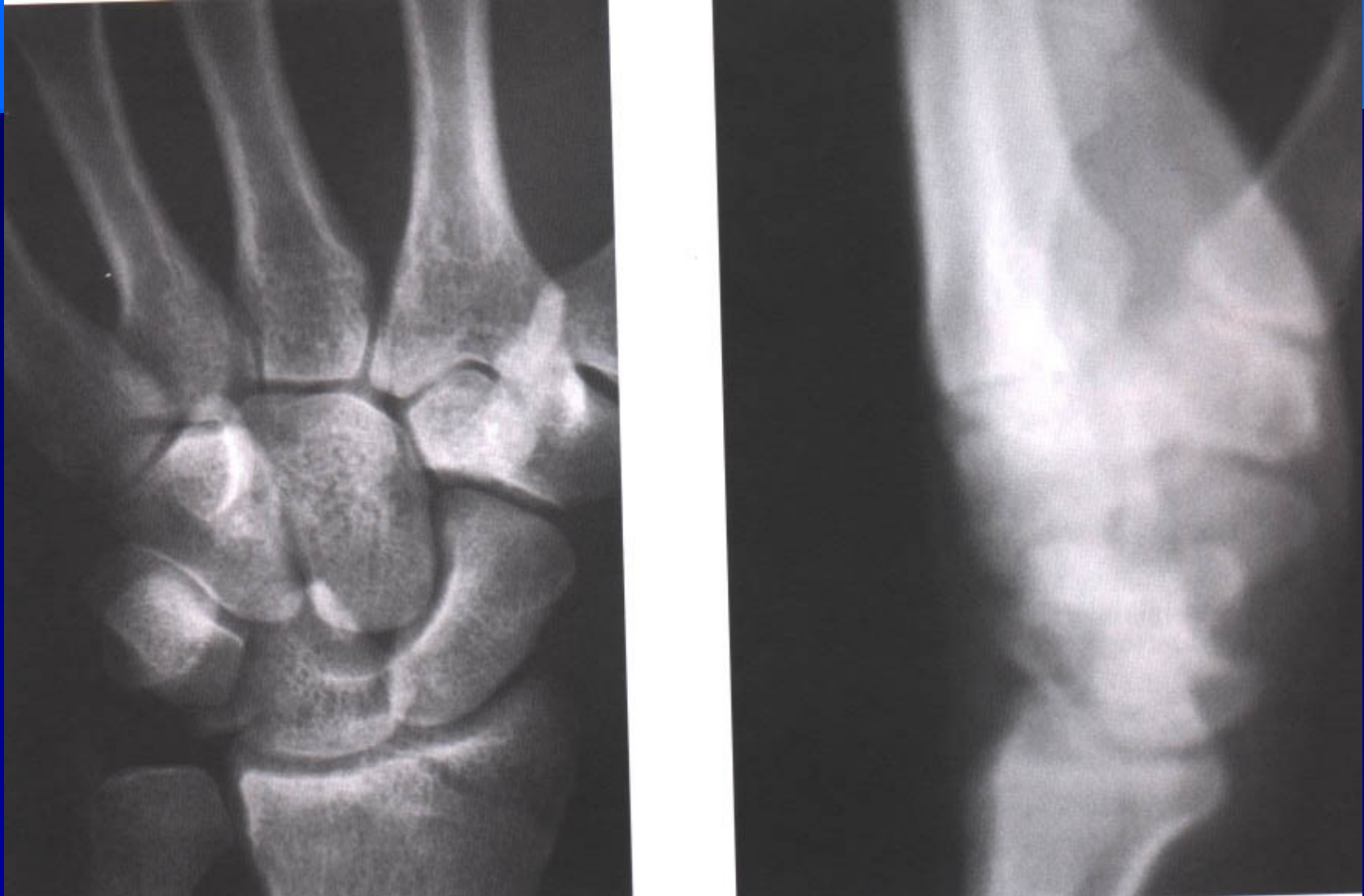Stubbins procedure



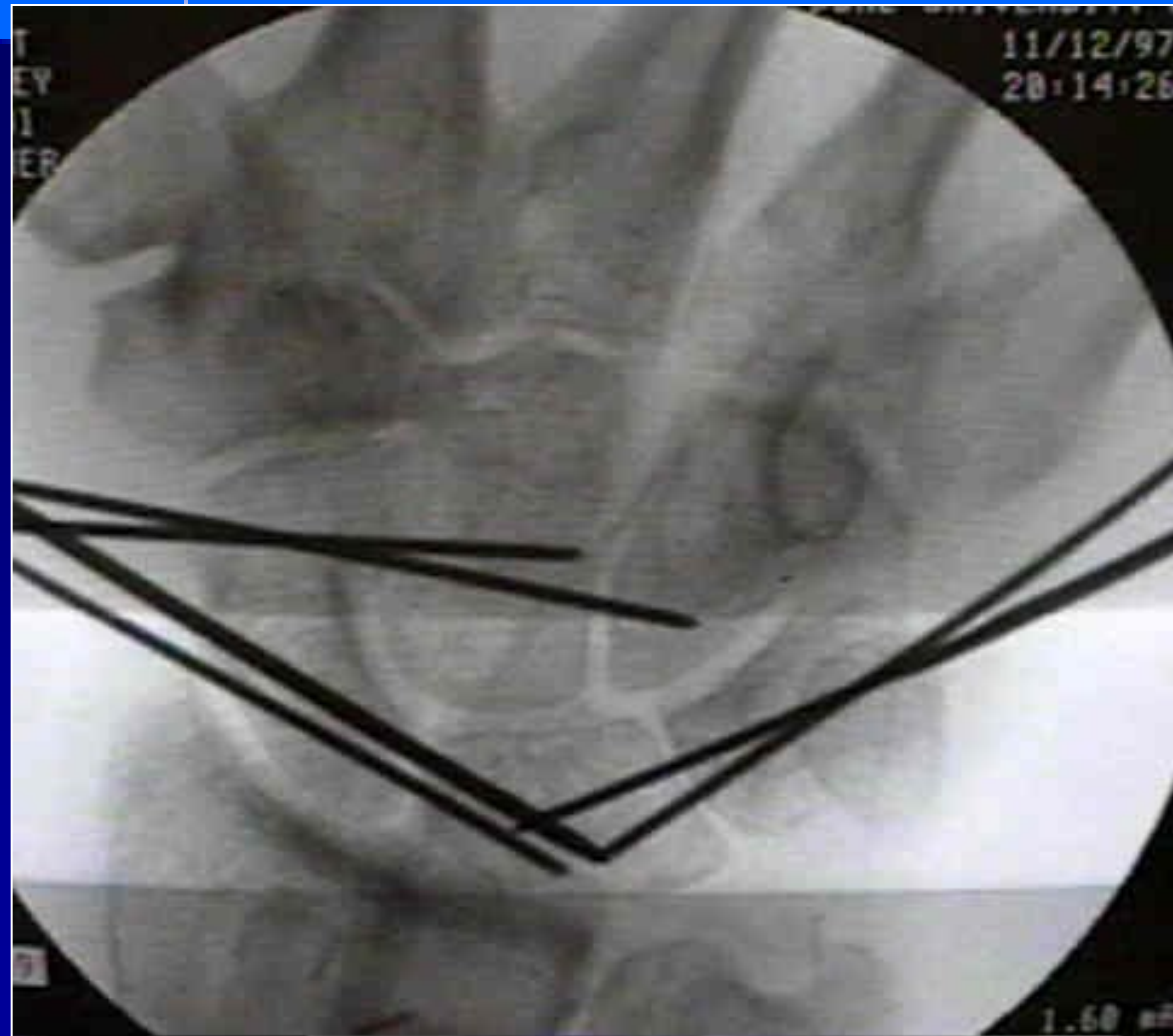Dislocation of lunate bone



Dislocation of lunate bone

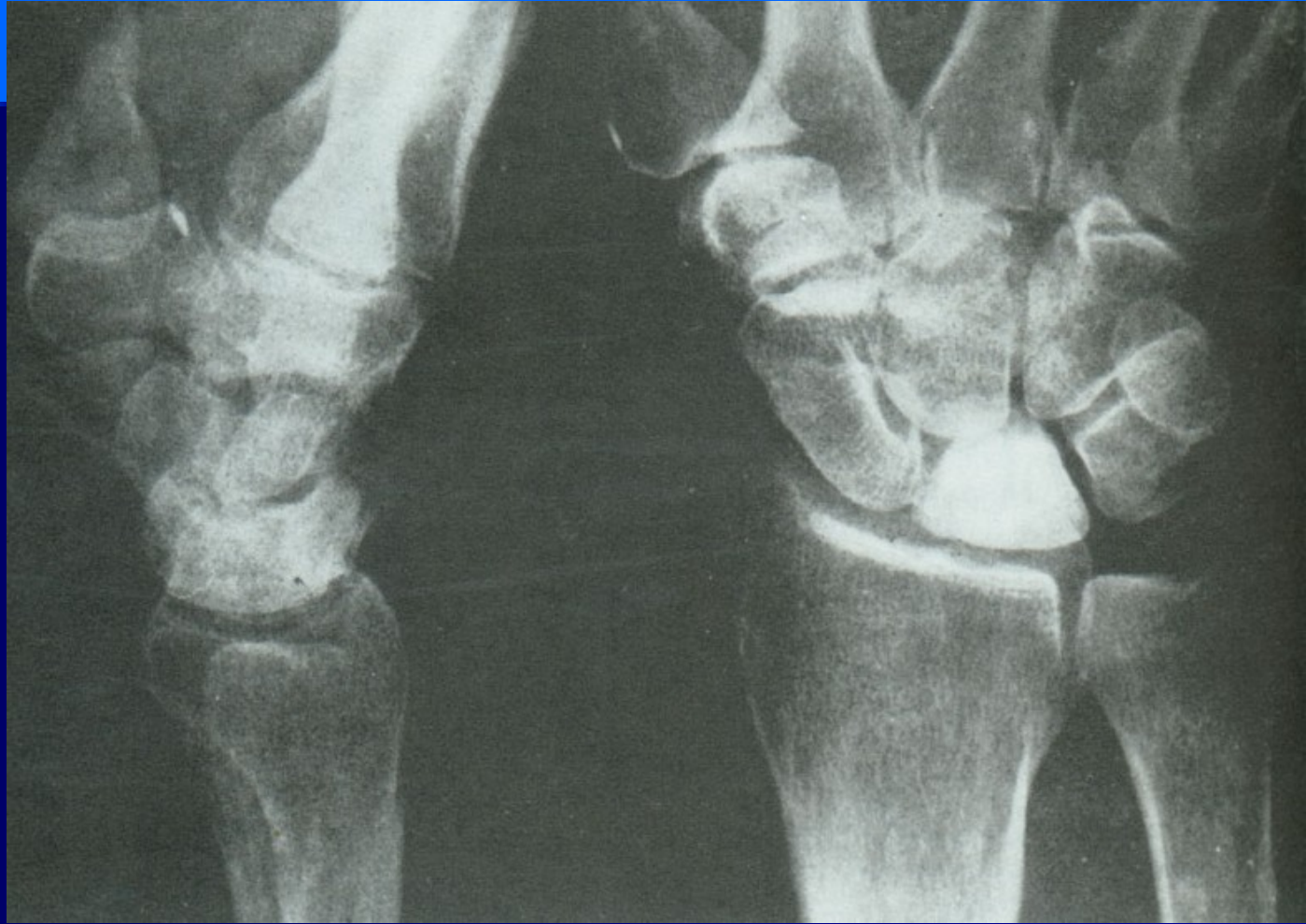


Perilunate dislocation

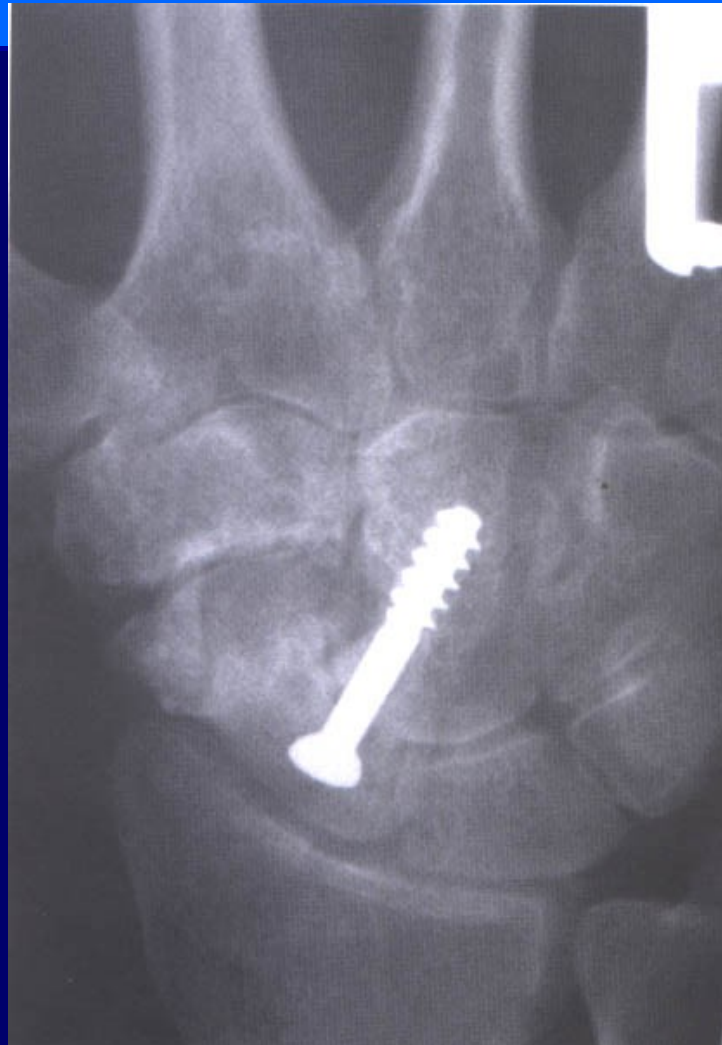

Fixation

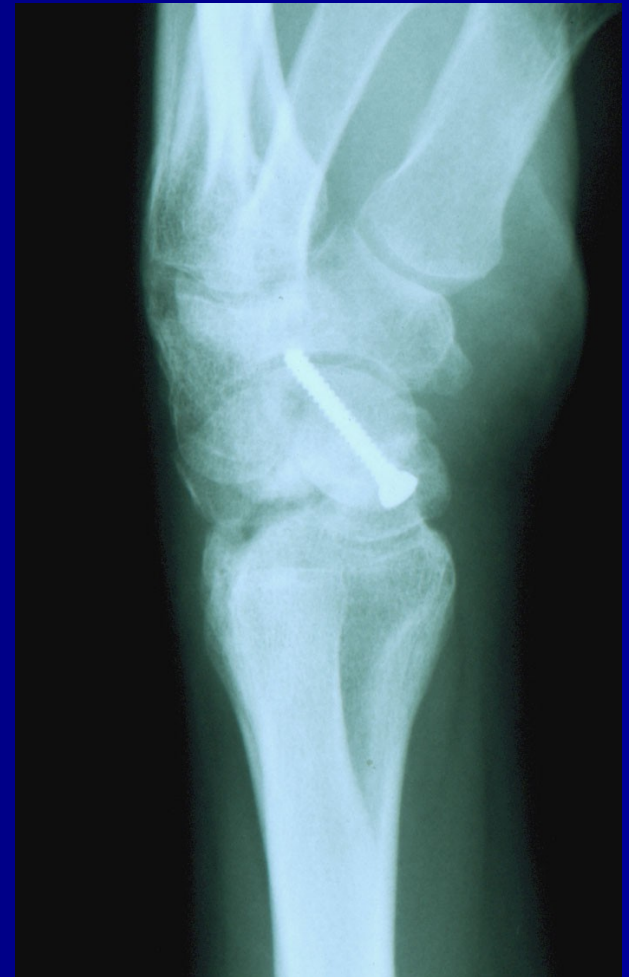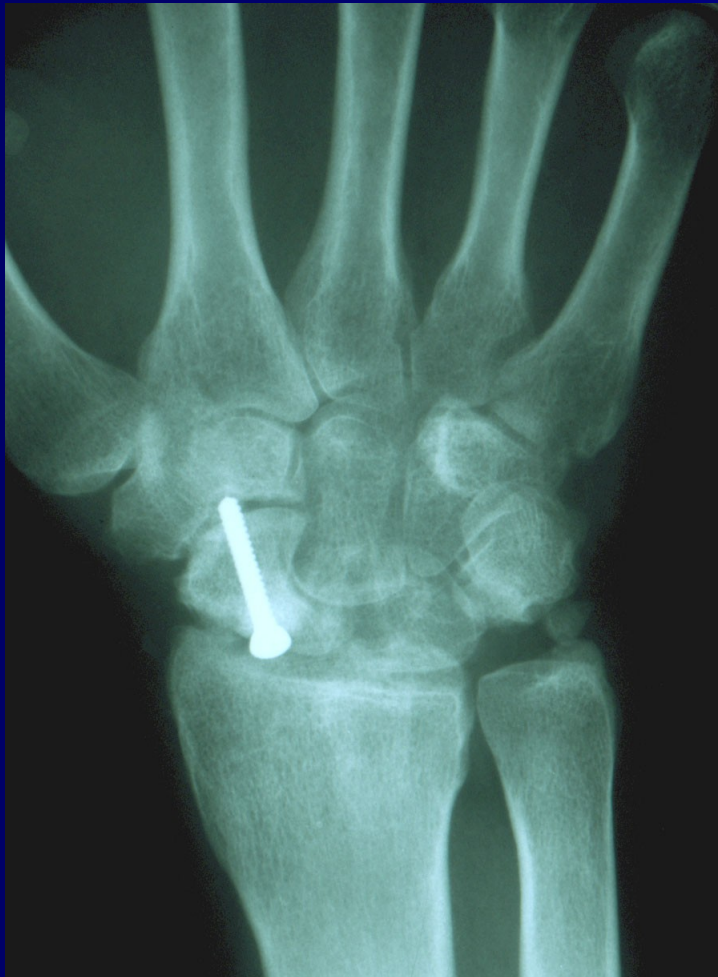M. Kienböck



Posttraumatic osteoarthritis

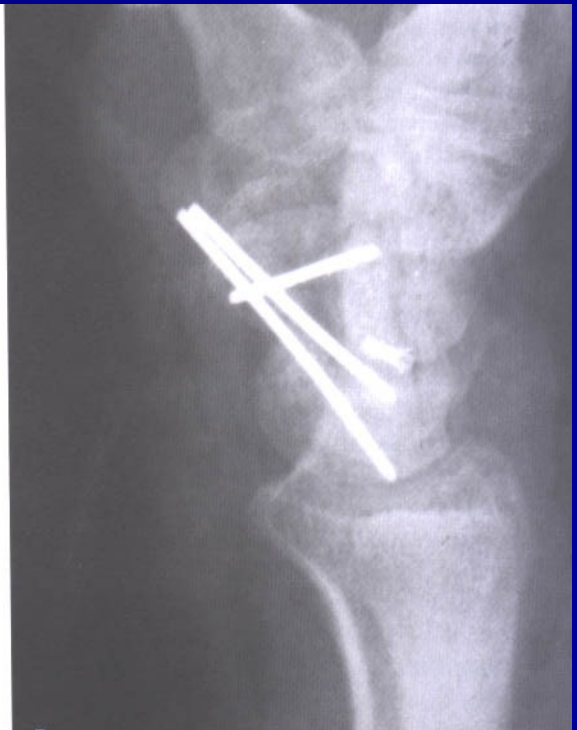
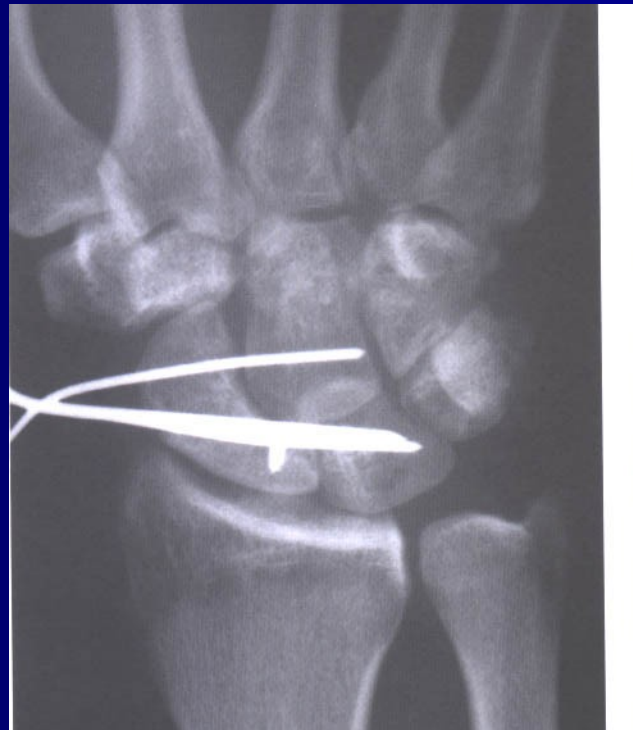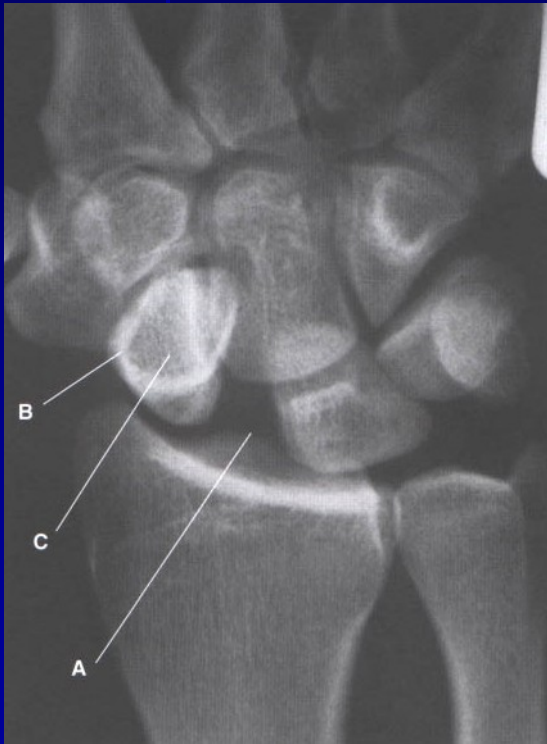


Posttraumatic O.A.

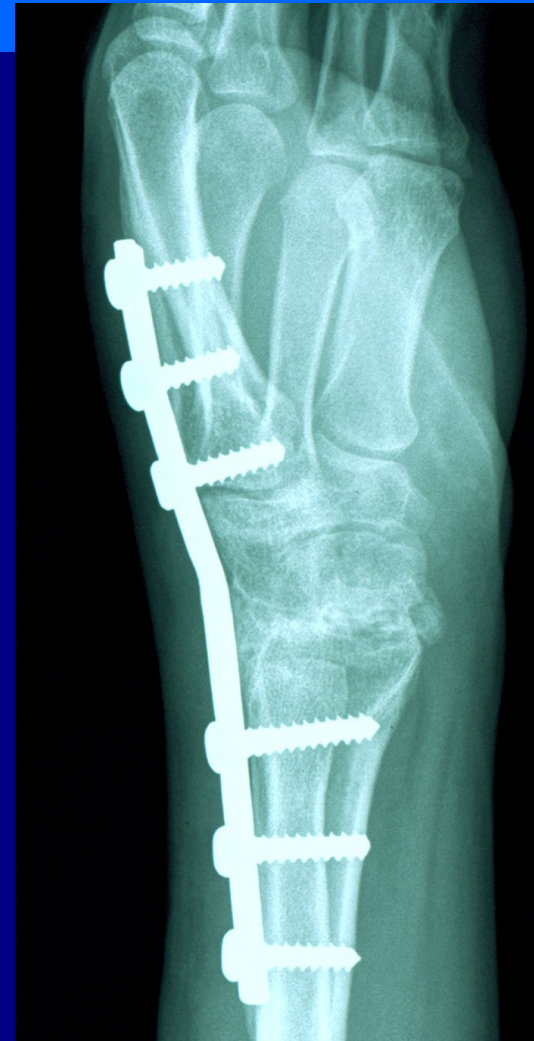
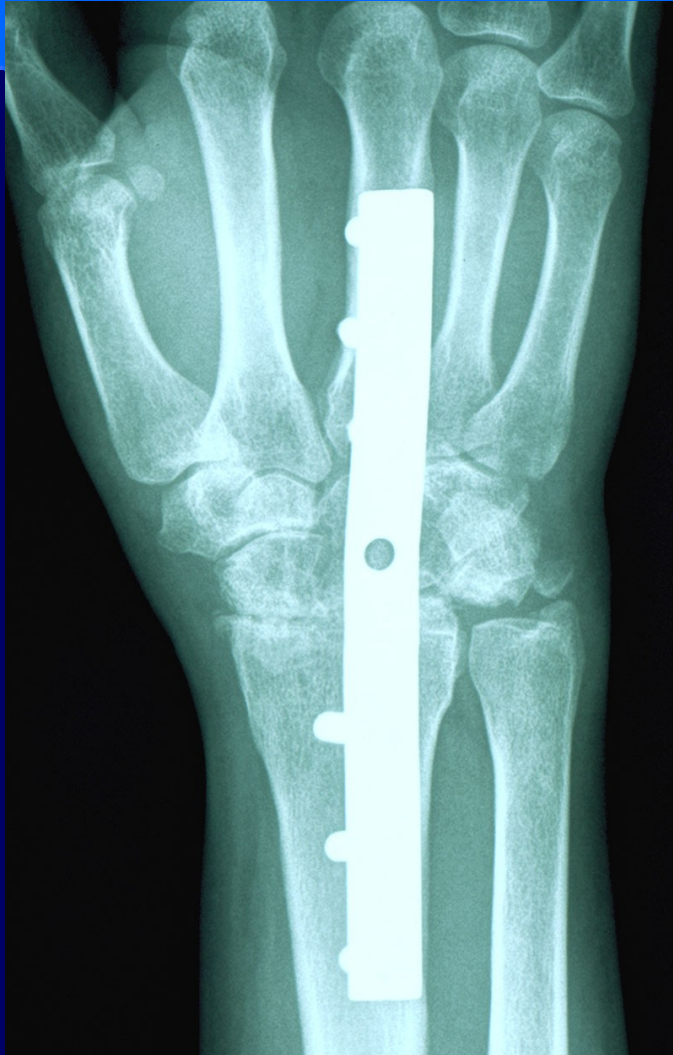

Scapholunate dissociation

- Terry Thomas sign

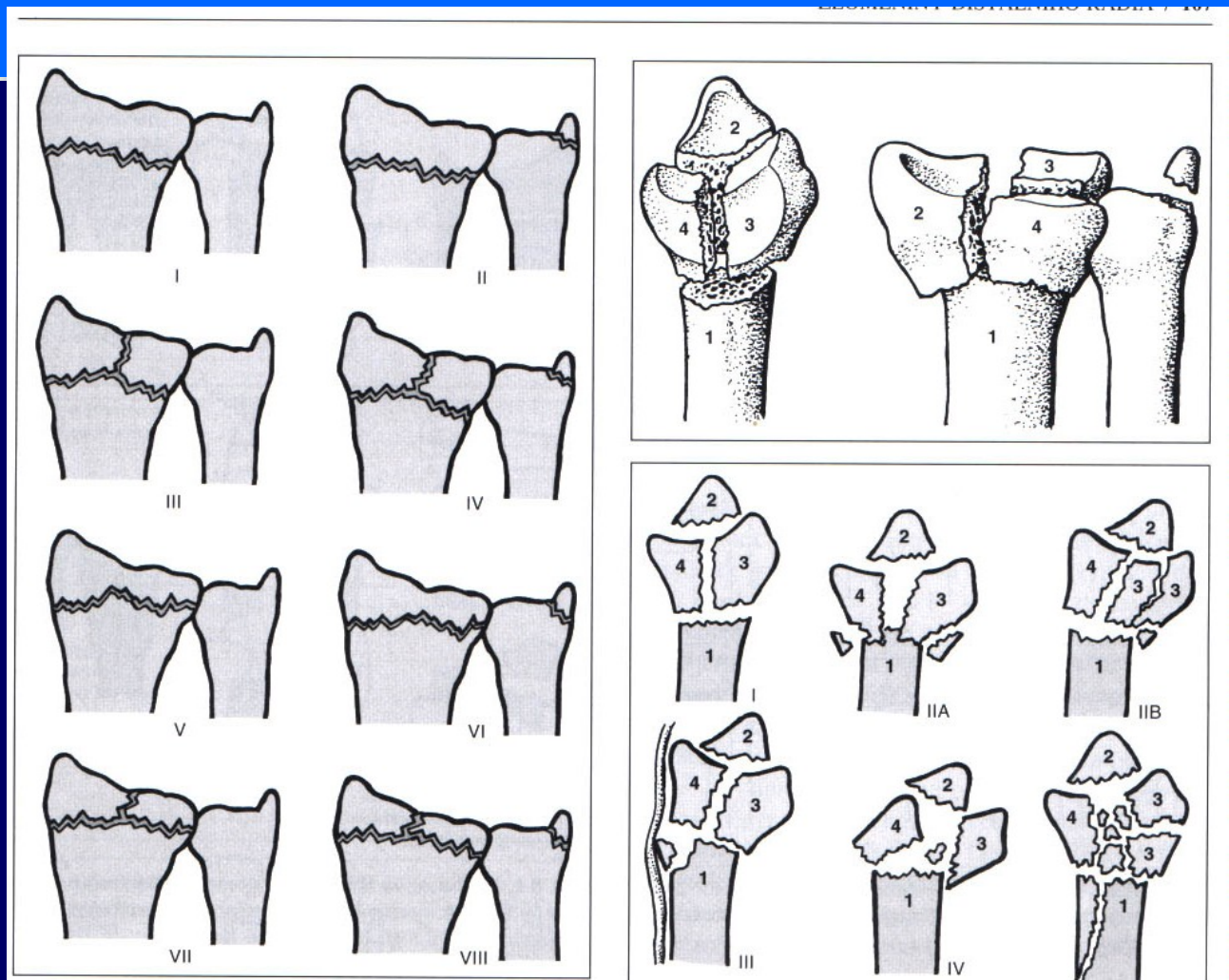


Arthrodesis of radiocarpal joint



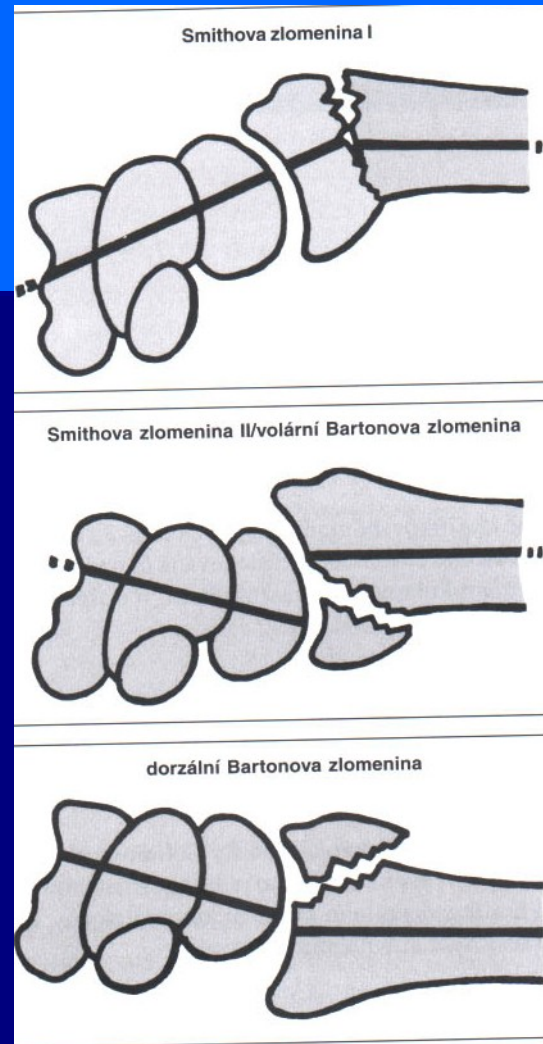
Colles' fracture

Frykman classification

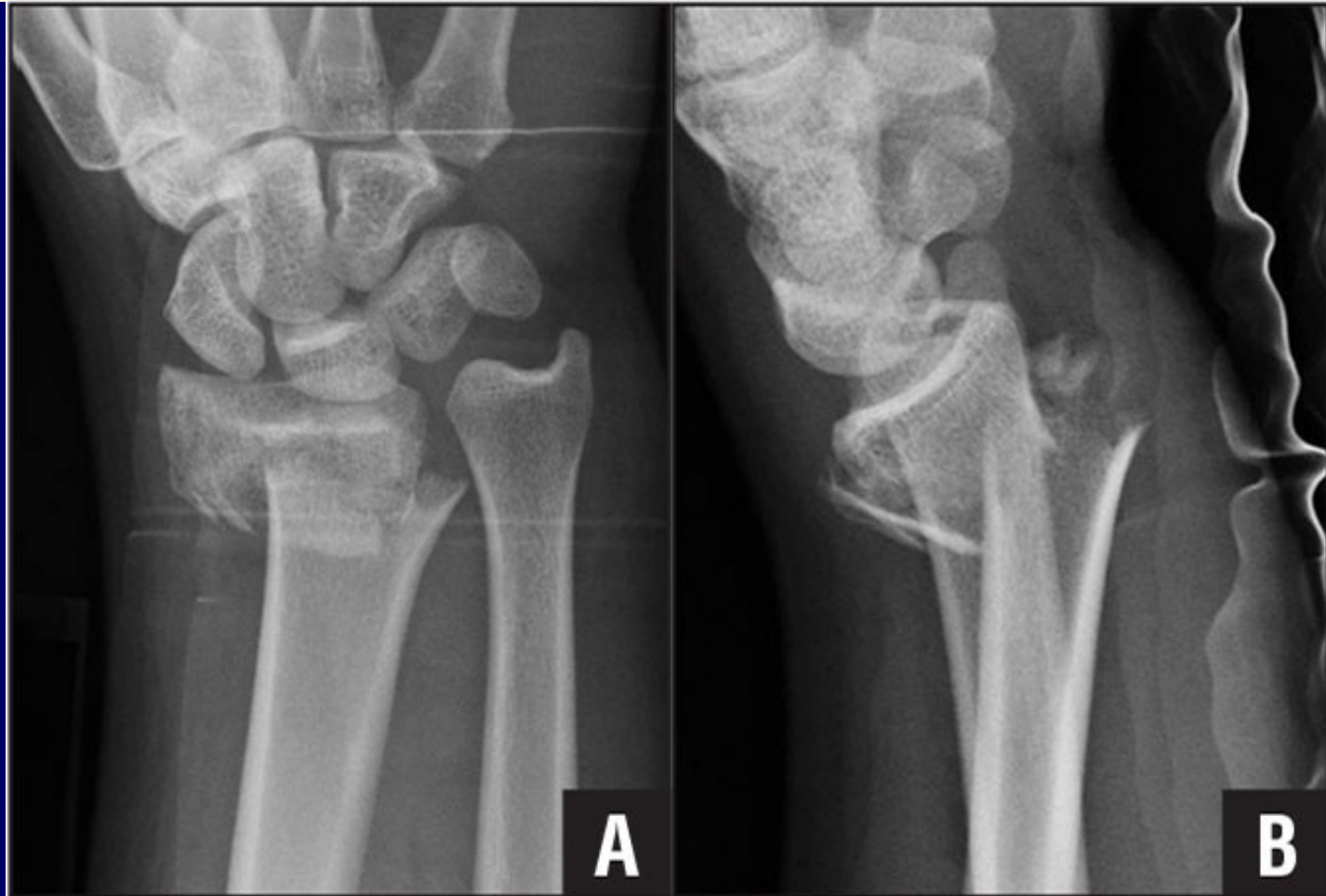

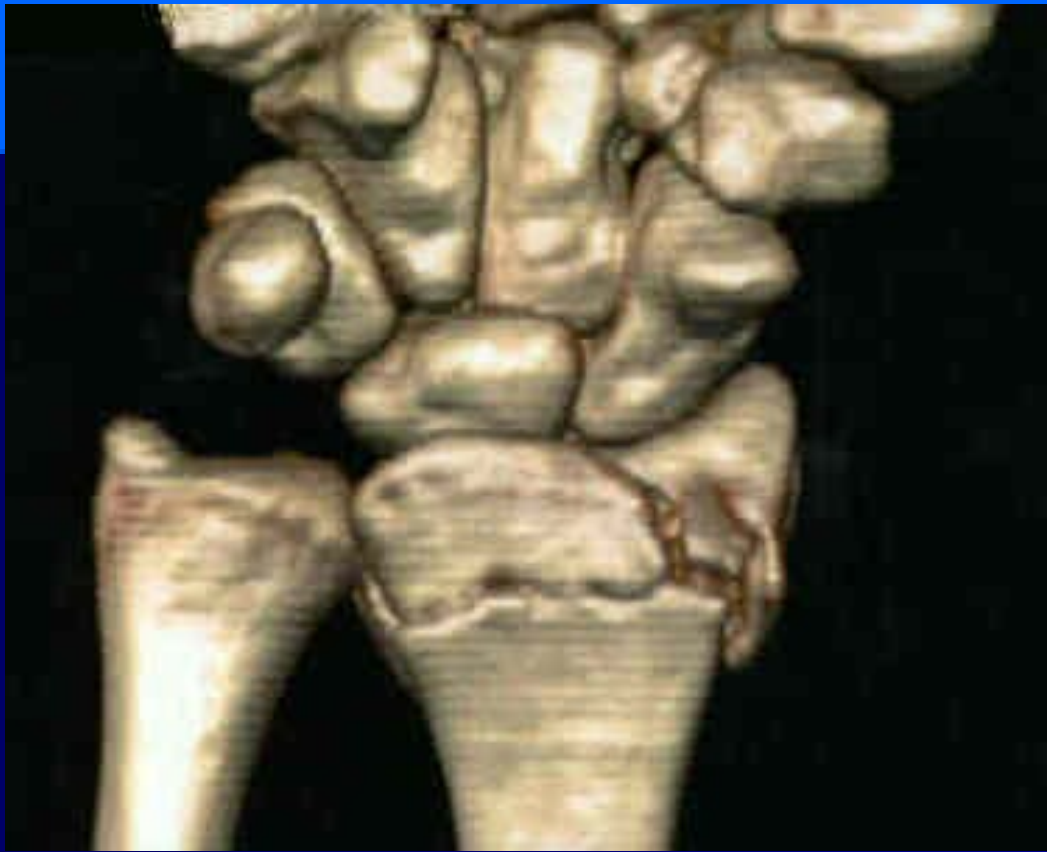Smith fracture

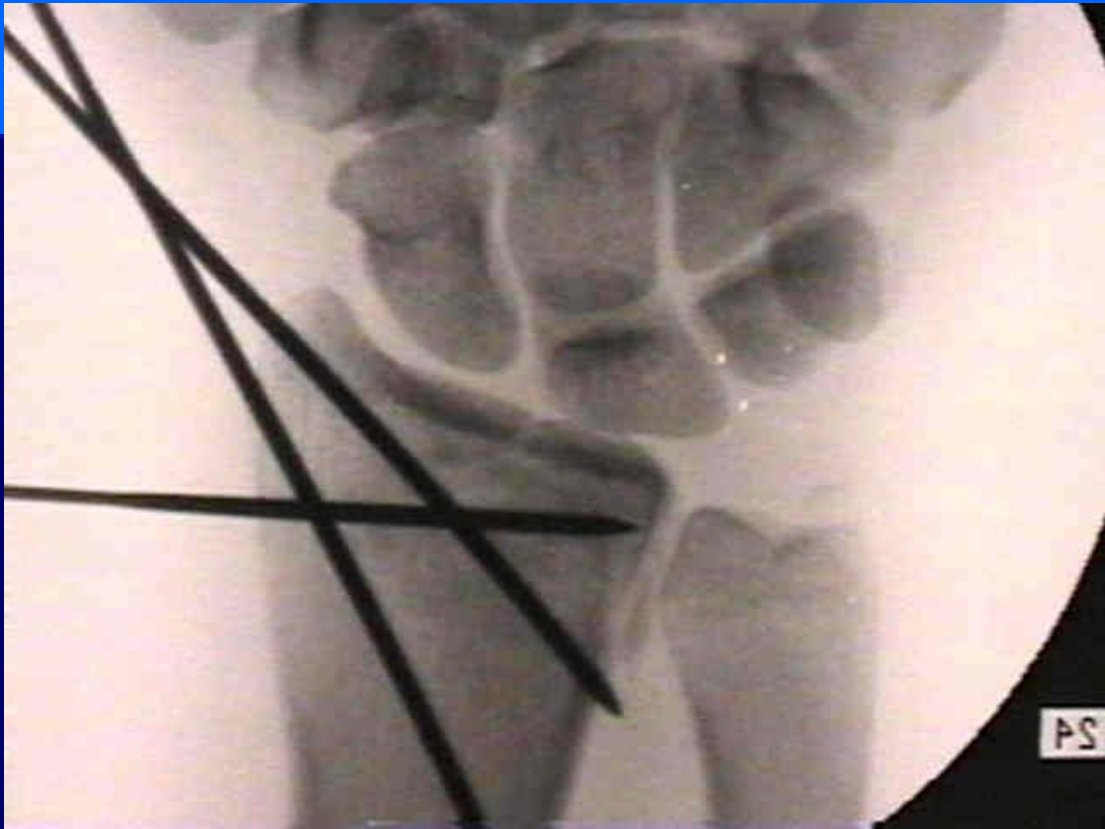
Barton fracture

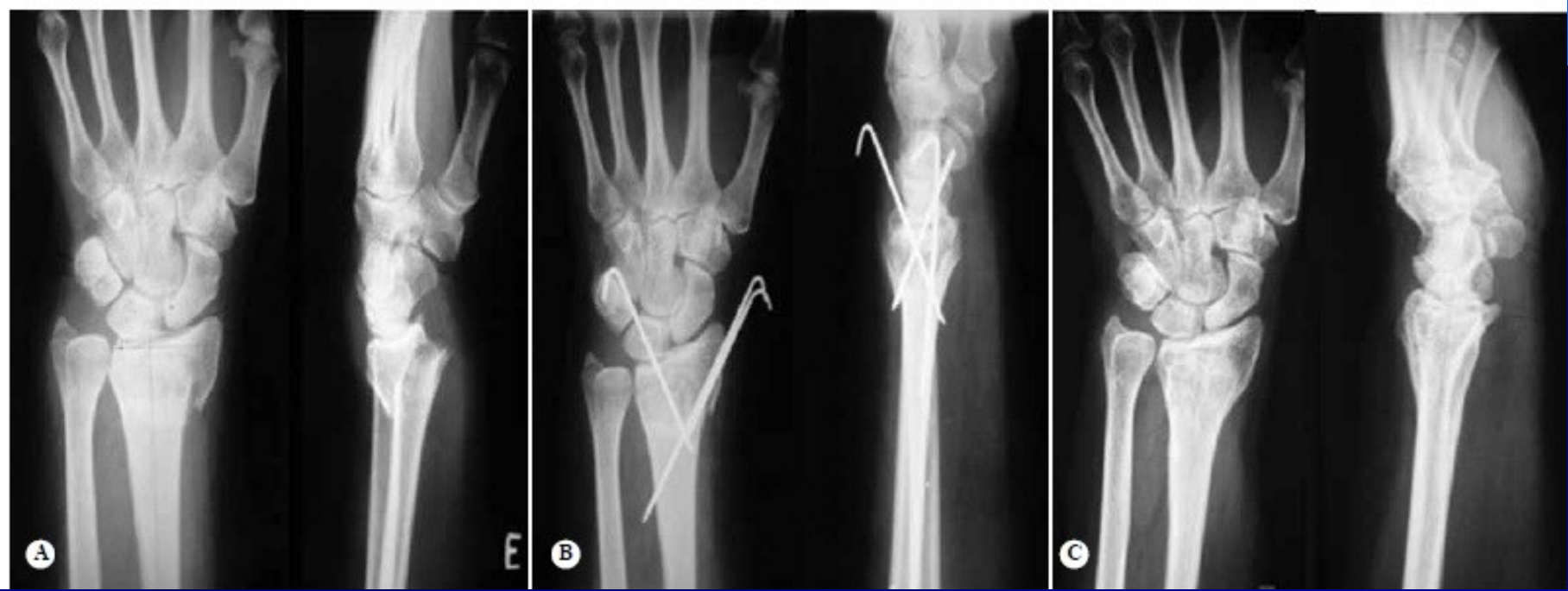

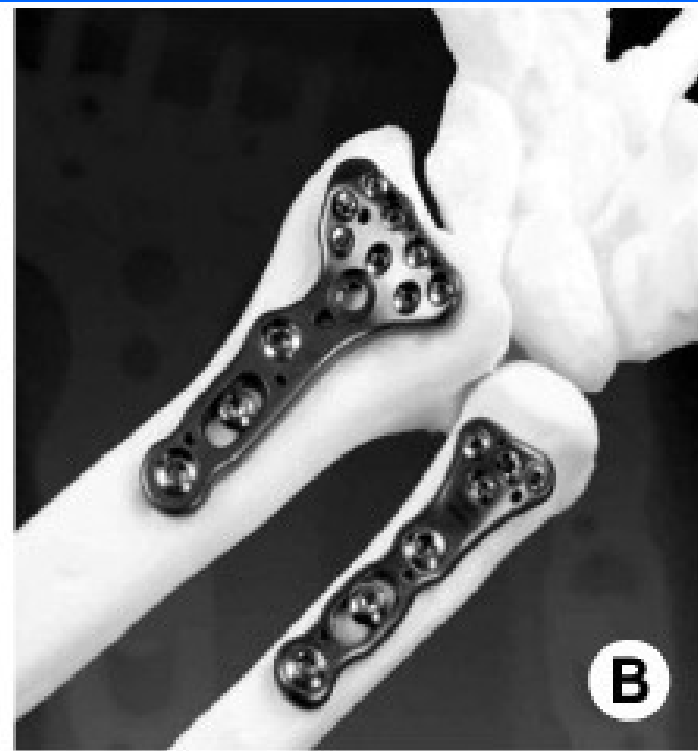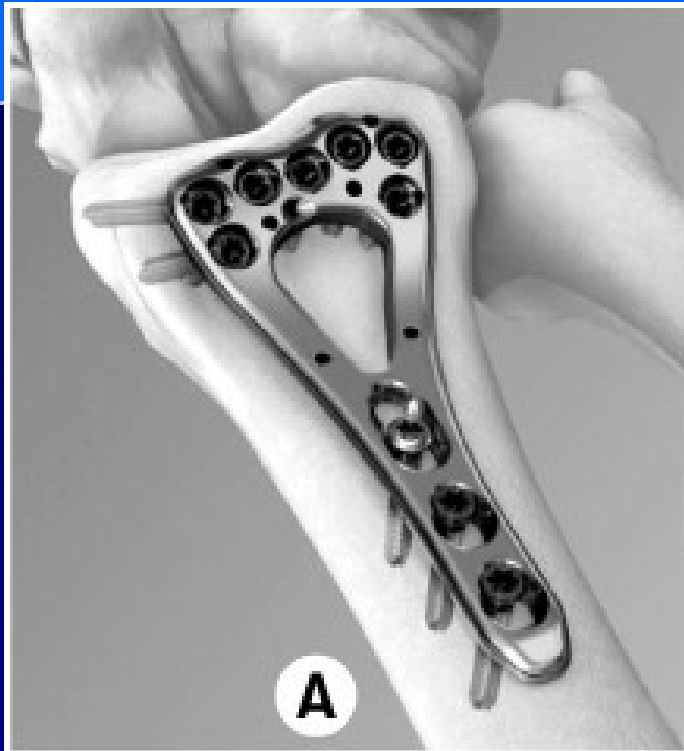
Colles' fracture

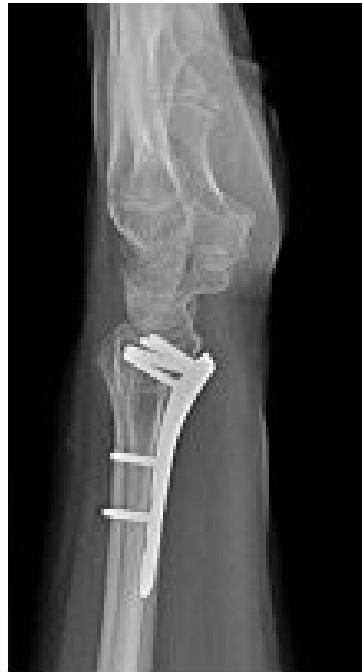
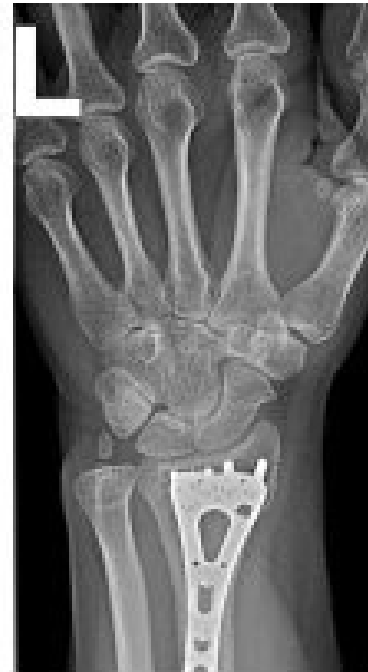
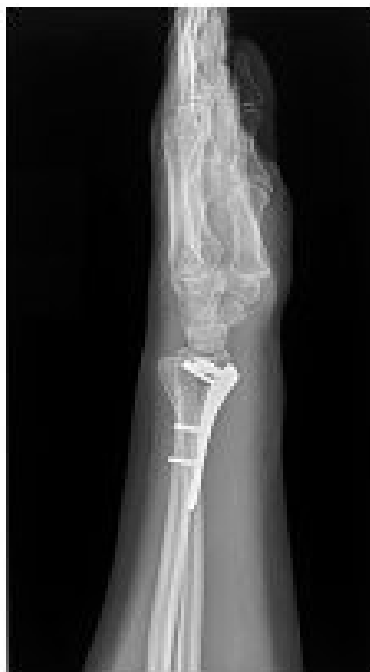
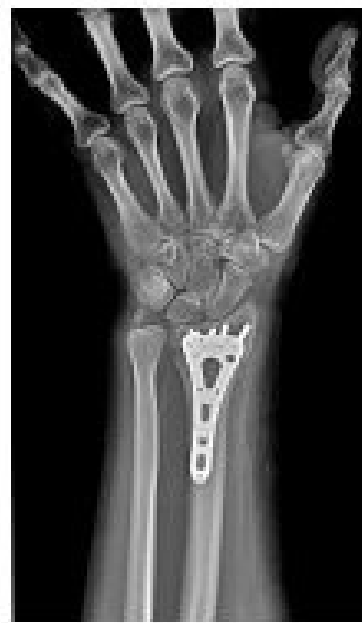
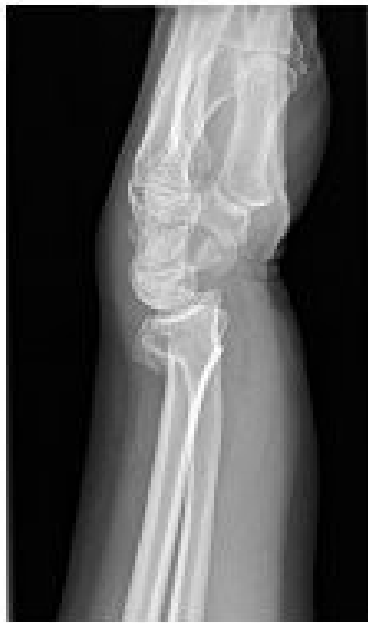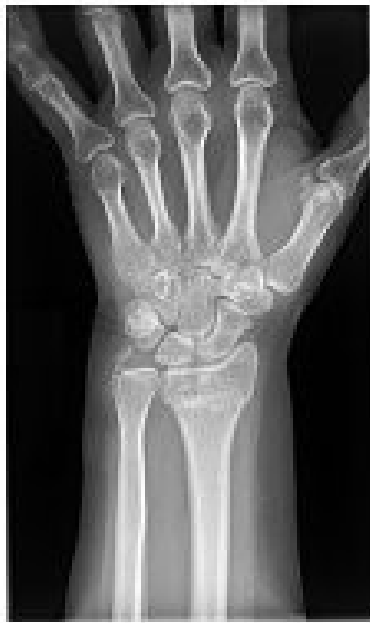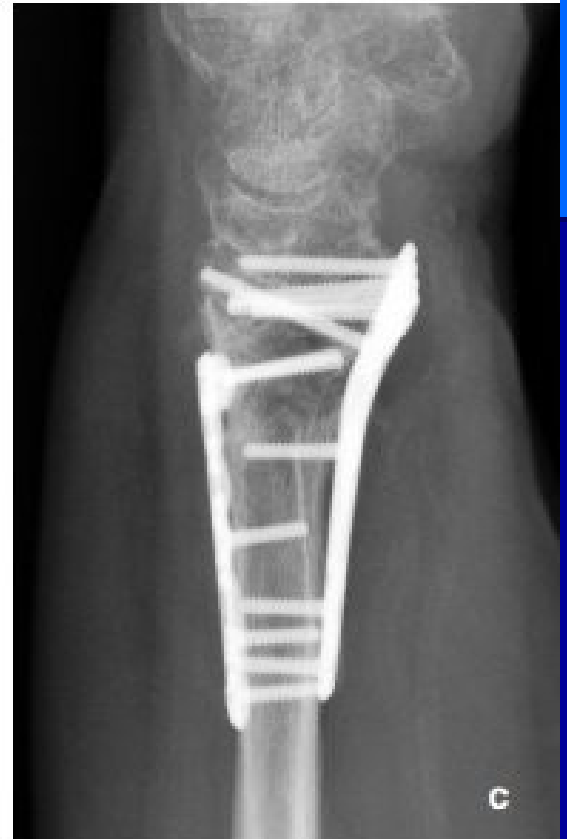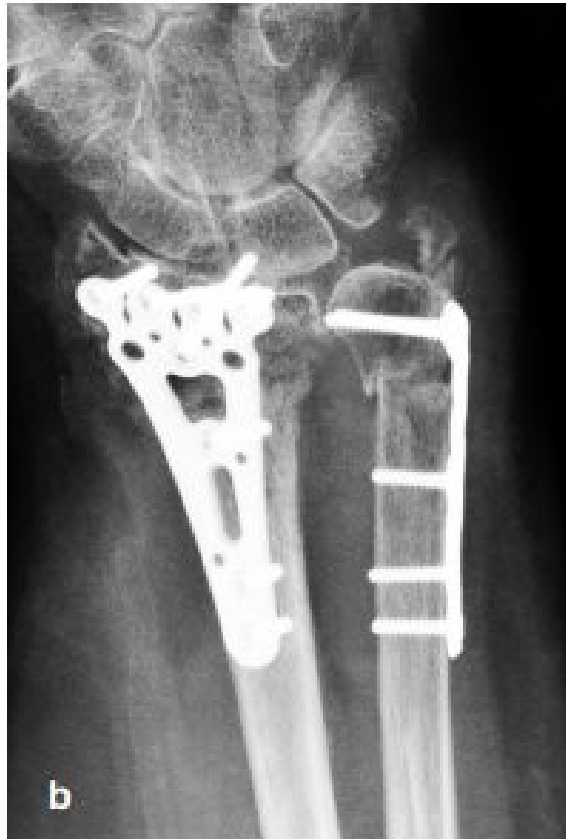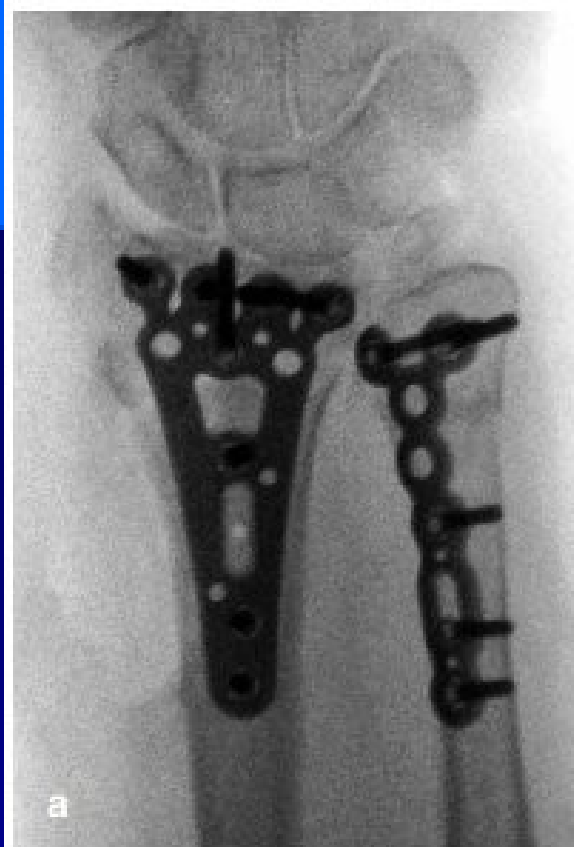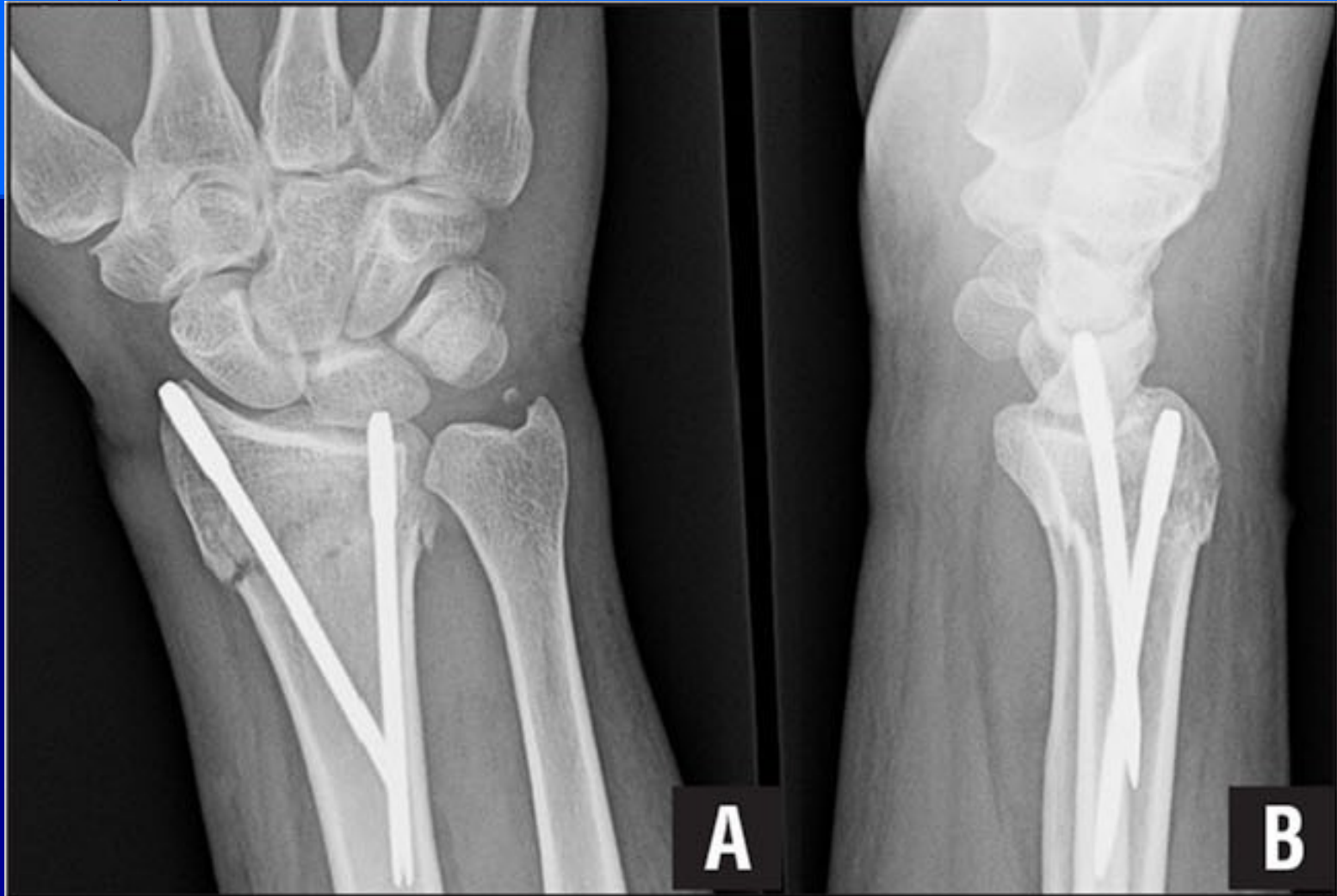




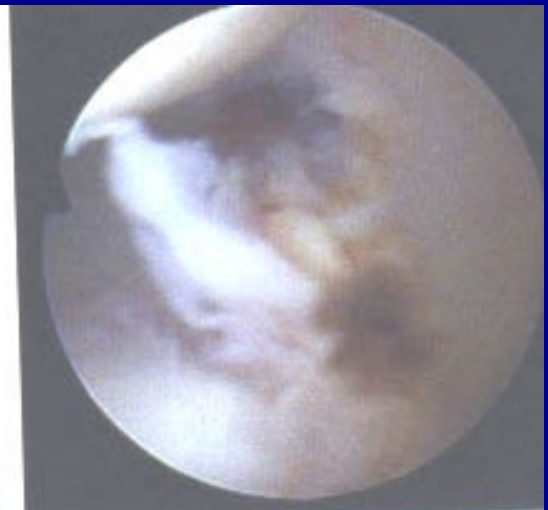






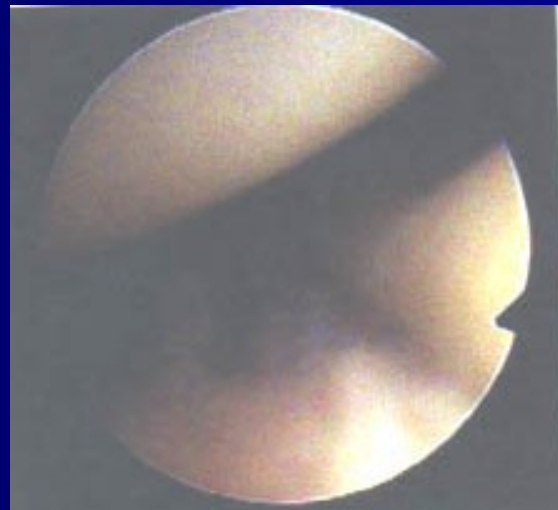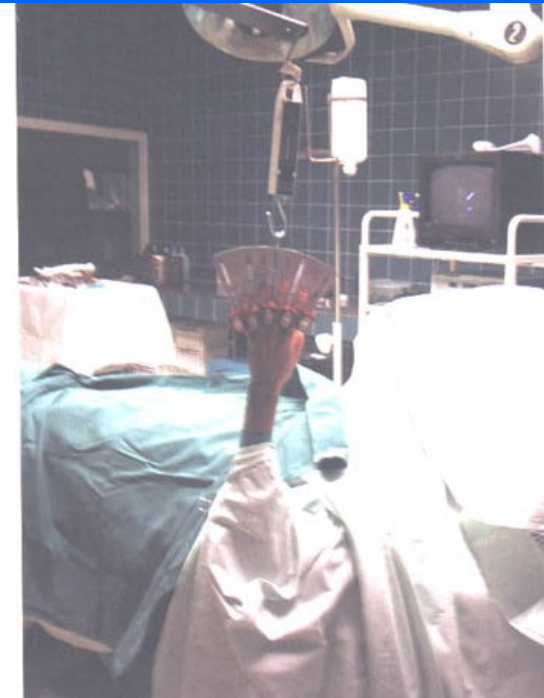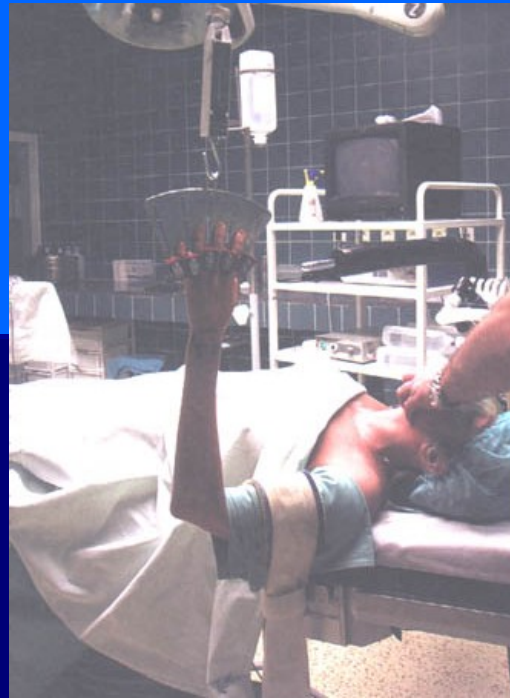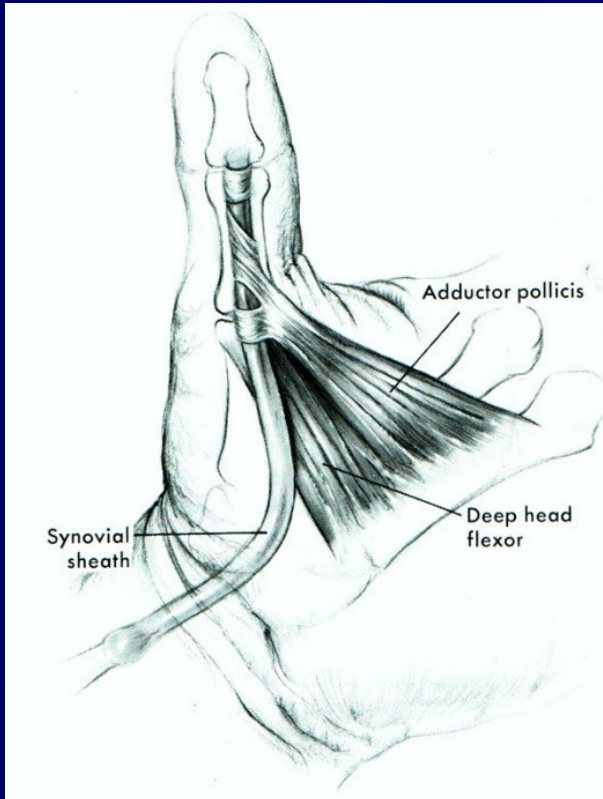


Arthroscopy of the wrist



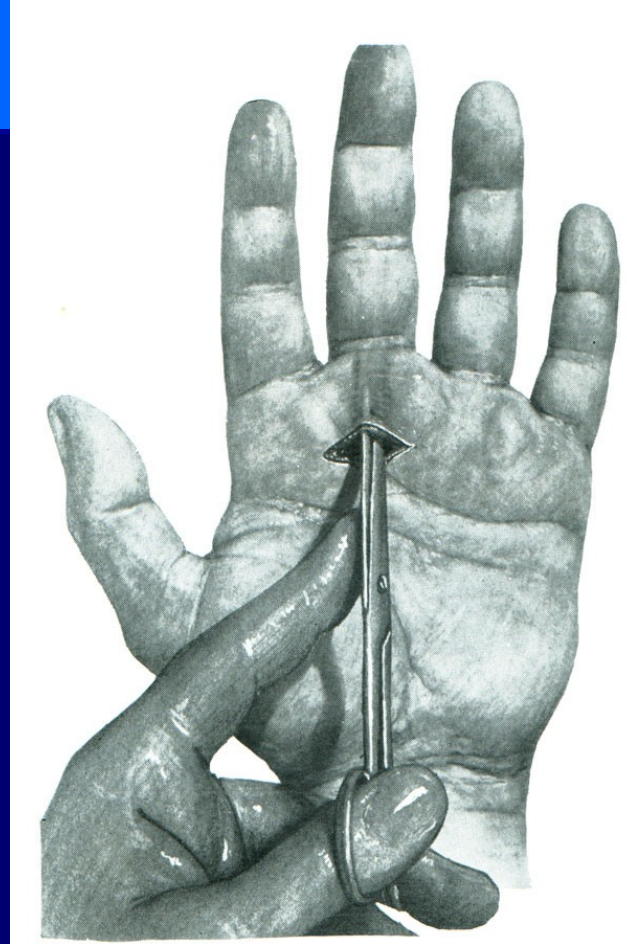Trigger thumb

- Snapping of the thumb



- **Therapy**
- **Steroid injection**
- **Surgical release of the first pulley**

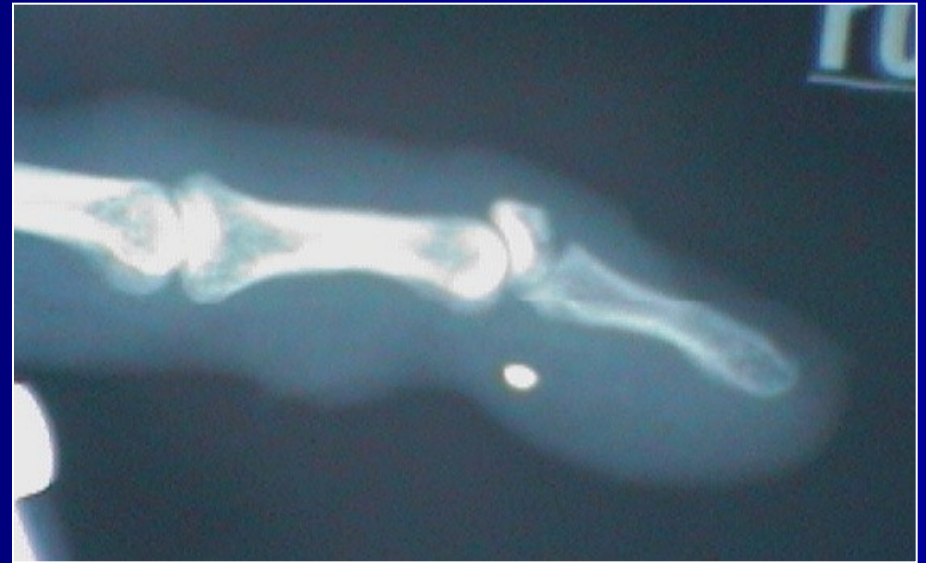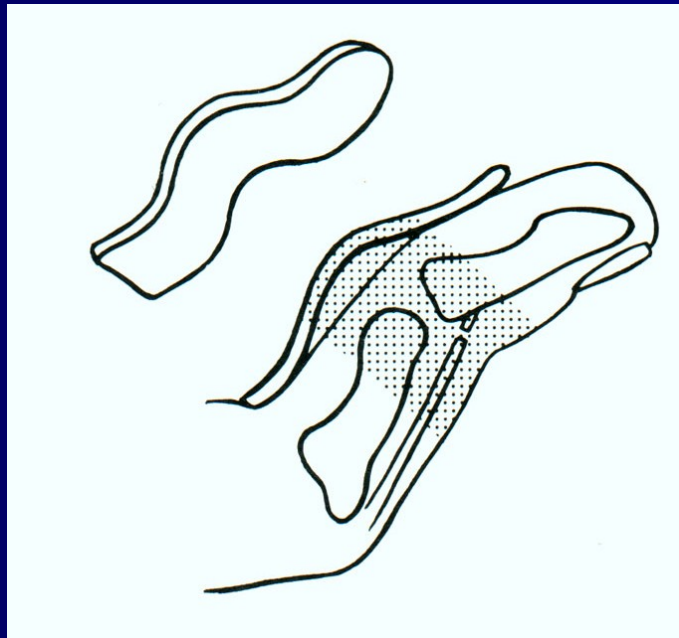
Trigger finger



Th: steroid injection, surgical release

Fracture of the base of distal phalanx- dorsal aponeurosis

Th : splinting



M. de Quervain

Stenosing tenosynovitis of
long abductor and short extensor
of the thumb

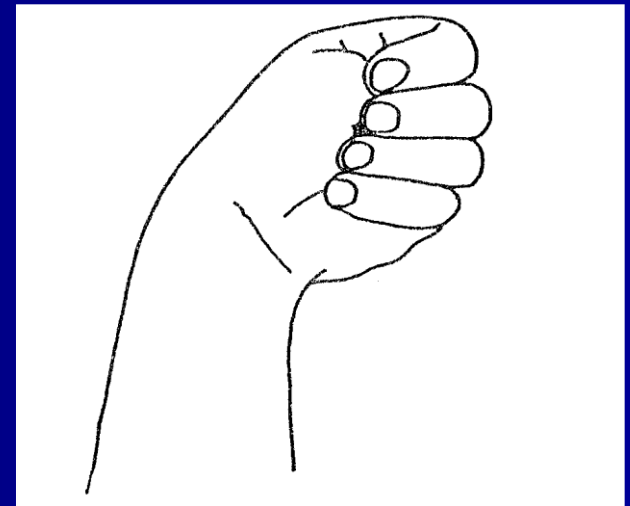
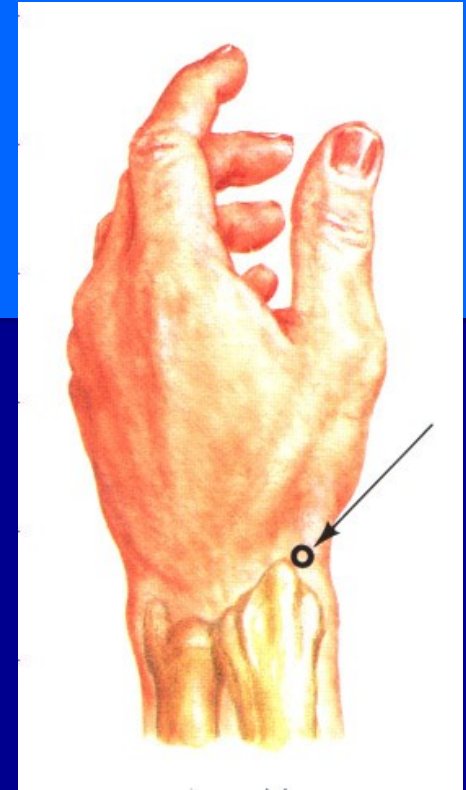
Tenderness over styloid process
Finkelstein test

Treatment

Rest, orthosis, plaster

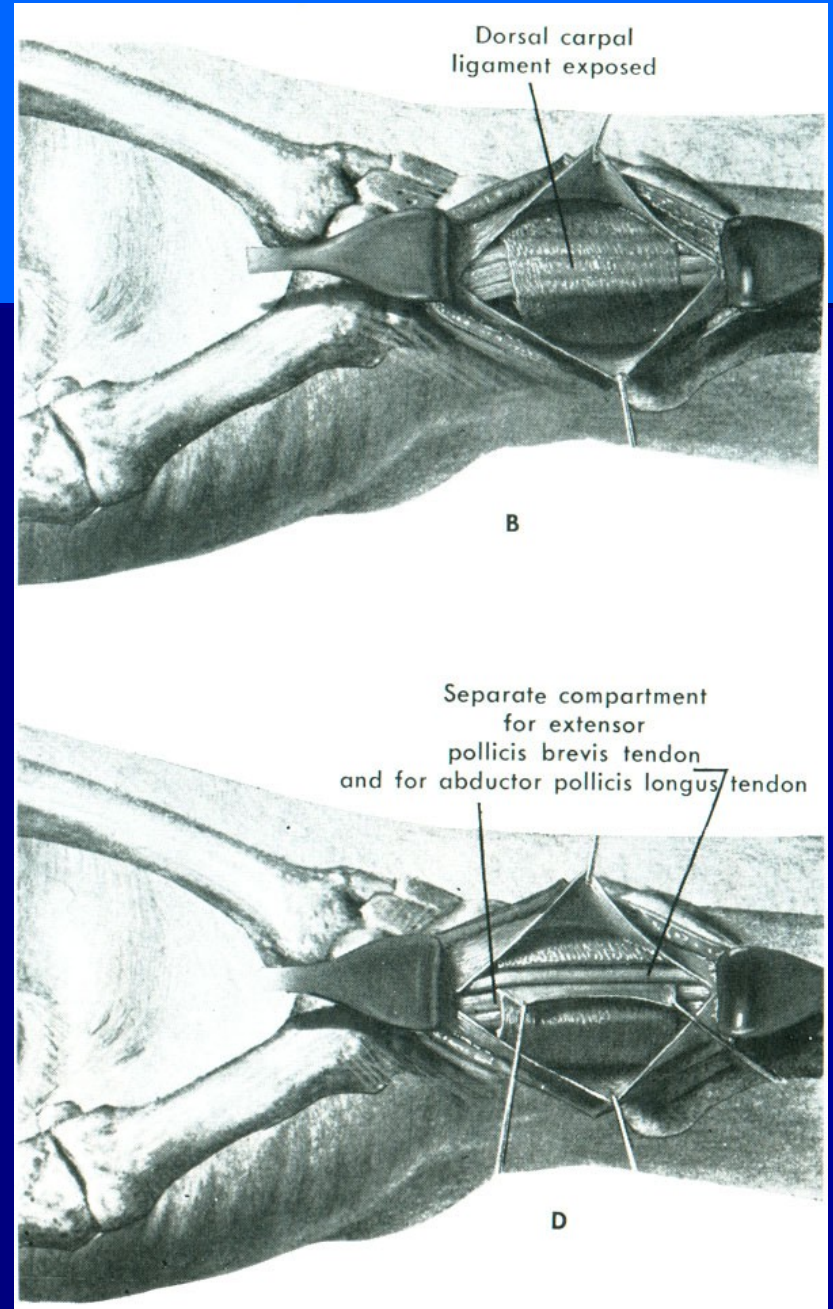
NSAID, corticoids

Surgery



M. de Quervain

Release of the tendon sheaths



Carpal tunnel syndrom

Compression neuropathy of median nerve

Pain, diminished muscle power

Hypotrophy of thenar muscles

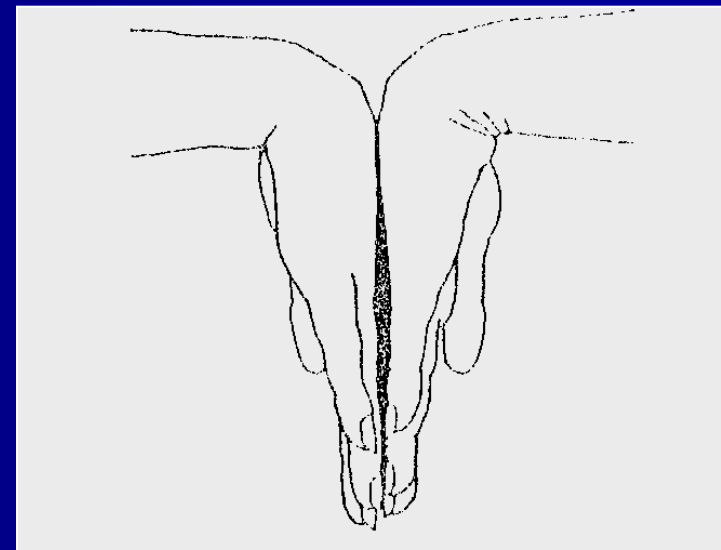
Paresthesia and numbness

Limited function of fingers

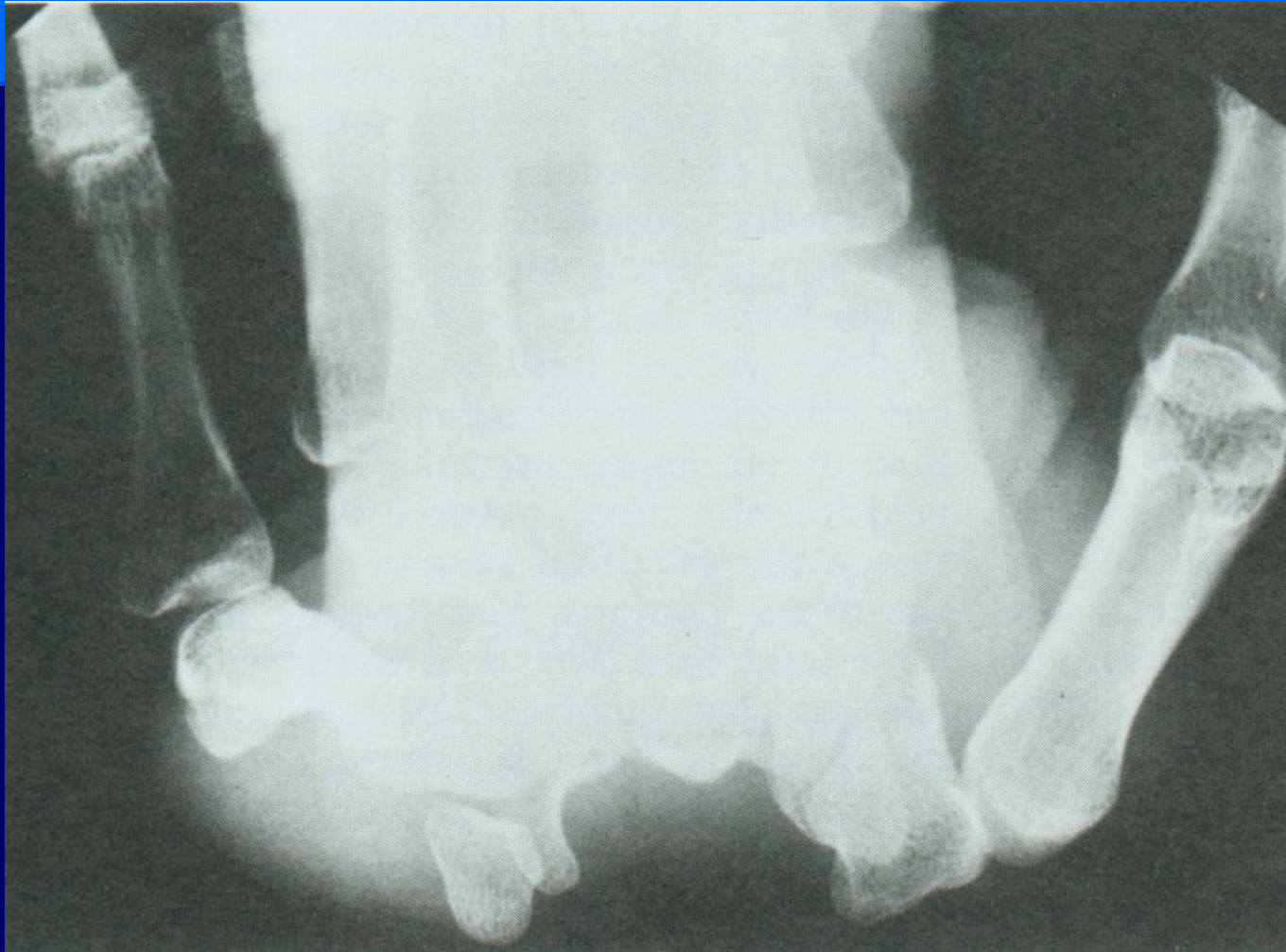
Tenderness

Tinnel sign

Phalen test



X ray for carpal tunnel

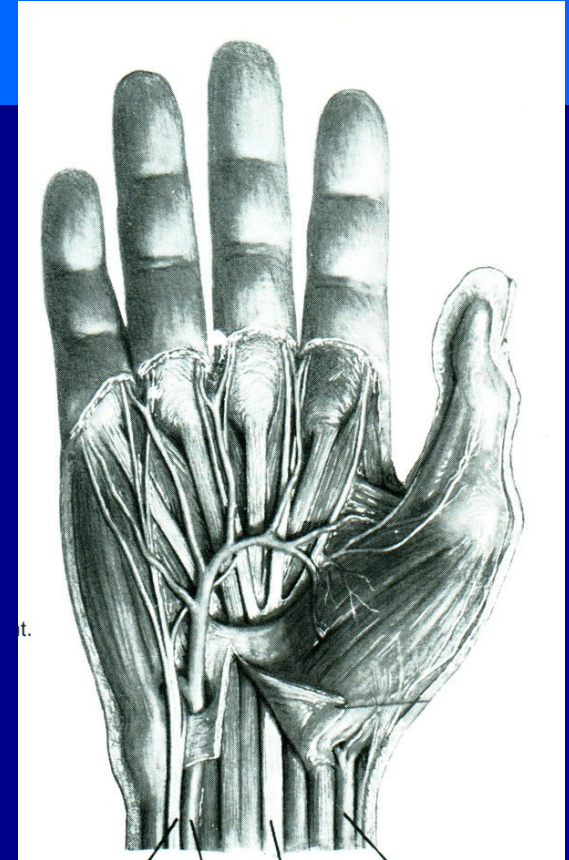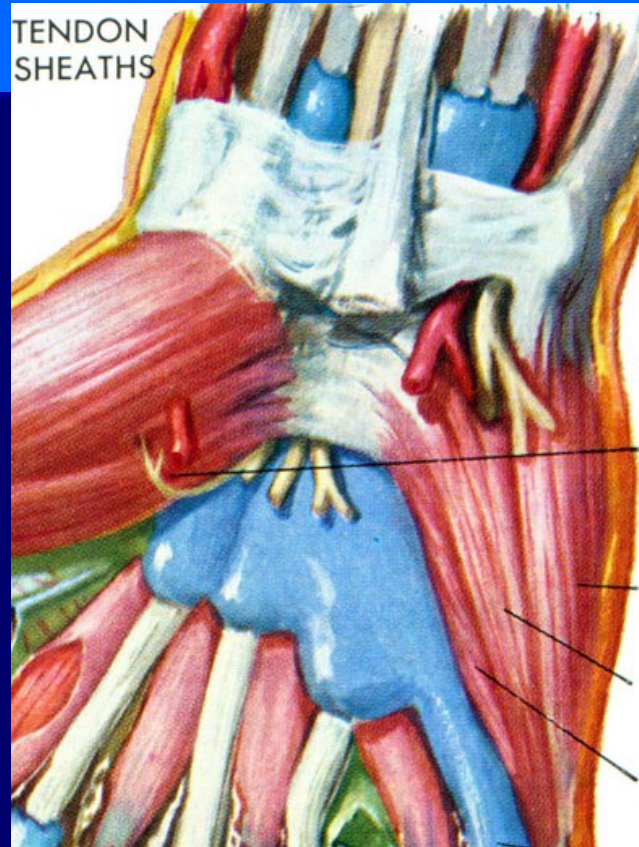


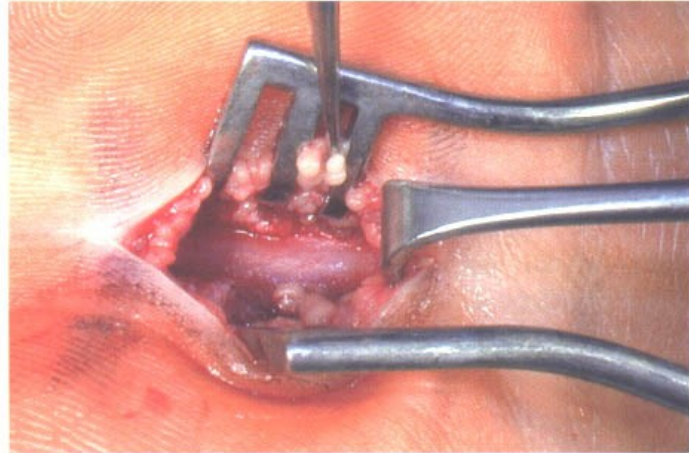
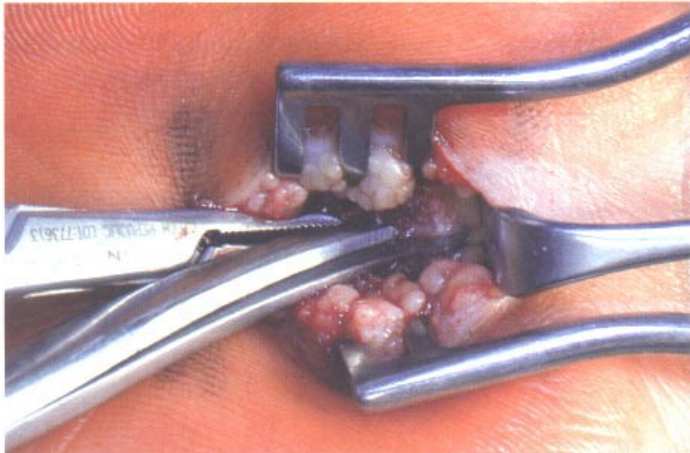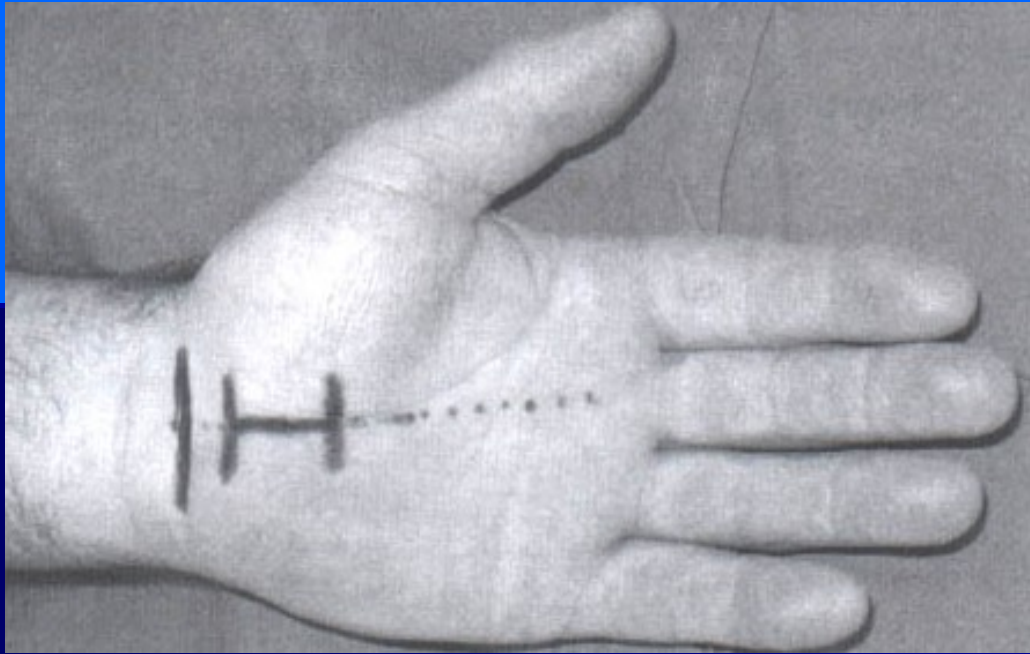
Carpal tunnel syndrom

Therapy

Conservative

Surgery





Guyon tunnel syndrom

Compression neuropathy of ulnar nerve
in hand

Paresthesia and numbness on
ulnar side

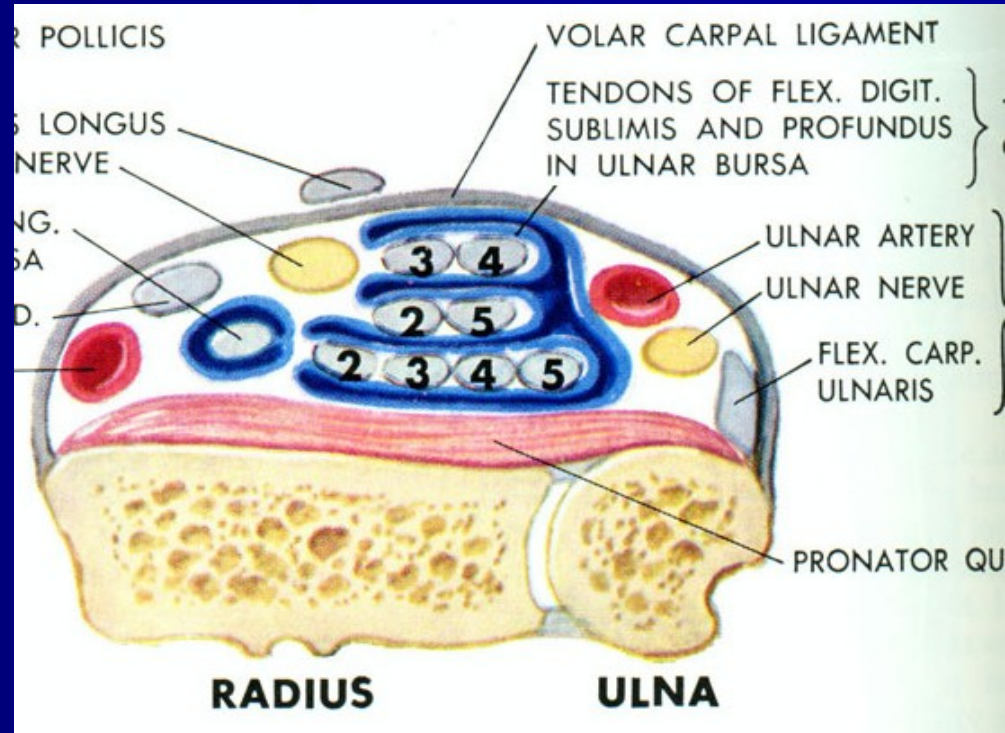
Hypotrophy of hypothenar

Limited function of 4.5. finger

Therapy

Conservative

Surgery

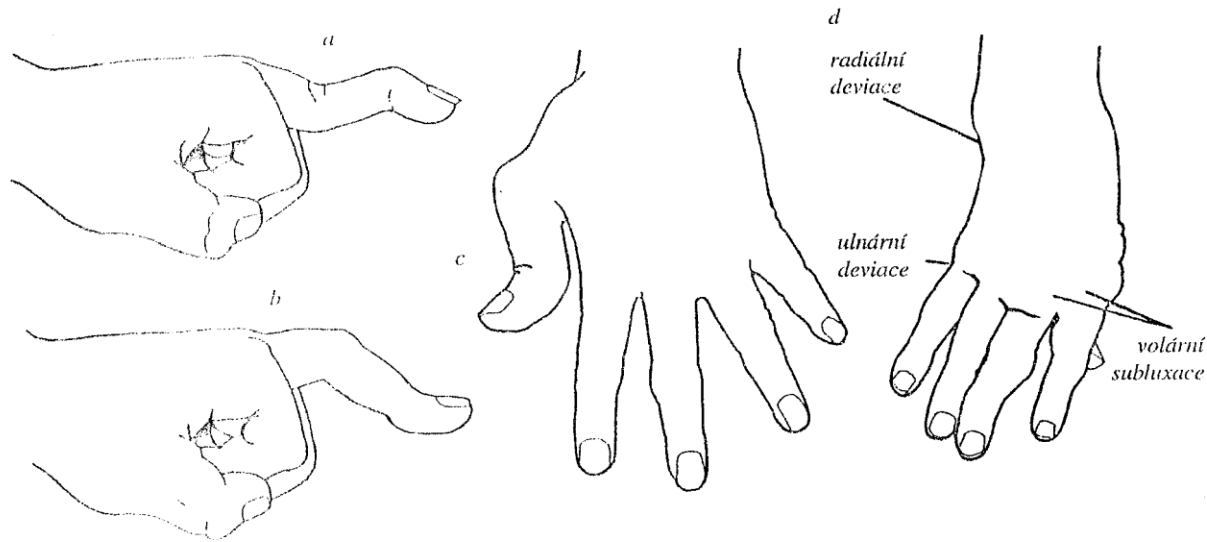


Tenosynovitis of flexors of extensors

- **tenosynovitis crepitans**

Th : rest, splinting, NSAID

Deformity of the hand in R.A.



Button hole deformity

Swan neck

Z deformity of the thumb

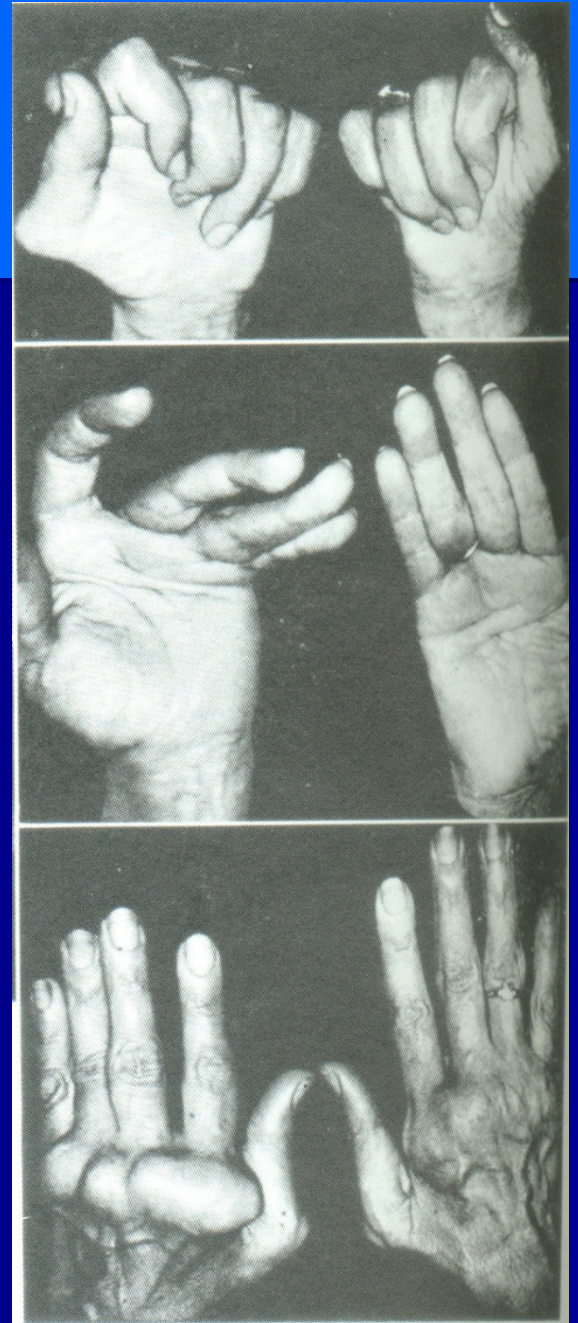
Ulnar deviation

Synovitis of MP, PIP a DIP joints

Telescopic fingers

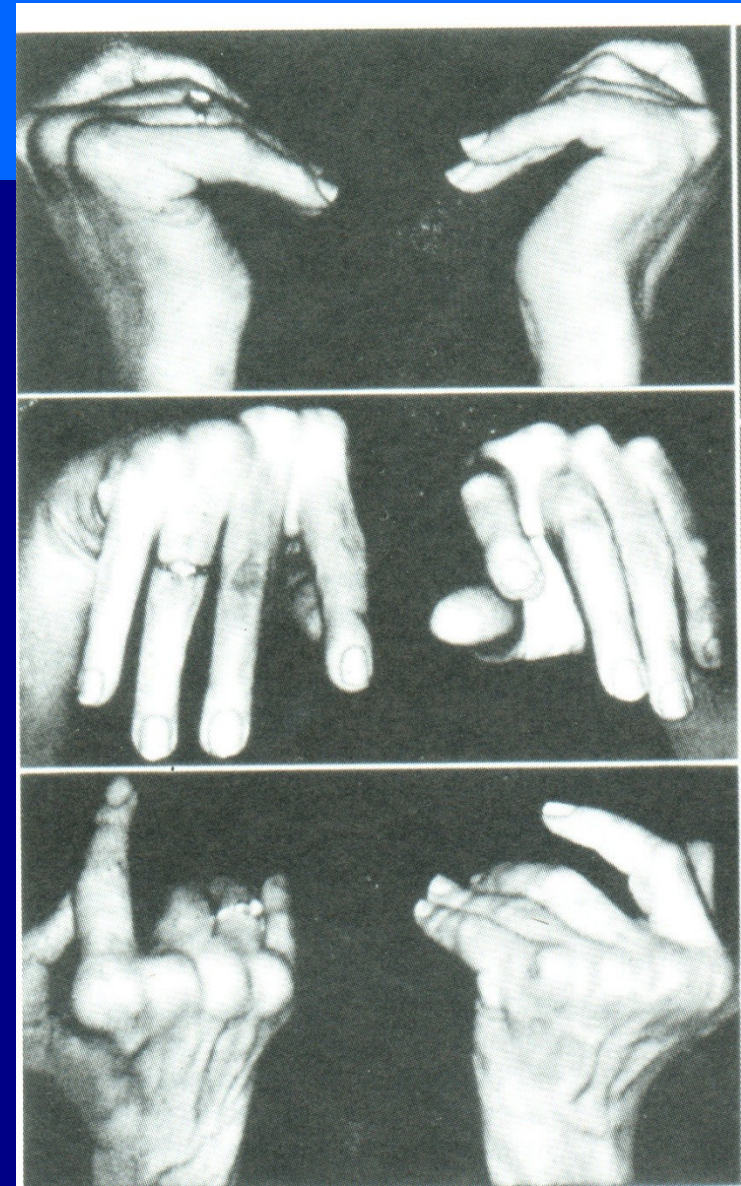
Rheumatoid hand

Complex deformity

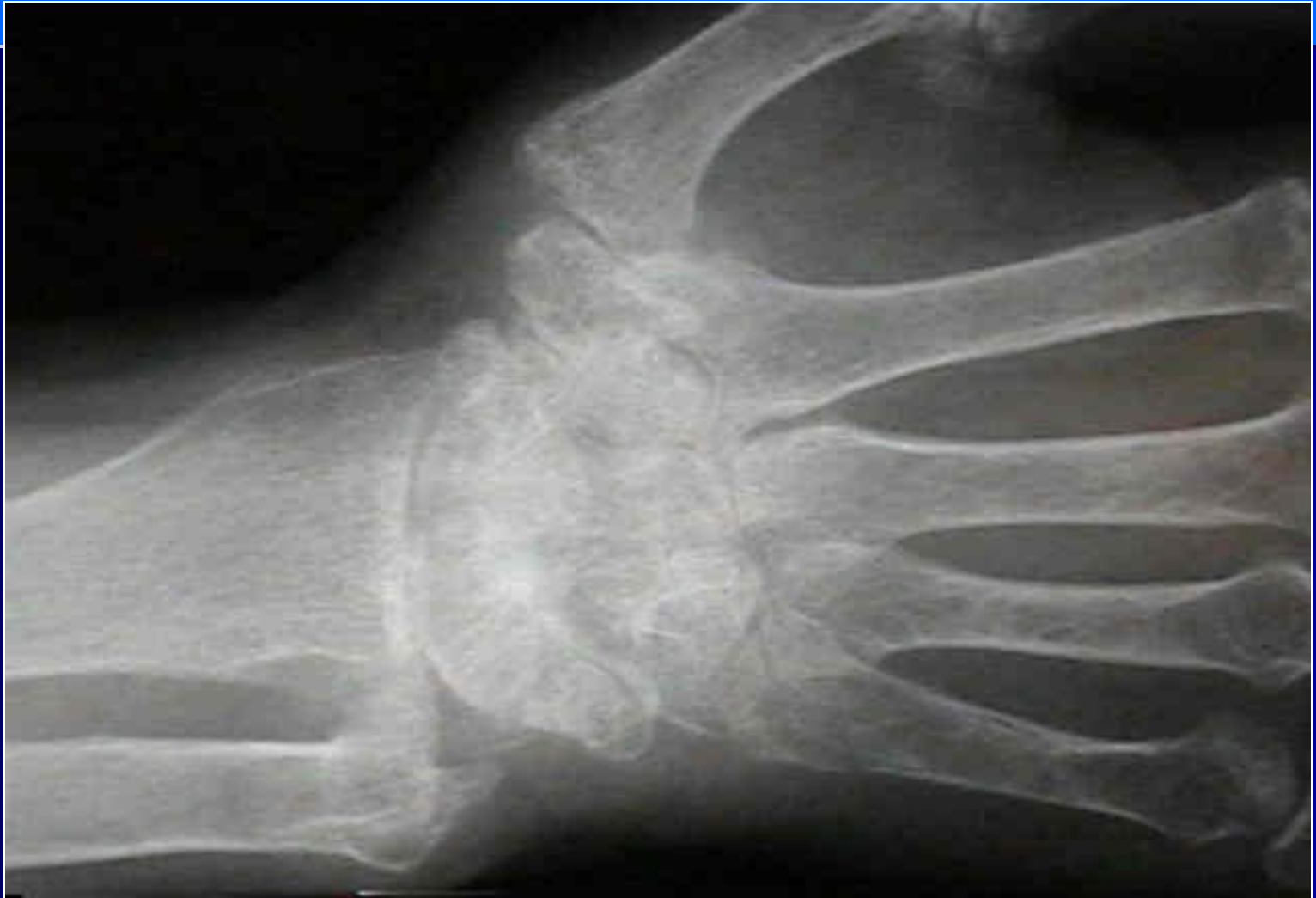

Rheumatoid hand

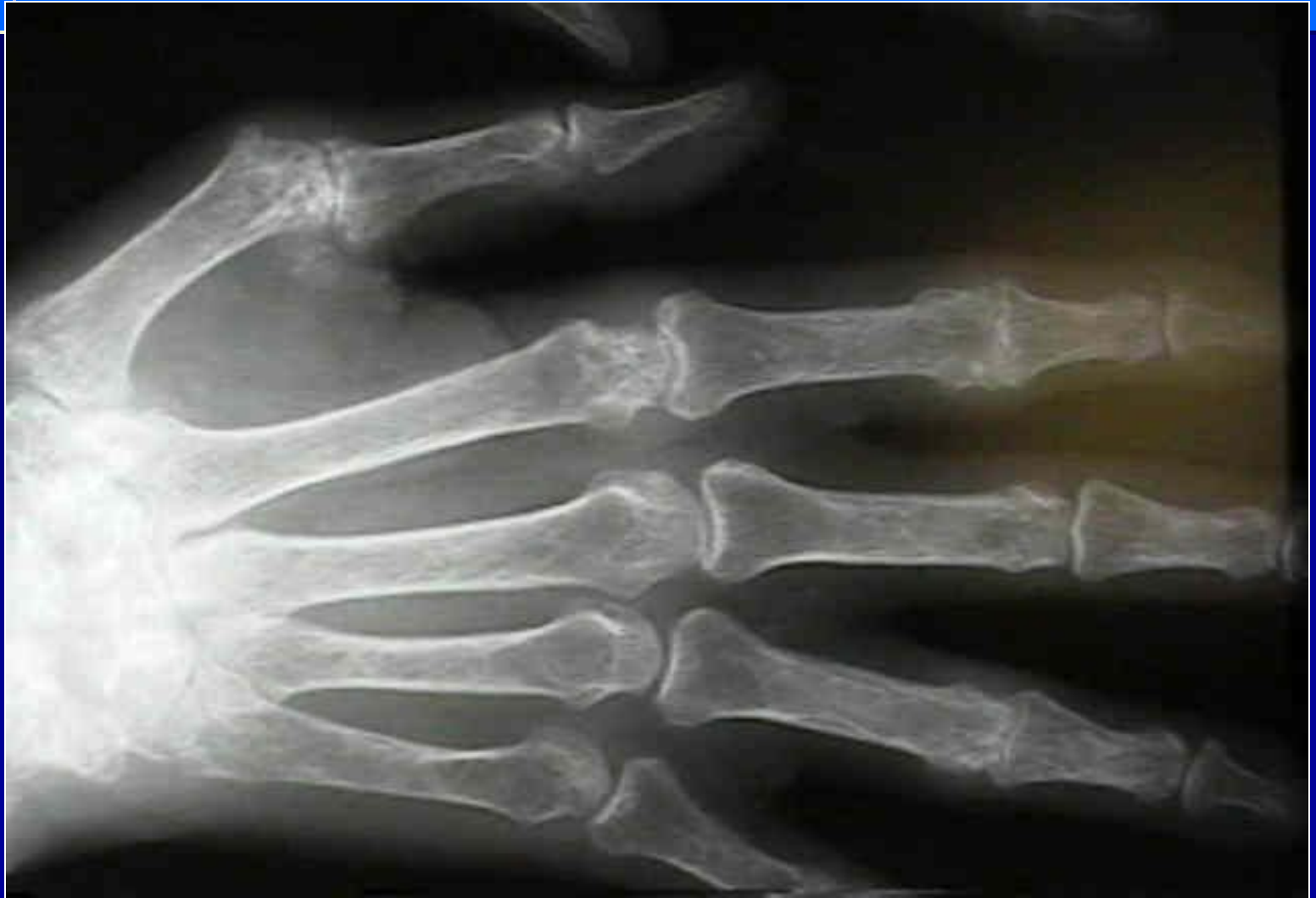Complex deformity



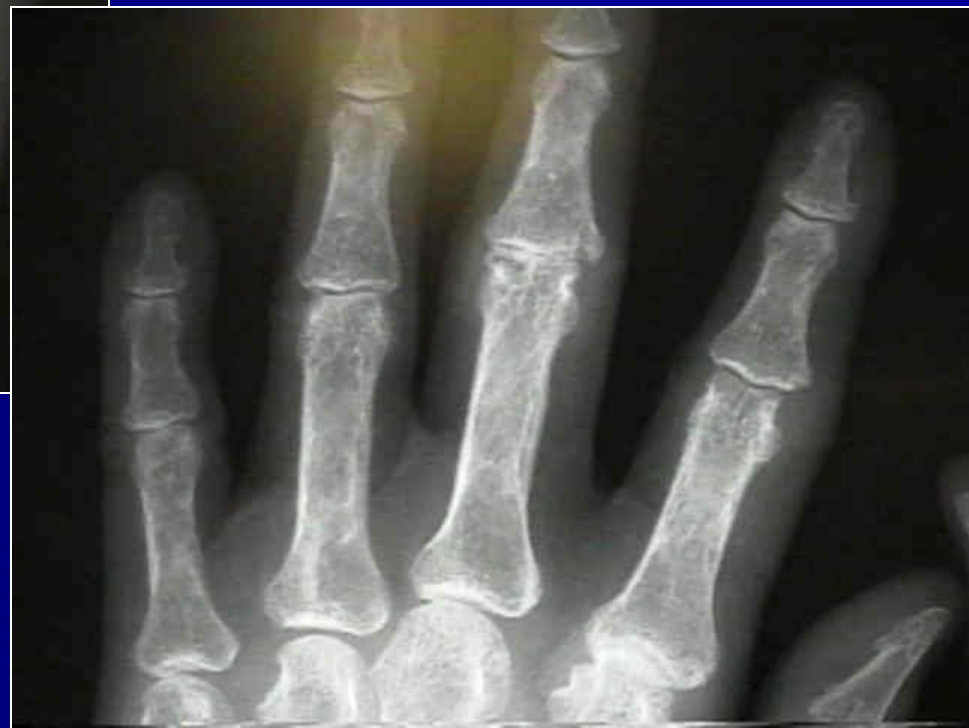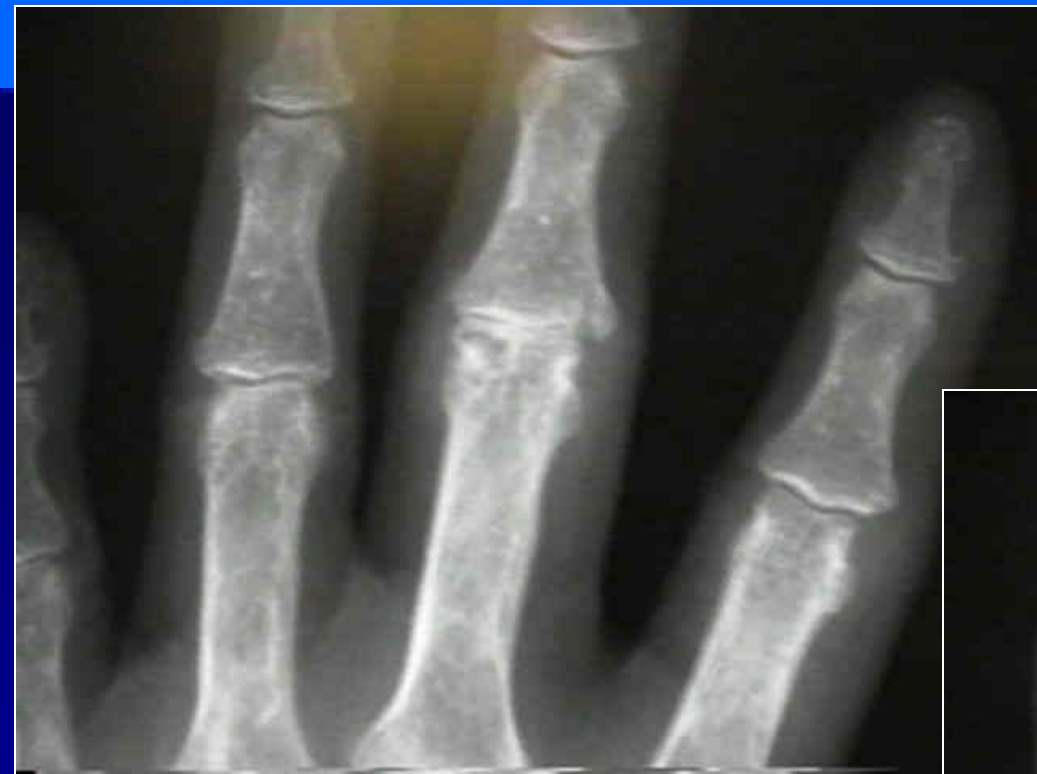R.A.



R.A.

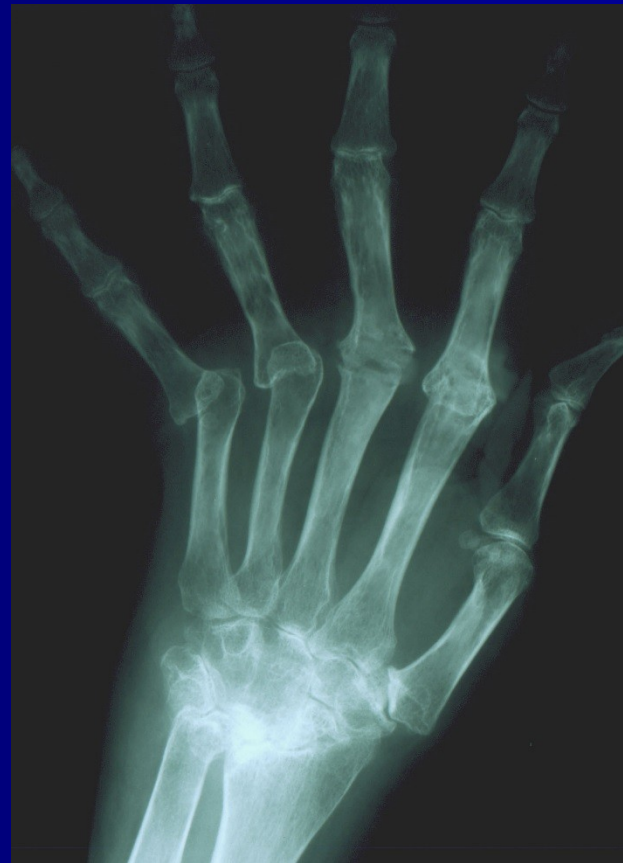

R.A.



Therapy of R.A.

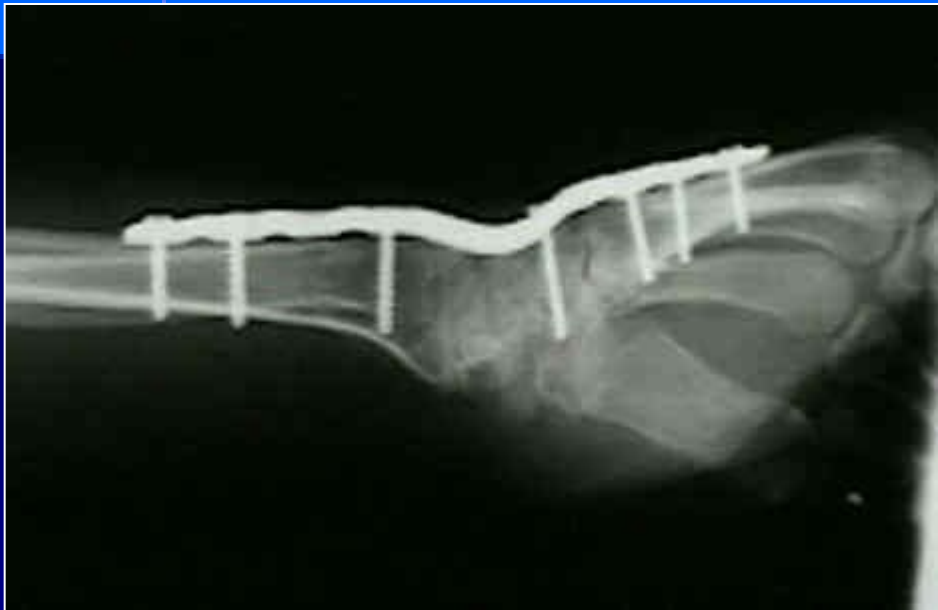
Rheumatology



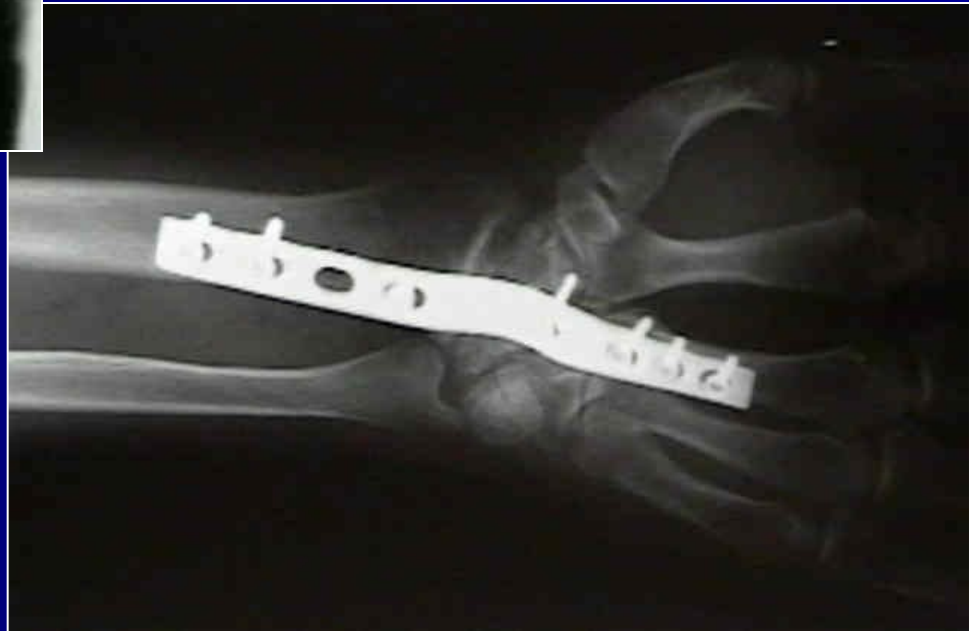Surgery

- synovectomy
- Reconstruction of tendons
- arthroplasty
- arthrodesis
- Artificial joints

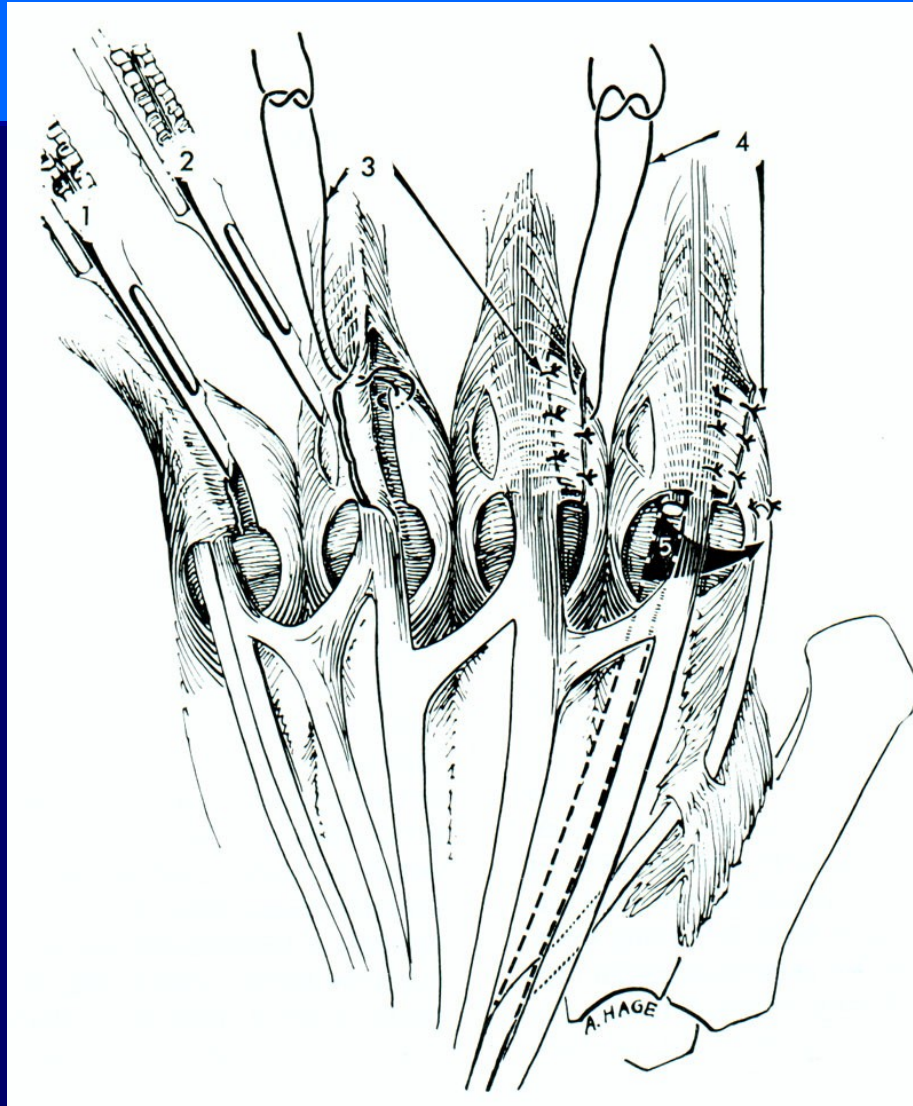
Arthrodesis



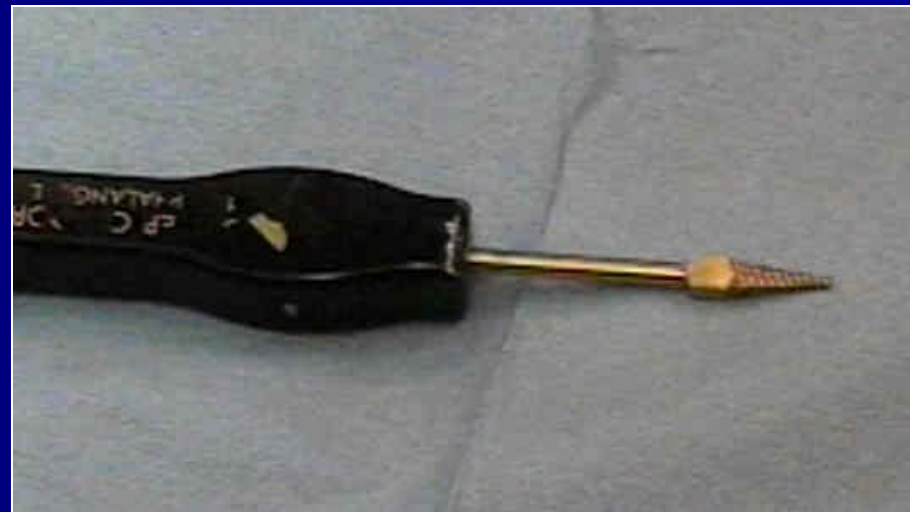- **10-15 st. Dorsiflexion**
- **-10 st. Ulnar deviation**

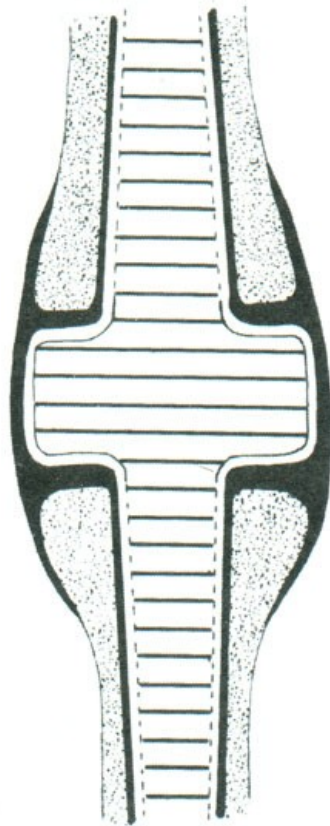

Synovectomy

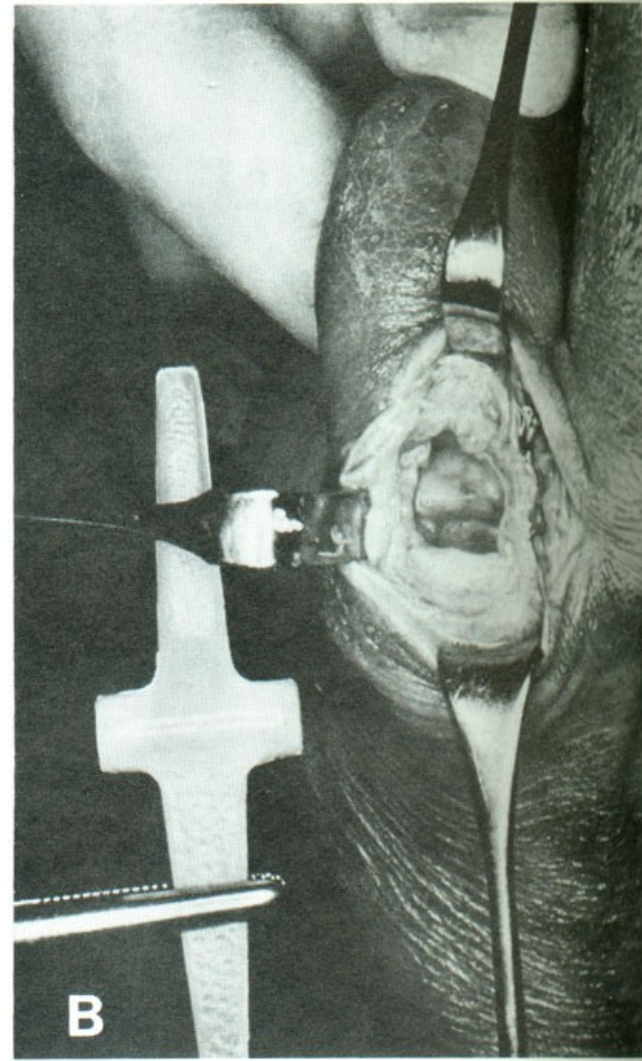


Silastix replacement

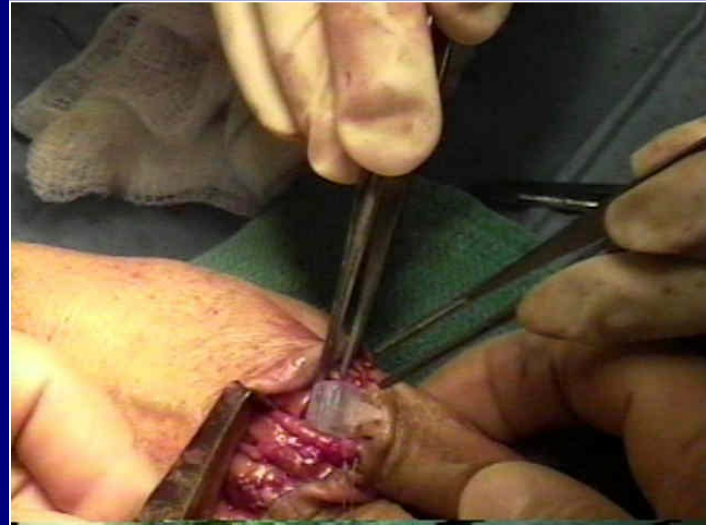
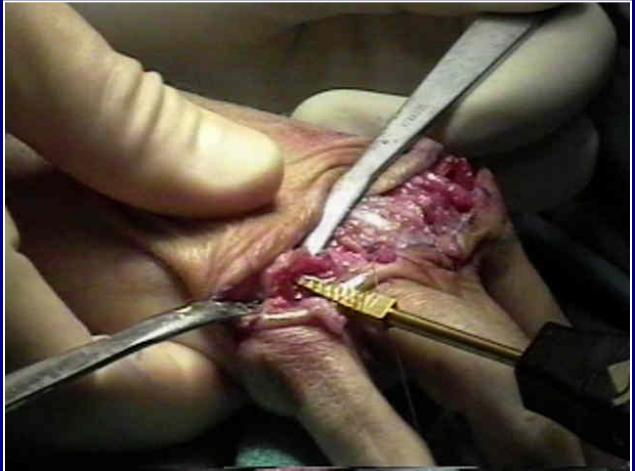
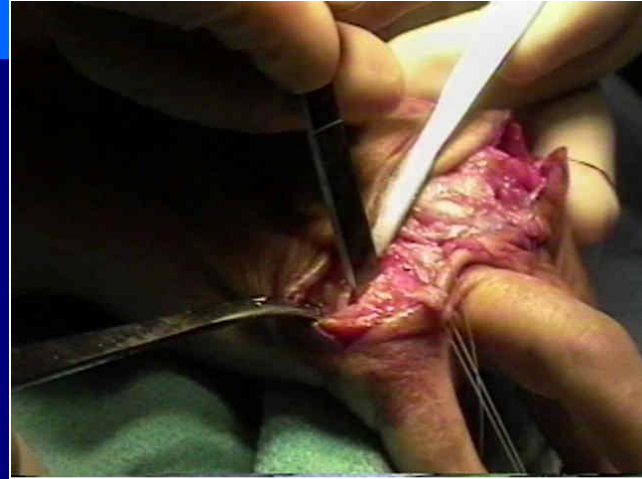
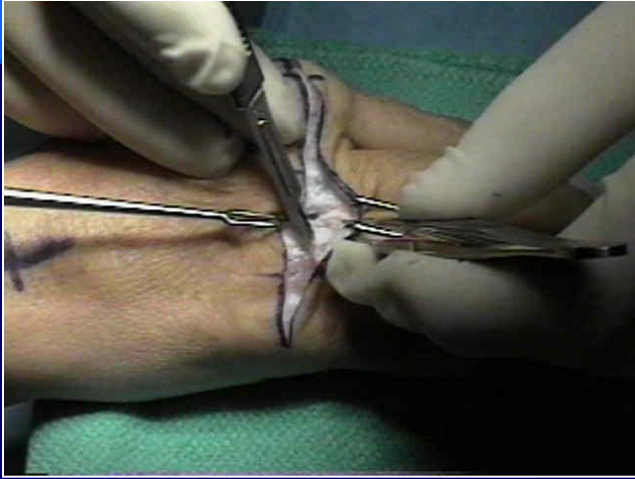



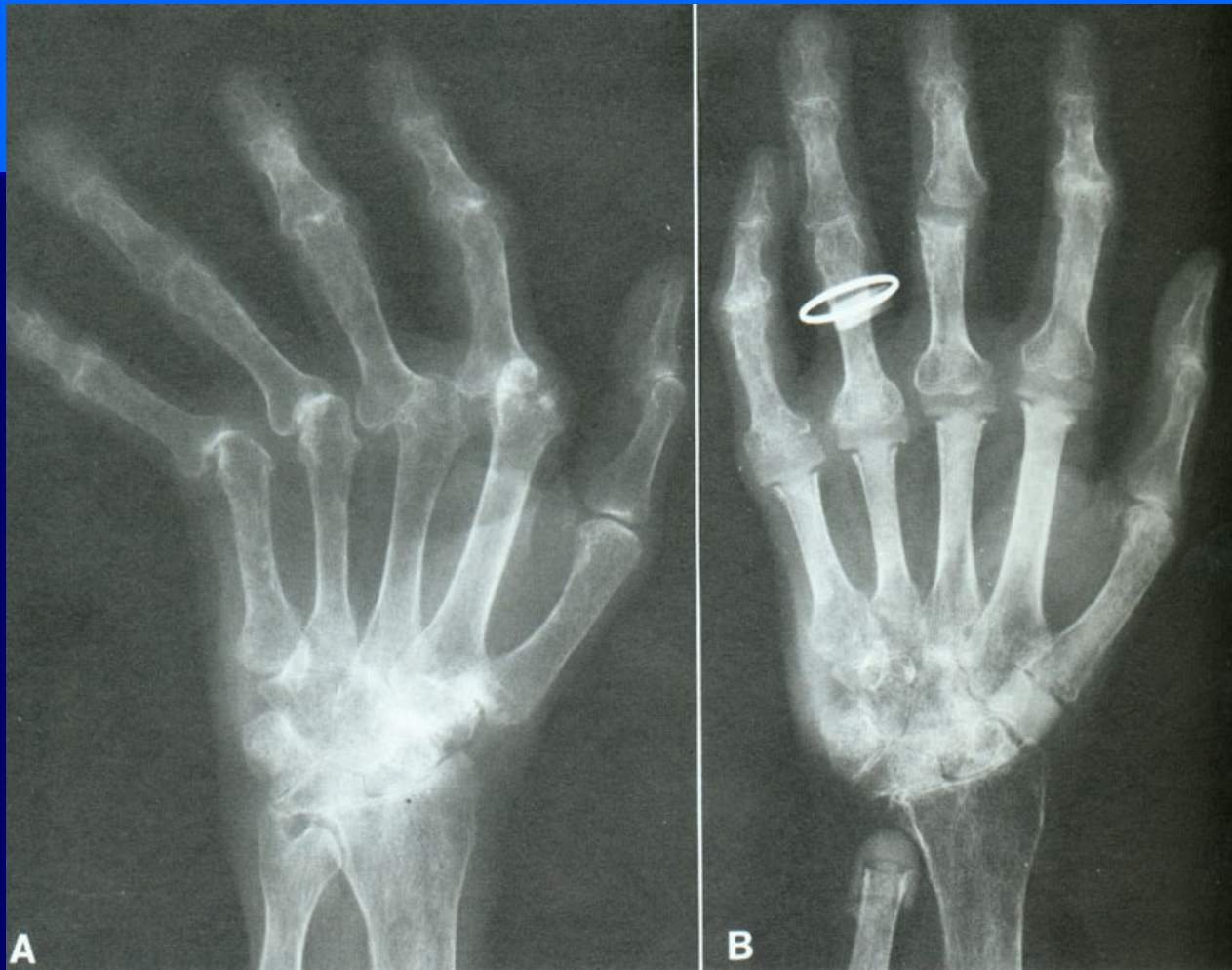
**FIXATION
BY
ENCAPSULATION**



Silastic replacement



Silastic joints



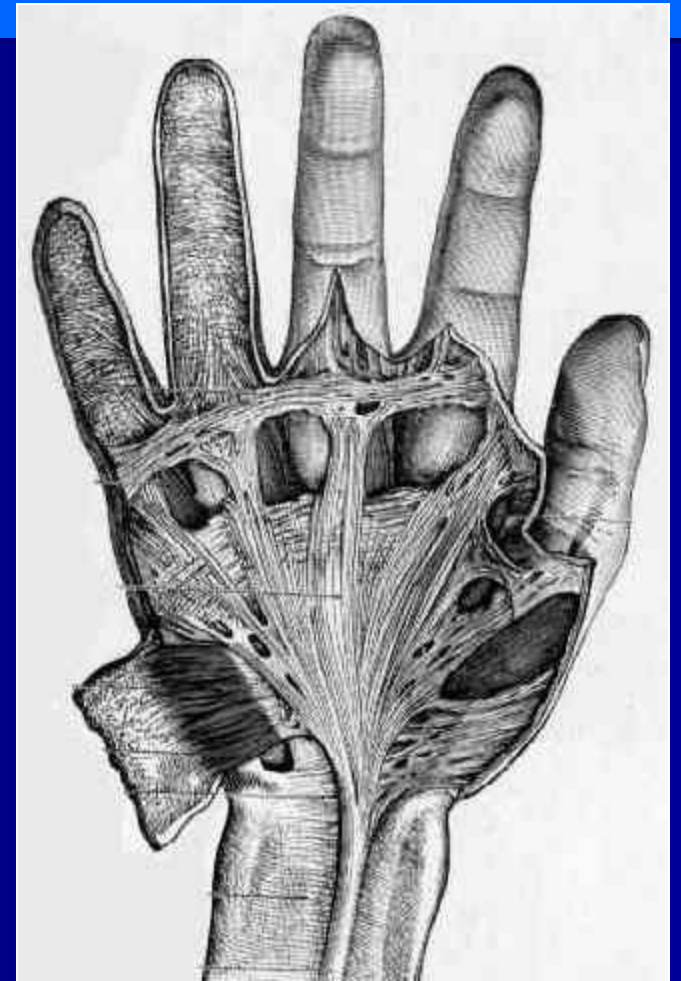
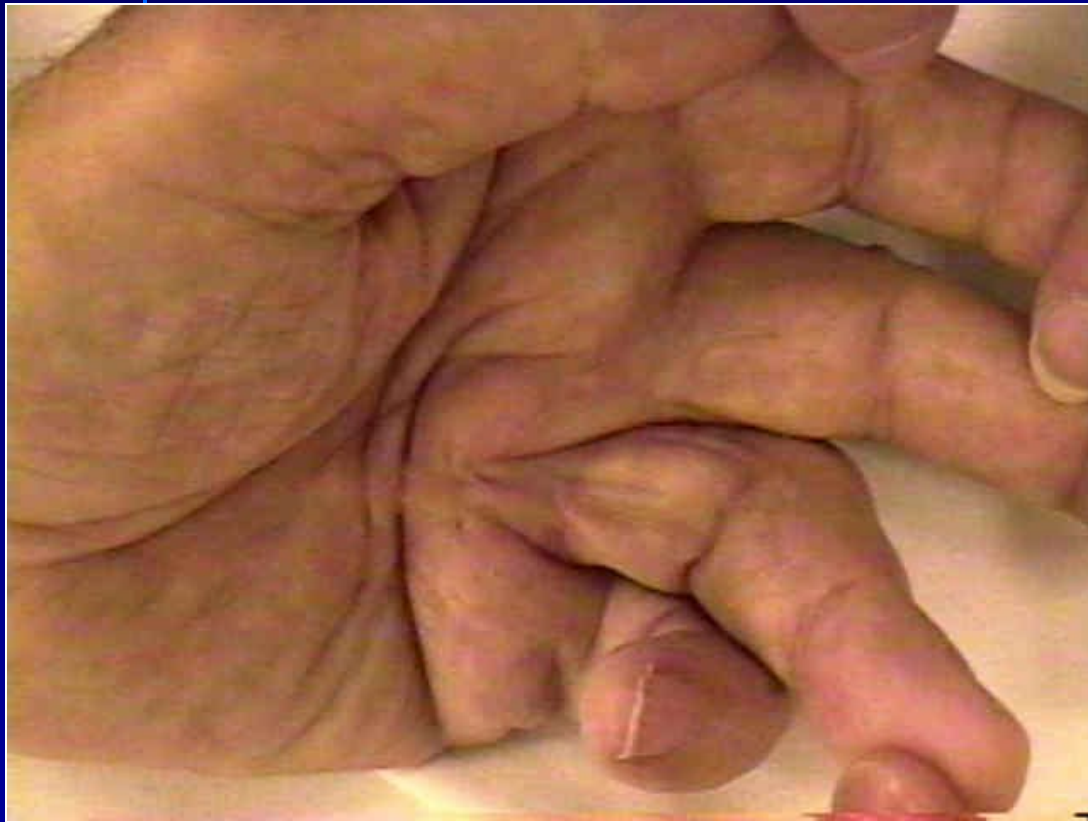A

B

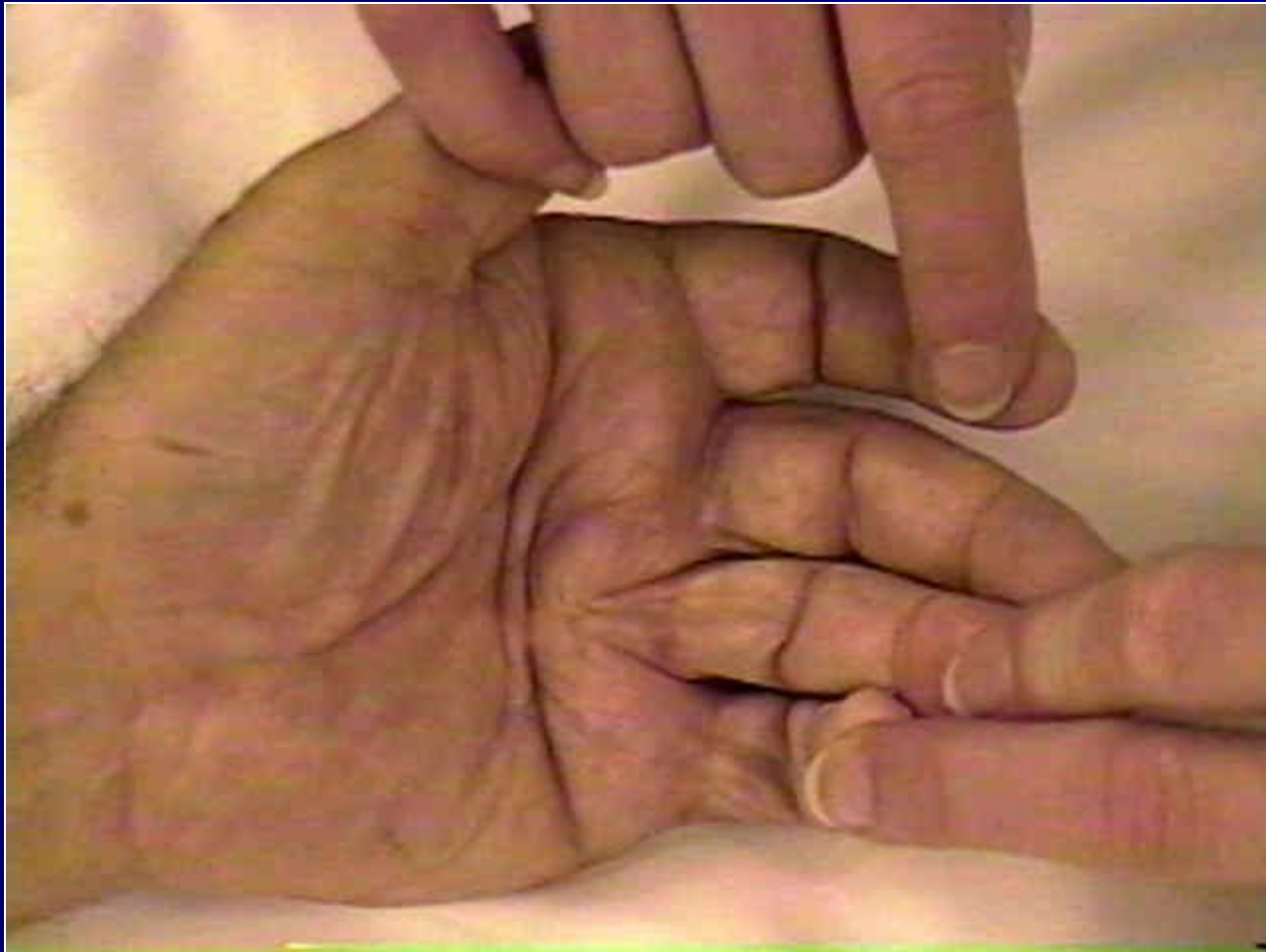
Preop.

Post op

Dupuytren contracture



Dupuytren contracture

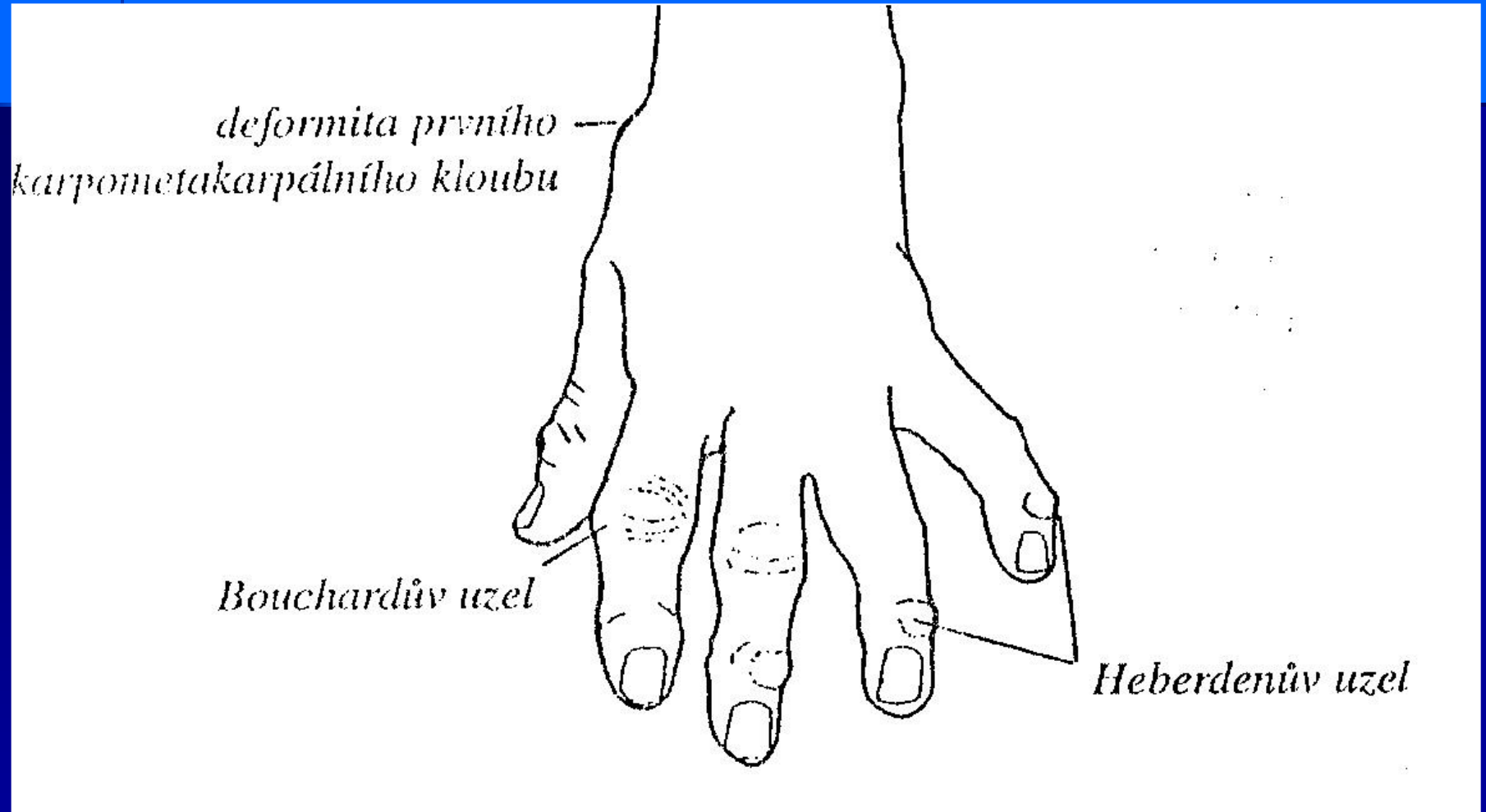


Ganglion

Disorder of joint capsule or tendon sheaths

Therapy: aspiration and steroid locally
surgery

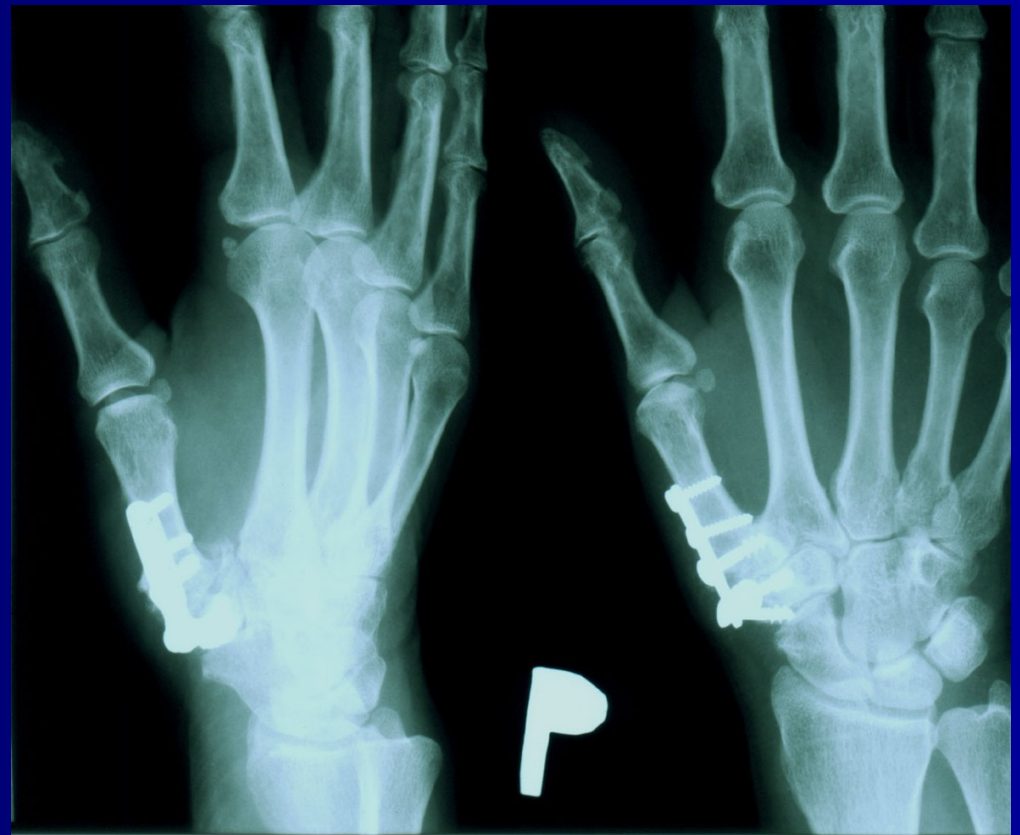Deformity in O.A. in hand



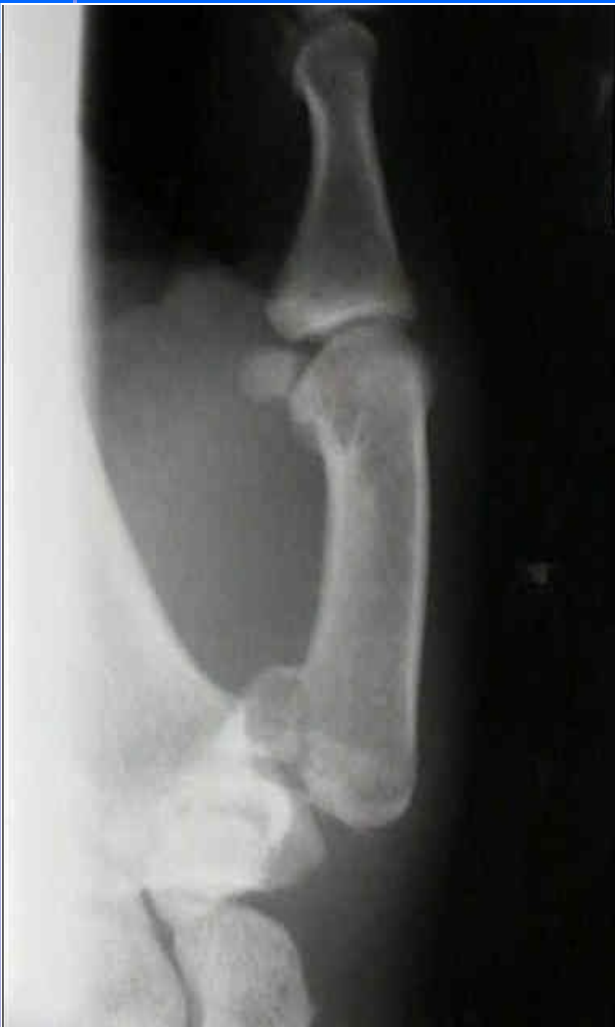Therapy of rhisarthrosis

Conservative

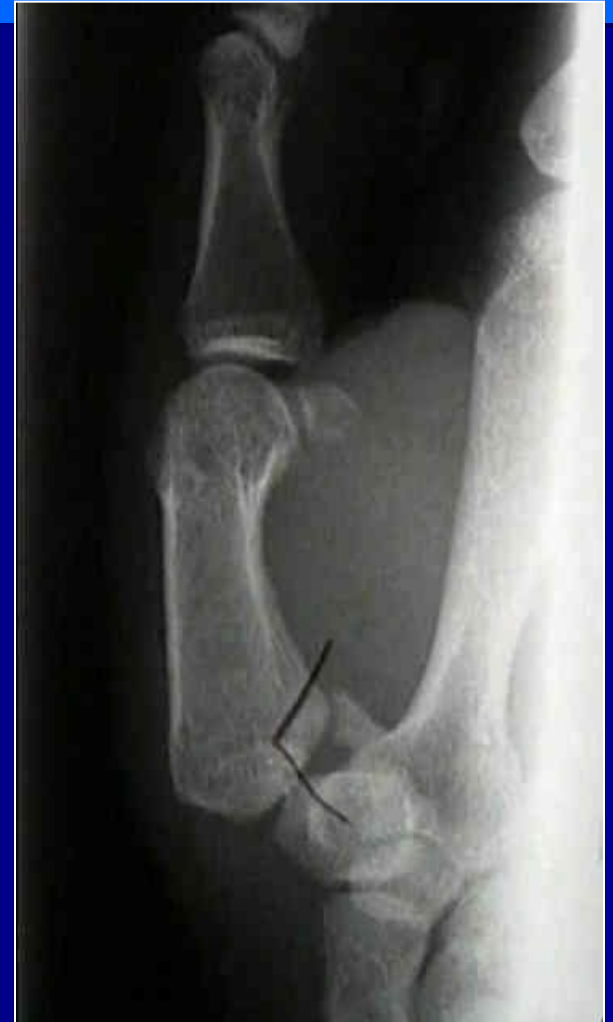Surgical



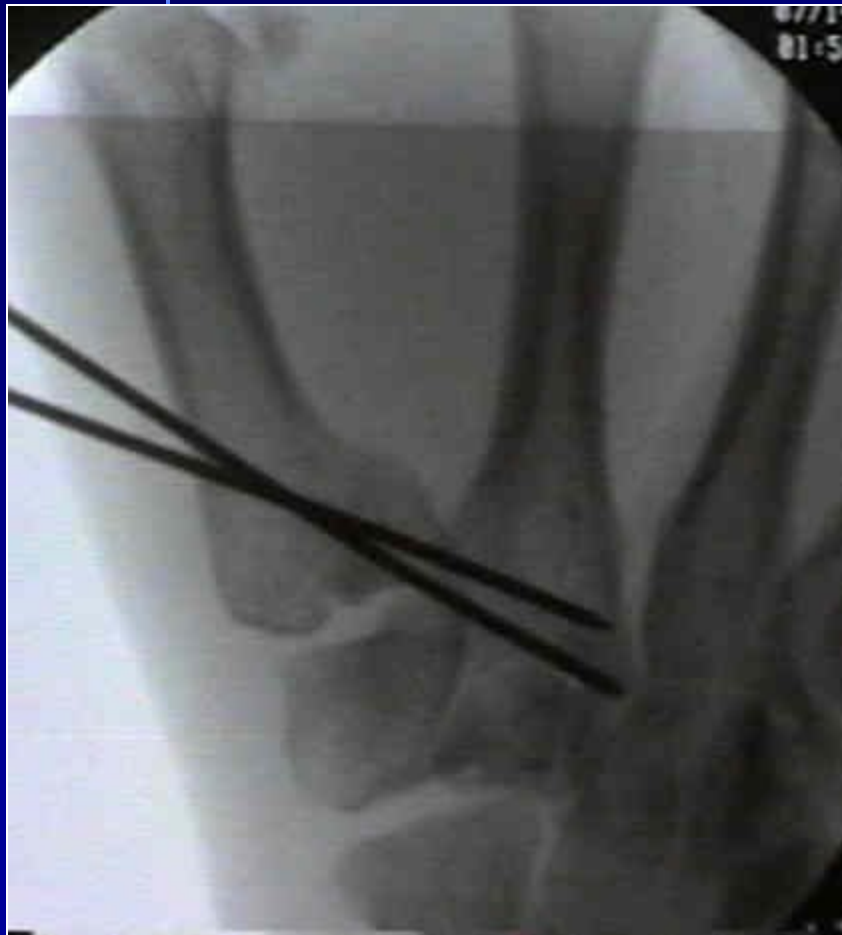Bennett fracture



- Bennett
- fracture

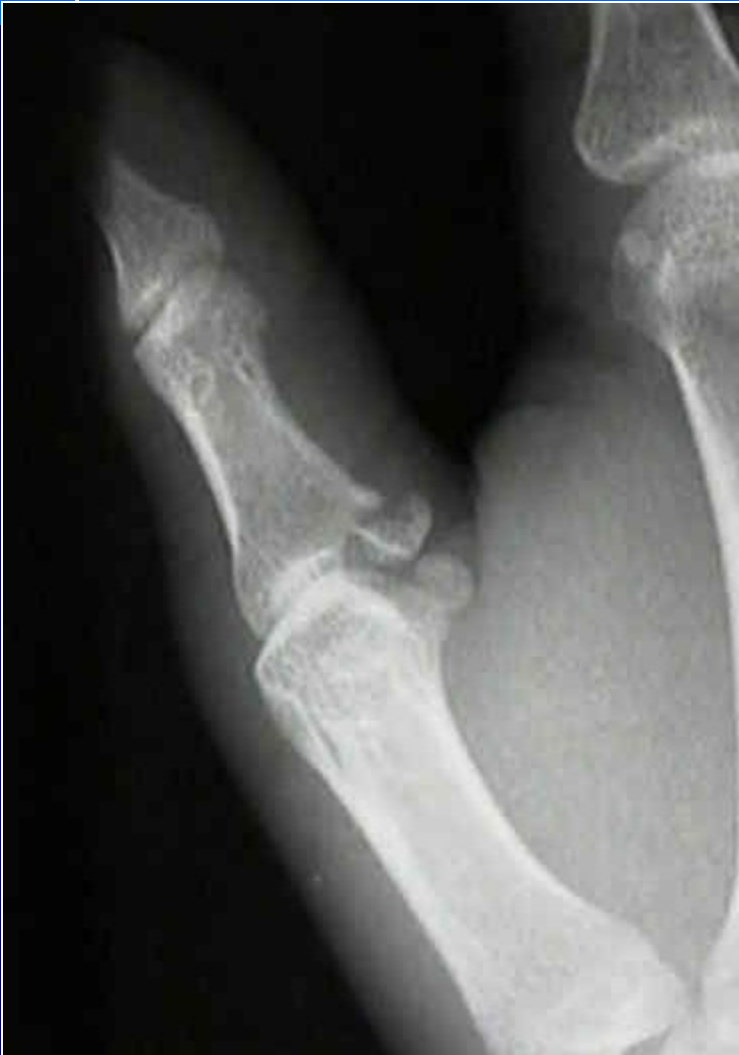

Therapy



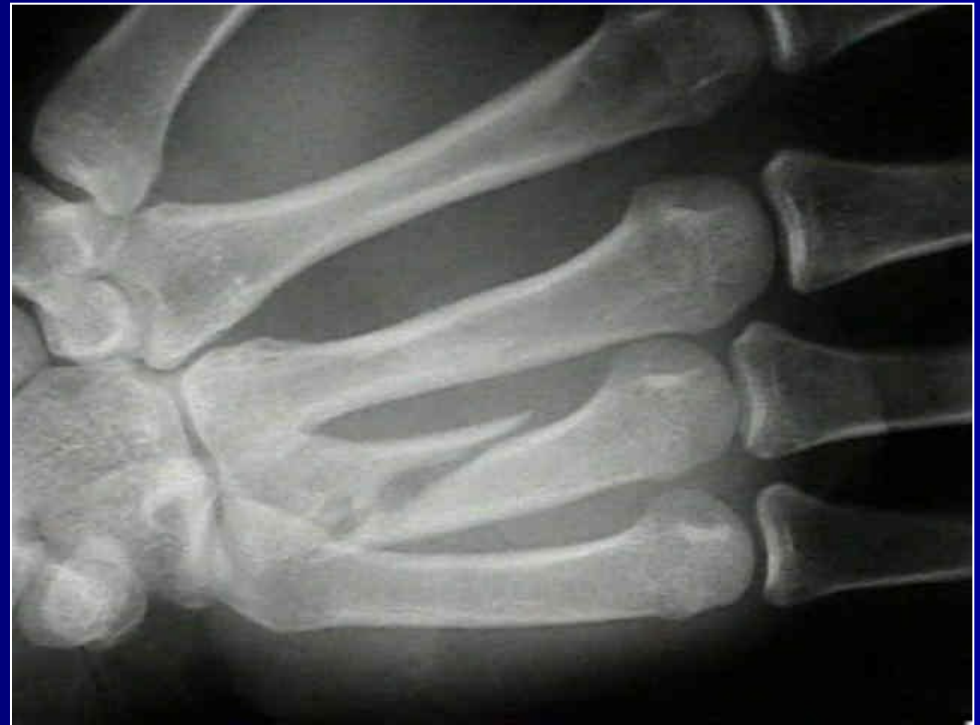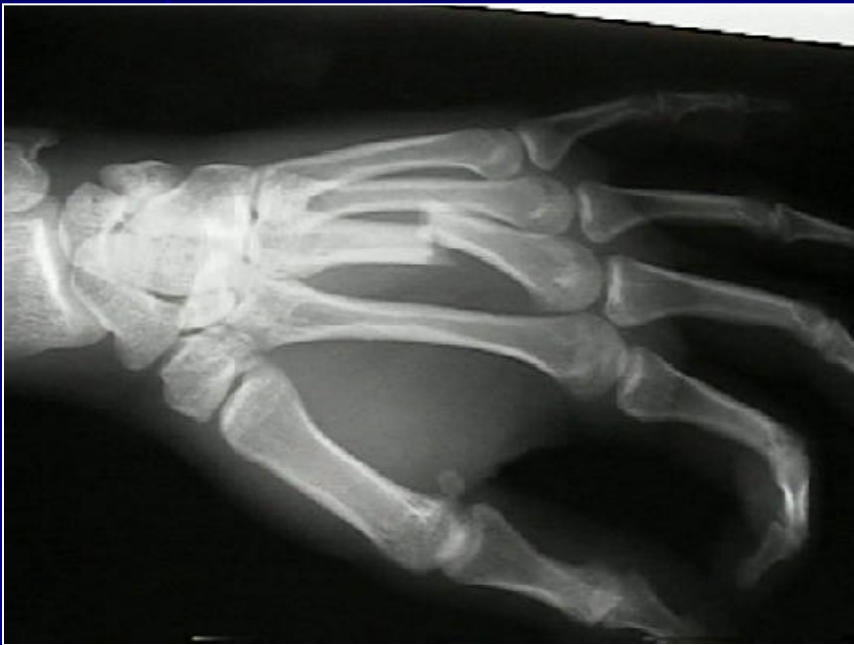- Percutaneous fixation
- ORIF - L splint
 - T splint
 - KW

Skier's fracture



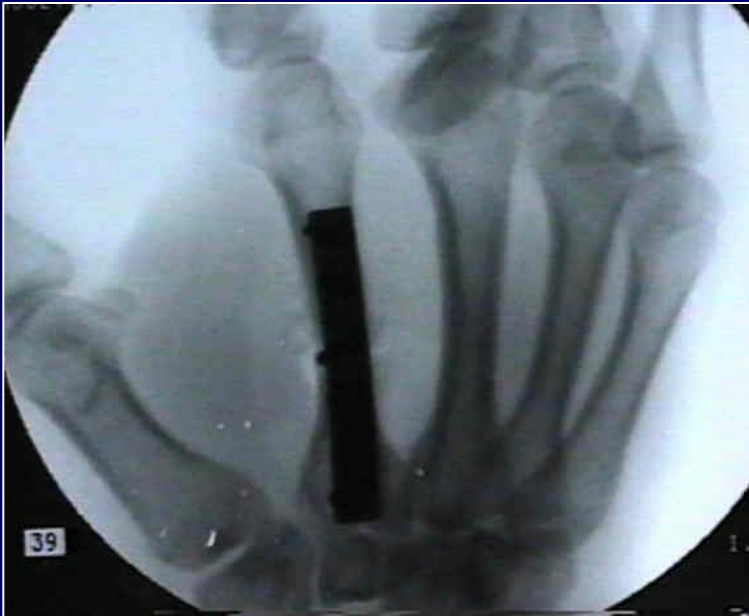- Avulsion fx of the base of proximal phalanx
- -ulnar collateral lig.

Fr. of diaphysis of metacarpal bone

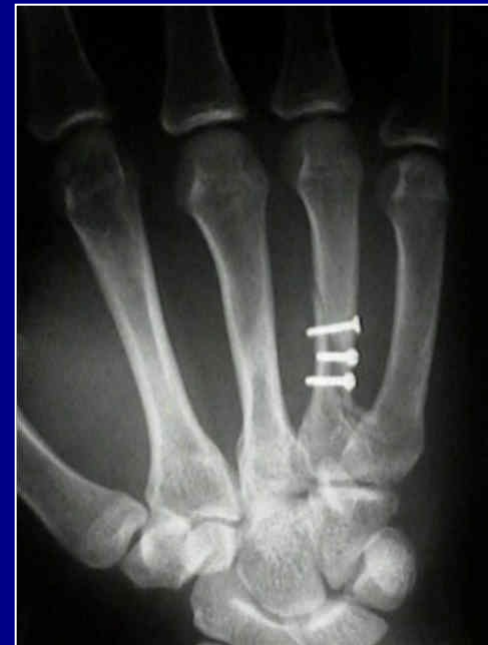

Therapy

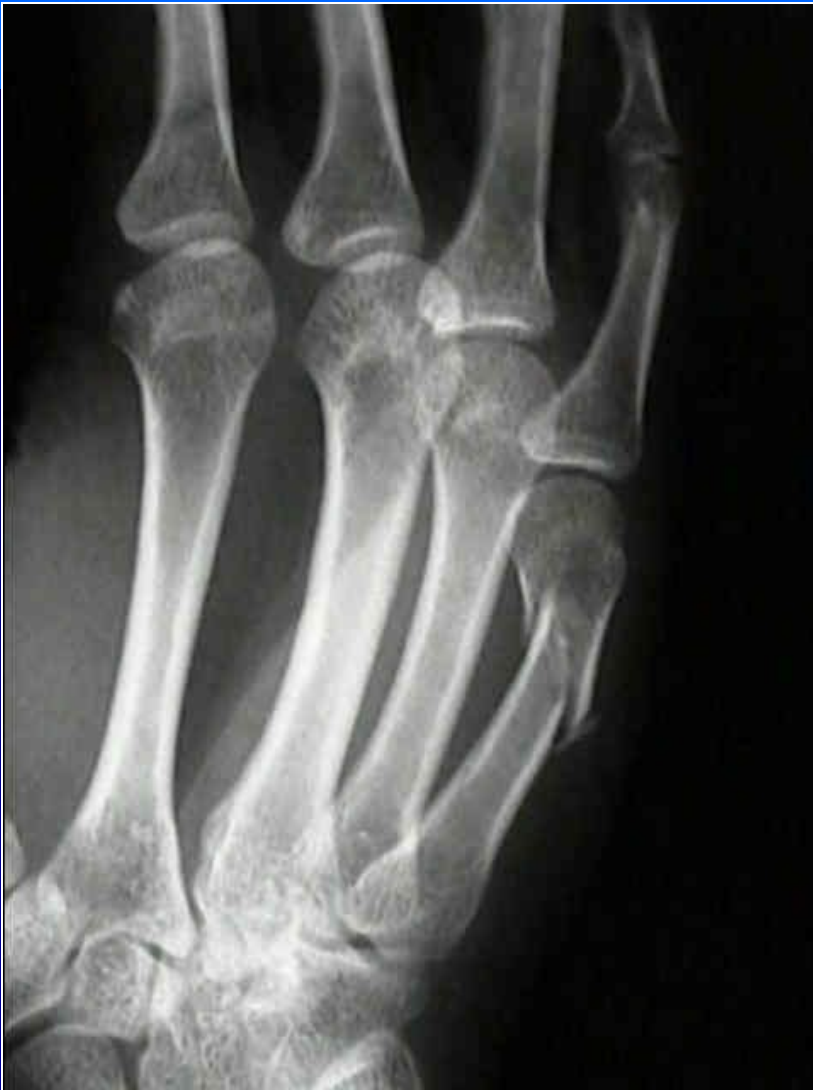ORIF



Screws



Boxer's fracture



- Neck of metacarpal bone with volar dislocation

Arthrodesis of PIP joint

