

# Amputation

Z. Rozkydal

# Amputation

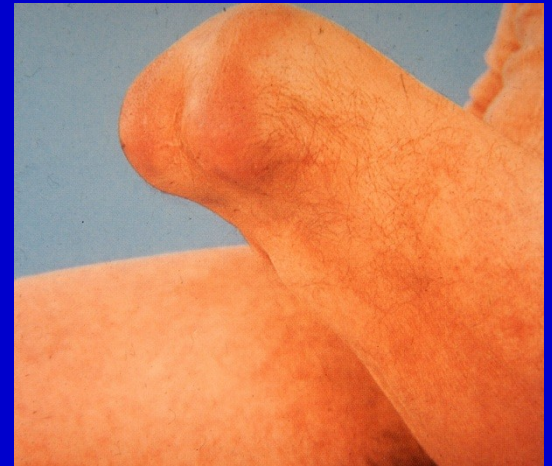Removal of periphery part of the limb at a level of the bone



Obr. 1. Amputation in the calf

# Disarticulation

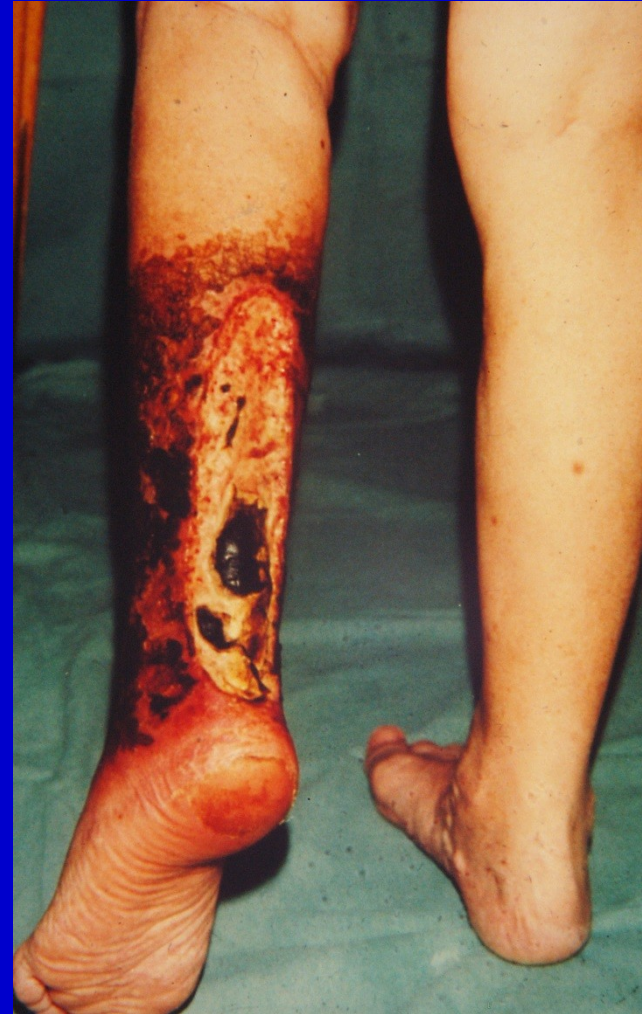Removal of periphery part of the limb at a level of the joint



Obr. 2. Disarticulation in the knee joint

# Indications

- Severe ischemia
- Severe trauma
- Infection with sepsis
- Malignant tumors
- Congenital diseases
- Neuropathies leading to deep trophic ulcers



Obr. 3. deep necrosis in the calf

# Preop. assessment

Individual access

Angiography

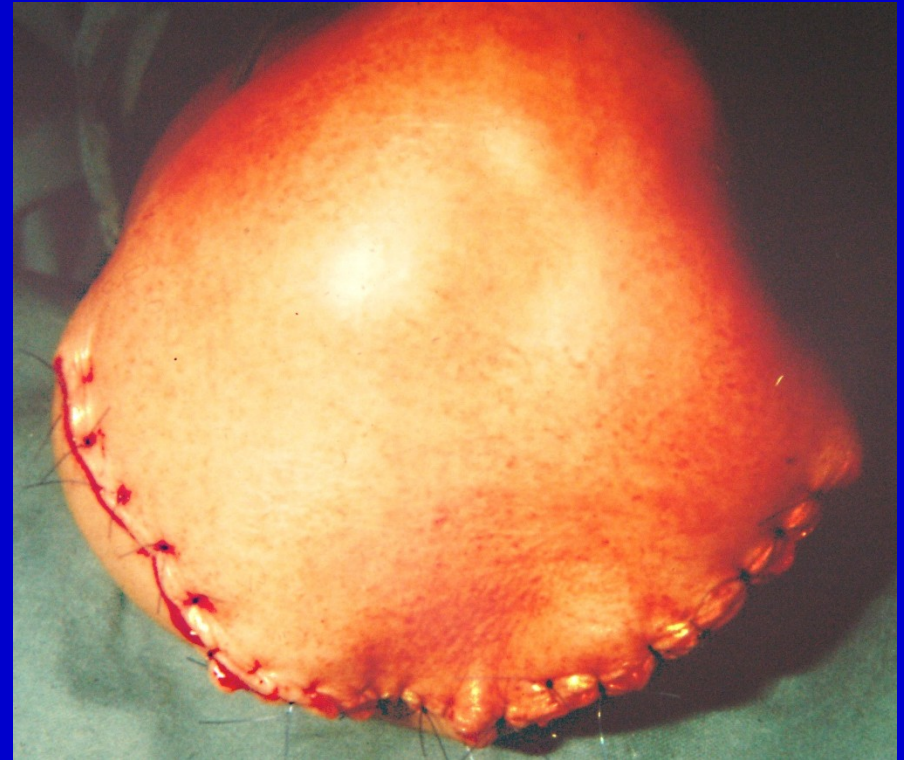General condition

Occupation

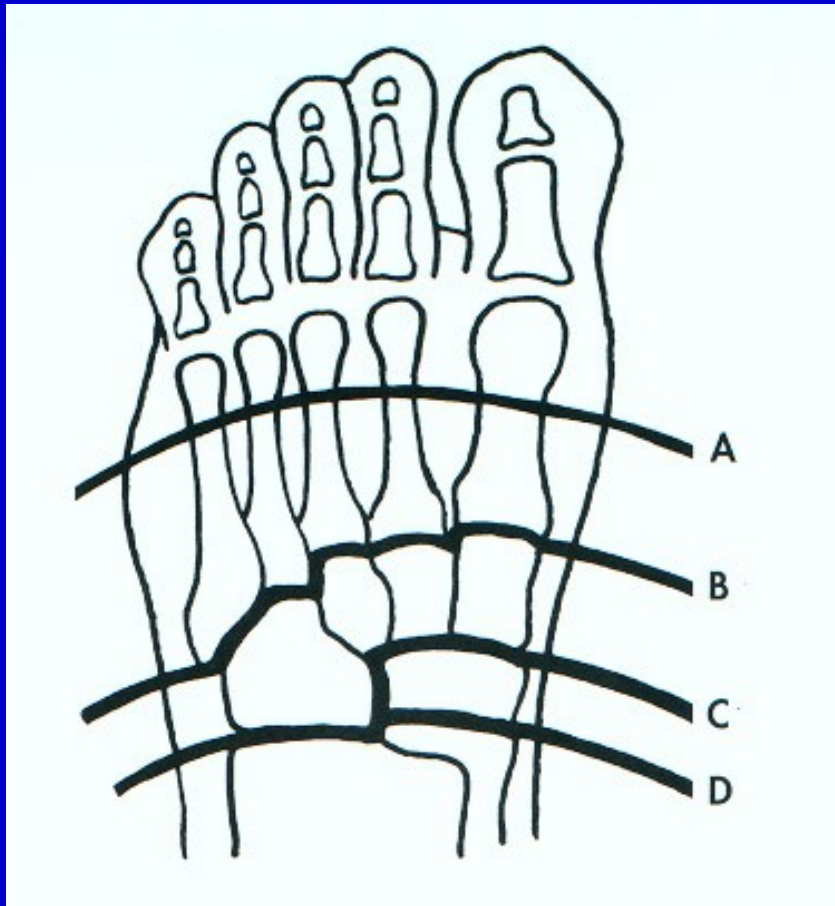
Level of amputation- consultation

# Technique

- Turniquet
- Safe surgical approach
- Carefull ligating of vessels
- Myoplastic surgery
  - suture of muscles end to end
- Dreinage of the wound
- Enough soft tissues
- Good skin coverage



# Amputation in the foot



Phalanx

Toes

A- Metatarsals- Sharp

B- Lisfranc

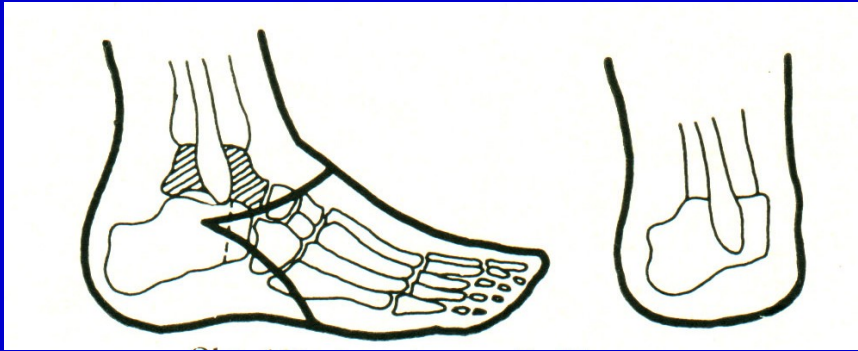
C- Bon-Jäger

D- Chopart

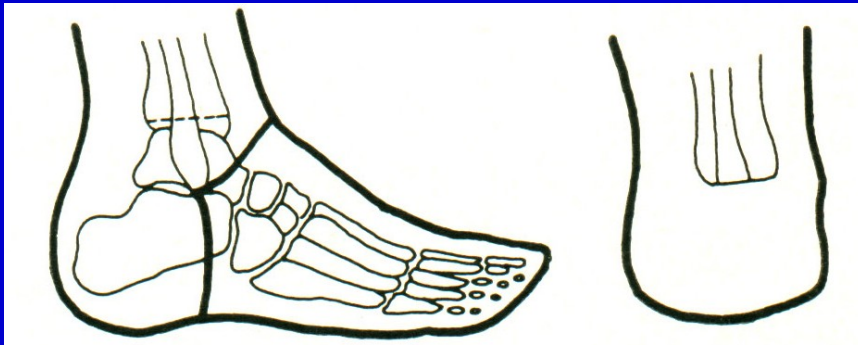Level of amputation in the foot



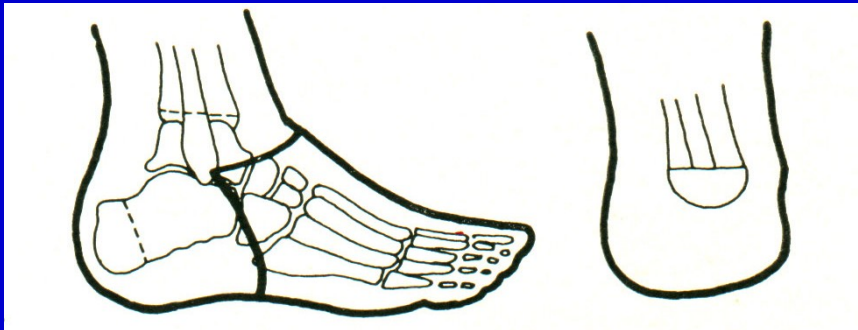# Amputation in the foot and in the ankle



Pirogov

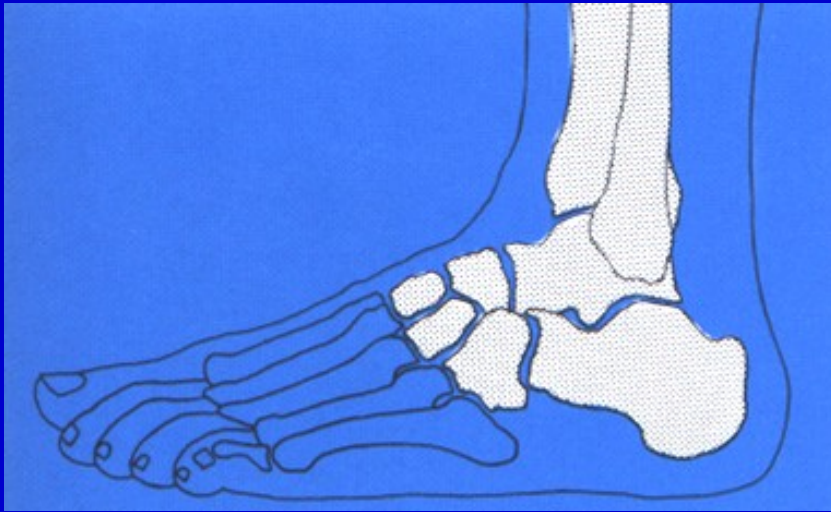


Syme

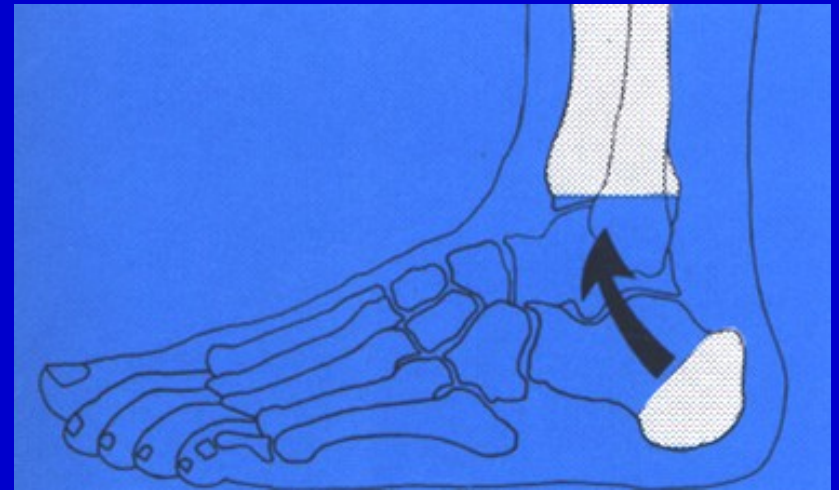


Boyd

# Amputation in the foot and the ankle



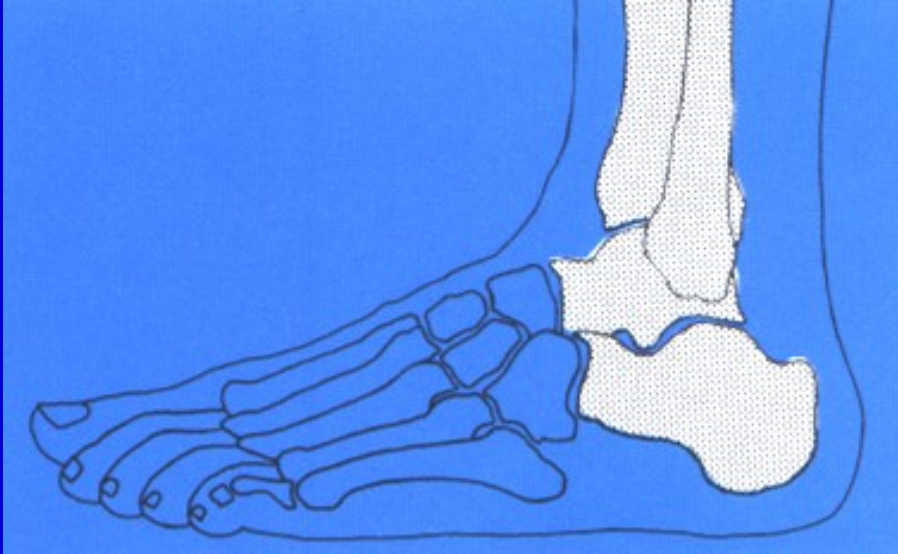
Amputation in Lisfranc joint



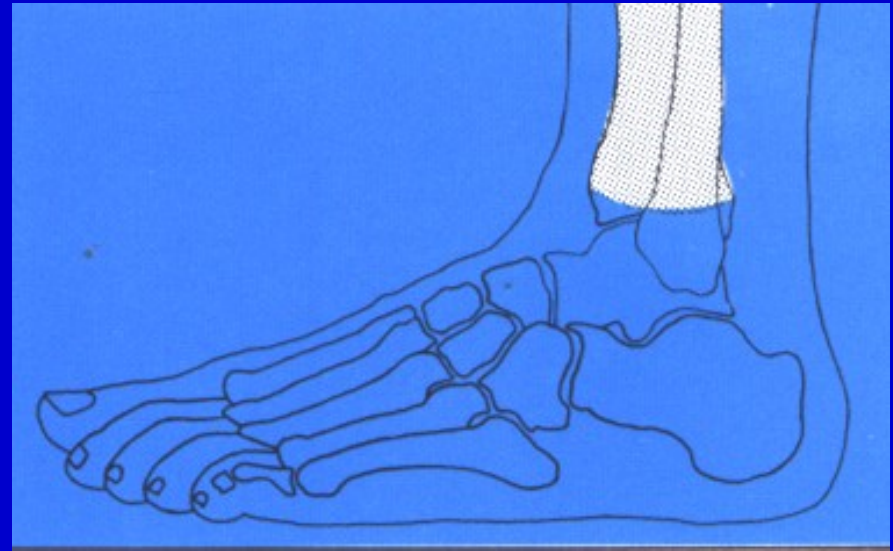
Pirogov amputation



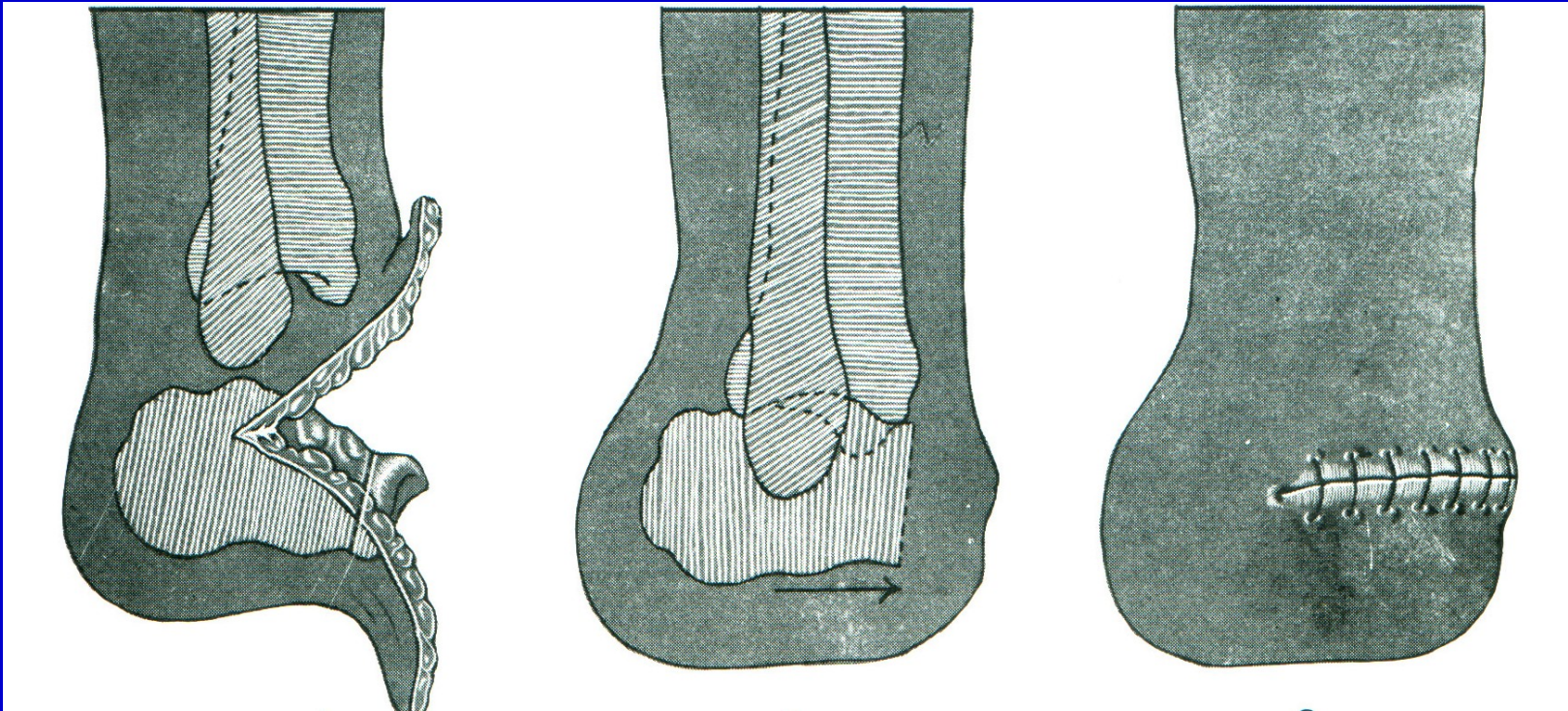
# Amputation in the foot and the ankle



Amputation in Chopart joint



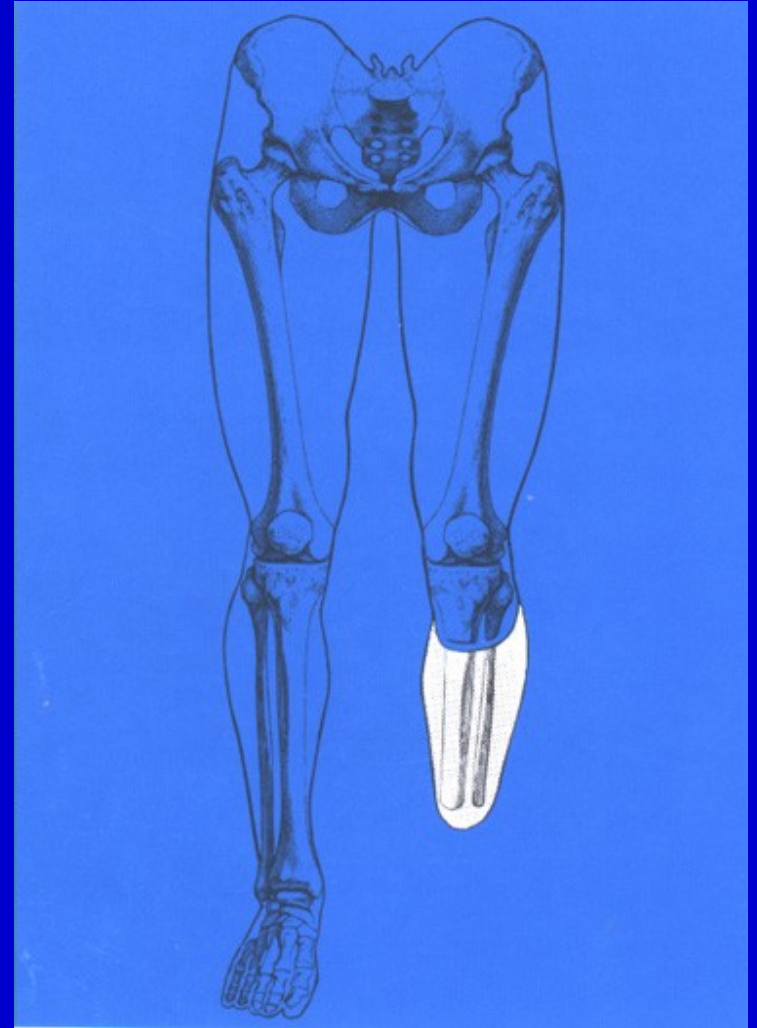
Syme amputation



Boyd amputation

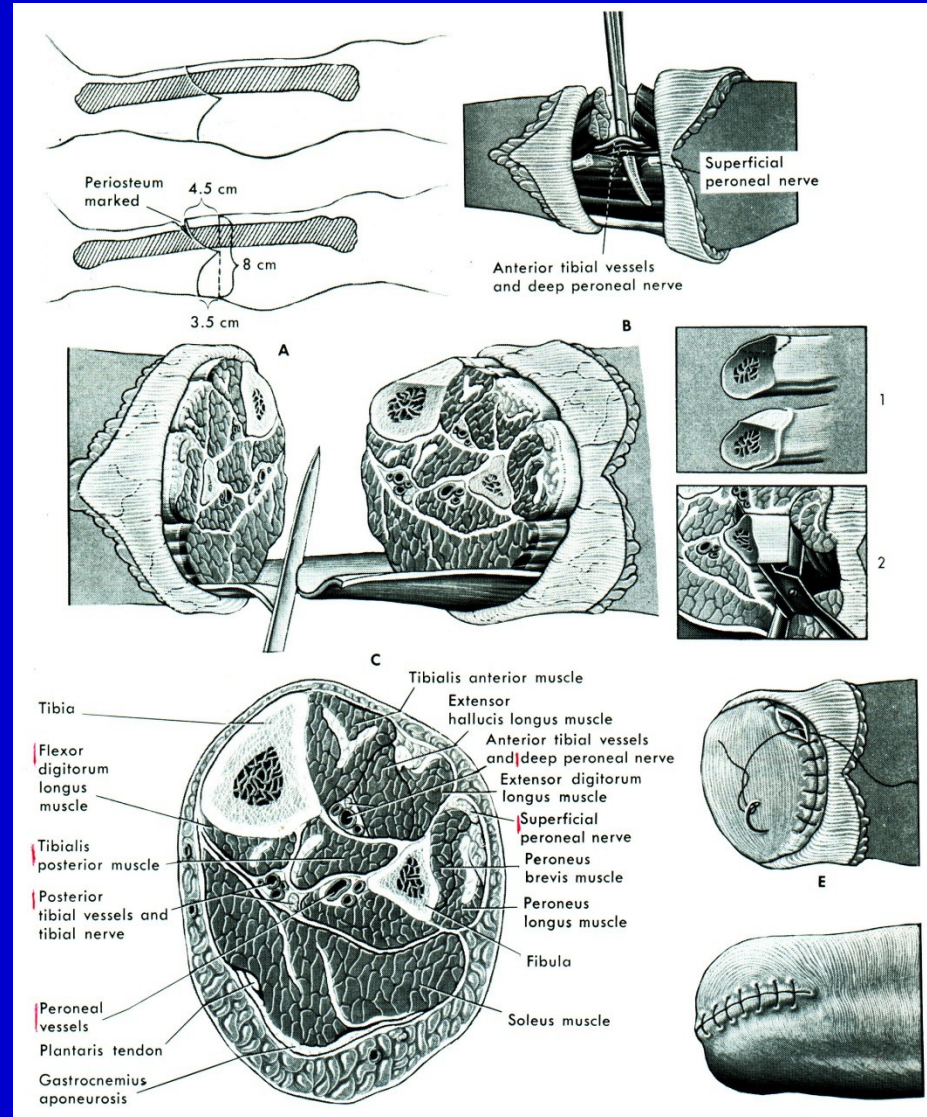
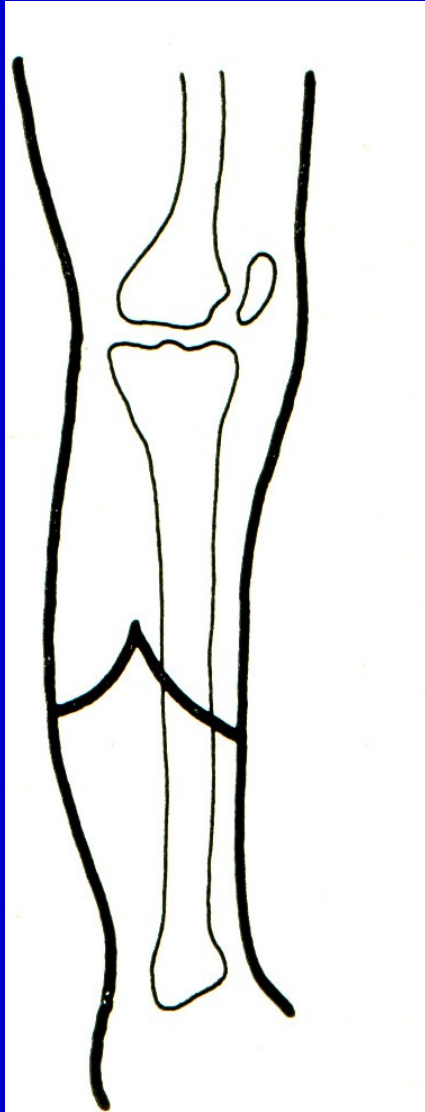
# Bellow knee amputation

8-15 cm bellow knee joint line



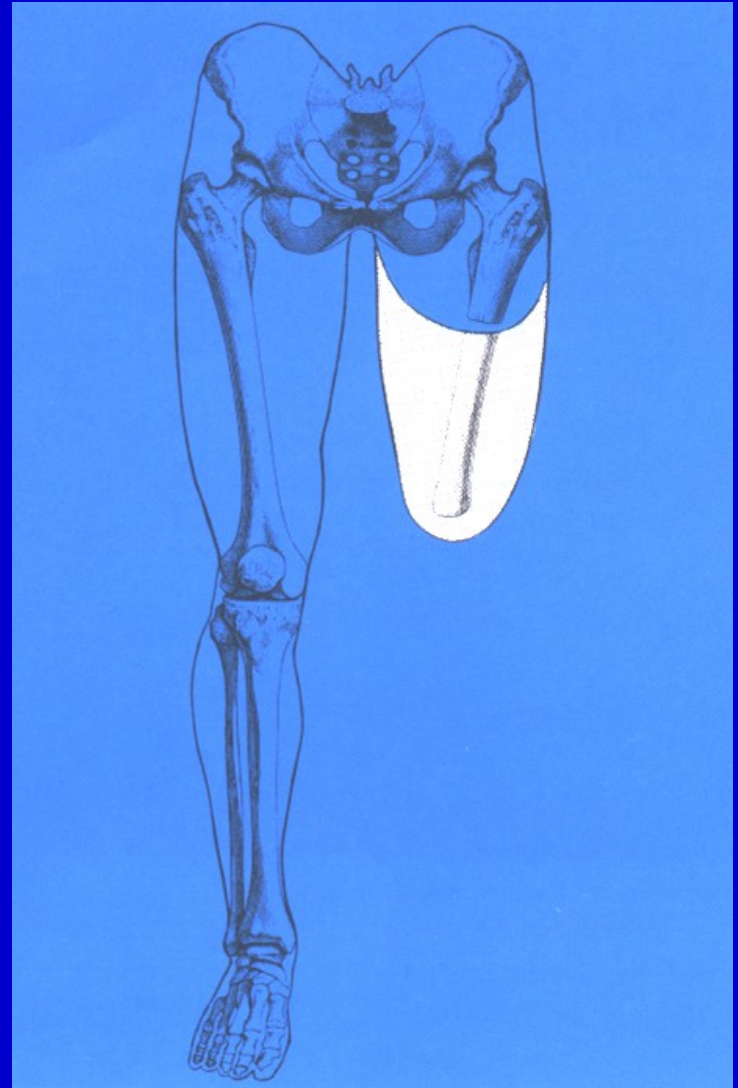


# Bellow knee amputation

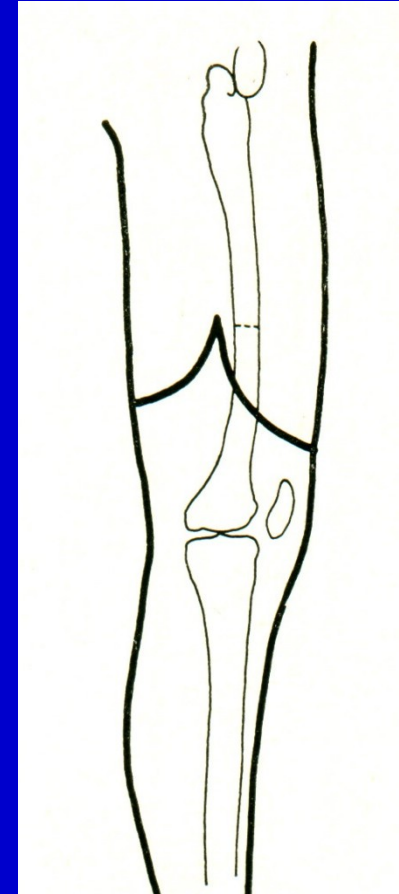
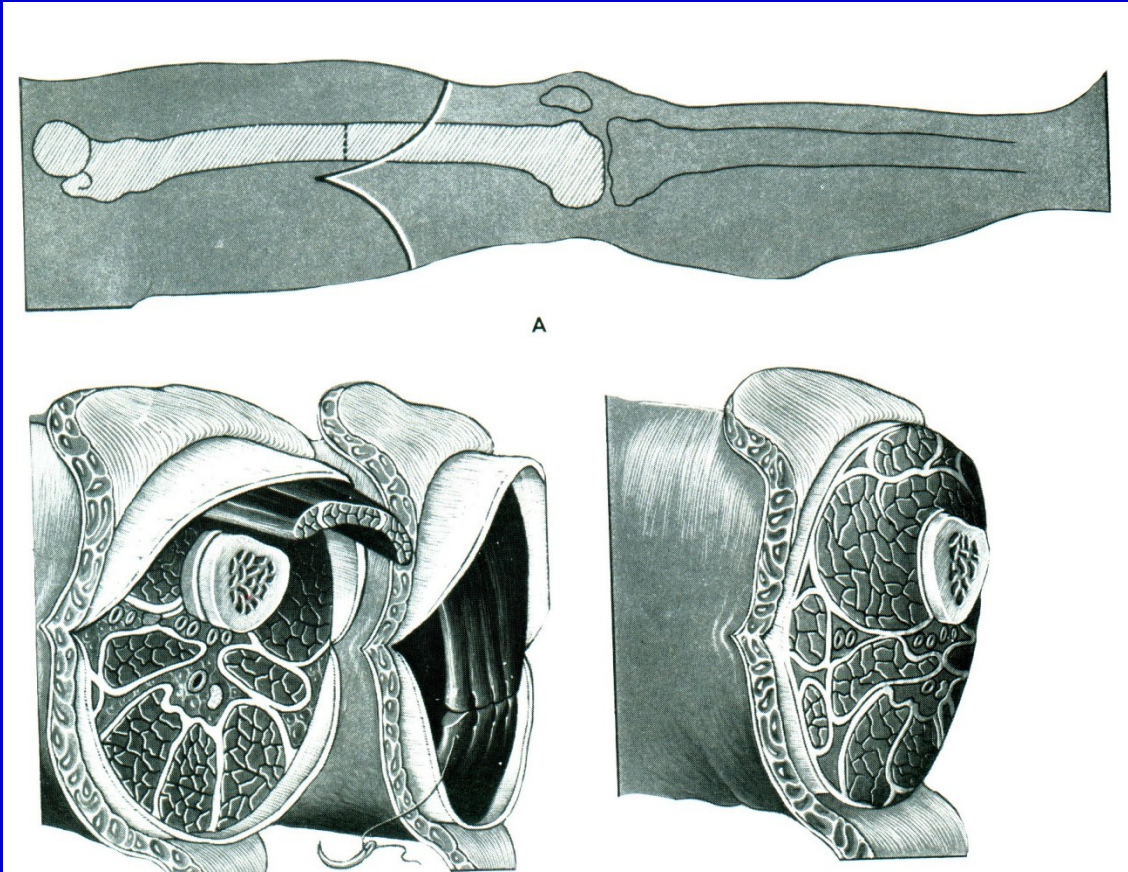


# Above knee amputation

In the middle third of the thigh

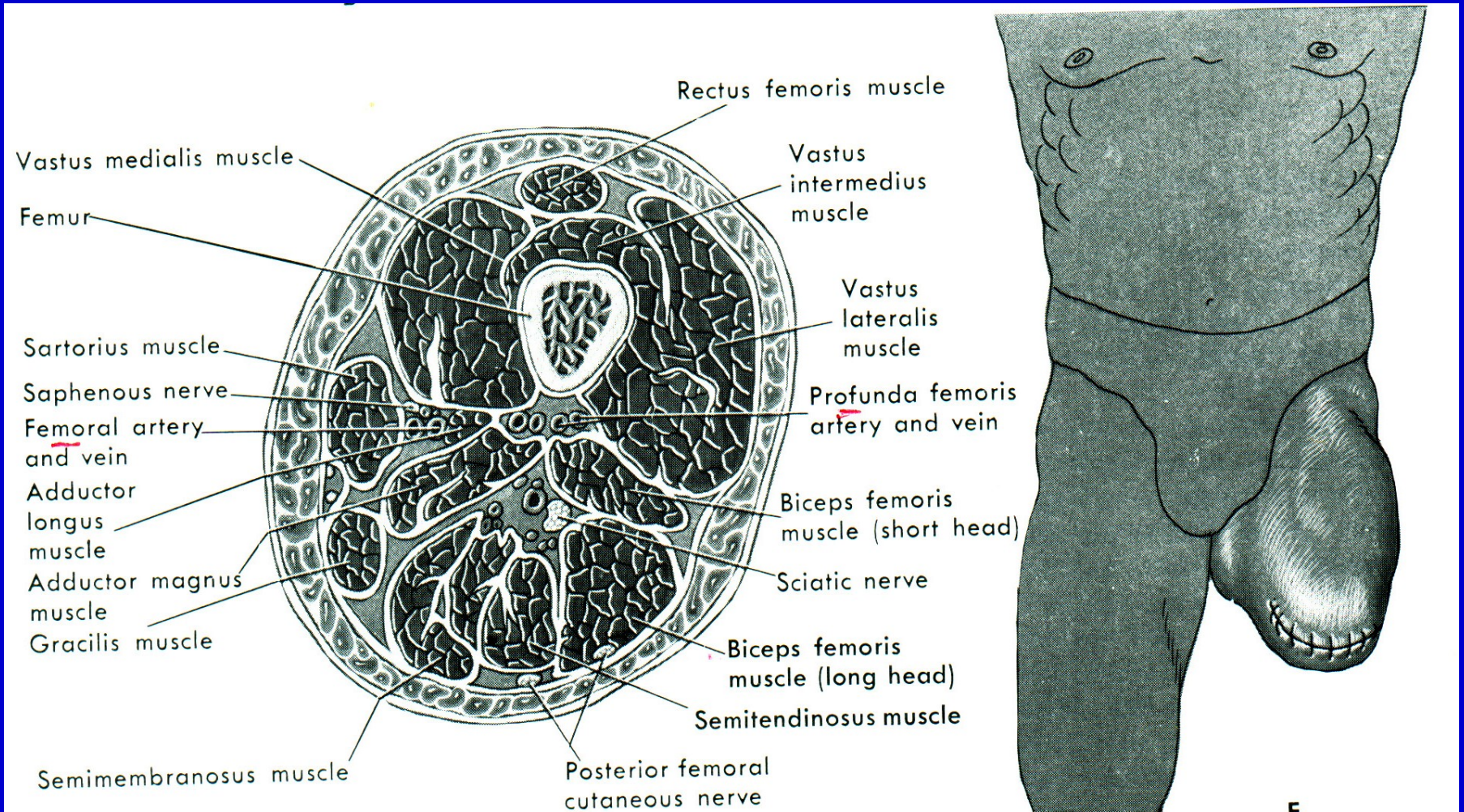


# Above knee amputation



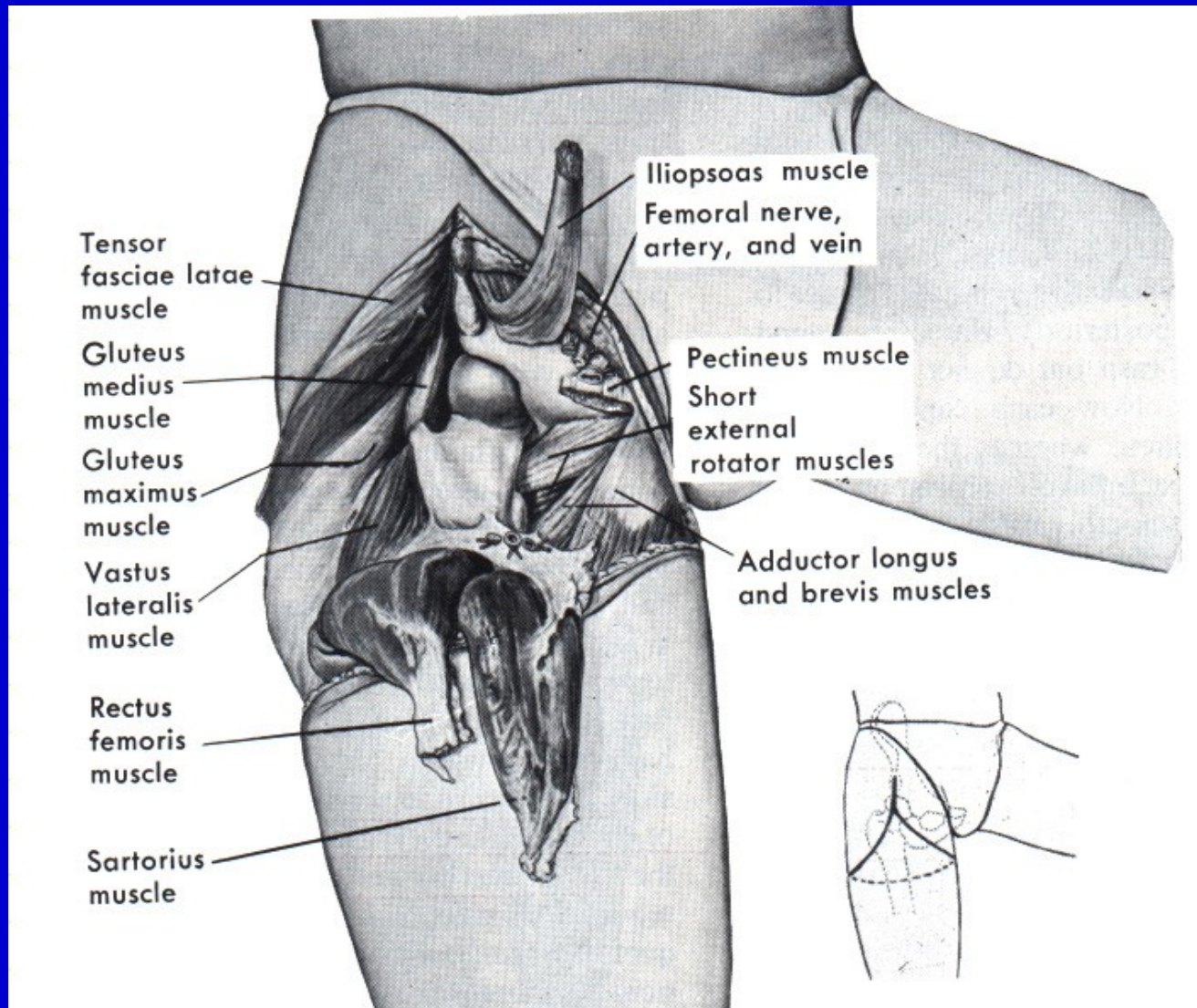


# Above knee amputation

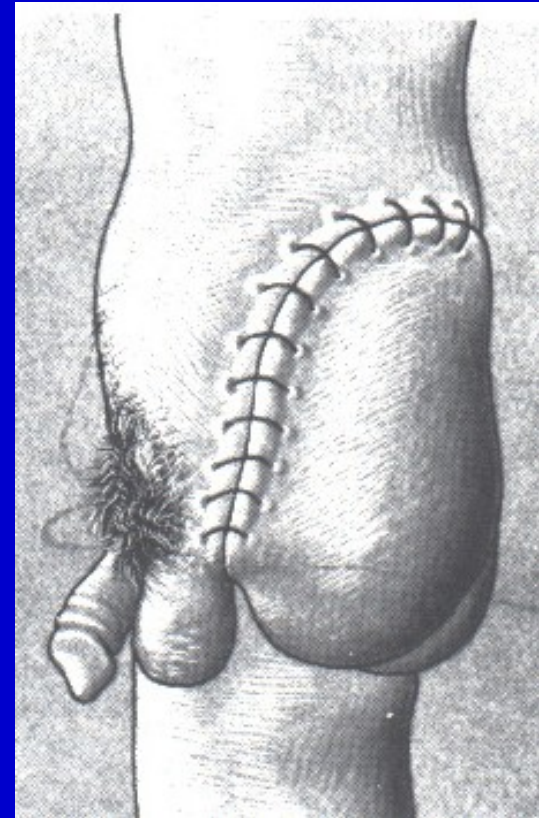
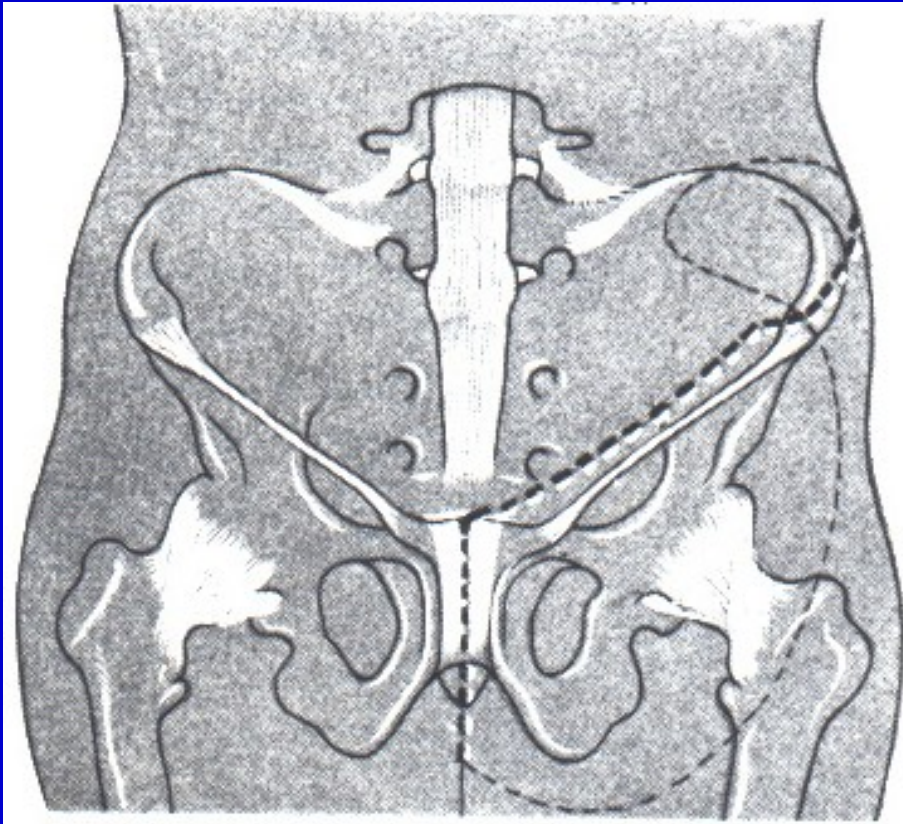




# Disarticulation of the hip



# Hindquarter amputation - hemipelvectomy

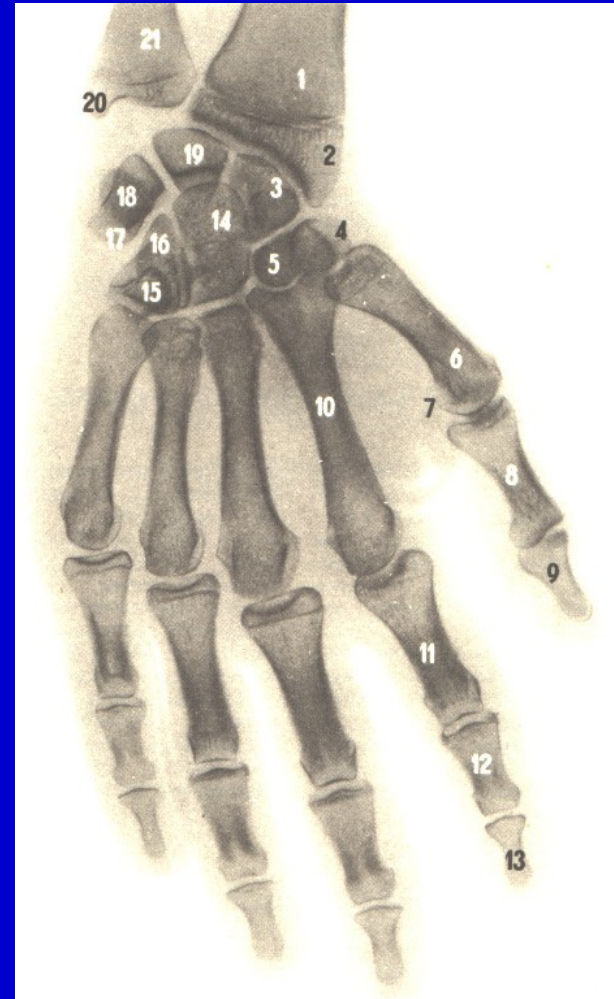


# Amputation in the hand

Phalanx

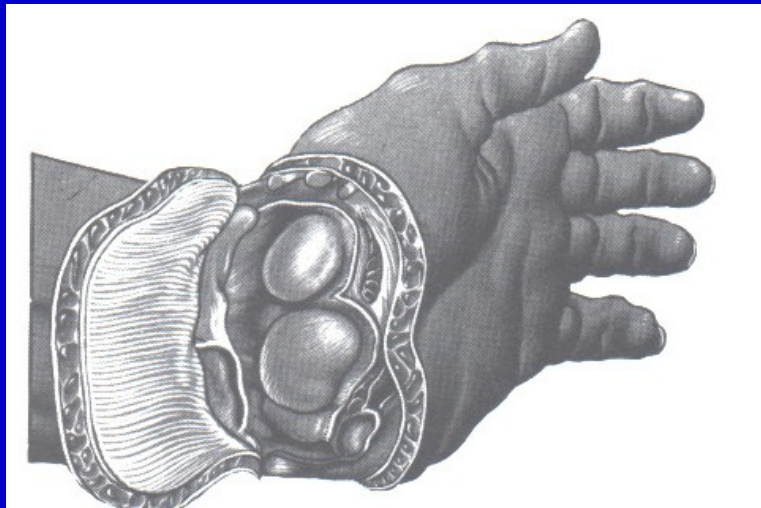
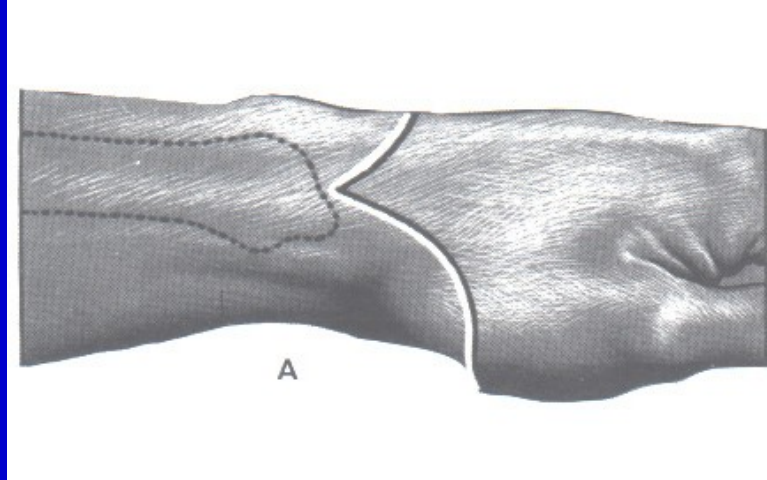
Fingers

Metacarpals

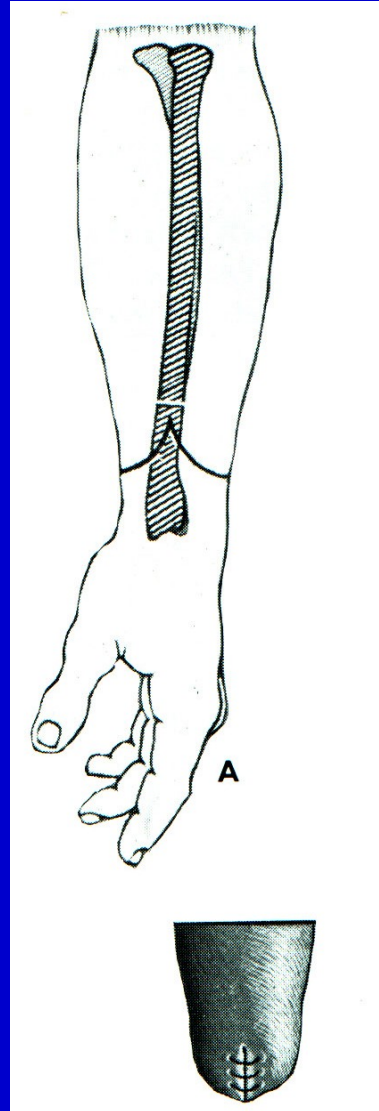




# Disarticulation in wrist joint

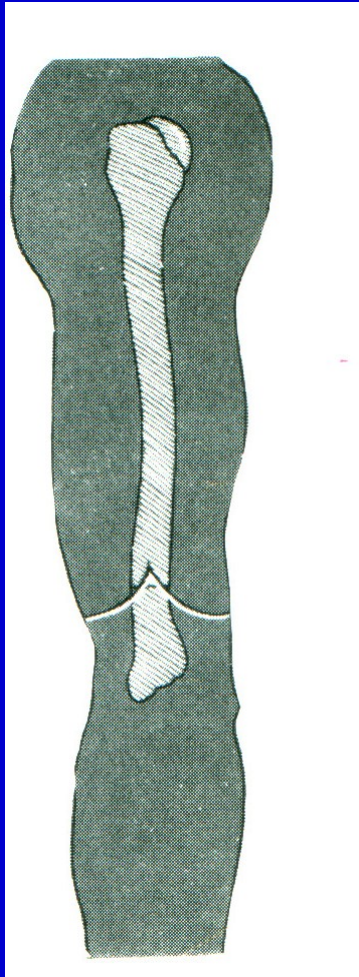


# Amputation through forearm

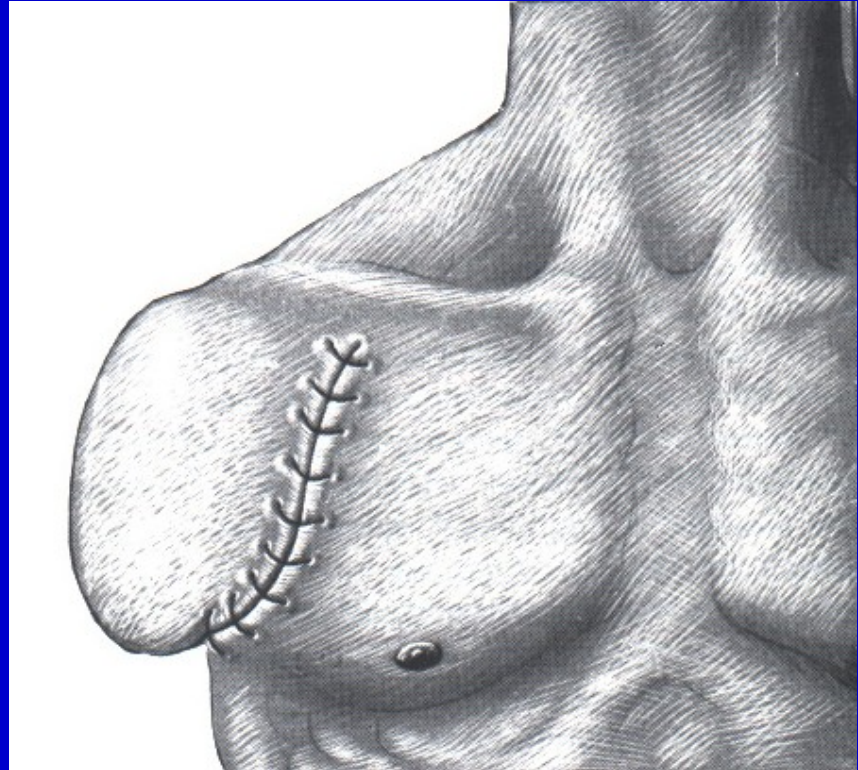




# Amputation through arm



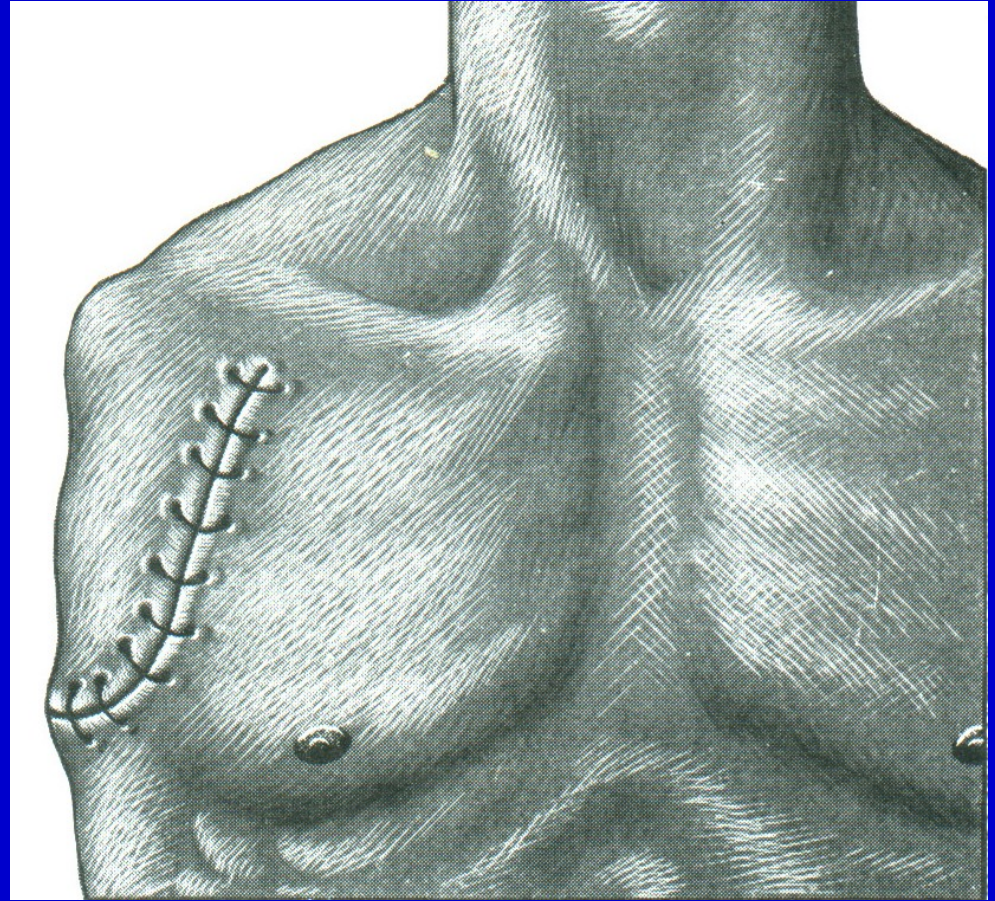
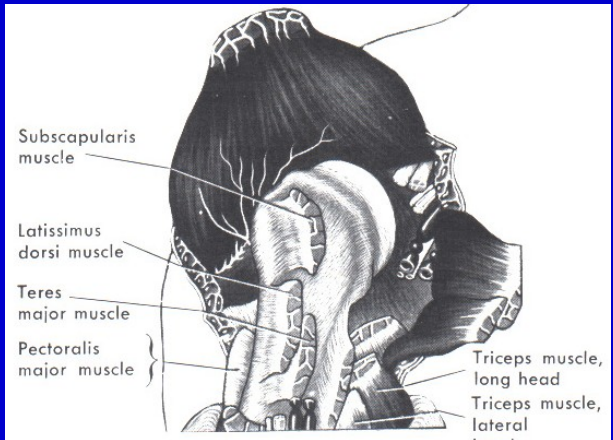
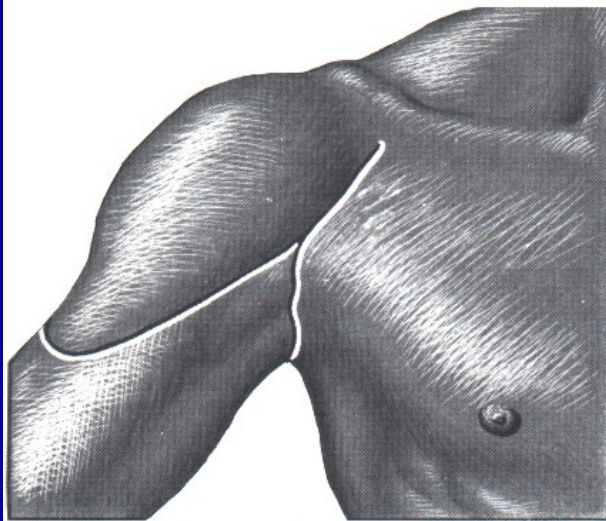
Above elbow amputation



Amputation in surgical neck

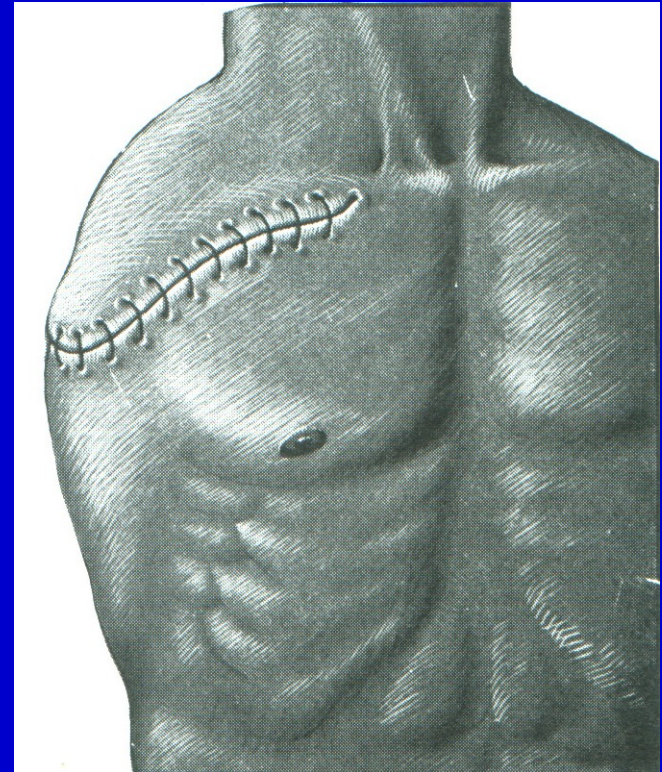
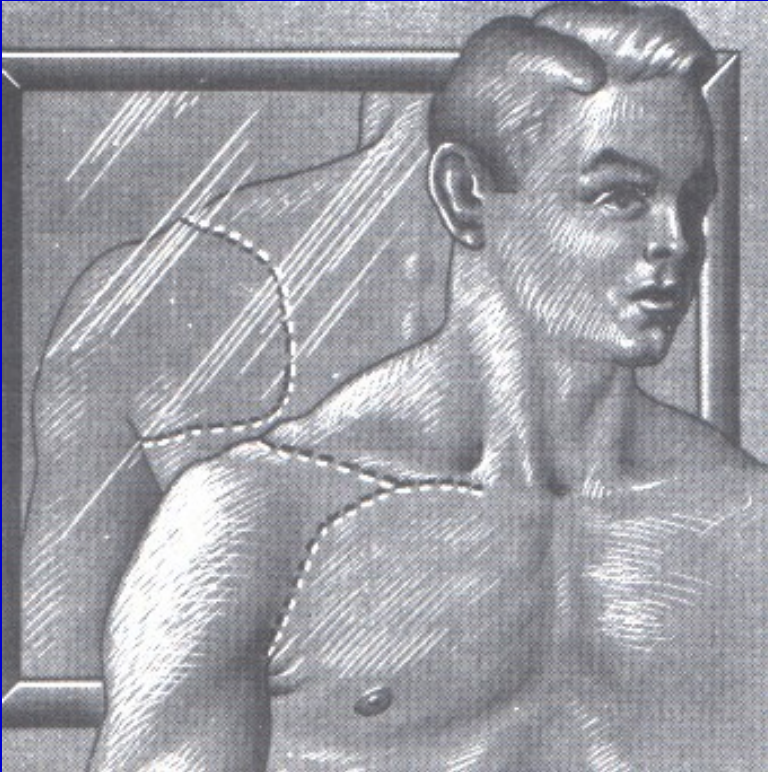


# Disarticulation in the shoulder



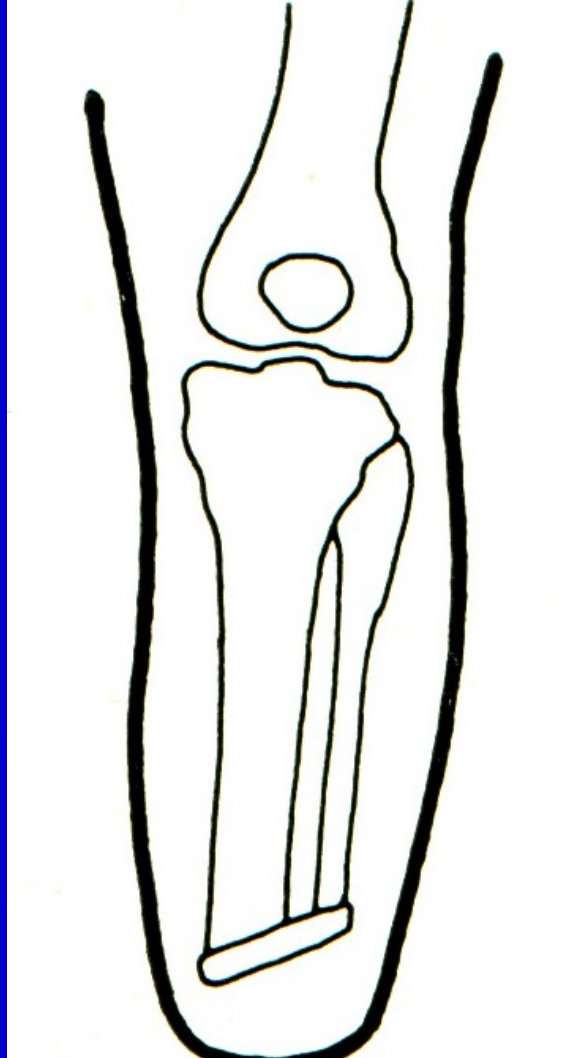


# Forequarter amputation



Interthoracoscapular amputation

# Osteoplastic amputation



# Gilotine amputation

War surgery

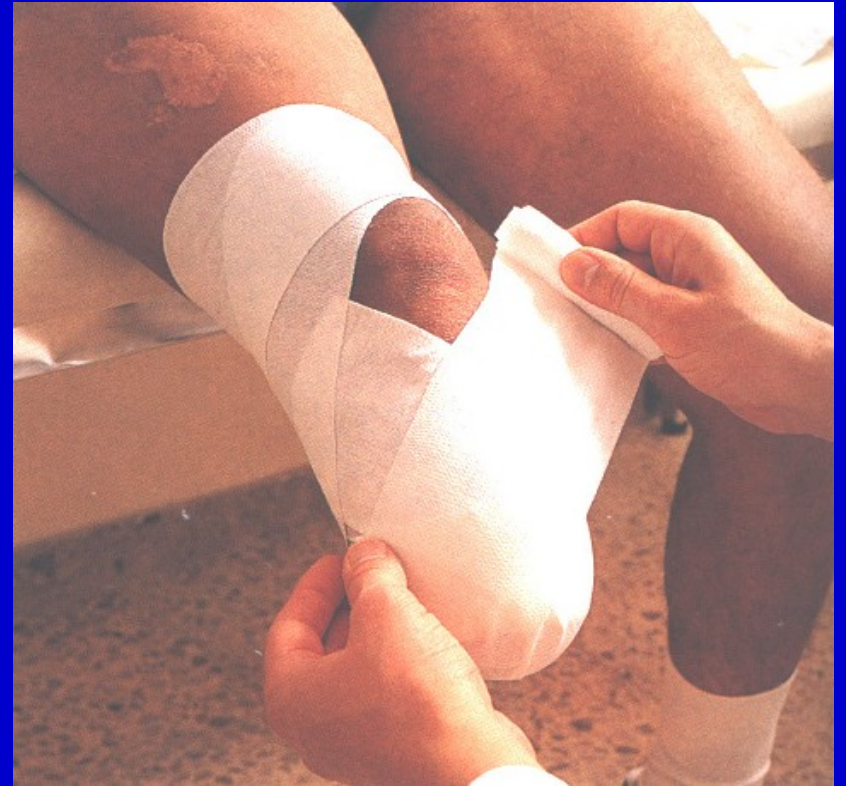One level cut of all structures

No suture of the wound

Requires reamputation

# Post op. management

Elastic bandage to conical shape  
Positioning  
Prevention of flexion contracture  
Proprioception  
Exercise in bed  
Verticalisation  
Walking





# The aim

Good quality stump

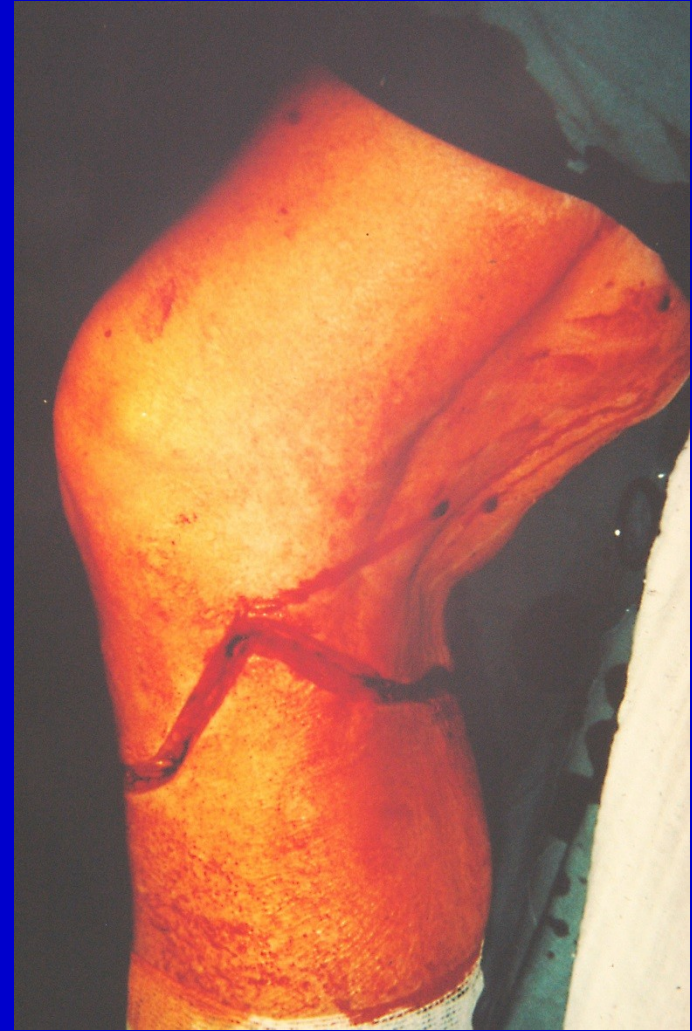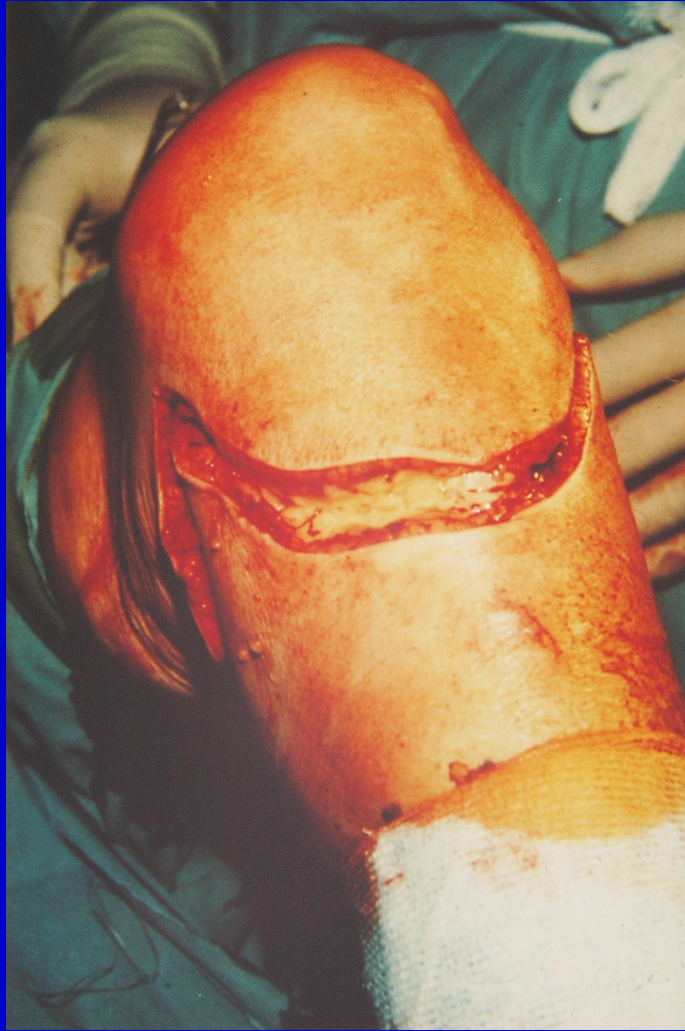Enough soft tissues

Strong muscles

Ability to walk

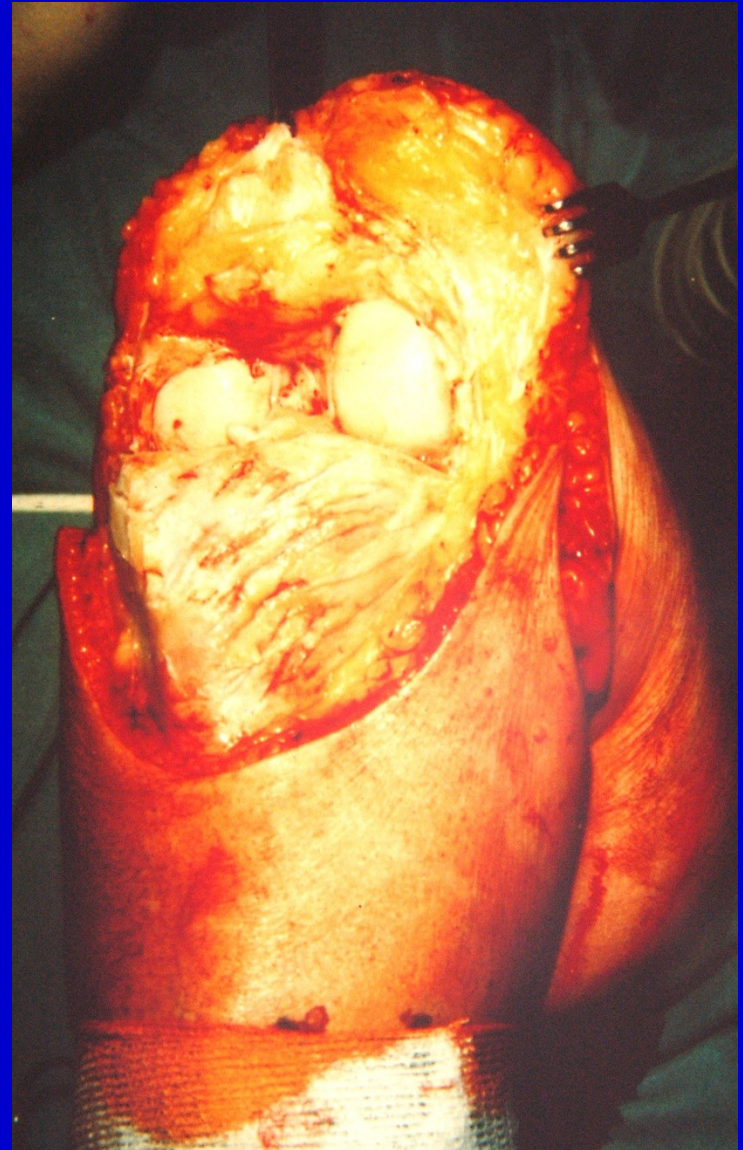
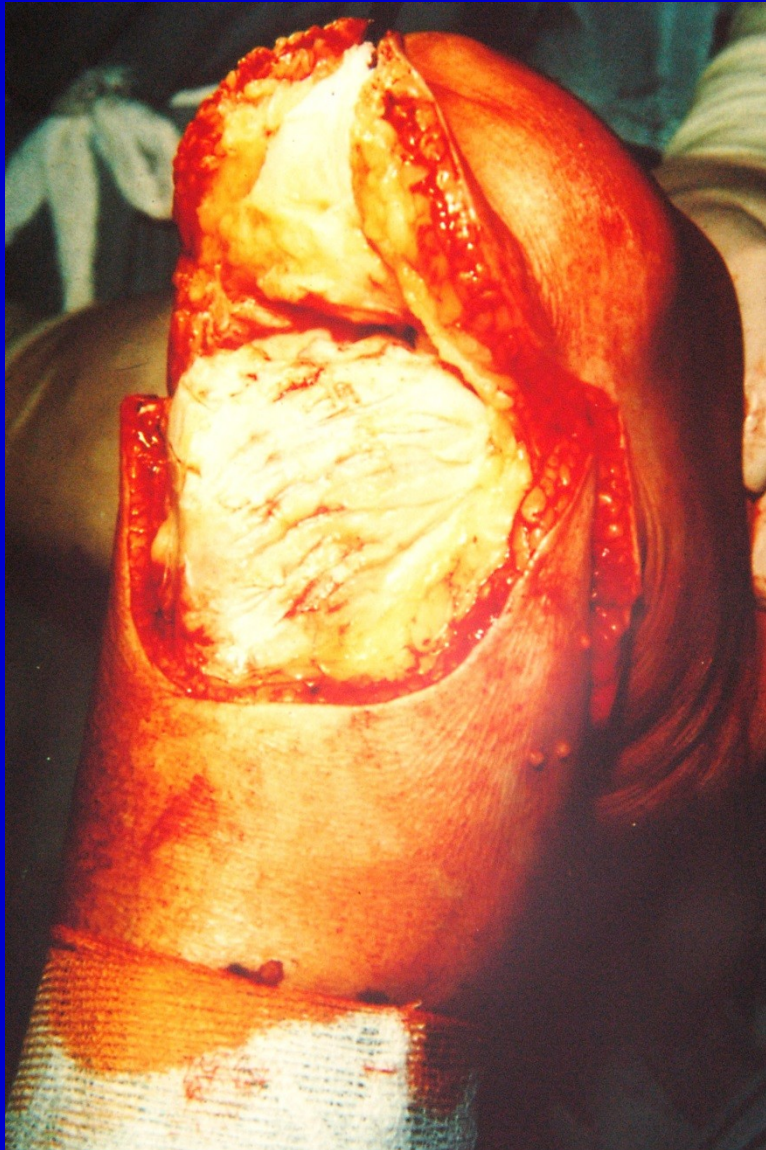
# Disarticulation in the knee region



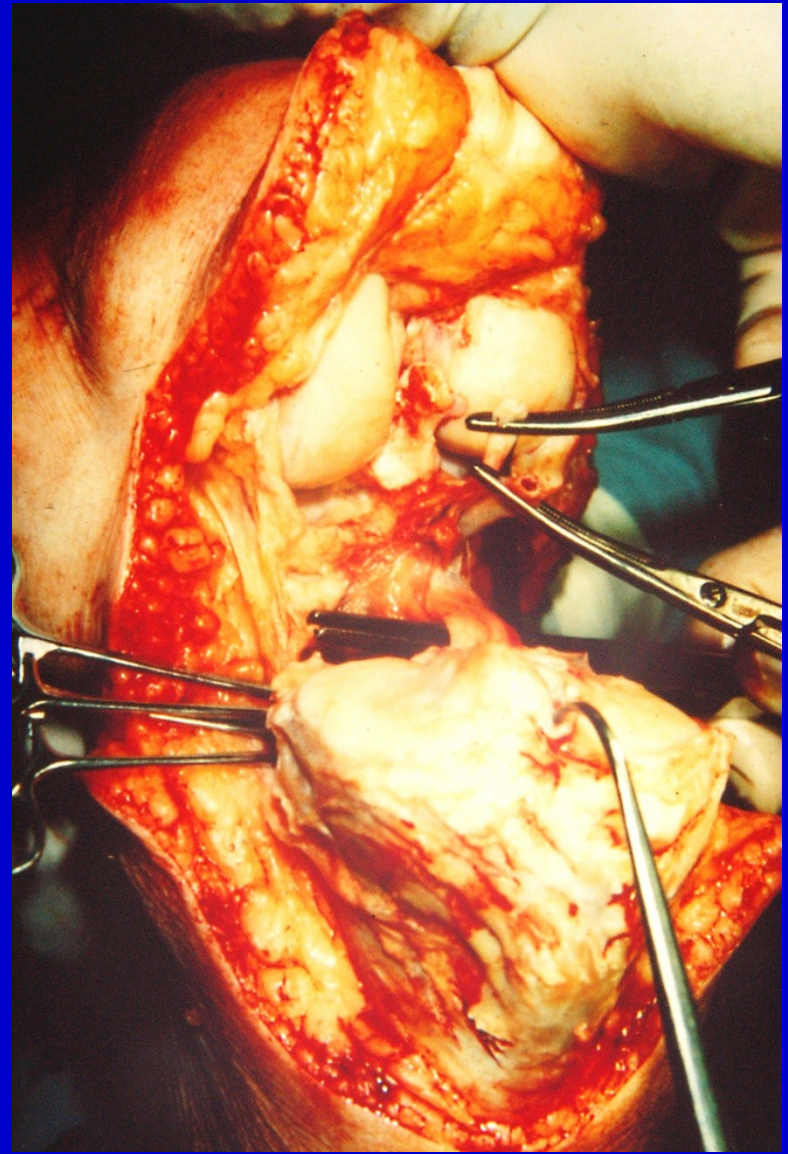
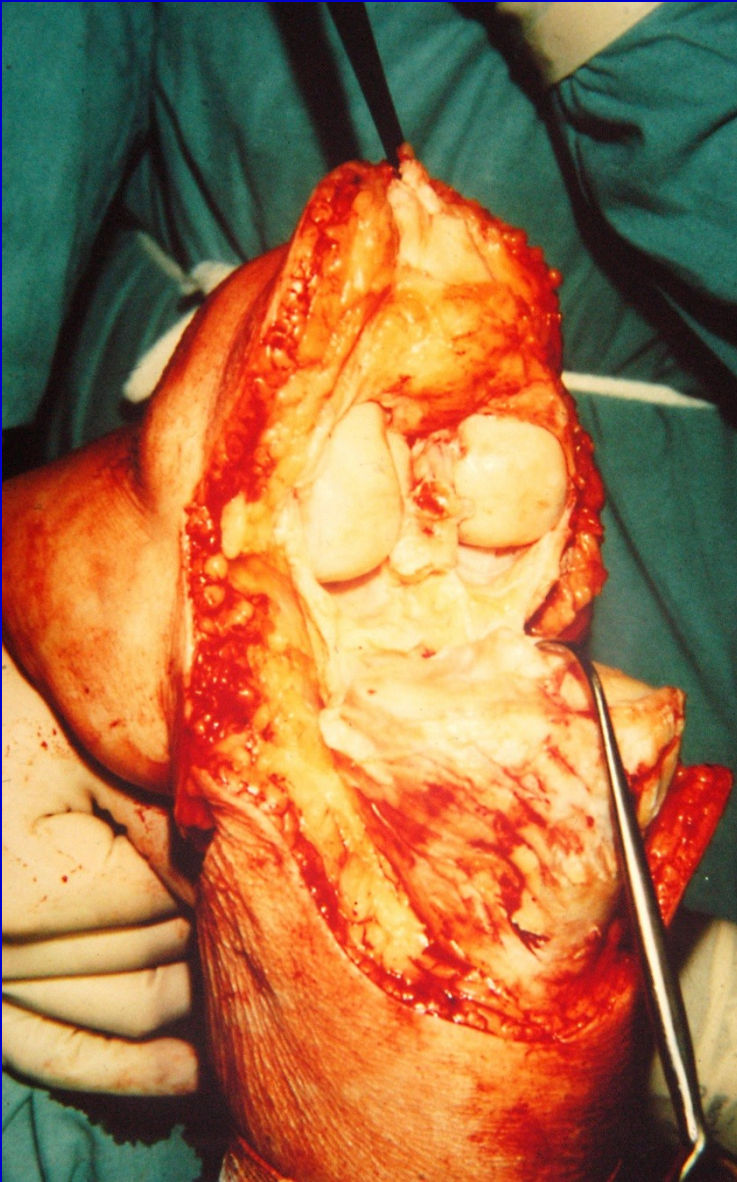
Skin incision





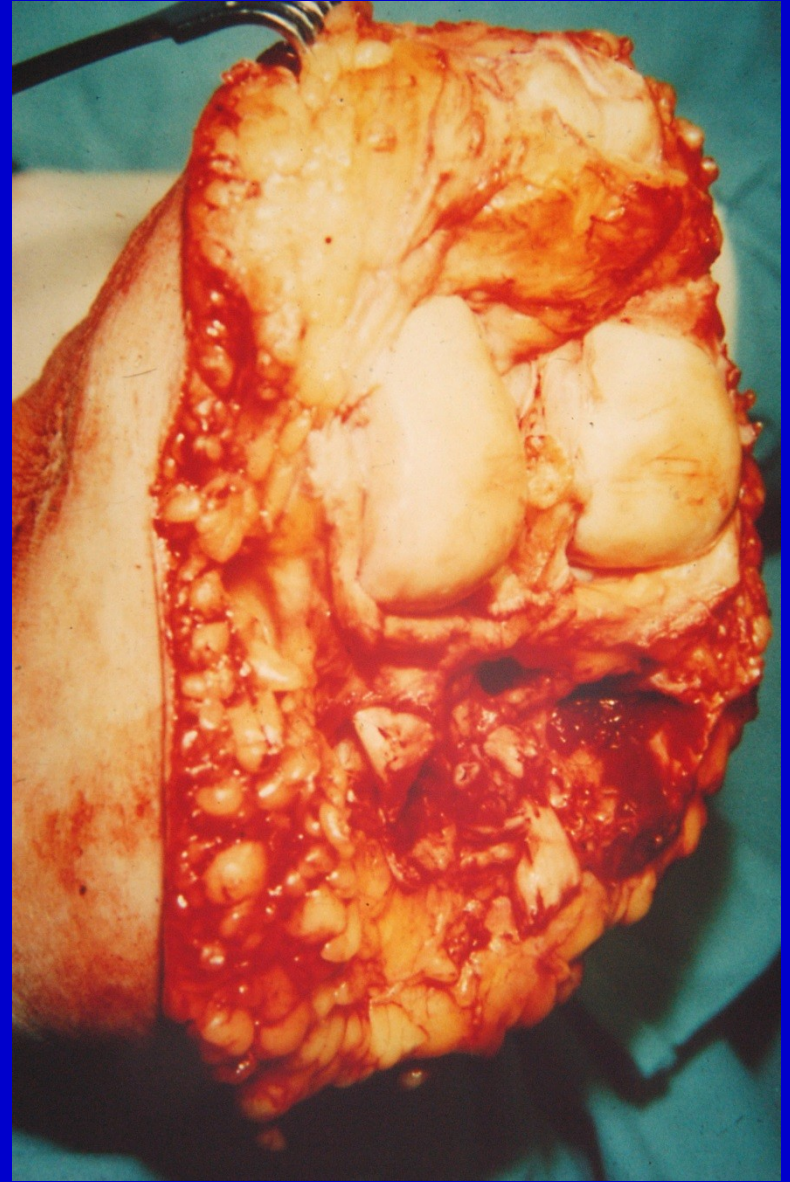
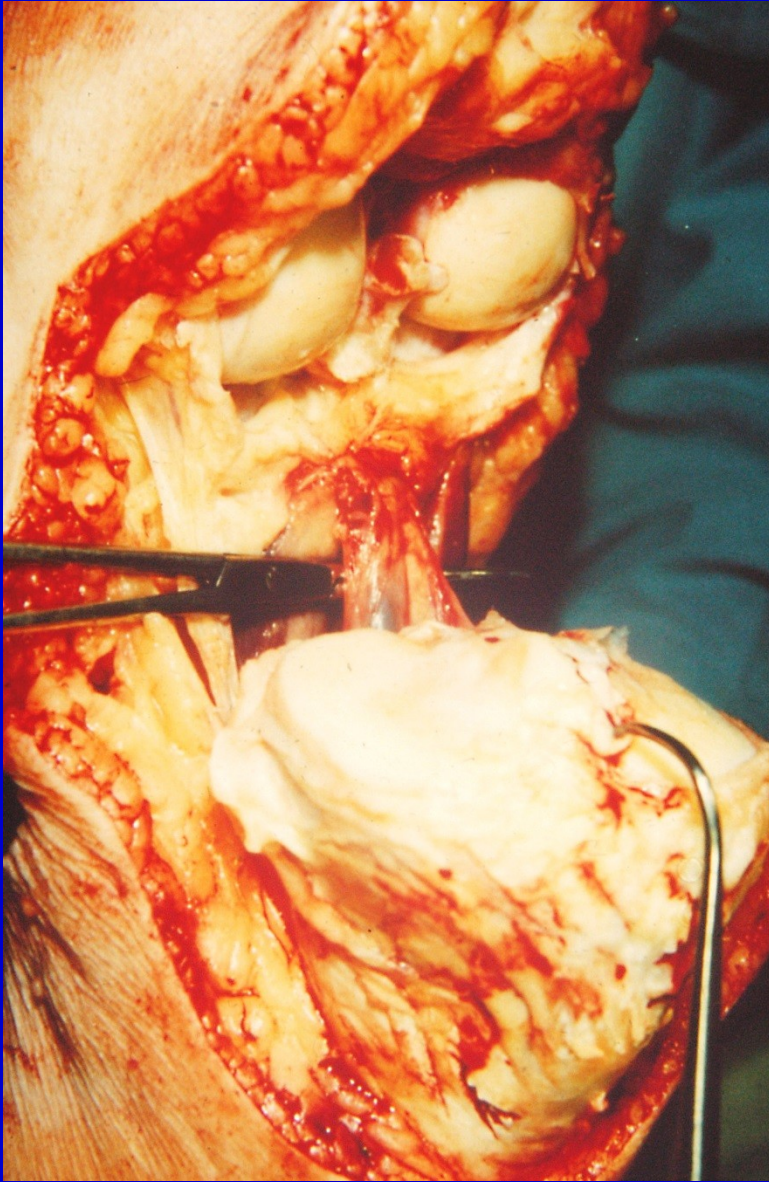
Joint capsule incision, elevation of the patella





Dissection of posterior joint capsule, section of tibial nerve

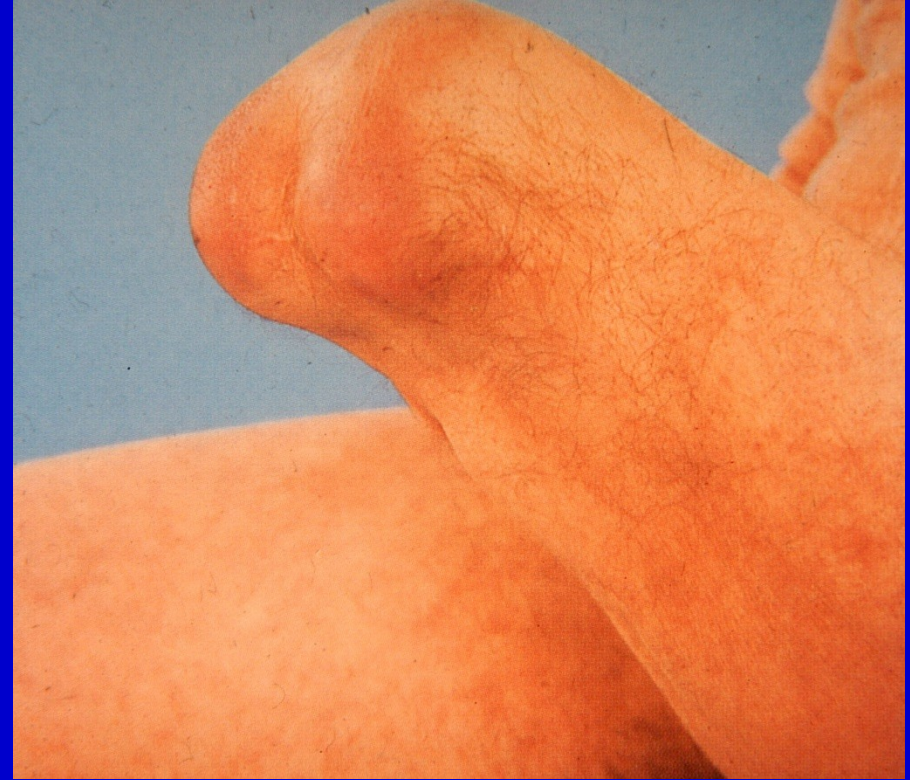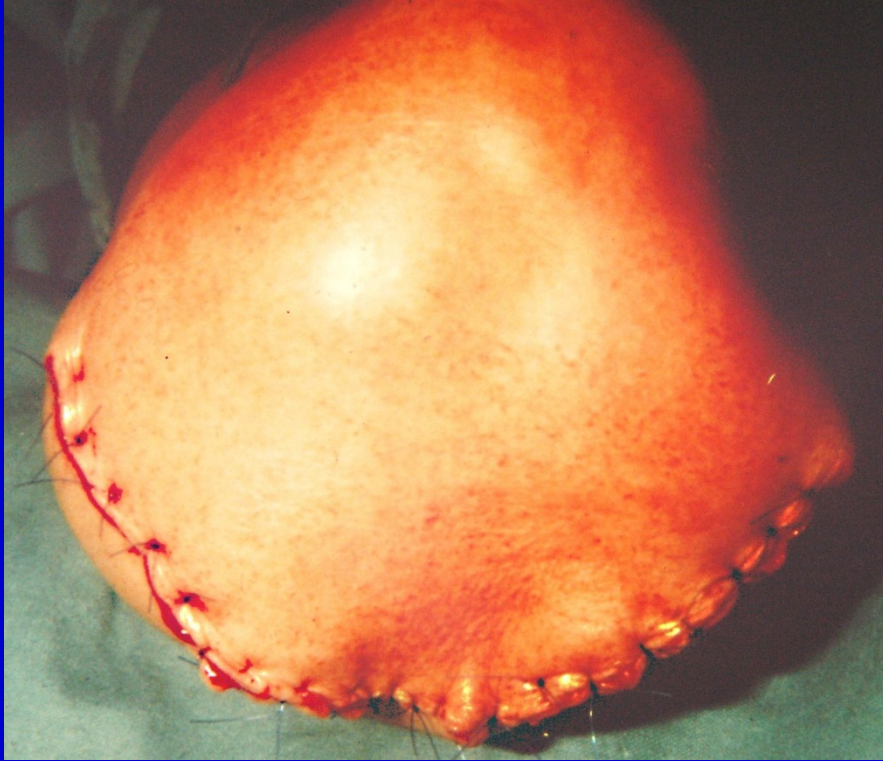




Ligation of popliteal vessels, removal of the limb

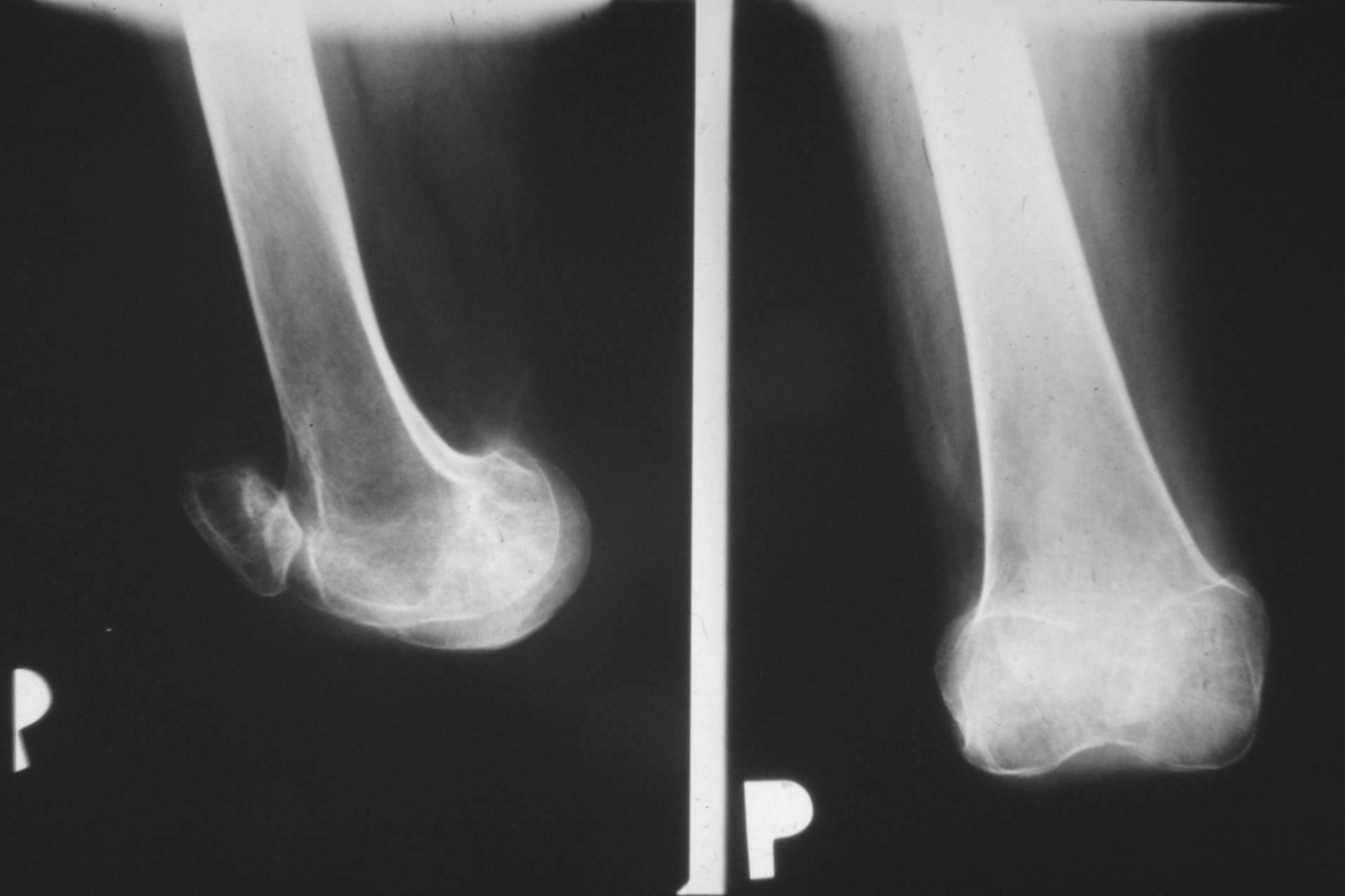


# Suture without tension

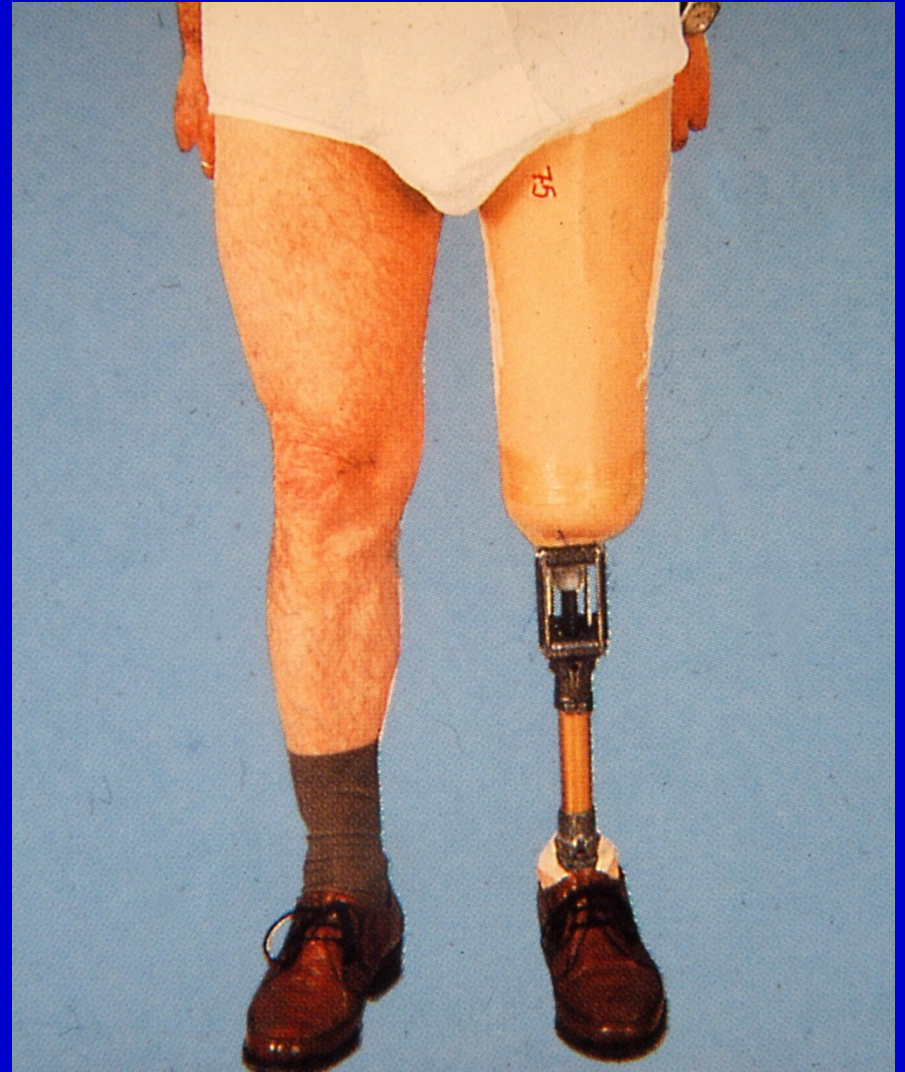
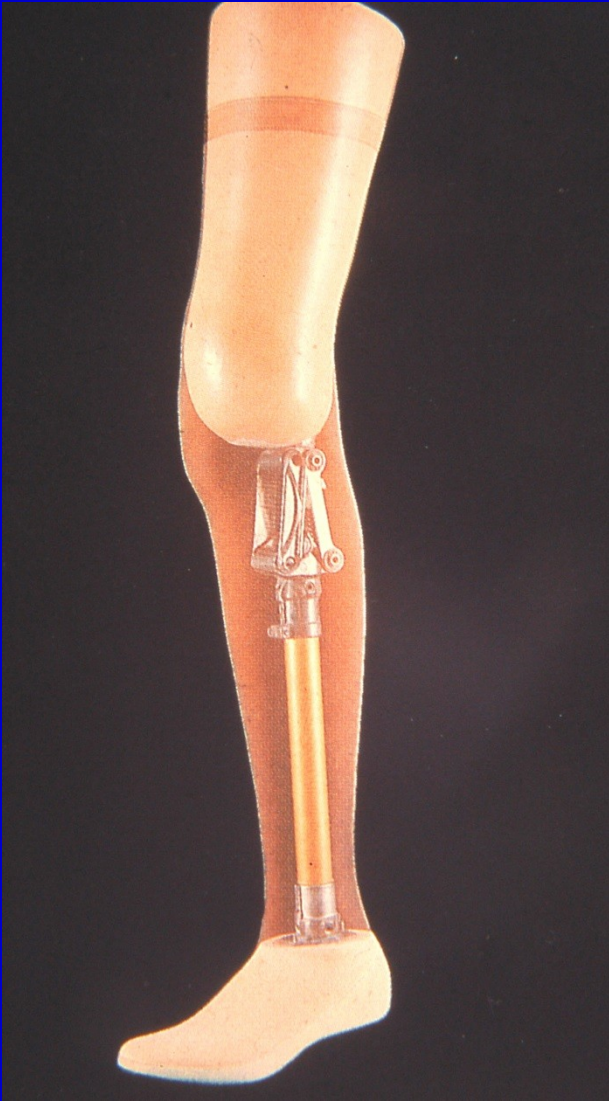
Suture of the wound, healed stump





X - ray after disarticulation



Prosthesis after disarticulation of the knee region