



<https://i.pinimg.com/originals/69/8d/e7/698de768ff8638068faae5c156a02034.jpg>

MUSCLE TISSUE

Petr Vaňhara, PhD

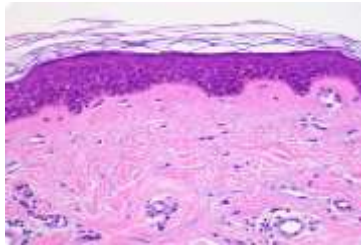
Dept. Histology & Embryology
Faculty of Medicine MU

pvanhara@med.muni.cz

CONTEMPORARY TISSUE CLASSIFICATION

Based on morphology and function:


Epithelium



Continual, avascular layers of cells with different functions, oriented to open space, with specific junctions and minimum of ECM and intercellular space.

Derivates of all three germ layers

Muscle



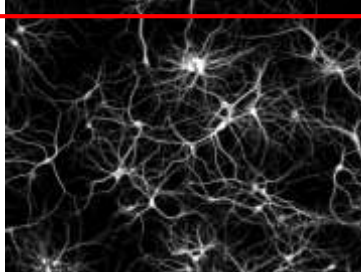
Cytoskeleton → contraction

Mesoderm – skeletal muscle, myocard, mesenchyme

– smooth muscles

Rarely ectoderm (eg. m. sphincter a m. dilatator pupillae)

Nerve

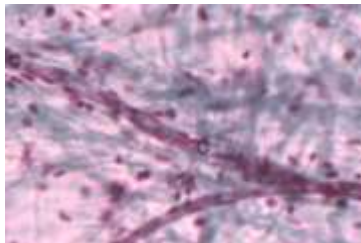


Neurons and neuroglia

Reception and transmission of electric signals

Ectoderm, rarely mesoderm (microglia)

Connective



Dominant extracellular matrix


Connective tissue, cartilage, bone...

Mesenchyme

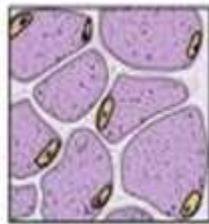
GENERAL CHARACTERISTIC OF MUSCLE TISSUE

Hallmarks

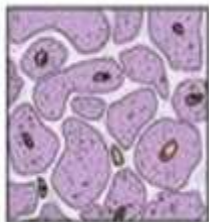
- Unique cell architecture
- Excitability and contraction
- Mesodermal origin



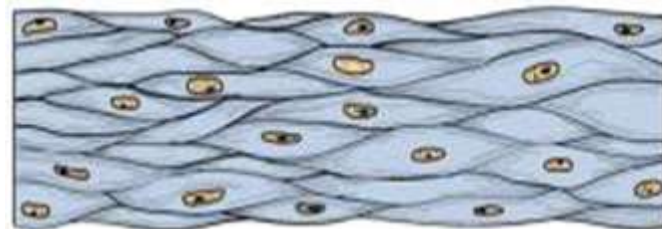
Striated skeletal

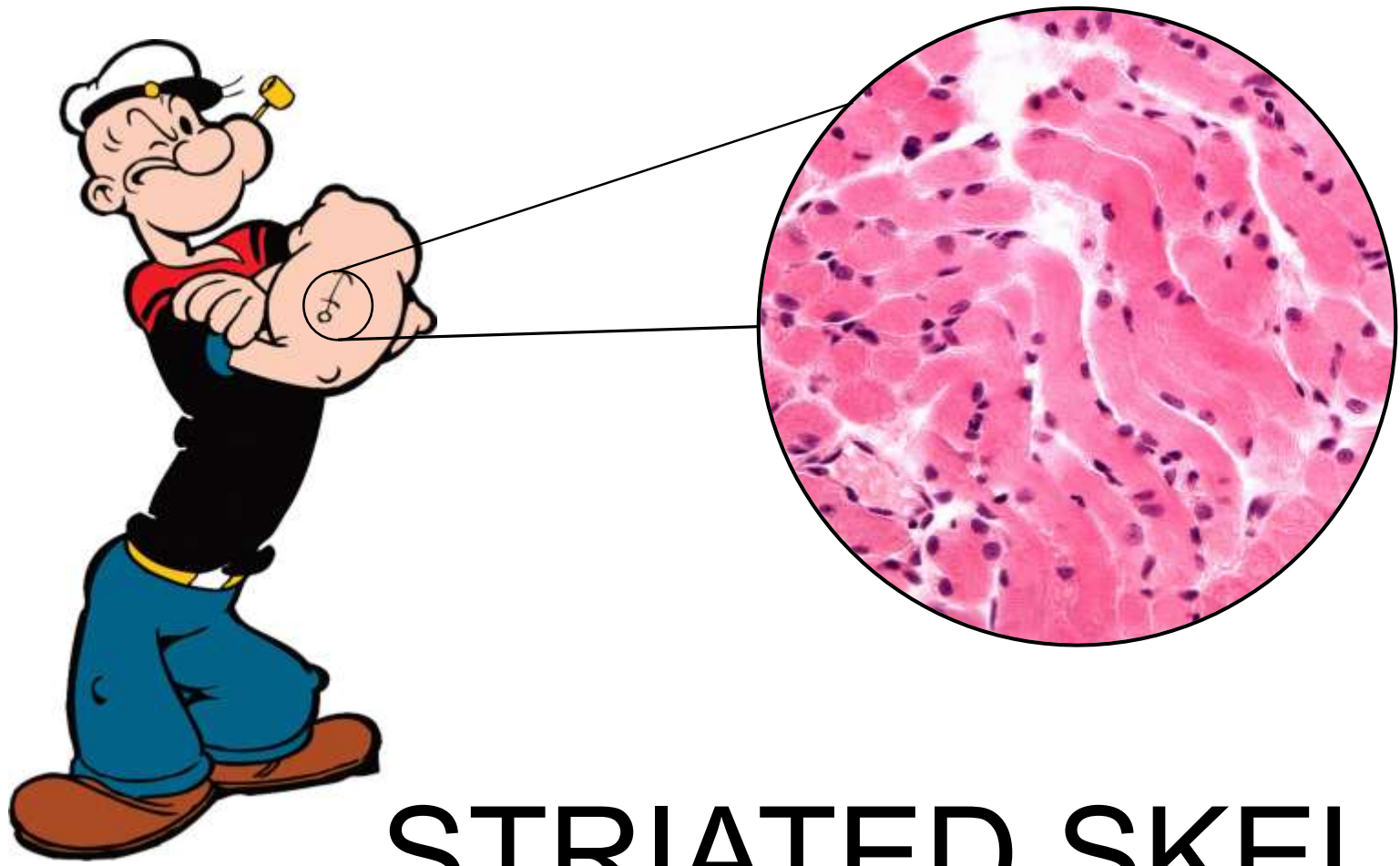


Striated cardiac



Smooth





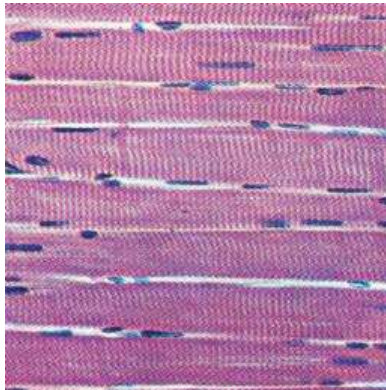
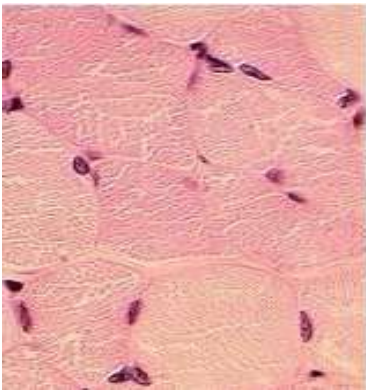
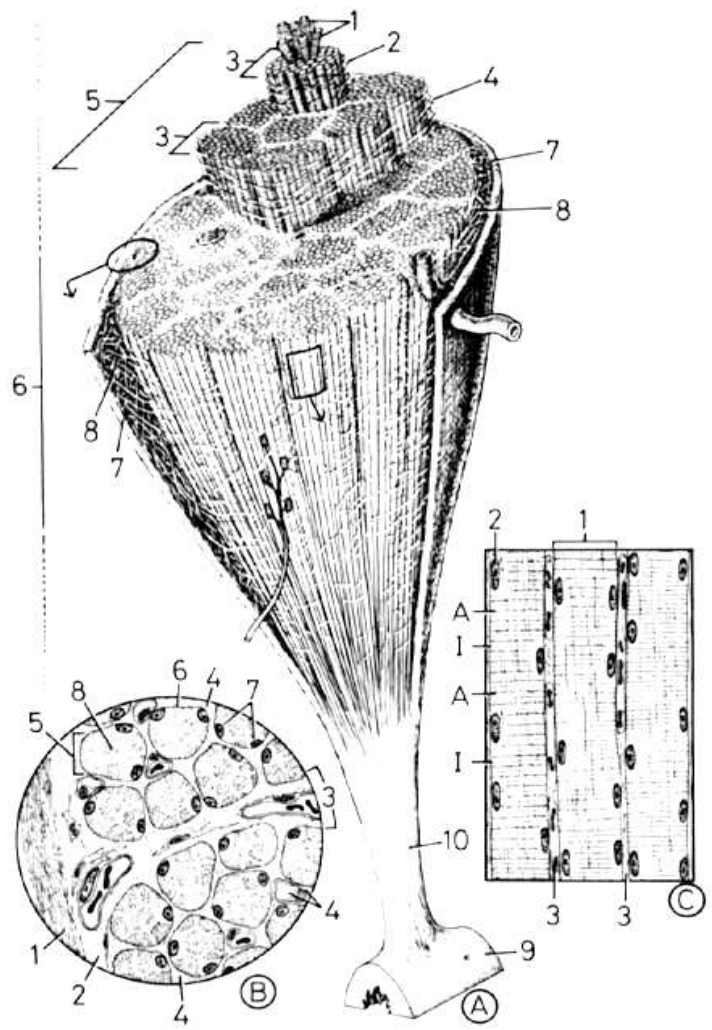
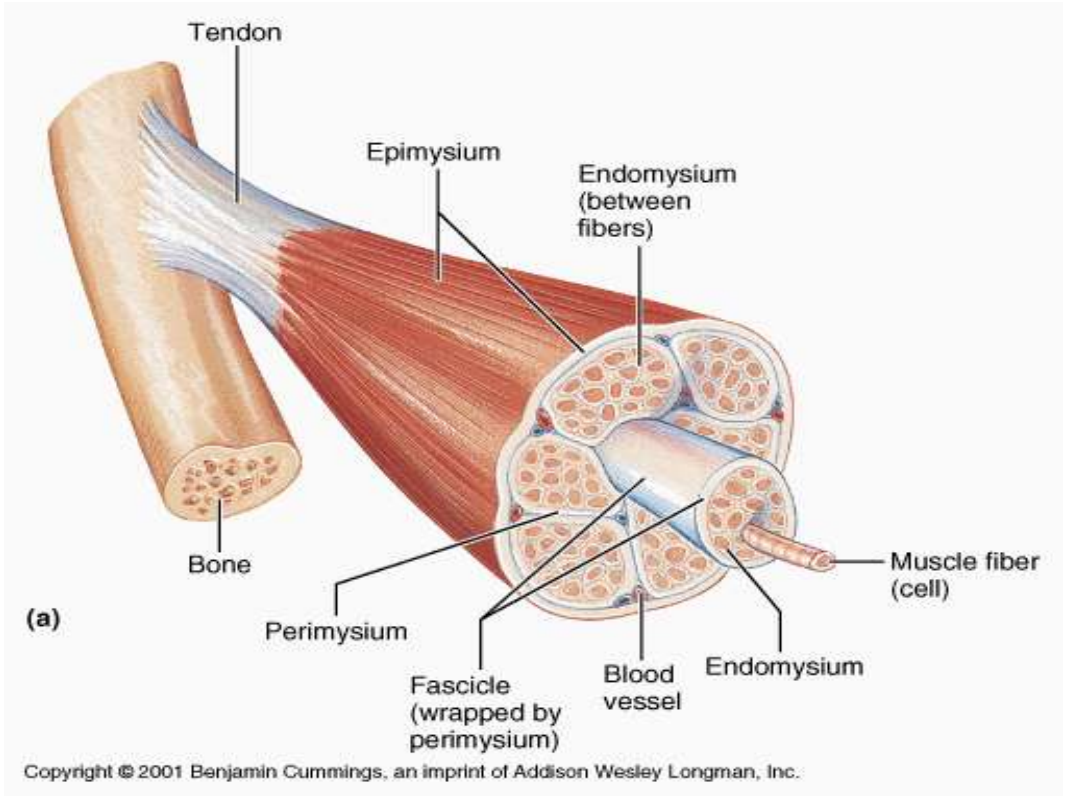
**STRIATED SKELETAL
MUSCLE TISSUE**

HISTOLOGY OF SKELETAL MUSCLE TISSUE

- Composition: muscle cells + connective tissue, blood vessels
- Unique cell architecture – long multinuclear cells – muscle fibers (rhabdomyocytes)
- Long axis of cells is oriented parallel with direction of contraction
- Specific terminology:
 - cell membrane = sarcolemma
 - cytoplasm = sarcoplasm
 - sER = sarcoplasmic reticulum

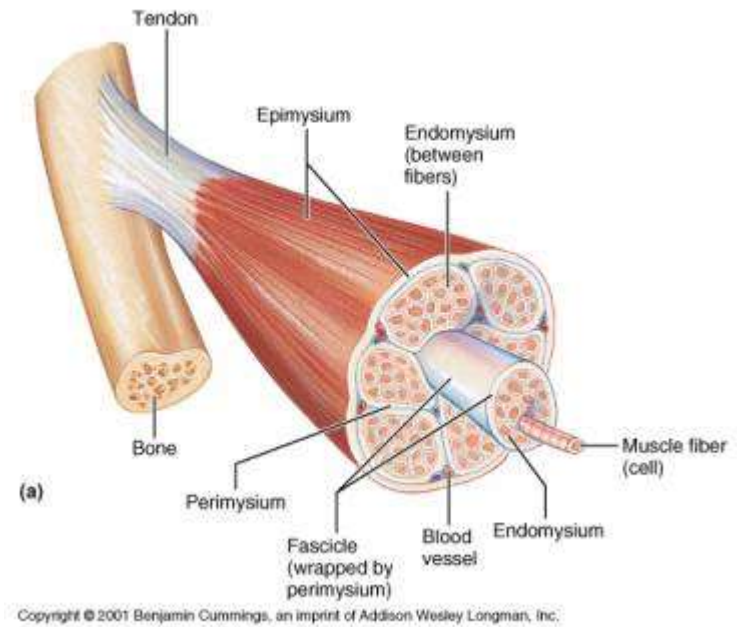
 - Muscle fiber – microscopic unit of skeletal muscle
 - Myofibril – LM unit – myofilaments – unit of muscle fibers
 - Myofilaments – filaments of actin and myosin (EM)

STRUCTURE OF SKELETAL MUSCLE




CONNECTIVE TISSUE OF SKELETAL MUSCLE

- Containment
- Limit of expansion of the muscle
- Transmission of muscular forces
- **Endomysium** – around each muscle cell (fiber)
- **Perimysium** – around and among the primary bundles of muscle cells
- **Epimysium** – dense irregular collagen c.t., continuous with tendons and fascia
- Fascia – dense regular collagen c.t.

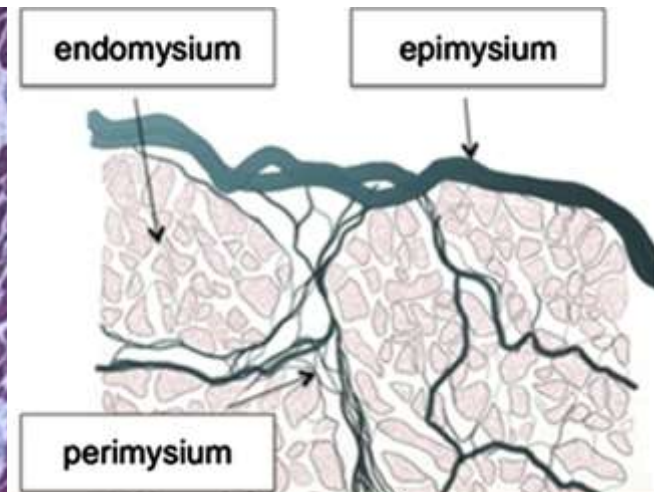
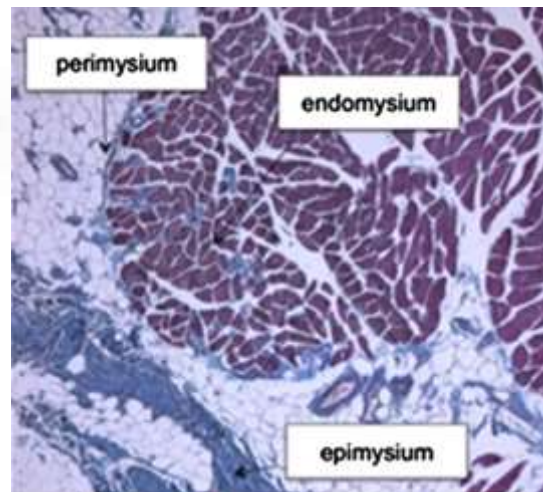


-mysiums

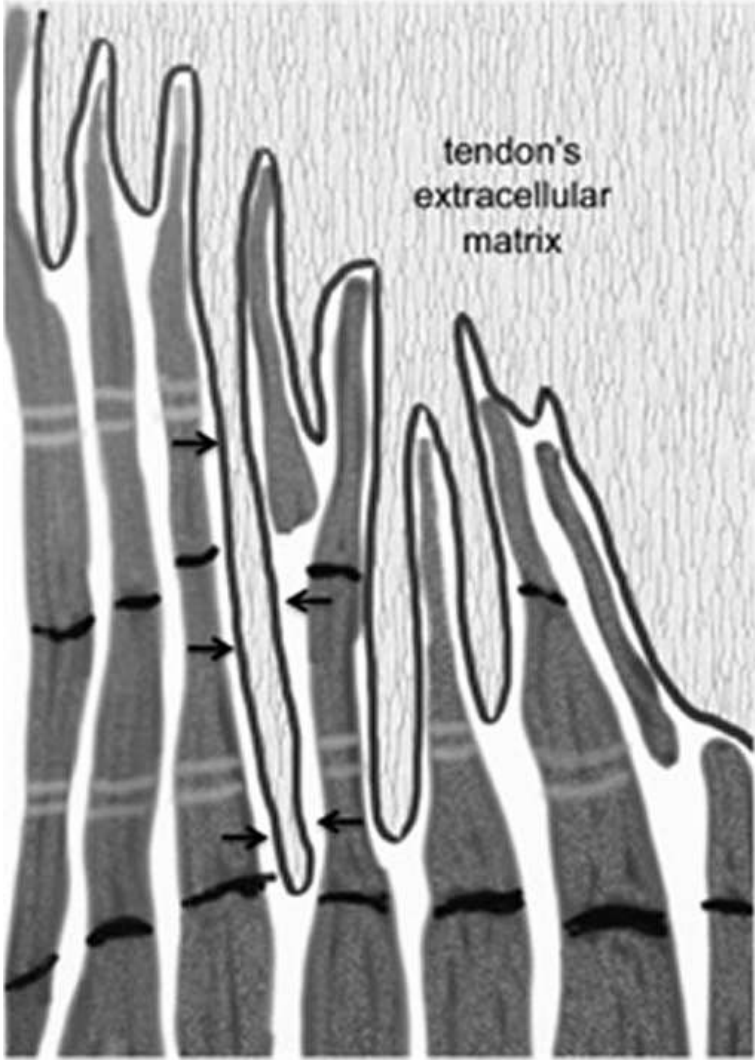

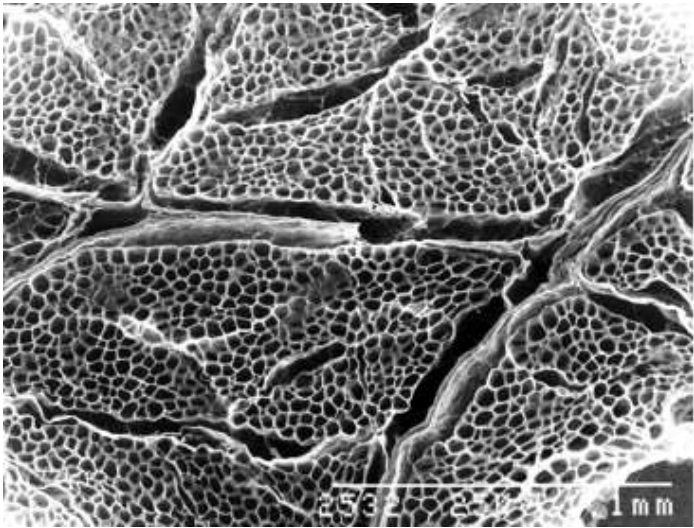
(connective tissue coats of a skeletal muscle)





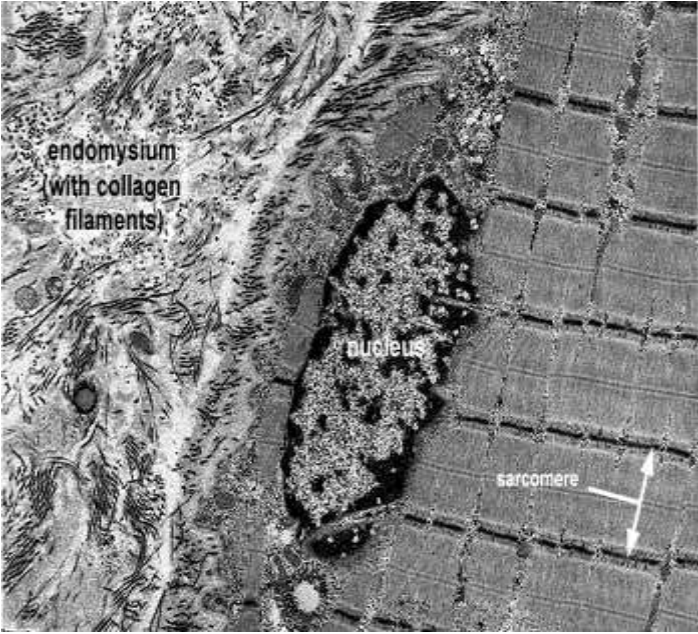
- skeletal muscle fiber
- endo - mysium
- peri - mysium
- epi - mysium




CONNECTIVE TISSUE OF SKELETAL MUSCLE



CONNECTIVE TISSUE OF SKELETAL MUSCLE




WHY IS SKELETAL MUSCLE
TISSUE STRIATED?



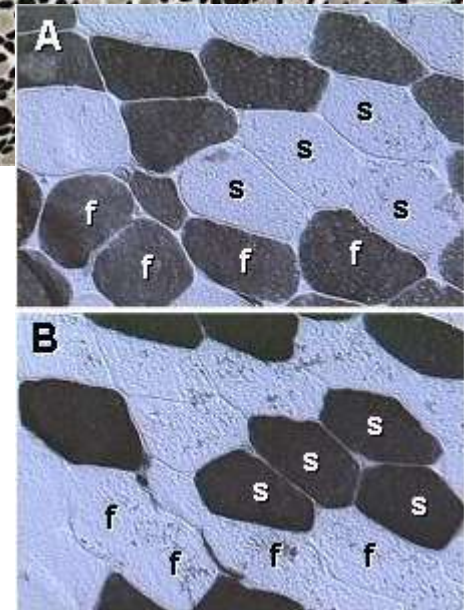
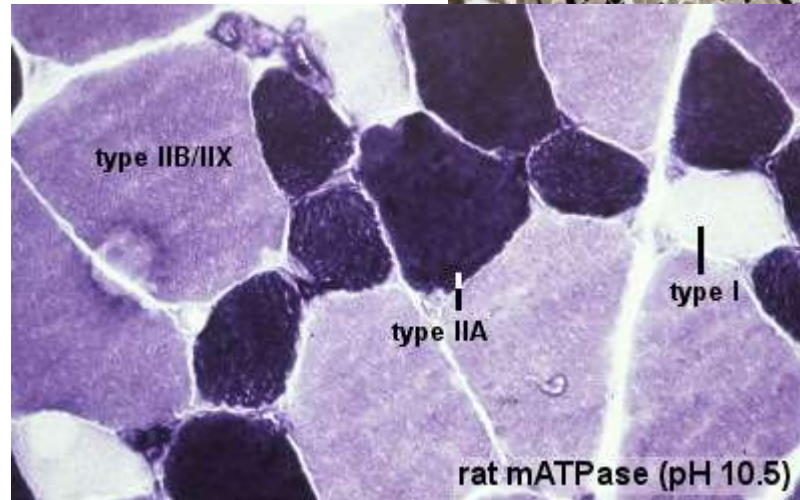
STRUCTURE OF SKELETAL MUSCLE

- morphological and functional unit: **muscle fiber (rhabdomyocyte)** – elongated, cylindrical-shaped, multinucleated cell (syncytium)
- nuclei are located at the periphery (under sarcolemma)
- **myofibrils** show cross striation
- diameter of muscle fiber: 25-100 μm
- length: millimeters - centimeters (up to 15)



CLASSIFICATION OF SKELETAL MUSCLE

- **Myosin heavy chain (MHC) type I and II**
 - distinct metabolic, contractile, and motor-unit properties
 - ATPase activity
- **Twitch type**
 - Fast vs. slow
- **Fiber color**
 - Red vs. white
- **Myoglobin content**
- **Glycogen content**
- **Energy metabolism**
- **Endurance**



CLASSIFICATION OF SKELETAL MUSCLE

Properties	Type I fibers	Type IIA fibers	Type IIX fibers
Motor Unit Type	Slow Oxidative (SO)	Fast Oxidative/Glycolytic (FOG)	Fast Glycolytic (FG)
Twitch Speed	Slow	Fast	Fast
Twitch Force	Small	Medium	Large
Resistance to fatigue	High	High	Low
Glycogen Content	Low	High	High
Capillary Supply	Rich	Rich	Poor
Myoglobin	High	High	Low
Red Color	Dark	Dark	Pale
Mitochondrial density	High	High	Low
Capillary density	High	Intermediate	Low
Oxidative Enzyme Capacity	High	Intermediate-high	Low
Z-Line Width	Intermediate	Wide	Narrow
Alkaline ATPase Activity	Low	High	High
Acidic ATPase Activity	High	Medium-high	Low

ULTRASTRUCTURE OF RHABDOMYOCYTE

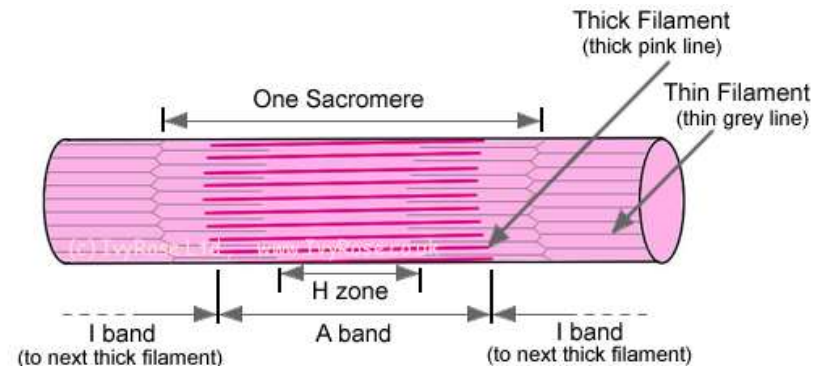
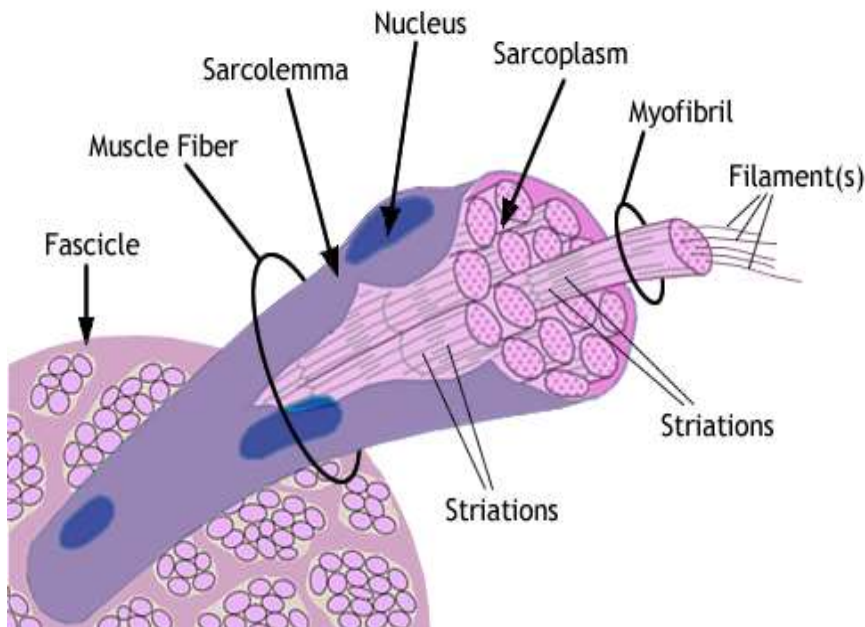
Muscle fiber = myofiber = syncytium = rhabdomyocyte

Muscle fiber – morphological and functional unit of skeletal muscle [\varnothing 25 – 100 μm]

Myofibrils – compartment of fiber sarcoplasm [\varnothing 0.5 – 1.5 μm]

Sarcomere – the smallest contractile unit [2.5 μm], serial arrangement in myofibrils

Myofilaments – actin and myosin, are organized into sarcomeres [\varnothing 8 and 15 nm]



ULTRASTRUCTURE OF RHABDOMYOCYTE

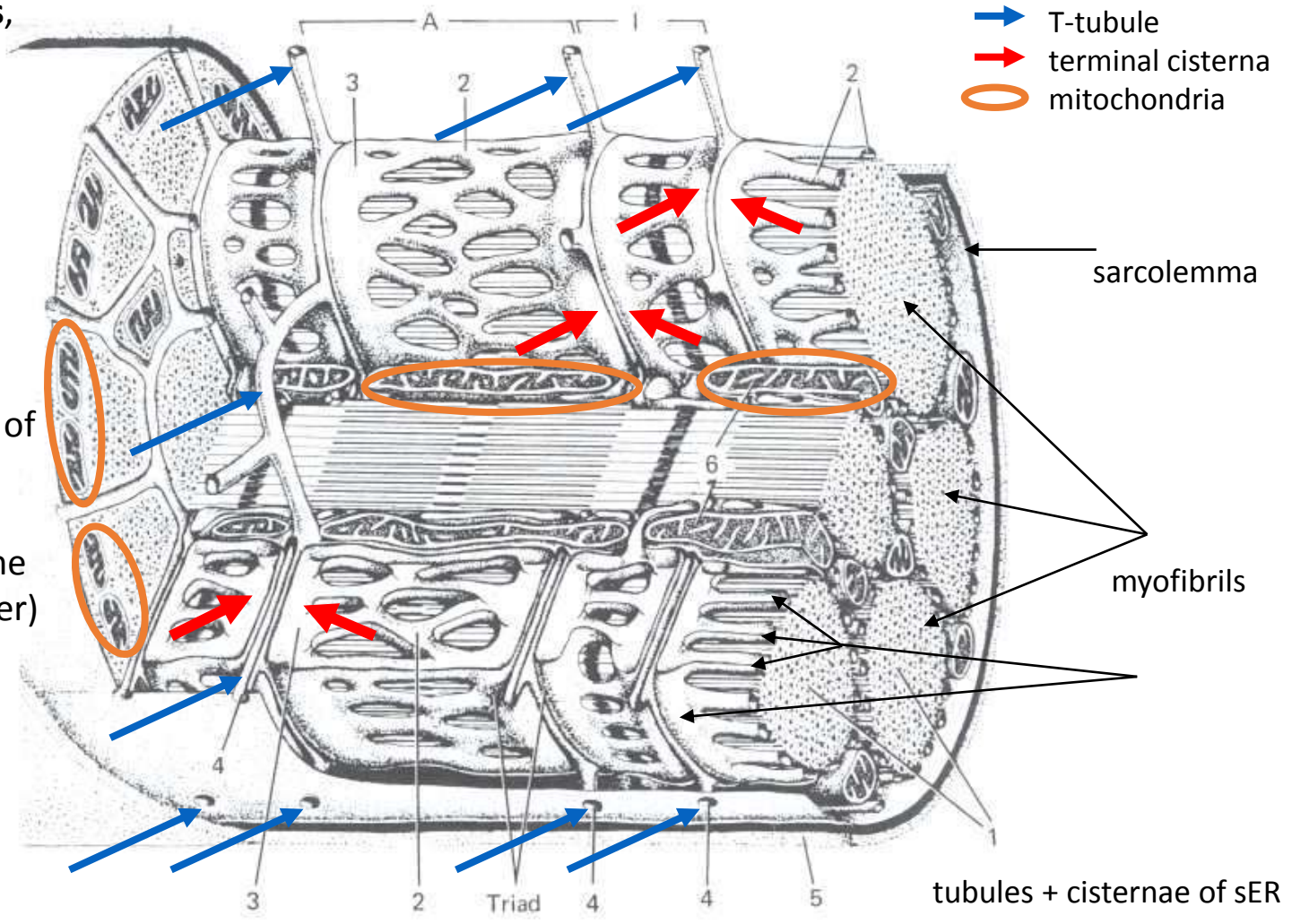
Sarcolemma + t-tubules,

Sarcoplasm:

Nuclei,
Mitochondria,
Golgi apparatus,
Glycogen (β granules)

Sarcoplasmic reticulum
(smooth ER) – reservoir of Ca^{2+}

Myofibrils (parallel to the length of the muscle fiber)



- ➡ T-tubule
- ➡ terminal cisterna
- mitochondria

sarcolemma

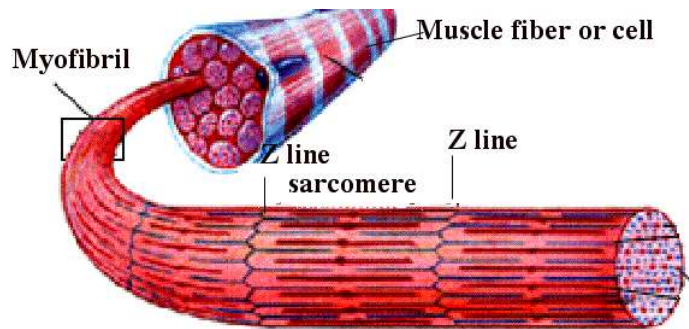
myofibrils

tubules + cisternae of sER

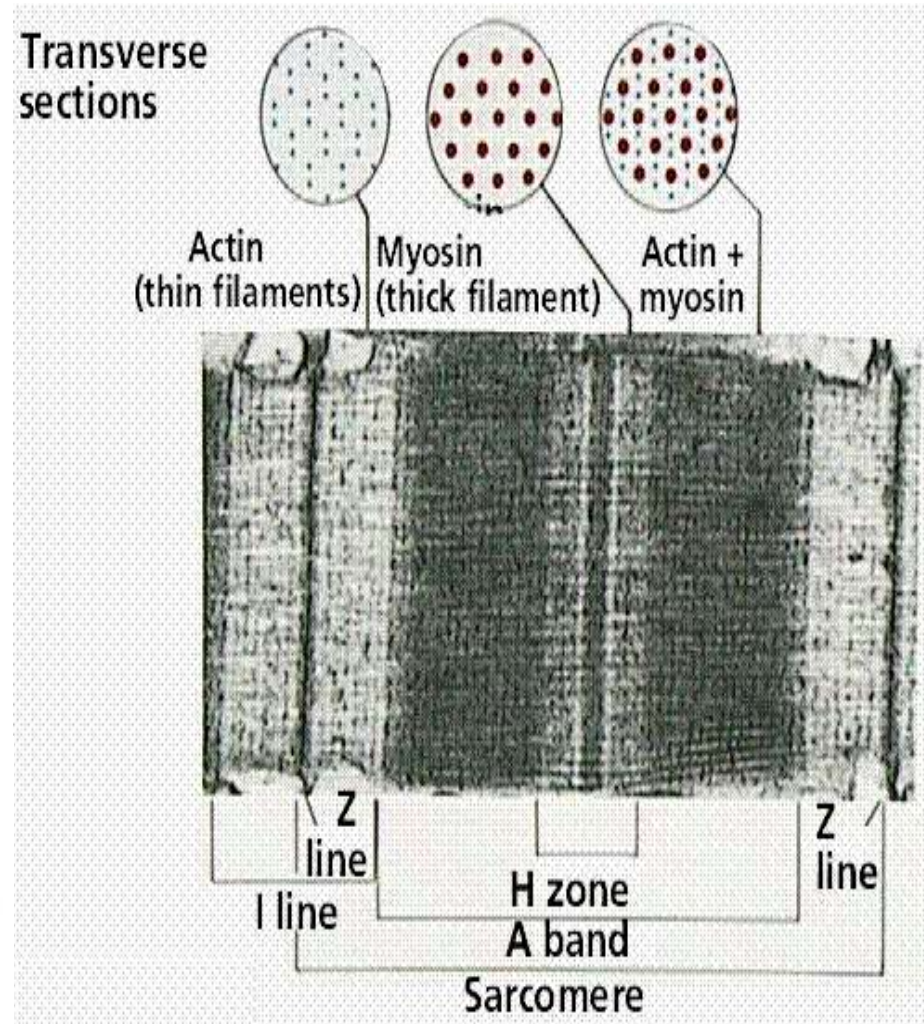
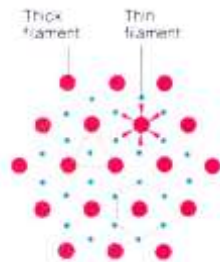
Triad

MYOFIBRILS

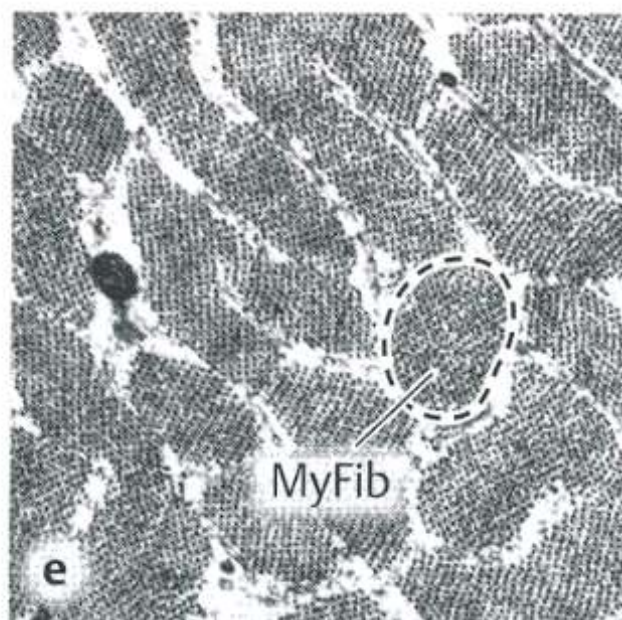

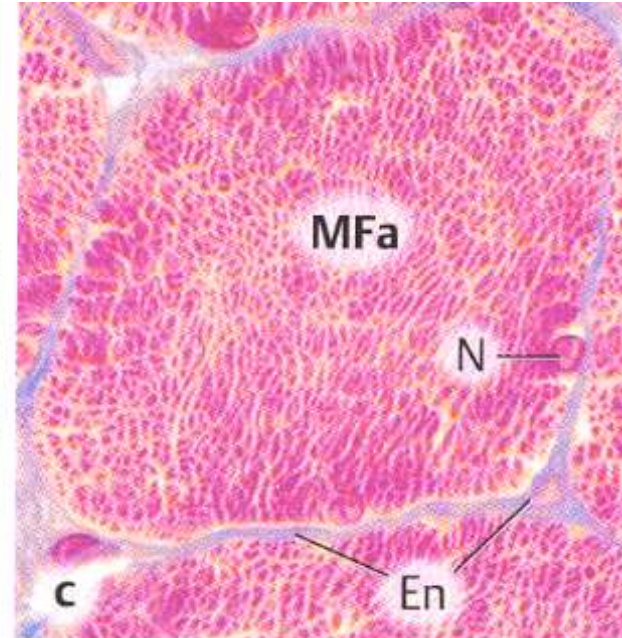


- elongated structures [\varnothing 0.5 – 1.5 μ] in sarcoplasm of muscle fiber oriented in parallel to the length of the fiber,



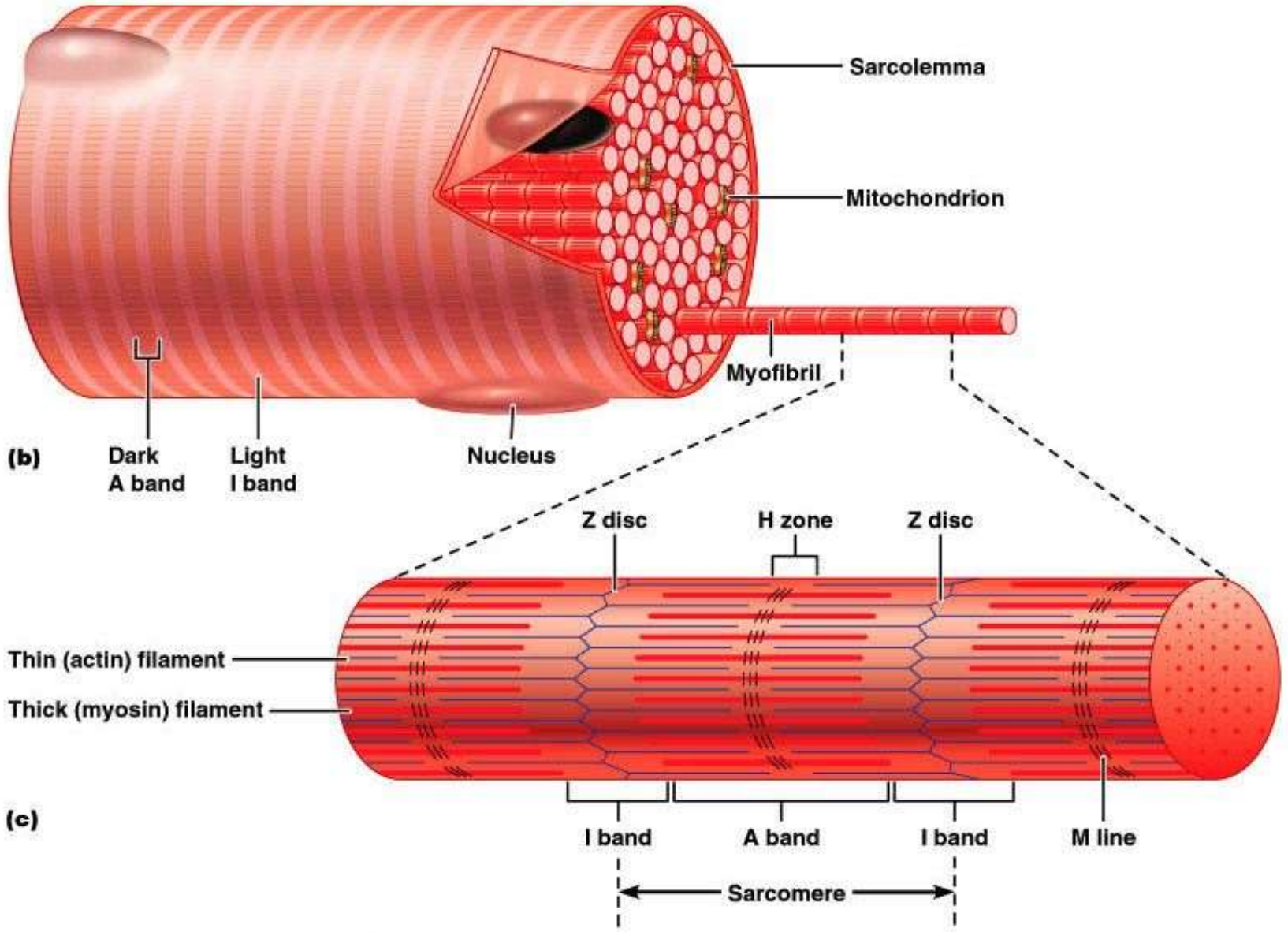
- Actin + myosin myofilaments
- Sarcomere
- Z-line
- M-line and H-zone
- I-band, A-band



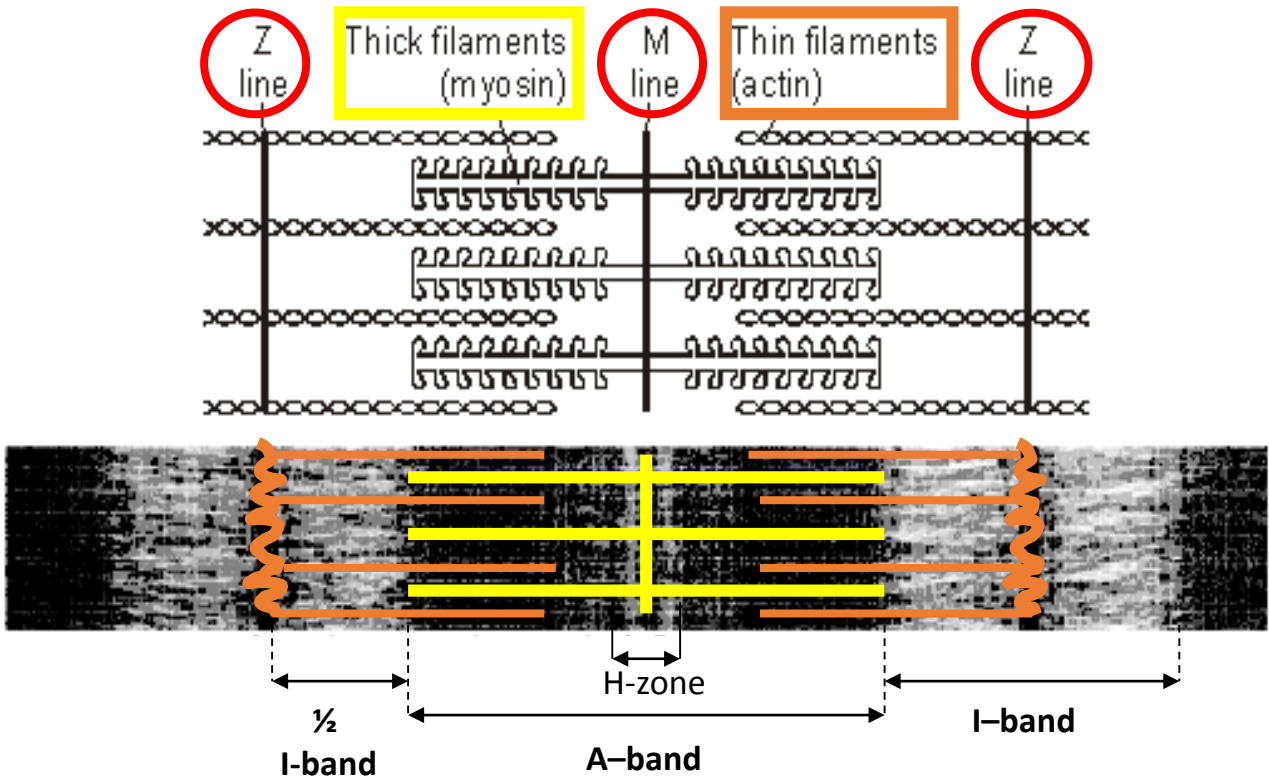
MYOFIBRILS




SARCOMERE



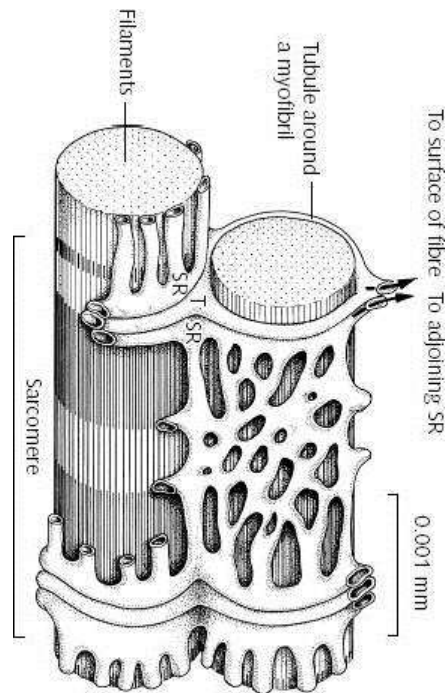
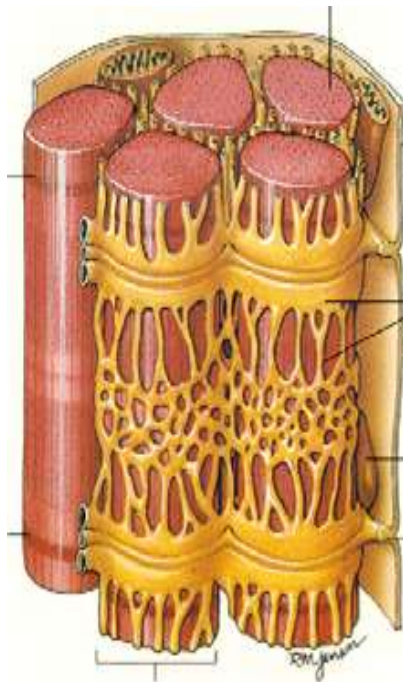
SARCOMERE



SARCOMERE



SARCOPLASMIC RETICULUM



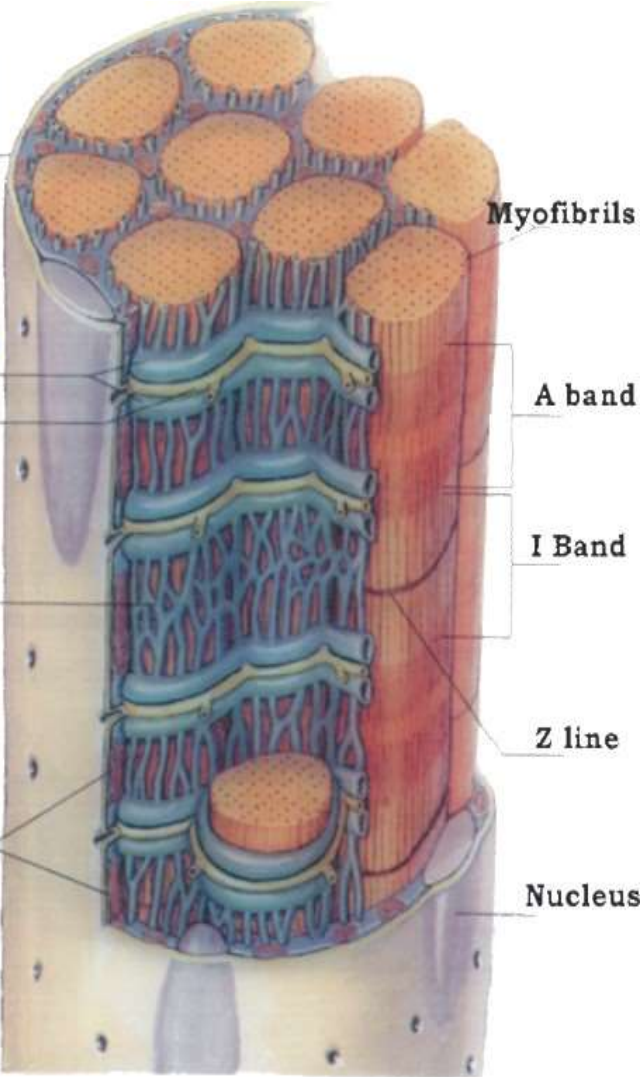

- Terminal cistern
- T-tubule
- Terminal cistern

TRIAD

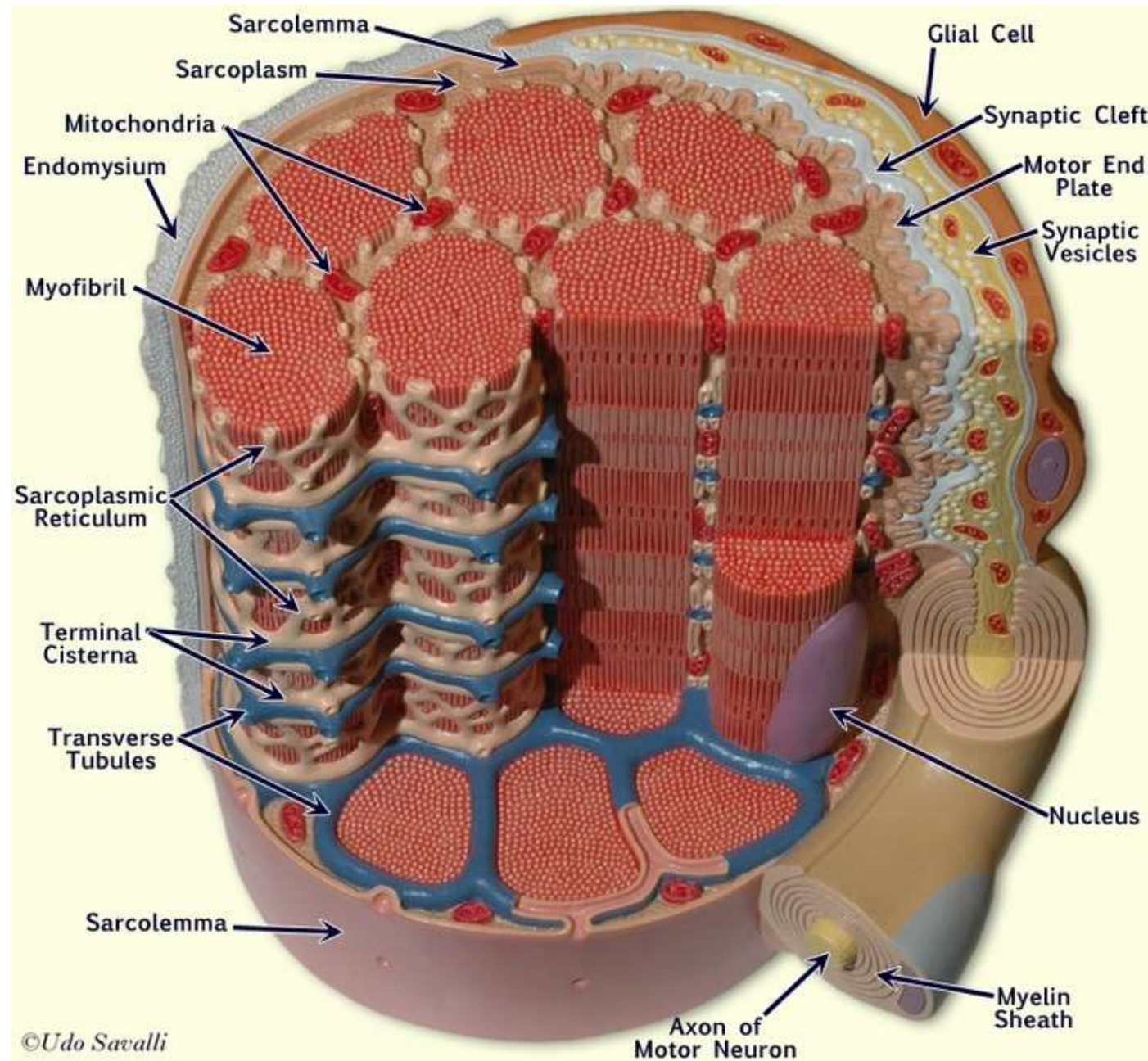
- communicating intracellular cavities around myofibrils, separated from cytosol
- **terminal cisternae** (“junction”) and **longitudinal tubules** (“L” system).
- reservoir of Ca^{++} ions

- **T-tubules** (“T” system) are invaginations of sarcoplasm and bring action potential to terminal cisternae change permeability of membrane for Ca^{++} ions

SARCOPLASMIC RETICULUM

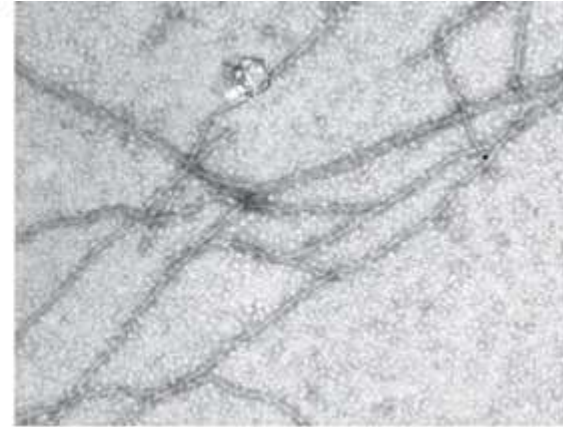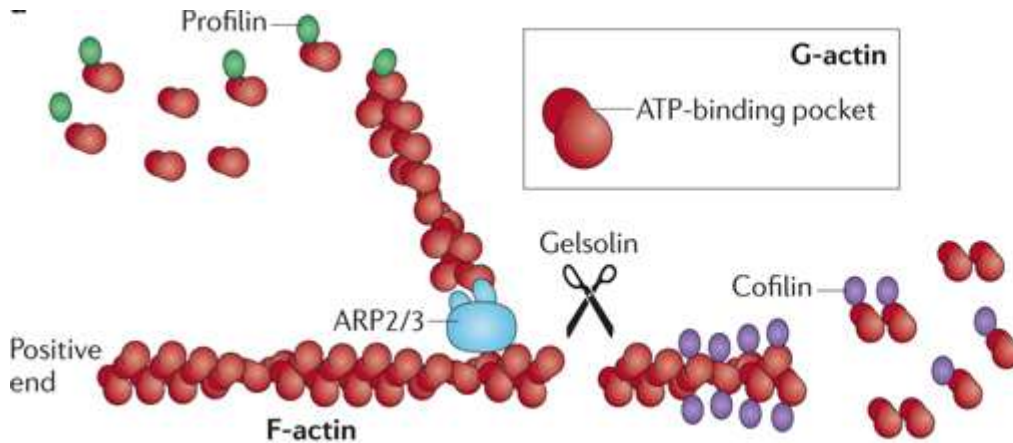


ULTRASTRUCTURE OF RHABDOMYOCYTE

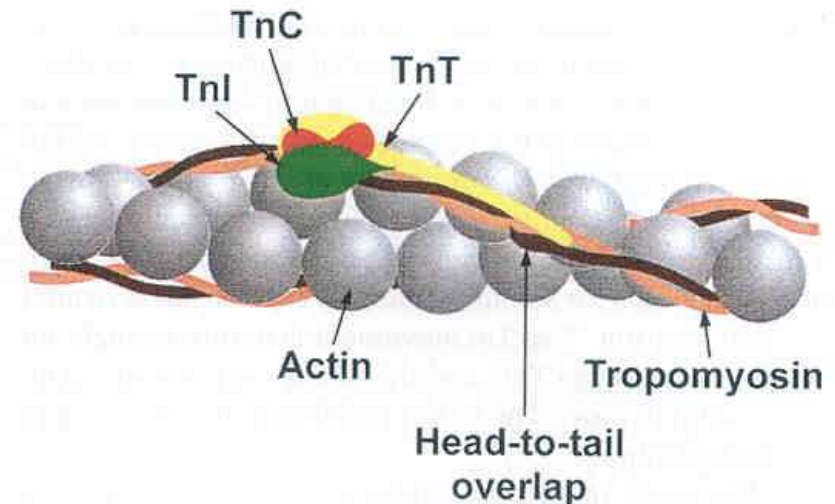


THIN MYOFILAMENTS

- **Fibrillar actin (F-actin)**, (\varnothing 7 nm, \leftrightarrow 1 μ m)



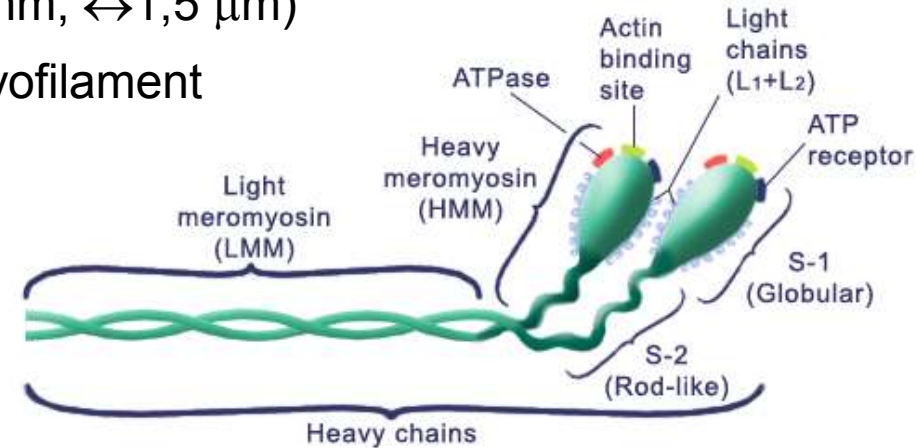
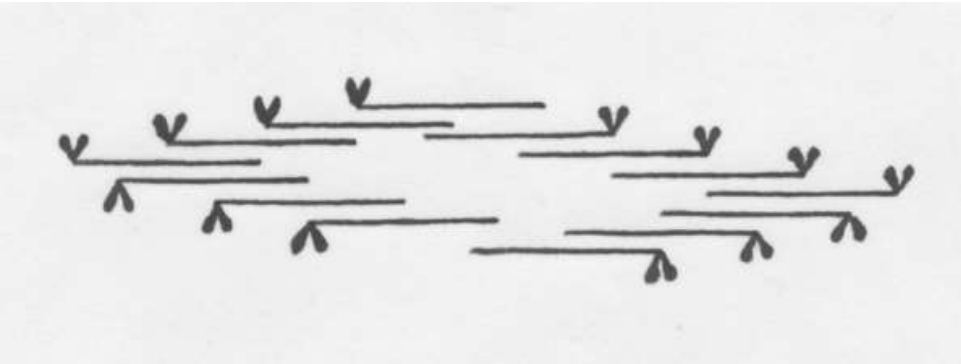
- Tropomyosin – thin double helix in groove of actin double helix, spans 7 monomers of G-actin
- Troponin – complex of 3 globular proteins
 - TnT (Troponin T) – binds tropomyosin
 - TnC (Troponin C) – binds calcium
 - TnI (Troponin I) inhibits interaction between thick and thin filaments



THICK MYOFILAMENTS

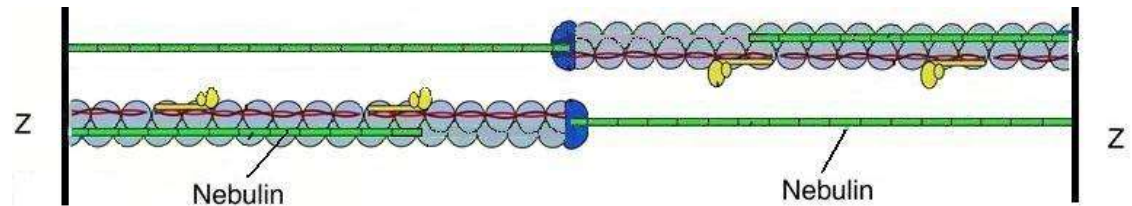
- **Myosin II**

- Large polypeptide, golf stick shape, (\varnothing 15 nm, \leftrightarrow 1,5 μ m)
- Bundles of myosin molecules form thick myofilament



- **Nebulin**


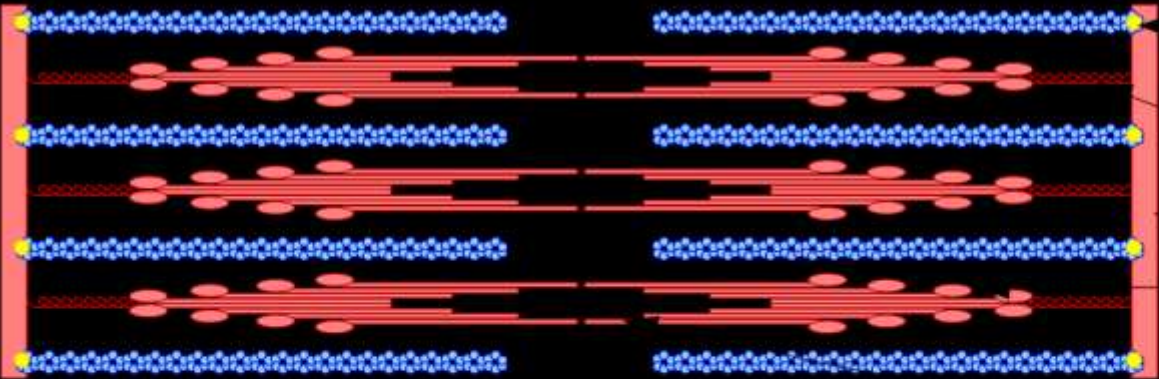
- 600-900kDa
- F-actin stabilization



- **Titin**

- >MDa
- Myosin II stabilization

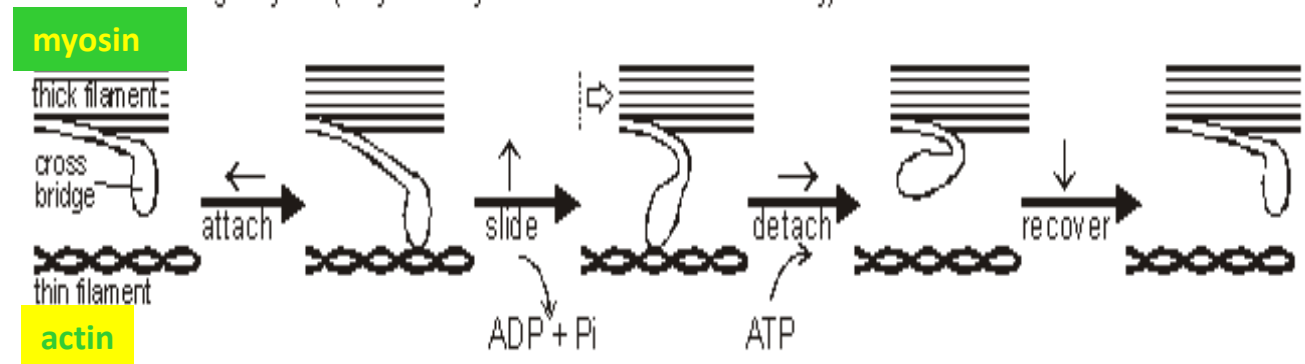
MYOFILAMENTS ASSEMBLE TO CONTRACTIVE STRUCTURES



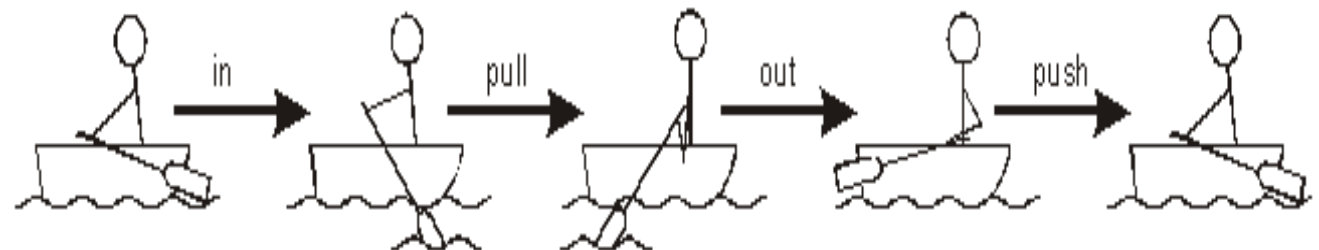
MYOFILAMENTS ASSEMBLE TO CONTRACTIVE STRUCTURES

- Propagation of action potential (depolarization) via T-tubule (= invagination of sarcolemma)
- Change of terminal cisternae permeability – releasing of Ca^+ ions increases their concentration in sarcoplasm
- Myosin binds actin - sarcomera then shortens by sliding movement – contraction
- Relaxation: repolarization, decreasing of Ca^{2+} ions concentration, inactivation of binding sites of actin for myosin

The Cross Bridge Cycle. (only one myosin head is shown for clarity)

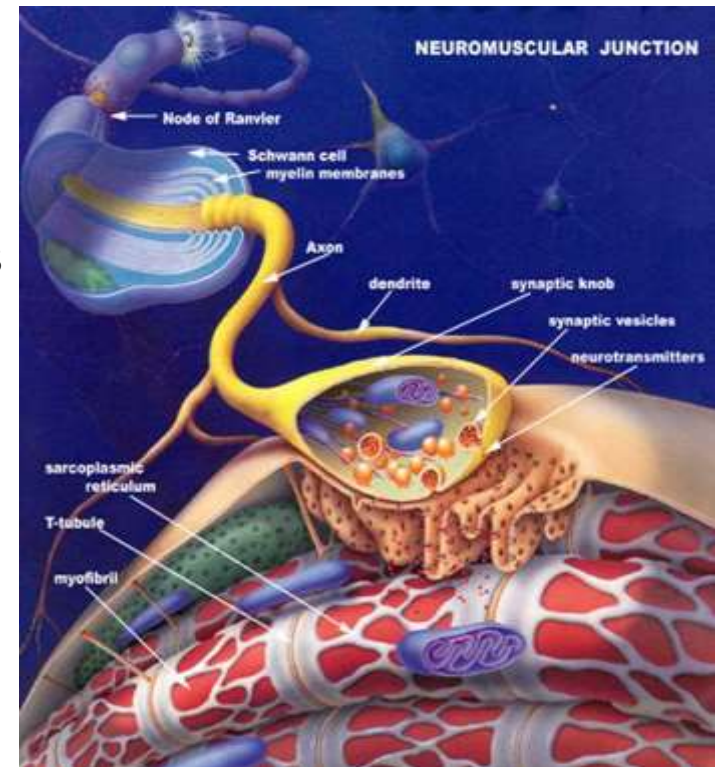


The Rowing Cycle



MECHANISM OF CONTRACTION

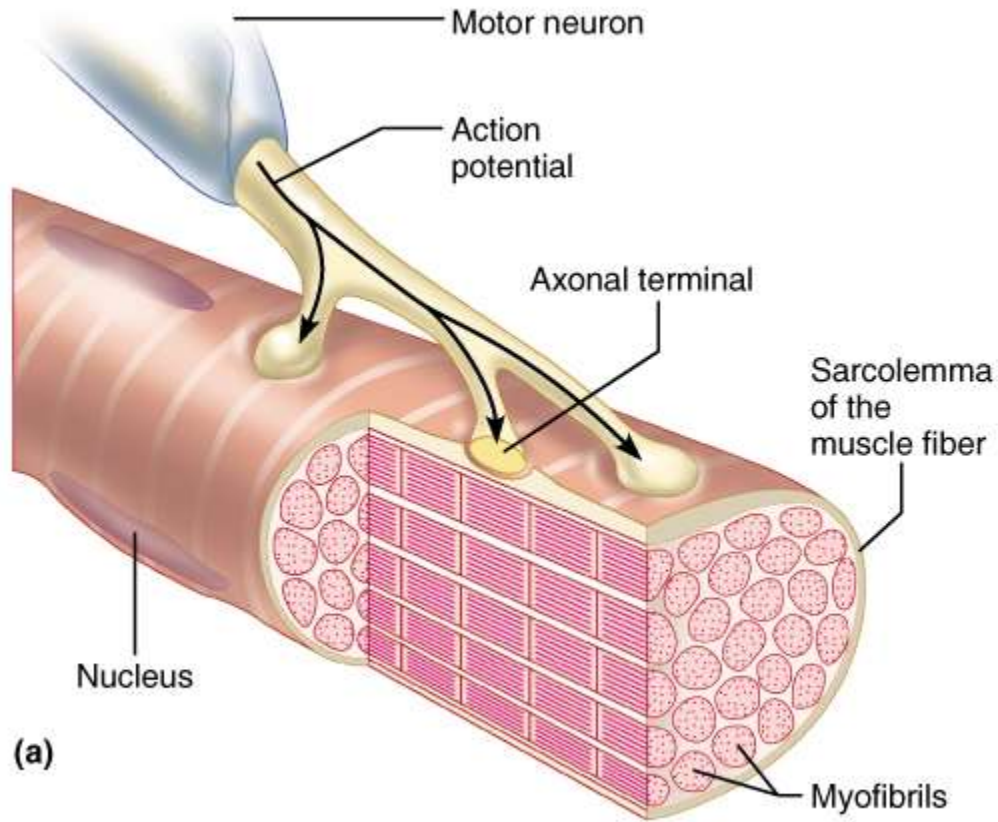
1. Impulse along motor neuron axon
2. Depolarization of presynaptic membrane (Na^+ influx)
3. Synaptic vesicles fuse with presynaptic membrane
4. Acetylcholine exocytosed to synaptic cleft
5. Acetylcholine diffuses over synaptic cleft
6. Acetylcholine binds to receptors in postsynaptic membrane
7. Depolarization of postsynaptic membrane and sarcolemma (Na^+ influx)
8. T-tubules depolarization
9. Depolarization of terminal cisternae of sER
10. Depolarization of complete sER
11. Release of Ca^{2+} from sER to sarcoplasm
12. Ca^{2+} binds TnC
13. Troponin complex changes configuration
14. Tropomyosin removed from actin-myosin binding sites
15. Globular parts of myosin bind to actin
16. ATPase in globular parts of myosin activated
17. Energy generated from $\text{ATP} \rightarrow \text{ADP} + \text{P}_i$
18. Movement of globular parts of myosin
19. Actin myofilament drag to the center of sarcomere
20. Sarcomeres contract (H-zone, I-band shorten)
21. Myofibrils contracted
22. Muscle fiber contracted



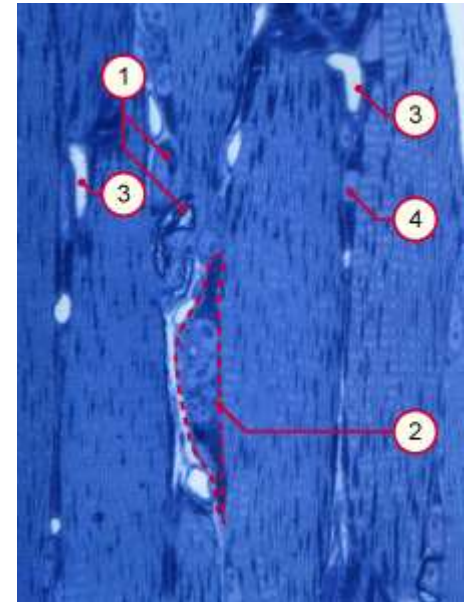
MECHANISM OF CONTRACTION

http://highered.mheducation.com/sites/0072495855/student_view0/chapter10/animation__breakdown_of_atp_and_cross-bridge_movement_during_muscle_contraction.html

NEUROMUSCULAR JUNCTION

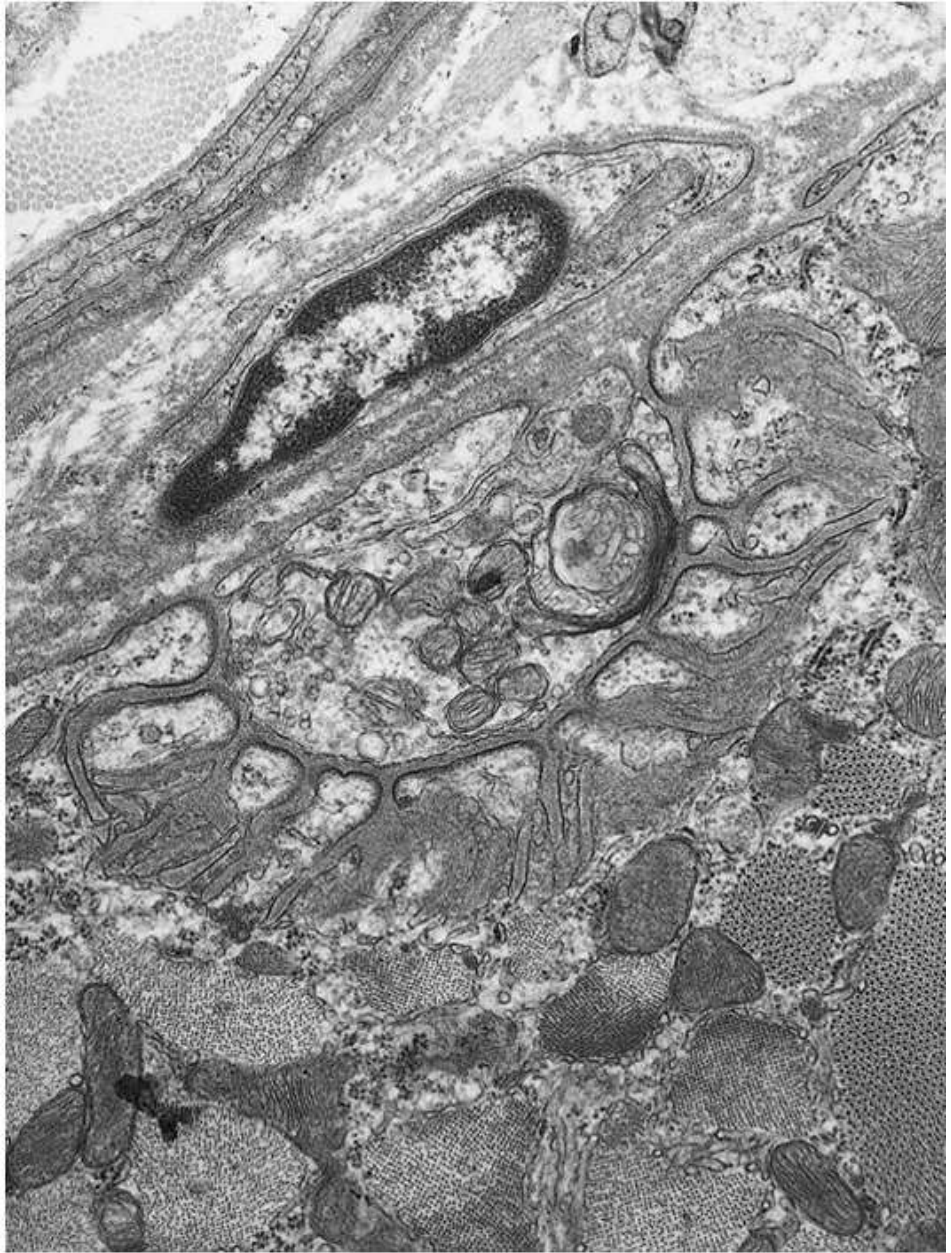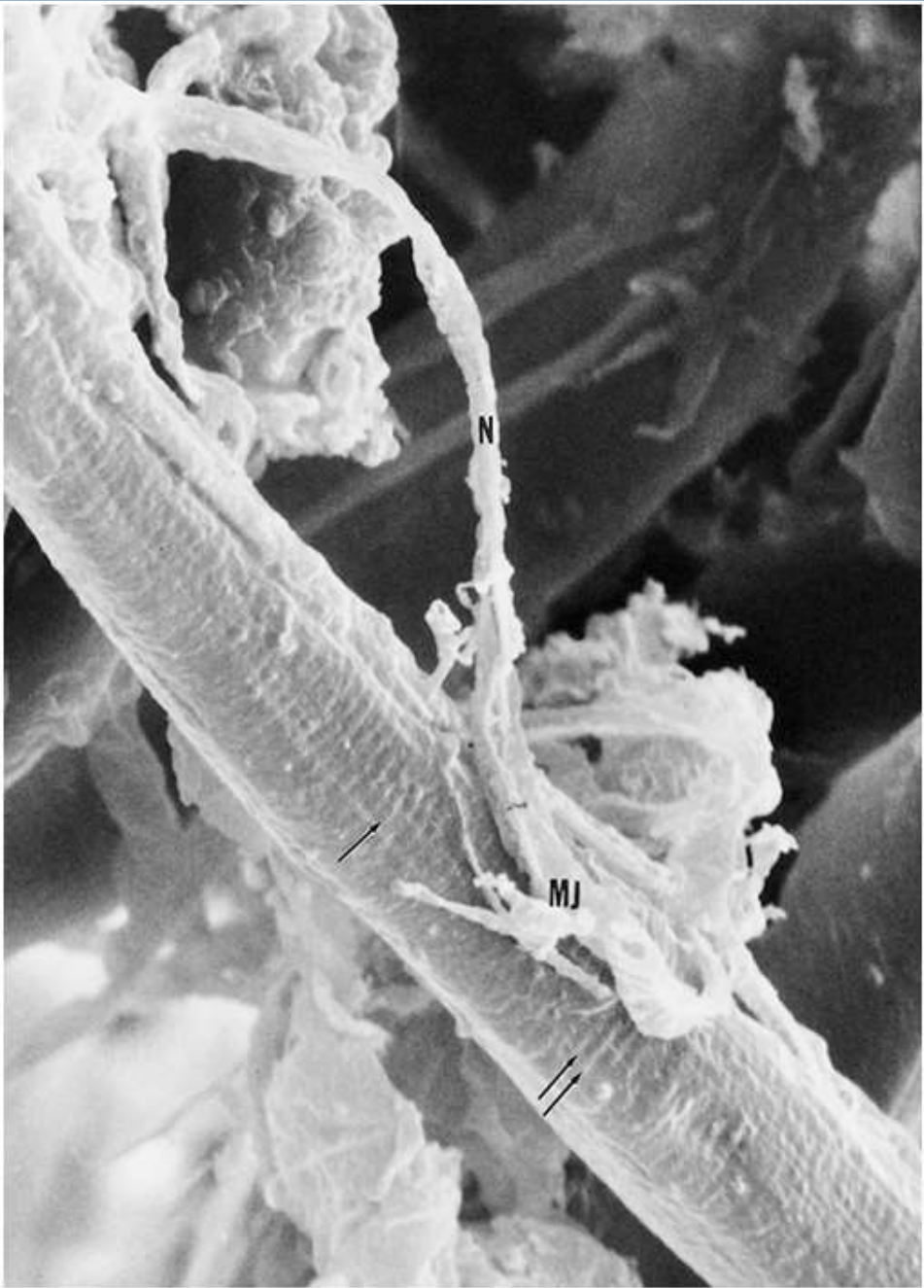


Copyright © 2001 Benjamin Cummings, an imprint of Addison Wesley Longman, Inc.

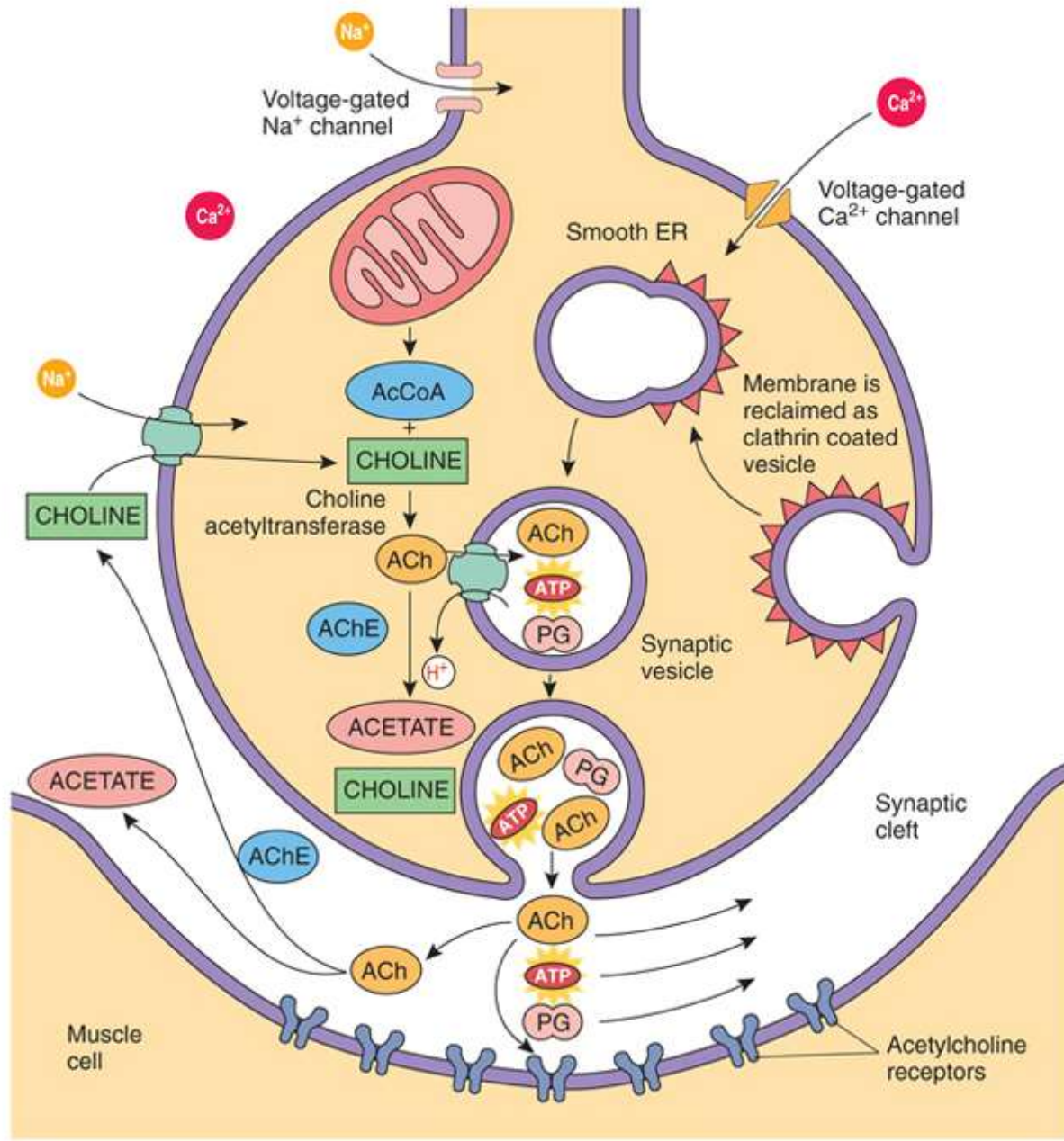


- 1 Myelinated axons
- 2 Neuromuscular junction
- 3 Capillaries
- 4 Muscle fiber nucleus

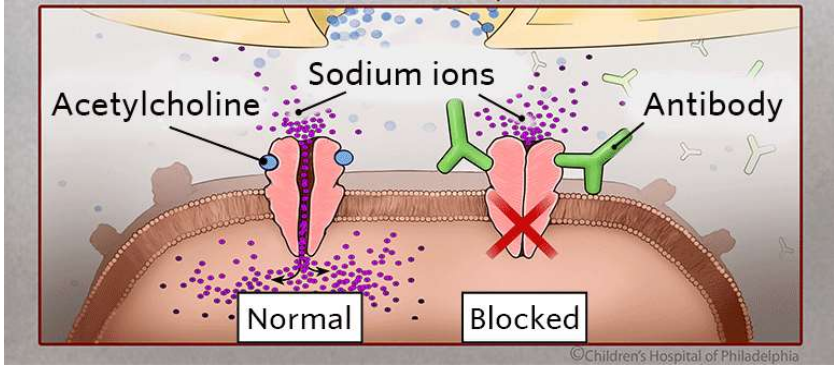
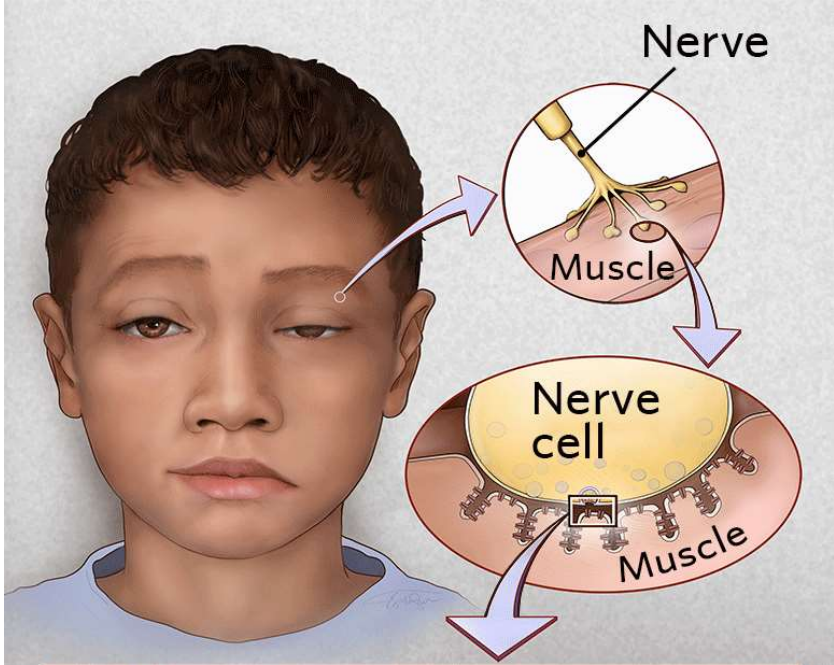
NEUROMUSCULAR JUNCTION



NEUROMUSCULAR JUNCTION



MYASTHENIA GRAVIS





Curare

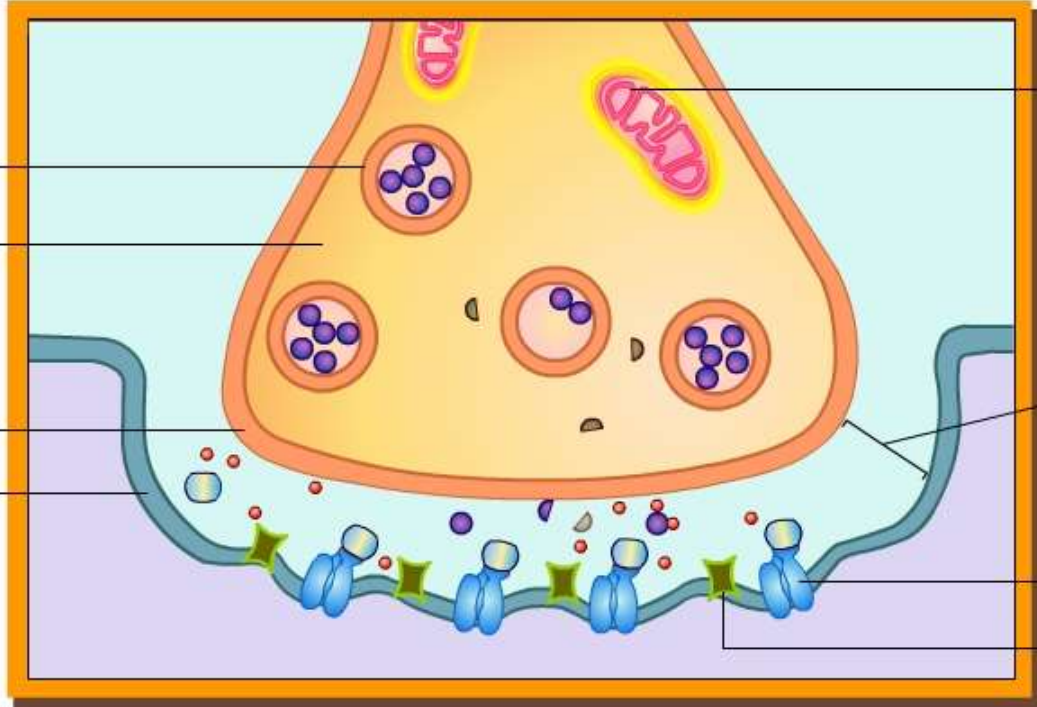
Synaptic vesicle

Synaptic knob

Presynaptic membrane

Postsynaptic membrane

- Curare
- Na⁺



Mitochondrion

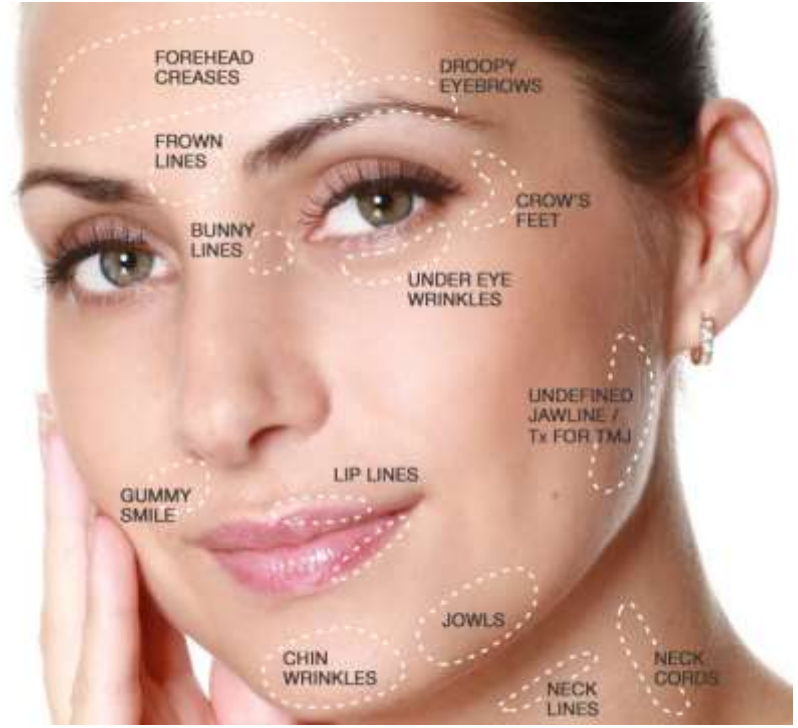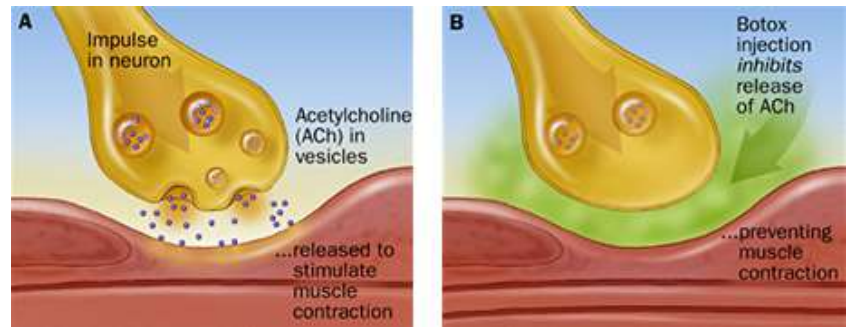

Synaptic cleft

Protein receptor

Acetylcholinesterase

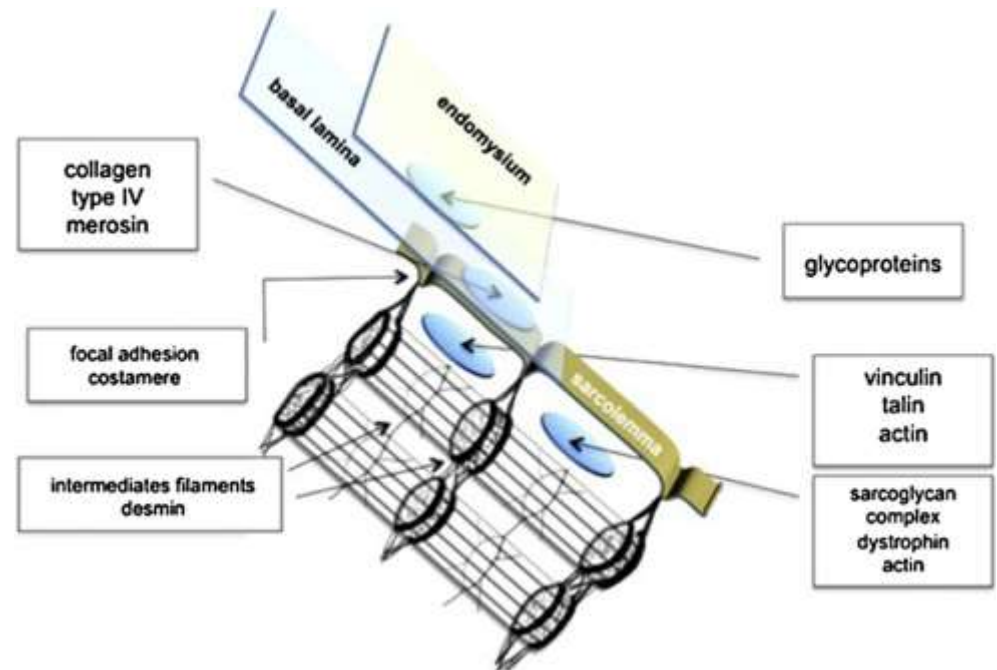
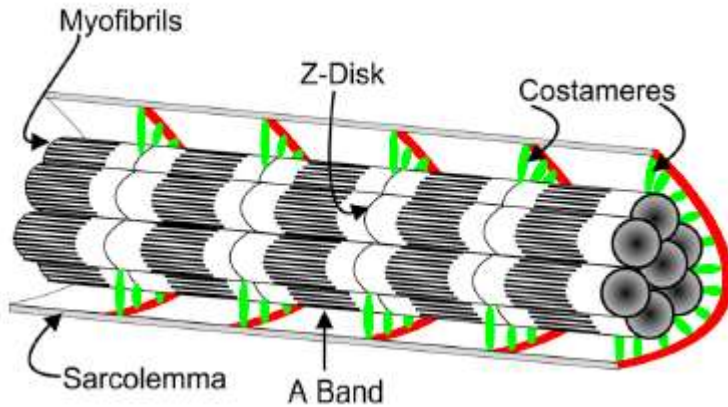
Botulotoxin

Clostridium botulinum

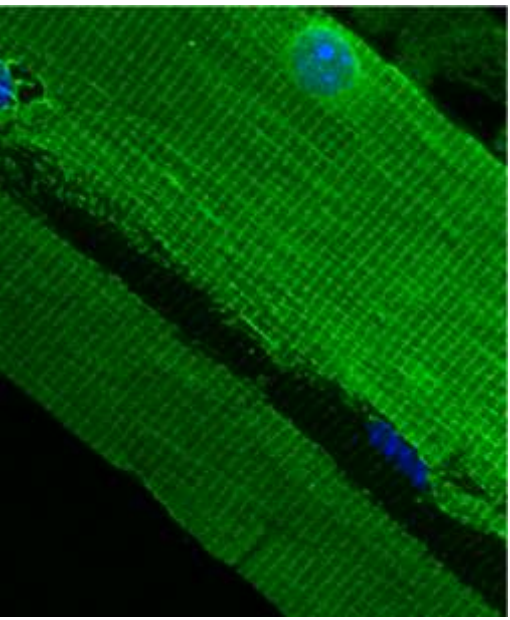
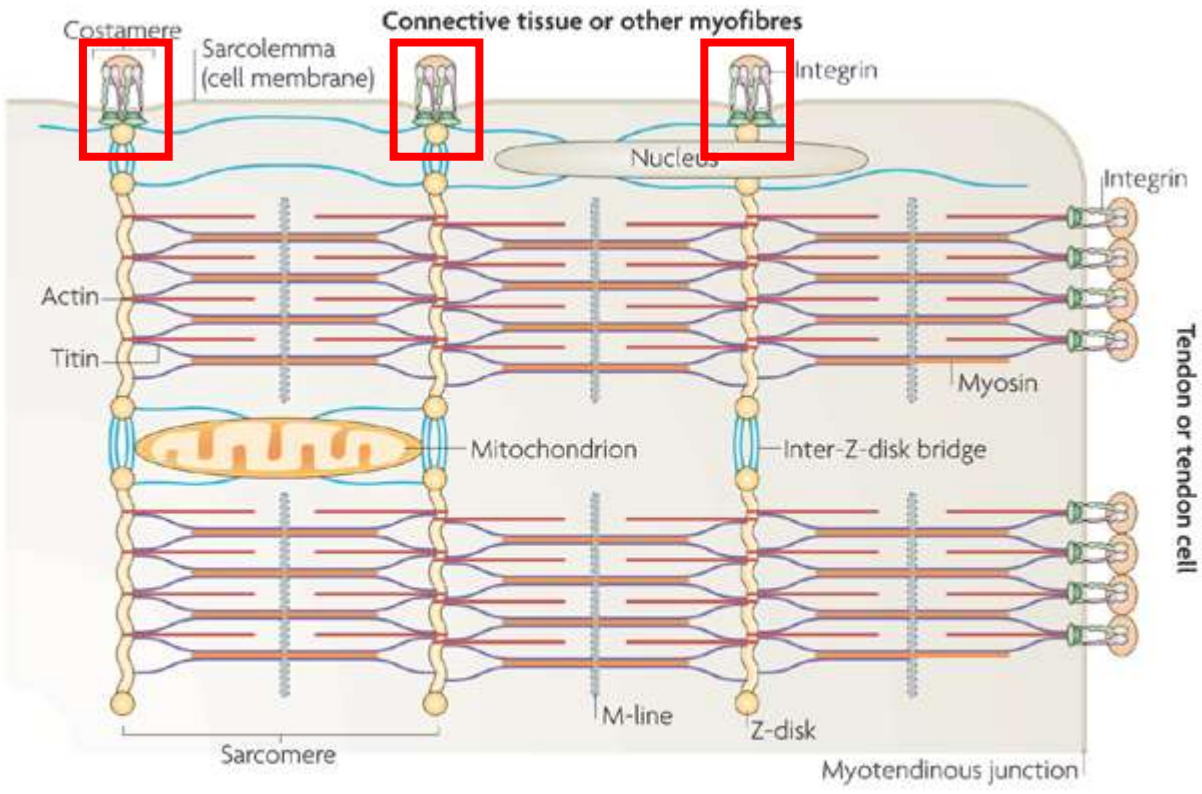


COSTAMERES

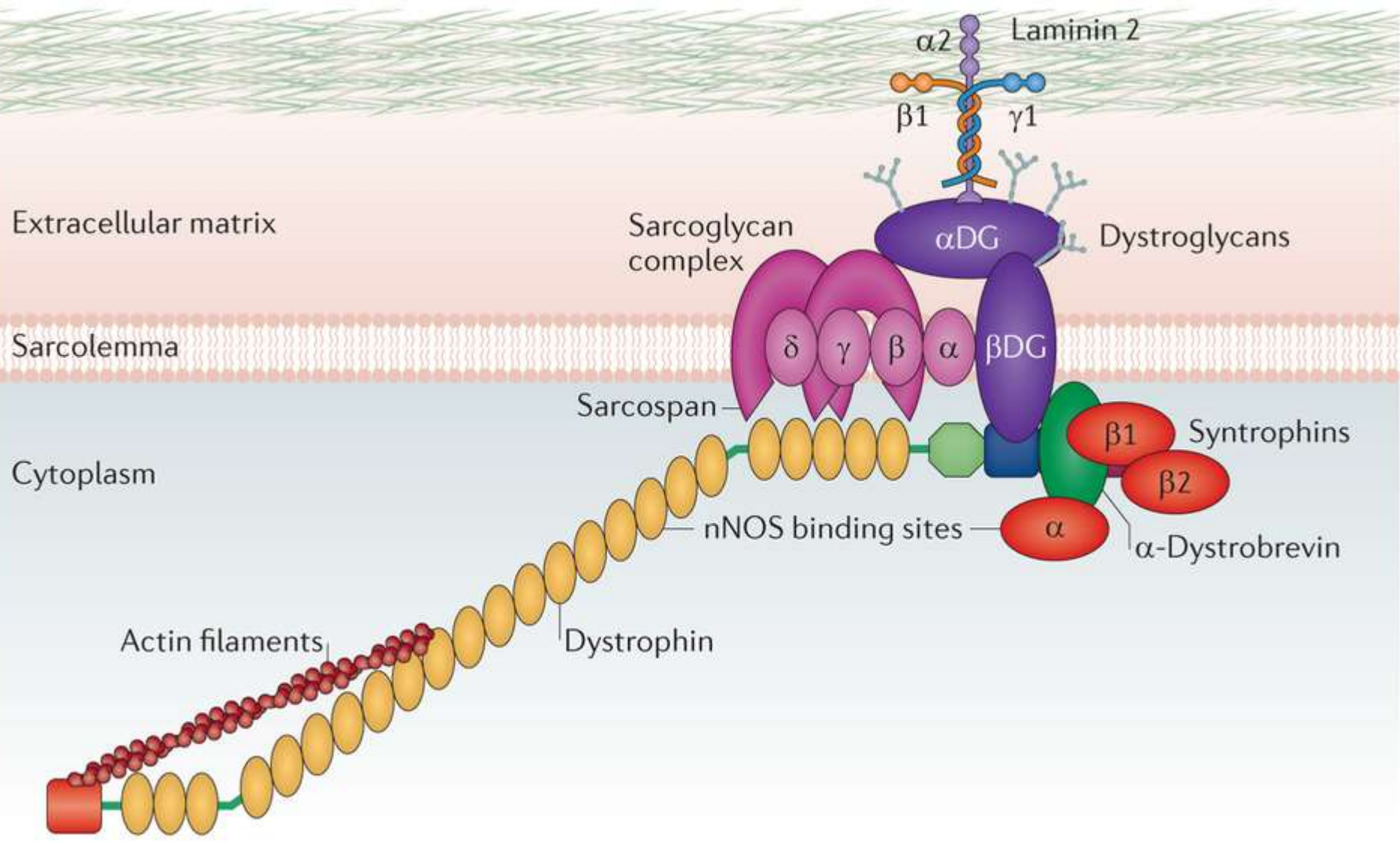
- Structural components linking myofibrils to sarcolemma
- Circumferential alignment
- **dystrophin-associated glycoprotein (DAG) complex**
 - links internal cytoskeleton to ECM
 - Integrity of muscle fiber



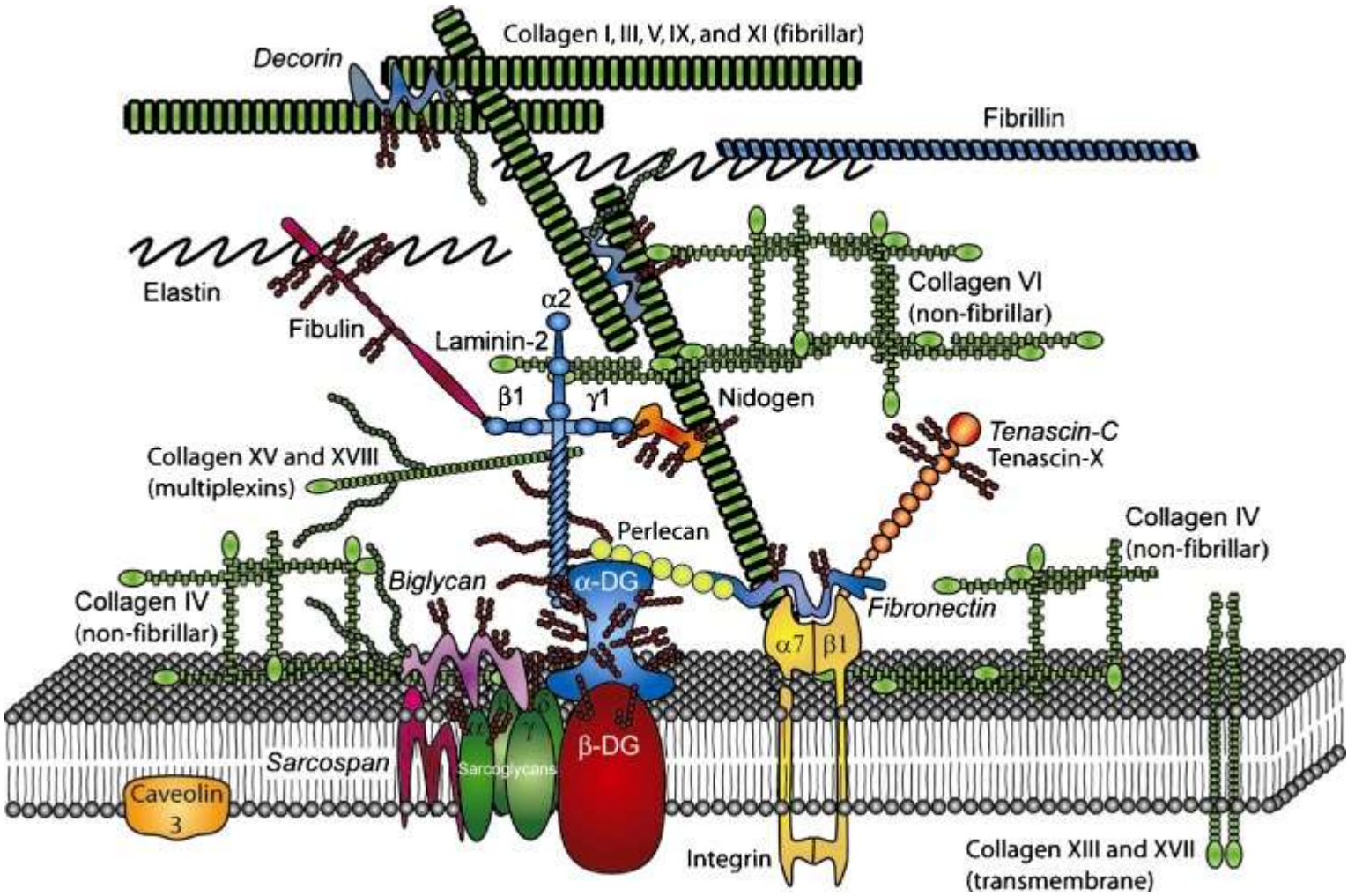
COSTAMERES



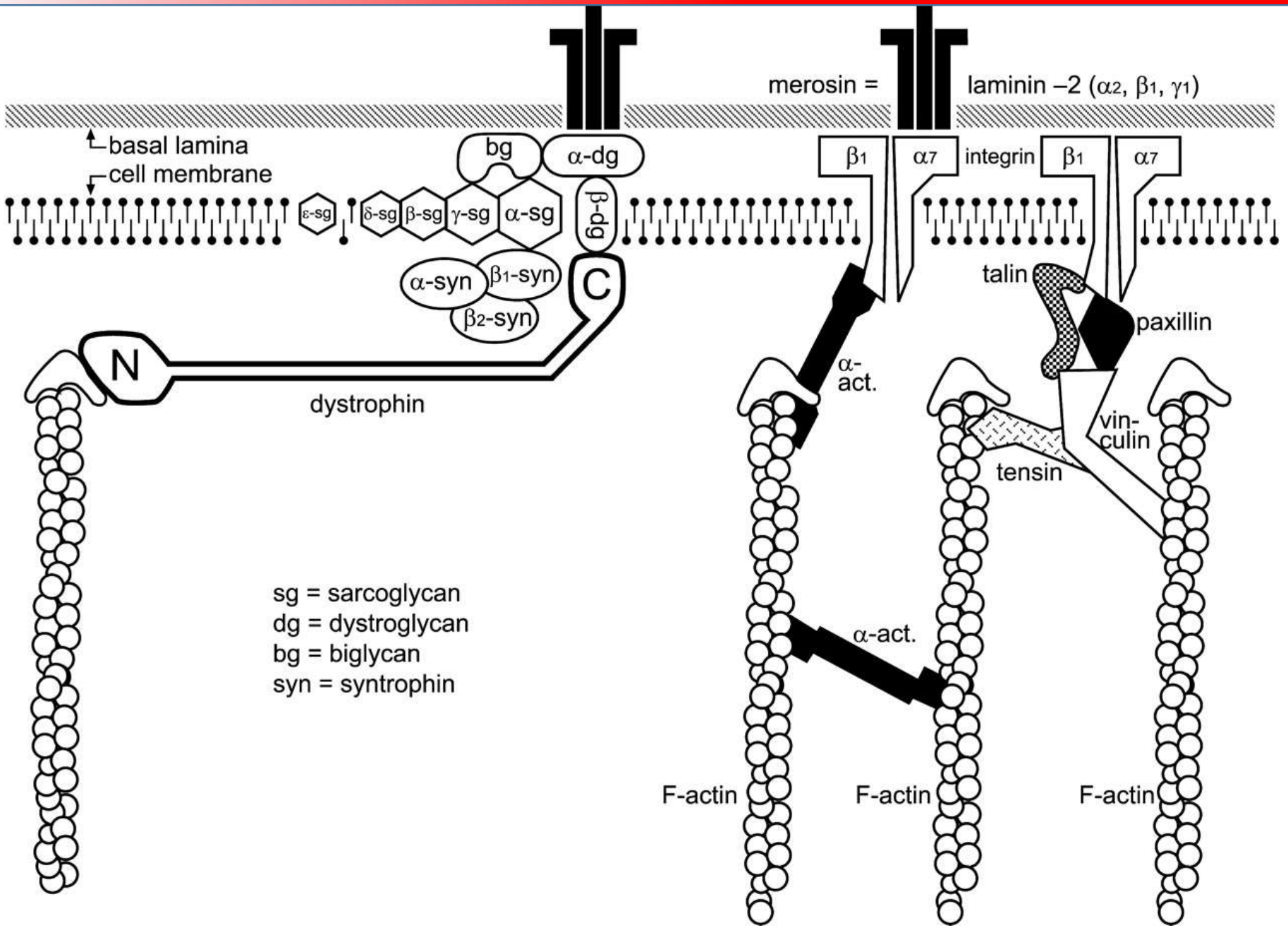
COSTAMERES



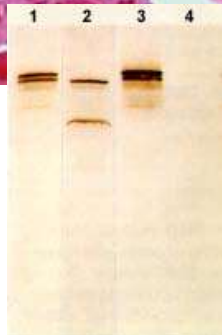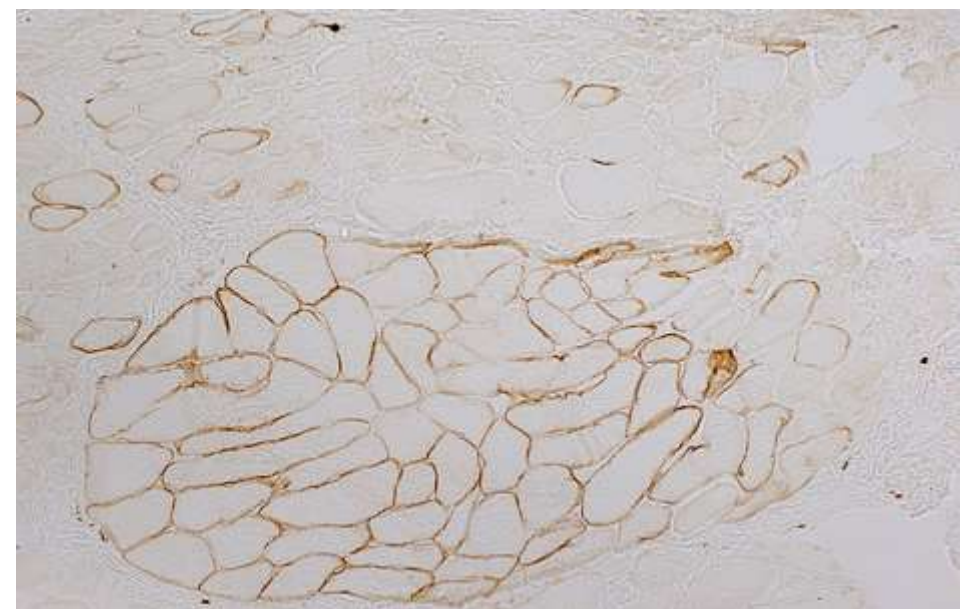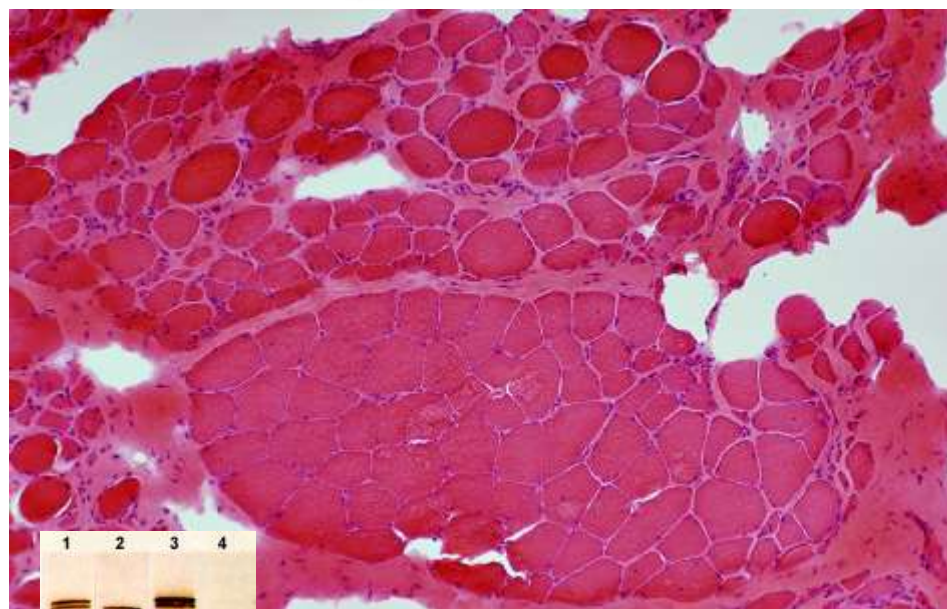
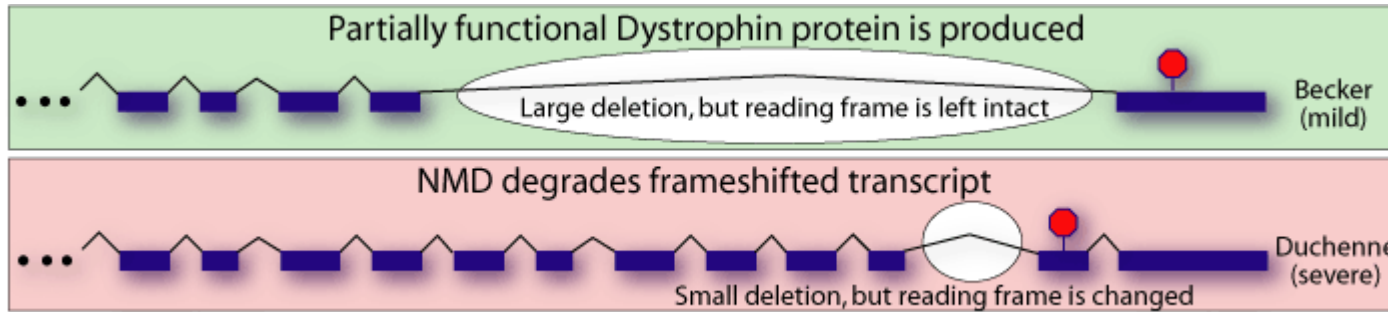
COSTAMERES



COSTAMERES

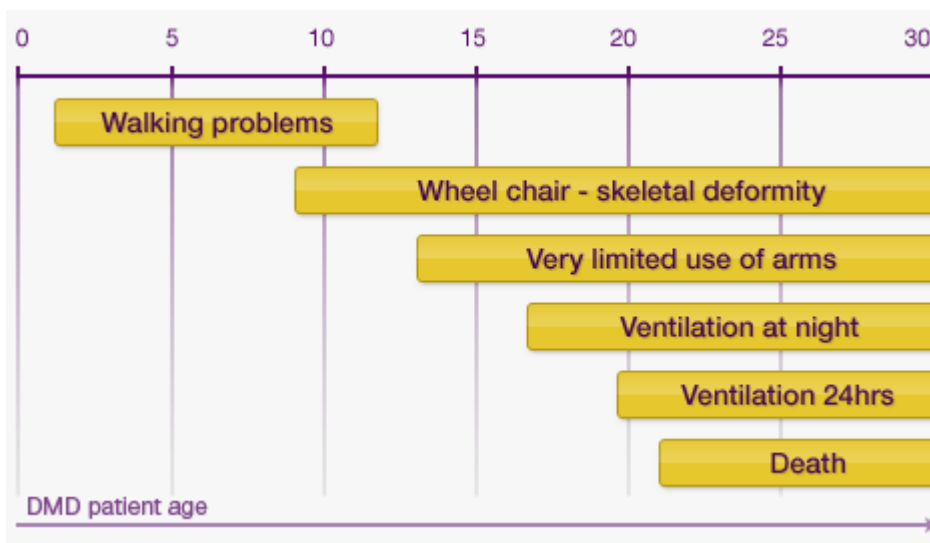
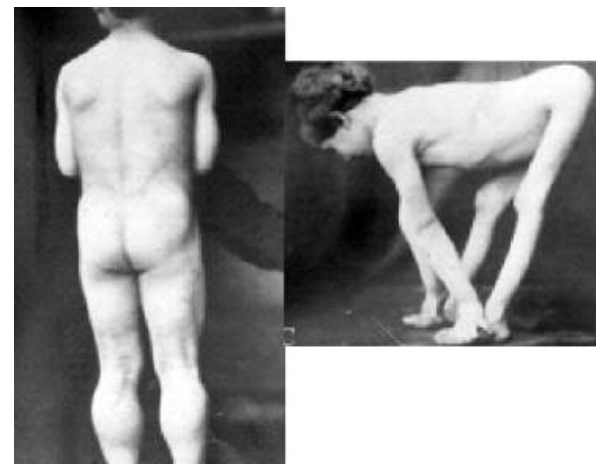
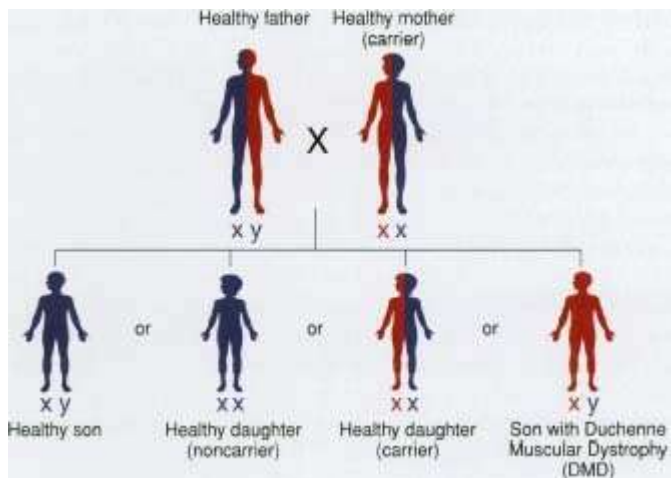


DUCHENNE MUSCULAR DYSTROPHY

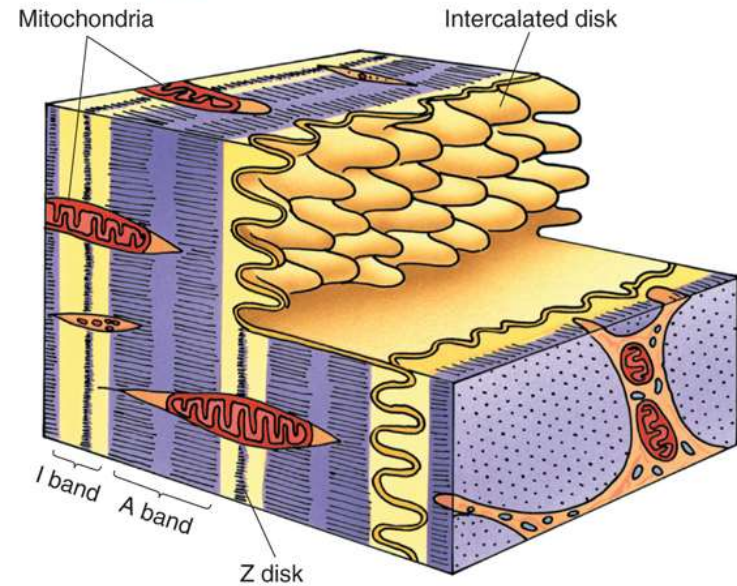
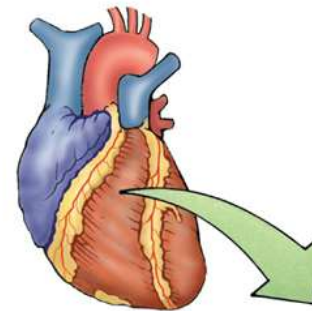
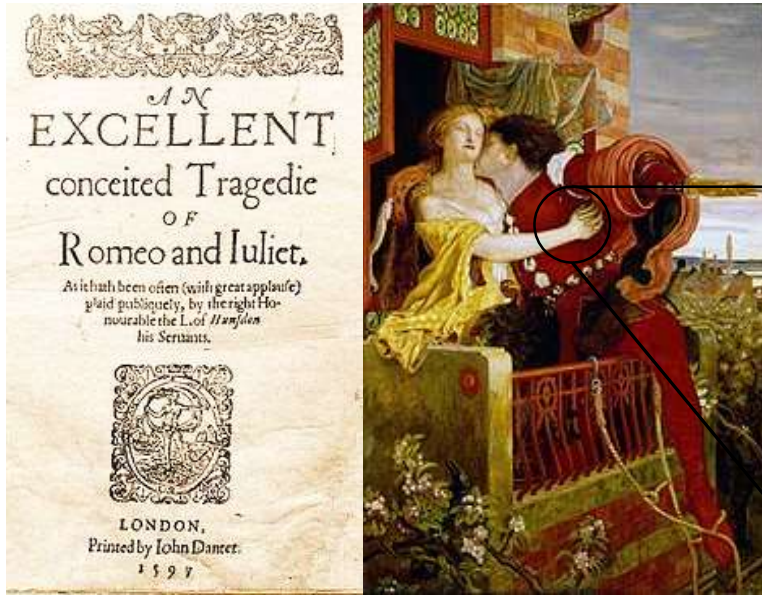

Lane 1: Becker dystrophy; Dystrophin has reduced abundance but normal size.
Lane 2: Becker dystrophy; Dystrophin has reduced size and abundance.
Lane 3: Normal; Dystrophin has normal size and amount.
Lane 4: Duchenne dystrophy; Almost no protein is present.

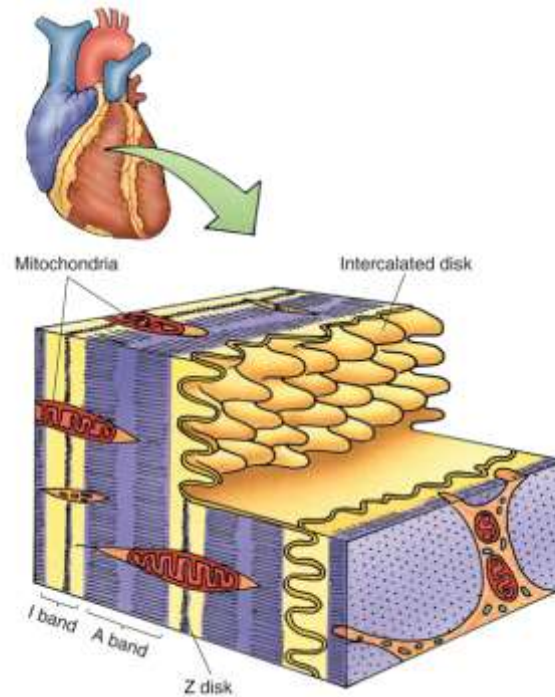
COSTAMERES



CARDIAC MUSCLE TISSUE

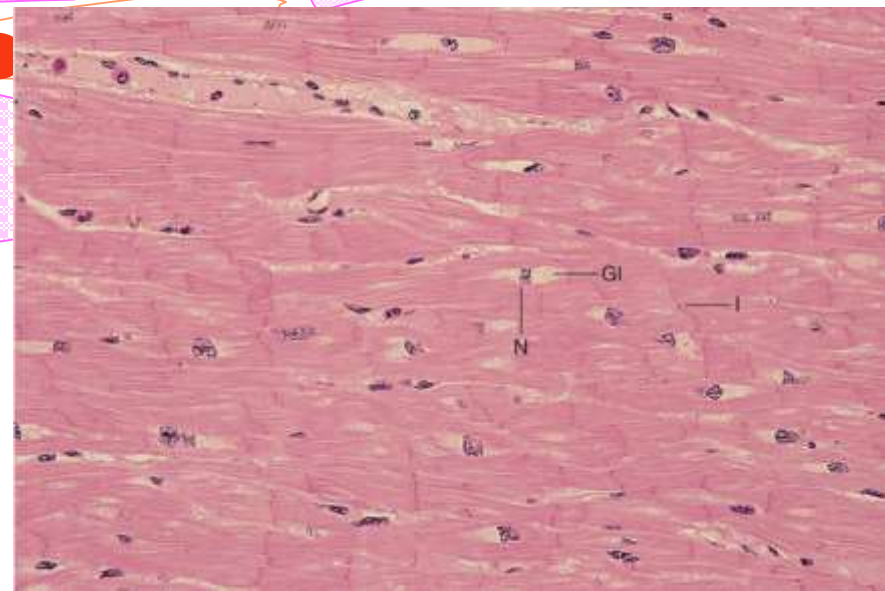
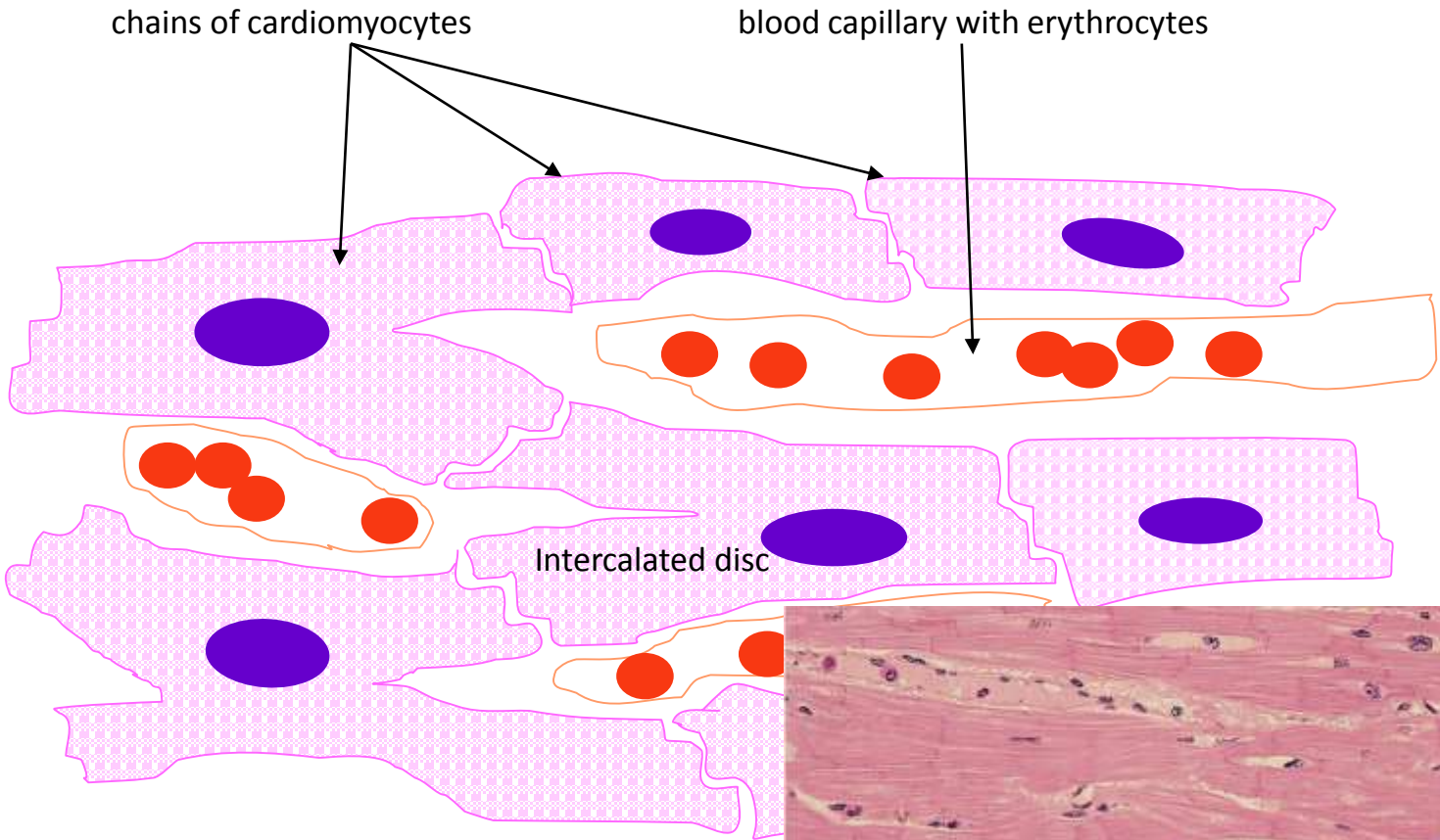


HISTOLOGY OF CARDIAC MUSCLE TISSUE

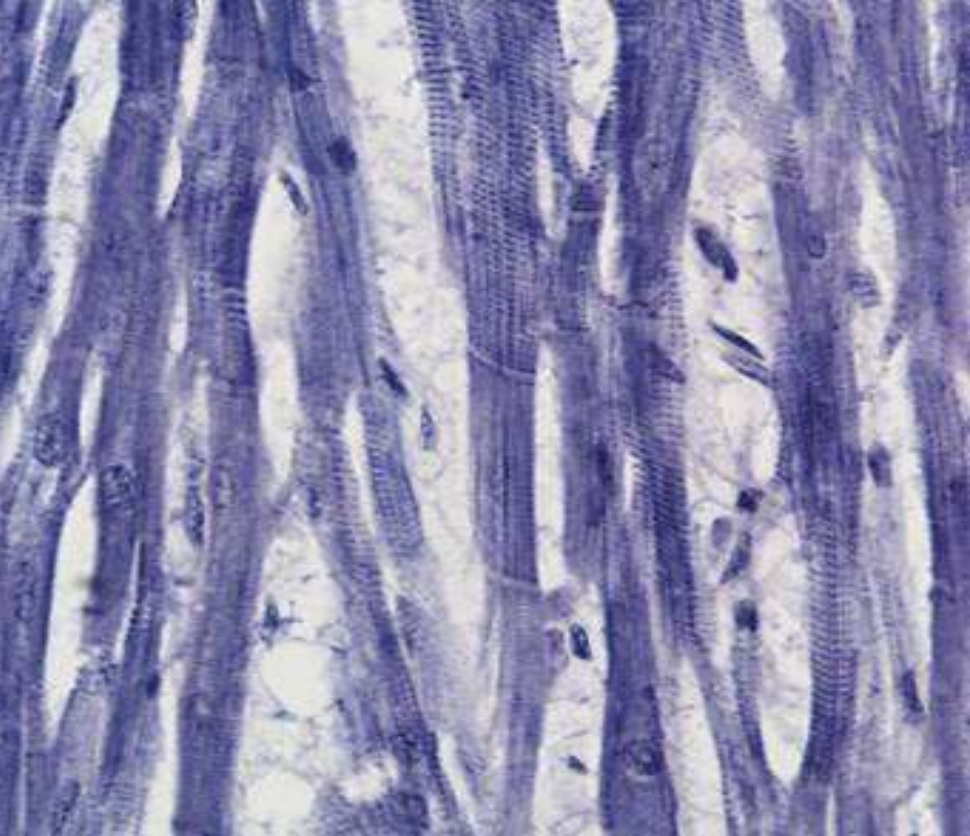
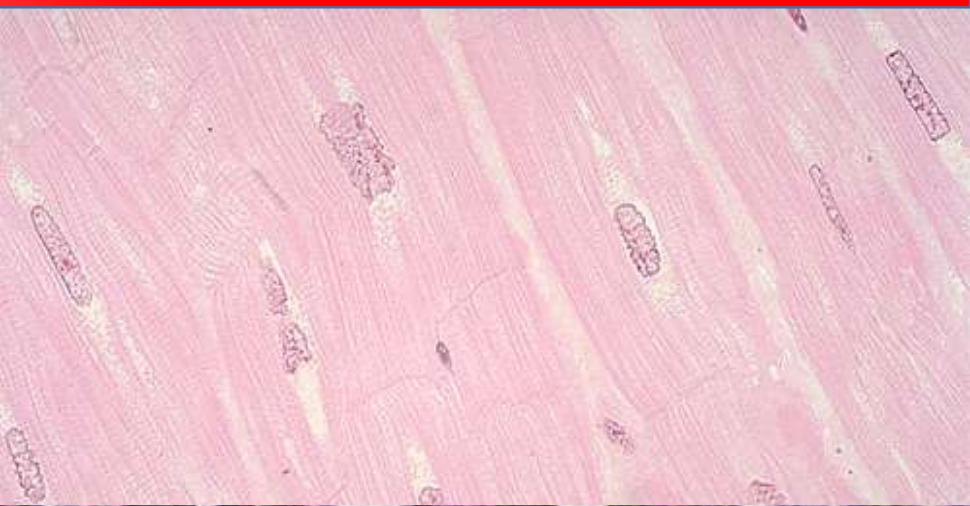
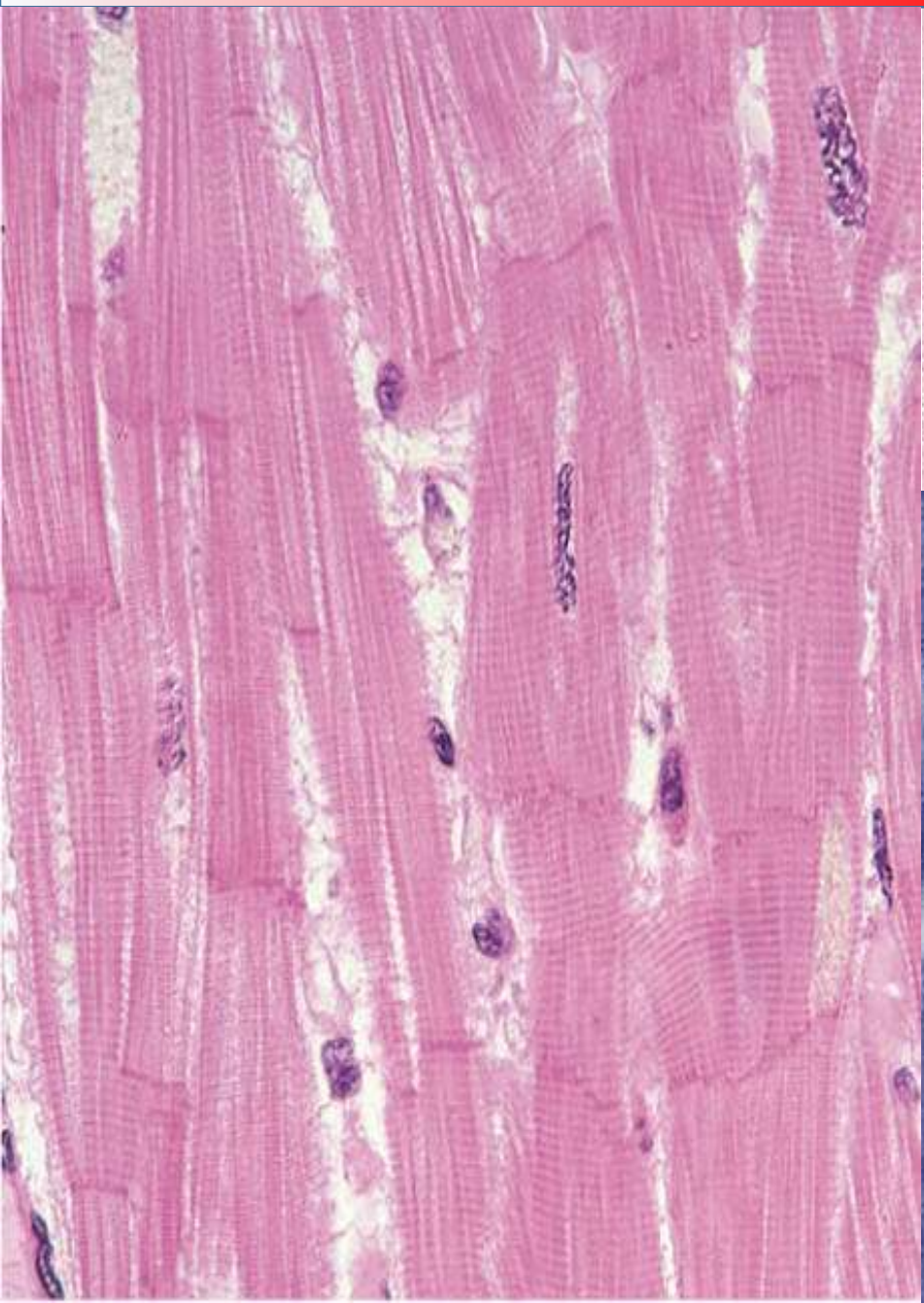


- made up of long branched fiber (cells) – **cardiomyocytes**,
- cardiomyocytes are cylindrical cells, branched on one or both ends (Y, X shaped cells),
- sarcoplasm: single nucleus in the center of cell, striated myofibrils, numerous mitochondria,
- cells are attached to one another by end-to-end junctions – intercalated discs.



HISTOLOGY OF CARDIAC MUSCLE TISSUE



HISTOLOGY OF CARDIAC MUSCLE TISSUE

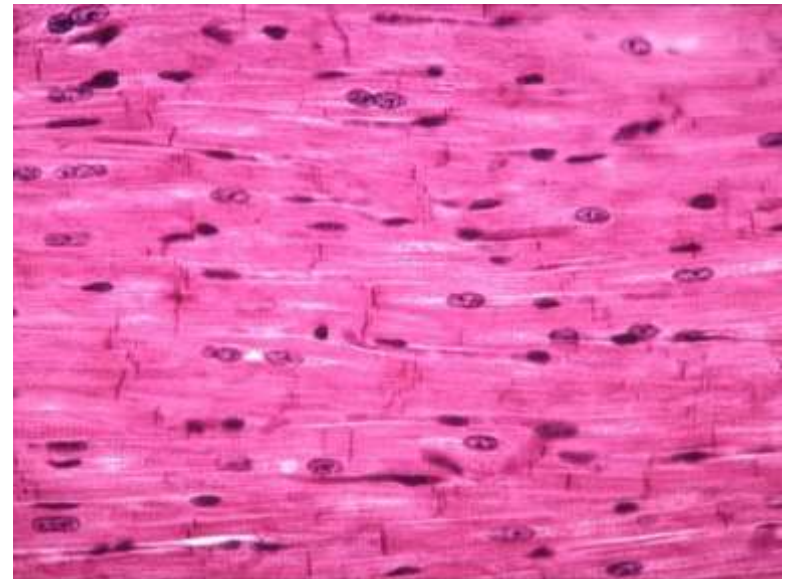
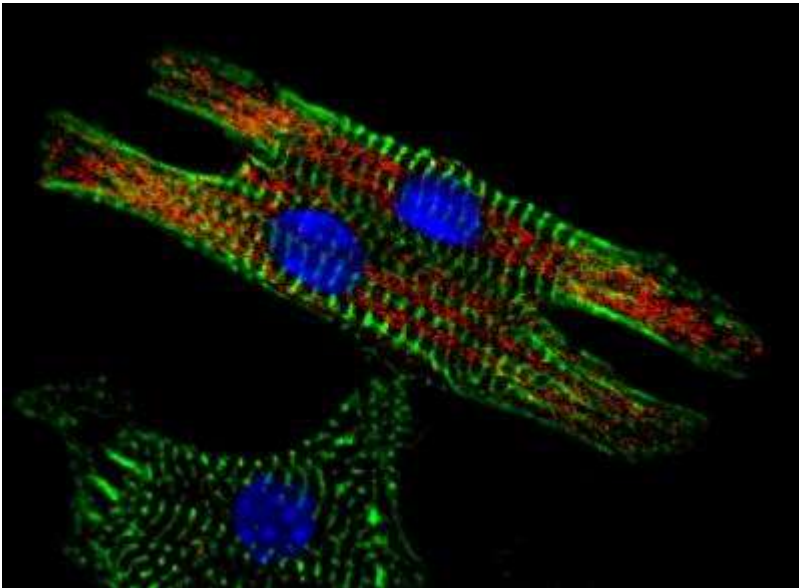


ULTRASTRUCTURE OF CARDIOMYCYTE



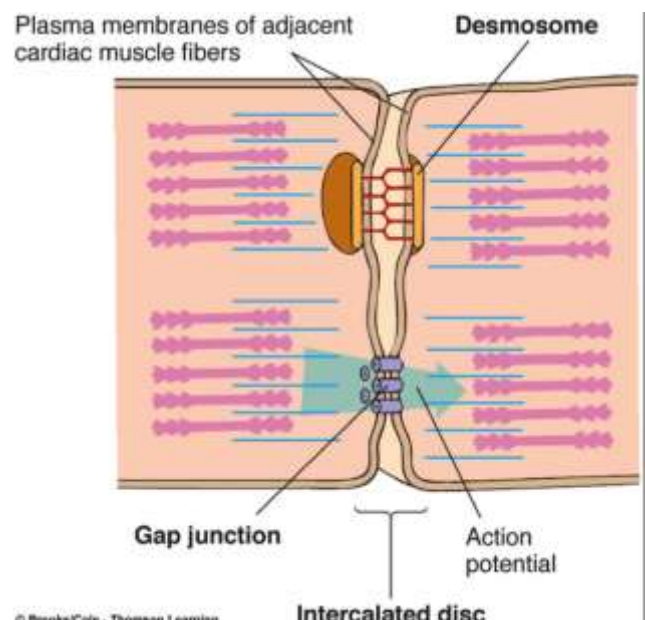
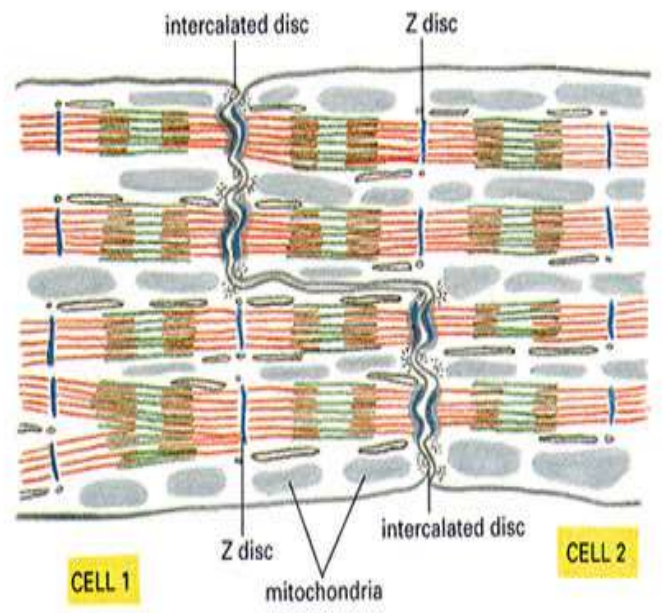
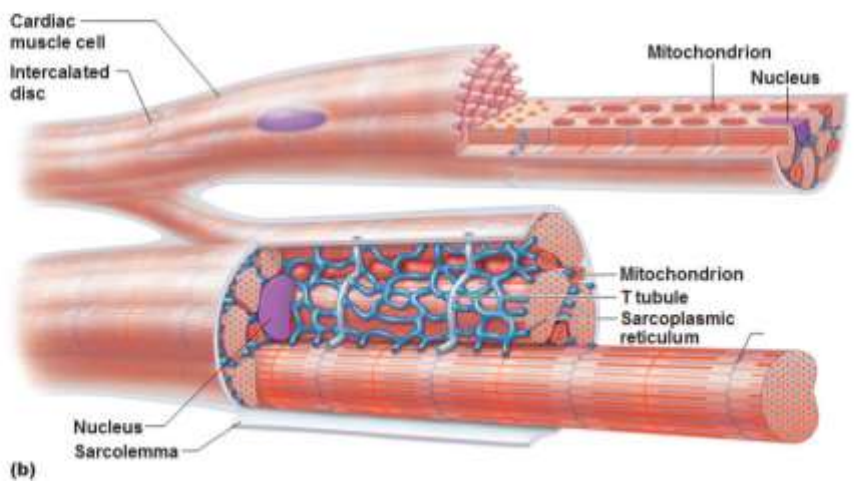
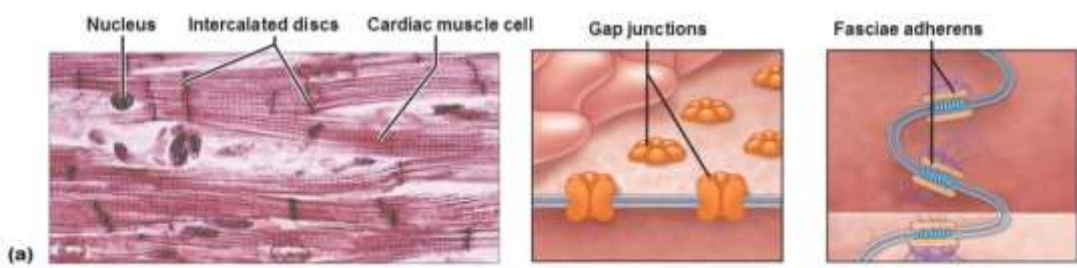
CARDIAC MUSCLE COMPARED TO SKELETAL

- no triads, but diads: 1 t-tubule + 1 cisterna
- t-tubules around the sarcomeres at the Z lines rather than at the zone of overlap
- sarcoplasmic reticulum via its tubules contact sarcolemma as well as the t-tubules
- cardiac muscle cells are totally dependent on aerobic metabolism to obtain the energy
- large numbers of mitochondria in sarcoplasm and abundant reserves of myoglobin (to store oxygen)
- abundant glycogen and lipid inclusions

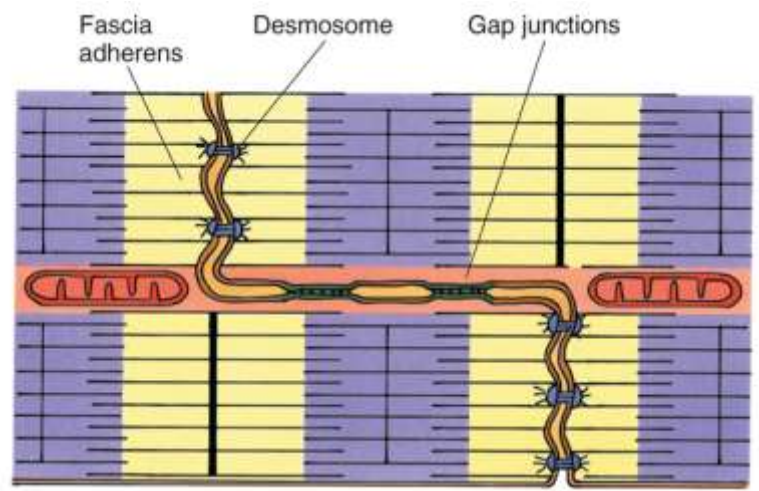
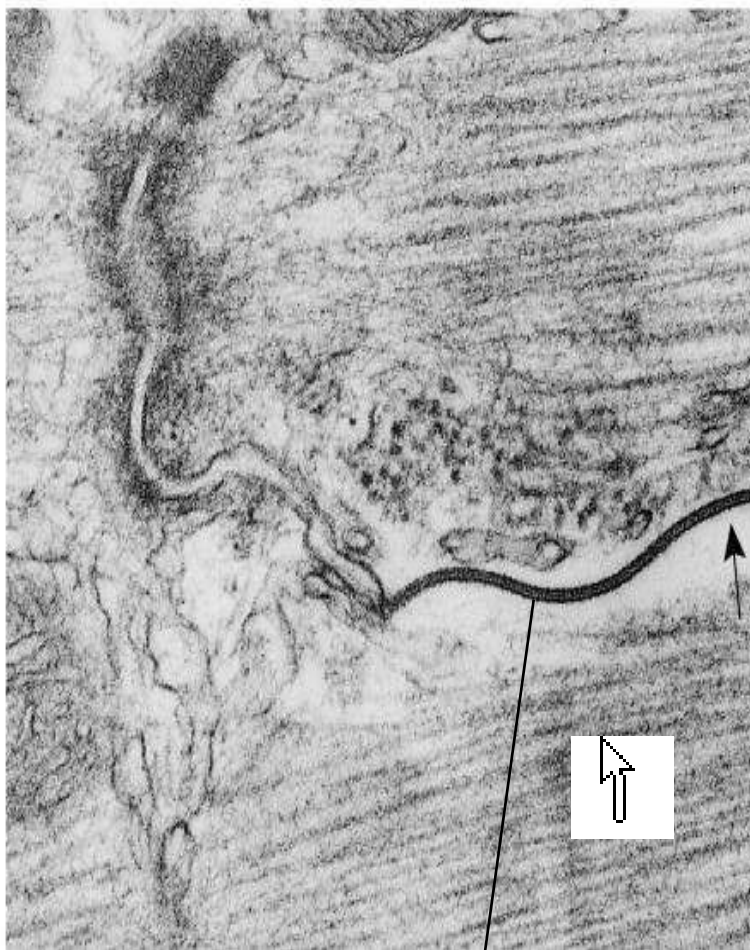


INTERCALATED DISC

- fasciae adherentes (adhesion of cells)
- nexus (quick intercellular communication – transport of ions, electric impulses, information)
- „scalariform“ shape of cell ends



INTERCALATED DISC



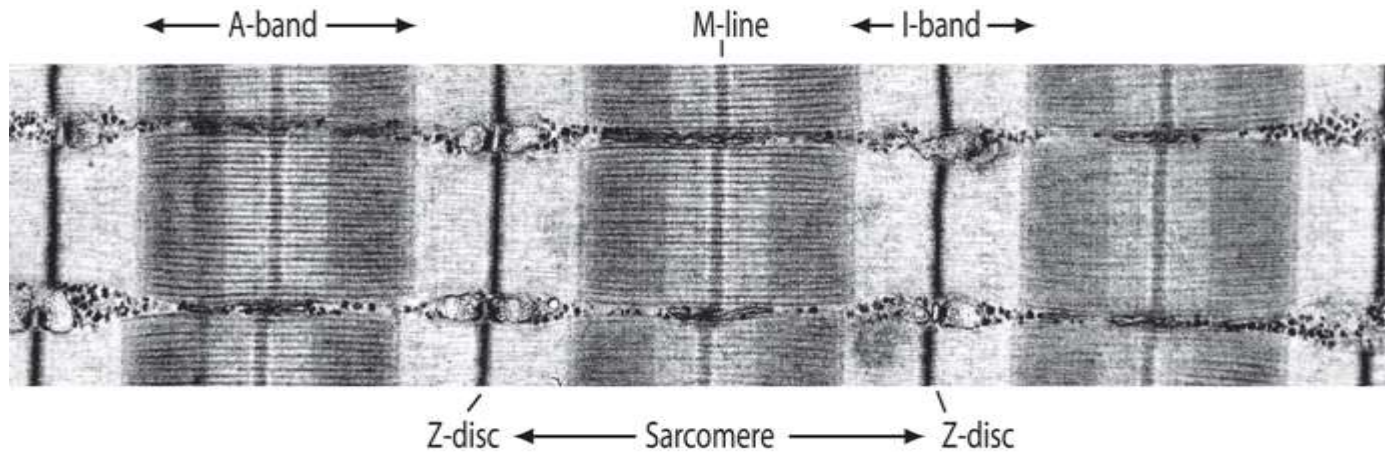
Intercalated disc:

nexus

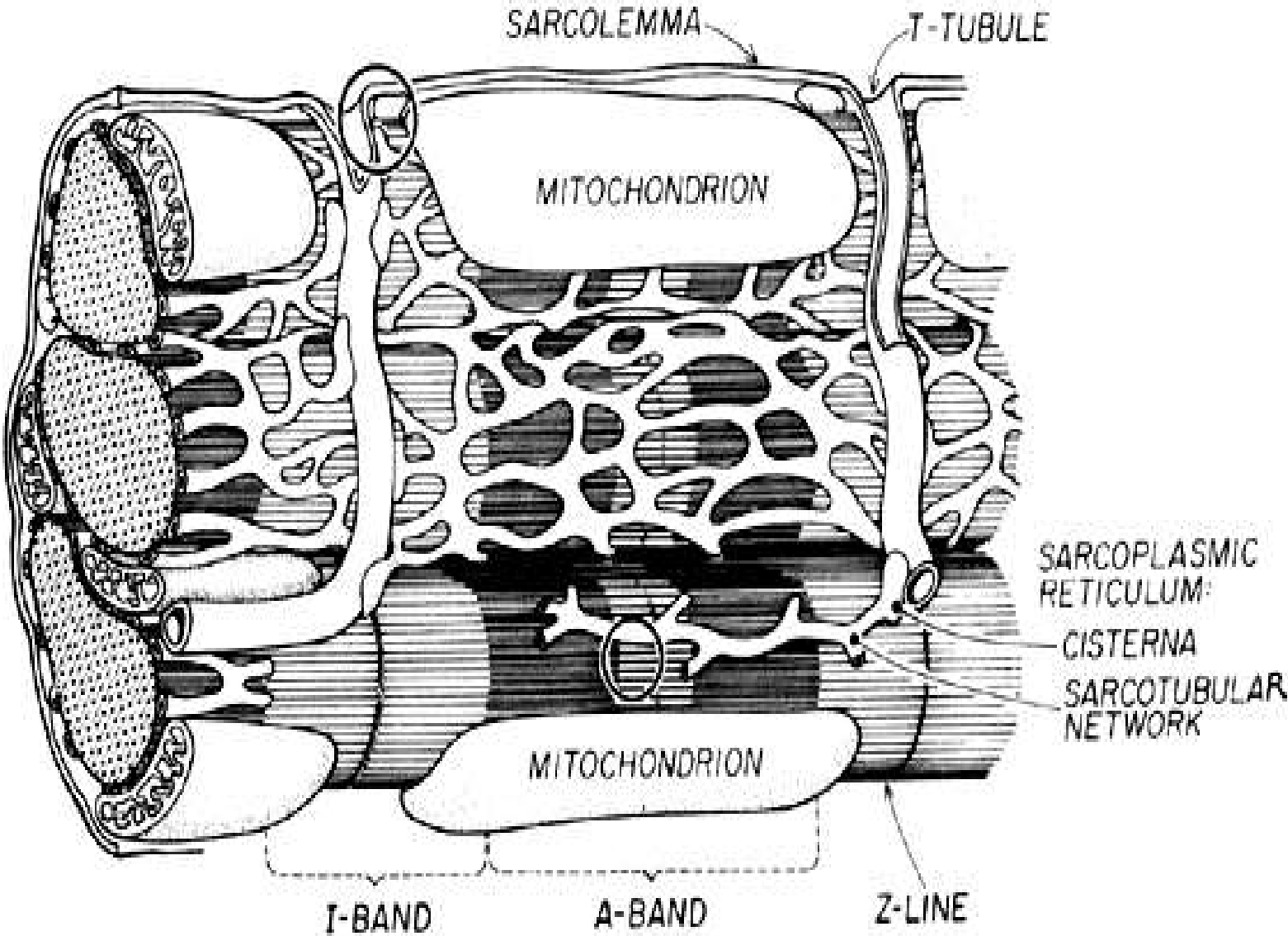
fascia adherens

MYOFIBRILS IN CARDIOMYOCYTE

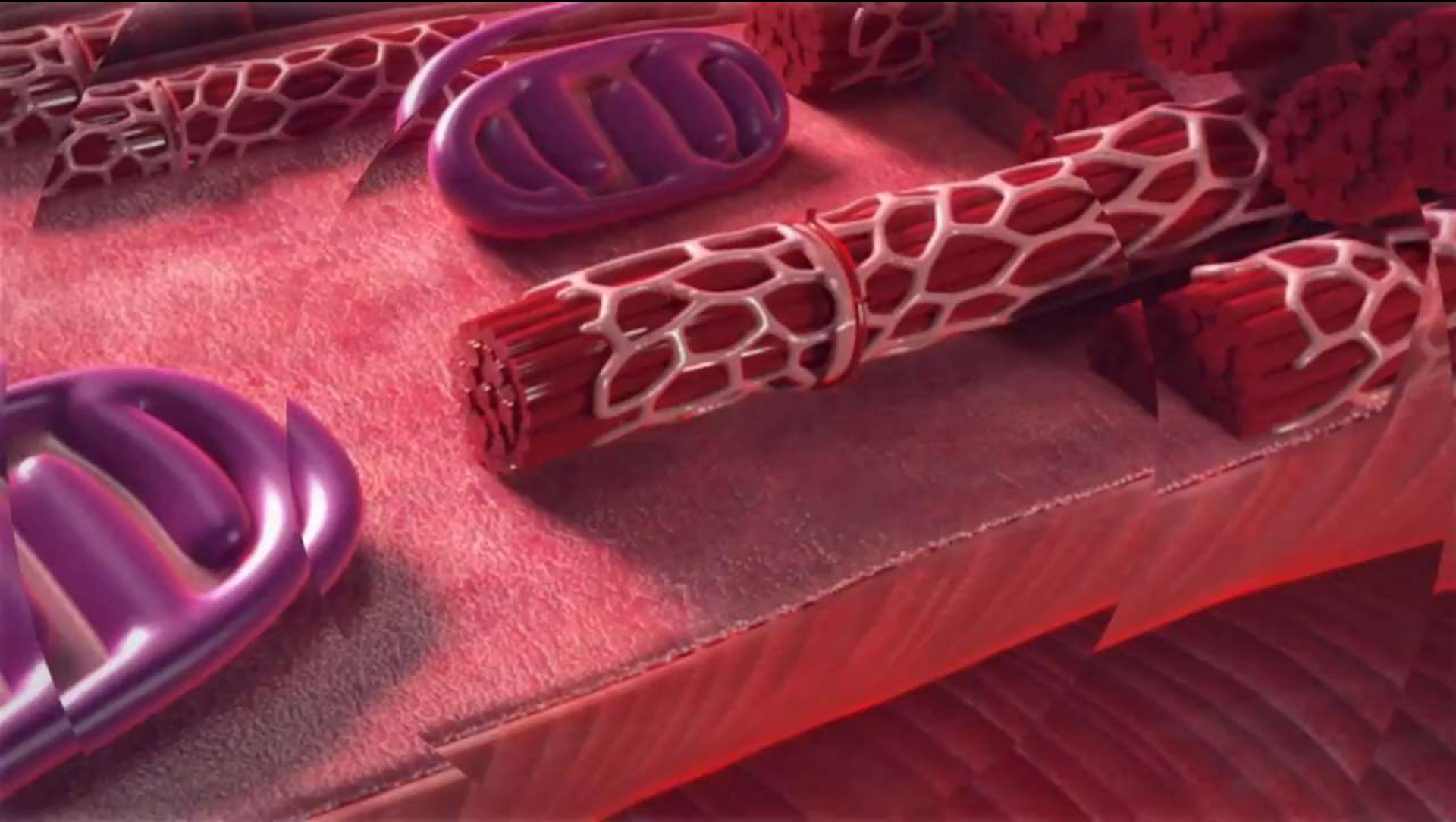
- Actin + myosin myofilaments
- Sarcomere
- Z-line
- M-line and H-zone
- I-band, A-band
- T-tubule + 1 cisterna = diad (around Z-line)



MYOFIBRILS IN CARDIOMYOCYTE

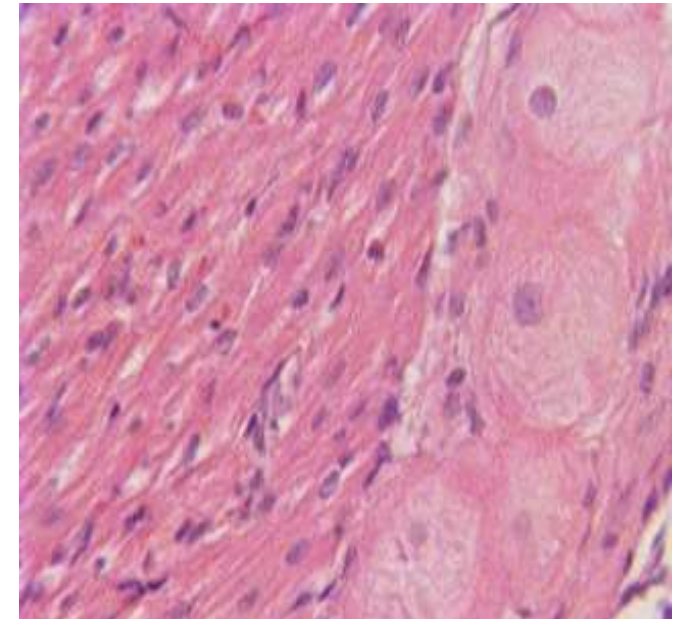
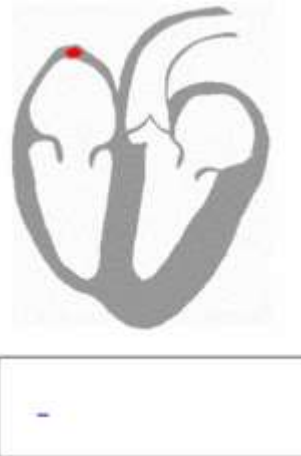
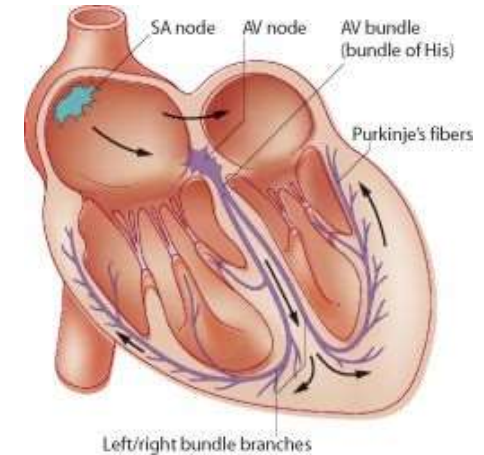


ULTRASTRUCTURE OF CARDIOMYOCYTES



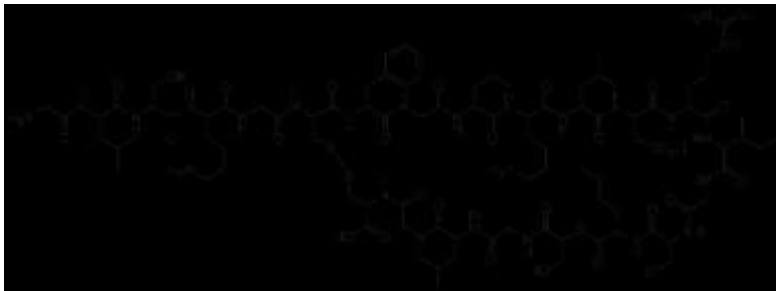
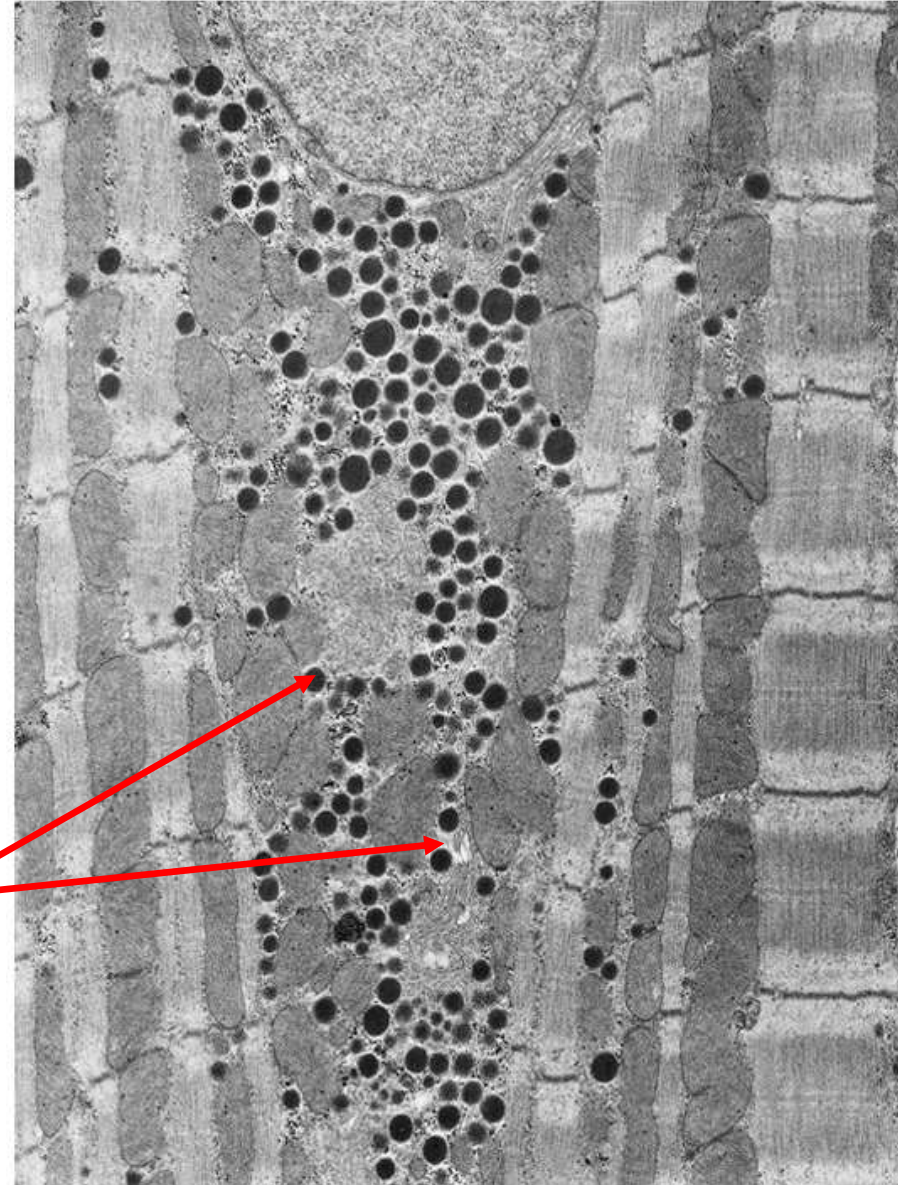
PURKINJE FIBERS

- are located in the inner layer of heart ventricle wall
- are specialized cells fibers that conduct an electrical stimuli or impulses that enables the heart to contract in a coordinated fashion
- numerous sodium ion channels and mitochondria, fewer myofibrils

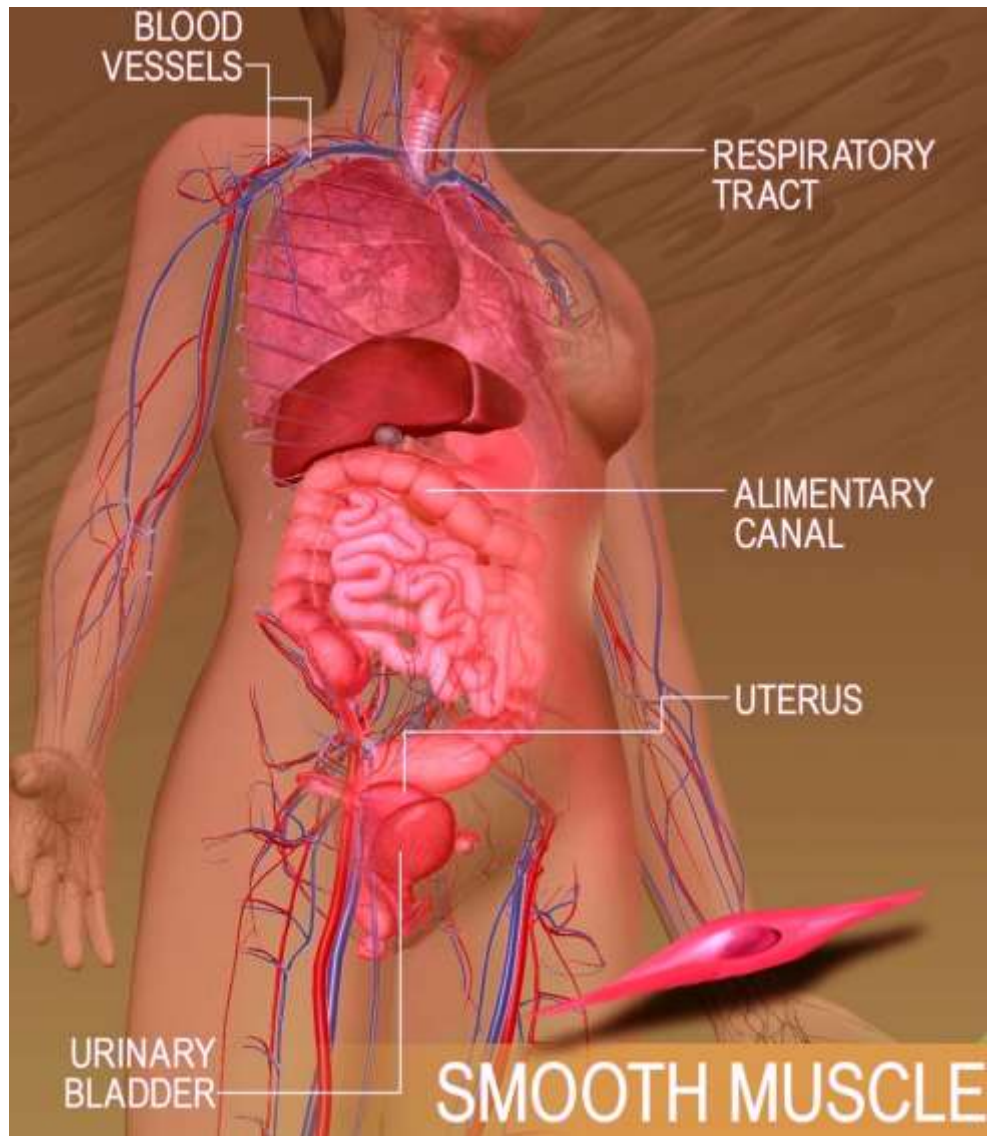


ATRIAL CARDIOMYOCYTES

- **Natriuretic peptide A (ANP)**
- atrial cardiomyocytes
- vasodilatation, diuresis



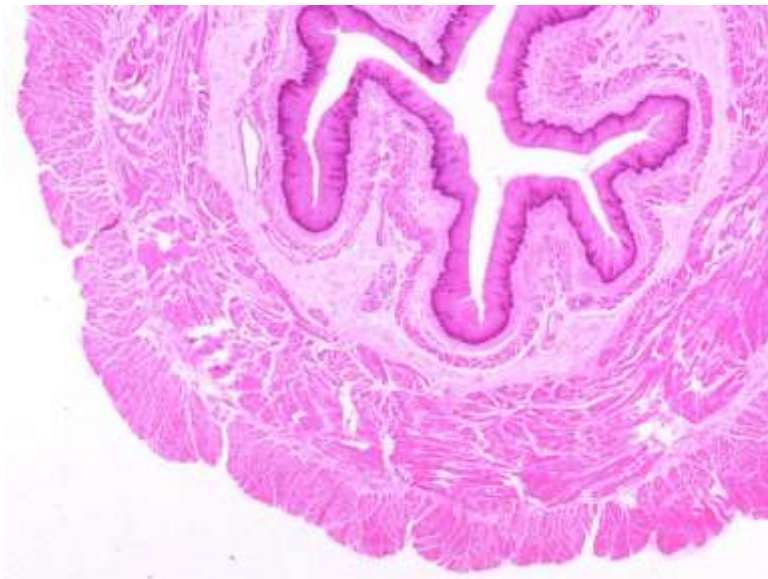
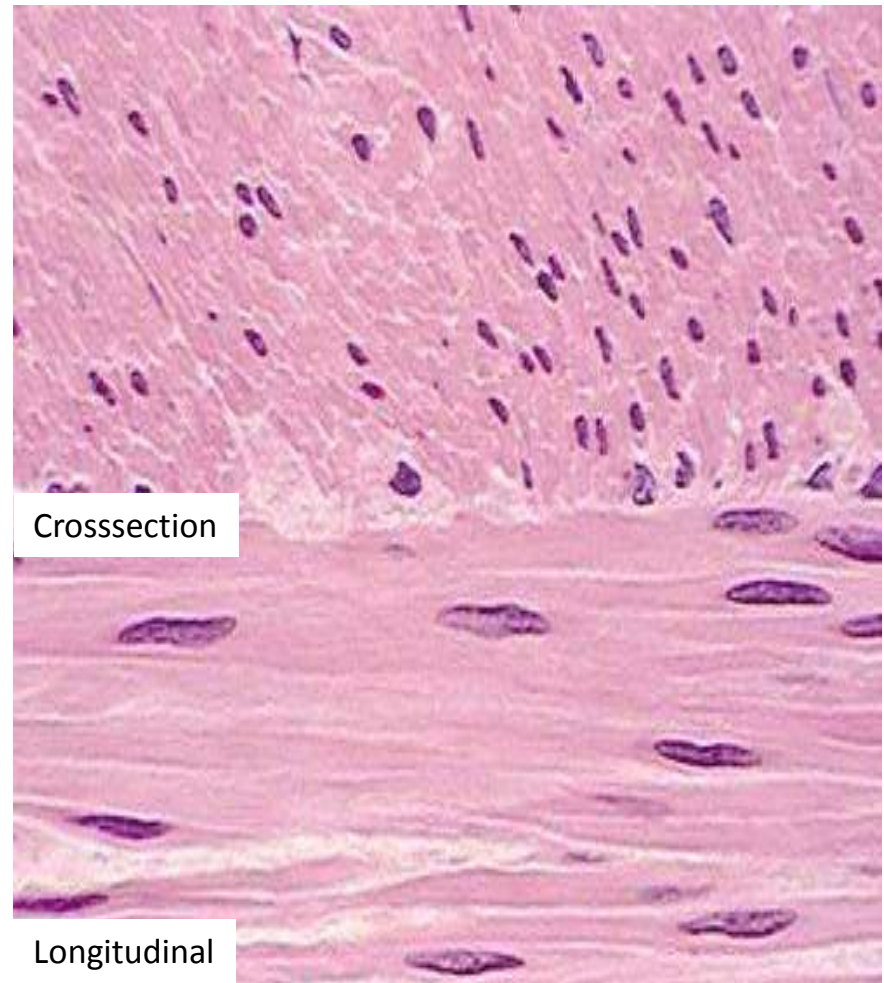
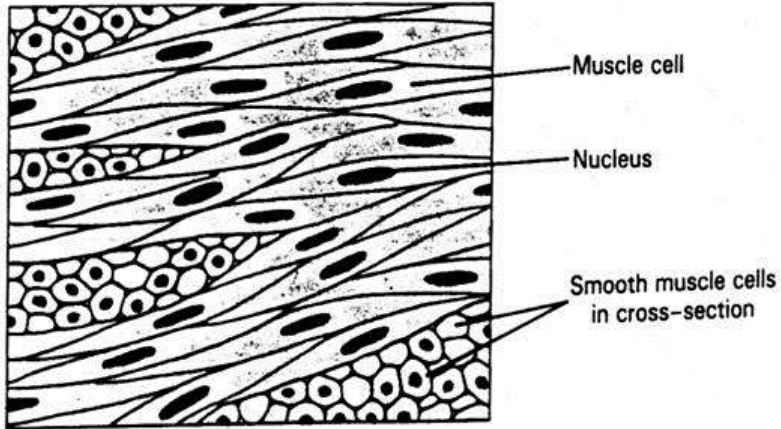
MUSCLE TISSUE



SMOOTH MUSCLE TISSUE

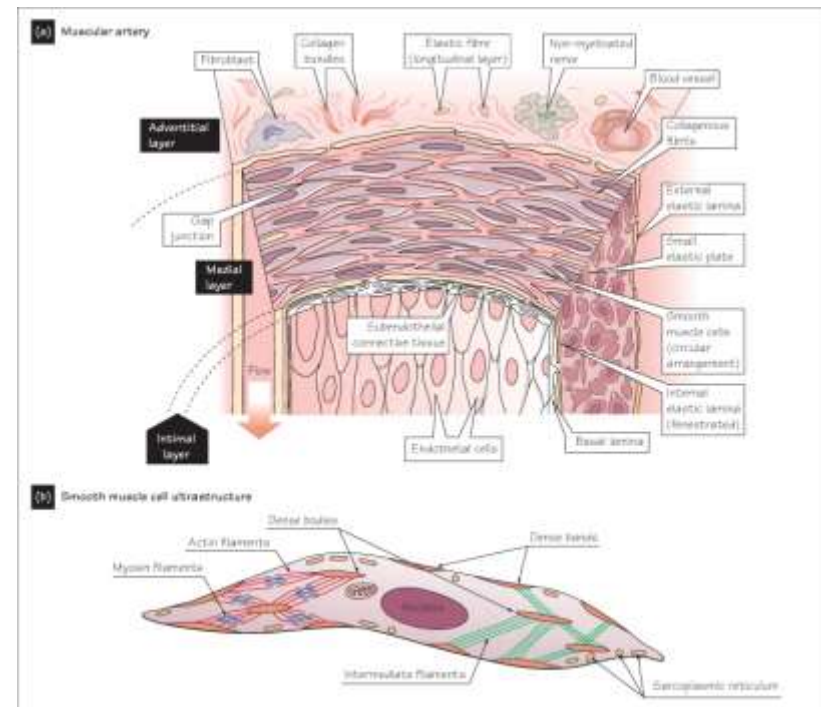
SMOOTH MUSCLE TISSUE

- Cells – **leiomyocytes** - form layers - eg. in walls of hollow organs



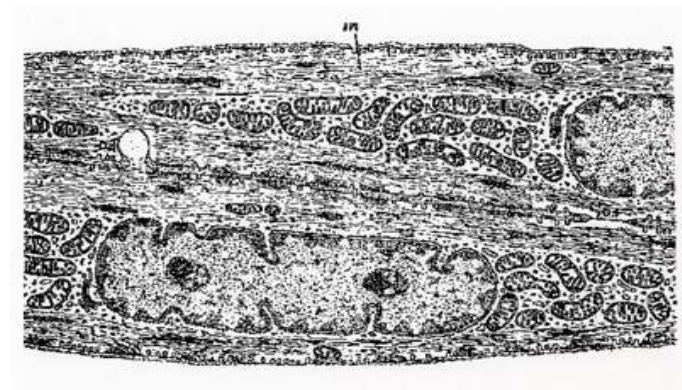
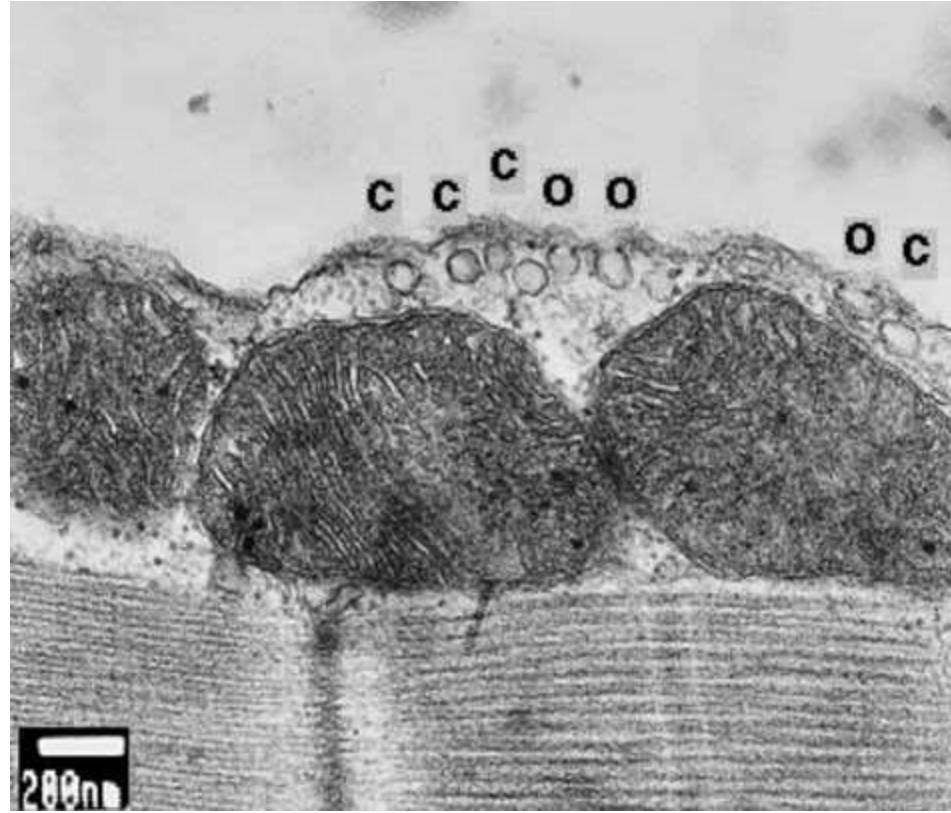
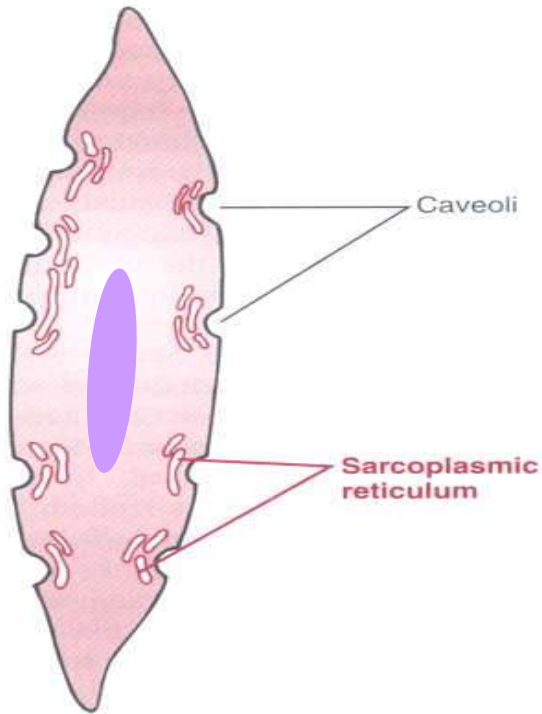
SMOOTH MUSCLE TISSUE

- spindle shaped cells (leiomyocytes) with myofilaments not arranged into myofibrils (no striation), 1 nucleus in the centre of the cell
- myofilaments form bands throughout the cell
- actin filaments attach to the sarcolemma by focal adhesions or to the dense bodies substituting Z-lines in sarcoplasm
- sarcoplasmic reticulum forms only tubules, Ca^{2+} ions are transported to the cell via pinocytotic vesicles
- zonulae occludentes and nexuses connect cells
- calmodulin

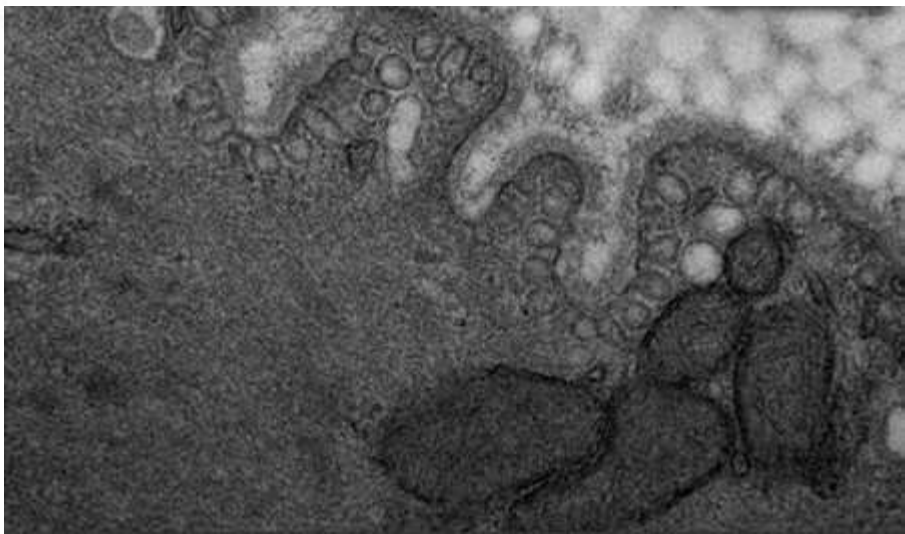
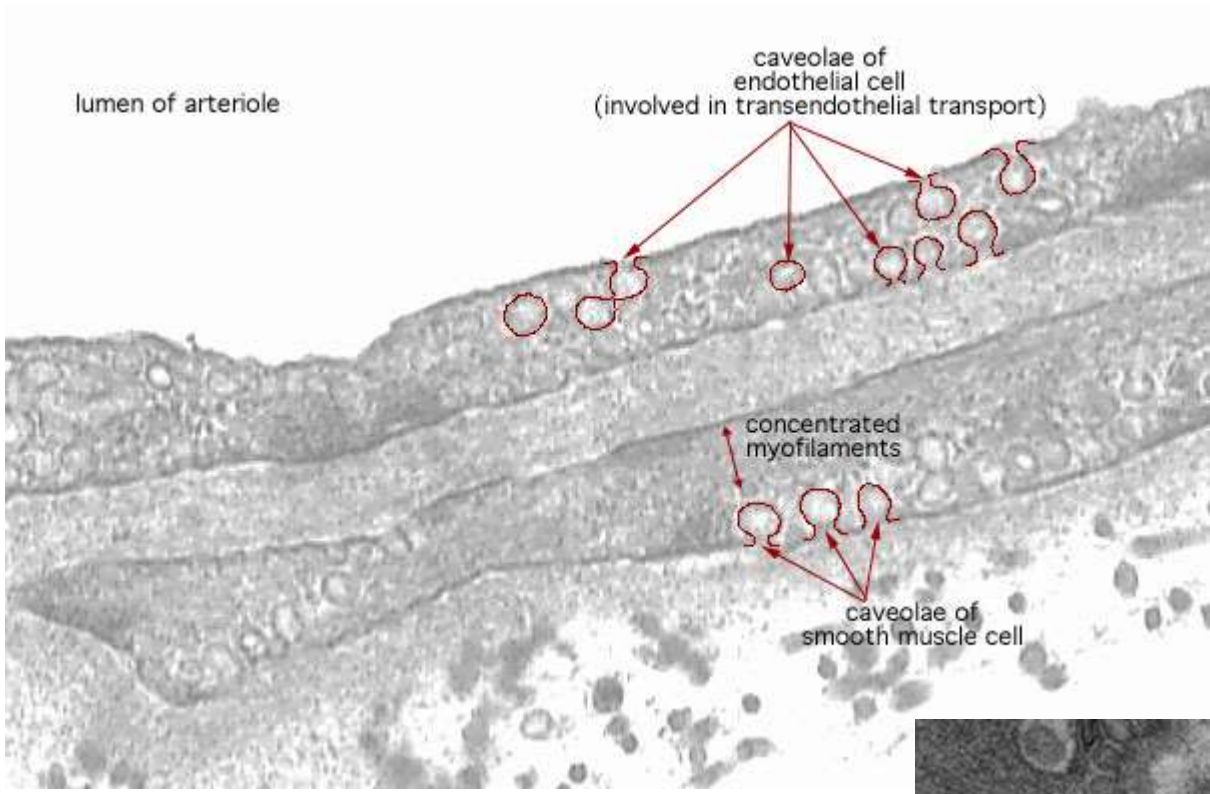


CAVEOLS

- caveolae are equivalent to t-tubules
- transmembrane ion channels



CAVEOLS



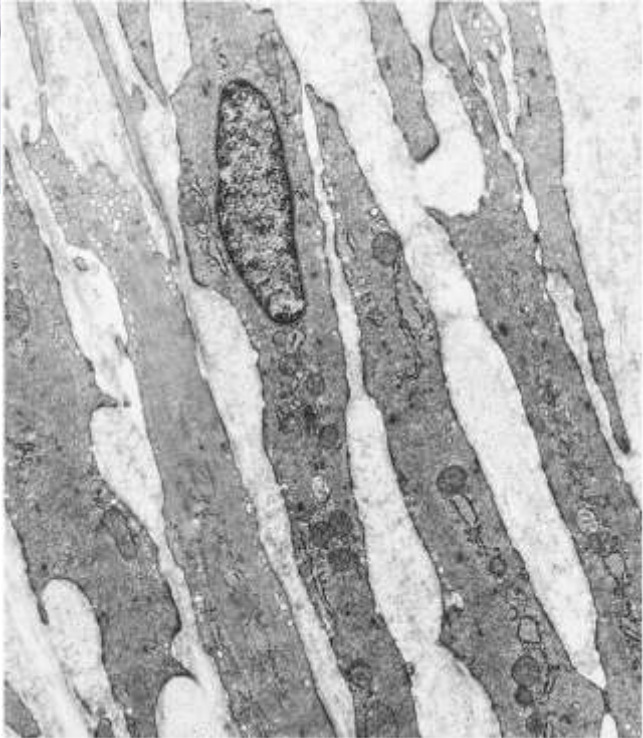
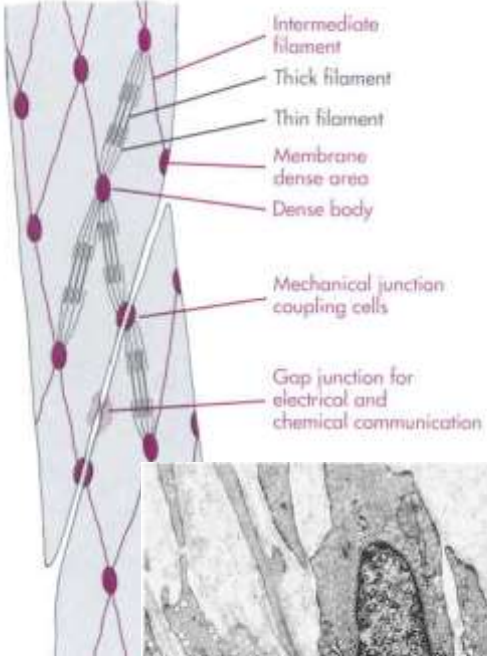
CONTRACTION OF LEIOMYCYTES



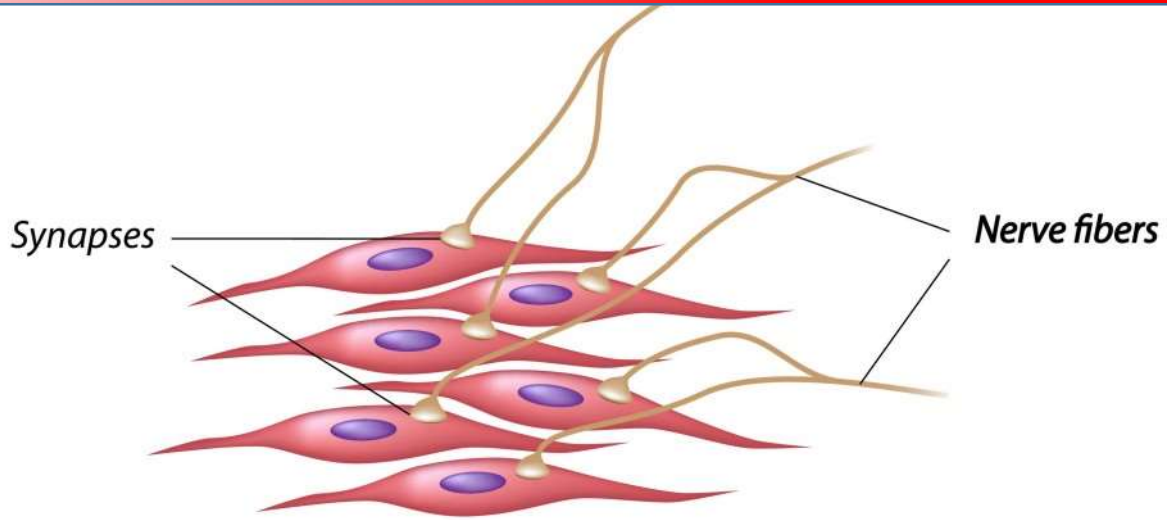
Relaxed smooth muscle cell



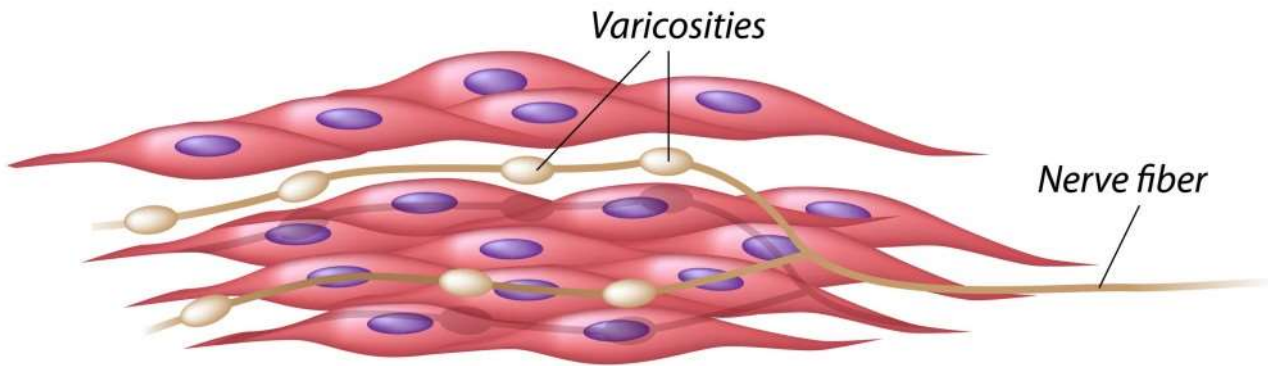
Contracted smooth muscle cell



INNERVATION OF LEIOMYCYTES



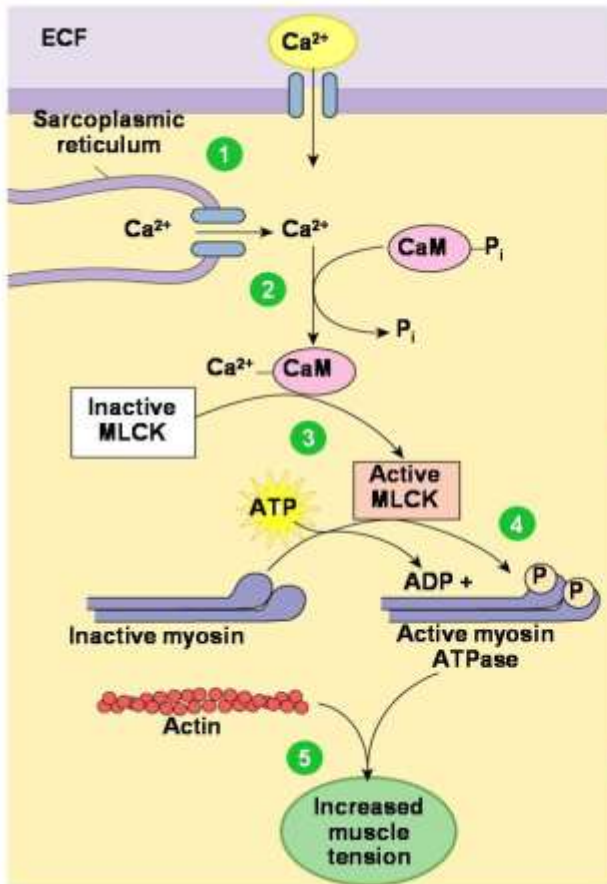
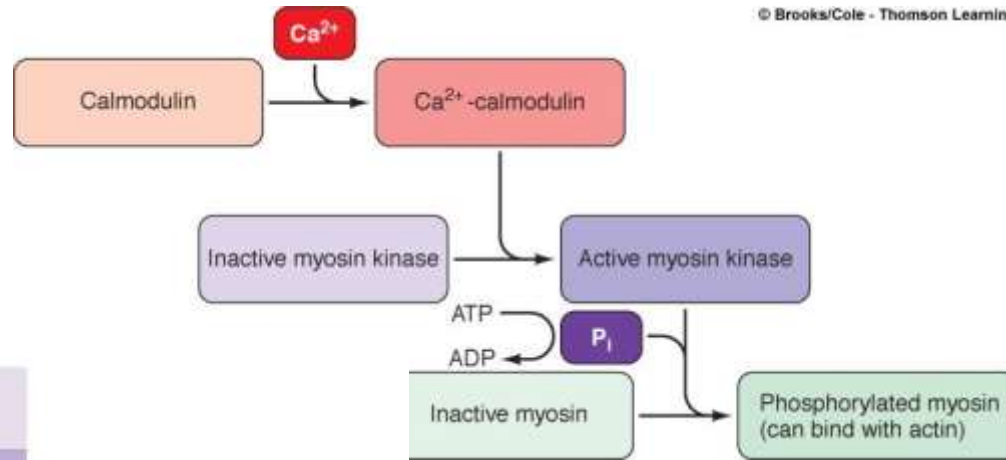
Multiunit Smooth Muscle



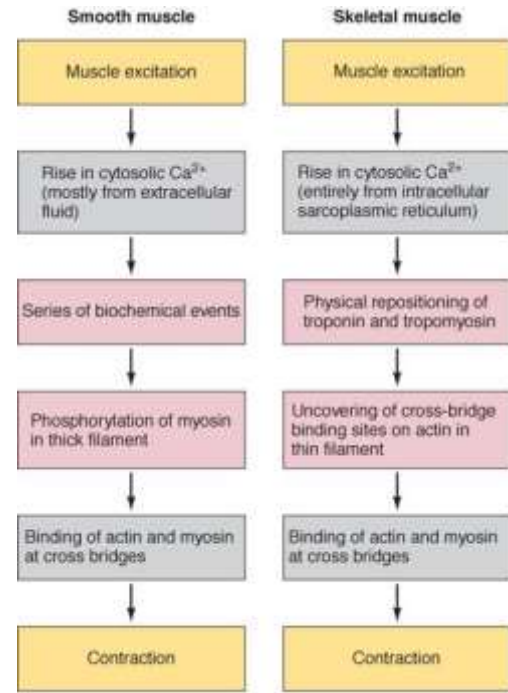
Single-unit Smooth Muscle

CONTRACTION OF LEIOMYCYTES

© Brooks/Cole - Thomson Learning



- 1 Intracellular Ca²⁺ concentrations increase when Ca²⁺ enters cell and is released from sarcoplasmic reticulum.
- 2 Ca²⁺ binds to calmodulin (CaM).
- 3 Ca²⁺-calmodulin activates myosin light chain kinase (MLCK).
- 4 MLCK phosphorylates light chains in myosin heads and increases myosin ATPase activity.
- 5 Active myosin crossbridges slide along actin and create muscle tension.

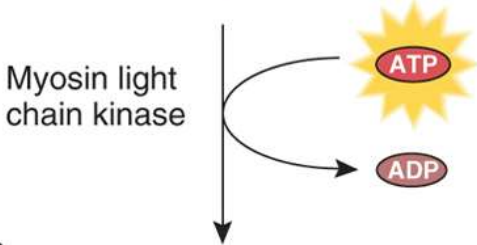
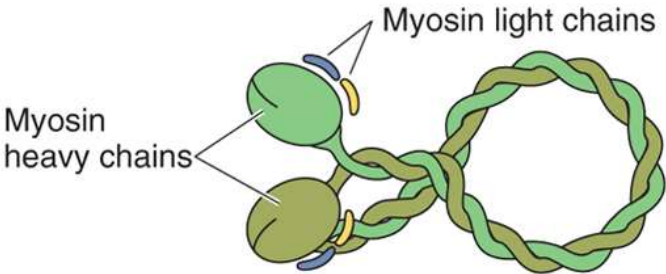


© Brooks/Cole - Thomson Learning

SMOOTH MUSCLE TISSUE

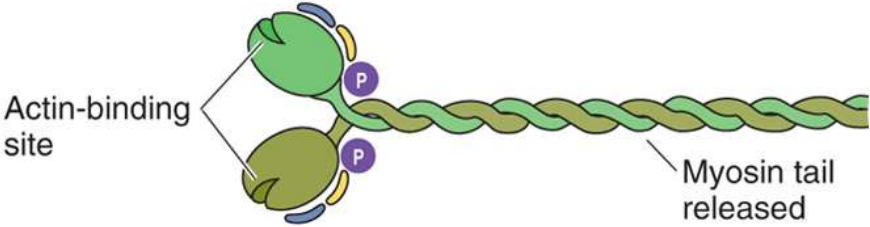
Inactive state

(light chains not phosphorylated)



Active state

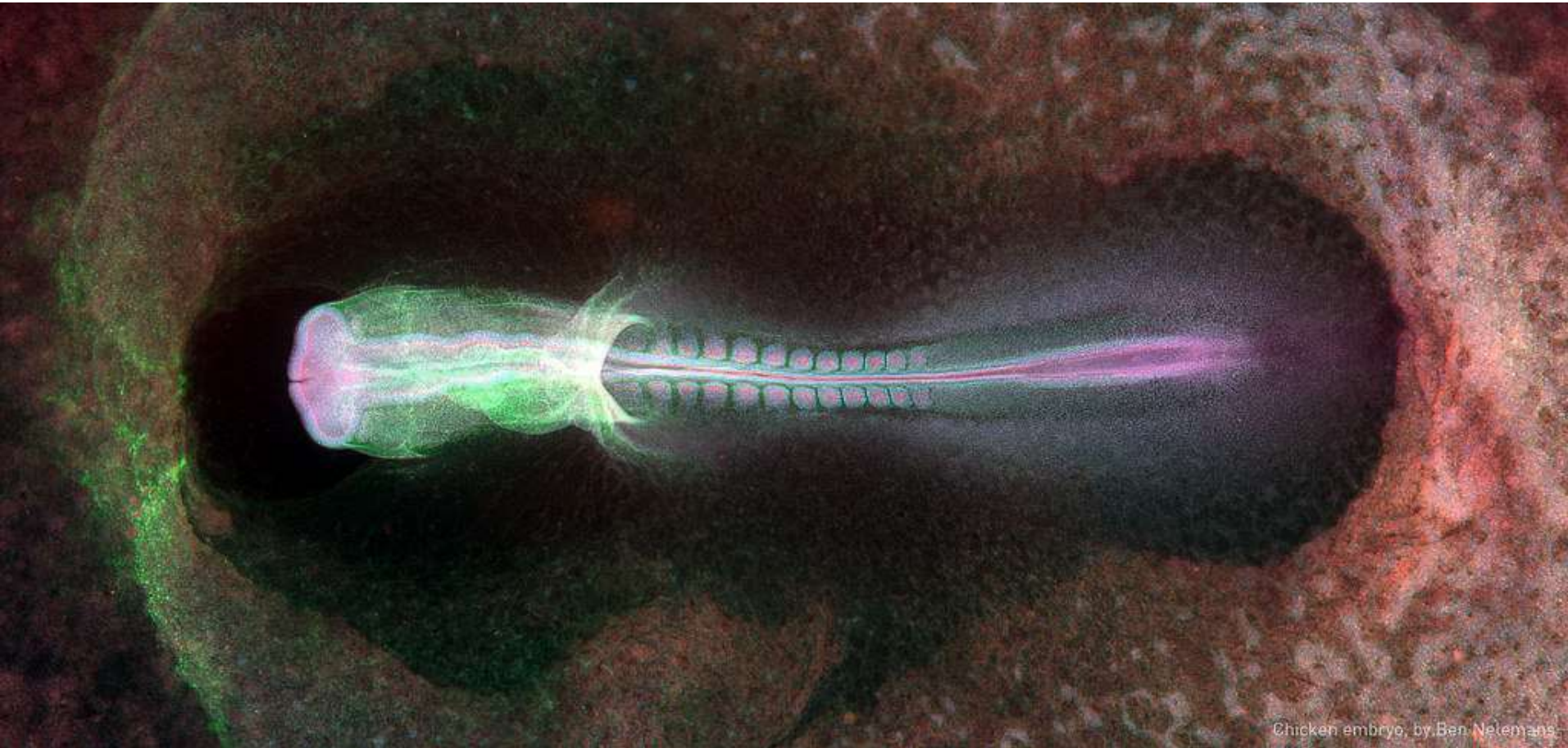
(light chains phosphorylated)



SUMMARY

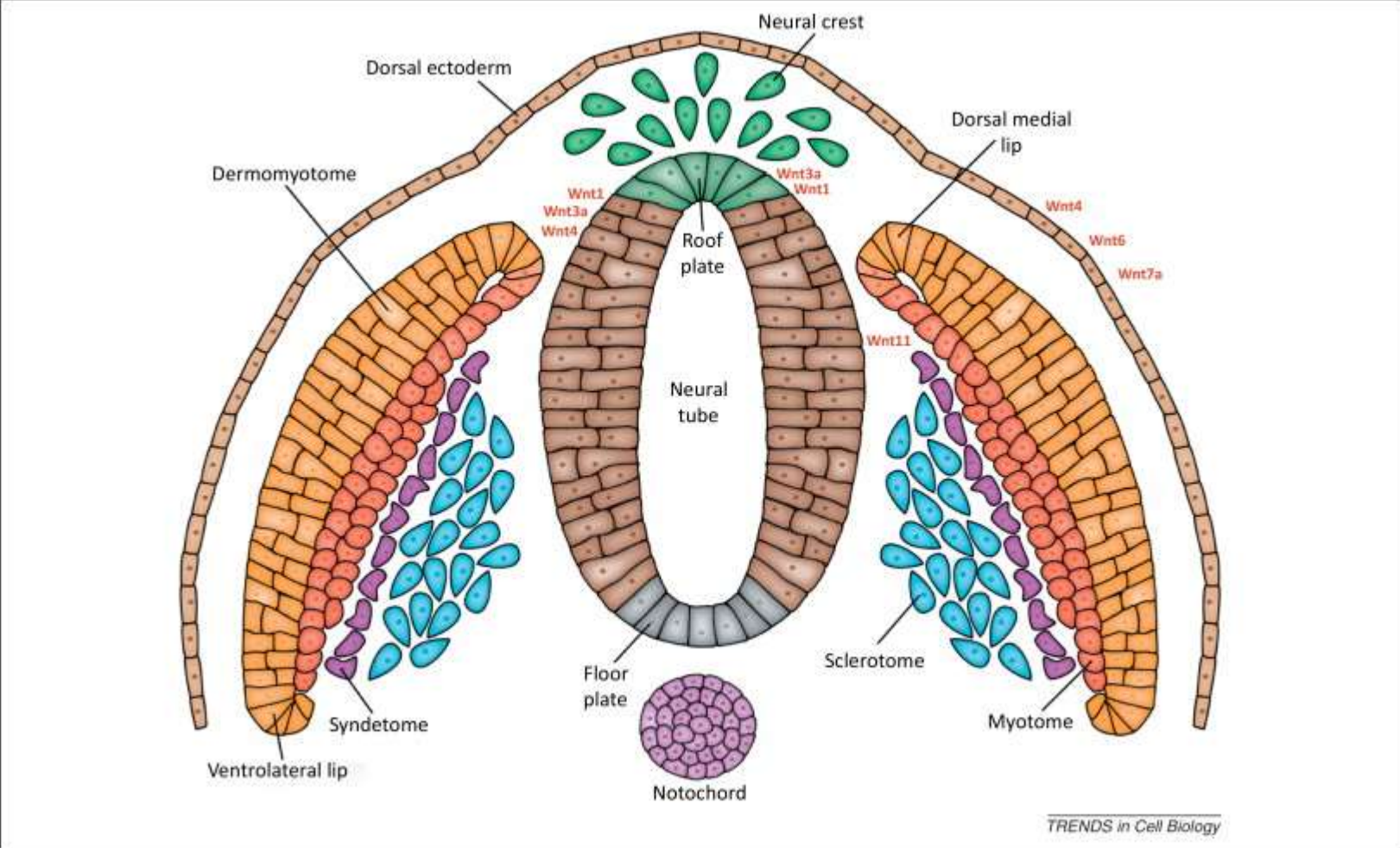
Hallmark	Skeletal muscle	Cardiac muscle	Smooth muscle
Cells	Thick, long, cylindrical, non-branched	Branched, cylindrical	Small, spindle-shaped
Nuclei	Abundant, peripherally	1-2, centrally	1, centrally
Filaments ratio (thin:thick)	6:1	6:1	12:1
sER and myofibrils	Regular sER around myofibrils	Less regular sER, myofibrils less apparent	Less regular sER, myofibrils not developed
T tubules	Between A-I band, triads	Z lines, diads	Not developed
Motor end plate	Present	Not present	Not present
Motor regulation	Voluntary control	No voluntary control	No voluntary control
Other	Bundles, c.t.	Intercalated discs	Caveoli, overlapping cells

EMBRYONIC DEVELOPMENT OF MUSCLE SYSTEM

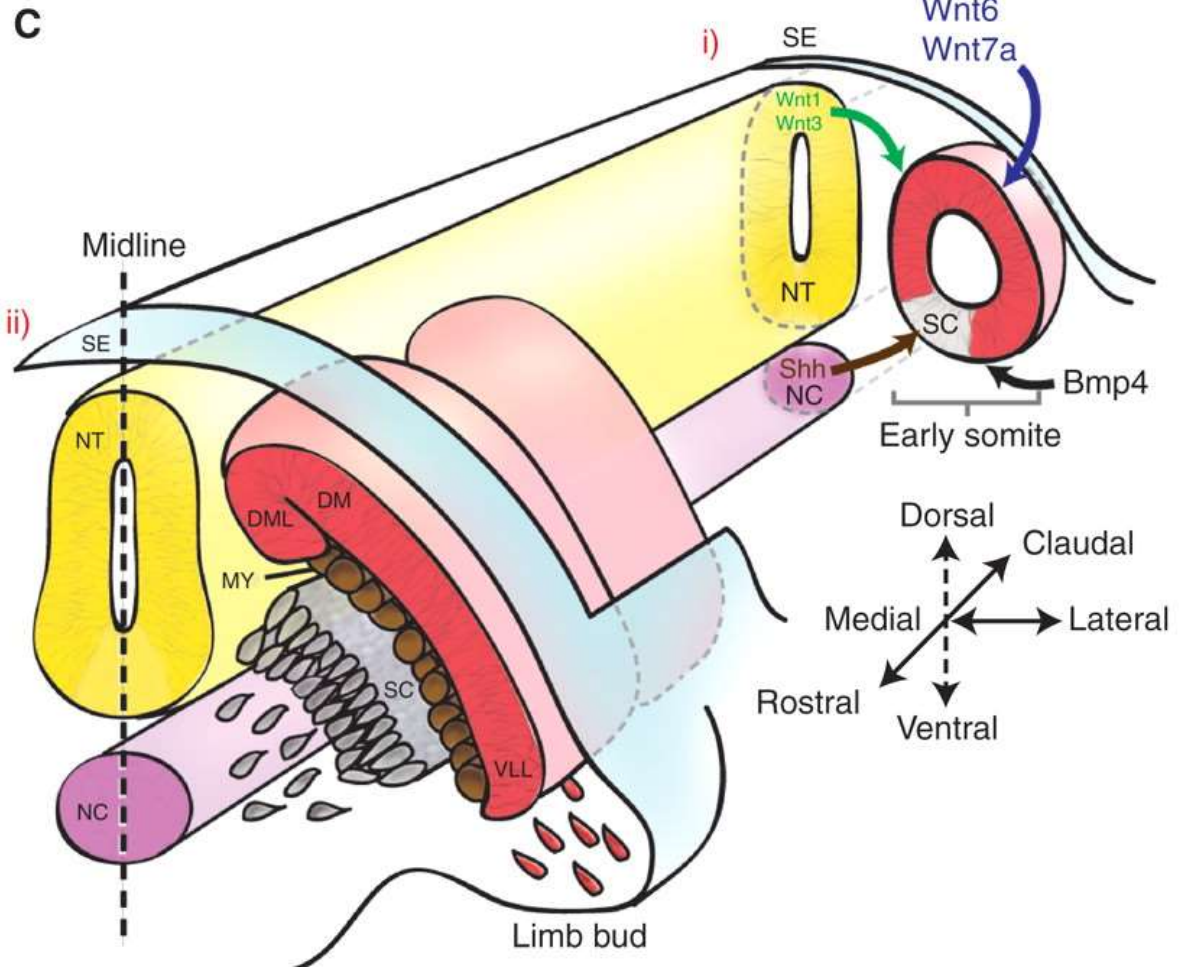
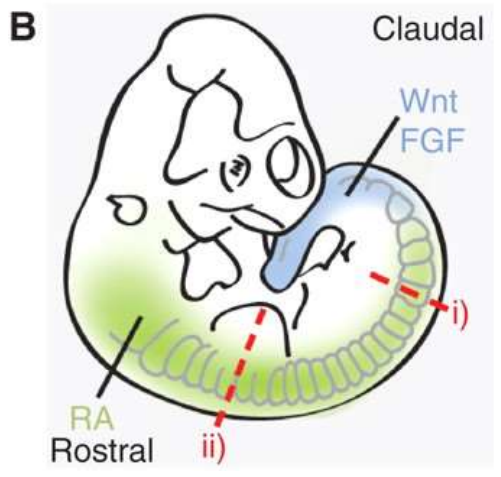
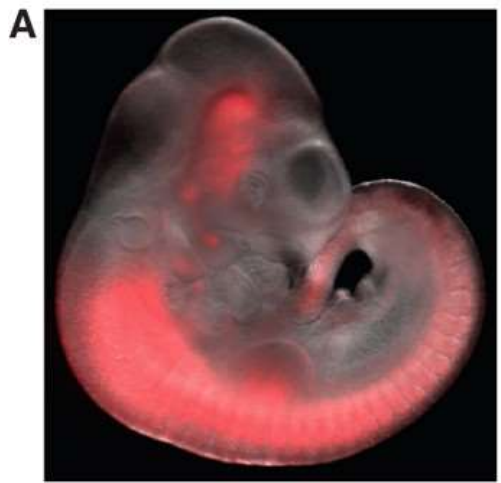


Chicken embryo, by Ben Nellemans

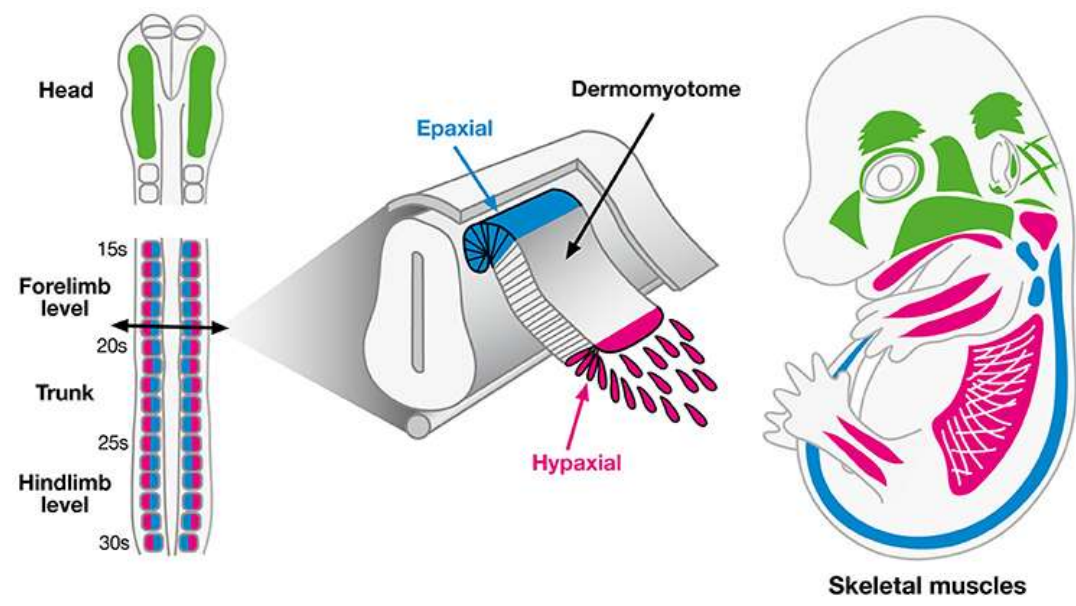
EMBRYONIC DEVELOPMENT OF MUSCLE SYSTEM



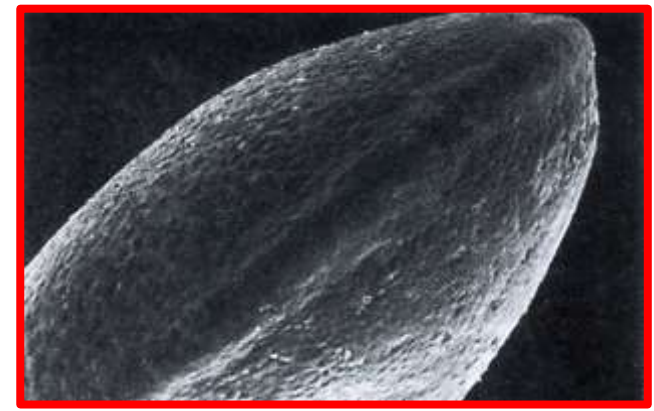
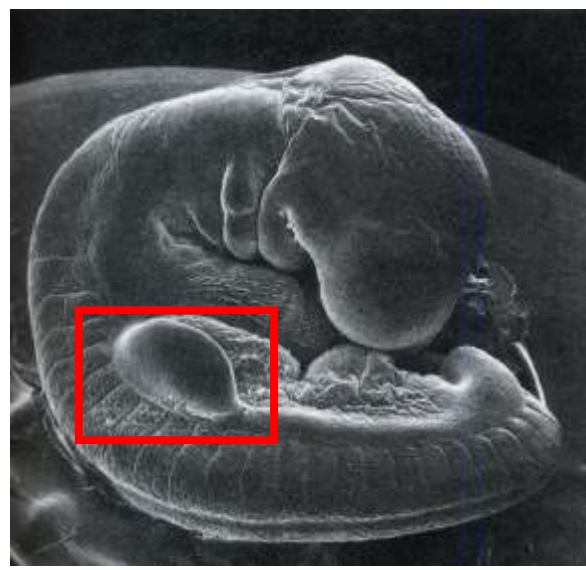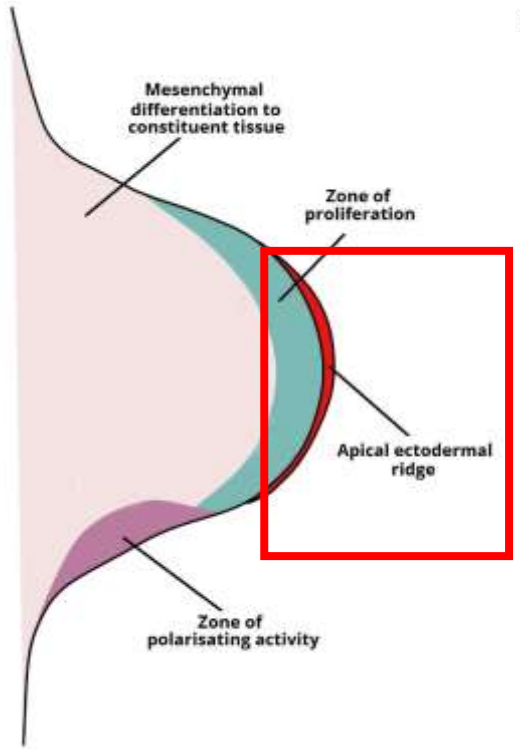
EMBRYONIC DEVELOPMENT OF MUSCLE TISSUE



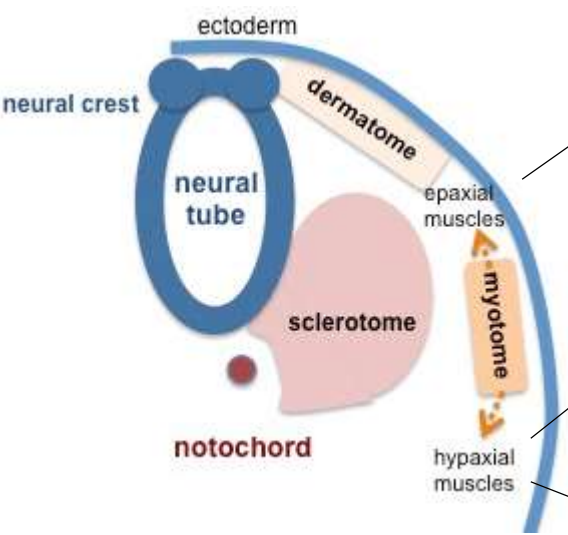
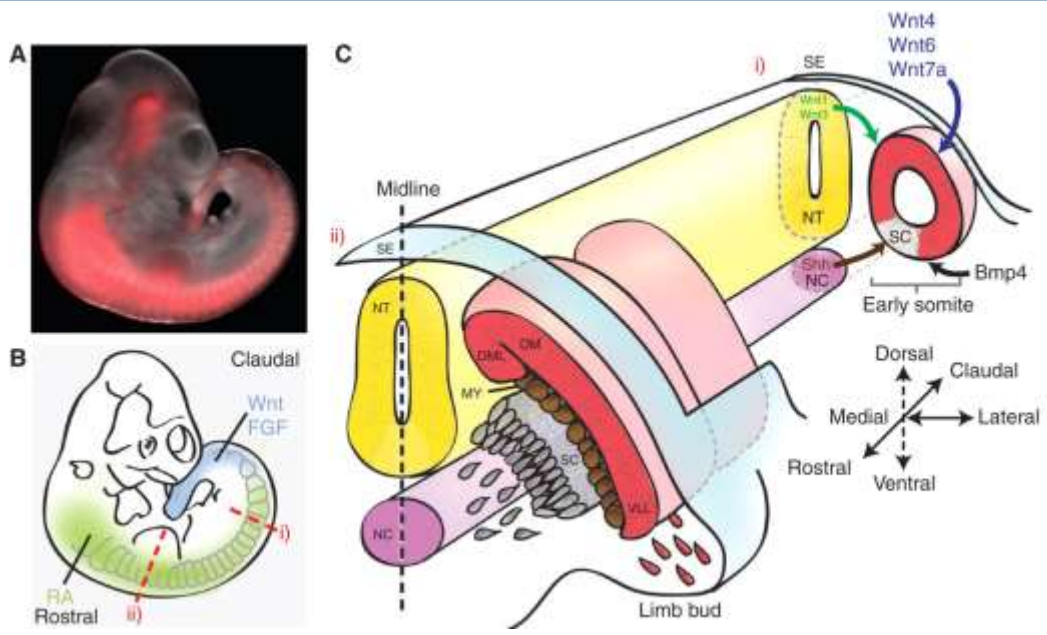
LIMB MUSCLES



Skeletal muscles



TRUNK MUSCLES



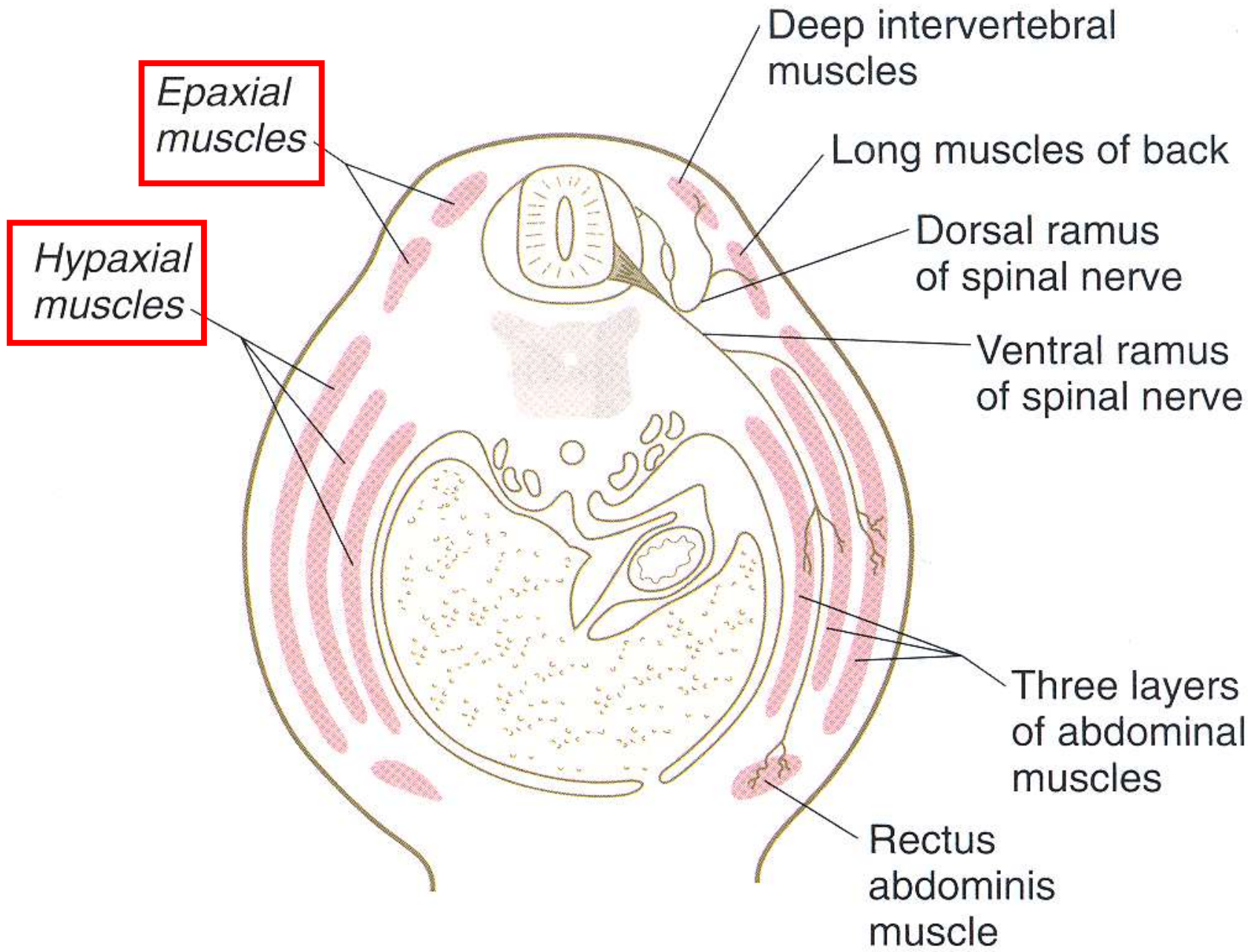
Hluboké zádové svaly

Spinokostální svaly

Povrchové vrstvy zádových svalů –
končetinový původ

Mezižební svaly

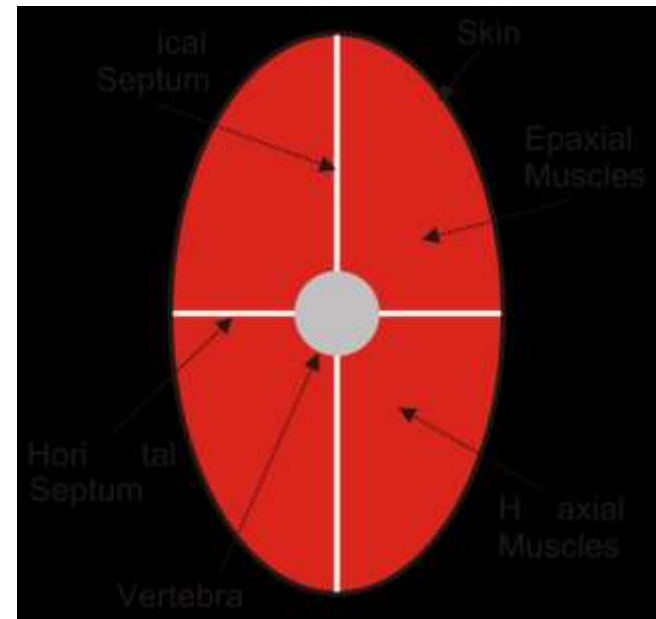
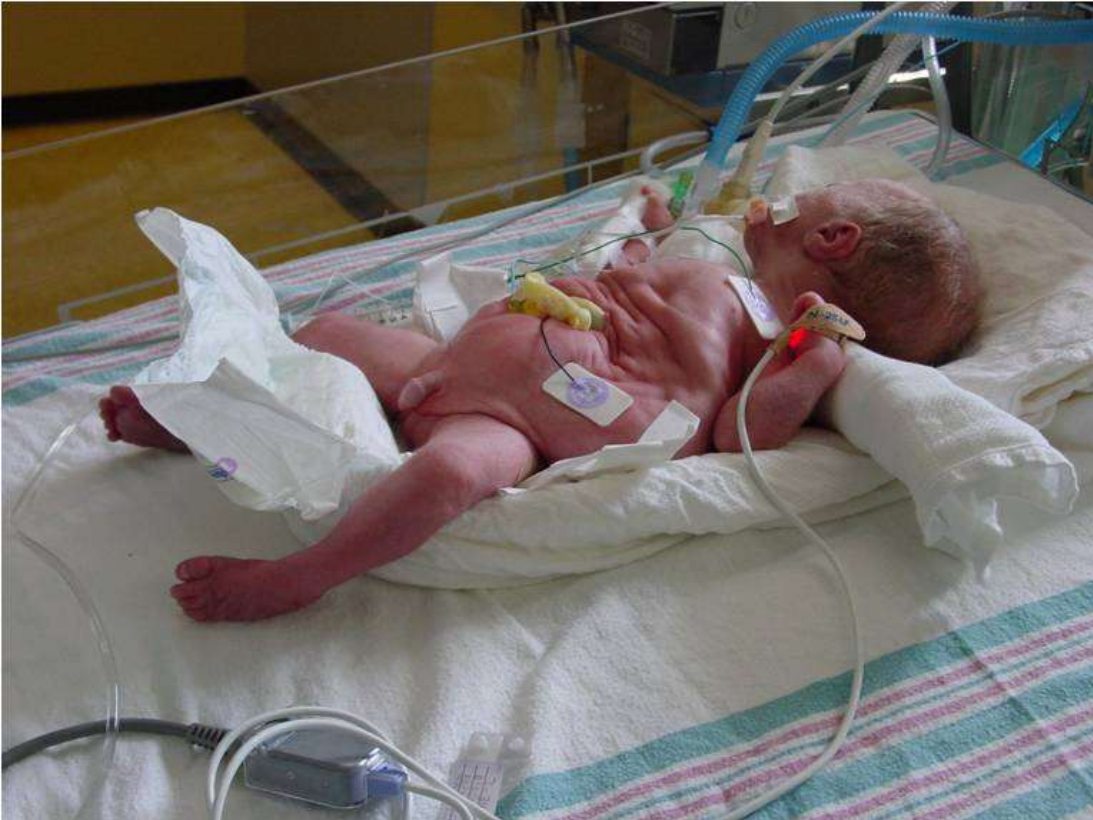TRUNK MUSCLES



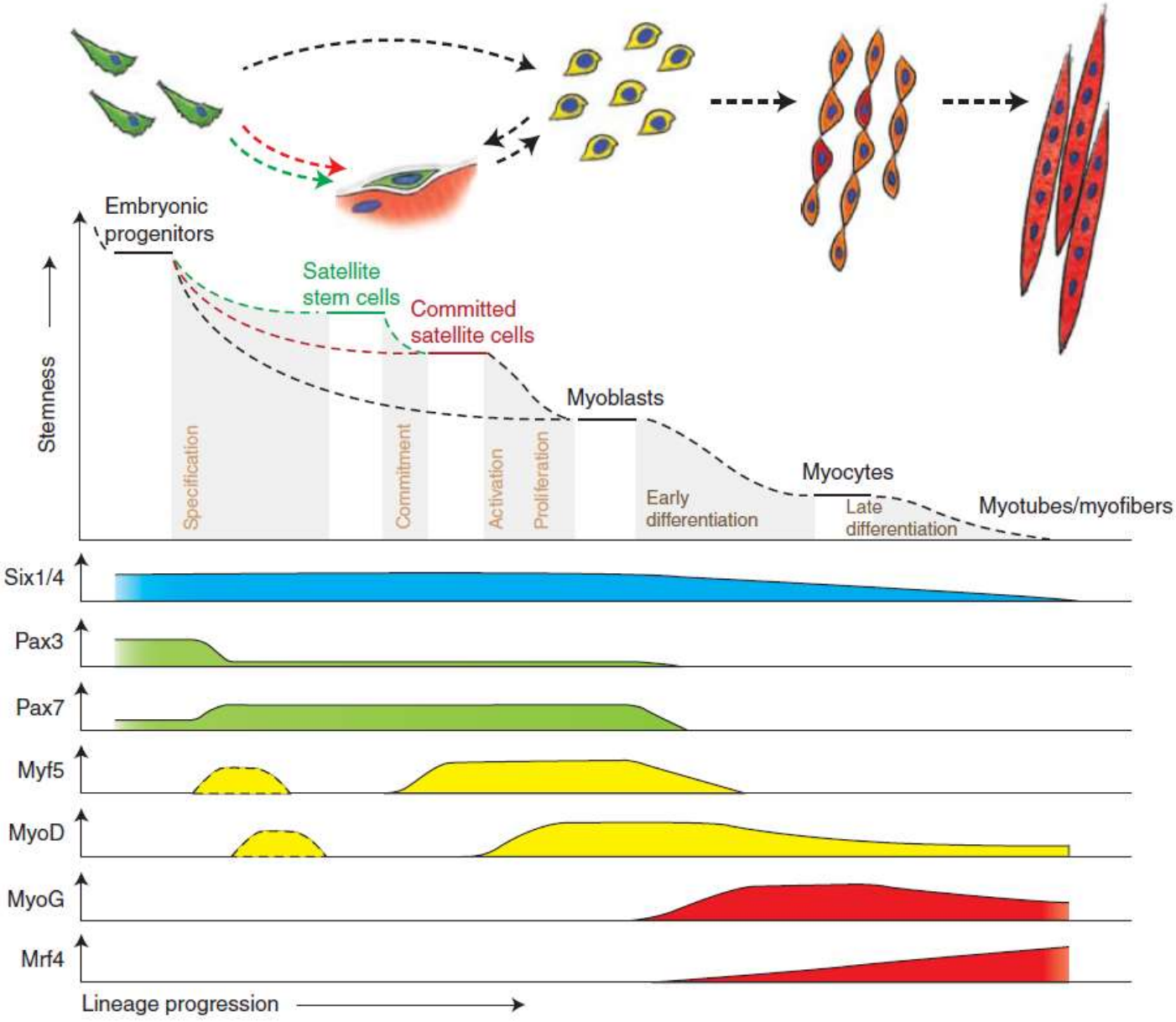
PRUNE BELLY SYNDROME

- Absence of abdominal muscles
- Failure of hypaxial specification
- VACTERL and aneuploidy association

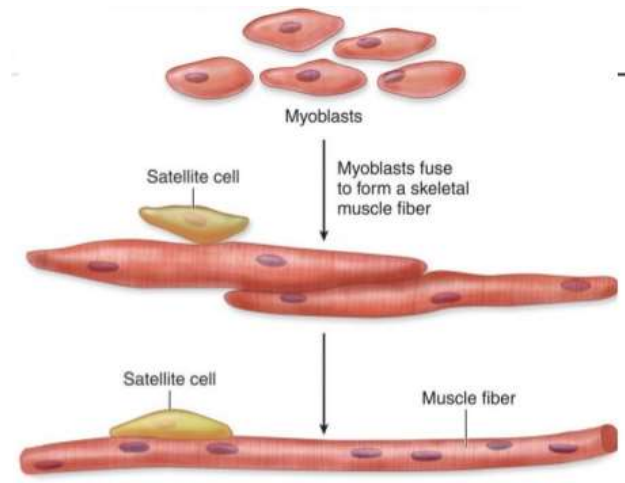
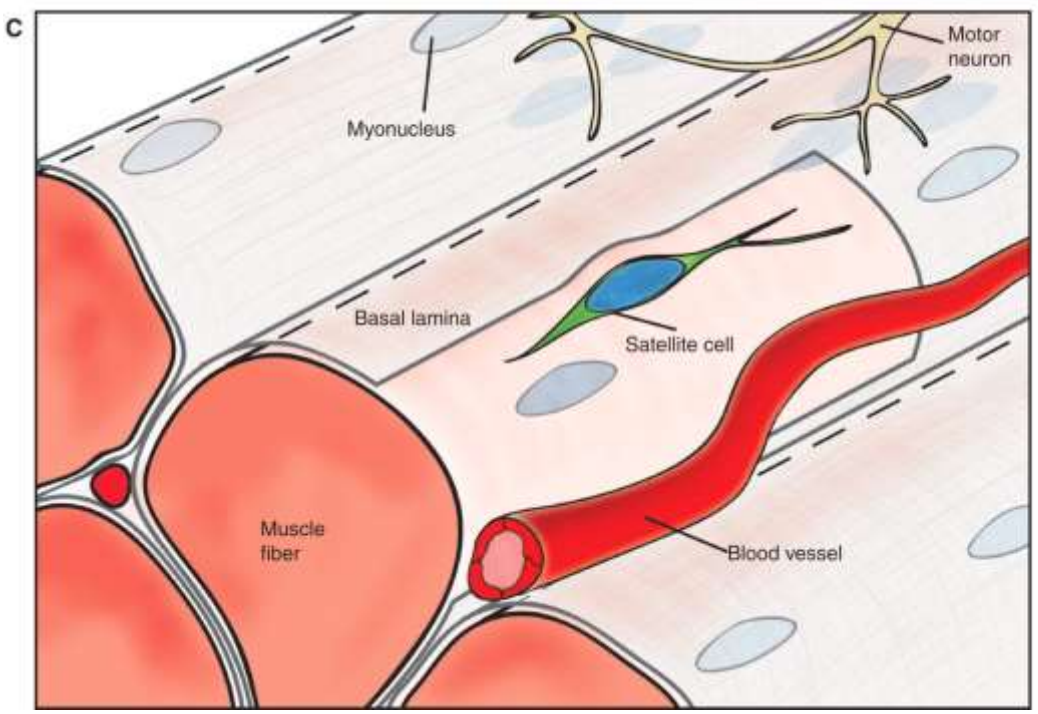
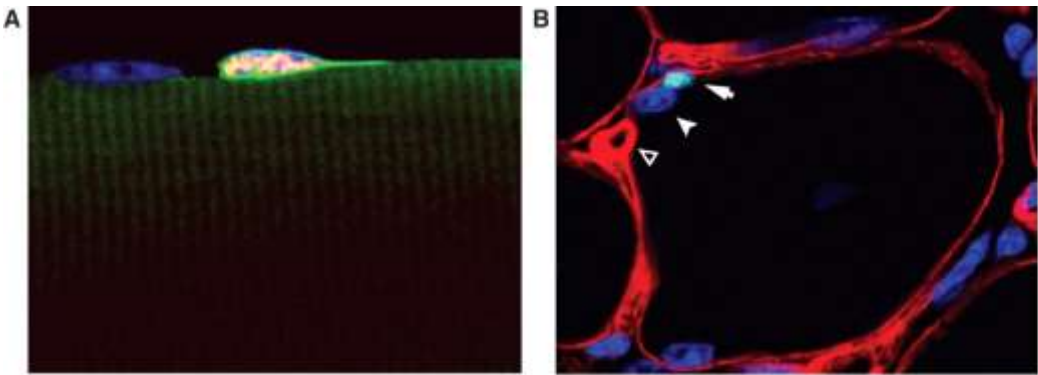
- V - Vertebral anomalies
- A - Anorectal malformations
- C - Cardiovascular anomalies
- T - Tracheoesophageal fistula
- E - Esophageal atresia
- R - Renal (Kidney) and/or radial anomalies
- L - Limb defects



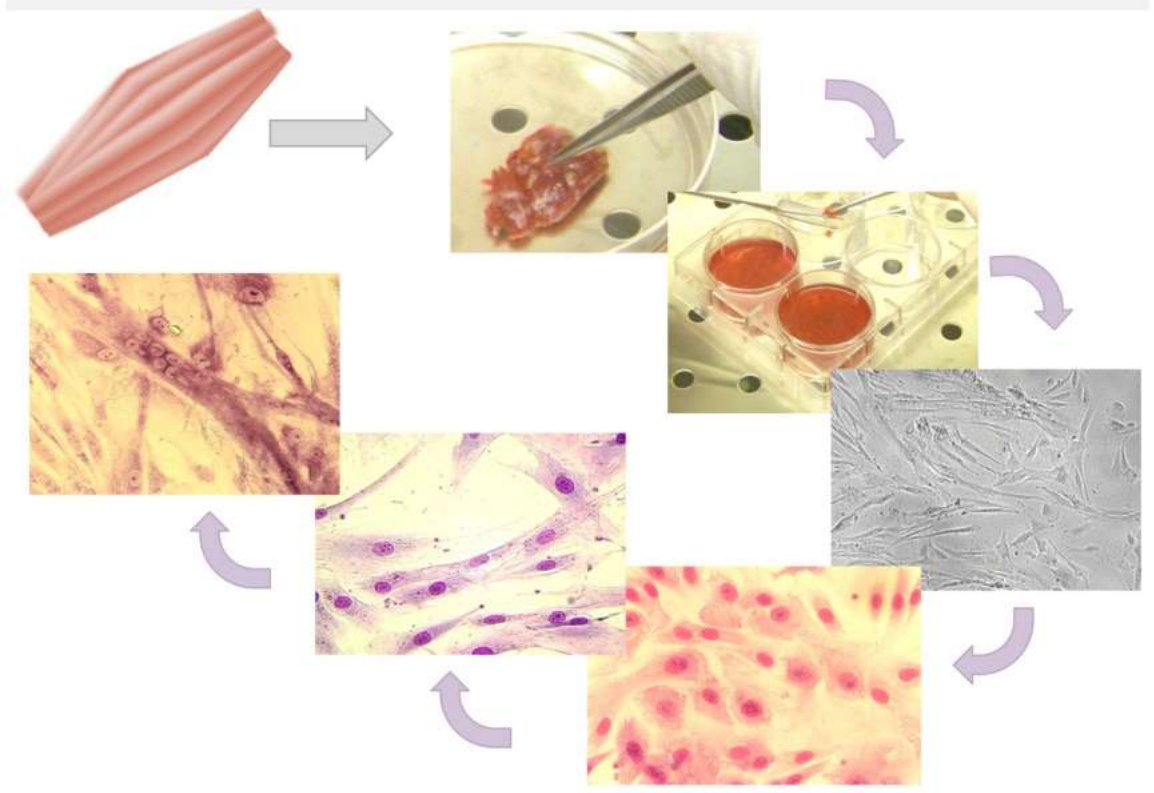
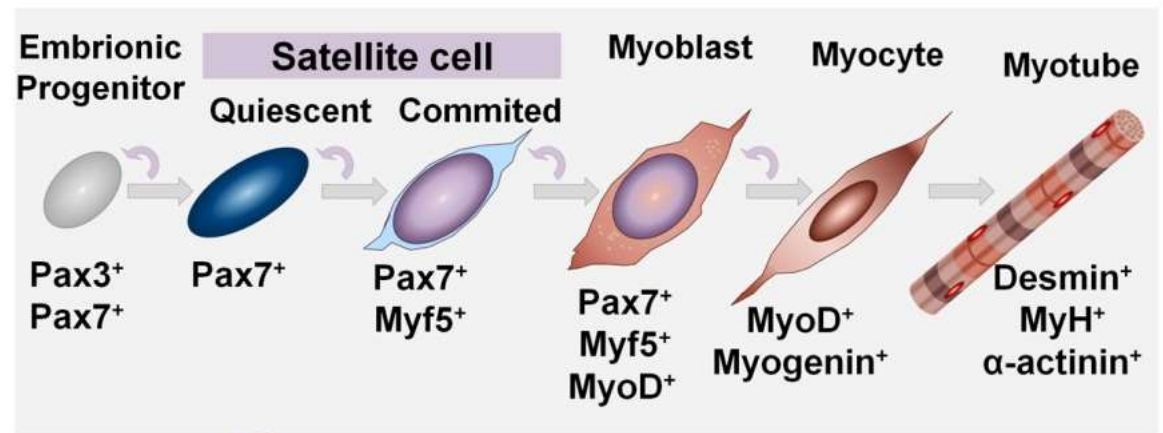
EMBRYONIC DEVELOPMENT OF SKELETAL MUSCLE TISSUE



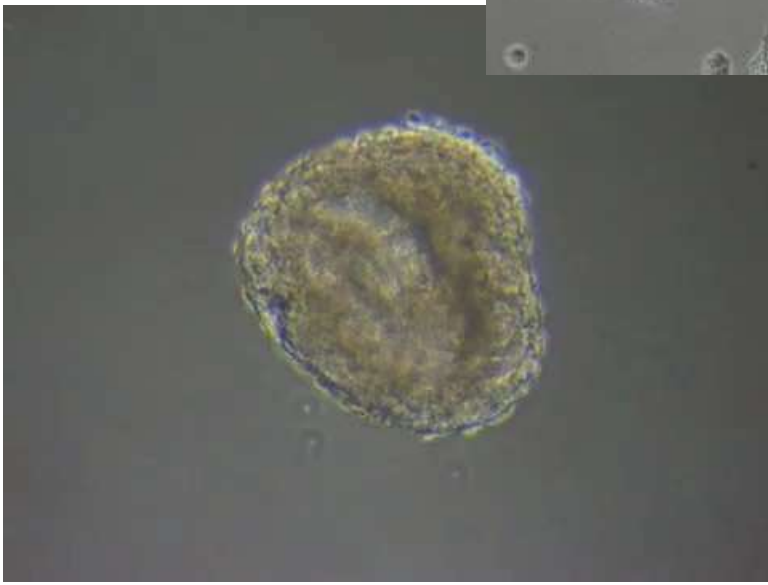
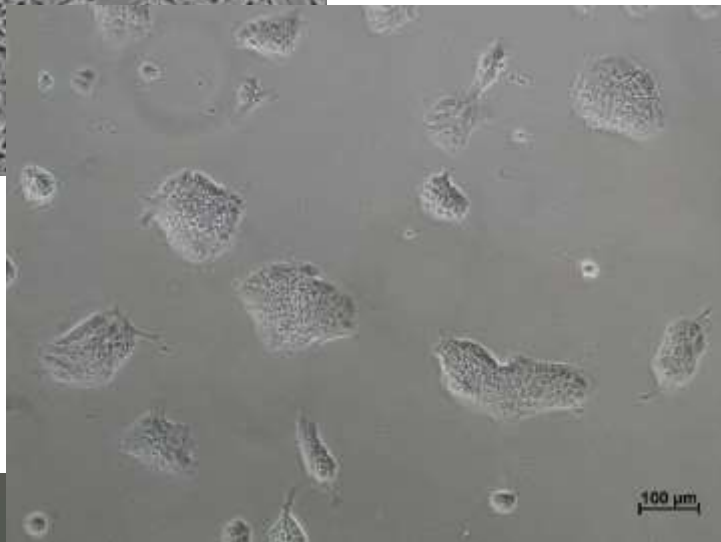
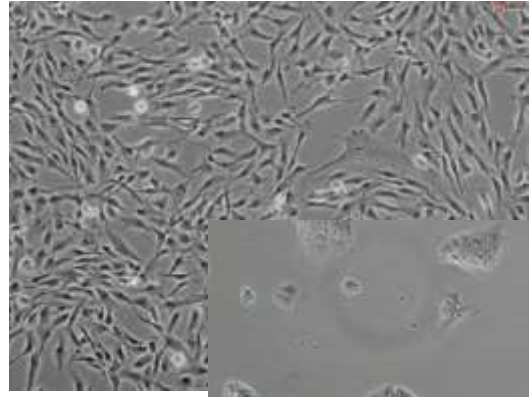
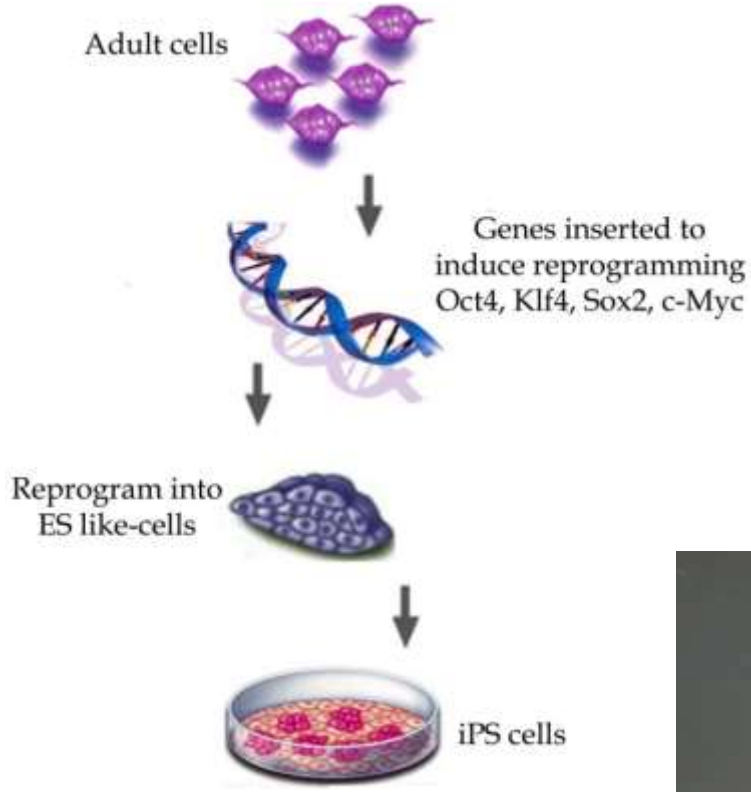
REGENERATION



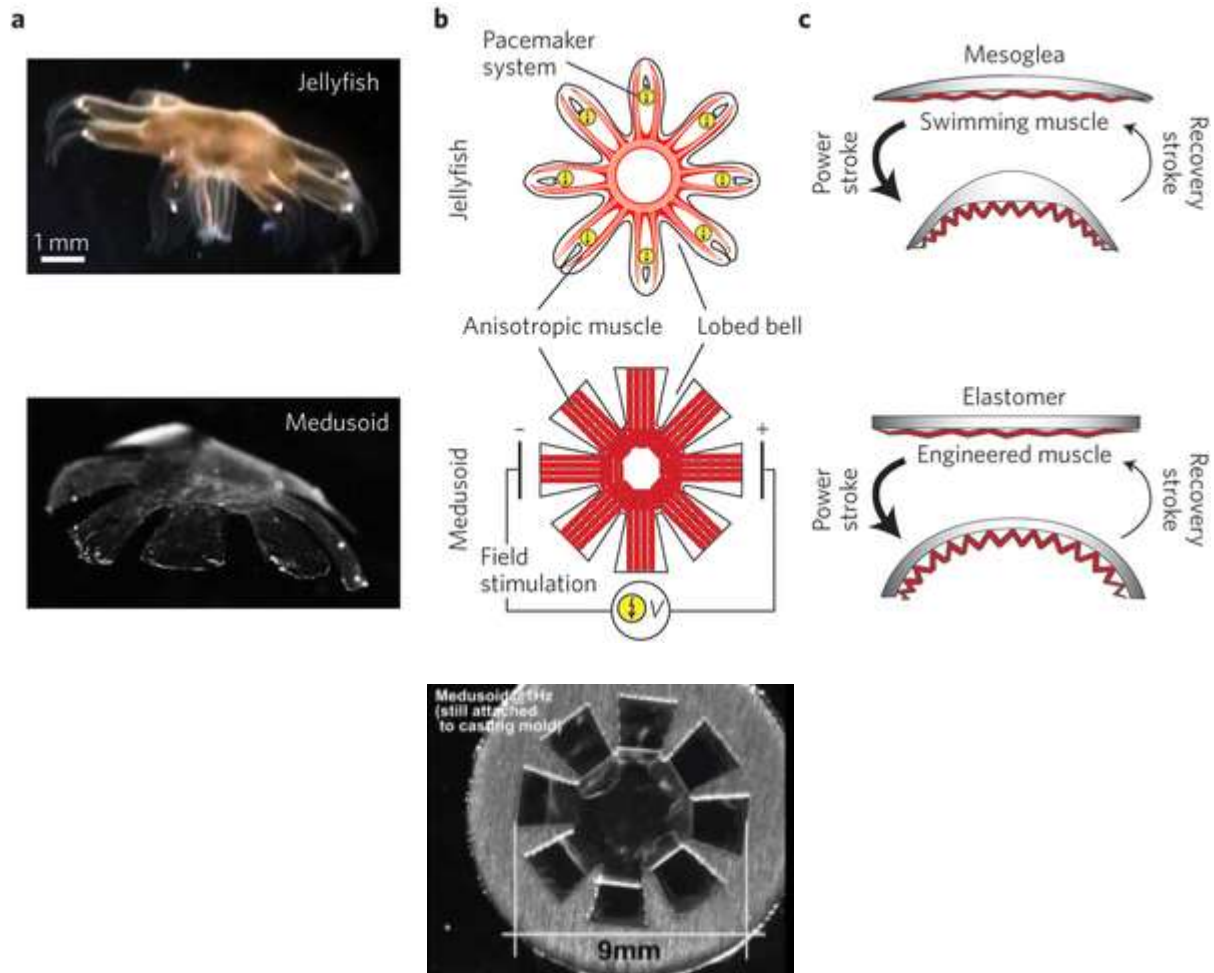
REGENERATION



DIFFERENTIATION IN VITRO



TISSUE ENGINEERING



<https://www.nature.com/articles/nbt.2269>

<https://www.nature.com/news/artificial-jellyfish-built-from-rat-cells-1.11046>

THANK YOU FOR ATTENTION

pvanhara@med.muni.cz

<http://www.med.muni.cz/histology>

