

Class III cavity

Location:

Proximal surfaces of incisors and canines without weakened or lost incisal edge

Material:

Composite

Glass ionomer (rather exceptionally, only if the cavity edges are not in the enamel, it is impossible to keep the working field dry – e.g. in handicapped patients)

Gaining access to the carious lesion:

Ball diamond or ball bur. We penetrate the carious lesion from the oral side, and guide the preparatory instrument obliquely from the adjacent tooth in order to minimize loss of tissues. We can keep enamel unsupported by dentin vestibulary.

Fig. 1: A carious lesion and the direction of the preparatory instrument

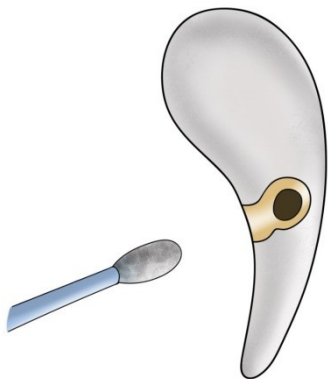


Fig. 2: Initiation of the preparation

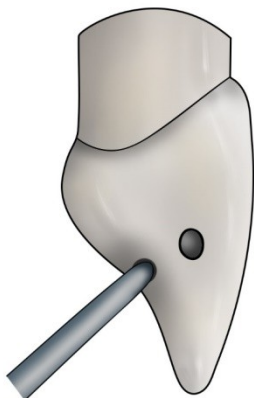
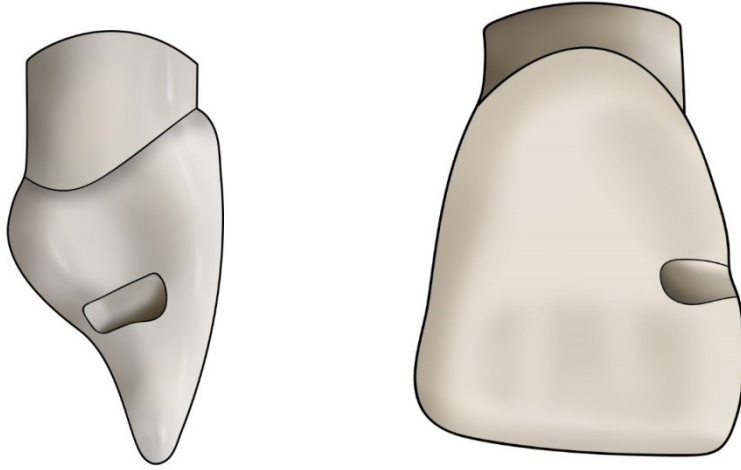
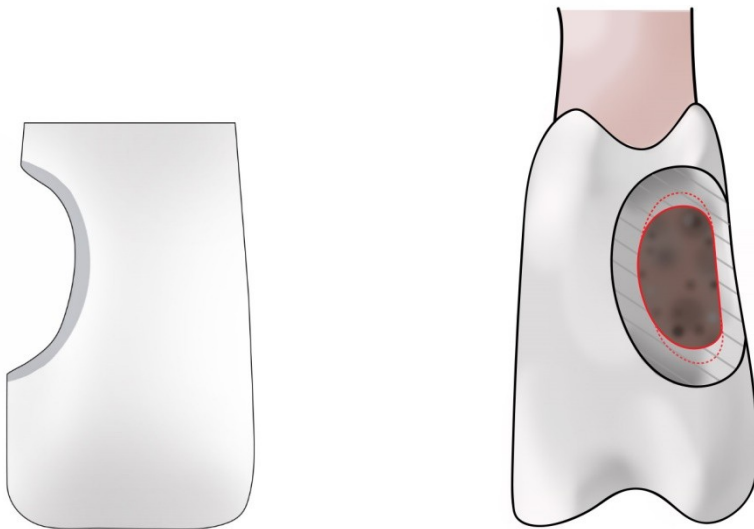


Fig. 3 a, b: Prepared cavity



We bevel the enamel at the outlines of the cavity by means of a diamond flame or pointed bur with fine grit – red code. We create a retentive border ca 1 mm wide.

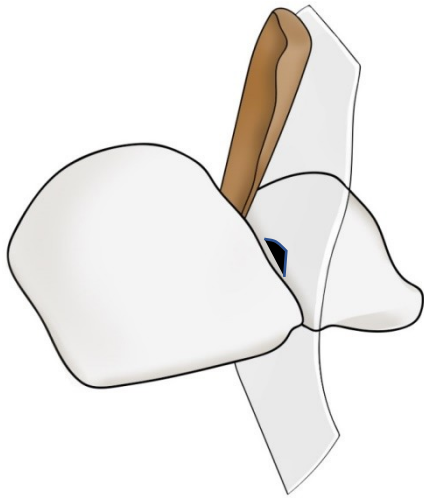
Fig. 4: Retentive border



MAKING OF THE FILLING

We work with a matrix – a transparent polyester band which is sealed by a wedge.

Fig. 5: Matrix (a transparent band sealed by a wedge)



The principle of retention of composite filling is a micromechanical bond (microretention) during which the composite material gets into microscopic spaces in enamel and dentin that have been prepared by orthophosphoric acid etching (35-37%). After securing a dry field, we apply the etching gel with content of acid – 20 s on enamel, 10 s on dentin. Then we wash the gel away and dry any excessive water. The next step is application of primer – it mediates the bond between composite and dentin. After its application and blowing, we apply the bond (it is identical with the organic compound of the composite, but it does not contain any filler). It flows into the microscopic unevennesses of enamel, dentin tubules and the collagen fibres of demineralized dentin. We blow it into a thin layer and polymer it by curing – with the light of polymerisation lamp. Then the composite is deposited in layers of ca 1 mm thick and their polymerisation follows. We begin from the oral side, the matrix can be pressed by a finger to the oral part of the tooth during application of the first layer.

Both primer and bond are applied with special brushes.

Fig. 6 a: The primer wets dentin and prevents the collapse of collagen fibres

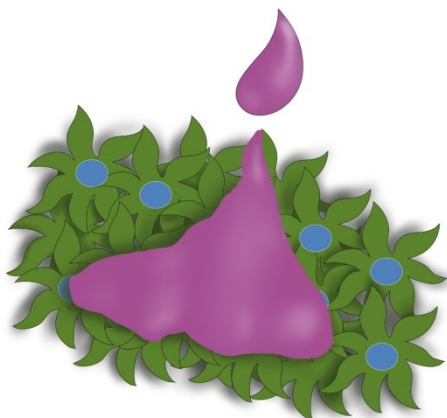
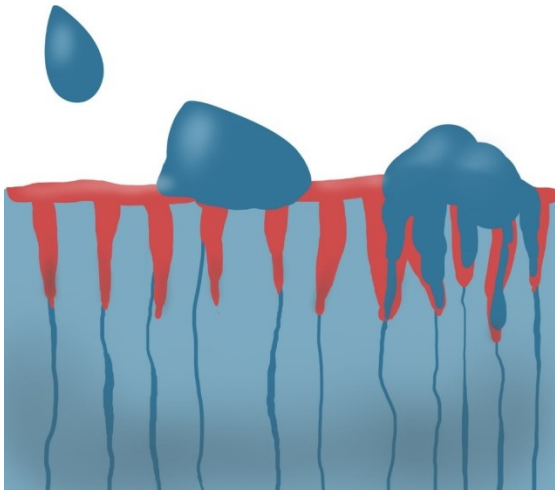


Fig. 6 b: The bond flows into the microscopic unevennesses and copolymerises with the composite



In the end, we treat the filling by very fine diamond burs (yellow code) and polish it with rubber tools and polishing discs. The transition between the filling and the tooth must be smooth. There are more concepts for composite polishing. Besides rubber tools, we can use special brushes, some of which have abrasive particles incorporated in them, others are used in combination with polishing pastes. Good tools are also flexible discs.